

# World Journal of *Gastrointestinal Oncology*

*World J Gastrointest Oncol* 2024 March 15; 16(3): 571-1090



## EDITORIAL

- 571 Synchronous gastric and colon cancers: Important to consider hereditary syndromes and chronic inflammatory disease associations  
*Shenoy S*
- 577 Neutrophil-to-lymphocyte ratio and platelet-to-lymphocyte ratio: Markers predicting immune-checkpoint inhibitor efficacy and immune-related adverse events  
*Jiang QY, Xue RY*
- 583 Early-onset gastrointestinal cancer: An epidemiological reality with great significance and implications  
*Triantafyllidis JK, Georgiou K, Konstadoulakis MM, Papalois AE*

## REVIEW

- 598 Management of obstructed colorectal carcinoma in an emergency setting: An update  
*Pavlidis ET, Galanis IN, Pavlidis TE*
- 614 Unraveling the enigma: A comprehensive review of solid pseudopapillary tumor of the pancreas  
*Xu YC, Fu DL, Yang F*

## MINIREVIEWS

- 630 Roles and application of exosomes in the development, diagnosis and treatment of gastric cancer  
*Guan XL, Guan XY, Zhang ZY*
- 643 Prognostic and predictive role of immune microenvironment in colorectal cancer  
*Kuznetsova O, Fedyanin M, Zavalishina L, Moskvina L, Kuznetsova O, Lebedeva A, Tryakin A, Kireeva G, Borshchev G, Tjulandin S, Ignatova E*
- 653 Pylorus-preserving gastrectomy for early gastric cancer  
*Sun KK, Wu YY*

## ORIGINAL ARTICLE

## Case Control Study

- 659 N-glycan biosignatures as a potential diagnostic biomarker for early-stage pancreatic cancer  
*Wen YR, Lin XW, Zhou YW, Xu L, Zhang JL, Chen CY, He J*
- 670 Expression and significance of pigment epithelium-derived factor and vascular endothelial growth factor in colorectal adenoma and cancer  
*Yang Y, Wen W, Chen FL, Zhang YJ, Liu XC, Yang XY, Hu SS, Jiang Y, Yuan J*

- 687 Impact of Alcian blue and periodic acid Schiff expression on the prognosis of gastric signet ring cell carcinoma

*Lin J, Chen ZF, Guo GD, Chen X*

#### Retrospective Cohort Study

- 699 Clinical profile and outcomes of hepatocellular carcinoma in primary Budd-Chiari syndrome

*Agarwal A, Biswas S, Swaroop S, Aggarwal A, Agarwal A, Jain G, Elhence A, Vaidya A, Gupte A, Mohanka R, Kumar R, Mishra AK, Gamanagatti S, Paul SB, Acharya SK, Shukla A, Shalimar*

- 716 Chinese herbal medicine decreases incidence of hepatocellular carcinoma in diabetes mellitus patients with regular insulin management

*Lai HC, Cheng JC, Yip HT, Jeng LB, Huang ST*

- 732 Combining systemic inflammatory response index and albumin fibrinogen ratio to predict early serious complications and prognosis after resectable gastric cancer

*Ren JY, Wang D, Zhu LH, Liu S, Yu M, Cai H*

- 750 Mucosa color and size may indicate malignant transformation of chicken skin mucosa-positive colorectal neoplastic polyps

*Zhang YJ, Yuan MX, Wen W, Li F, Jian Y, Zhang CM, Yang Y, Chen FL*

- 761 Epidemiology, therapy and outcome of hepatocellular carcinoma between 2010 and 2019 in Piedmont, Italy

*Bracco C, Gallarate M, Badinella Martini M, Magnino C, D'Agnano S, Canta R, Racca G, Melchio R, Serraino C, Polla Mattiot V, Gollè G, Fenoglio L*

- 773 Study on sex differences and potential clinical value of three-dimensional computerized tomography pelvimetry in rectal cancer patients

*Zhou XC, Ke FY, Dhamija G, Chen H, Wang Q*

#### Retrospective Study

- 787 High patatin like phospholipase domain containing 8 expression as a biomarker for poor prognosis of colorectal cancer

*Zhou PY, Zhu DX, Chen YJ, Feng QY, Mao YH, Zhuang AB, Xu JM*

- 798 Combining prognostic value of serum carbohydrate antigen 19-9 and tumor size reduction ratio in pancreatic ductal adenocarcinoma

*Xia DQ, Zhou Y, Yang S, Li FF, Tian LY, Li YH, Xu HY, Xiao CZ, Wang W*

- 810 Influence of transcatheter arterial embolization on symptom distress and fatigue in liver cancer patients

*Yang XM, Yang XY, Wang XY, Gu YX*

- 819 T2-weighted imaging-based radiomic-clinical machine learning model for predicting the differentiation of colorectal adenocarcinoma

*Zheng HD, Huang QY, Huang QM, Ke XT, Ye K, Lin S, Xu JH*

- 833 Predictive value of positive lymph node ratio in patients with locally advanced gastric remnant cancer

*Zhuo M, Tian L, Han T, Liu TF, Lin XL, Xiao XY*

- 844 Risk of cardiovascular death in patients with hepatocellular carcinoma based on the Fine-Gray model  
*Zhang YL, Liu ZR, Liu Z, Bai Y, Chi H, Chen DP, Zhang YM, Cui ZL*
- 857 Preoperatively predicting vessels encapsulating tumor clusters in hepatocellular carcinoma: Machine learning model based on contrast-enhanced computed tomography  
*Zhang C, Zhong H, Zhao F, Ma ZY, Dai ZJ, Pang GD*
- 875 Comparison of mismatch repair and immune checkpoint protein profile with histopathological parameters in pancreatic, peripapillary/ampullary, and choledochal adenocarcinomas  
*Aydin AH, Turhan N*
- 883 Assessment of programmed death-ligand 1 expression in primary tumors and paired lymph node metastases of gastric adenocarcinoma  
*Coimbra BC, Pereira MA, Cardili L, Alves VAF, de Mello ES, Ribeiro U Jr, Ramos MFKP*

### Observational Study

- 894 Identification of breath volatile organic compounds to distinguish pancreatic adenocarcinoma, pancreatic cystic neoplasm, and patients without pancreatic lesions  
*Tiankanon K, Pungpipattrakul N, Sukaram T, Chaiteerakij R, Rerknimitr R*
- 907 Clinical features and prognostic factors of duodenal neuroendocrine tumours: A comparative study of ampullary and nonampullary regions  
*Fang S, Shi YP, Wang L, Han S, Shi YQ*

### Clinical and Translational Research

- 919 Construction of an immune-related gene signature for overall survival prediction and immune infiltration in gastric cancer  
*Ma XT, Liu X, Ou K, Yang L*
- 933 Clinical efficacy and pathological outcomes of transanal endoscopic intersphincteric resection for low rectal cancer  
*Xu ZW, Zhu JT, Bai HY, Yu XJ, Hong QQ, You J*
- 945 Identification of a novel inflammatory-related gene signature to evaluate the prognosis of gastric cancer patients  
*Hu JL, Huang MJ, Halina H, Qiao K, Wang ZY, Lu JJ, Yin CL, Gao F*

### Basic Study

- 968 Verteporfin fluorescence in antineoplastic-treated pancreatic cancer cells found concentrated in mitochondria  
*Zhang YQ, Liu QH, Liu L, Guo PY, Wang RZ, Ba ZC*
- 979 Effects of *Helicobacter pylori* and Moluodan on the Wnt/ $\beta$ -catenin signaling pathway in mice with precancerous gastric cancer lesions  
*Wang YM, Luo ZW, Shu YL, Zhou X, Wang LQ, Liang CH, Wu CQ, Li CP*

- 991** Mitochondrial carrier homolog 2 increases malignant phenotype of human gastric epithelial cells and promotes proliferation, invasion, and migration of gastric cancer cells  
*Zhang JW, Huang LY, Li YN, Tian Y, Yu J, Wang XF*
- 1006** Ubiquitin-specific protease 21 promotes tumorigenicity and stemness of colorectal cancer by deubiquitinating and stabilizing ZEB1  
*Lin JJ, Lu YC*
- 1019** Long non-coding RNA GATA6-AS1 is mediated by N6-methyladenosine methylation and inhibits the proliferation and metastasis of gastric cancer  
*Shen JJ, Li MC, Tian SQ, Chen WM*
- 1029** CALD1 facilitates epithelial-mesenchymal transition progression in gastric cancer cells by modulating the PI3K-Akt pathway  
*Ma WQ, Miao MC, Ding PA, Tan BB, Liu WB, Guo S, Er LM, Zhang ZD, Zhao Q*

#### **META-ANALYSIS**

- 1046** Efficacy and safety of perioperative therapy for locally resectable gastric cancer: A network meta-analysis of randomized clinical trials  
*Kuang ZY, Sun QH, Cao LC, Ma XY, Wang JX, Liu KX, Li J*

#### **SCIENTOMETRICS**

- 1059** Insights into the history and tendency of glycosylation and digestive system tumor: A bibliometric-based visual analysis  
*Jiang J, Luo Z, Zhang RC, Wang YL, Zhang J, Duan MY, Qiu ZJ, Huang C*

#### **CASE REPORT**

- 1076** Managing end-stage carcinoid heart disease: A case report and literature review  
*Bulj N, Tomasic V, Cigrovski Berkovic M*
- 1084** Hemorrhagic cystitis in gastric cancer after nanoparticle albumin-bound paclitaxel: A case report  
*Zhang XJ, Lou J*

**ABOUT COVER**

Peer Review of *World Journal of Gastrointestinal Oncology*, Noha Elkady, MD, Assistant Professor, Department of Pathology, Faculty of Medicine Menoufia University, Shibin Elkom 32511, Egypt. drnohaelkady@gmail.com

**AIMS AND SCOPE**

The primary aim of *World Journal of Gastrointestinal Oncology* (WJGO, *World J Gastrointest Oncol*) is to provide scholars and readers from various fields of gastrointestinal oncology with a platform to publish high-quality basic and clinical research articles and communicate their research findings online.

WJGO mainly publishes articles reporting research results and findings obtained in the field of gastrointestinal oncology and covering a wide range of topics including liver cell adenoma, gastric neoplasms, appendiceal neoplasms, biliary tract neoplasms, hepatocellular carcinoma, pancreatic carcinoma, cecal neoplasms, colonic neoplasms, colorectal neoplasms, duodenal neoplasms, esophageal neoplasms, gallbladder neoplasms, *etc.*

**INDEXING/ABSTRACTING**

The WJGO is now abstracted and indexed in PubMed, PubMed Central, Science Citation Index Expanded (SCIE, also known as SciSearch®), Journal Citation Reports/Science Edition, Scopus, Reference Citation Analysis, China Science and Technology Journal Database, and Superstar Journals Database. The 2023 edition of Journal Citation Reports® cites the 2022 impact factor (IF) for WJGO as 3.0; IF without journal self cites: 2.9; 5-year IF: 3.0; Journal Citation Indicator: 0.49; Ranking: 157 among 241 journals in oncology; Quartile category: Q3; Ranking: 58 among 93 journals in gastroenterology and hepatology; and Quartile category: Q3. The WJGO's CiteScore for 2022 is 4.1 and Scopus CiteScore rank 2022: Gastroenterology is 71/149; Oncology is 197/366.

**RESPONSIBLE EDITORS FOR THIS ISSUE**

Production Editor: Xiang-Di Zhang; Production Department Director: Xiang Li; Editorial Office Director: Jia-Ru Fan.

**NAME OF JOURNAL**

*World Journal of Gastrointestinal Oncology*

**ISSN**

ISSN 1948-5204 (online)

**LAUNCH DATE**

February 15, 2009

**FREQUENCY**

Monthly

**EDITORS-IN-CHIEF**

Monjur Ahmed, Florin Burada

**EDITORIAL BOARD MEMBERS**

<https://www.wjgnet.com/1948-5204/editorialboard.htm>

**PUBLICATION DATE**

March 15, 2024

**COPYRIGHT**

© 2024 Baishideng Publishing Group Inc

**INSTRUCTIONS TO AUTHORS**

<https://www.wjgnet.com/bpg/gerinfo/204>

**GUIDELINES FOR ETHICS DOCUMENTS**

<https://www.wjgnet.com/bpg/GerInfo/287>

**GUIDELINES FOR NON-NATIVE SPEAKERS OF ENGLISH**

<https://www.wjgnet.com/bpg/gerinfo/240>

**PUBLICATION ETHICS**

<https://www.wjgnet.com/bpg/GerInfo/288>

**PUBLICATION MISCONDUCT**

<https://www.wjgnet.com/bpg/gerinfo/208>

**ARTICLE PROCESSING CHARGE**

<https://www.wjgnet.com/bpg/gerinfo/242>

**STEPS FOR SUBMITTING MANUSCRIPTS**

<https://www.wjgnet.com/bpg/GerInfo/239>

**ONLINE SUBMISSION**

<https://www.f6publishing.com>



## Management of obstructed colorectal carcinoma in an emergency setting: An update

Efstathios T Pavlidis, Ioannis N Galanis, Theodoros E Pavlidis

**Specialty type:** Oncology

**Provenance and peer review:**

Invited article; Externally peer reviewed.

**Peer-review model:** Single blind

**Peer-review report's scientific quality classification**

Grade A (Excellent): 0

Grade B (Very good): B

Grade C (Good): C

Grade D (Fair): D

Grade E (Poor): 0

**P-Reviewer:** Feng B, China; Qi L, China; Yan B, China

**Received:** October 21, 2023

**Peer-review started:** October 21, 2023

**First decision:** December 6, 2023

**Revised:** December 6, 2023

**Accepted:** January 16, 2024

**Article in press:** January 16, 2024

**Published online:** March 15, 2024



**Efstathios T Pavlidis, Ioannis N Galanis, Theodoros E Pavlidis**, 2<sup>nd</sup> Propedeutic Department of Surgery, Hippokration General Hospital, School of Medicine, Aristotle University of Thessaloniki, Thessaloniki 54642, Greece

**Corresponding author:** Theodoros E Pavlidis, Doctor, PhD, Emeritus Professor, Surgeon, 2<sup>nd</sup> Propedeutic Department of Surgery, Hippokration General Hospital, School of Medicine, Aristotle University of Thessaloniki, 49 Konstantinoupoleos, Thessaloniki 54642, Greece. [pavlidth@auth.gr](mailto:pavlidth@auth.gr)

### Abstract

Colorectal carcinoma is common, particularly on the left side. In 20% of patients, obstruction and ileus may be the first clinical manifestations of a carcinoma that has advanced (stage II, III or even IV). Diagnosis is based on clinical presentation, plain abdominal radiogram, computed tomography (CT), CT colonography and positron emission tomography/CT. The best management strategy in terms of short-term operative or interventional and long-term oncological outcomes remains unknown. For the most common left-sided obstruction, the first choice should be either emergency surgery or endoscopic decompression by self-expandable metal stents or tubes. The operative plan should be either one-stage or two-stage resection. One-stage resection with on-table bowel decompression and irrigation can be accompanied or not accompanied by proximal defunctioning stoma (colostomy or ileostomy). Primary anastomosis is more convenient but has increased risks of anastomotic leakage and morbidity. Two-stage resection (Hartmann's procedure) is safer and the most widely used despite temporally affecting quality of life. Damage control surgery in high-risk frail patients is less frequently performed since it can be successfully substituted with endoscopic stenting or tubing. For the less common right-sided obstruction, one-stage surgical resection is more beneficial than endoscopic decompression. The role of minimally invasive surgery (laparoscopic or robotic) is a subject of debate. Emergency laparoscopic-assisted management is advantageous to some extent but requires much expertise due to inherent difficulties in dissecting the distended colon and the risk of rupture and subsequent septic complications. The decompressing stent as a bridge to elective surgery more substantially decreases the risks of morbidity and mortality than emergency surgery for decompression and has equivalent medium-term overall survival and disease-free survival rates. Its combination with neoadjuvant chemotherapy or radiation may have a positive effect on long-term oncological outcomes. Management plans are crucial and must be individualized to better fit each case.



**Key Words:** Acute abdomen; Obstructive ileus; Colorectal carcinoma; Emergency surgery; Colectomy; Intraluminal metal stents

©The Author(s) 2024. Published by Baishideng Publishing Group Inc. All rights reserved.

**Core Tip:** Acute obstruction is common in patients with more advanced colorectal carcinoma and may be the first manifestation mainly of left-sided obstruction and in elderly individuals. Emergency decompression is mandatory. Emergency surgical resection and primary anastomosis accompanied or not accompanied by proximal defunctioning stoma must be the first treatment choice for fit patients under 70 years. Hartmann's two-stage procedure, although more preferable, must be the second alternative choice. Emergency endoscopic self-expandable metal stents must be preferred in unfit patients as a bridge to surgery and for palliative treatment in all inoperable cases. However, these basic management principles constitute a general direction. Decision-making is important and should be individualized.

**Citation:** Pavlidis ET, Galanis IN, Pavlidis TE. Management of obstructed colorectal carcinoma in an emergency setting: An update. *World J Gastrointest Oncol* 2024; 16(3): 598-613

**URL:** <https://www.wjgnet.com/1948-5204/full/v16/i3/598.htm>

**DOI:** <https://dx.doi.org/10.4251/wjgo.v16.i3.598>

## INTRODUCTION

Colorectal carcinoma is common, with its incidence increasing in young adults, and left-sided obstruction being the most common. It is the third most common carcinoma, after lung, and breast or prostate carcinoma and the second leading cause of cancer-related deaths, after lung carcinoma, in the United States and Western Europe, causing more than 50000 deaths annually in the United States[1-3]. Early detection and proper management improves survival and avoids complications (mainly obstruction, perforation, bleeding, and fistula)[4-8].

In 20%-30% of patients, mainly geriatrics, obstruction and ileus may be the first clinical manifestations of carcinoma that has advanced (stage II, III, or even IV)[2,9-12]. It is a potentially fatal condition that requires emergency intestinal decompression[3,13], and various models that predict the risk of mortality have been developed[14]. On the other hand, obstruction is the most common cause (75%-80%) of presentation to the emergency department among patients with colorectal carcinoma[15]. Younger age (under 50 years), males, and those with ascending colon obstruction have a greater possibility of presenting to the emergency department for care[3,8]. Subsequently, colorectal cancer screening is necessary to prevent obstruction. Screening is recommended, particularly for those with predisposing factors such as a family history of colorectal cancer or sleep apnea[2].

Strategies for the emergency management of left-sided obstruction in patients with colorectal cancer have been described in various guidelines[16], however, strategies for the management of right-sided obstruction in colorectal carcinoma patients are somewhat different, clearly advising one-stage resection[17-20].

The growth pattern of colorectal carcinoma has been estimated. The median doubling time was 211 d, and the median rate of increase in tumor volume was 34.1% per 62 d[21].

The best management strategy in terms of short-term operative or interventional and long-term oncological outcomes remains unknown[16,22,23]. Early decompression is crucial because it prevents further bowel distention, ischemia and perforation, leading to fecal peritonitis and septic shock[23,24].

For left-sided obstruction, the first choice should be either emergency surgery or endoscopic decompression by self-expandable metal stent placement[10,22,25-27] or rectal tubes[19,28-31] as a bridge to surgery. However, there have been conflicting aspects. Stenting is not considered to be the gold standard. It may be related to possible perforation that causes septic subsequences leading to severe sepsis and septic shock. In addition, micro-perforation may promote cancer cell diffuse dissemination and distant metastasis. For rectal carcinoma, stenting is associated with technical difficulties and more stent migration[17,32].

The operative plan should be either one-stage or two-stage resection or, rarely, three-stage resection. One-stage resection with on-table bowel decompression and irrigation could be accompanied or not accompanied by proximal defunctioning stoma (colostomy or ileostomy)[16,22,23]. For obstructions in patients with low rectal carcinoma, major resections, even extensive pelvic surgery, may be performed in selected cases[33] despite the increased risk of morbidity, including empty pelvic syndrome (mainly small intestinal obstruction) and subsequent mortality[34].

Operative management of such emergency cases, regardless of preoperative multimorbidity or not, is related to higher risks of mortality and morbidity than nonoperative interventional management[35]. It is well known that both diabetes mellitus and liver cirrhosis increase the risks of postoperative morbidity and mortality, especially in patients treated with colorectal surgery and in those requiring emergency treatment. Thus, such morbidities should be considered when selecting the type of surgery[11,36].

A model was recently constructed that could accurately predict the risk of 30-day mortality after emergency operation for acute abdomen, including colorectal obstruction. It is based on a scoring system including 13 preoperative factors and may be valuable in deciding to perform an emergency operation, considering its kind, duration, and intensity[37].



Choosing the best management strategy can be challenging, and the choice should be evaluated under careful consideration of the patient's physical status and the condition caused by the present disease, taking into account that for colorectal operative interventions, the risk of inpatient mortality is increased by 6.9%, as has been assessed recently. This indicates that more conservative and interventional treatment may be more favorable in severe cases[38].

One-stage resection with primary anastomosis is more convenient but has increased risks of anastomotic leakage and morbidity[24]. Subtotal or total resection is a less common alternative[17].

Two-stage resection (Hartmann's procedure) is safer and the most widely used procedure worldwide despite temporally negatively affecting quality of life. It has been preferred over the three-stage procedure[16,17,24].

Damage control surgery in high-risk frail patients has been less frequently performed since it can be successfully substituted with metal stent or drainage tubing placement[39,40].

The role of minimally invasive surgery (laparoscopic or robotic) is still a subject of debate. Initial emergency laparoscopic management has been performed in approximately 20% of cases[41]; after initial stenting as a bridge to surgery, elective laparoscopic management has been performed in 32% of cases[24]. However, although emergency laparoscopic-assisted management is advantageous to some extent, it requires much expertise due to inherent difficulties in dissecting the distended colon and the risks of rupture and subsequent septic complications[41].

The decompressing stent as a bridge to elective surgery more substantially reduces the risks of morbidity and mortality than emergency surgery for decompression and has equivalent medium-term overall and disease-free survival rates[42]. Its combination with neoadjuvant chemotherapy or radiation for rectal cancer may have a positive effect on oncological outcomes[43].

Genetic studies may be needed mainly to prevent and, less commonly, diagnose colorectal carcinoma in cases of anorectal outlet obstruction that causes persistent constipation, since many studies have found a correlation between them [44].

This narrative review evaluates the current knowledge on severe obstruction in patients with colorectal carcinoma, emphasizing proper diagnosis and emergency management. This study was based on a large body of literature published in PubMed until September 2023, focusing particularly on full-text papers published only in the English language over the last five years.

## Diagnosis

Large bowel obstruction may be predominantly located on the left side (65%) but also the right side (35%)[45], as the boundary is considered to be the splenic flexure. They have the same clinical manifestation of obstructive ileus but somewhat different management[17].

Diagnosis is based on clinical examination and imaging. The onset is characterized by suspension of gas and feces, abdominal distension, deep pain or fullness, and nausea or possible vomiting. Vomiting is more apparent and earlier on the right side, while the distention is more obvious on the left side[15].

Plain abdominal radiogram shows marked colon dilation with possible small bowel dilation and air-fluid levels[46].

Computed tomography (CT) is needed to confirm tumor existence and its precise location. CT is the first choice imaging technique for the evaluation of colorectal obstruction and perforation[40].

Colonoscopy can assess the entire colon and confirm the presence of a tumor in cases requiring differentiation from pseudo-obstruction (Ogilvie's syndrome)[2,12,47-49].

This need for complete colon evaluation in patients with left-sided obstruction is mandatory because it may reveal another proximal synchronous neoplastic lesion in 3%-11% of cases, which modifies the management policy. However, this is often impossible because the endoscope cannot pass through the obstruction caused by the tumor or provides limited view of an unprepared colon. In such cases, CT colonography or even positron emission tomography/CT could be a valuable imaging modality influencing the operative strategy[47].

A large retrospective study conducted in China including 1474 patients operated on for obstructed colorectal carcinoma found, by multivariate analysis, several prediction factors for diagnosis and better management of obstruction. They include neutrophil to lymphocyte ratio, albumin and total protein levels, gamma-glutamyl transpeptidase, alkaline phosphatase, carbohydrate antigen 19-9, carcinoembryonic antigen, and carbohydrate antigen 125[50].

Another study conducted in China including 472 patients evaluated a new serum biomarker of chemokine ligand-7 that has been proposed for the diagnosis and prognosis of obstructed colorectal carcinoma[51].

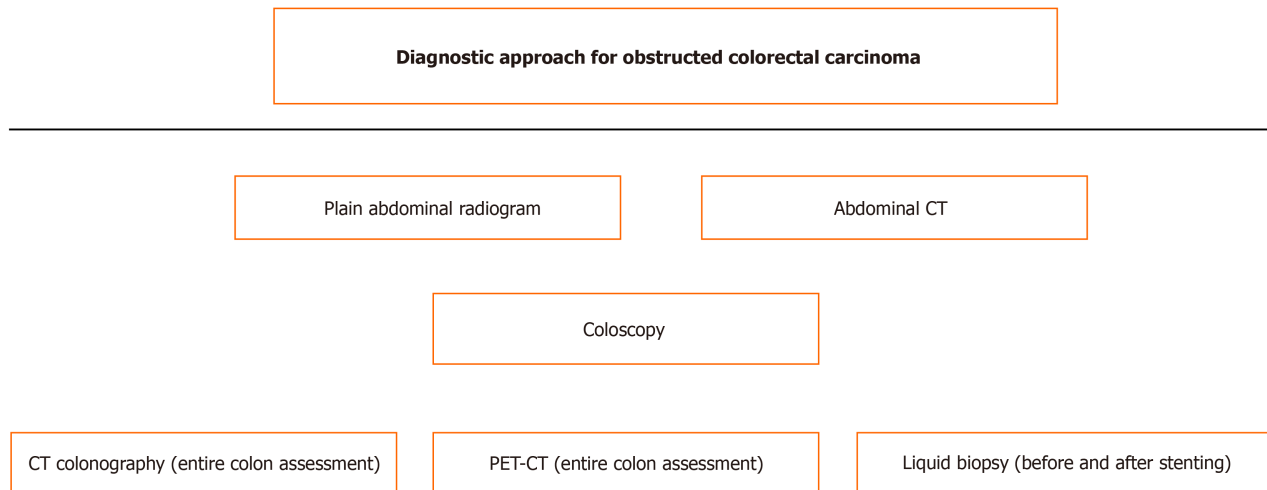
Liquid biopsy could detect circulating cancer cells or their parts in serum before and after stenting mainly for prospective research efforts[52,53].

The surgical risk score has been found to be a reliable independent factor for predicting morbidity and mortality, which could be helpful in management decision-making[54]. The diagnostic steps are shown schematically in Figure 1.

## MANAGEMENT

### Applicable guidelines

In the World Society of Emergency Surgery guidelines, right colectomy is the treatment method of choice for right-sided obstruction. Self-expandable metallic stents are related to better short-term outcomes than emergency surgery for decompression of a left-sided obstruction. However, they may have unclear long-term oncological outcomes, particularly in patients appropriate for curative resection. Subsequently, the recommendation of self-expandable metallic stents (SEMS) as a bridge to surgery must be limited in selected cases and by expertise. Primary anastomosis is preferred over Hartmann's two-stage procedure for suitable patients by experienced surgeons[40].



**Figure 1 Scheme of diagnostic steps for obstructed colorectal carcinoma.** CT: Computed tomography; PET-CT: Positron emission tomography/computed tomography.

According to the European Society of Gastrointestinal Endoscopy, although initially in 2014, the use of self-expandable metallic stents as a bridge to surgery was strongly discouraged but, since 2020, has been recommended after discussion and decision sharing with patients highly likely to be cured by surgical intervention. The time interval until surgical intervention must not exceed 2 wk. Stenting is indicated as the method of choice for palliation in patients with inoperable tumors[55].

In the American Society of Colon and Rectal Surgeons guidelines, either emergency therapeutic radical resection or SEMS as a bridge-to-surgery mainly laparoscopic resection, are recommended. The choice of management should be individualized according to patient-related factors, equipment availability and expertise of the center. The rate of successful stent placement fluctuates between 77% and 81%, and the perforation rate fluctuates between 2% and 9% but is accompanied by an increased recurrence risk. Tumors at other locations (synchronous) may be managed either by two segmental colon resections or subtotal colectomy[56].

### Other general considerations

The current management policy depends on the location of acute obstruction. For right-sided curable obstruction, a therapeutic surgical intervention is indicated in most cases[18]. For left-sided obstruction, various choices exist, including curative resection accompanied or not accompanied by primary anastomosis, endoscopic stent placement usually or drainage placement, and diverting stoma formation[15,22,24,57]. It should be individualized in most cases[23] and according to a reliable scoring system[58]. The management options are shown schematically in Figure 2.

A large study conducted in Denmark and the United Kingdom (Yorkshire) assessed the trends in the surgical management of colorectal carcinoma in both elective and emergency settings. Emergency resection rates were similar in both countries (15%), increasing with age and disease stage. Emergency resection rates decreased in Denmark mainly for left-sided obstruction, whereas the rate of endoscopic stenting has increased, but it was less than 2% for right-sided obstruction. There was a slight increase in the incidence of endoscopic stenting in the United Kingdom for left-sided obstruction. The mortality rate reduced significantly over time in both elective and emergency settings and in both countries[59].

Emergency decompression, either decompressing stoma or endoscopic stenting as a bridge to subsequent surgical resection on an elective basis, is considered to be highly beneficial for high-risk patients, particularly in geriatric frail patients equal to or above 70 years[60].

A large retrospective multicenter study conducted in the Netherlands including almost all hospitals (75 out of 77) and 2587 patients with curative resection of obstructed left-sided colorectal carcinoma (among them, 345 cases of decompressing stoma and 229 cases of endoscopic stenting) showed a decreasing trend in the incidence (from 86.2% to 69.6%) of reversal of emergency resection and an increasing trend in the incidence (from 1.3% to 7.8%) of self-expandable metal stent implantation along with a continuing increase (from 5.2% to 22.7%) in the incidence of decompressing stoma creation. The latter was related to more subsequent laparoscopic resections (66% vs 35.5%), more two-stage operations (41.5% vs 28.6%, respectively), and fewer permanent stoma creations (14.7% vs 29.5%, respectively). Despite these favorable progressions, the rates of morbidity (40%) and mortality (7%) in these high-risk patients remained rather high[61].

Another debatable issue concerns the optimal time interval between acute decompression and second-time curative resection. A comparative study conducted in the Netherlands including 168 patients with a time between decompression and repeat resection less than and more than 4 wk found a decrease in mortality (1.8% vs 12.3%) and an increase in 5-year survival (75% vs 51.4%)[62].

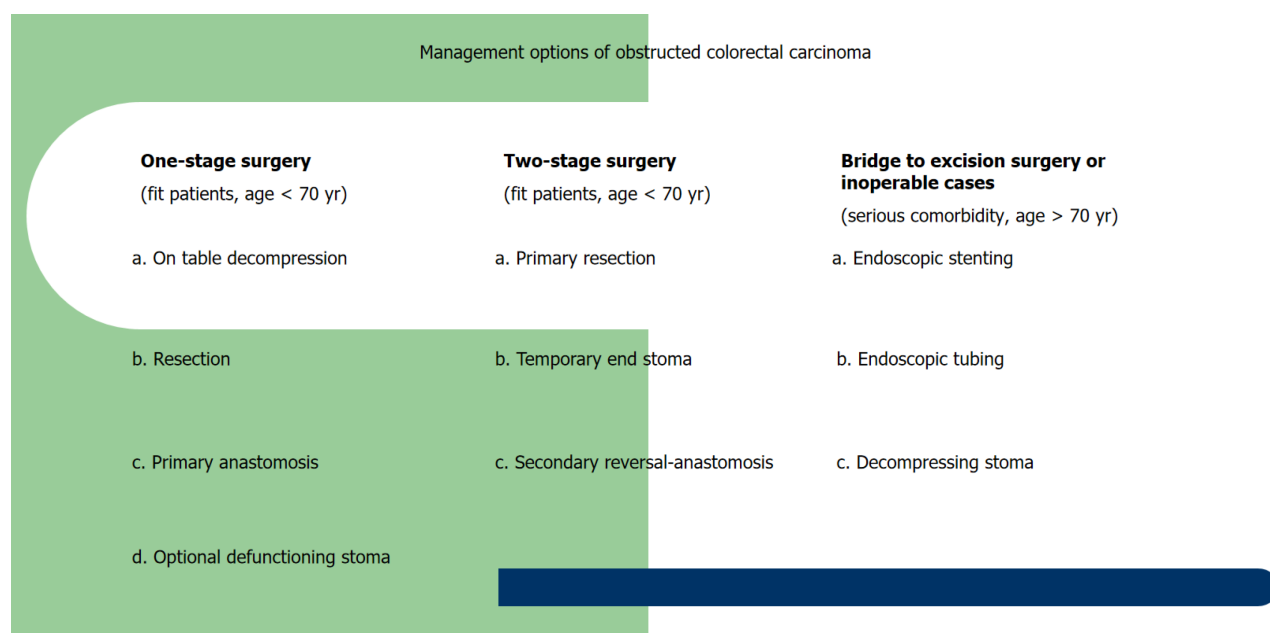


Figure 2 Scheme of management options for obstructed colorectal carcinoma.

### Endoscopic stenting

Self-expendable metal stents were introduced almost 20 years ago to relieve left-sided colorectal carcinoma stenosis. Since then, much progress has been made in improving the quality of equipment material, interventional techniques and expertise. There is no disagreement for their use in inoperable cases for palliative treatment[32,63-66], which in addition is more cost-effective and has shorter hospitalization than emergency surgery[67]. However, whether they should be applied as a bridge to surgery in suitable patients with potentially curable tumors, who could undergo therapeutic surgical intervention initially without any delay, remains a subject of debate.

The main argument in favor of stenting is based on the high possibility of a subsequent elective resection procedure instead of a high-risk emergency resection that has increased risks of morbidity and mortality[25,66,68-70]. Furthermore, it may increase the possibility of primary anastomosis limiting the creation of stomas and the chance for laparoscopic operations[1,32,39,65,71].

On the other hand, fears and reservations have to do with the risk of perforation and mainly microperforations that facilitate the spread of cancer cells. "Do not touch", a basic postulate of traditional oncological surgery, means avoiding any manipulations of the tumor to prevent its dissemination. Notably, manipulations are not extrinsically high-risk but rather intrinsically high-risk (endoluminal) as there is a risk of partially fragmenting the tumor, thus opening the lumen [13,31,32,52,53].

Two cycles of preoperative chemotherapy with fluorouracil, leucovorin and oxaliplatin have been recommended to manage any cancer cell dissemination after stenting as a bridge to surgery restricting any potential unwilling effect of stent application[72]. It seems reasonable, but there are not survival data supporting this choice.

Self-expendable metal stents may be covered or uncovered and have diameters ranging between 10 and 25 mm and lengths between 60 and 12 mm[32,63,73]. A covered stent exhibited a higher migration rate and lower obstruction rate than an uncovered stent. Among the most commonly used are WallFlex, Niti-S, HANAROSTENT Naturfit, and JE-NTLLY. Complications may occur in less than 5% of cases, including bleeding, perforation, migration and obstruction. Given that stenting takes place under endoscopic and fluoroscopic guidance, sufficient experience in both colonoscopy and fluoroscopy is needed[32,48].

The use of super-flexible metal stents has been proposed for the management of acute obstruction, where passing the stent through the right and left colonic curve may be difficult as it may be highly tortuous[74].

An interesting case in which a fully covered self-expandable metal stent was used for cecostomy to relieve an inoperable ascending colon malignant obstruction after failed percutaneous cecum catheterization was previously reported [75].

A systematic review and meta-analysis revealed that uncovered metal stents were related to fewer complications, tumor overgrowth, stent migration or need for reinsertion, and more stent patency; thus, they are more preferable to covered metal stents[76].

Migration is the main disadvantage of covered stents, which may occur in up to 40% of cases. A recent prospective randomized control trial conducted in Korea including 60 patients compared two types of covered stents, *i.e.*, Flare and ComV. They found the following acceptable and comparable short-term results: (1) Technical success of 90% *vs* 96.7%; (2) clinical success of 85.2% *vs* 75.9%; and (3) stent migration of 11.1% *vs* 13.8%[77].

Perforation and peritonitis are more likely to occur after stenting in cases of benign acute obstructions. Thus, in benign cases, careful stenting is required due to an inherent high risk of perforation (22.4%), as suggested by a large nationwide study conducted in the United States including 4257 patients with self-expendable metal stent placement for relief of

acute large bowel obstruction[78]. The evaluation of short-term stenting outcomes is shown in Table 1.

Balloon dilatation is not recommended before stenting. Plain abdominal radiogram after stenting is necessary to assess the stent position and to exclude perforation based on the absence of intraabdominal free-air[48,79]. A multicenter retrospective study conducted in Japan including 129 patients with therapeutic surgery after stenting found that patients with postoperative infection had worse oncological outcomes, affecting relapse-free survival[48]. While the short-term outcomes are well studied and not conflicting, the long-term oncological outcomes remain unclear[13,32,80].

A nationwide retrospective cohort study conducted in the United States including 9706 patients with left-sided obstructed colorectal carcinoma found that a minority of 9.7% underwent stenting as a bridge to surgery, while most of them underwent emergency surgery. The bridging rate increased from 7.7% in 2010 to 16.4% in 2016. It was related to a lower incidence of stoma formation than emergency surgery and had comparable short-term outcomes in terms of morbidity and mortality rates. There were no long-term oncological outcomes[1].

There have been conflicting aspects about the safety and long-term oncological outcomes of self-expendable metal stents used as a bridge to surgery for left-sided acute obstruction in patients with colorectal carcinoma. A recent study conducted in Spain including 110 such patients showed a technical success rate of 95.7% and clinical effectiveness rate of 91.3%; a perforation rate of 13% and migration, occlusion rate of 2.9%; a higher rate following laparoscopic colectomy; a lower rate of colostomy, morbidity and mortality than emergency curative resection; and similar rates with the latter of overall survival and disease-free survival[39].

Another recent study conducted in Spain including 92 patients with obstructed left-sided colorectal carcinoma (two-thirds as bridging and one-third for palliation of inoperable tumor) reported a technical success rate of 92.4%, clinical effectiveness rate of 89.1% and perforation rate of 9.8%[63].

Another recent study conducted in Japan assessing the use of self-expendable metal stents with low axial force in 202 patients for the management of left-sided obstruction in patients with colorectal carcinoma, the technical success rate was 97.5%, clinical effectiveness rate was 96%, stent migration rate was 1%, stent occlusion rate was 1.5%, and there was no perforation attributed to that type of stent[81].

A retrospective study conducted in China including 434 patients using a two-person method reported a technique success rate of 98.6%, clinical effectiveness rate of 94.9% and complication rate of 4.4%. These included mainly bowel perforation (1.4%), stent migration (0.5%), stent detachment (0.7%) and stool impaction (1.4%)[49].

In a retrospective comparative study conducted in Japan including 48 patients with left-sided colorectal carcinoma, as a bridge to surgery, decompression by self-expendable metal stents or transanal tubes had similar complication and 5-year survival rates but the stenting group had better clinical success rates, shorter time to oral intake and better albumin levels [28]. Likewise, a systematic review and meta-analysis showed results in favor of metal stents, even in obstructions located in the right colon[29]. The comparison of results between stenting and tubing as a bridge to surgery is shown in Table 2.

A retrospective comparative study conducted in Egypt including 65 patients with American Society of Anesthesiologists (ASA) scores  $\geq$  III, acute obstruction and an inoperable case of colorectal carcinoma stage IV located in the rectosigmoid region assessed the short-term outcomes of both stenting and Hartmann's operation. They reported technical success for all stenting cases, indicating similar effectiveness and safety for operable cases but better recovery and shorter hospitalization[82].

A retrospective study conducted in the United States including 199 patients who underwent stenting for obstructed inoperable colorectal carcinoma stage IV found a high technical success rate but not proportional clinical effectiveness. The perforation rate was comparable in patients treated with and without bevacizumab[83].

Another retrospective comparative study conducted in Spain including 95 patients with obstructed inoperable colorectal carcinoma stage IV underwent stenting or emergency surgical resection. They found that both were effective, but surgery did not influence survival; thus, it is not recommended[84].

A recent systematic review and meta-analysis including 10 studies and 1273 patients found higher perineural and lymphatic invasion after stenting as a bridge to surgery that led to worse overall survival than initial surgery[85].

Another recent systematic review and meta-analysis including 27 studies and 3894 patients after stenting as a bridge to surgery found similar results for initial surgery, 3-year and 5-year disease-free survival and overall survival[86]. Comparison results of emergency resection and endoscopic stenting as bridge to surgery is shown in Table 3.

In a recent multicenter prospective study conducted in 46 Japanese hospitals, WallFlex stents were implanted in 208 patients with left-sided obstruction of colorectal carcinoma (stage II and III) and not only were short-term outcomes evaluated but also long-term oncological outcomes. They found interesting rates: (1) Overall survival: 1-year of 94.1%, 3-year of 77.4%, 5-year of 67.4%; (2) relapse free survival: 1-year of 81.6%, 3-year of 65.6%, 5-year of 57.9%; (3) technical success of 99% and clinical success rate of 92.8%; (4) perforation of 1.9% and migration, occlusion rate of 1.3%; and (5) overall recurrence of 31% and it was poorer in four perforation cases. These long-term outcomes have been considered satisfactory and attributed to a notably low perforation rate[87].

A retrospective nationwide comparative study conducted in Sweden including 196 patients with acute obstruction colorectal carcinoma assessed the long-term outcomes between stenting and colostomy as a bridge to surgery. They found comparable long-term outcomes but less permanent colostomy, more surgical resections, and shorter hospitalization in the stenting group[88].

### Endoscopic tube drainage

Endoscopic transanal drainage tubes (retrograde bowel drainage tubes or Dennis colorectal tubes) have been used as alternatives to endoscopic self-expendable metal stents as bridges to surgery for decompression of acute left-sided colorectal obstruction, thus avoiding the need for a high-risk emergency surgery and stoma formation[28,29,31,53].



**Table 1 Evaluation of endoscopic stenting short-term outcomes**

Ref.	Patients (Nu)	Study	Tech success (%)	Clin success (%)	Perforation (%)	Migration occlusion (%)
Recuenco <i>et al</i> [39]	69	Single center retrospective Spain	97.5	91.3	13	2.9
Angulo McGrath <i>et al</i> [63]	92	Single center retrospective Spain	92.4	89.1	9.8	-
Sasaki <i>et al</i> [81]	202	Single center retrospective Japan	97.5	96	0	2.5
Yan <i>et al</i> [49]	434	Single center retrospective China	98.6	94.9	1.4	0.5
Kuwai <i>et al</i> [87]	208	Multicenter prospective Japan	99	92.8	1.9	1.3
Lee <i>et al</i> [77]	60	Single center retrospective Korea	93.3	80.5	5.3	12.5

**Table 2 Comparison results of endoscopic stenting and endoscopic tubing**

Ref.	Patients (Nu)	Study	Clin success	Complications	Survival
Inoue <i>et al</i> [28]	48	Single center retrospective Japan	Better in stenting (100% vs 80.6%)	Similar (0 vs 4%)	Equivalent (5-yr: 69.5% vs 38.4%)
Xu <i>et al</i> [29]	704	Meta-analysis China	Better in stenting (94.5% vs 86.1%)	Fewer in stenting (6.9% vs 12.4%)	-
Kagami <i>et al</i> [30]	53	Single center retrospective Japan	Better in stenting (100% vs 81.8%)	Fewer in stenting (0 vs 18.2%)	Equivalent (3-yr: 73% vs 80.9%)
Matsuda <i>et al</i> [89]	581	Meta-analysis Japan	Better in stenting (93.2% vs 77.3%)	Equivalent (5.5% vs. 11.7%)	-
Numata <i>et al</i> [31]	225	Multicenter prospective Japan	Better in stenting (92.6% vs 75.3%)	Fewer post-operative in stenting (21.1% vs 33.3%)	Similar (3 yr: 87.1% vs 90.5%)
Takahashi <i>et al</i> [53]	35	Single center prospective Japan	Similar (88% vs 90%)	Similar (12% vs 10%)	<sup>1</sup> Increased circulating DNA on day 7 in stenting (992 vs 308 ng/mL)
Suzuki <i>et al</i> [18]	40	Single center retrospective Japan	Similar (89.5% vs 85.7%)	Similar (10.5% vs 14.2%)	Better in tubing (5 yr: 79.5% vs 32%)

<sup>1</sup>Highlight of importance.

However, metal stents have been proven to be more effective and related to fewer complications than drainage tubes [28,29]. Likewise, a study conducted in Japan including 53 patients with obstructed left-sided colorectal carcinoma compared endoscopic transanal tubes and endoscopic self-expandable metal stents for decompression as a bridge to surgery. They found better short-term outcomes for stenting and equivalent long-term outcomes (3-year overall survival of 80.9% for tubing and 73% for stenting)[30].

A meta-analysis including 581 patients compared the short-term outcomes between endoscopic transanal tubes and self-expandable metal stents for decompression as a bridge to surgery in obstructed colorectal carcinoma. They found that stenting and tubing had equivalent morbidity and mortality after surgery[89].

A recent multicenter study conducted in Japan including 10 hospitals and 225 patients with obstructed colorectal carcinoma compared transanal decompression tubes and self-expandable metal stents. They found similar long-term outcomes, *i.e.*, 3-year relapse-free survival (66.7% vs 69.9%) and 3-year overall survival (90.5% vs 87.1%), between the tubing and stenting groups. However, the short-term outcome showed that stenting was favored over tubing regarding less stoma formation, fewer complications and shorter hospitalization[31].

Another study conducted in Japan including 35 patients with obstructed colorectal carcinoma performed genomic analysis (liquid biopsy) in addition to clinical outcome assessment and compared transanal tubes and self-expandable metal stents. They found similar short-term outcomes, but stenting increased the levels of circulating cell-free DNA and circulating tumor DNA in plasma, in contrast to no increase in the tubing group. This was attributed to mechanical compression causing tumor injury and could have a negative effect on the long-term oncological outcome[53].

Otherwise, for right-sided obstructed colorectal carcinoma, although the method of choice must be emergency curative surgical resection, a study conducted in Japan including 40 patients compared endoscopic tubes (transanal or transnasal) and endoscopic self-expandable metal stents as the choice for bridging to surgery and found similar morbidity, clearly

**Table 3 Comparison results of emergency resection and endoscopic stenting as bridge to surgery**

Ref.	Patients (Nu)	Study	Morbidity	Mortality	Long-term outcome
McKechnie <i>et al</i> [24]	9403	Meta-analysis Canada	Similar (27.2% vs 27.8%)	Improved in stenting (4.4% vs 6.1%)	Equivalent (insufficient data)
Paniagua García-Señoráns <i>et al</i> [42]	251	Single centre Retrospective Spain	Improved in stenting (36% vs 62.5%)	Equivalent (5.3% vs 6.3%)	Equivalent (3-yr DFS: 31.4.6% vs 33.4%, 3-yr OS: 37.5% vs 36.1%)
Wang <i>et al</i> [70]	78	Single centre Retrospective China	Similar (16.2% vs 26.8%)	Similar (0 vs 4.9%)	Similar (median overall survival: 36 months for both groups)
Hadaya <i>et al</i> [1]	9706	Nation-wide United States	Similar (12.2% vs 14.4%)	Similar (1.2% vs 3.4%)	Undetermined
Balciscueta <i>et al</i> [85]	1273	Meta-analysis Spain	-	-	Worse in stenting; <sup>1</sup> Higher risk of perineural (45.6% vs 32.6%)- lymphatic (47.4 % vs 42%) invasion
Spannenburg <i>et al</i> [86]	3894	Meta-analysis Australia	Improved in stenting (26.09% vs 41.4%)	Improved in stenting (6.5% vs 8.1%)	Similar recurrence (31% vs 25%)
Boeding <i>et al</i> [101]	600	Meta-analysis Netherlands	Improved in stenting (30% vs 42%)	Improved in stenting (1.2% vs 7.2%)	Similar (5-yr DFS: 65.6% vs 63.1%, 5-yr OS: 66.9% vs 64%)

<sup>1</sup>Highlight of importance.

DFS: Disease-free survival; OS: Overall survival.

better 5-year overall survival (79.5% vs 32%), and 3-year disease-free survival (68.9% vs 45.9%) rates in the tubing group than in the stenting group[18]. The advantages and disadvantages of tubing and stenting are shown in Table 4.

## SURGERY

### General considerations

Surgery constitutes the main treatment option for obstructed colorectal carcinoma stage II or III, aiming for a potent sustainable or permanent cure[17,19,24,90]. For right-sided obstruction involving the cecum, ascending colon, hepatic flexure, and transverse colon, the operative plan is clear and depends basically on therapeutic right colectomy with extended lymphadenectomy that includes complete transverse mesocolon excision and primary anastomosis. The addition of a defunctioning loop ileostomy is optional according to the assessment of local intraoperative conditions[17,19,40,91].

A recent nationwide retrospective study conducted in the Netherlands including 525 patients with obstructed right-sided colon carcinoma found that primary resection and anastomosis were performed in 88% of patients with defunctioning ileostomy (25%), and staged resection after stenting or tubing was used as a bridge to surgery in 5% of cases[20].

A French nationwide retrospective study including 776 patients with right obstructed colon cancer showed primary resection 92% accompanied by anastomosis 82% with added defunctioning loop ileostomy 3.6% or accompanied by double-end stoma 18%; diverting stoma 8% or ileocolic bypass 1.7% as palliation. They found postoperative morbidity 51%, anastomotic leakage 10%, mortality 10%, 5-year overall survival of 42%, disease-free survival of 42% and cancer-specific survival of 62%. By multivariate analysis, the following predictive factors were found for severe morbidity: Age > 70 years, ASA score ≥ 3, and hemodynamic instability; for reduced overall survival: peritonitis, synchronous metastases, and no adjuvant chemotherapy. The high morbidity and mortality may indicate staged management in high-risk patients[19].

In addition to radical traditional right colectomy, extended right colectomy removes the entire transverse colon with both flexures when the carcinoma involves the transverse colon, and primary ileocolic anastomosis is the method of first choice. A defunctioning proximal loop ileostomy may sometimes be preferred. Additionally, excision without anastomosis but an end ileostomy is sometimes needed[17].

For left-sided obstruction involving the splenic flexure, descending colon, sigmoid, and rectum, there are several different operative plans, but the optimal management is conflicting. Wide resection with extended lymphadenectomy, including total mesocolon or mesorectal excision, primary anastomosis or Hartmann's procedure, is the most widely used. Other operative options include subtotal or total colectomy with ileorectal anastomosis, when large dilatation and ischemic changes of the colon exist, urgent decompressing colostomy followed by surgical resection in the first stage and anastomosis in the second stage (two-stage procedure) and colostomy reversal in the third stage (three-stage procedure) [16].

The French nationwide study including 1500 patients with obstructed left-sided colorectal carcinoma found that their primary management was based on endoscopic stenting in 18% of cases. Emergency surgical management consists of diverting colostomy (38%), segmental colectomy (27%), Hartmann's procedure (20%), and subtotal colectomy (15%). By

**Table 4 Advantages and disadvantages of stenting and tubing**

Method	Advantages	Disadvantages
Endoscopic stenting	Higher clinical success; fewer complications	More expensive
Endoscopic tubing	Lower cost	Lower clinical success; more complications

multivariate analysis, diverting colostomy and segmental colectomy had a better prognosis than the other two operative options. They advocated, as surgical options, diverting colostomy in high-risk patients, and Hartmann's procedure or subtotal colectomy in cases with ischemia or perforation[90].

For left-sided acute obstruction, the choice of emergency decompression colostomy or endoscopic stenting depends on the management plan. The former is preferable in operable cases, while the latter is preferable in inoperable cases as palliative treatment[92].

A systematic review and meta-analysis showed primary anastomosis was more frequent in patients with decompressing stoma, with higher costs (2000 \$), and higher recurrence rates found in patients with stenting as a bridge to surgery; subsequently, these findings advocate in favor of stoma instead of stenting for emergency decompression[93].

Total mesocolon excision, which is of great importance for harvested lymph node extended dissection and determines the radicality of surgical resection affecting the oncological outcome, has been found that after sigmoidectomy for carcinoma, it is not related to remote bowel dysfunction or impairment in quality of life[91].

Various methods have been applied for stoma creation, either ileostomy or colostomy, to avoid the main complication of parastomal hernia. It may occur in 40% of cases within 2 years, affecting quality of life and causing obstructive ileus [94].

Pelvic exenteration even in the emergency setting, such as acute obstruction of rectal carcinoma, could be performed safely in terms of radicality, offering satisfactory results with a 3-year overall survival of 54.4%[33].

For splenic flexure location (5%), there are operative difficulties, which increase morbidity and mortality; thus, much attention must be paid during surgery. Similar technical difficulties may be encountered with stent placement in such locations. A recent large French multicenter study including 58 centers and 2325 patients with obstructed colorectal carcinoma, among whom 11% had splenic flexure obstruction and stenting in only 11.4%, found the following surgical interventions: (1) Decompressing stoma (39%); (2) segmental colectomy (39%); (3) subtotal colectomy (17%); and (4) left colectomy (5%). The rate of intraoperative complications was 3% and that of anastomotic leakage was 4%, without differences among the surgical procedures in terms of postoperative complications and oncological outcomes[46].

The previously mentioned French nationwide study including all 1957 patients with obstructive colorectal cancer recently compared the results of 56 centers with different hospital volumes. They found that it did not affect the outcomes of emergency management alone, but when the outcome of overall management was assessed, it influenced the morbidity and mortality without affecting the oncological outcome[95].

A retrospective study conducted in China including 839 patients with emergency surgery for obstructed colorectal carcinoma evaluated a modified ERAS protocol (enhanced recovery after surgery). They found faster bowel movements, fewer complications and shorter hospitalization[96].

The incidence of surgical site infections, the main cause of nosocomial infections, is increased after emergency surgery for obstructed colorectal carcinoma[97].

It has been reported that in inoperable obstructed carcinoma with peritoneal metastases, debulking surgery could improve symptom relief and survival without increasing morbidity and mortality[98].

### One-stage procedure

One-stage resection with on-table bowel decompression and irrigation accompanied by primary anastomosis must be the preferred choice in younger (under 70 years), fit patients without major comorbidities, with ASA score I or II[17,40,99,100]. A recent systematic review including 9 studies and 600 patients with obstructed right-sided colorectal carcinoma found that one-stage surgery had more complications (42% *vs* 30%) and higher mortality (7.2% *vs* 1.2%) but similar 5-year overall and disease-free survival when compared to staged treatment[101].

A distended colon without any preparation discourages many surgeons from performing primary anastomosis, thus preferring Hartmann's procedure. However, the performance of anastomosis and the addition of a defunctioning stoma may overcome these fears. Given Hartmann's procedure reversal can occur at least 3-6 months after the initial operation, or even never, sometimes disturbing the quality of life[102], it is often more complicated and copious than reversal within one month of a right-sided loop transverse colostomy or loop ileostomy; thus, this addition could be a reasonable alternative to Hartmann's procedure[16,22,23,40].

A recent retrospective multicenter study conducted in Japan including 520 patients with obstructed colorectal carcinoma who had a primary surgical resection compared the outcomes of elderly patients 75 years and older (resection rate of 79%) with nonelderly patients (resection rate of 90%). They found similar short-term outcomes and recurrence-free survival but higher 90-d mortality in the elderly group. This finding may indicate urgent primary decompression followed by elective surgery in elderly patients[103].

Although the routine use of prophylactic intraabdominal drainage for colorectal anastomosis is not recommended in general, for emergency primary anastomosis due to obstructed colorectal carcinoma, it is a justifiable choice[104].



### Two-stage procedure

This approach basically avoids the need for primary anastomosis and includes: (1) The most widely applicable Hartmann's procedure since its first introduction in 1920, in which primary rectosigmoid resection is performed, but without primary anastomosis, accompanied by temporary end sigmoid colostomy, with secondary anastomosis and its reversal; and (2) primary decompressing proximal colostomy, secondary resection and anastomosis abolishing the primary stoma [22,46,82,105,106].

Emergency stoma for urgent decompression may be either transverse colostomy (right-left) and sigmoid colostomy or loop ileostomy of the terminal ileum. Second, elective surgical resection and anastomosis can be performed in operable cases[46].

The site of colostomy depends on the tumor location and preference of the surgeon. Comparing transverse colostomy to sigmoid colostomy, no other difference was found, but the latter had a lower risk of prolapse than the former[7].

A recent study conducted in Taiwan including 191 patients with left-sided obstructed colorectal carcinoma showed that the two-stage procedure had more complications (57.1% *vs* 36%) than the three-stage procedure, including mainly surgical site infection and wound dehiscence. In addition, they found similar rates of anastomotic leakage, 5-year overall survival (33% *vs* 35%), and 5-year disease-free survival (60% *vs* 58.4%)[16]. There are well-defined incriminating factors for wound dehiscence after colorectal carcinoma surgery[107], which must be considered, particularly in emergency surgery.

Decompressing colostomy as a bridge to surgery for left-sided obstructed colorectal carcinoma is being more frequently performed. A recent nationwide study conducted in 75 Dutch hospitals including 236 patients who underwent emergency decompression colostomy and 472 patients who underwent emergency resection for left-sided obstructed colorectal carcinoma compared the results of these two management options. They found that primary decompression colostomy was accompanied by more subsequent laparoscopic resections and anastomoses (56.8% *vs* 9.2%) than primary resection, lower 90-d mortality (1.7% *vs* 7.2%) and permanent stoma (23.4% *vs* 42.4%) rates, and higher 3-year overall survival rates (79.4% *vs* 73.3%). This two-stage surgical management approach could be followed to improve outcomes, particularly in elderly individuals over 70 years[108].

It has been found that the reversal of Hartmann's procedure is associated with a notable morbidity of 34%, including mainly surgical site infection (22%) and anastomotic leakage (5%), and mortality of 8.3%, especially in patients with obesity and a high ASA score ( $\geq 3$ )[106].

Neoadjuvant chemotherapy after emergency decompressing stoma creation and before subsequent elective resection may be an option that could improve the prognosis[109].

### Three-stage procedure

This approach has not gained wide acceptance and follows a two-stage procedure, the primary decompressing stoma was created, which was left in site for possible protection of secondary anastomosis and would be closed a third time[16].

### Minimally invasive surgery

The applicability of emergency laparoscopic surgery for left-sided obstructed colorectal carcinoma is limited[24]. A nationwide study conducted in the Netherlands compared the results of 158 patients who underwent emergency laparoscopic surgery and 474 patients who underwent emergency open surgery. They found that the laparoscopic approach was favored over open surgery. It was associated with fewer 90-d complications (26.6% *vs* 38.4%), similar 90-d mortality, increased 3-year overall survival (81% *vs* 69.4%) and disease-free survival (68.3% *vs* 52.3%). Laparoscopic surgery in an emergency setting exhibits lower morbidity and higher 3-year survival rates but requires expertise and equipment to overcome the difficulties of a distended bowel to avoid causing iatrogenic perforation injury[41]. Endoscopic incision and dilation of the anastomotic stricture after colectomy can be used [110].

### Prognosis

It is well known that emergency surgery reduces long-term survival in cancer patients. It has also been confirmed in emergency colorectal resection[111]. A recent study conducted in Austria including 59 patients (4.5%) who underwent emergency colectomy for colorectal carcinoma among 1297 patients treated with elective colectomy for colorectal carcinoma found that emergency resection reduced 5-year overall survival (35.6% *vs* 64.4%) and disease-free survival (54.2% *vs* 75.4%) and increased 1-year recurrence (47.5% *vs* 25.4%) rates. The 5-year overall survival rate for elective cases was higher in laparoscopic than open colectomy (71.4% *vs* 62.2%)[4]. Right-sided obstruction, despite more primary resections and anastomoses, is related to a worse prognosis than left-sided obstruction[45].

A recent nationwide retrospective study conducted in the Netherlands including 525 patients managed for obstructed (7%) and 6891 patients managed for nonobstructive (93%) right-sided colon carcinoma found that in all stages, obstruction was associated with worse 90-d mortality (10% *vs* 3%) and 5-year overall survival (42% *vs* 73%) than no obstruction [20].

Mortality after emergency surgery for obstructed colorectal carcinoma reaches up to 11.72%. Various high-risk predictive factors were identified, including right-sided location, age 70 years or more, cachexia, obesity, septic conditions, and increased creatinine and platelet levels[112].

Obstructions involving the splenic flexure have a worse prognosis than those in other locations[46]. Obese patients with obstructive colorectal cancer exhibit more severe clinical presentation than those without obesity and similar postoperative morbidity but more colostomy complications in left-sided cases[113].

Comorbidities such as cardiovascular, cerebral, chronic obstructive disease and diabetes mellitus may affect the oncological outcome of colorectal carcinoma patients, including acute obstruction[114].

After emergency surgery for obstructed colorectal carcinoma, elderly patients have increased morbidity and reduced survival, mainly those over 84 years[105]. The finding of an obstructive colorectal carcinoma on colonoscopy predicts more advanced stage and reduced overall survival[115]. Some prognostic systems, such as the modified inflammation marker Glasgow score, may predict the long-term oncological outcome in obstructed colorectal carcinoma[116].

## CONCLUSION

Obstructed colorectal carcinoma is common in the emergency setting and is the main cause of colon-related obstructive ileus mainly in elderly patients. It requires emergency decompression to prevent more severe complications. For right-sided obstructions, one-stage emergency resection surgery and primary anastomosis are widely accepted. For left-sided obstructions, there are conflicting aspects. Emergency one-stage on-table bowel decompression, surgical resection and primary anastomosis accompanied or not, by loop right transverse colostomy or loop ileostomy, must be the method of choice for fit patients under 70 years. However, in daily clinical practice, the two-stage Hartmann's procedure is favored worldwide. In unfit patients, emergency decompression by endoscopic self-expandable metal stents mainly or decompressing tubes as a bridge to surgery must be the first choice. The alternative second choice is decompressing colostomy. Stenting is also indicated in all inoperable cases as palliation. Laparoscopic management requires considerable relevant experience but is associated with better short-term and possibly long-term outcomes. Management plans are crucial, and decision-making must be individualized to better fit each case, covering all needs and thus improving the results.

## FOOTNOTES

**Author contributions:** Pavlidis TE designed research, contributed new analytic tools, analyzed data and review; Galanis IN analyzed data and review; Pavlidis ET performed research, analyzed data, review and wrote the paper.

**Conflict-of-interest statement:** There is no conflict of interest associated with any of the senior author or other coauthors contributed their efforts in this manuscript.

**Open-Access:** This article is an open-access article that was selected by an in-house editor and fully peer-reviewed by external reviewers. It is distributed in accordance with the Creative Commons Attribution NonCommercial (CC BY-NC 4.0) license, which permits others to distribute, remix, adapt, build upon this work non-commercially, and license their derivative works on different terms, provided the original work is properly cited and the use is non-commercial. See: <https://creativecommons.org/licenses/by-nc/4.0/>

**Country/Territory of origin:** Greece

**ORCID number:** Efstathios T Pavlidis 0000-0002-7282-8101; Ioannis N Galanis 0009-0001-4283-0788; Theodoros E Pavlidis 0000-0002-8141-1412.

**S-Editor:** Qu XL

**L-Editor:** A

**P-Editor:** Xu ZH

## REFERENCES

- 1 Hadaya J, Verma A, Sanaiha Y, Mabeza RM, Chen F, Benharash P. Preoperative stents for the treatment of obstructing left-sided colon cancer: a national analysis. *Surg Endosc* 2023; **37**: 1771-1780 [PMID: 36220989 DOI: 10.1007/s00464-022-09650-8]
- 2 Samuel G, Kratzer M, Asagbra O, Kinderwater J, Poola S, Udom J, Lambert K, Mian M, Ali E. Facilitators and barriers to colorectal cancer screening in an outpatient setting. *World J Clin Cases* 2021; **9**: 5850-5859 [PMID: 34368304 DOI: 10.12998/wjcc.v9.i21.5850]
- 3 Singh P, Patel K, Arya P, Singh E, Mishra A. A Comparison of Emergency First Presentations of Colorectal Cancer in Under-50 and Over-50 Year-Old Patients. *J Invest Surg* 2020; **33**: 514-519 [PMID: 30644772 DOI: 10.1080/08941939.2018.1545060]
- 4 Esswein K, Ninkovic M, Gasser E, Barenberg L, Perathoner A, Kafka-Ritsch R. Emergency resection is an independent risk factor for decreased long-term overall survival in colorectal cancer: a matched-pair analysis. *World J Surg Oncol* 2023; **21**: 310 [PMID: 37759235 DOI: 10.1186/s12957-023-03182-8]
- 5 Rudolph C, Engholm G, Pritzkeleit R, Storm HH, Katalinic A. Colorectal Cancer Survival in German-Danish Border Regions-A Registry-Based Cohort Study. *Cancers (Basel)* 2023; **15** [PMID: 37760444 DOI: 10.3390/cancers15184474]
- 6 Tan WJ, Lin W, Sultana R, Foo FJ, Tang CL, Chew MH. A prognostic score predicting survival following emergency surgery in patients with metastatic colorectal cancer. *ANZ J Surg* 2021; **91**: 2493-2498 [PMID: 34374482 DOI: 10.1111/ans.17065]
- 7 Dylen MYC, Lee JWK, Ting LY, Ragupathi T, Yu NJ, Lim F, Farouk R, Seng CC. Transverse Colostomy Differs in Outcomes Compared to Sigmoid Colostomy: A Cohort Analysis. *J Invest Surg* 2022; **35**: 783-787 [PMID: 34334098 DOI: 10.1080/08941939.2021.1956025]
- 8 Ali G, Shaikat A, Masood S, Akram B, Ghaffar A, Gondal KM. A Profile of Colorectal Tumors Presenting as Emergency. *J Coll Physicians Surg Pak* 2021; **31**: 74-78 [PMID: 33546538 DOI: 10.29271/jcpsp.2021.01.74]
- 9 Ndlovu N, Kader S, Moodley Y, Cheddie S, Madiba TE. A South African central hospital's experience with malignant colorectal obstruction. *S Afr J Surg* 2023; **61**: 139-143 [PMID: 37381812 DOI: 10.36303/SAJS.3854]
- 10 Lauro A, Binetti M, Vaccari S, Cervellera M, Tonini V. Obstructing Left-Sided Colonic Cancer: Is Endoscopic Stenting a Bridge to Surgery or

- a Bridge to Nowhere? *Dig Dis Sci* 2020; **65**: 2789-2799 [PMID: 32583222 DOI: 10.1007/s10620-020-06403-2]
- 11 **Schootman M**, Jeffe DB, Ratnapradipa KL, Eberth JM, Davidson NO. Increased 30-Day Mortality Risk in Patients With Diabetes Mellitus After Colon Cancer Surgery: A Mediation Analysis. *Dis Colon Rectum* 2020; **63**: 290-299 [PMID: 31977584 DOI: 10.1097/DCR.0000000000001586]
  - 12 **Bento JH**, Bianchi ET, Tustumi F, Leonardi PC, Junior UR, Ceconello I. Surgical Management of Malignant Intestinal Obstruction: Outcome and Prognostic Factors. *Chirurgia (Bucur)* 2019; **114**: 343-351 [PMID: 31264572 DOI: 10.21614/chirurgia.114.3.343]
  - 13 **Seo SY**, Kim SW. Endoscopic Management of Malignant Colonic Obstruction. *Clin Endosc* 2020; **53**: 9-17 [PMID: 31906606 DOI: 10.5946/ce.2019.051]
  - 14 **Chan HC**, Huang CC, Chattopadhyay A, Yeh KH, Lee WC, Chiang CJ, Lee HY, Cheng SH, Lu TP. Predicting Colon Cancer-Specific Survival for the Asian Population Using National Cancer Registry Data from Taiwan. *Ann Surg Oncol* 2022; **29**: 853-863 [PMID: 34427821 DOI: 10.1245/s10434-021-10646-2]
  - 15 **EuroSurg Collaborative**. Acute PresentatiOn of coLorectaL cancer - an internatiOnal snapshot (APOLLO): Protocol for a prospective, multicentre cohort study. *Colorectal Dis* 2023; **25**: 144-149 [PMID: 36579365 DOI: 10.1111/codi.16464]
  - 16 **Lin YZ**, Cheng HH, Huang SC, Chang SC, Lan YT. Comparison of two-stage and three-stage surgery for obstructing left-sided colon cancer. *ANZ J Surg* 2022; **92**: 1466-1471 [PMID: 35357758 DOI: 10.1111/ans.17639]
  - 17 **Yoo RN**, Cho HM, Kye BH. Management of obstructive colon cancer: Current status, obstacles, and future directions. *World J Gastrointest Oncol* 2021; **13**: 1850-1862 [PMID: 35070029 DOI: 10.4251/wjgo.v13.i12.1850]
  - 18 **Suzuki Y**, Moritani K, Seo Y, Takahashi T. Comparison of decompression tubes with metallic stents for the management of right-sided malignant colonic obstruction. *World J Gastroenterol* 2019; **25**: 1975-1985 [PMID: 31086465 DOI: 10.3748/wjg.v25.i16.1975]
  - 19 **Mege D**, Manceau G, Beyer-Berjot L, Bridoux V, Lakkis Z, Venara A, Voron T, Brunetti F, Sielezneff I, Karoui M; AFC (French Surgical Association) Working Group. Surgical management of obstructive right-sided colon cancer at a national level results of a multicenter study of the French Surgical Association in 776 patients. *Eur J Surg Oncol* 2018; **44**: 1522-1531 [PMID: 30041941 DOI: 10.1016/j.ejso.2018.06.027]
  - 20 **Boeding JRE**, Elferink MAG, Tanis PJ, de Wilt JHW, Gobardhan PD, Verhoef C, Schreinemakers MJ. Surgical treatment and overall survival in patients with right-sided obstructing colon cancer-a nationwide retrospective cohort study. *Int J Colorectal Dis* 2023; **38**: 248 [PMID: 37796315 DOI: 10.1007/s00384-023-04541-3]
  - 21 **Burke JR**, Brown P, Quyn A, Lambie H, Tolan D, Sagar P. Tumour growth rate of carcinoma of the colon and rectum: retrospective cohort study. *BJS Open* 2020; **4**: 1200-1207 [PMID: 32996713 DOI: 10.1002/bjs.5.50355]
  - 22 **Giordano A**, Podda M, Montori G, Botteri E, Fugazzola P, Ortenzi M, Guerrieri M, Vettoretto N, Agresta F, Sartori A, Bergamini C, Martellucci J, Guariniello A, Fransvea P, Azzinnaro A, Scatizzi M, Catena F, Cocolini F, Ansaloni L, Sartelli M, Sapienza P, Mingoli A, Prosperi P. Colonic Resection, Stoma, or Self-expanding Metal Stents for Obstructive Left Colon Cancer: the CROSCO-I study protocol. *Minerva Surg* 2023 [PMID: 37705392 DOI: 10.23736/S2724-5691.23.09969-0]
  - 23 **Girardot-Miglierina A**, Kefleyesus A, Clerc D, Grass F, Demartines N, Hübner M, Hahnloser D. [Obstructed colon cancer: which strategy in 2022?]. *Rev Med Suisse* 2022; **18**: 1192-1199 [PMID: 35703861 DOI: 10.53738/REVMED.2022.18.786.1192]
  - 24 **McKechnie T**, Springer JE, Cloutier Z, Archer V, Alavi K, Doumouras A, Hong D, Eskicioglu C. Management of left-sided malignant colorectal obstructions with curative intent: a network meta-analysis. *Surg Endosc* 2023; **37**: 4159-4178 [PMID: 36869265 DOI: 10.1007/s00464-023-09929-4]
  - 25 **Chan DKH**, Tan KK. Stenting versus surgery in obstructed malignant colorectal cancer-a review of short and long-term results. *J Gastrointest Oncol* 2020; **11**: 486-490 [PMID: 32655926 DOI: 10.21037/jgo.2020.01.08]
  - 26 **Lam J**, Chauhan V, Lam I, Kannappa L, Salama Y. Colorectal stenting in England: a cross-sectional study of practice. *Ann R Coll Surg Engl* 2020; **102**: 451-456 [PMID: 32347738 DOI: 10.1308/rcsann.2020.0077]
  - 27 **Webster PJ**, Aldoori J, Burke DA. Optimal management of malignant left-sided large bowel obstruction: do international guidelines agree? *World J Emerg Surg* 2019; **14**: 23 [PMID: 31139245 DOI: 10.1186/s13017-019-0242-5]
  - 28 **Inoue H**, Arita T, Kuriu Y, Shimizu H, Kiuchi J, Yamamoto Y, Konishi H, Morimura R, Shiozaki A, Ikoma H, Kubota T, Fujiwara H, Okamoto K, Otsuji E. Emergency Management of Obstructive Colorectal Cancer - A Retrospective Study of Efficacy and Safety in Self-expanding Metallic Stents and Trans-anal Tubes. *In Vivo* 2021; **35**: 2289-2296 [PMID: 34182508 DOI: 10.21873/in vivo.12502]
  - 29 **Xu J**, Zhang S, Jiang T, Zhao YJ. Transanal drainage tubes vs metallic stents for acute malignant left-sided bowel obstruction: A systematic review and meta-analysis. *Medicine (Baltimore)* 2020; **99**: e18623 [PMID: 31914042 DOI: 10.1097/MD.00000000000018623]
  - 30 **Kagami S**, Funahashi K, Ushigome M, Koike J, Kaneko T, Koda T, Kurihara A, Nagashima Y, Yoshino Y, Goto M, Mikami T, Chino K. Comparative study between colonic metallic stent and anal tube decompression for Japanese patients with left-sided malignant large bowel obstruction. *World J Surg Oncol* 2018; **16**: 210 [PMID: 30333034 DOI: 10.1186/s12957-018-1509-0]
  - 31 **Numata K**, Numata M, Shirai J, Sawazaki S, Okamoto H, Godai T, Katayama Y, Atsumi Y, Kazama K, Uchiyama M, Kohmura T, Mushiaki H, Sugano N, Higuchi A, Kato A, Iguchi K, Rino Y, Shiozawa M. Short- and long-term outcomes of transanal decompression tube and self-expandable metallic stent for obstructive colorectal cancer based on a multicenter database (KYCC2110). *J Surg Oncol* 2023; **128**: 1372-1379 [PMID: 37753717 DOI: 10.1002/jso.27454]
  - 32 **Binetti M**, Lauro A, Tonini V. Colonic stent for bridge to surgery for acute left-sided malignant colonic obstruction: A review of the literature after 2020. *World J Clin Oncol* 2022; **13**: 957-966 [PMID: 36618078 DOI: 10.5306/wjco.v13.i12.957]
  - 33 **Thiptanakit C**, Chowchankit I, Panya S, Kanjanasilp P, Malakorn S, Pattana-Arun J, Sahakitrungruang C. Urgent Pelvic Exenteration: Should the Indication Be Extended? *Dis Colon Rectum* 2018; **61**: 561-566 [PMID: 29624550 DOI: 10.1097/DCR.0000000000001083]
  - 34 **Nekkanti SS**, Jajoo B, Mohan A, Vasudevan L, Peelay Z, Kazi M, Desouza A, Saklani A. Empty pelvis syndrome: a retrospective audit from a tertiary cancer center. *Langenbecks Arch Surg* 2023; **408**: 331 [PMID: 37615748 DOI: 10.1007/s00423-023-03069-y]
  - 35 **Rosen CB**, Roberts SE, Wirtalla CJ, Keele LJ, Kaufman EJ, Halpern SD, Reilly PM, Neuman MD, Kelz RR. The Conditional Effects of Multimorbidity on Operative Versus Nonoperative Management of Emergency General Surgery Conditions: A Retrospective Observational Study Using an Instrumental Variable Analysis. *Ann Surg* 2023; **278**: e855-e862 [PMID: 37212397 DOI: 10.1097/SLA.0000000000005901]
  - 36 **Johnson KM**, Newman KL, Green PK, Berry K, Cornia PB, Wu P, Beste LA, Itani K, Harris AHS, Kamath PS, Ioannou GN. Incidence and Risk Factors of Postoperative Mortality and Morbidity After Elective Versus Emergent Abdominal Surgery in a National Sample of 8193 Patients With Cirrhosis. *Ann Surg* 2021; **274**: e345-e354 [PMID: 31714310 DOI: 10.1097/SLA.0000000000003674]
  - 37 **Eugene N**, Kuryba A, Martin P, Oliver CM, Berry M, Moppett IK, Johnston C, Hare S, Lockwood S, Murray D, Walker K, Cromwell DA; NELA Project Team. Development and validation of a prognostic model for death 30 days after adult emergency laparotomy. *Anaesthesia*

- 2023; **78**: 1262-1271 [PMID: [37450350](#) DOI: [10.1111/anae.16096](#)]
- 38 **Kaufman EJ**, Keele LJ, Wirtalla CJ, Rosen CB, Roberts SE, Mavroudis CL, Reilly PM, Holena DN, McHugh MD, Small D, Kelz RR. Operative and Nonoperative Outcomes of Emergency General Surgery Conditions: An Observational Study Using a Novel Instrumental Variable. *Ann Surg* 2023; **278**: 72-78 [PMID: [35786573](#) DOI: [10.1097/SLA.0000000000005519](#)]
- 39 **Recuenco CB**, Septiem JG, Díaz JA, Vasallo IJT, de la Madriz AA, Carneros VJ, Rodríguez JLR, Navalón JMJ, Miramón FJJ. Effect of self-expandable metal stent on morbidity and mortality and oncological prognosis in malignant colonic obstruction: retrospective analysis of its use as curative and palliative treatment. *Int J Colorectal Dis* 2022; **37**: 475-484 [PMID: [35066617](#) DOI: [10.1007/s00384-021-04081-8](#)]
- 40 **Pisano M**, Zorcolo L, Merli C, Cimbanassi S, Poiasina E, Ceresoli M, Agresta F, Allievi N, Bellanova G, Coccolini F, Coy C, Fugazzola P, Martinez CA, Montori G, Paolillo C, Penachim TJ, Pereira B, Reis T, Restivo A, Rezende-Neto J, Sartelli M, Valentino M, Abu-Zidan FM, Ashkenazi I, Bala M, Chiara O, De' Angelis N, Deidda S, De Simone B, Di Saverio S, Finotti E, Kenji I, Moore E, Wexner S, Biffl W, Coimbra R, Guttadauro A, Leppäniemi A, Maier R, Magnone S, Mefire AC, Peitzmann A, Sakakushev B, Sugrue M, Viale P, Weber D, Kashuk J, Fraga GP, Kluger I, Catena F, Ansaloni L. 2017 WSES guidelines on colon and rectal cancer emergencies: obstruction and perforation. *World J Emerg Surg* 2018; **13**: 36 [PMID: [30123315](#) DOI: [10.1186/s13017-018-0192-3](#)]
- 41 **Zwanenburg ES**, Veld JV, Amelung FJ, Borstlap WAA, Dekker JWT, Hompes R, Tuynman JB, Westerterp M, van Westreenen HL, Bemelman WA, Consten ECJ, Tanis PJ; Dutch Snapshot Research Group. Short- and Long-term Outcomes After Laparoscopic Emergency Resection of Left-Sided Obstructive Colon Cancer: A Nationwide Propensity Score-Matched Analysis. *Dis Colon Rectum* 2023; **66**: 774-784 [PMID: [35522731](#) DOI: [10.1097/DCR.0000000000002364](#)]
- 42 **Paniagua García-Señoráns M**, Sánchez Santos R, Cano Valderrama Ó, Vigorita V, de Castro Parga ML, Cea Pereira S, Rodríguez Fernández L, Moncada Iribarren E. Stent as bridge to surgery decreases postoperative complications without worsening oncological outcomes: retrospective unicentric cohort study and stent placement protocol. *Surg Endosc* 2023; **37**: 6298-6307 [PMID: [37198409](#) DOI: [10.1007/s00464-023-10091-0](#)]
- 43 **Moutzoukis M**, Argyriou K, Kapsoritakis A, Christodoulou D. Endoscopic luminal stenting: Current applications and future perspectives. *World J Gastrointest Endosc* 2023; **15**: 195-215 [PMID: [37138934](#) DOI: [10.4253/wjge.v15.i4.195](#)]
- 44 **Wang S**, Fan Z. The role of GSTM1 gene polymorphism in pathophysiology, evaluation, and management of constipation of anorectal outlet obstruction. *Cell Mol Biol (Noisy-le-grand)* 2021; **67**: 163-167 [PMID: [34933715](#) DOI: [10.14715/cmb/2021.67.3.25](#)]
- 45 **Mege D**, Manceau G, Beyer L, Bridoux V, Lakkis Z, Venara A, Voron T, de'Angelis N, Abdalla S, Sielezneff I, Karoui M; AFC (French Surgical Association) Working Group. Right-sided vs. left-sided obstructing colonic cancer: results of a multicenter study of the French Surgical Association in 2325 patients and literature review. *Int J Colorectal Dis* 2019; **34**: 1021-1032 [PMID: [30941568](#) DOI: [10.1007/s00384-019-03286-2](#)]
- 46 **Labiad C**, Manceau G, Mege D, Cazelles A, Voron T, Bridoux V, Lakkis Z, Abdalla S, Karoui M; AFC (French Surgical Association) Working Group. Emergency surgery for obstructive splenic flexure colon cancer: results of a multicentric study of the French Surgical Association (AFC). *Updates Surg* 2022; **74**: 107-115 [PMID: [34813043](#) DOI: [10.1007/s13304-021-01206-0](#)]
- 47 **McGarry J**, Ng ZQ, Ryan F, Theophilus M. Utility of CT colonography and/or PET-CT preoperatively in obstructing left-sided colorectal cancers - a systematic review. *ANZ J Surg* 2023; **93**: 1487-1494 [PMID: [37025031](#) DOI: [10.1111/ans.18450](#)]
- 48 **Matsuda A**, Yamada T, Takahashi G, Matsumoto S, Yokoyama Y, Sonoda H, Ohta R, Shinji S, Sekiguchi K, Kuriyama S, Kanaka S, Yoshida H. Postoperative infectious complications have a negative oncological impact in patients after stent placement with malignant large bowel obstruction. *Int J Colorectal Dis* 2023; **38**: 2 [PMID: [36602578](#) DOI: [10.1007/s00384-022-04290-9](#)]
- 49 **Yan FH**, Zhang Y, Bian CL, Liu XS, Chen BC, Wang Z, Wang H, Ji-Fu E, Yu ED. Self-expanding metal stent insertion by colorectal surgeons using a two-person approach colonoscopy without fluoroscopic monitoring in the management of acute colorectal obstruction: a 14-year experience. *World J Surg Oncol* 2021; **19**: 194 [PMID: [34215276](#) DOI: [10.1186/s12957-021-02309-z](#)]
- 50 **Cao Y**, Ke S, Gu J, Mao F, Yao S, Deng S, Yan L, Wu K, Liu L, Cai K. The Value of Haematological Parameters and Tumour Markers in the Prediction of Intestinal Obstruction in 1474 Chinese Colorectal Cancer Patients. *Dis Markers* 2020; **2020**: 8860328 [PMID: [32855747](#) DOI: [10.1155/2020/8860328](#)]
- 51 **Li L**, Zhang L, Zhang T, Qi X, Cheng G, Xia L. Serum Chemokine CXCL7 as a Potential Novel Biomarker for Obstructive Colorectal Cancer. *Front Oncol* 2020; **10**: 599363 [PMID: [33643903](#) DOI: [10.3389/fonc.2020.599363](#)]
- 52 **Ishibashi R**, Yoshida S, Odawara N, Kishikawa T, Kondo R, Nakada A, Hakuta R, Takahara N, Tanaka E, Sekiba K, Seimiya T, Ohnaga T, Otsuka M, Koike K. Detection of circulating colorectal cancer cells by a custom microfluid system before and after endoscopic metallic stent placement. *Oncol Lett* 2019; **18**: 6397-6404 [PMID: [31807163](#) DOI: [10.3892/ol.2019.11047](#)]
- 53 **Takahashi G**, Yamada T, Iwai T, Takeda K, Koizumi M, Shinji S, Uchida E. Oncological Assessment of Stent Placement for Obstructive Colorectal Cancer from Circulating Cell-Free DNA and Circulating Tumor DNA Dynamics. *Ann Surg Oncol* 2018; **25**: 737-744 [PMID: [29235008](#) DOI: [10.1245/s10434-017-6300-x](#)]
- 54 **Collard MK**, Moszkowicz D, Clause-Verdreau AC, Beauchet A, Cudennee T, Vychnevskaia K, Malafosse R, Peschaud F. Postoperative morbidity and mortality for malignant colon obstruction: the American College of Surgeon calculator reliability. *J Surg Res* 2018; **226**: 112-121 [PMID: [29661276](#) DOI: [10.1016/j.jss.2017.11.070](#)]
- 55 **van Hooft JE**, Veld JV, Arnold D, Beets-Tan RGH, Everett S, Götz M, van Halsema EE, Hill J, Manes G, Meisner S, Rodrigues-Pinto E, Sabbagh C, Vandervoort J, Tanis PJ, Vanbiervliet G, Arezzo A. Self-expandable metal stents for obstructing colonic and extracolonic cancer: European Society of Gastrointestinal Endoscopy (ESGE) Guideline - Update 2020. *Endoscopy* 2020; **52**: 389-407 [PMID: [32259849](#) DOI: [10.1055/a-1140-3017](#)]
- 56 **Vogel JD**, Felder SI, Bhamra AR, Hawkins AT, Langenfeld SJ, Shaffer VO, Thorsen AJ, Weiser MR, Chang GJ, Lightner AL, Feingold DL, Paquette IM. The American Society of Colon and Rectal Surgeons Clinical Practice Guidelines for the Management of Colon Cancer. *Dis Colon Rectum* 2022; **65**: 148-177 [PMID: [34775402](#) DOI: [10.1097/DCR.0000000000002323](#)]
- 57 **Rodrigues-Pinto E**, Morais R, Coelho C, Pereira P, Repici A, Macedo G. Bridge-to-surgery versus emergency surgery in the management of left-sided acute malignant colorectal obstruction - Efficacy, safety and long-term outcomes. *Dig Liver Dis* 2019; **51**: 364-372 [PMID: [30558864](#) DOI: [10.1016/j.dld.2018.11.006](#)]
- 58 **Aicher BO**, Betancourt-Ramirez A, Grossman MD, Heise H, Schroepel TJ, Hernandez MC, Zielinski MD, Kongkaewpaisan N, Kaafarani HMA, Wagner A, Grabo D, Scott M, Peck G, Chang G, Matsushima K, Cullinane DC, Cullinane LM, Stocker B, Posluszny J, Simonoski UJ, Catalano RD, Vasileiou G, Yeh DD, Agrawal V, Truitt MS, Pickett M, Dultz L, Muller A, Ong AW, San Roman JL, Barth N, Fackelmayer O, Velopulos CG, Hendrix C, Estroff JM, Gambhir S, Nahmias J, Jeyamurugan K, Bugaev N, O'Meara L, Kufera J, Diaz JJ, Bruns BR. Validation of the American Association for the Surgery of Trauma Emergency General Surgery Grading System for Colorectal Resection: An EAST



- Multicenter Study. *Am Surg* 2022; **88**: 953-958 [PMID: 35275764 DOI: 10.1177/0003134820960022]
- 59 **Taylor JC**, Iversen LH, Burke D, Finan PJ, Iles MM, Morris EJA, Quirke P; YCR BCIP Study Group. Differences in the management of patients requiring an emergency resection for colonic cancer in two European populations. *BJS Open* 2022; **6** [PMID: 36260651 DOI: 10.1093/bjsopen/zrac126]
- 60 **Zattoni D**, Christoforidis D. How best to palliate and treat emergency conditions in geriatric patients with colorectal cancer. *Eur J Surg Oncol* 2020; **46**: 369-378 [PMID: 31973923 DOI: 10.1016/j.ejso.2019.12.020]
- 61 **Veld JV**, Amelung FJ, Borstlap WAA, Eise van Halsema E, Consten ECJ, Siersema PD, Ter Borg F, Silvester van der Zaag E, Fockens P, Bemelman WA, Elise van Hooft J, Tanis PJ; Dutch Snapshot Research Group. Changes in Management of Left-Sided Obstructive Colon Cancer: National Practice and Guideline Implementation. *J Natl Compr Canc Netw* 2019; **17**: 1512-1520 [PMID: 31805533 DOI: 10.6004/jnccn.2019.7326]
- 62 **de Roos MAJ**, Hugen N, Hazebroek EJ, Spillenaar Bilgen EJ. Delayed surgical resection of primary left-sided obstructing colon cancer is associated with improved short- and long-term outcomes. *J Surg Oncol* 2021; **124**: 1146-1153 [PMID: 34346510 DOI: 10.1002/jso.26632]
- 63 **Angulo McGrath I**, Martínez Burgos M, Bracho González M, Durán Campos A, Marín García D, Vázquez Pedreño L, Jiménez Pérez M. Experience in the treatment of obstructive colorectal cancer with self-expandable colon prosthesis in a tertiary hospital. *Rev Esp Enferm Dig* 2022; **114**: 626-627 [PMID: 35469401 DOI: 10.17235/reed.2022.8797/2022]
- 64 **Kim M**, Rai M, Teshima C. Interventional Endoscopy for Palliation of Luminal Gastrointestinal Obstructions in Management of Cancer: Practical Guide for Oncologists. *J Clin Med* 2022; **11** [PMID: 35330037 DOI: 10.3390/jcm11061712]
- 65 **Morino M**, Arezzo A, Farnesi F, Forcignanò E. Colonic Stenting in the Emergency Setting. *Medicina (Kaunas)* 2021; **57** [PMID: 33915760 DOI: 10.3390/medicina57040328]
- 66 **Alonso-Hernández N**, Segura-Sampedro JJ, Soldevila Verdeguer CM, Ochogavía Seguí A, Olea Martínez-Mediero JM, Fernández Isart M, Gamundi Cuesta M, González-Argente XF. Results of a national survey on the use of stents for the treatment of colonic obstruction. *Cir Esp (Engl Ed)* 2020; **98**: 533-539 [PMID: 32220416 DOI: 10.1016/j.ciresp.2020.02.006]
- 67 **Young CJ**, Zahid A. Randomized controlled trial of colonic stent insertion in non-curable large bowel obstruction: a post hoc cost analysis. *Colorectal Dis* 2018; **20**: 288-295 [PMID: 29091349 DOI: 10.1111/codi.13951]
- 68 **Lim TZ**, Tan KK. Endoscopic stenting in colorectal cancer. *J Gastrointest Oncol* 2019; **10**: 1171-1182 [PMID: 31949937 DOI: 10.21037/jgo.2019.02.15]
- 69 **Orlando VM**, Palma R, Fugazza A, Repici A. Colonic stents for malignant bowel obstruction: current status and future prospects. *Expert Rev Med Devices* 2019; **16**: 1053-1061 [PMID: 31778081 DOI: 10.1080/17434440.2019.1697229]
- 70 **Wang Y**, Hu H, Wang M, Han X, Zhang Q, Yu L, Chen Y, Wang G. Self-expanding metallic stent as a bridge to surgery *versus* emergency surgery for acute obstructive colorectal cancer: a retrospective study. *Cancer Manag Res* 2019; **11**: 2709-2718 [PMID: 3114329 DOI: 10.2147/CMAR.S192801]
- 71 **Asbjarnardottir MG**, Valsdottir EB, Sigurdsson HK, Moller PH. [Stenting for colorectal cancer obstruction in Icelandic patients]. *Laeknabladid* 2020; **106**: 569-573 [PMID: 33252048 DOI: 10.17992/ibl.2020.12.610]
- 72 **Liu JJ**, Ma TH, Qin QY, Wang L. Stent placement followed by preoperative chemotherapy and elective surgery for acute malignant colorectal obstruction: Six cases of report. *World J Gastrointest Oncol* 2019; **11**: 264-269 [PMID: 30918598 DOI: 10.4251/wjgo.v11.i3.264]
- 73 **Weston BR**, Patel JM, Pande M, Lum PJ, Ross WA, Raju GS, Lynch PM, Coronel E, Ge PS, Lee JH. Efficacy of uncovered colonic stents for extrinsic *versus* intrinsic malignant large bowel obstruction. *Surg Endosc* 2021; **35**: 4511-4519 [PMID: 32909212 DOI: 10.1007/s00464-020-07965-y]
- 74 **Yang K**, Zhu YQ, Chen NW, Wang ZG, Cheng YS. Super-Flexible Through-the-Scope Self-Expandable Metallic Stent Insertion for the Management of Malignant Tortuous Hepatic or Splenic Flexure Colonic Obstruction. *Chin Med J (Engl)* 2018; **131**: 1381-1384 [PMID: 29786060 DOI: 10.4103/0366-6999.232811]
- 75 **Lim CH**, McDonald NM, Freeman ML, Amateau SK. Percutaneous cecostomy with fully covered self-expandable metal stent for initial management of severe malignant colon obstruction. *Endoscopy* 2017; **49**: E313-E315 [PMID: 28992638 DOI: 10.1055/s-0043-119973]
- 76 **Mashar M**, Mashar R, Hajibandeh S. Uncovered *versus* covered stent in management of large bowel obstruction due to colorectal malignancy: a systematic review and meta-analysis. *Int J Colorectal Dis* 2019; **34**: 773-785 [PMID: 30903271 DOI: 10.1007/s00384-019-03277-3]
- 77 **Lee JS**, Lee HS, Kim ES, Jung MK, Jung JT, Kim HG, Lee DW, Kim DJ, Lee YJ, Yang CH; Daegu-Gyeongbuk Gastrointestinal Study Group (DGSB). Comparison of different types of covered self-expandable metal stents for malignant colorectal obstruction. *Surg Endosc* 2021; **35**: 4124-4133 [PMID: 32789723 DOI: 10.1007/s00464-020-07869-x]
- 78 **Kwaan MR**, Ren Y, Wu Y, Xirasagar S. Colonic Stent Use by Indication and Patient Outcomes: A Nationwide Inpatient Sample Study. *J Surg Res* 2021; **265**: 168-179 [PMID: 33940240 DOI: 10.1016/j.jss.2021.03.048]
- 79 **Hsu J**, Sevak S. Management of Malignant Large-Bowel Obstruction. *Dis Colon Rectum* 2019; **62**: 1028-1030 [PMID: 31397752 DOI: 10.1097/DCR.0000000000001441]
- 80 **Donlon NE**, Kelly ME, Narouz F, McCormick PH, Larkin JO, Mehigan BJ. Colonic stenting as a bridge to surgery in malignant large bowel obstruction: oncological outcomes. *Int J Colorectal Dis* 2019; **34**: 613-619 [PMID: 30652215 DOI: 10.1007/s00384-019-03239-9]
- 81 **Sasaki T**, Yoshida S, Isayama H, Narita A, Yamada T, Enomoto T, Sumida Y, Kyo R, Kuwai T, Tomita M, Moroi R, Shimada M, Hirata N, Saida Y. Short-Term Outcomes of Colorectal Stenting Using a Low Axial Force Self-Expandable Metal Stent for Malignant Colorectal Obstruction: A Japanese Multicenter Prospective Study. *J Clin Med* 2021; **10** [PMID: 34768456 DOI: 10.3390/jcm10214936]
- 82 **Mahfouz MF**, Salama TMS, Afifi AH, Dabous HMK. Effectiveness and early postoperative outcomes of palliative endoluminal stenting *versus* Hartmann's procedure in acute malignant bowel obstruction in high-risk patients. *Ann Coloproctol* 2022; **38**: 141-145 [PMID: 34167187 DOI: 10.3393/ac.2021.01.28]
- 83 **Lee JH**, Emelogu I, Kukreja K, Ali FS, Noguera-Gonzalez G, Lum P, Coronel E, Ross W, Raju GS, Lynch P, Thirumurthi S, Stroehlein J, Wang Y, You YN, Weston B. Safety and efficacy of metal stents for malignant colonic obstruction in patients treated with bevacizumab. *Gastrointest Endosc* 2019; **90**: 116-124 [PMID: 30797835 DOI: 10.1016/j.gie.2019.02.016]
- 84 **Seoane Urgorri A**, Saperas E, O'Callaghan Castella E, Pera Román M, Raga Gil A, Riu Pons F, Barranco Priego L, Dedeu Cusco JM, Pantaleón Sánchez M, Bessa Caserras X, Álvarez-González MA. Colonic stent vs surgical resection of the primary tumor. Effect on survival from stage-IV obstructive colorectal cancer. *Rev Esp Enferm Dig* 2020; **112**: 694-700 [PMID: 32755149 DOI: 10.17235/reed.2020.5701/2018]
- 85 **Balciscueta I**, Balciscueta Z, Uribe N, García-Granero E. Perineural invasion is increased in patients receiving colonic stenting as a bridge to surgery: a systematic review and meta-analysis. *Tech Coloproctol* 2021; **25**: 167-176 [PMID: 33200308 DOI: 10.1007/s10151-020-02350-2]
- 86 **Spannenburg L**, Sanchez Gonzalez M, Brooks A, Wei S, Li X, Liang X, Gao W, Wang H. Surgical outcomes of colonic stents as a bridge to

- surgery versus emergency surgery for malignant colorectal obstruction: A systematic review and meta-analysis of high quality prospective and randomised controlled trials. *Eur J Surg Oncol* 2020; **46**: 1404-1414 [PMID: 32418754 DOI: 10.1016/j.ejso.2020.04.052]
- 87 **Kuwai T**, Tamaru Y, Kusunoki R, Yoshida S, Matsuzawa T, Isayama H, Maetani I, Shimada M, Yamada T, Saito S, Tomita M, Koizumi K, Shiratori T, Enomoto T, Saida Y. Long-term outcomes of standardized colonic stenting using WallFlex as a bridge to surgery: Multicenter prospective cohort study. *Dig Endosc* 2022; **34**: 840-849 [PMID: 34525244 DOI: 10.1111/den.14137]
- 88 **Axmarker T**, Leffler M, Lepsenyi M, Thorlacius H, Syk I. Long-term survival after self-expanding metallic stent or stoma decompression as bridge to surgery in acute malignant large bowel obstruction. *BJS Open* 2021; **5** [PMID: 33880530 DOI: 10.1093/bjsopen/zrab018]
- 89 **Matsuda A**, Yamada T, Matsumoto S, Sakurazawa N, Kawano Y, Sekiguchi K, Matsutani T, Miyashita M, Yoshida H. Short-term outcomes of a self-expandable metallic stent as a bridge to surgery vs. a transanal decompression tube for malignant large-bowel obstruction: a meta-analysis. *Surg Today* 2019; **49**: 728-737 [PMID: 30798434 DOI: 10.1007/s00595-019-01784-y]
- 90 **Mege D**, Manceau G, Bridoux V, Voron T, Sabbagh C, Lakkis Z, Venara A, Ouassini M, Denost Q, Kepenekian V, Sielezneff I, Karoui M; AFC (French Surgical Association) Working Group. Surgical management of obstructive left colon cancer at a national level: Results of a multicentre study of the French Surgical Association in 1500 patients. *J Visc Surg* 2019; **156**: 197-208 [PMID: 30948208 DOI: 10.1016/j.jvisurg.2018.11.008]
- 91 **Bertelsen CA**, Elfeki H, Neuenschwander AU, Laurberg S, Kristensen B, Emmertsen KJ. The risk of long-term bowel dysfunction after resection for sigmoid adenocarcinoma: a cross-sectional survey comparing complete mesocolic excision with conventional surgery. *Colorectal Dis* 2018; **20**: O256-O266 [PMID: 29947168 DOI: 10.1111/codi.14318]
- 92 **Trigui A**, Rejab H, Akrouit A, Harbi H, Kachaou A, Fendri S, Frikha MF, Mzali R. [Comparison between endoscopic stenting and colostomy in the management of obstructing cancer of the left colon: Literature review]. *Presse Med* 2019; **48**: 173-180 [PMID: 30799150 DOI: 10.1016/j.lpm.2019.01.007]
- 93 **Gavrilidis P**, de'Angelis N, Wheeler J, Askari A, Di Saverio S, Davies JR. Diversion, resection, or stenting as a bridge to surgery for acute neoplastic left-sided colonic obstruction: a systematic review and network meta-analysis of studies with curative intent. *Ann R Coll Surg Engl* 2021; **103**: 235-244 [PMID: 33682486 DOI: 10.1308/rcsann.2020.7137]
- 94 **Tabusa H**, Blazeby JM, Blencowe N, Callaway M, Daniels IR, Gunning A, Hollingworth W, McNair AG, Murkin C, Pinkney TD, Rogers CA, Smart NJ, Reeves BC. Protocol for the UK cohort study to investigate the prevention of parastomal hernia (the CIPHER study). *Colorectal Dis* 2021; **23**: 1900-1908 [PMID: 33686656 DOI: 10.1111/codi.15621]
- 95 **Aubert M**, Mege D, Manceau G, Bridoux V, Lakkis Z, Venara A, Voron T, Abdalla S, Beyer-Berjot L, Sielezneff I, Sabbagh C, Karoui M; AFC (French Surgical Association) Working Group. Impact of hospital volume on outcomes after emergency management of obstructive colon cancer: a nationwide study of 1957 patients. *Int J Colorectal Dis* 2020; **35**: 1865-1874 [PMID: 32504329 DOI: 10.1007/s00384-020-03602-1]
- 96 **Shang Y**, Guo C, Zhang D. Modified enhanced recovery after surgery protocols are beneficial for postoperative recovery for patients undergoing emergency surgery for obstructive colorectal cancer: A propensity score matching analysis. *Medicine (Baltimore)* 2018; **97**: e12348 [PMID: 30278512 DOI: 10.1097/MD.00000000000012348]
- 97 **Colás-Ruiz E**, Del-Moral-Luque JA, Gil-Yonte P, Fernández-Cebrián JM, Alonso-García M, Villar-Del-Campo MC, Durán-Poveda M, Rodríguez-Caravaca G. Incidence of surgical site infection and risk factors in rectal surgery: A prospective cohort study. *Cir Esp (Engl Ed)* 2018; **96**: 640-647 [PMID: 30093098 DOI: 10.1016/j.ciresp.2018.06.007]
- 98 **Chen PJ**, Wang L, Peng YF, Chen N, Wu AW. Surgical intervention for malignant bowel obstruction caused by gastrointestinal malignancies. *World J Gastrointest Oncol* 2020; **12**: 323-331 [PMID: 32206182 DOI: 10.4251/wjgo.v12.i3.323]
- 99 **Danzi M**, Grimaldi L, De Capua M, Tammaro N, Danzi R, Sivero L. Obstructing left sided colorectal cancer. A retrospective single Center study. *Ann Ital Chir* 2019; **90**: 121-126 [PMID: 30569909]
- 100 **Malakorn S**, Stein SL, Lee JH, You YN. Urgent Management of Obstructing Colorectal Cancer: Divert, Stent, or Resect? *J Gastrointest Surg* 2019; **23**: 425-432 [PMID: 30284201 DOI: 10.1007/s11605-018-3990-8]
- 101 **Boeding JRE**, Ramphal W, Rijken AM, Crolla RMPH, Verhoef C, Gobardhan PD, Schreinemakers JMJ. A Systematic Review Comparing Emergency Resection and Staged Treatment for Curable Obstructing Right-Sided Colon Cancer. *Ann Surg Oncol* 2021; **28**: 3545-3555 [PMID: 33067743 DOI: 10.1245/s10434-020-09124-y]
- 102 **Capona R**, Hassab T, Sapci I, Aiello A, Liska D, Holubar S, Lightner AL, Steele SR, Valente MA. Surgical intervention for mechanical large bowel obstruction at a tertiary hospital: Which patients receive a stoma and how often are they reversed? *Am J Surg* 2021; **221**: 594-597 [PMID: 33288223 DOI: 10.1016/j.amjsurg.2020.11.029]
- 103 **Kondo A**, Okano K, Kumamoto K, Kobara H, Nagahara T, Wato M, Shibato T, Minato T, Masaki T, Suzuki Y, Kagawa Gastroenterology Forum. Surgical management and outcomes of obstructive colorectal cancer in elderly patients: A multi-institutional retrospective study. *Surgery* 2022; **172**: 60-68 [PMID: 34998620 DOI: 10.1016/j.surg.2021.12.007]
- 104 **Podda M**, Di Saverio S, Davies RJ, Atzeni J, Balestra F, Virdis F, Reccia I, Jayant K, Agresta F, Pisanu A. Prophylactic intra-abdominal drainage following colorectal anastomoses. A systematic review and meta-analysis of randomized controlled trials. *Am J Surg* 2020; **219**: 164-174 [PMID: 31138400 DOI: 10.1016/j.amjsurg.2019.05.006]
- 105 **Manceau G**, Mege D, Bridoux V, Lakkis Z, Venara A, Voron T, Sielezneff I, Karoui M; French Surgical Association Working Group. Emergency Surgery for Obstructive Colon Cancer in Elderly Patients: Results of a Multicentric Cohort of the French National Surgical Association. *Dis Colon Rectum* 2019; **62**: 941-951 [PMID: 31283592 DOI: 10.1097/DCR.0000000000001421]
- 106 **Kartal K**, Citgez B, Koksall MH, Besler E, Akgun IE, Mihmanli M. Colostomy reversal after a Hartmann's procedure Effects of experience on mortality and morbidity. *Ann Ital Chir* 2019; **90**: 539-544 [PMID: 31270277]
- 107 **Söderbäck H**, Gunnarsson U, Martling A, Hellman P, Sandblom G. Incidence of wound dehiscence after colorectal cancer surgery: results from a national population-based register for colorectal cancer. *Int J Colorectal Dis* 2019; **34**: 1757-1762 [PMID: 31501927 DOI: 10.1007/s00384-019-03390-3]
- 108 **Veld JV**, Amelung FJ, Borstlap WAA, van Halsem EE, Consten ECJ, Dekker JWT, Siersema PD, Ter Borg F, van der Zaag ES, Fockens P, Bemelman WA, de Wilt JHW, van Hooft JE, Tanis PJ; Dutch Snapshot Research Group. Decompressing Stoma as a Bridge to Elective Surgery is an Effective Strategy for Left-sided Obstructive Colon Cancer: A National, Propensity-score Matched Study. *Ann Surg* 2020; **272**: 738-743 [PMID: 32833768 DOI: 10.1097/SLA.0000000000004173]
- 109 **Manceau G**, Voron T, Mege D, Bridoux V, Lakkis Z, Venara A, Beyer-Berjot L, Abdalla S, Sielezneff I, Lefèvre JH, Karoui M; AFC (French Surgical Association) Working Group. Prognostic factors and patterns of recurrence after emergency management for obstructing colon cancer: multivariate analysis from a series of 2120 patients. *Langenbecks Arch Surg* 2019; **404**: 717-729 [PMID: 31602503 DOI: 10.1007/s00423-019-01819-5]

- 110 **Yuan X**, Liu W, Ye L, Wu M, Hu B. Combination of endoscopic incision and balloon dilation for treatment of a completely obstructed anastomotic stenosis following colorectal resection: A case report. *Medicine (Baltimore)* 2019; **98**: e16292 [PMID: [31261603](#) DOI: [10.1097/MD.00000000000016292](#)]
- 111 **Lavanchy JL**, Vaisnora L, Haltmeier T, Zlobec I, Brügger LE, Candinas D, Schnüriger B. Oncologic long-term outcomes of emergency versus elective resection for colorectal cancer. *Int J Colorectal Dis* 2019; **34**: 2091-2099 [PMID: [31709491](#) DOI: [10.1007/s00384-019-03426-8](#)]
- 112 **Mihailov R**, Firescu D, Constantin GB, Mihailov OM, Hoara P, Birla R, Patrascu T, Panaitescu E. Mortality Risk Stratification in Emergency Surgery for Obstructive Colon Cancer-External Validation of International Scores, American College of Surgeons National Surgical Quality Improvement Program Surgical Risk Calculator (SRC), and the Dedicated Score of French Surgical Association (AFC/OCC Score). *Int J Environ Res Public Health* 2022; **19** [PMID: [36294094](#) DOI: [10.3390/ijerph192013513](#)]
- 113 **Genser L**, Manceau G, Mege D, Bridoux V, Lakkis Z, Venara A, Voron T, Bege T, Sielezneff I, Karoui M; on behalf of the AFC (French Surgical Association) Working Group. 30-Day Postoperative Morbidity of Emergency Surgery for Obstructive Right- and Left-Sided Colon Cancer in Obese Patients: A Multicenter Cohort Study of the French Surgical Association. *Dig Surg* 2020; **37**: 111-118 [PMID: [30939470](#) DOI: [10.1159/000497450](#)]
- 114 **Quintana JM**, Anton-Ladislao A, Lázaro S, Gonzalez N, Bare M, Fernandez-de-Larrea N, Redondo M, Escobar A, Sarasqueta C, Garcia-Gutierrez S, Aguirre U; REDISSEC-CARESS/CCR group. Effect of comorbidities on long-term outcomes of colorectal cancer patients. *Eur J Cancer Care (Engl)* 2022; **31**: e13561 [PMID: [35174571](#) DOI: [10.1111/ecc.13561](#)]
- 115 **Abu Baker F**, Taher R, Ganayem M, Mari A, Oren G, Kopelman Y. Obstructive colon cancers at endoscopy are associated with advanced tumor stage and poor patient outcome. A retrospective study on 398 patients. *Eur J Gastroenterol Hepatol* 2021; **33**: 50-53 [PMID: [32675779](#) DOI: [10.1097/MEG.0000000000001839](#)]
- 116 **Sato R**, Oikawa M, Kakita T, Okada T, Abe T, Yazawa T, Tsuchiya H, Akazawa N, Sato M, Ohira T, Harada Y, Okano H, Ito K, Ohuchi N, Tsuchiya T. Preoperative change of modified Glasgow prognostic score after stenting predicts the long-term outcomes of obstructive colorectal cancer. *Surg Today* 2020; **50**: 232-239 [PMID: [31407166](#) DOI: [10.1007/s00595-019-01862-1](#)]





Published by **Baishideng Publishing Group Inc**  
7041 Koll Center Parkway, Suite 160, Pleasanton, CA 94566, USA

**Telephone:** +1-925-3991568

**E-mail:** [office@baishideng.com](mailto:office@baishideng.com)

**Help Desk:** <https://www.f6publishing.com/helpdesk>

<https://www.wjgnet.com>

