

World Journal of *Gastrointestinal Oncology*

World J Gastrointest Oncol 2024 March 15; 16(3): 571-1090



EDITORIAL

- 571 Synchronous gastric and colon cancers: Important to consider hereditary syndromes and chronic inflammatory disease associations
Shenoy S
- 577 Neutrophil-to-lymphocyte ratio and platelet-to-lymphocyte ratio: Markers predicting immune-checkpoint inhibitor efficacy and immune-related adverse events
Jiang QY, Xue RY
- 583 Early-onset gastrointestinal cancer: An epidemiological reality with great significance and implications
Triantafyllidis JK, Georgiou K, Konstadoulakis MM, Papalois AE

REVIEW

- 598 Management of obstructed colorectal carcinoma in an emergency setting: An update
Pavlidis ET, Galanis IN, Pavlidis TE
- 614 Unraveling the enigma: A comprehensive review of solid pseudopapillary tumor of the pancreas
Xu YC, Fu DL, Yang F

MINIREVIEWS

- 630 Roles and application of exosomes in the development, diagnosis and treatment of gastric cancer
Guan XL, Guan XY, Zhang ZY
- 643 Prognostic and predictive role of immune microenvironment in colorectal cancer
Kuznetsova O, Fedyanin M, Zavalishina L, Moskvina L, Kuznetsova O, Lebedeva A, Tryakin A, Kireeva G, Borshchev G, Tjulandin S, Ignatova E
- 653 Pylorus-preserving gastrectomy for early gastric cancer
Sun KK, Wu YY

ORIGINAL ARTICLE

Case Control Study

- 659 N-glycan biosignatures as a potential diagnostic biomarker for early-stage pancreatic cancer
Wen YR, Lin XW, Zhou YW, Xu L, Zhang JL, Chen CY, He J
- 670 Expression and significance of pigment epithelium-derived factor and vascular endothelial growth factor in colorectal adenoma and cancer
Yang Y, Wen W, Chen FL, Zhang YJ, Liu XC, Yang XY, Hu SS, Jiang Y, Yuan J

- 687 Impact of Alcian blue and periodic acid Schiff expression on the prognosis of gastric signet ring cell carcinoma

Lin J, Chen ZF, Guo GD, Chen X

Retrospective Cohort Study

- 699 Clinical profile and outcomes of hepatocellular carcinoma in primary Budd-Chiari syndrome

Agarwal A, Biswas S, Swaroop S, Aggarwal A, Agarwal A, Jain G, Elhence A, Vaidya A, Gupte A, Mohanka R, Kumar R, Mishra AK, Gamanagatti S, Paul SB, Acharya SK, Shukla A, Shalimar

- 716 Chinese herbal medicine decreases incidence of hepatocellular carcinoma in diabetes mellitus patients with regular insulin management

Lai HC, Cheng JC, Yip HT, Jeng LB, Huang ST

- 732 Combining systemic inflammatory response index and albumin fibrinogen ratio to predict early serious complications and prognosis after resectable gastric cancer

Ren JY, Wang D, Zhu LH, Liu S, Yu M, Cai H

- 750 Mucosa color and size may indicate malignant transformation of chicken skin mucosa-positive colorectal neoplastic polyps

Zhang YJ, Yuan MX, Wen W, Li F, Jian Y, Zhang CM, Yang Y, Chen FL

- 761 Epidemiology, therapy and outcome of hepatocellular carcinoma between 2010 and 2019 in Piedmont, Italy

Bracco C, Gallarate M, Badinella Martini M, Magnino C, D'Agnano S, Canta R, Racca G, Melchio R, Serraino C, Polla Mattiot V, Gollè G, Fenoglio L

- 773 Study on sex differences and potential clinical value of three-dimensional computerized tomography pelvimetry in rectal cancer patients

Zhou XC, Ke FY, Dhamija G, Chen H, Wang Q

Retrospective Study

- 787 High patatin like phospholipase domain containing 8 expression as a biomarker for poor prognosis of colorectal cancer

Zhou PY, Zhu DX, Chen YJ, Feng QY, Mao YH, Zhuang AB, Xu JM

- 798 Combining prognostic value of serum carbohydrate antigen 19-9 and tumor size reduction ratio in pancreatic ductal adenocarcinoma

Xia DQ, Zhou Y, Yang S, Li FF, Tian LY, Li YH, Xu HY, Xiao CZ, Wang W

- 810 Influence of transcatheter arterial embolization on symptom distress and fatigue in liver cancer patients

Yang XM, Yang XY, Wang XY, Gu YX

- 819 T2-weighted imaging-based radiomic-clinical machine learning model for predicting the differentiation of colorectal adenocarcinoma

Zheng HD, Huang QY, Huang QM, Ke XT, Ye K, Lin S, Xu JH

- 833 Predictive value of positive lymph node ratio in patients with locally advanced gastric remnant cancer

Zhuo M, Tian L, Han T, Liu TF, Lin XL, Xiao XY

- 844 Risk of cardiovascular death in patients with hepatocellular carcinoma based on the Fine-Gray model
Zhang YL, Liu ZR, Liu Z, Bai Y, Chi H, Chen DP, Zhang YM, Cui ZL
- 857 Preoperatively predicting vessels encapsulating tumor clusters in hepatocellular carcinoma: Machine learning model based on contrast-enhanced computed tomography
Zhang C, Zhong H, Zhao F, Ma ZY, Dai ZJ, Pang GD
- 875 Comparison of mismatch repair and immune checkpoint protein profile with histopathological parameters in pancreatic, peripapillary/ampullary, and choledochal adenocarcinomas
Aydin AH, Turhan N
- 883 Assessment of programmed death-ligand 1 expression in primary tumors and paired lymph node metastases of gastric adenocarcinoma
Coimbra BC, Pereira MA, Cardili L, Alves VAF, de Mello ES, Ribeiro U Jr, Ramos MFKP

Observational Study

- 894 Identification of breath volatile organic compounds to distinguish pancreatic adenocarcinoma, pancreatic cystic neoplasm, and patients without pancreatic lesions
Tiankanon K, Pungpipattrakul N, Sukaram T, Chaiteerakij R, Rerknimitr R
- 907 Clinical features and prognostic factors of duodenal neuroendocrine tumours: A comparative study of ampullary and nonampullary regions
Fang S, Shi YP, Wang L, Han S, Shi YQ

Clinical and Translational Research

- 919 Construction of an immune-related gene signature for overall survival prediction and immune infiltration in gastric cancer
Ma XT, Liu X, Ou K, Yang L
- 933 Clinical efficacy and pathological outcomes of transanal endoscopic intersphincteric resection for low rectal cancer
Xu ZW, Zhu JT, Bai HY, Yu XJ, Hong QQ, You J
- 945 Identification of a novel inflammatory-related gene signature to evaluate the prognosis of gastric cancer patients
Hu JL, Huang MJ, Halina H, Qiao K, Wang ZY, Lu JJ, Yin CL, Gao F

Basic Study

- 968 Verteporfin fluorescence in antineoplastic-treated pancreatic cancer cells found concentrated in mitochondria
Zhang YQ, Liu QH, Liu L, Guo PY, Wang RZ, Ba ZC
- 979 Effects of *Helicobacter pylori* and Moluodan on the Wnt/ β -catenin signaling pathway in mice with precancerous gastric cancer lesions
Wang YM, Luo ZW, Shu YL, Zhou X, Wang LQ, Liang CH, Wu CQ, Li CP

- 991** Mitochondrial carrier homolog 2 increases malignant phenotype of human gastric epithelial cells and promotes proliferation, invasion, and migration of gastric cancer cells
Zhang JW, Huang LY, Li YN, Tian Y, Yu J, Wang XF
- 1006** Ubiquitin-specific protease 21 promotes tumorigenicity and stemness of colorectal cancer by deubiquitinating and stabilizing ZEB1
Lin JJ, Lu YC
- 1019** Long non-coding RNA GATA6-AS1 is mediated by N6-methyladenosine methylation and inhibits the proliferation and metastasis of gastric cancer
Shen JJ, Li MC, Tian SQ, Chen WM
- 1029** CALD1 facilitates epithelial-mesenchymal transition progression in gastric cancer cells by modulating the PI3K-Akt pathway
Ma WQ, Miao MC, Ding PA, Tan BB, Liu WB, Guo S, Er LM, Zhang ZD, Zhao Q

META-ANALYSIS

- 1046** Efficacy and safety of perioperative therapy for locally resectable gastric cancer: A network meta-analysis of randomized clinical trials
Kuang ZY, Sun QH, Cao LC, Ma XY, Wang JX, Liu KX, Li J

SCIENTOMETRICS

- 1059** Insights into the history and tendency of glycosylation and digestive system tumor: A bibliometric-based visual analysis
Jiang J, Luo Z, Zhang RC, Wang YL, Zhang J, Duan MY, Qiu ZJ, Huang C

CASE REPORT

- 1076** Managing end-stage carcinoid heart disease: A case report and literature review
Bulj N, Tomasic V, Cigrovski Berkovic M
- 1084** Hemorrhagic cystitis in gastric cancer after nanoparticle albumin-bound paclitaxel: A case report
Zhang XJ, Lou J

ABOUT COVER

Peer Review of *World Journal of Gastrointestinal Oncology*, Noha Elkady, MD, Assistant Professor, Department of Pathology, Faculty of Medicine Menoufia University, Shibin Elkom 32511, Egypt. drnohaelkady@gmail.com

AIMS AND SCOPE

The primary aim of *World Journal of Gastrointestinal Oncology* (WJGO, *World J Gastrointest Oncol*) is to provide scholars and readers from various fields of gastrointestinal oncology with a platform to publish high-quality basic and clinical research articles and communicate their research findings online.

WJGO mainly publishes articles reporting research results and findings obtained in the field of gastrointestinal oncology and covering a wide range of topics including liver cell adenoma, gastric neoplasms, appendiceal neoplasms, biliary tract neoplasms, hepatocellular carcinoma, pancreatic carcinoma, cecal neoplasms, colonic neoplasms, colorectal neoplasms, duodenal neoplasms, esophageal neoplasms, gallbladder neoplasms, *etc.*

INDEXING/ABSTRACTING

The WJGO is now abstracted and indexed in PubMed, PubMed Central, Science Citation Index Expanded (SCIE, also known as SciSearch®), Journal Citation Reports/Science Edition, Scopus, Reference Citation Analysis, China Science and Technology Journal Database, and Superstar Journals Database. The 2023 edition of Journal Citation Reports® cites the 2022 impact factor (IF) for WJGO as 3.0; IF without journal self cites: 2.9; 5-year IF: 3.0; Journal Citation Indicator: 0.49; Ranking: 157 among 241 journals in oncology; Quartile category: Q3; Ranking: 58 among 93 journals in gastroenterology and hepatology; and Quartile category: Q3. The WJGO's CiteScore for 2022 is 4.1 and Scopus CiteScore rank 2022: Gastroenterology is 71/149; Oncology is 197/366.

RESPONSIBLE EDITORS FOR THIS ISSUE

Production Editor: Xiang-Di Zhang; Production Department Director: Xiang Li; Editorial Office Director: Jia-Ru Fan.

NAME OF JOURNAL

World Journal of Gastrointestinal Oncology

ISSN

ISSN 1948-5204 (online)

LAUNCH DATE

February 15, 2009

FREQUENCY

Monthly

EDITORS-IN-CHIEF

Monjur Ahmed, Florin Burada

EDITORIAL BOARD MEMBERS

<https://www.wjgnet.com/1948-5204/editorialboard.htm>

PUBLICATION DATE

March 15, 2024

COPYRIGHT

© 2024 Baishideng Publishing Group Inc

INSTRUCTIONS TO AUTHORS

<https://www.wjgnet.com/bpg/gerinfo/204>

GUIDELINES FOR ETHICS DOCUMENTS

<https://www.wjgnet.com/bpg/GerInfo/287>

GUIDELINES FOR NON-NATIVE SPEAKERS OF ENGLISH

<https://www.wjgnet.com/bpg/gerinfo/240>

PUBLICATION ETHICS

<https://www.wjgnet.com/bpg/GerInfo/288>

PUBLICATION MISCONDUCT

<https://www.wjgnet.com/bpg/gerinfo/208>

ARTICLE PROCESSING CHARGE

<https://www.wjgnet.com/bpg/gerinfo/242>

STEPS FOR SUBMITTING MANUSCRIPTS

<https://www.wjgnet.com/bpg/GerInfo/239>

ONLINE SUBMISSION

<https://www.f6publishing.com>



Pylorus-preserving gastrectomy for early gastric cancer

Ke-Kang Sun, Yong-You Wu

Specialty type: Oncology

Provenance and peer review:

Invited article; Externally peer reviewed.

Peer-review model: Single blind

Peer-review report's scientific quality classification

Grade A (Excellent): 0

Grade B (Very good): B

Grade C (Good): 0

Grade D (Fair): 0

Grade E (Poor): 0

P-Reviewer: Ergenç M, Turkey

Received: December 21, 2023

Peer-review started: December 21, 2023

First decision: January 10, 2024

Revised: January 15, 2024

Accepted: February 6, 2024

Article in press: February 6, 2024

Published online: March 15, 2024



Ke-Kang Sun, Department of Gastrointestinal Surgery, The Affiliated Kunshan Hospital to Jiangsu University, Suzhou 215300, Jiangsu Province, China

Yong-You Wu, Department of Gastrointestinal Surgery, The Second Affiliated Hospital of Soochow University, Suzhou 215008, Jiangsu Province, China

Corresponding author: Yong-You Wu, FRCS (Ed), MD, MM, PhD, Chief Doctor, Director, Professor, Department of Gastrointestinal Surgery, The Second Affiliated Hospital of Soochow University, No. 1055 Sanxiang Road, Suzhou 215008, Jiangsu Province, China.

wuyongyou72@126.com

Abstract

Pylorus-preserving gastrectomy (PPG) has been widely accepted as a function-preserving gastrectomy for middle-third early gastric cancer (EGC) with a distal tumor border at least 4 cm proximal to the pylorus. The procedure essentially preserves the function of the pyloric sphincter, which requires to preserve the upper third of the stomach and a pyloric cuff at least 2.5 cm. The suprapyloric and infrapyloric vessels are usually preserved, as are the hepatic and pyloric branches of the vagus nerve. Compared with distal gastrectomy, PPG has significant advantages in preventing dumping syndrome, body weight loss and bile reflux gastritis. The postoperative complications after PPG have reached an acceptable level. PPG can be considered a safe, effective, and superior choice in EGC, and is expected to be extensively performed in the future.

Key Words: Gastric cancer; Pylorus-preserving gastrectomy; Oncological safety; Gastric stasis

©The Author(s) 2024. Published by Baishideng Publishing Group Inc. All rights reserved.

Core Tip: Pylorus-preserving gastrectomy (PPG) has been widely accepted as a function-preserving gastrectomy for middle-third early gastric cancer. The procedure requires to preserve the upper third of the stomach and a pyloric cuff at least 2.5 cm. The hepatic and pyloric branches of the vagus nerve are usually preserved. PPG has significant advantages in preventing dumping syndrome, body weight loss and bile reflux gastritis.

Citation: Sun KK, Wu YY. Pylorus-preserving gastrectomy for early gastric cancer. *World J Gastrointest Oncol* 2024; 16(3): 653-658

URL: <https://www.wjgnet.com/1948-5204/full/v16/i3/653.htm>

DOI: <https://dx.doi.org/10.4251/wjgo.v16.i3.653>

INTRODUCTION

Pylorus-preserving gastrectomy (PPG) was initially proposed for treating gastric ulcers in 1967[1]. It has since been regularly performed as a function-preserving gastrectomy for early gastric cancer (EGC) in Japan and South Korea[2], which embodies the pursuit of "precision medicine". In its development over 60 years, PPG has gradually reached a consensus on lymph node dissection, the length of the pyloric cuff, and preservation of the vagus nerve and pyloric vessels. PPG is acceptable with favorable outcomes for the middle portion EGC. This article reviewed the development history, indications, oncological safety, complications, and functional benefits of PPG.

HISTORICAL DEVELOPMENT

As early as the end of the 19th century, surgeons have tried to perform gastrectomy with the preservation of the gastric antrum and pylorus to reduce the complications of bile gastric reflux and dumping syndrome. Segmental gastrectomy (SG) was first reported in gastric ulcers treatment in 1897[3]. However, SG was abandoned in the 1920s because of postoperative complications such as anastomotic stenosis, ulcer recurrence, and delayed gastric emptying (DGE)[4,5]. Subsequently, Wangenstein[6] recommended the supplementing pyloroplasty to promote gastric drainage, but this exactly offset the merits of preserving the pylorus. Maki *et al*[1] first described the detailed surgical procedures of PPG in 1967, and reported long-term satisfactory results in gastric ulcer treatment in 1992[7]. However, the development of internal medicine has greatly changed the therapeutic strategy of peptic ulcer, and PPG has gradually faded out of gastric ulcers treatment. In 1991, Kodama and Koyama[8] first proposed PPG for treating EGC. At this late hour, PPG has been recommended as a treatment route for middle-third EGC with a distal tumor border at least 4 cm proximal to the pylorus [9]. Nunobe *et al*[10] reported that to retain the functions of the gastric antrum and pylorus, the length of the preserved gastric antrum should be at least 2.5 cm. Since most T1aN0M0 cases undergo endoscopic mucosal resection, the indications of PPG are mainly T1aN0M0 cases which are not suitable for endoscopic resection and T1bN0M0 cases. It can also be considered as an additive surgery after endoscopic resection[9].

LYMPH NODE DISSECTION

Preservation of pyloric function during PPG procedure depends on the pyloric antrum blood flow and nerve preservation, which result in the incomplete dissection of No. 5 and No. 6 lymph nodes. In recent years, the regularity of lymph node metastasis with the middle portion EGC has provided a theoretical basis for PPG. In 1991, Kodama and Koyama[8] investigated the lymphatic drainage pathways in middle-third gastric cancer by the subserosal injection of activated carbon particles on the lesser and greater curvatures of the stomach. The results showed that the lymph flowed mostly from the lesser curvature to the No. 3 and No. 7 lymph nodes, with few draining to the No. 5 nodes, while drainage from the greater curvature included the No. 4d and No. 6 lymph nodes. 154 patients undergoing subtotal gastrectomy for middle-third EGC were analyzed and the result showed no involvement of the No. 5 and No. 6 lymph nodes in 82 cases with mucosal invasion, while No. 6 node involvement was only confirmed in 4.2% (3/72) patients with submucosal invasion. Another cohort study of 701 cases found metastasis rates of 0% and 0.4% for the No. 5 and No. 6 nodes, respectively, and involvement of No. 12a and No. 11p was negligible in middle-body EGC[11]. Therefore, the authors proposed that PPG is safe for middle-third EGC, as well as for high and moderately differentiated T2 gastric cancer below 4 cm in diameter. In 2013, Shinohara *et al*[12] investigated the embryology and topographic anatomy of the infrapyloric lymph region and divided No. 6 lymph nodes into 3 subgroups, namely 6a, 6v and 6i. No. 6a is separated from No. 6i by the infrapyloric artery and the initial branch of the right gastroepiploic artery. The involvement No. 6i lymph node is extremely rare, which provides an important theoretical basis for selective dissection of No. 6 lymph nodes in PPG. Similarly, to retain the hepatic and pyloric branches of the vagus nerve, No. 5 and No. 12a lymph nodes are routinely preserved. Additionally, metastasis to the left suprapancreatic lymph nodes is extremely rare, so that dissection of the No. 11p node is not required in PPG. Therefore, the dissection of No. 1, 3, 4sb, 4d, 6a, 6v, 7, 8a, 9 lymph nodes is required in PPG procedure (Figure 1)[9].

ANASTOMOSIS METHOD

Both extracorporeal and intracorporeal anastomosis can be performed in PPG. The extracorporeal anastomosis was attached from the middle incision in the upper abdomen with the anastomosis site lying directly beneath[13,14]. This allowed the surgeons to palpate the margin before transection of the stomach, avoiding insufficient resection margin or

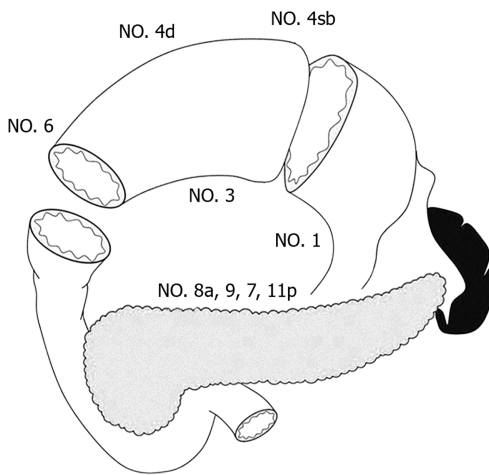


Figure 1 Lymph node dissection in pylorus-preserving gastrectomy.

excessive resection. The handsewn anastomosis can be intermittent or continuous suture, and a continuous suture does not increase the risk of anastomotic stenosis. More recently, total laparoscopic gastrectomy was gradually performed, and there are many methods for intracorporeal anastomosis[15]. Yang *et al*[16] performed a layer-to-layer manual anastomosis of the anterior and posterior walls using two double-needle barbed sutures intracorporeal. Alternatively, suture of the posterior side with a linear stapler and handsewn suture on the front side was performed. Intracorporeal delta-shaped gastrogastrostomy with a linear stapler was a relatively simple method during laparoscopic PPG, but it requires the sacrifice of part of the gastric antrum. Additionally, the antrum and proximal remnant stomach twist partially around the anastomosis, and the lesser curvature side was not used for anastomosis[15]. A retrospective analysis showed no significant difference in proximal margin, the number of lymph nodes, surgical complication and postoperative hospital stay between intracorporeal and extracorporeal anastomosis[17]. Ohashi *et al*[18] reported the “piercing method” to perform intracorporeal end-to-end anastomosis with a linear stapler, but this method is cumbersome and time-consuming. Similarly, overlap anastomosis also requires the sacrifice of a certain length of the gastric antrum. Interruption of the annular muscle may affect the function of the gastric antrum. Therefore, extracorporeal anastomosis is still performed by hand suture in many institutions.

ONCOLOGICAL SAFETY

The concerns surrounding the oncological safety of PPG come from two aspects: The limited dissection of the No. 5 and No. 6 lymph nodes and the resection margins of the stomach. Since PPG meets the requirement of a 2-cm margin, and the frozen section diagnosis can also determine the tumor resection margin during the operation. Therefore, the concerns mainly come from incomplete lymph node dissection. According to a database of 305 patients with middle-third EGC, the rate of No. 5 lymph node metastasis was 0.2%; meanwhile, a 98% overall 5-year survival and 0% cancer-specific mortality was reported after PPG[19]. Jiang *et al*[14] reported an overall 3-year survival rate of 97.8 % and disease-specific 3-year survival rate of 99.3 % in 188 patients received PPG. These results were consistent with previous reports on the mortality after distal gastrectomy (DG) for EGC. A multicenter cohort analysis involving 1004 EGC patients (502 PPG and 502 DG) showed that the 5-year overall survival rate was 98.4% for PPG and 96.6% for DG, and no significant differences in either overall survival or relapse-free survival between the two groups[20]. Another systematic review evaluated the pathological and oncological outcomes between PPG and DG in 4500 EGC patients. The results showed fewer lymph nodes harvested, shorter proximal and distal margins in the PPG group, and there was no significant difference in overall survival or relapse-free survival[21]. Thus, the oncological safety of PPG was comparable to that of DG in EGC patients. In addition, due to the accuracy of preoperative staging, some patients with preoperative diagnosis of T1 showed T2 or deeper invasion[22]. Whether such patients require additive surgery is another question to be concerned. Takahashi *et al* [23] reported that 6.4% of the patients had postoperative pT2 or deeper after PPG in 897 patients; nevertheless, no higher recurrence rate was observed in these patients. It has been reported that patients with a preoperative staging of T1 but postoperative pT2 had a better prognosis and less occurrence of lymph node metastases in comparison with patients preoperatively diagnosed as T2[24]. Although several retrospective studies have reported acceptable long-term survival outcomes for PPG[14,19,20,25,26], it has not been confirmed by prospective clinical studies. It is hoped that the ongoing multicenter randomized controlled trial KLASS-04 will settle the question of the advantages of PPG to DG in terms of oncological safety and functional benefits.

POSTOPERATIVE COMPLICATION

The core technology of PPG is the functional preservation of the pylorus, and it can theoretically prevent postoperative dumping syndrome and alkaline reflux. Recent studies have shown that compared with DG, PPG can maintain body weight and better postoperative nutritional status[25,27,28]. Terayama *et al*[29] compared postoperative skeletal muscle index between PPG and DG in old EGC patients, and the result showed a great advantage in maintaining the postoperative skeletal muscle mass after PPG. Moreover, the retention of the hepatic branches could also reduce the occurrence of cholestasis and gallbladder stones. Nevertheless, PPG is also associated with non-negligible postoperative complications, namely DGE, gastric stasis or gastroparesis. Therefore, to benefit patients with PPG, it is necessary to understand the mechanisms responsible for postoperative DGE and find the preventive methods. It is acknowledged that the normal pyloric function is largely dependent on the length of the pyloric cuff, together with the retention of circulation and nerve supply to the pyloric antrum. In the early years of PPG, surgeons focused on the retention of the vagus nerve and, at that time, the preservation of the pyloric and hepatic branches was strictly required. With the continuous deepening of research, people realized that the blood flow of the pyloric cuff was another important factor in the functional preservation of the pylorus. Kiyokawa *et al*[30] found that the preservation the infrapyloric vein significantly reduced the incidence of DGE after PPG, which may be effective to reduce pyloric edema. The appropriate length of the pyloric cuff is another important factor affecting postoperative complications. Nakane *et al*[31] demonstrated that 2.5 cm was superior in terms of some postoperative complications and weight recovery compared with 1.5 cm. However, Morita *et al*[32] found that the occurrence of gastric stasis did not differ between cuff length 3.0 cm and over 3.0 cm. The Postgastrectomy Syndrome Assessment Study after PPG revealed that the dimensions of the proximal gastric remnant and hand-sewn anastomosis also played a significant part in postoperative symptoms and quality of life[33]. In terms of patient eligibility, a retrospective study found that age (≥ 61 years), diabetes, and postoperative intra-abdominal infection were risk factors for DGE[23]. High body mass index was identified as another risk factor for gastric stasis after PPG[22]. The patients with the presence of hiatal hernia and dietary complications would predispose to reflux esophagitis after PPG[34,35].

CONCLUSION

PPG has been widely accepted as a function-preserving gastrectomy for middle-third EGC. Compared with DG, PPG has significant advantages in preventing dumping syndrome, body weight loss and bile reflux gastritis. The postoperative complications after PPG have reached an acceptable level. The preservation of pyloric function has complicated the technicalities of PPG and suggested the potential risks associated with incomplete lymph node dissection. The precise determination of functional benefits, oncological safety, technique standardization and the clarification of complications have not been strictly addressed. It is also not fully understood whether patients benefit from PPG if they suffer gastric stasis, or whether PPG for EGC increases the risk of secondary gastric cancer.

FOOTNOTES

Author contributions: Sun KK performed the research and wrote the paper; Wu YY designed the research and approved the final manuscript.

Conflict-of-interest statement: All the Authors have no conflict of interest related to the manuscript.

Open-Access: This article is an open-access article that was selected by an in-house editor and fully peer-reviewed by external reviewers. It is distributed in accordance with the Creative Commons Attribution NonCommercial (CC BY-NC 4.0) license, which permits others to distribute, remix, adapt, build upon this work non-commercially, and license their derivative works on different terms, provided the original work is properly cited and the use is non-commercial. See: <https://creativecommons.org/licenses/by-nc/4.0/>

Country/Territory of origin: China

ORCID number: Ke-Kang Sun 0000-0002-7442-2412; Yong-You Wu 0000-0002-4951-8068.

S-Editor: Lin C

L-Editor: A

P-Editor: Cai YX

REFERENCES

- 1 Maki T, Shiratori T, Hatafuku T, Sugawara K. Pylorus-preserving gastrectomy as an improved operation for gastric ulcer. *Surgery* 1967; **61**: 838-845 [PMID: 5338114]
- 2 Kosuga T, Tsujiura M, Nakashima S, Masuyama M, Otsuji E. Current status of function-preserving gastrectomy for gastric cancer. *Ann Gastroenterol Surg* 2021; **5**: 278-286 [PMID: 34095717 DOI: 10.1002/ags3.12430]

- 3 Mikulicz-Radecki J. Die chirurgische Behandlung des chronischen Magengeschwurs. *Verhandl Deutsch Gesselsch Chir* 1897; **26**: 31
- 4 Barber WH. Annular Segmental Gastrectomy. *Ann Surg* 1917; **66**: 672-678 [PMID: 17863827 DOI: 10.1097/0000658-191712000-00007]
- 5 Fujimura T, Fushida S, Kayahara M, Ohta T, Kinami S, Miwa K. Transectional gastrectomy: an old but renewed concept for early gastric cancer. *Surg Today* 2010; **40**: 398-403 [PMID: 20425540 DOI: 10.1007/s00595-009-4151-1]
- 6 Wangenstein OH. Segmental gastric resection: an acceptable operation for peptic ulcer; tubular resection unacceptable. *Surgery* 1957; **41**: 686-690 [PMID: 13422099]
- 7 Sasaki I, Fukushima K, Naito H, Matsuno S, Shiratori T, Maki T. Long-term results of pylorus-preserving gastrectomy for gastric ulcer. *Tohoku J Exp Med* 1992; **168**: 539-548 [PMID: 1306602 DOI: 10.1620/tjem.168.539]
- 8 Kodama M, Koyama K. Indications for pylorus preserving gastrectomy for early gastric cancer located in the middle third of the stomach. *World J Surg* 1991; **15**: 628-33; discussion 633 [PMID: 1949863 DOI: 10.1007/BF01789211]
- 9 Japanese Gastric Cancer Association. Japanese gastric cancer treatment guidelines 2018 (5th edition). *Gastric Cancer* 2021; **24**: 1-21 [PMID: 32060757 DOI: 10.1007/s10120-020-01042-y]
- 10 Nunobe S, Hiki N, Fukunaga T, Tokunaga M, Ohyama S, Seto Y, Yamaguchi T. Laparoscopy-assisted pylorus-preserving gastrectomy: preservation of vagus nerve and infrapyloric blood flow induces less stasis. *World J Surg* 2007; **31**: 2335-2340 [PMID: 17952497 DOI: 10.1007/s00268-007-9262-5]
- 11 Khalayleh H, Kim YW, Yoon HM, Ryu KW. Assessment of Lymph Node Metastasis in Patients With Gastric Cancer to Identify Those Suitable for Middle Segmental Gastrectomy. *JAMA Netw Open* 2021; **4**: e211840 [PMID: 33729506 DOI: 10.1001/jamanetworkopen.2021.1840]
- 12 Shinohara H, Kurahashi Y, Kanaya S, Haruta S, Ueno M, Udagawa H, Sakai Y. Topographic anatomy and laparoscopic technique for dissection of no. 6 infrapyloric lymph nodes in gastric cancer surgery. *Gastric Cancer* 2013; **16**: 615-620 [PMID: 23314832 DOI: 10.1007/s10120-012-0229-3]
- 13 Hiki N, Kaminishi M. Pylorus-preserving gastrectomy in gastric cancer surgery--open and laparoscopic approaches. *Langenbecks Arch Surg* 2005; **390**: 442-447 [PMID: 16096761 DOI: 10.1007/s00423-005-0573-4]
- 14 Jiang X, Hiki N, Nunobe S, Fukunaga T, Kumagai K, Nohara K, Sano T, Yamaguchi T. Postoperative outcomes and complications after laparoscopy-assisted pylorus-preserving gastrectomy for early gastric cancer. *Ann Surg* 2011; **253**: 928-933 [PMID: 21358534 DOI: 10.1097/SLA.0b013e3182117b24]
- 15 Kumagai K, Hiki N, Nunobe S, Sekikawa S, Chiba T, Kiyokawa T, Jiang X, Tanimura S, Sano T, Yamaguchi T. Totally laparoscopic pylorus-preserving gastrectomy for early gastric cancer in the middle stomach: technical report and surgical outcomes. *Gastric Cancer* 2015; **18**: 183-187 [PMID: 24481853 DOI: 10.1007/s10120-014-0337-3]
- 16 Yang J, Xie J, Xu L, Yin Y, Lao X, Yan Z. Clinical Experience of Intracorporeal Hand-sewn Anastomosis Following Totally Laparoscopic Pylorus-Preserving Gastrectomy for Middle-Third Early Gastric Cancer. *J Gastrointest Surg* 2022; **26**: 659-661 [PMID: 34545544 DOI: 10.1007/s11605-021-05132-9]
- 17 Alzahrani K, Park JH, Lee HJ, Park SH, Choi JH, Wang C, Alzahrani F, Suh YS, Kong SH, Park DJ, Yang HK. Short-term Outcomes of Pylorus-Preserving Gastrectomy for Early Gastric Cancer: Comparison Between Extracorporeal and Intracorporeal Gastrogastronomy. *J Gastric Cancer* 2022; **22**: 135-144 [PMID: 35534450 DOI: 10.5230/jgc.2022.22.e16]
- 18 Ohashi M, Hiki N, Ida S, Kumagai K, Nunobe S, Sano T. A novel method of intracorporeal end-to-end gastrogastronomy in laparoscopic pylorus-preserving gastrectomy for early gastric cancer, including a unique anastomotic technique: piercing the stomach with a linear stapler. *Surg Endosc* 2018; **32**: 4337-4343 [PMID: 29785457 DOI: 10.1007/s00464-018-6237-6]
- 19 Hiki N, Sano T, Fukunaga T, Ohyama S, Tokunaga M, Yamaguchi T. Survival benefit of pylorus-preserving gastrectomy in early gastric cancer. *J Am Coll Surg* 2009; **209**: 297-301 [PMID: 19717032 DOI: 10.1016/j.jamcollsurg.2009.05.027]
- 20 Aizawa M, Honda M, Hiki N, Kinoshita T, Yabusaki H, Nunobe S, Shibasaki H, Matsuki A, Watanabe M, Abe T. Oncological outcomes of function-preserving gastrectomy for early gastric cancer: a multicenter propensity score matched cohort analysis comparing pylorus-preserving gastrectomy versus conventional distal gastrectomy. *Gastric Cancer* 2017; **20**: 709-717 [PMID: 27672061 DOI: 10.1007/s10120-016-0644-y]
- 21 Hou S, Liu F, Gao Z, Ye Y. Pathological and oncological outcomes of pylorus-preserving versus conventional distal gastrectomy in early gastric cancer: a systematic review and meta-analysis. *World J Surg Oncol* 2022; **20**: 308 [PMID: 36153587 DOI: 10.1186/s12957-022-02766-0]
- 22 Park DJ, Kim YW, Yang HK, Ryu KW, Han SU, Kim HH, Hyung WJ, Park JH, Suh YS, Kwon OK, Yoon HM, Kim W, Park YK, Kong SH, Ahn SH, Lee HJ. Short-term outcomes of a multicentre randomized clinical trial comparing laparoscopic pylorus-preserving gastrectomy with laparoscopic distal gastrectomy for gastric cancer (the KLASS-04 trial). *Br J Surg* 2021; **108**: 1043-1049 [PMID: 34487147 DOI: 10.1093/bjs/znab295]
- 23 Takahashi R, Ohashi M, Hiki N, Makuuchi R, Ida S, Kumagai K, Sano T, Nunobe S. Risk factors and prognosis of gastric stasis, a crucial problem after laparoscopic pylorus-preserving gastrectomy for early middle-third gastric cancer. *Gastric Cancer* 2020; **23**: 707-715 [PMID: 31916027 DOI: 10.1007/s10120-019-01037-4]
- 24 Tokunaga M, Hiki N, Fukunaga T, Ohyama S, Yamada K, Yamaguchi T. Better prognosis of T2 gastric cancer with preoperative diagnosis of early gastric cancer. *Ann Surg Oncol* 2009; **16**: 1514-1519 [PMID: 19290492 DOI: 10.1245/s10434-009-0404-x]
- 25 Tsujiura M, Hiki N, Ohashi M, Nunobe S, Kumagai K, Ida S, Hayami M, Sano T, Yamaguchi T. Excellent Long-Term Prognosis and Favorable Postoperative Nutritional Status After Laparoscopic Pylorus-Preserving Gastrectomy. *Ann Surg Oncol* 2017; **24**: 2233-2240 [PMID: 28280944 DOI: 10.1245/s10434-017-5828-0]
- 26 Morita S, Katai H, Saka M, Fukagawa T, Sano T, Sasako M. Outcome of pylorus-preserving gastrectomy for early gastric cancer. *Br J Surg* 2008; **95**: 1131-1135 [PMID: 18690631 DOI: 10.1002/bjs.6295]
- 27 Eom BW, Park B, Yoon HM, Ryu KW, Kim YW. Laparoscopy-assisted pylorus-preserving gastrectomy for early gastric cancer: A retrospective study of long-term functional outcomes and quality of life. *World J Gastroenterol* 2019; **25**: 5494-5504 [PMID: 31576095 DOI: 10.3748/wjg.v25.i36.5494]
- 28 Suh YS, Han DS, Kong SH, Kwon S, Shin CI, Kim WH, Kim HH, Lee HJ, Yang HK. Laparoscopy-assisted pylorus-preserving gastrectomy is better than laparoscopy-assisted distal gastrectomy for middle-third early gastric cancer. *Ann Surg* 2014; **259**: 485-493 [PMID: 23652333 DOI: 10.1097/SLA.0b013e318294d142]
- 29 Terayama M, Ohashi M, Makuuchi R, Hayami M, Ida S, Kumagai K, Sano T, Nunobe S. A continuous muscle-sparing advantage of pylorus-preserving gastrectomy for older patients with cT1N0M0 gastric cancer in the middle third of the stomach. *Gastric Cancer* 2023; **26**: 145-154 [PMID: 36207477 DOI: 10.1007/s10120-022-01345-2]

- 30 **Kiyokawa T**, Hiki N, Nunobe S, Honda M, Ohashi M, Sano T. Preserving infrapyloric vein reduces postoperative gastric stasis after laparoscopic pylorus-preserving gastrectomy. *Langenbecks Arch Surg* 2017; **402**: 49-56 [PMID: 27815708 DOI: 10.1007/s00423-016-1529-6]
- 31 **Nakane Y**, Michiura T, Inoue K, Sato M, Nakai K, Yamamichi K. Length of the antral segment in pylorus-preserving gastrectomy. *Br J Surg* 2002; **89**: 220-224 [PMID: 11856138 DOI: 10.1046/j.0007-1323.2001.01984.x]
- 32 **Morita S**, Sasako M, Saka M, Fukagawa T, Sano T, Katai H. Correlation between the length of the pyloric cuff and postoperative evaluation after pylorus-preserving gastrectomy. *Gastric Cancer* 2010; **13**: 109-116 [PMID: 20602198 DOI: 10.1007/s10120-010-0549-0]
- 33 **Namikawa T**, Hiki N, Kinami S, Okabe H, Urushihara T, Kawahira H, Fukushima N, Kodera Y, Yumiba T, Oshio A, Nakada K. Factors that minimize postgastrectomy symptoms following pylorus-preserving gastrectomy: assessment using a newly developed scale (PGSAS-45). *Gastric Cancer* 2015; **18**: 397-406 [PMID: 24760336 DOI: 10.1007/s10120-014-0366-y]
- 34 **Nunobe S**, Hiki N. Function-preserving surgery for gastric cancer: current status and future perspectives. *Transl Gastroenterol Hepatol* 2017; **2**: 77 [PMID: 29034350 DOI: 10.21037/tgh.2017.09.07]
- 35 **Otake R**, Kumagai K, Ohashi M, Makuuchi R, Ida S, Sano T, Nunobe S. Reflux Esophagitis After Laparoscopic Pylorus-Preserving Gastrectomy for Gastric Cancer. *Ann Surg Oncol* 2023; **30**: 2294-2303 [PMID: 36509874 DOI: 10.1245/s10434-022-12902-5]



Published by **Baishideng Publishing Group Inc**
7041 Koll Center Parkway, Suite 160, Pleasanton, CA 94566, USA

Telephone: +1-925-3991568

E-mail: office@baishideng.com

Help Desk: <https://www.f6publishing.com/helpdesk>

<https://www.wjgnet.com>

