

WJG 20th Anniversary Special Issues (1): Hepatocellular carcinoma

Alcohol and hepatocellular carcinoma: A review and a point of view

Gianni Testino, Silvia Leone, Paolo Borro

Gianni Testino, Paolo Borro, Centro Alcológico Regionale-Regione Liguria, Alcoholic Unit, Department of General Internal and Specialist Medicine, IRCCS AOU San Martino-National Institute for Cancer Research-IST, 16100 Genova, Italy
 Silvia Leone, Department of Internal Medicine, Clinical Pharmacology and Toxicology Unit, University of Genoa, 16100 Genova, Italy

Author contributions: Testino G, Leone S and Borro P contributed equally to this work.

Correspondence to: Gianni Testino, MD, Centro Alcológico Regionale-Regione Liguria, Alcoholic Unit, Department of General Internal and Specialist Medicine, IRCCS AOU San Martino-National Institute for Cancer Research-IST, Padiglione 10, Piazzale R. Benzi 10, 16132 Genova, Italy. gianni.testino@hsanmartino.it
 Telephone: +39-1-5552769 Fax: +39-1-5552738

Received: February 14, 2014 Revised: April 30, 2014

Accepted: July 22, 2014

Published online: November 21, 2014

stage with portal hypertension, liver transplantation is the optimal option; and in cases of associated disease, percutaneous ethanol injections, radiofrequency and microwave ablation are the ideal treatments. Despite the possibility of detecting microvascular invasion with HR, several studies and some randomized controlled trials revealed that overall survival and DSF rates in patients with VES HCC are much the same after ablation and HR. Therefore, ablation can be regarded as a first-line choice for patients with VES HCC. It is important to emphasize that the choice of treatment should be weighed carefully in the context of a multidisciplinary cancer team.

© 2014 Baishideng Publishing Group Inc. All rights reserved.

Key words: Alcohol; Alcoholic liver disease; Hepatocellular carcinoma; Percutaneous ablation

Abstract

It is well recognized that one cause of chronic liver disease and hepatocellular carcinoma (HCC) is alcohol consumption. Research in Italy and the United States concludes that the most common cause of HCC (responsible for 32% to 45% of HCC) is alcohol. It has recently been shown that a significant relationship between alcohol intake, metabolic changes, and hepatitis virus infection does exist. Alcohol may be a factor in the development of HCC *via* direct (genotoxic) and indirect mechanisms (cirrhosis). There is only one way of diagnosing HCC, which is early identification through surveillance, when curative treatments become possible. After stopping alcohol intake the risk of liver cancer decreases by 6% to 7% a year, and an estimated time period of 23 years is also needed. Therefore, surveillance is also important in former drinkers and, in our opinion, independently from the presence of compensated cirrhosis. In cases of very early stage (VES) and early

Core tip: It is well recognized that one cause of chronic liver disease and hepatocellular carcinoma (HCC) is alcohol consumption. There is only one way of diagnosing HCC, which is early identification through surveillance, when curative treatments become possible. After stopping alcohol intake the risk of liver cancer decreases by 6% to 7% a year, and an estimated time period of 23 years is also needed. Ablation can be regarded as a first-line choice for patients with very early stage HCC. It is important to underline that the choice of treatment should be weighed carefully in the context of a multidisciplinary cancer team.

Testino G, Leone S, Borro P. Alcohol and hepatocellular carcinoma: A review and a point of view. *World J Gastroenterol* 2014; 20(43): 15943-15954 Available from: URL: <http://www.wjgnet.com/1007-9327/full/v20/i43/15943.htm> DOI: <http://dx.doi.org/10.3748/wjg.v20.i43.15943>

INTRODUCTION

Hepatocellular carcinoma (HCC) is ranked the sixth most common form of cancer globally, and is the third most common cause of cancer mortality^[1]. The most recent statistics available estimated 609000 deaths globally from this disease in 2004^[2].

According to the World Health Organization (WHO), liver disease is responsible for 70% of directly recorded mortality from alcohol, and alcohol causes around 80% of deaths from liver disease^[3].

Among men and women, 33% (11%-54%) and 18% (3%-38%) of the total number of HCCs is caused by past and present alcohol intake in the selected European countries (France, Italy, the United Kingdom, the Netherlands, Greece, Germany, and Denmark)^[4].

More recently, Welzel *et al.*^[5] evidenced that the largest attributable fraction of the population is associated with alcohol abuse plus HCV infection (39.7%), followed by diabetes/obesity (36.6%), alcohol related liver disorders (23.5%), HCV (22.4%), HBV (6.3%), and rare genetic disorders (3.2%).

Mancebo *et al.*^[6] affirmed that the annual HCC rate among those patients with Child-Pugh Class A or B alcoholic cirrhosis is around 2.5%. Both platelet count and age can be used to classify those at risk of developing HCC into 3 separate groups during the next 5 years. The annual HCC rate in the group having neither of these factors (age < 55 years, platelets > 125000), with one factor (age > 55 years or platelets < 125000), and with both factors (age > 55 years and platelets < 125000) was 0.3%, 2.6%, and 4.8% ($P < 0.0001$) respectively.

NATURAL HISTORY OF ALCOHOL ASSOCIATED TO HCC

The spectrum of hepatic injury caused by alcohol ranges from clinically insignificant or biochemical damage, to alcoholic hepatitis, fatty liver, and all the way up to cirrhosis^[7,8].

Alcohol intake leads to liver damage through endotoxins, oxidative stress, and inflammation^[8,9].

Furthermore, independently to the ingestion of alcohol through drinking, ethanol is produced endogenously in small quantities in a normal intermediary metabolism, and in the gastrointestinal tract in particular, by the formation of microbes. The concentrations caused by this process in human venous blood have been approximated as being between 0 and 50 μm ^[5].

Liver function is responsible for most alcohol metabolism. The three metabolic systems in the liver able to perform ethanol oxidation are: the microsomal ethanol oxidizing system, which is to be found in the smooth endoplasmic reticulum of hepatocytes, cytosolic alcohol dehydrogenase (ADH), and catalase, situated on the peroxisomes. The finished product of all these hepatic enzymes is acetaldehyde.

The dominating enzyme pathway is alcohol dehydro-

genase^[8].

The alcohol oxidation caused by any of the mechanisms outlined above produces acetaldehyde, which is quickly metabolized to acetate, mostly by cytosolic Aldehyde Dehydrogenase 1 (ALDH1) and mitochondrial Aldehyde Dehydrogenase 2 (ALDH2)^[7,8].

There are various histological stages through which alcoholic liver disease (ALD) is thought to advance: fatty liver (steatosis), steatohepatitis (alcoholic hepatitis, alcoholic steatonecrosis), fibrosis, cirrhosis and HCC.

Alcoholic steatosis is largely macrovesicular, being more pronounced in zone three of the liver acinus, the area around the central veins. As yet there has been no clarification of the pathophysiology of ALD. The intra-mitochondrial redox potential is changed by the metabolism of ethanol through the generation of NADH by ADH. Oxidative stress is thus caused by ethanol. This in turn is detrimental to tricarboxylic acid cycle activity and the beta-oxidation of fatty acids, leading to an increase in intra-hepatocellular free fatty acids, a greater formation of triacylglycerol, and higher rates of synthesis of very low-density lipoprotein^[9].

A non-oxidative pathway of ethanol also exists. In order to form fatty acid ethyl esters the esterification of ethanol with fatty acids has to take place; this reaction is initiated and catalysed by the fatty acid ethyl esters synthase enzyme. Phosphatidylethanol *via* phospholipase D with a decrease in phosphatidylcholine is also generated *via* this pathway^[8].

The intestinal epithelial tight junctions are disturbed by acetaldehyde through augmenting the intestinal permeability to endotoxins. A vital part is played by endotoxemia in damaging the liver by triggering Kupffer cells to secrete a spectrum of reactive oxygen intermediates and cytokines, and by causing hepatic sinusoids to increase vascular permeability^[8]. Tumor necrosis factor (TNF)- α , along with a rise in TNF- α receptors, and acting as an inflammatory mediator, could well lead to further hepatic injury. It is recognized that an increase in TNF- α is related to a worse prognosis^[8]. We can state that cellular oxidative-stress (due to a disproportion between a lack of anti-oxidant defence mechanisms and the generation of free radicals, which includes a decrease in phosphatidylcholine, glutathione, and vitamin E) along with endotoxemia are definitely the main mediators in the progression to steatohepatitis and fibrosis^[8].

Around 20% to 40% of patients with steatosis have changes on their liver biopsies indicative of steatohepatitis: steatosis along with hepatocellular damage and the related fibrosis and inflammation.

When steatohepatitis has developed, the liver morphology rarely goes back to normal, even after cessation, and there is a higher risk of the development of cirrhosis. Once the stellate cells have been activated (fibrogenesis), the hepatic stellate cells (HSC) react to a range of stimuli in both an autocrine and paracrine way to reproduce, migrate and contract; they secrete extracellular matrix components, cytokines, chemokine, proteases and growth

factors. They also express transcription factors and signalling molecules^[8].

Three principal kinds of scarring are prominent in human ALD: sinusoidal capillarization (pericellular fibrosis), centrilobular scarring and periportal fibrosis. The fibrosis process ends in central-to-central veins bridging fibrosis and regenerative nodules, or cirrhosis.

Among the various genetic polymorphisms that favour alcoholic hepatopathy, some of them are strongly determining. The list includes genes that modulate alcohol metabolism, oxidative stress, lipid storage, endotoxin-induced inflammation, and fibrogenetic pathways. Recently, two genetic polymorphisms have been identified: TNF- α and patatin-like phospholipase domain-containing protein 3^[10].

Polymorphism of the gene encoding for CD14 expressed on a Kupffer cell has been implicated in the risk of ALD and HCC.

RISK FACTORS

There is no clear-cut linear association between the amount of alcohol ingested and the development of hepatic disease.

Studies have shown women to be two times as susceptible as men to alcohol-mediated hepatotoxicity, and they can develop more serious ALD after a shorter time consuming alcohol and with smaller quantities.

It was found by O'Shea *et al*^[11] that consuming 25 to 80 g/d of alcohol for 10 years or more for men and 12 to 20 g/d for women increases the risk of developing cirrhosis.

It was reported by Bellentani *et al*^[12] that the changes of developing cirrhosis or more minor liver disease with an alcohol consumption of more than 30 g/d were 13.7 and 23.6 in comparison to teetotallers^[8,12].

In a more up-to-date meta-analysis, increased chances of death from cirrhosis was observed in both men and women consuming 12-24 g of alcohol daily. Furthermore, the study also recorded a significant rise in women drinking up to 12 g/d. It has been proposed by the European Association for the Study of Liver Disease that if there is a threshold, then it is very low and difficult to detect due to the difficulties of measuring a daily alcohol intake of less than 10-12 g^[8].

Consuming alcohol between mealtimes has been shown to raise the odds of developing ALD by 2.7 times in comparison with those who drink only with their meals.

Other crucial important independent risk factors come into play: abdominal fat, obesity, diabetes, hyperlipidaemia, resistance to insulin, metabolic syndrome, various hepatitis viruses (mostly HBV and HCV) and Pearls grade^[8,11,13].

It was demonstrated by Raynard *et al*^[14] that blood fasting glucose and body mass index (BMI) are further independent risk factors for the development of fibrosis in alcohol-related hepatic disease. It has also been independ-

ently verified that there is a correlation between Pearls Grade and a fibrosis score. Being overweight or obese also lead to a rise in susceptibility to endotoxin hepatic injury. Moreover, it is recognized that there is a close association between endotoxemia and the severity of alcohol-related hepatic damage.

Alcohol consumption and chronic hepatitis C infection are responsible for 70% to 90% of all chronic hepatic disease in western countries. Moreover, as many as 8% to 43% of patients with ALD also test positive for anti-HCV.

A major risk factor in both the histological and clinical progression of HCV infection is alcohol consumption. It was shown in a recent study that the combined effects of alcohol and HCV work together to augment free radical formation in the liver, and to lower its antioxidant defences. Moreover, it has been assessed that both moderate (< 50 g/d) and heavy drinking (> 50 g/d) increase the odds of developing oxidative stress by 3 times and 13 to 24 times, respectively^[9,15]. It was also demonstrated by Perlemuter *et al*^[16] that the expression of HCV core protein and chronic ingestion of alcohol in combination enhance hepatic lipid peroxidation and work together to increase the expression of hepatic TNF- α and TGF- β . The HSC are activated by TGF- β , causing extracellular matrix to be overproduced; The formation of ROS is also caused by TGF- β , which may lead to further hepatic fibrosis^[9,16].

ALCOHOL AND CARCINOGENESIS

Recently, the International Agency for Cancer Research (WHO) evidenced that ethanol, acetaldehyde and alcohol intake are carcinogenic for humans (group 1). Alcohol consumption is associated with an increased risk of the following cancer types: head and neck, oral cavity, pharynx, larynx, oesophagus, bowel, breast and, obviously, liver^[17-20].

The underlying causes of cancers related to alcohol consumption are not yet clear, although various factors have been proposed as having a role to play^[21-23]: the localized effects of alcohol, the induction of cytochrome P4502E1 (CYP2E1) (the conversion of various xenobiotics), acetaldehyde (isoenzyme polymorphism), malnutrition, the interaction with retinoids, alterations in the level of methylation, immunological surveillance and angiogenesis.

Alcohol could well be crucial in initiating cancers, due to enhancing certain oncogene expression or the impairment of cells' ability to mend their DNA, thus increasing the chances that oncogenic mutations will take place.

ADH metabolizes ethanol to acetaldehyde. This function is also carried out by CYP2E1 and, to a much lesser degree, by catalase. It is then oxidized to acetate by ALDH.

Acetaldehyde is not only extremely toxic, it is also carcinogenic. Cells or tissues are exposed to an amount of acetaldehyde after alcohol consumption which may be

significant and could well increase carcinogenesis.

Acetaldehyde derived from the metabolism of ethanol is carcinogenic for humans (Group 1: oesophagus, neck and head). Studies have shown^[8] that beer has a significantly lower acetaldehyde content than wine or spirits.

ALDH is the enzyme which causes the oxidation of acetaldehyde. Acetaldehyde formation and degradation is dependent on the actions of both ADH and ALDH.

Exposure to acetaldehyde in men is known to be cumulative. An up-to-date, large-scale epidemiological survey has backed up this premise by showing a supra-multiplicative combined chance of oesophageal cancer in subjects who consume both alcohol and tobacco, and who were low ADH1B and ALDH2-deficient carriers (the highest adjusted OR being as high as 382.3)^[8,24,25].

The activity of total alcohol dehydrogenase is significantly greater in cancer tissues than in healthy ones (*i.e.* oesophagus, liver and colon-rectum). ADH activity in cancer cells is much greater than ALDH activity, indicating that cancer cells have a higher propensity for ethanol oxidation, but less capability for removing acetaldehyde than healthy tissues^[8,26,27].

Both ADH and ALDH are encoded by multiple genes. As some of these genes exist in several different forms and the enzymes which are encoded by certain of these variants may lead to increased levels of acetaldehyde, the presence of these variants may cause a predisposition to cancer. Recently it was evidenced that the combination of a genotype of myeloperoxidase (MPO) (associated with higher MPO expression), and just one Ala-superoxide dismutase 2 allele (related to high hepatic iron levels) significantly increases the odds of the occurrence of HCC and mortality in patients suffering from alcoholic cirrhosis^[8,28,29].

It is possible that alcohol acts as a co-carcinogen by increasing the effects of direct carcinogens found, for example, in diet and tobacco. This effect of alcohol is partly due to CYP450 enzyme induction (in the lungs, liver and intestine), which can metabolize various dietary and tobacco components into those free radicals which promote cancer^[23].

The concentration of CYP2E1 in the liver has been demonstrated as being possibly related to hydroxyethyl radical generation, and therefore to lipid peroxidation. Lipid peroxidation triggers the production of 4-hydroxynonenal, which can bind to purine and pyrimidine DNA bases, thus generating carcinogenic exocyclic etheno-DNA adducts. A significant association has been shown to exist between CYP2E1 induction and the occurrence of exocyclic etheno-DNA adducts in hepatocytes.

It has been demonstrated by Seitz that CYP2E1 activity takes place at fairly low levels of alcohol ingestion (40 g/d) and that, with this level of consumption, induction is detectable even within one week, although how far and how much is different between individuals. Some patients show a very minor level of CYP2E1 activity-related induction, while others show a much higher level. Therefore, it is likely that this difference in level of CYP2E1

activity-related induction may have an effect on alcoholic carcinogenesis in men^[22].

Chronic alcohol ingestion also leads to lower levels of retinoic acid. This is mainly caused by CYP2E1 induction, which leads to the degradation of retinol and retinoic acid to polar metabolites (for example, 4-oxo and 18-hydroxy retinoic acid). This rise in the metabolism of retinoic acid leads to reduced levels of retinoic acid, thus causing an augmented expression of the AP1 gene and a subsequent rise in the c-jun and c-fos proteins. In the end this leads to a rise in cyclin D1, which is related to hyperproliferation in the liver. Therefore, there is a relationship between retinoic acid deficiency and accelerated carcinogenesis^[22].

DNA methylation alters the expression of genes: hypomethylation is related to enhanced gene expression. The hypomethylation of tumor promoter genes in particular has been suggested as a possible underlying factor for the cancer development. The decrease in the liver enzyme methyladenosyltransferase II in alcohol-related diseases causes lower S-adenosylmethionine (SAME) production, (the methyl donor for DNA methylation reactions). Moreover, levels of homocysteine are usually augmented in alcohol-related diseases, leading to an increase in S-adenosylhomocysteine levels and restricting the activity of DNA methyltransferase enzymes. In some experimental models, a scarcity of SAME caused by a diet lacking in methionine-choline, causes DNA hypomethylation and increases in the breaking of DNA strands, thereby producing DNA instability and a greater risk of cancer. In transgenic mice which have no methyladenosyltransferase II, the spontaneous development of HCC occurs. These experiments provide evidence for DNA methylation abnormalities being an underlying factor for cancer in alcohol-related diseases^[30-33]. Figure 1 shows the main alcohol-induced carcinogenic pathways.

HEPATOCARCINOGENESIS

Role of alcohol

Alcohol-related cirrhosis of the liver is most likely the main risk factor for HCC in groups of people with low rates of infection of the hepatitis B and hepatitis C viruses, such as the United States and northern Europe.

There have been studies in the United States and in Italy which indicate that alcohol is the main cause of HCC (making up 32% to 45% of HCC).

Alcohol intake has definitely been recognized as a cause of HCC. This may well be related to the development of HCC due to direct (genotoxic) and indirect factors (cirrhosis development)^[34].

There is a liver carcinogenesis model proposed by Donato *et al.*^[34] showing the disease to have been caused by alcohol consumption.

It shows both the early (initiation) and late stages (promotion/progression) of carcinogenesis.

Long-term alcohol intake, as mentioned above, causes CYP2E1 enzyme induction; this results in augmented

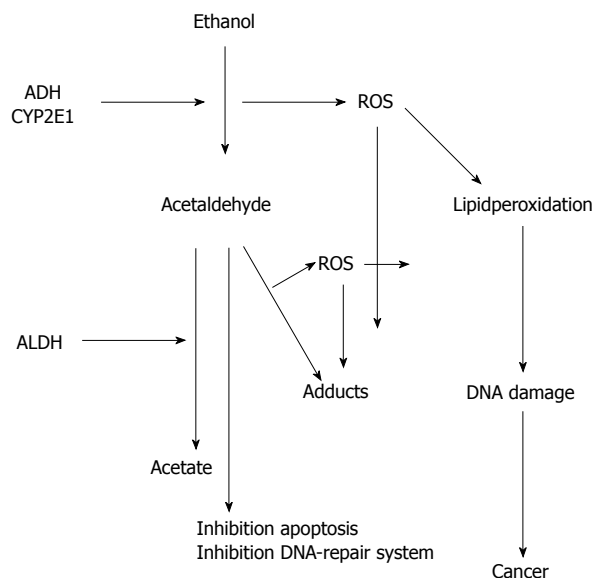


Figure 1 Alcohol ANS carcinogenesis. ADH: Alcohol dehydrogenase; CYP2E1: Cytochrome P4502E1; ALDH: Aldehyde dehydrogenase; ROS: Reactive oxygen species.

hepatic acetaldehyde production. Hepatic oxidative stress and the production of reactive oxygen species (ROS), especially hydroxyethyl radicals, increase dramatically. ROS is able to form protein adducts and DNA. Free radicals are also able to react with lipid molecules located in the cell membrane, allowing the production of biologically reactive aldehyde molecules.

We recently studied the various mechanisms of the *starting-point* of carcinogenesis in subjects with long-term ALD^[34,35].

Since alcohol is one of the leading causes of ROS production and oxidative stress, how often DNA damage occurs in the peripheral lymphocytes of patients with ALD seems to be of particular interest.

According to our experience, human lymphocytes were separated from peripheral blood (4 mL) using centrifugation through a Ficoll solution for 30 min at $400 \times g$. After being plated in 24-well uncoated tissue culture plates (2×10^5 cells/14.5-mm well), the fragmentation of the DNA was measured using an alkaline Comet assay as used by Singh *et al.*^[36]. For each patient the images of 50 randomly chosen cells from 2 slides were studied, and how much DNA damage had occurred was measured by tail length (TL) and tail moment (TM) with computerized image analysis (Sorin System, Florence, Italy). TM is calculated by measuring the tail length and the fraction of the total DNA contained in the tail.

A statistically significant increase in average TL and TM values can indicate alkali-labile sites and DNA single-strand breaks, was evidenced in the lymphocytes of subjects with alcoholic cirrhosis.

These data indicate a direct genotoxic effect of alcohol. The close relationship between alcohol consumption and oxidative DNA damage indicates that free radicals arising from the metabolism of ethanol could lead to the

fragmentation of DNA in lymphocytes. In general, these results indicate that genotoxic mechanisms may occur in alcohol-dependent subjects' livers, and therefore may be a factor behind hepatocarcinogenesis.

Moreover, the level of fragmentation of DNA in peripheral blood lymphocytes seems to correlate with how severe liver cirrhosis is.

Lambert *et al.*^[37] defined DNA methylation patterns in HCC. They discovered a high number of specific genes with aberrant hypermethylation. The genes which were differentially hypermethylated in HCC are commonly found in the host response to infection (DOK1), neurotransmission and angiogenic growth (CHRNA3), Ras signalling (RASSF1A), and detoxification of carcinogens (GSTP1).

The most commonly hypermethylated gene is RASSF1A which is a tumor suppressor gene. The second most frequently methylated gene (tumor suppressor) in HCCs is DOK1. In 54% of the cases, hypermethylation of GSTP1 was found. GSTP1 belongs to the glutathione S-transferase family that prevents variety of carcinogens from damaging cells. Lambert *et al.*^[37] concluded that specific genes in cirrhotic tissue with aberrant methylation, although not at all common, backed up the theory that the hypermethylation of certain genes in pre-malignant lesions could well predate and thus be a factor in the development of hepatic cancer.

Human Toll-like-receptor (TLR) constitutes 11 members, structurally recognizable by the existence of a leucine-rich repeat domain within their extracellular domain, and a Toll/Interleukin-1 receptor domain within their intracellular domain; each one being responsible for recognizing specific viruses, bacteria and fungi microbial structures. Despite a robust pro-inflammatory and antiviral response after TLR stimulation being favourable to get rid of pathogens at first, a longer or greater activation of TLR signalling could well be disadvantages^[38]. TLRs are molecular sensors; they sense products deriving from pathogens, and bind to various adapter proteins that kick-start specific signalling pathways, for example the interleukin 1 (IL1), the receptor-associated kinase family, and the TANK-binding kinase 1. These adapters trigger pathways which cause the activation of their own specific transcription factor; interferon regulatory factor 3 (IRF3) and nuclear factor kappa B (NF- κ B). Both IRF3 NF- κ B cause the discharge of many different immune and inflammatory cytokines such as TNF and IL6, which have proven to be perfect targets for inflammatory diseases. In experimental models, mice deficient in TLR were discovered to be safe from, or developed fewer inducible tumors. These findings indicate that biological signals are stimulated tumor cells activated by TLR; this might be a connection between inflammation and cancer on a molecular level^[38].

Eirò *et al.*^[38] showed a relationship between the expression of TLR, tumor aggression and unfavourable prognosis. These outcomes provide support for conducting additional studies about the impact of TLRs on HCC

prognosis, and to investigate and develop novel therapeutic strategies for liver cancer.

Forty percent of HCCs are clonal, and are thus considered to originate from progenitor/stem cells.

Telomere length in proliferating tissues is longest at birth and shortens progressively with age, so telomere length is a marker of biological cellular aging. Individuals with shorter telomeres have a higher risk of cancer at multiple sites.

Pavanello *et al.*^[39] demonstrated that telomere length was nearly halved in alcohol consumers compared with controls, and decreased in relation with an increase in drink-units per day. Individuals drinking > 4 drink-units/d had substantially shorter telomere lengths than those drinking < 4 drink-units/d. Telomere shortening is a feature of chronic liver disease and cirrhosis. Telomerase reactivation has been associated with hepatocarcinogenesis in the advanced stages (dysplastic lesions up to well differentiated, moderately differentiated and poorly differentiated HCC)^[40]. Eighty five percent of human HCC specimens showed a reactivation of telomerase activity, thus providing a selection advantage aiding uncontrolled hepatocyte replication^[41].

Loss and/or mutation of p53 usually occurs in late stages of tumorigenesis (dysplastic nodule HCC)^[40].

A methyl-deficient diet is often observed in alcoholics. Lu and Mato^[42] demonstrated that knockout mice with impaired SAMe synthesis spontaneously developed fatty liver and hepatocellular carcinoma; SAMe administration induced apoptosis in the hepatoma cells and prevented liver cancer, thus supporting this hypothesis.

During the late phase (promotion/progression), hepatocyte DNA could well be caused by hyperproliferation to become vulnerable to mutagenesis, leading to gene instability. Moreover, it has been shown that HCC develops due to chronic oxidative stress applying specific pressure that gives rise to the outgrowth of progenitor cell clones which are most resistant to oxidant injury^[43].

Usually, liver progenitor cells are the second line of defence against liver failure. Oval cells have the bipotential ability to differentiate between hepatocytes and bile duct cells. Progenitor cells are present in the terminal bile ductules, also called the canals of Hering. This latent group of cells is a reserve population to be triggered to action when the adult hepatocytes cannot mend or regenerate the damaged liver. The oval cells reproduce in the portal zone and appear to be a grouping of progenitor cells surrounded by cells made up of intermediate differentiation.

Most mature hepatocytes in alcoholic fatty livers are senescent, and cannot replicate to compensate for the increased rates of hepatocyte death caused by ethanol^[44].

Gu *et al.*^[45] highlighted that ethanol induces angiogenesis and vascular endothelial growth factor (VEGF) expression. In their research, a CAM model from the embryo of a chick with human fibrosarcoma was used to show that administering a physiologically appropriate dose of ethanol produced a significant rise in intramu-

ral vascular volume density and growth of tumor and, together with the up-regulation of VEGF expression in tumors. The authors discovered that physiologically relevant amounts of alcohol led to a dose-related rise in both VEGF mRNA, and protein expression in cultured fibrosarcoma cells in humans.

This experience of Gu *et al.*^[45] supports the hypothesis that angiogenesis induction and VEGF expression by alcohol represent an important factor behind the progression of cancer associated with alcohol intake^[46].

Matsushashi *et al.*^[47] evidenced that alcohol intake is closely related to the tumor volume doubling time of HCC in patients with type C cirrhosis.

Nahon *et al.*^[29] demonstrated that MPO and manganese superoxide dismutase 2 (MnSOD2) polymorphisms comodulate the chances of HCC and mortality in alcoholic cirrhosis.

Their objective was to find out whether G-463A-MPO, Ala16Val-SOD2, or T-262C-CAT (catalase) dimorphisms have an effect on the risks of HCC and mortality in alcoholic cirrhosis. The GG-MPO genotype (causing a high MPO expression) together with at least one Ala-SOD2 allele (correlated to a high iron score in the liver) significantly increased the chances of HCC and mortality in subjects with alcoholic cirrhosis.

A modest intake of alcohol (20-70 g/d) might play a more significant role in hepatic carcinogenesis than is presently thought^[48].

Recently, Persson *et al.*^[49] evidenced how the consumption of three drinks per day is positively associated with both HCC occurrence and liver disease mortality. In this study, folate intake modified the relationship between alcohol and HCC incidence, but had no effect on the relationship between alcohol and liver disease mortality.

Alcohol and cofactors

There is a major correlation between alcohol intake (50 to 80 g/d), hepatitis virus infection (HBV, HCV, and metabolic changes, which has recently been shown by Hassan *et al.*^[50]. They showed a serious rise in risk when alcohol intake is associated with diabetes mellitus and hepatitis viruses. A common pathway for hepatocarcinogenesis has been suggested.

In cases of heavy alcohol intake (> 80 g/d) along with long-term hepatitis virus infection (HBV or HCV), an OR of 53.9 has been found (alcohol alone OR = 2.4, virus alone OR = 19.1); in cases of heavy alcohol intake along with diabetes (both insulin-dependent and non-insulin-dependent) an OR of 9.9 has been found (diabetes alone 2.4)^[50,51].

The risk of HCC incidence is 3.1 times higher in users of alcohol who have a BMI of 30 kg/m² or higher, compared with non-users with a BMI of less than 30 kg/m², which is suggestive of a synergic effect. Obesity significantly augments the risk of HCC incidence in users of alcohol, but not in non-users^[51].

French *et al.*^[52] demonstrated the role of TLR signalling as being the factor behind liver stem cell and pro-

genitor transformation to HCC. This pathway indicates how alcohol raises the chance of HCC in cases of HCV and HBV infection, hemochromatosis, diabetes, and α -1-antitrypsin deficiency. This correlation is caused by triggering a common pathway; TLR signalling leads through NF- κ B activation to the production of pro-inflammatory cytokines and the expression of growth factors *via* the stimulation of the activator protein 1.

HCV NS5A-induced TLR4 is triggered by endotoxemia correlated with alcohol consumption, causing further TLR4 signalling, which in turn up-regulates the stem cell marker Nanog necessary for TLR4-dependent liver oncogenesis. This discovery on the NS5A-TLR4-Nanog axis in synergistic oncogenesis is starting to give new insights into molecular mechanisms for HCC in alcoholic HCV patients. Experimental studies performed on rats, identified that Nanog is up-regulated by TLR4 activation and by the CD133/Nanog-positive cells being present in hepatic tumors. The TLR4-dependent mechanism leads to liver disease through HCV and alcohol, and is partially dependent on Nanog, a TLR4 downstream gene^[53].

It is well known that, in cases of non-alcoholic hepatic disease, HCC development might be favoured by moderate alcohol consumption.

SURVEILLANCE AND DIAGNOSIS

A causal link between alcohol consumption and HCC has been confirmed.

In a multivariate analysis, four variables have been found to be independent predictors of HCC: being 55 years of age and over, the co-presence of anti-HCV positivity, prothrombin activity of 75% or less, and a platelet count of $< 75 \times 10^3/\text{mL}$ ^[54,55].

Surveillance leading to early discovery is the only way of diagnosing HCC when curative treatments are possible^[56].

High-risk HCC groups for whom surveillance is recommended include: cirrhotic patients from any cause, non-cirrhotic patients with chronic HBV infection, and those with a perinatal acquisition of the infection, or with an end-stage liver disease.

Moreover, a meta-analysis indicates that the risk of hepatic cancer actually decreases after giving up alcohol by 6% to 7% a year. An estimated period of 23 years is necessary after giving up drinking, as is a correspondingly high 95% confidence period of 14 to 70 years in order that the risk of hepatic cancer becomes the same as that of teetotallers^[57].

Therefore, surveillance for HCC should also be imperative in former drinkers and, in our opinion, independently of the presence of compensated cirrhosis^[58,59].

Ultrasonography (US) is recommended as the primary surveillance exam for HCC.

One operator-dependent technique is US; an appropriate professional training program to carry out US is

strictly necessary.

The ITALICA Group affirmed that semi-annual surveillance increases the detection rate of very early HCC, and reduces the number of advanced tumors as compared to an annual program.

The detection of serum levels of α -fetoprotein is not adequate for surveillance^[60,61].

The identification of nodules of under 2 cm is considered the ideal goal of surveillance due to their excellent prognosis after radical treatments^[61-64].

Ultrasound-guided biopsies may be particularly valuable for the diagnosis of small nodules in cirrhosis; nevertheless, they may be not completely reliable as sampling errors are possible. Differential diagnosis between early HCC and dysplastic nodules is difficult, including biopsy material.

Immunohistochemical staining for heat-shock protein-70, glypican-3, and glutamine synthetase could well establish a diagnosis when non-conclusive results return from conventional staining^[65]. 30% of HCC may have non-diagnostic biopsies.

US has to be repeated at 3-mo intervals if a nodule smaller than 1 cm has been found; in cases of nodules of over 1 cm, the diagnosis should be made by imaging criteria based on contrast enhancement patterns (CT and MR). During the arterial phase intense contrast uptake, and during the venous/delayed phase contrast washout, are both considered specific for HCC.

Contrast-enhanced US (CEUS) is not advisable due to false positive HCC diagnosis in subjects suffering from cholangiocarcinoma^[66,67].

Recently, Friedrich-Rust *et al*^[59,68] confirmed that international guidelines for ultrasounds recommended the performance of CEUS as the most effective method after conventional ultrasounds for the diagnostic work-up of focal liver lesion.

The results emerging from meta-analysis back up the proposals of the European Federation of Societies for Ultrasound in Medicine and Biology to utilise CEUS as the first method of choice.

In the diagnosis of HCC, no statistically significant difference was found between CT/MRI and CEUS, while CEUS sensitivity was found to be much higher.

Jang *et al*^[69] confirmed that CEUS can be routinely utilised for focal lesions found unexpectedly by a conventional US, and to make obscure lesions detected on an MRI or CT clearer.

In relation to the chance that CEUS gives false-positive HCC diagnoses in subjects suffering from cholangiocarcinoma, the authors affirm that hypervascular cholangiocarcinoma can present an enhancement pattern much the same as that of HCC during the arterial phase. Although this more often presents as early washout^[69-71] in CEUS, and the median time of the beginning of washout is recognized as being 2 min in HCC. CEUS is found in a few European and Asian guidelines, but has not re-

ceived approval from the FDA in the United States^[69,72-74].

VERY EARLY AND EARLY HCC: STADIATION AND TRADITIONAL TREATMENT

The Barcelona Clinic Liver Cancer criteria (BCLC) are well known by hepatologists^[75].

We have mainly focused on Very Early Stage and Early Stage HCC. Usually, PST is 0-1.

Very early stage HCC (VES) consists of the existence of a single nodule smaller than 2 cm in a patient with Child-Pugh A disease.

Early stage (ES) is the presence of a single nodule of under 5 cm, or up to 3 nodules of under 3 cm.

Hepatic resection (HR) is the most effective treatment for VES HCC; in cases of normal portal pressure and normal values of bilirubin. An excellent functional hepatic reserve with no signs of portal hypertension is essential to guarantee good outcomes and avoid life-threatening postsurgical complications^[76].

Liver transplantation appears to be the best choice in cases of VES and ES HCC with portal hypertension. If comorbidities exist, percutaneous ethanol injections and radiofrequency (RF) are the ideal treatments^[77].

ABLATION TREATMENT: THE EVOLUTION

HR is viewed as the most effective treatment for patients who are not eligible for LT.

This point of view is not founded on RCTs *vs* other possible treatment options, but on the medical assumption that HR is the most appropriate treatment to obtain total tumor ablation, along with a surrounding layer of tissue.

This point of view was formed in spite of some non-RCTs comparing HR and ablation that did not produce more favourable results in favour of HR.

HR certainly allows histological evaluations; the presence of microvascular invasion and microsatellite nodules must be taken into account to establish a prognosis. It is a well-known fact that the presence of these histological findings is possible, even in cases of nodules of < 2 cm.

A few authors have proposed that the discovery of risk factors of recurrence, for example microsatellite nodules after resection or microvascular invasion ought to be considered an indication for LT ("ab initio" LT)^[77-79].

Kojiro *et al.*^[80] made a distinction between indistinctly and distinctly nodular HCC.

Nevertheless, microinvasion is improbable in cases of nodules of < 1.5 cm, and in cases of nodules of between 1.5 cm and 2 cm, microinvasion is found in about 10% of cases on the basis of the experimental data^[81-84].

Nodules of between 1 cm and 1.5 cm show typical features; they are indistinctly nodular, well-differentiated, with a rate of microinvasion of about 2%, without satel-

litis, and with a hypovascular pattern.

HCCs of between 1.5 and 2 cm are usually moderately/well-differentiated, with a distinctly nodular structure, a rate of microinvasion of between 10% and 22%, with satellitosis in about 10% of cases, and with a hypovascular pattern.

With an increasing diameter, the rate of microinvasion increases proportionally (30%-60% in nodules 2-5 cm in size, and up to 60%-80% in those 5 cm in size)^[81].

Despite the possibility of detecting microvascular invasion with HR, several studies and some RCTs revealed that the rates of OS and DFS in subjects with VES HCC are much the same after ablation and HR^[63,85,86].

These data have indicated the need to revise the Barcelona Criteria, with specific regard to VES HCC treatment; the OS rate is similar between resection and ablation (5-year survival rate, resection 64%-91%, ablation 67%-86%)^[76,87-90].

Most authors consider ablation as the treatment of choice for patients with single HCC nodules measuring 2 cm or less, even when no contraindications for resective surgery exist, and obviously when the anatomical position of the nodule allows access without exposing patients to life-threatening complications.

The 5-year survival rate for both surgical resection and ablation varies in relation to the presence of portal hypertension; the survival rate is > 70% in patients without portal hypertension, which reduces to 50%-60% in cases of portal hypertension (> 10 mmHg), and in cases of decompensated cirrhosis the survival rate is lower than 50%.

Tremosini *et al.*^[91] affirmed that the outcome offered by resection or liver transplantation may be similar to that offered by ablation if all tumours could be effectively ablated. Indeed, in a solitary HCC of < 2 cm, ablation should be considered as the first choice over transplant because the risk of recurrence would not make the latter feasible. Then resection would be considered if ablation should fail.

As time has passed, most authors have confirmed this concept^[91], gradually abandoning the concern with microinvasion.

Recently, however, microinvasion has been associated with a poor prognosis, even in those patients who underwent "ab initio" LT, compared to those who had resection (or other treatments)^[92]. HCV infected patients, as well as those with ALD, had the same poor prognosis in cases of microinvasion.

Barreto *et al.*^[92] confirmed that Sumie *et al.*^[93] had earlier recognized the impact of vascular invasion and had suggested the use of the Gross classification as a basis for predicting patients who were at an increased risk for having microscopic vascular invasion.

The Markow model analysis demonstrated that ablation leads to lower rates of complication, almost no peri-operative death, lower non-neoplastic tissue ablation, and becomes less expensive by decreasing treatment times, stays in hospital, materials utilised, and the requirement

for blood transfusions^[94].

Therefore, ablation can be viewed as the most effective option for patients with VES HCC, who are not eligible for LT^[87].

Lencioni and Crocetti^[87] described long-term outcomes of HCC patients treated with RF ablation; the published results show that in subjects with ES HCC and Child-Pugh class A disease, 5-year survival periods reach 51% to 64%, and can be as high as 76% in patients who meet the BCLC surgical resection criteria.

One unanswered question is if RF ablation can challenge surgical resection as the first treatment of choice in cases of early HCC (a solitary nodule of under 5 cm); there are no definitive conclusions.

Some trials affirm that in cases of a solitary nodule of between 2 cm and 3 cm, there is no significant difference in the OS between SR and RFA. In cases of a solitary nodule of > 3 cm, the OS is significantly longer in the resection group. In patients with a solitary HCC of between 3 and 5 cm in size, the RF-TACE combination could be considered. Moreover, local tumour progression rates seem to be significantly less in the RF and TACE ablation-treated group than in the RF ablation-only group (6% *vs* 39%, *P* = 0.012)^[95].

Surveillance after ablation can be organized as follows (even if there are not enough data to define an optimal surveillance protocol after treatment): a multiphase, cross-sectional image analysis 1 mo after the treatment, then at 3-mo intervals for at least 2 years, and at 6 to 12-mo intervals thereafter.

The risk of HCC decreases after cessation of alcohol by 6% to 10% a year; after several years the risk becomes equal to that of the general population^[96].

Many authors have considered the issue of chemoprevention. Prevention strategies, in cases of viral aetiology, have been evaluated over the years (up to the proposal of a maintenance interferon therapy). On the other hand, in cases of alcohol-related diseases or NASH, the issue is still under debate^[87]. Further research on chemoprotective agents is ongoing (*i.e.*, silybin, SAME and curcumin, alone or in association).

Chemoprevention should obviously be associated with nutritional therapy and physical activity (healthy diet and lifestyle) appropriate to the patients' clinical conditions.

We can conclude, as suggested by Le *et al.*^[97], that: "ablation may be appropriate in selected considering both medical and surgical criteria. Ablation offers a safe and efficacious alternative with improved long-term survival and the choice between resection and ablation for patients with HCC should be weighed carefully in the context of a multidisciplinary cancer team" (hepatologist, surgeon, oncologist and so on).

REFERENCES

- 1 Lok AS, Everhart JE, Wright EC, Di Bisceglie AM, Kim HY, Sterling RK, Everson GT, Lindsay KL, Lee WM, Bonkovsky HL, Dienstag JL, Ghany MG, Morishima C, Morgan TR. Maintenance peginterferon therapy and other factors associated with hepatocellular carcinoma in patients with advanced hepatitis C. *Gastroenterology* 2011; **140**: 840-849; quiz e12 [PMID: 21129375 DOI: 10.1053/j.gastro.2010.11.050]
- 2 Sanyal AJ, Yoon SK, Lencioni R. The etiology of hepatocellular carcinoma and consequences for treatment. *Oncologist* 2010; **15** Suppl 4: 14-22 [PMID: 21115577 DOI: 10.1634/theoncologist.2010-S4-14]
- 3 Sheron N, Hawkey C, Gilmore I. Projections of alcohol deaths—a wake-up call. *Lancet* 2011; **377**: 1297-1299 [PMID: 21334738 DOI: 10.1016/S0140-6736(11)]
- 4 Schütze M, Boeing H, Pischon T, Rehm J, Kehoe T, Gmel G, Olsen A, Tjønneland AM, Dahm CC, Overvad K, Clavel-Chapelon F, Boutron-Ruault MC, Trichopoulos A, Benetou V, Zylis D, Kaaks R, Rohrmann S, Palli D, Berrino F, Tumino R, Vineis P, Rodríguez L, Agudo A, Sánchez MJ, Dorronsoro M, Chirlaque MD, Barricarte A, Peeters PH, van Gils CH, Khaw KT, Wareham N, Allen NE, Key TJ, Boffetta P, Slimani N, Jenab M, Romaguera D, Wark PA, Riboli E, Bergmann MM. Alcohol attributable burden of incidence of cancer in eight European countries based on results from prospective cohort study. *BMJ* 2011; **342**: d1584 [PMID: 21474525 DOI: 10.1136/bmj.d1584]
- 5 Welzel TM, Graubard BI, Quraishi S, Zeuzem S, Davila JA, El-Serag HB, McGlynn KA. Population-attributable fractions of risk factors for hepatocellular carcinoma in the United States. *Am J Gastroenterol* 2013; **108**: 1314-1321 [PMID: 23752878 DOI: 10.1038/ajg.2013.160]
- 6 Mancebo A, González-Diéguez ML, Cadahía V, Varela M, Pérez R, Navascués CA, Sotorriés NG, Martínez M, Rodrigo L, Rodríguez M. Annual incidence of hepatocellular carcinoma among patients with alcoholic cirrhosis and identification of risk groups. *Clin Gastroenterol Hepatol* 2013; **11**: 95-101 [PMID: 22982095 DOI: 10.1016/j.cgh.2012.09.007]
- 7 Crawford JM. Histologic findings in alcoholic liver disease. *Clin Liver Dis* 2012; **16**: 699-716 [PMID: 23101978 DOI: 10.1016/j.cld.2012.08.004]
- 8 Testino G. Alcoholic hepatitis. *J Med Life* 2013; **6**: 161-167 [PMID: 23904876]
- 9 Sherman DIN, Preedy V, Watson RR. Ethanol and the liver. London: Taylor and Francis, 2002
- 10 Stickel F, Hampe J. Genetic determinants of alcoholic liver disease. *Gut* 2012; **61**: 150-159 [PMID: 22110053 DOI: 10.1136/gutjnl-2011-301239]
- 11 O'Shea RS, Dasarthy S, McCullough AJ. Alcoholic liver disease. *Hepatology* 2010; **51**: 307-328 [PMID: 20034030 DOI: 10.1002/hep.23258]
- 12 Bellentani S, Saccoccio G, Costa G, Tiribelli C, Manenti F, Sodde M, Saveria Crocè L, Sasso F, Pozzato G, Cristianini G, Brandi G. Drinking habits as cofactors of risk for alcohol induced liver damage. The Dionysos Study Group. *Gut* 1997; **41**: 845-850 [PMID: 9462221]
- 13 Mathurin P, Lucey MR. Management of alcoholic hepatitis. *J Hepatol* 2012; **56** Suppl 1: S39-S45 [PMID: 22300464 DOI: 10.1016/S0168-8278(12)60005-1]
- 14 Raynard B, Balian A, Fallik D, Capron F, Bedossa P, Chaput JC, Naveau S. Risk factors of fibrosis in alcohol-induced liver disease. *Hepatology* 2002; **35**: 635-638 [PMID: 11870378]
- 15 Safdar K, Schiff ER. Alcohol and hepatitis C. *Semin Liver Dis* 2004; **24**: 305-315 [PMID: 15349807]
- 16 Perlemuter G, Lettéron P, Carnot F, Zavala F, Pessayre D, Nalpas B, Bréchet C. Alcohol and hepatitis C virus core protein additively increase lipid peroxidation and synergistically trigger hepatic cytokine expression in a transgenic mouse model. *J Hepatol* 2003; **39**: 1020-1027 [PMID: 14642621]
- 17 Rehm J, Baliunas D, Borges GL, Graham K, Irving H, Kehoe T, Parry CD, Patra J, Popova S, Poznyak V, Roerecke M, Room R, Samokhvalov AV, Taylor B. The relation between different dimensions of alcohol consumption and burden of disease: an overview. *Addiction* 2010; **105**: 817-843 [PMID: 20331573 DOI: 10.1111/j.1360-0443.2010.02899.x]
- 18 Grosse Y, Baan R, Straif K, Secretan B, El Ghissassi F, Bou-

- vard V, Benbrahim-Tallaa L, Guha N, Galichet L, Coglian V. A review of human carcinogens-Part A: pharmaceuticals. *Lancet Oncol* 2009; **10**: 13-14 [PMID: 19115512]
- 19 **Secretan B**, Straif K, Baan R, Grosse Y, El Ghissassi F, Bouvard V, Benbrahim-Tallaa L, Guha N, Freeman C, Galichet L, Coglian V. A review of human carcinogens--Part E: tobacco, areca nut, alcohol, coal smoke, and salted fish. *Lancet Oncol* 2009; **10**: 1033-1034 [PMID: 19891056]
 - 20 **IARC (WHO)**. A review of human carcinogens. *IARC Monogr Eval Carcinog Risks Hum* 2012; **100**: 377-503
 - 21 **Lachenmeier DW**, Sohnius EM. The role of acetaldehyde outside ethanol metabolism in the carcinogenicity of alcoholic beverages: evidence from a large chemical survey. *Food Chem Toxicol* 2008; **46**: 2903-2911 [PMID: 18577414 DOI: 10.1016/j.fct.2008.05.034]
 - 22 **Seitz HK**, Stickel F, Homann N. Pathogenetic mechanisms of upper aerodigestive tract cancer in alcoholics. *Int J Cancer* 2004; **108**: 483-487 [PMID: 14696110]
 - 23 **Seitz HK**, Stickel F. Molecular mechanisms of alcohol-mediated carcinogenesis. *Nat Rev Cancer* 2007; **7**: 599-612 [PMID: 17646865]
 - 24 **Salaspuro M**. Acetaldehyde: a cumulative carcinogen in humans. *Addiction* 2009; **104**: 551-553 [PMID: 19335653]
 - 25 **Lee CH**, Lee JM, Wu DC, Goan YG, Chou SH, Wu IC, Kao EL, Chan TF, Huang MC, Chen PS, Lee CY, Huang CT, Huang HL, Hu CY, Hung YH, Wu MT. Carcinogenic impact of ADH1B and ALDH2 genes on squamous cell carcinoma risk of the esophagus with regard to the consumption of alcohol, tobacco and betel quid. *Int J Cancer* 2008; **122**: 1347-1356 [PMID: 18033686]
 - 26 **Pöschl G**, Seitz HK. Alcohol and cancer. *Alcohol Alcohol* 2004; **39**: 155-165 [PMID: 15082451]
 - 27 **Seitz HK**, Becker P. Alcohol metabolism and cancer risk. *Alcohol Res Health* 2007; **30**: 38-41, 44-47 [PMID: 17718399]
 - 28 **Salaspuro M**. Acetaldehyde as a common denominator and cumulative carcinogen in digestive tract cancers. *Scand J Gastroenterol* 2009; **44**: 912-925 [PMID: 19396661 DOI: 10.1080/00365520902912563]
 - 29 **Nahon P**, Sutton A, Rufat P, Zioli M, Akouche H, Laguillier C, Charnaux N, Ganne-Carrié N, Grando-Lemaire V, N'Kon Tchou G, Trinchet JC, Gattegno L, Pessayre D, Beaugrand M. Myeloperoxidase and superoxide dismutase 2 polymorphisms modulate the risk of hepatocellular carcinoma and death in alcoholic cirrhosis. *Hepatology* 2009; **50**: 1484-1493 [PMID: 19731237 DOI: 10.1002/hep.23187]
 - 30 **Morgan TR**, Mandayam S, Jamal MM. Alcohol and hepatocellular carcinoma. *Gastroenterology* 2004; **127**: S87-S96 [PMID: 15508108]
 - 31 **Testino G**, Borro P. Alcohol and gastrointestinal oncology. *World J Gastrointest Oncol* 2010; **2**: 322-325 [PMID: 21160893 DOI: 10.4251/wjgo.v2.i8.322]
 - 32 **Testino G**. The burden of cancer attributable to alcohol consumption. *Maedica (Buchar)* 2011; **6**: 313-320 [PMID: 22879847]
 - 33 **Testino G**, Borro P, Ancarani O, Sumberaz A. Human carcinogenesis and alcohol in hepato-gastroenterology. *Eur Rev Med Pharmacol Sci* 2012; **16**: 512-518 [PMID: 22696879]
 - 34 **Donato F**, Tagger A, Gelatti U, Parrinello G, Boffetta P, Albertini A, Decarli A, Trevisi P, Ribero ML, Martelli C, Porru S, Nardi G. Alcohol and hepatocellular carcinoma: the effect of lifetime intake and hepatitis virus infections in men and women. *Am J Epidemiol* 2002; **155**: 323-331 [PMID: 11836196]
 - 35 **Grossi S**, Sumberaz A, Gosmar M, Mattioli F, Testino G, Martelli A. DNA damage in peripheral blood lymphocytes of patients with cirrhosis related to alcohol abuse or to hepatitis B and C viruses. *Eur J Gastroenterol Hepatol* 2008; **20**: 22-25 [PMID: 18090985]
 - 36 **Singh NP**, McCoy MT, Tice RR, Schneider EL. A simple technique for quantitation of low levels of DNA damage in individual cells. *Exp Cell Res* 1988; **175**: 184-191 [PMID: 3345800]
 - 37 **Lambert MP**, Paliwal A, Vaissière T, Chemin I, Zoulim F, Tommasino M, Hainaut P, Sylla B, Scoazec JY, Tost J, Herceg Z. Aberrant DNA methylation distinguishes hepatocellular carcinoma associated with HBV and HCV infection and alcohol intake. *J Hepatol* 2011; **54**: 705-715 [PMID: 21146512 DOI: 10.1016/j.jhep.2010.07.027]
 - 38 **Eiró N**, Altadill A, Juárez LM, Rodríguez M, González LO, Atienza S, Bermúdez S, Fernandez-Garcia B, Fresno-Forcelledo MF, Rodrigo L, Vizoso FJ. Toll-like receptors 3, 4 and 9 in hepatocellular carcinoma: Relationship with clinicopathological characteristics and prognosis. *Hepatol Res* 2014; **44**: 769-778 [PMID: 23742263 DOI: 10.1111/hepr.12180]
 - 39 **Pavanello S**, Hoxha M, Dioni L, Bertazzi PA, Snenghi R, Nalesso A, Ferrara SD, Montisci M, Baccarelli A. Shortened telomeres in individuals with abuse in alcohol consumption. *Int J Cancer* 2011; **129**: 983-992 [PMID: 21351086 DOI: 10.1002/ijc.25999]
 - 40 **Farazi PA**, DePinho RA. Hepatocellular carcinoma pathogenesis: from genes to environment. *Nat Rev Cancer* 2006; **6**: 674-687 [PMID: 16929323]
 - 41 **Hoare M**, Das T, Alexander G. Ageing, telomeres, senescence, and liver injury. *J Hepatol* 2010; **53**: 950-961 [PMID: 20739078 DOI: 10.1016/j.jhep.2010.06.009]
 - 42 **Mato JM**, Lu SC. The hepatocarcinogenic effect of methionine and choline deficient diets: an adaptation to the Warburg effect? *Alcohol Clin Exp Res* 2011; **35**: 811-814 [PMID: 21284672 DOI: 10.1111/j.1530-0277.2010.01404.x]
 - 43 **Roskams T**, Yang SQ, Koteish A, Durnez A, DeVos R, Huang X, Achten R, Verslype C, Diehl AM. Oxidative stress and oval cell accumulation in mice and humans with alcoholic and nonalcoholic fatty liver disease. *Am J Pathol* 2003; **163**: 1301-1311 [PMID: 14507639]
 - 44 **Riehle KJ**, Dan YY, Campbell JS, Fausto N. New concepts in liver regeneration. *J Gastroenterol Hepatol* 2011; **26** Suppl 1: 203-212 [PMID: 21199532 DOI: 10.1111/j.1440-1746.2010.06539.x]
 - 45 **Gu JW**, Bailey AP, Sartin A, Makey I, Brady AL. Ethanol stimulates tumor progression and expression of vascular endothelial growth factor in chick embryos. *Cancer* 2005; **103**: 422-431 [PMID: 15597382]
 - 46 **Zhan P**, Qian Q, Yu LK. Prognostic significance of vascular endothelial growth factor expression in hepatocellular carcinoma tissue: a meta-analysis. *Hepatobiliary Surg Nutr* 2013; **2**: 148-155 [PMID: 24570933 DOI: 10.3978/j.issn.2304-3881.2013.06.06]
 - 47 **Matsushashi T**, Yamada N, Shinzawa H, Takahashi T. Effect of alcohol on tumor growth of hepatocellular carcinoma with type C cirrhosis. *Intern Med* 1996; **35**: 443-448 [PMID: 8835593]
 - 48 **Tokushige K**, Hashimoto E, Horie Y, Taniai M, Higuchi S. Hepatocellular carcinoma in Japanese patients with nonalcoholic fatty liver disease, alcoholic liver disease, and chronic liver disease of unknown etiology: report of the nationwide survey. *J Gastroenterol* 2011; **46**: 1230-1237 [PMID: 21748549 DOI: 10.1007/s00535-011-0431-9]
 - 49 **Persson EC**, Schwartz LM, Park Y, Trabert B, Hollenbeck AR, Graubard BI, Freedman ND, McGlynn KA. Alcohol consumption, folate intake, hepatocellular carcinoma, and liver disease mortality. *Cancer Epidemiol Biomarkers Prev* 2013; **22**: 415-421 [PMID: 23307533 DOI: 10.1158/1055-9965.9965.EPI-12-1169]
 - 50 **Hassan MM**, Hwang LY, Hatten CJ, Swaim M, Li D, Abbruzzese JL, Beasley P, Patt YZ. Risk factors for hepatocellular carcinoma: synergism of alcohol with viral hepatitis and diabetes mellitus. *Hepatology* 2002; **36**: 1206-1213 [PMID: 12395331]
 - 51 **Grewal P**, Viswanathan VA. Liver cancer and alcohol. *Clin Liver Dis* 2012; **16**: 839-850 [PMID: 23101985 DOI: 10.1016/j.cld.2012.08.011]

- 52 **French SW**, Oliva J, French BA, Li J, Bardag-Gorce F. Alcohol, nutrition and liver cancer: role of Toll-like receptor signaling. *World J Gastroenterol* 2010; **16**: 1344-1348 [PMID: 20238401]
- 53 **Machida K**. TLRs, Alcohol, HCV, and Tumorigenesis. *Gastroenterol Res Pract* 2010; **2010**: 518674 [PMID: 21331379 DOI: 10.1155/2010/518674]
- 54 **Della Corte C**, Colombo M. Surveillance for hepatocellular carcinoma. *Semin Oncol* 2012; **39**: 384-398 [PMID: 22846857 DOI: 10.1053/j.seminoncol.2012.05.002]
- 55 **Velázquez RF**, Rodríguez M, Navascués CA, Linares A, Pérez R, Sotorriós NG, Martínez I, Rodrigo L. Prospective analysis of risk factors for hepatocellular carcinoma in patients with liver cirrhosis. *Hepatology* 2003; **37**: 520-527 [PMID: 12601348]
- 56 **de Lope CR**, Tremosini S, Forner A, Reig M, Bruix J. Management of HCC. *J Hepatol* 2012; **56** Suppl 1: S75-S87 [PMID: 22300468 DOI: 10.1016/S0168-8278(12)60009-9]
- 57 **Heckley GA**, Jarl J, Asamoah BO, G-Gerdtham U. How the risk of liver cancer changes after alcohol cessation: a review and meta-analysis of the current literature. *BMC Cancer* 2011; **11**: 446 [PMID: 21995442 DOI: 10.1186/1471-2407-11-446]
- 58 **Testino G**. Alcoholic diseases in hepato-gastroenterology: a point of view. *Hepatogastroenterology* 2008; **55**: 371-377 [PMID: 18613369]
- 59 **Borro P**, Testino G. Contrast-enhanced ultrasound for focal liver lesions. Is it necessary an hepatologist expert in ultrasound techniques in the third millennium? *Liver Int* 2013; **33**: 1609-1610 [PMID: 23998437 DOI: 10.1111/liv]
 - 60 **Santi V**, Trevisani F, Gramenzi A, Grignaschi A, Mirici-Cappa F, Del Poggio P, Di Nolfo MA, Benvegnù L, Farinati F, Zoli M, Giannini EG, Borzio F, Caturelli E, Chiaramonte M, Bernardi M. Semiannual surveillance is superior to annual surveillance for the detection of early hepatocellular carcinoma and patient survival. *J Hepatol* 2010; **53**: 291-297 [PMID: 20483497 DOI: 10.1016/j.jhep.2010.03.010]
 - 61 **Borro P**, Testino G. Surveillance for hepatocellular carcinoma in alcoholic patients. *Am J Gastroenterol* 2013; **108**: 1811 [PMID: 24192961 DOI: 10.1038/ajg.2013.296]
 - 62 **Ikai I**, Arii S, Kojiro M, Ichida T, Makuuchi M, Matsuyama Y, Nakanuma Y, Okita K, Omata M, Takayasu K, Yamaoka Y. Reevaluation of prognostic factors for survival after liver resection in patients with hepatocellular carcinoma in a Japanese nationwide survey. *Cancer* 2004; **101**: 796-802 [PMID: 15305412]
 - 63 **Huang GT**, Lee PH, Tsang YM, Lai MY, Yang PM, Hu RH, Chen PJ, Kao JH, Sheu JC, Lee CZ, Chen DS. Percutaneous ethanol injection versus surgical resection for the treatment of small hepatocellular carcinoma: a prospective study. *Ann Surg* 2005; **242**: 36-42 [PMID: 15973099]
 - 64 **Lin SM**, Lin CJ, Lin CC, Hsu CW, Chen YC. Randomised controlled trial comparing percutaneous radiofrequency thermal ablation, percutaneous ethanol injection, and percutaneous acetic acid injection to treat hepatocellular carcinoma of 3 cm or less. *Gut* 2005; **54**: 1151-1156 [PMID: 16009687]
 - 65 **Di Tommaso L**, Destro A, Seok JY, Balladore E, Terracciano L, Sangiovanni A, Iavarone M, Colombo M, Jang JJ, Yu E, Jin SY, Morengi E, Park YN, Roncalli M. The application of markers (HSP70 GPC3 and GS) in liver biopsies is useful for detection of hepatocellular carcinoma. *J Hepatol* 2009; **50**: 746-754 [PMID: 19231003 DOI: 10.1016/j.jhep.2008.11.014]
 - 66 **Vilana R**, Forner A, Bianchi L, García-Criado A, Rimola J, de Lope CR, Reig M, Ayuso C, Brú C, Bruix J. Intrahepatic peripheral cholangiocarcinoma in cirrhosis patients may display a vascular pattern similar to hepatocellular carcinoma on contrast-enhanced ultrasound. *Hepatology* 2010; **51**: 2020-2029 [PMID: 20512990 DOI: 10.1002/hep.23600]
 - 67 **Bruix J**, Sherman M. Management of hepatocellular carcinoma: an update. *Hepatology* 2011; **53**: 1020-1022 [PMID: 21374666 DOI: 10.1002/hep.24199]
 - 68 **Friedrich-Rust M**, Klopffleisch T, Nierhoff J, Herrmann E, Vermehren J, Schneider MD, Zeuzem S, Bojunga J. Contrast-Enhanced Ultrasound for the differentiation of benign and malignant focal liver lesions: a meta-analysis. *Liver Int* 2013; **33**: 739-755 [PMID: 23432804 DOI: 10.1111/liv.12115]
 - 69 **Jang JY**, Kim MY, Jeong SW, Kim TY, Kim SU, Lee SH, Suk KT, Park SY, Woo HY, Kim SG, Heo J, Baik SK, Kim HS, Tak WY. Current consensus and guidelines of contrast enhanced ultrasound for the characterization of focal liver lesions. *Clin Mol Hepatol* 2013; **19**: 1-16 [PMID: 23593604 DOI: 10.3350/cmh.2013.19.1.1]
 - 70 **Barreiros AP**, Piscaglia F, Dietrich CF. Contrast enhanced ultrasound for the diagnosis of hepatocellular carcinoma (HCC): comments on AASLD guidelines. *J Hepatol* 2012; **57**: 930-932 [PMID: 22739095 DOI: 10.1016/j.jep.2012.04.018]
 - 71 **Boozari B**, Soudah B, Rifai K, Schneidewind S, Vogel A, Hecker H, Hahn A, Schlue J, Dietrich CF, Bahr MJ, Kubicka S, Manns MP, Gebel M. Grading of hypervascular hepatocellular carcinoma using late phase of contrast enhanced sonography - a prospective study. *Dig Liver Dis* 2011; **43**: 484-490 [PMID: 21377941 DOI: 10.1016/j.dld.2011.01.001]
 - 72 **Trillaud H**, Bruel JM, Valette PJ, Vilgrain V, Schmutz G, Oyen R, Jakubowski W, Danes J, Valek V, Greis C. Characterization of focal liver lesions with SonoVue-enhanced sonography: international multicenter-study in comparison to CT and MRI. *World J Gastroenterol* 2009; **15**: 3748-3756 [PMID: 19673015]
 - 73 **Strobel D**, Seitz K, Blank W, Schuler A, Dietrich C, von Herbay A, Friedrich-Rust M, Kunze G, Becker D, Will U, Kratzer W, Albert FW, Pachmann C, Dirks K, Strunk H, Greis C, Bernatik T. Contrast-enhanced ultrasound for the characterization of focal liver lesions--diagnostic accuracy in clinical practice (DEGUM multicenter trial). *Ultraschall Med* 2008; **29**: 499-505 [PMID: 19241506 DOI: 10.1055/s-2008-1027806]
 - 74 **Dietrich CF**, Ignee A, Trojan J, Fellbaum C, Schuessler G. Improved characterisation of histologically proven liver tumours by contrast enhanced ultrasonography during the portal venous and specific late phase of SHU 508A. *Gut* 2004; **53**: 401-405 [PMID: 14960524]
 - 75 **Bruix J**, Sherman M, Llovet JM, Beaugrand M, Lencioni R, Burroughs AK, Christensen E, Pagliaro L, Colombo M, Rodés J. Clinical management of hepatocellular carcinoma. Conclusions of the Barcelona-2000 EASL conference. European Association for the Study of the Liver. *J Hepatol* 2001; **35**: 421-430 [PMID: 11592607]
 - 76 **Genco C**, Cabibbo G, Maida M, Brancatelli G, Galia M, Alessi N, Butera G, Genova C, Romano P, Raineri M, Giaratano A, Midiri M, Cammà C. Treatment of hepatocellular carcinoma: present and future. *Expert Rev Anticancer Ther* 2013; **13**: 469-479 [PMID: 23560841 DOI: 10.1586/era.13.21]
 - 77 **Colombo M**, Raoul JL, Lencioni R, Galle PR, Zucman-Rossi J, Bañares R, Seehofer D, Neuhaus P, Johnson P. Multi-disciplinary strategies to improve treatment outcomes in hepatocellular carcinoma: a European perspective. *Eur J Gastroenterol Hepatol* 2013; **25**: 639-651 [PMID: 23628963 DOI: 10.1097/MEG.0b013e32835e33bb]
 - 78 **Sala M**, Fuster J, Llovet JM, Navasa M, Solé M, Varela M, Pons F, Rimola A, García-Valdecasas JC, Brú C, Bruix J. High pathological risk of recurrence after surgical resection for hepatocellular carcinoma: an indication for salvage liver transplantation. *Liver Transpl* 2004; **10**: 1294-1300 [PMID: 15376311]
 - 79 **Fuks D**, Dokmak S, Paradis V, Diouf M, Durand F, Belghiti J. Benefit of initial resection of hepatocellular carcinoma followed by transplantation in case of recurrence: an intention-to-treat analysis. *Hepatology* 2012; **55**: 132-140 [PMID: 21932387 DOI: 10.1002/hep.24680]
 - 80 **Kojiro M**. Histopathology of liver cancers. *Best Pract Res Clin Gastroenterol* 2005; **19**: 39-62 [PMID: 15757804]

- 81 **Livraghi T**, Brambilla G, Carnaghi C, Tommasini MA, Torzilli G. Is it time to reconsider the BCLC/AASLD therapeutic flow-chart? *J Surg Oncol* 2010; **102**: 868-876 [PMID: 20886553 DOI: 10.1002/jso.21733]
- 82 **Maeda T**, Takenaka K, Taguchi K, Kajiyama K, Shirabe K, Shimada M, Honda H, Sugimachi K. Small hepatocellular carcinoma with minute satellite nodules. *Hepatogastroenterology* 2000; **47**: 1063-1066 [PMID: 11020880]
- 83 **Sasaki Y**, Imaoka S, Ishiguro S, Nakano H, Kasugai H, Fujita M, Inoue E, Ishikawa O, Furukawa H, Nakamori S, Kuroda C, Iwanaga T. Clinical features of small hepatocellular carcinomas as assessed by histologic grades. *Surgery* 1996; **119**: 252-260 [PMID: 8619179]
- 84 **Kanai T**, Hirohashi S, Upton MP, Noguchi M, Kishi K, Makuuchi M, Yamasaki S, Hasegawa H, Takayasu K, Moriyama N. Pathology of small hepatocellular carcinoma. A proposal for a new gross classification. *Cancer* 1987; **60**: 810-819 [PMID: 2439190]
- 85 **Chen MS**, Li JQ, Zheng Y, Guo RP, Liang HH, Zhang YQ, Lin XJ, Lau WY. A prospective randomized trial comparing percutaneous local ablative therapy and partial hepatectomy for small hepatocellular carcinoma. *Ann Surg* 2006; **243**: 321-328 [PMID: 16495695]
- 86 **Lü MD**, Kuang M, Liang LJ, Xie XY, Peng BG, Liu GJ, Li DM, Lai JM, Li SQ. [Surgical resection versus percutaneous thermal ablation for early-stage hepatocellular carcinoma: a randomized clinical trial]. *Zhonghua Yixue Zazhi* 2006; **86**: 801-805 [PMID: 16681964]
- 87 **Lencioni R**, Crocetti L. Local-regional treatment of hepatocellular carcinoma. *Radiology* 2012; **262**: 43-58 [PMID: 22190656 DOI: 10.1148/radiol.11110144]
- 88 **Forner A**, Llovet JM, Bruix J. Hepatocellular carcinoma. *Lancet* 2012; **379**: 1245-1255 [PMID: 22353262 DOI: 10.1016/S0140-6736(11)61347-0]
- 89 **Groeschl RT**, Gamblin TC, Turaga KK. Ablation for hepatocellular carcinoma: validating the 3-cm breakpoint. *Ann Surg Oncol* 2013; **20**: 3591-3595 [PMID: 23720072 DOI: 10.1245/s10434-013-3031-5]
- 90 **Cucchetti A**, Piscaglia F, Cescon M, Ercolani G, Pinna AD. Systematic review of surgical resection vs radiofrequency ablation for hepatocellular carcinoma. *World J Gastroenterol* 2013; **19**: 4106-4118 [PMID: 23864773 DOI: 10.3748/wjg.v19.i26.4106]
- 91 **Tremosini S**, Reig M, de Lope CR, Forner A, Bruix J. Treatment of early hepatocellular carcinoma: Towards personalized therapy. *Dig Liver Dis* 2010; **42** Suppl 3: S242-S248 [PMID: 20547310 DOI: 10.1016/S1590-8658(10)60512-9]
- 92 **Barreto SG**, Brooke-Smith M, Dolan P, Wilson TG, Padbury RT, Chen JW. Cirrhosis and microvascular invasion predict outcomes in hepatocellular carcinoma. *ANZ J Surg* 2013; **83**: 331-335 [PMID: 22943449 DOI: 10.1111/j.1445-2197.2012.06196.x]
- 93 **Sumie S**, Kuromatsu R, Okuda K, Ando E, Takata A, Fukushima N, Watanabe Y, Kojiro M, Sata M. Microvascular invasion in patients with hepatocellular carcinoma and its predictable clinicopathological factors. *Ann Surg Oncol* 2008; **15**: 1375-1382 [PMID: 18324443 DOI: 10.1245/s10434-008-9846-9]
- 94 **Cho YK**, Kim JK, Kim WT, Chung JW. Hepatic resection versus radiofrequency ablation for very early stage hepatocellular carcinoma: a Markov model analysis. *Hepatology* 2010; **51**: 1284-1290 [PMID: 20099299 DOI: 10.1002/hep.23466]
- 95 **Veltri A**, Moretto P, Doriguzzi A, Pagano E, Carrara G, Gandini G. Radiofrequency thermal ablation (RFA) after transarterial chemoembolization (TACE) as a combined therapy for unresectable non-early hepatocellular carcinoma (HCC). *Eur Radiol* 2006; **16**: 661-669 [PMID: 16228211]
- 96 **Testino G**, Borro P. Chemoprevention of hepatocellular carcinoma in patients with hepatitis C virus related cirrhosis. *World J Hepatol* 2013; **5**: 521-527 [PMID: 24179611 DOI: 10.4254/wjh.v5.i10.521]
- 97 **Le M**, Nelson R, Lee W, Wiatrek R, Singh G, Garcia-Aguilar J, Kim J. An appraisal of radiofrequency ablation and surgical resection for hepatocellular carcinoma: results from the surveillance, epidemiology, and end results registry. *Am Surg* 2012; **78**: 1091-1095 [PMID: 23025948]

P- Reviewer: Zhang JY S- Editor: Ma YJ L- Editor: A
E- Editor: Zhang DN





Published by **Baishideng Publishing Group Inc**

8226 Regency Drive, Pleasanton, CA 94588, USA

Telephone: +1-925-223-8242

Fax: +1-925-223-8243

E-mail: bpgoffice@wjgnet.com

Help Desk: <http://www.wjgnet.com/esps/helpdesk.aspx>

<http://www.wjgnet.com>



ISSN 1007-9327

