

[全部](#)[图片](#)[新闻](#)[购物](#)[地图](#)[更多](#)[设置](#)[工具](#)

找到约 4,660 条结果 (用时 0.46 秒)

您是不是要找：[Huge primary *dedifferentiated* pancreatic liposarcoma mimics carcinosarcoma in a young female: A case report with literature review](#)

[Case report of giant retroperitoneal liposarcoma in a young woman ...](#)

<https://www.ijsurgery.com/index.php/isj/article/view/3135> ▼ [翻译此页](#)

作者：FM Moreno - 2018

[Case report of giant retroperitoneal liposarcoma in a young woman. ... Giant retroperitoneal liposarcoma: Case report and review of the literature. ... A retrospective, single-center cohort study on 65 patients with primary retroperitoneal liposarcoma. ... for huge retroperitoneal liposarcoma involving the pancreas, right kidney, ...](#)

缺少字词：[dedifferentiated mimics carcinosarcoma](#)

[Carcinosarcoma of the Pancreas: Case Report With Comprehensive ...](#)

<https://www.ncbi.nlm.nih.gov/pubmed/28902796> - [翻译此页](#)

作者：DA Ruess - 2017 - [相关文章](#)

[Carcinosarcoma of the Pancreas: Case Report With Comprehensive Literature Review.](#) Ruess DA(1), Kayser C, Neubauer J, Fichtner-Feigl S, Hopt UT, Wittel ...

缺少字词：[huge primary dedifferentiated liposarcoma mimics young](#)

[Carcinosarcoma of the pancreas: a case report and review of the ...](#)

<https://www.ncbi.nlm.nih.gov/pubmed/12204065> ▼ [翻译此页](#)

作者：F Darvishian - 2002 - 被引用次数：48 - [相关文章](#)

[Carcinosarcoma of the pancreas: a case report and review of the literature. ... and the other component was high-grade sarcoma with features of malignant fibrous ... this carcinosarcoma is the seventh reported case of a primary pancreatic ...](#)

缺少字词：[huge dedifferentiated mimics young female](#)

[Liposarcoma disease: Malacards - Research Articles, Drugs, Genes ...](#)

<https://www.malacards.org/card/liposarcoma?showAll=True>

Most patients with liposarcoma have no symptoms until the tumor is large 163, pancreatitis, 9.9 [Dedifferentiated liposarcoma of the oral floor: A case study and literature](#) Retroperitoneal liposarcoma with different mimics: 2 case reports Primary Diaphragmatic Dedifferentiated Liposarcoma in a Young Female ...

Name of Journal: *World Journal of Clinical Cases*

Manuscript NO: 45069

Manuscript Type: CASE REPORT

**Huge primary dedifferentiated pancreatic liposarcoma mimicking
carcinosarcoma in a young female: A case report**

Liu Z *et al.* Huge primary dedifferentiated pancreatic liposarcoma

Zhe Liu, Wu-Feng Fan, Gui-Chen Li, Jin Long, Yuan-Hong Xu, Gang Ma

Match Overview

1	Crossref 16 words Lee, Jen-Chieh, Yung-Ming Jeng, Jau-Yu Liao, Jia-Huei Tsa i, Hung-Han Hsu, and Ching-Yao Yang. "Alternative lengthe	1%
2	Internet 13 words crawled on 06-Jul-2018 www.tandfonline.com	1%
3	Internet 13 words crawled on 20-Sep-2014 efiloop.com	1%



All

Images

Videos

翻译成中文

关闭取词

25,400 Results

Any time ▾

Massive retroperitoneal dedifferentiated liposarcoma in a ...

<https://academic.oup.com/jscr/article/2018/10/rjy272/5123437> ▾

However, due to the lack of sufficient access to healthcare, she did not seek any medical attention. After complete removal of the mass the patient underwent complete recovery, **dedifferentiated liposarcoma** (DDL) was the final diagnosis. **CASE REPORT.** Patient is a 34-year-old **female** ...

Author: Fernando X Moyon, Miguel A Moyon, ... **Publish Year:** 2018

A case of huge primary liposarcoma in the liver | Request PDF

https://www.researchgate.net/publication/7243421_A_case_of_huge...

A 61-year-old **female** patient who suffered from a **huge primary liposarcoma** in the central portion of the liver had the clinical presentations of fever, nausea, vomiting, jaundice, and body weight loss.

Pancreatic liposarcoma. Case report with review of ...

https://www.researchgate.net/publication/15828028_Pancreatic...

Case report with review of retroperitoneal liposarcomas | **A case report** of a large **pancreatic liposarcoma** is presented showing a five-year survival with aggressive surgical excision as the only ...

[PDF] A Huge Myxoid Liposarcoma in the Liver - Rare Tumor: A ...

www.remedypublications.com/remedy-open-access/pdfs_folder/roa-v3...

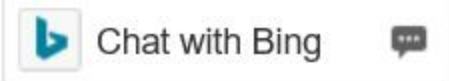
Case Report. Published: 22 Mar, 2018. Introduction. Sarcomas are rare malignant tumors arising from mesenchymal cells. Sarcoma in the liver represent 0.1% to 2% of **primary** hepatic cancer [1,2]. We present a **case** of hepatic **liposarcoma** in a . previously healthy 59 year-old man, admitted to our hospital due to a palpable mass in the abdomen.

Dedifferentiated liposarcoma composed predominantly of ...

<https://www.sciencedirect.com/science/article/pii/S0046817717304963>

Summary. Tumors originated in the retroperitoneum ($n = 5$; 3 in the psoas muscle) and deep soft tissue of the thigh ($n = 1$). All 3 patients with follow-up died of metastatic disease within 4 to 8 months. Preoperative biopsy diagnoses never suggested dedifferentiated liposarcoma as ...

Author: Abbas Agaimy, Michael Michal, Ladisl... **Publish Year:** 2018

[国内版](#)[国际版](#)

Huge primary dedifferentiated pancreatic liposarcoma mimicking carcinosarcoma

[All](#)[Images](#)[Videos](#)[翻译成中文](#)[开启取词](#)

27,000 Results

Any time ▾

Massive retroperitoneal dedifferentiated liposarcoma in a ...

<https://academic.oup.com/jscr/article/2018/10/rjy272/5123437> ▾

However, due to the lack of sufficient access to healthcare, she did not seek any medical attention. After complete removal of the mass the patient underwent complete recovery, **dedifferentiated liposarcoma** (DDL) was the final diagnosis. **CASE REPORT.** Patient is a 34-year-old **female** ...

Author: Fernando X Moyon, Miguel A Moyon, ... **Publish Year:** 2018

A case of huge primary liposarcoma in the liver | Request PDF

https://www.researchgate.net/publication/7243421_A_case_of_huge...

A 61-year-old **female** patient who suffered from a **huge primary liposarcoma** in the central portion of the liver had the clinical presentations of fever, nausea, vomiting, jaundice, and body weight loss.

[PDF] A Huge Myxoid Liposarcoma in the Liver - Rare Tumor: A ...

www.remedypublications.com/remedy-open-access/pdfs_folder/roa-v3...

Case Report. Published: 22 Mar, 2018. Introduction. Sarcomas are rare malignant tumors arising from mesenchymal cells. Sarcoma in the liver represent 0.1% to 2% of **primary** hepatic cancer [1,2]. We present **a case** of hepatic **liposarcoma** in a . previously healthy 59 year-old man, admitted to our hospital due to a palpable mass in the abdomen.

(PDF) A case of huge retroperitoneal liposarcoma in pregnancy

https://www.researchgate.net/publication/262781693_A_case_of_huge...

Introduction: We **report a case** of a **huge well-differentiated liposarcoma** with **dedifferentiated areas contributing** to the patient's unfavorable outcome.

Primary Liposarcoma of the Duodenum: A First Case ...

<https://mafiadoc.com/primary-liposarcoma-of-the-duodenum-a-first...> ▾

Case Report Primary Orbital **Liposarcoma** ... **Liposarcoma** is a malignant tumor of adipose tissue and considered to be the most common soft tissue sarcoma in adults.1 **Liposarcoma** of the orbit is rare with