

# World Journal of *Gastrointestinal Surgery*

*World J Gastrointest Surg* 2024 April 27; 16(4): 974-1217



## EDITORIAL

- 974 How to identify early complications in patients undergoing distal gastrectomy?  
*Tropeano G, Chiarello MM, Fico V, Brisinda G*
- 982 Quality assessment of surgery for colorectal cancer: Where do we stand?  
*Morarasu S, Livadaru C, Dimofte GM*
- 988 Emerging molecules, tools, technology, and future of surgical knife in gastroenterology  
*Kumar A, Goyal A*
- 999 Carcinoembryonic antigen in the diagnosis, treatment, and follow-up of focal liver lesions  
*Dilek ON, Arslan Kahraman Dİ, Kahraman G*
- 1008 Relationship between *Helicobacter pylori* infection and colorectal polyp/colorectal cancer  
*Liu Y, Yang DQ, Jiang JN, Jiao Y*

## MINIREVIEWS

- 1017 Near-infrared cholangiography with intragallbladder indocyanine green injection in minimally invasive cholecystectomy  
*Symeonidis S, Mantzoros I, Anestiadou E, Ioannidis O, Christidis P, Bitsianis S, Bisbinas V, Zapsalis K, Karastergiou T, Athanasiou D, Apostolidis S, Angelopoulos S*
- 1030 Blastomas of the digestive system in adults: A review  
*Liu Y, El Jabbour T, Somma J, Nakanishi Y, Ligato S, Lee H, Fu ZY*

## ORIGINAL ARTICLE

## Retrospective Study

- 1043 Single-center retrospective study of the diagnostic value of double-balloon enteroscopy in Meckel's diverticulum with bleeding  
*He T, Yang C, Wang J, Zhong JS, Li AH, Yin YJ, Luo LL, Rao CM, Mao NF, Guo Q, Zuo Z, Zhang W, Wan P*
- 1055 Prognostic value of a nomogram model for postoperative liver metastasis of colon cancer  
*Cheng DX, Xu KD, Liu HB, Liu Y*
- 1066 Computer-assisted three-dimensional individualized extreme liver resection for hepatoblastoma in proximity to the major liver vasculature  
*Xiu WL, Liu J, Zhang JL, Wang JM, Wang XF, Wang FF, Mi J, Hao XW, Xia N, Dong Q*
- 1078 Research on the prognostic value of adjusting intraperitoneal three-dimensional quality evaluation mode in laparoscopic cholecystectomy patients  
*Zhou Y, Chen ZQ*

- 1087** Construction of a predictive model for acute liver failure after hepatectomy based on neutrophil-to-lymphocyte ratio and albumin-bilirubin score

*Li XP, Bao ZT, Wang L, Zhang CY, Yang W*

- 1097** Predicting short-term thromboembolic risk following Roux-en-Y gastric bypass using supervised machine learning

*Ali H, Inayat F, Moond V, Chaudhry A, Afzal A, Anjum Z, Tahir H, Anwar MS, Dahiya DS, Afzal MS, Nawaz G, Sohail AH, Aziz M*

- 1109** Comparative analysis of two digestive tract reconstruction methods in total laparoscopic radical total gastrectomy

*Dong TX, Wang D, Zhao Q, Zhang ZD, Zhao XF, Tan BB, Liu Y, Liu QW, Yang PG, Ding PA, Zheng T, Li Y, Liu ZJ*

- 1121** Incidence of surgical site infection in minimally invasive colorectal surgery

*Ni LT, Zhao R, Ye YR, Ouyang YM, Chen X*

### Observational Study

- 1130** Burden of gallstone disease in the United States population: Prepandemic rates and trends

*Unalp-Arida A, Ruhl CE*

### Prospective Study

- 1149** Kuicolong-yu enema decoction retains traditional Chinese medicine enema attenuates inflammatory response ulcerative colitis through TLR4/NF- $\kappa$ B signaling pathway

*Han L, Tang K, Fang XL, Xu JX, Mao XY, Li M*

### SYSTEMATIC REVIEWS

- 1155** Quality-adjusted life years and surgical waiting list: Systematic review of the literature

*de la Plaza Llamas R, Ortega Azor L, Hernández Yuste M, Gorini L, Latorre-Fragua RA, Díaz Candelas DA, Al Shwely Abduljabar F, Gemio del Rey IA*

### META-ANALYSIS

- 1165** Impact of different anastomosis methods on post-recurrence after intestinal resection for Crohn's disease: A meta-analysis

*Wang ZZ, Zhao CH, Shen H, Dai GP*

### CASE REPORT

- 1176** Suspected coexistence of perianal necrotizing sweet syndrome in chronic myelomonocytic leukemia: A case report

*Yu KQ, Li HX, Wu J*

- 1184** Successful splenic artery embolization in a patient with Behçet's syndrome-associated splenic rupture: A case report

*Zhu GZ, Ji DH*

- 1189** Stercoral perforation of the cecum: A case report

*Yu HC, Pu TW, Kang JC, Chen CY, Hu JM, Su RY*

- 1195** Percutaneous transhepatic stenting for acute superior mesenteric vein stenosis after pancreaticoduodenectomy with portal vein reconstruction: A case report  
*Lin C, Wang ZY, Dong LB, Wang ZW, Li ZH, Wang WB*
- 1203** Endoscopic treatment of bleeding gastric ulcer causing gastric wall necrosis: A case report  
*Li WF, Gao RY, Xu JW, Yu XQ*
- 1208** Intermittent melena and refractory anemia due to jejunal cavernous lymphangioma: A case report  
*Liu KR, Zhang S, Chen WR, Huang YX, Li XG*

**LETTER TO THE EDITOR**

- 1215** New frontiers in ectopic pancreatic tissue management  
*Covantsev S*



**ABOUT COVER**

Editorial Board Member of *World Journal of Gastrointestinal Surgery*, Arunachalam Rathnaswami, FACS, MBBS, MS, MNAMS, MCh, Ex-Professor and Head, Department of Surgical Gastroenterology, SRM Medical College Hospital and Research Institute SRMIST, Kattankulathur, Chennai, TamilNadu 603203, India. arunarathna@gmail.com

**AIMS AND SCOPE**

The primary aim of *World Journal of Gastrointestinal Surgery* (WJGS, *World J Gastrointest Surg*) is to provide scholars and readers from various fields of gastrointestinal surgery with a platform to publish high-quality basic and clinical research articles and communicate their research findings online.

WJGS mainly publishes articles reporting research results and findings obtained in the field of gastrointestinal surgery and covering a wide range of topics including biliary tract surgical procedures, biliopancreatic diversion, colectomy, esophagectomy, esophagostomy, pancreas transplantation, and pancreatectomy, *etc.*

**INDEXING/ABSTRACTING**

The WJGS is now abstracted and indexed in Science Citation Index Expanded (SCIE, also known as SciSearch®), Current Contents/Clinical Medicine, Journal Citation Reports/Science Edition, PubMed, PubMed Central, Reference Citation Analysis, China Science and Technology Journal Database, and Superstar Journals Database. The 2023 Edition of Journal Citation Reports® cites the 2022 impact factor (IF) for WJGS as 2.0; IF without journal self cites: 1.9; 5-year IF: 2.2; Journal Citation Indicator: 0.52; Ranking: 113 among 212 journals in surgery; Quartile category: Q3; Ranking: 81 among 93 journals in gastroenterology and hepatology; and Quartile category: Q4.

**RESPONSIBLE EDITORS FOR THIS ISSUE**

Production Editor: Zi-Hang Xu, Production Department Director: Xiang Li, Cover Editor: Jia-Ru Fan.

**NAME OF JOURNAL**

*World Journal of Gastrointestinal Surgery*

**ISSN**

ISSN 1948-9366 (online)

**LAUNCH DATE**

November 30, 2009

**FREQUENCY**

Monthly

**EDITORS-IN-CHIEF**

Peter Schemmer

**EDITORIAL BOARD MEMBERS**

<https://www.wjgnet.com/1948-9366/editorialboard.htm>

**PUBLICATION DATE**

April 27, 2024

**COPYRIGHT**

© 2024 Baishideng Publishing Group Inc

**INSTRUCTIONS TO AUTHORS**

<https://www.wjgnet.com/bpg/gerinfo/204>

**GUIDELINES FOR ETHICS DOCUMENTS**

<https://www.wjgnet.com/bpg/GerInfo/287>

**GUIDELINES FOR NON-NATIVE SPEAKERS OF ENGLISH**

<https://www.wjgnet.com/bpg/gerinfo/240>

**PUBLICATION ETHICS**

<https://www.wjgnet.com/bpg/GerInfo/288>

**PUBLICATION MISCONDUCT**

<https://www.wjgnet.com/bpg/gerinfo/208>

**ARTICLE PROCESSING CHARGE**

<https://www.wjgnet.com/bpg/gerinfo/242>

**STEPS FOR SUBMITTING MANUSCRIPTS**

<https://www.wjgnet.com/bpg/GerInfo/239>

**ONLINE SUBMISSION**

<https://www.f6publishing.com>



## Stercoral perforation of the cecum: A case report

Hung-Chun Yu, Ta-Wei Pu, Jung-Cheng Kang, Chao-Yang Chen, Je-Ming Hu, Ruei-Yu Su

**Specialty type:** Gastroenterology and hepatology

**Provenance and peer review:** Unsolicited article; Externally peer reviewed.

**Peer-review model:** Single blind

**Peer-review report's scientific quality classification**

Grade A (Excellent): 0  
Grade B (Very good): B  
Grade C (Good): 0  
Grade D (Fair): 0  
Grade E (Poor): 0

**P-Reviewer:** Ghannam WM, Egypt

**Received:** November 26, 2023

**Peer-review started:** November 26, 2023

**First decision:** December 11, 2023

**Revised:** January 11, 2024

**Accepted:** March 18, 2024

**Article in press:** March 18, 2024

**Published online:** April 27, 2024



**Hung-Chun Yu**, Department of Surgery, Taichung Armed Forces General Hospital, Taichung 411228, Taiwan

**Hung-Chun Yu**, Department of Surgery, Tri-Service General Hospital, National Defense Medical Center, Taipei 11490, Taiwan

**Ta-Wei Pu, Chao-Yang Chen**, Division of Colon and Rectal Surgery, Department of Surgery, Tri-Service General Hospital Songshan Branch, National Defense Medical Center, Taipei 105, Taiwan

**Jung-Cheng Kang**, Division of Colon and Rectal Surgery, Department of Surgery, Taiwan Adventist Hospital, Taipei 105, Taiwan

**Je-Ming Hu**, Division of Colon and Rectal Surgery, Department of Surgery, Tri-Service General Hospital, National Defense Medical Center, Taipei 114, Taiwan

**Ruei-Yu Su**, Department of Pathology, Tri-Service General Hospital, National Defense Medical Center, Taipei 105, Taiwan

**Ruei-Yu Su**, Department of Pathology and Laboratory Medicine, Taoyuan Armed Forces General Hospital, Taoyuan 325, Taiwan

**Corresponding author:** Ta-Wei Pu, MD, Chief Doctor, Doctor, Surgeon, Division of Colon and Rectal Surgery, Department of Surgery, Tri-Service General Hospital Songshan Branch, National Defense Medical Center, No. 131 Jiankang Road, Taipei 105, Taiwan. [tawei0131@gmail.com](mailto:tawei0131@gmail.com)

### Abstract

#### BACKGROUND

With less than 90 reported cases to date, stercoral perforation of the colon is a rare occurrence. Stercoral ulceration is thought to occur due to ischemic pressure necrosis of the bowel wall, which is caused by the presence of a stercoraceous mass. To underscore this urgent surgical situation concerning clinical presentation, surgical treatment, and results, we present the case of a 66-year-old man with a stercoral perforation.

#### CASE SUMMARY

A 66-year-old man with a history of hypertension, hyperlipidemia, and gout presented at the emergency department with lower abdominal pain and a low-grade fever lasting for a few hours. Abdominal computed tomography indicated a suspected bezoar (approximately 7.6 cm) in the dilated cecum, accompanied by pericolic fat stranding, mild proximal dilatation of the ileum, pneumoperitoneum,

and minimal ascites. Intraoperatively, feculent peritonitis with isolated cecal perforation were observed. Consequently, a right hemicolectomy with peritoneal lavage was performed. A histopathological examination supported the intraoperative findings.

## CONCLUSION

In stercoral perforations, a diagnosis should be diligently pursued, especially in older adults, and prompt surgical intervention should be implemented.

**Key Words:** Acute abdomen; Colectomy; Peritoneal lavage; Pneumoperitoneum; Bezoars; Case report

©The Author(s) 2024. Published by Baishideng Publishing Group Inc. All rights reserved.

**Core Tip:** Spontaneous perforations are classified as either stercoral or idiopathic based on underlying etiologic and pathologic factors. In this case, the operative findings and histopathology report led us to conclude that the perforation was stercoral. This perforation is characterized by a rounded or ovoid-shaped defect with underlying necrotic and inflammatory edges in the absence of significant injuries, obstructions, tumors, and diverticulosis. This condition is commonly observed in chronically ill patients at a rate of 47% in the sigmoid colon and 30% in the rectosigmoid colon. In this manuscript, we present a rare case of bezoar-induced stercoral perforation of the cecum.

**Citation:** Yu HC, Pu TW, Kang JC, Chen CY, Hu JM, Su RY. Stercoral perforation of the cecum: A case report. *World J Gastrointest Surg* 2024; 16(4): 1189-1194

**URL:** <https://www.wjgnet.com/1948-9366/full/v16/i4/1189.htm>

**DOI:** <https://dx.doi.org/10.4240/wjgs.v16.i4.1189>

## INTRODUCTION

With less than 90 reported cases to date, stercoral perforation of the colon is a rare occurrence. Stercoral ulceration is thought to occur due to ischemic pressure necrosis of the bowel wall, which is caused by the presence of a stercoraceous mass[1]. To underscore this urgent surgical situation concerning clinical presentation, surgical treatment, and results, we present the case of a 66-year-old man with a stercoral perforation.

## CASE PRESENTATION

### Chief complaints

A 66-year-old man presented at the emergency department with a 4-h history of lower abdominal and epigastric pain with low-grade fever.

### History of present illness

The patient had a normal bowel movement at around 6 am on the day of presentation, then 4 h later he developed abdominal pain in the lower abdomen that increased in intensity and extended to the epigastric area. The pain was accompanied by multiple bowel movements, without nausea or vomiting. He presented to the hospital four hours after the abdominal pain started with lower abdominal pain.

### History of past illness

The patient had a history of hypertension, hyperlipidemia, and gout, and regularly visited the cardiology outpatient department for follow-up and maintenance medication. The patient had no history of rectal bleeding, anorexia, or weight loss. Seven years before presentation, the patient underwent a colonoscopy, which revealed no abnormal mucosal or mass lesions up to the ileocecal valve.

### Personal and family history

The patient has a history of cigarette smoking, averaging 1-1.5 packs per day for decades. Additionally, he occasionally consumed alcohol socially. Regarding family history, his mother had a history of hypertension and diabetes mellitus.

### Physical examination

On physical examination, the patient was conscious and alert. His vital signs were: Body temperature, 36.2 degree Celsius; pulse, 96 beats per minute; blood pressure, 142/82 mmHg. Examination of the abdomen demonstrated rebound tenderness in the right lower quadrants and suprapubic area upon palpation, normal bowel sounds, no tympanic sounds,

and no Murphy's sign. A digital rectal examination revealed traces of stool with a minimal amount of gross blood. No masses were palpable.

### Laboratory examinations

A complete blood count showed a white blood cell count of  $18.05 \times 10^9/L$  and a haemoglobin level of 14.7 gm/dL. Other laboratory investigations showed normal results.

### Imaging examinations

A plain radiograph of the kidneys, ureters, and bladder revealed a focal lesion in the right lower quadrant of the abdomen (Figure 1). Further imaging *via* an abdominal computed tomography scan showed a suspected bezoar (approximately 7.6 cm in diameter) in the dilated cecum accompanied by pericolic fat stranding, mild proximal dilatation of the ileum, pneumoperitoneum, and minimal ascites (Figure 2A and B).

## FINAL DIAGNOSIS

Spontaneous cecal perforation, status post right hemicolectomy on admission to the hospital, status post wound debridement with rectus abdominis flap on post-operative day 12.

## TREATMENT

The intravenous antibiotics flomoxef and metronidazole, were administered. A decision was made to perform exploratory laparotomy, during which a rounded perforation (7 cm  $\times$  5 cm in diameter) of the cecum was found (Figure 3A). Upon dissection, the cecal wall was found to be thin, without any obvious tumorous lesions on the mucosa (Figure 3B). Seropurulent fluid was present in the peritoneal cavity (Figure 3C) with fecal contamination (Figure 3D). The bezoar extracted from the dilated cecum was 9 centimeters in diameter (Figure 3E). Consequently, a right hemicolectomy with peritoneal lavage was performed. Histopathological examination revealed a grossly rounded cecal perforation with ischemic necrosis (Figure 4A). Microscopically, the mucosa around the perforation exhibited acute transmural inflammatory cell infiltration and fibroblast proliferation (Figure 4B). Remarkable ischemic necrosis with crypt loss was observed.

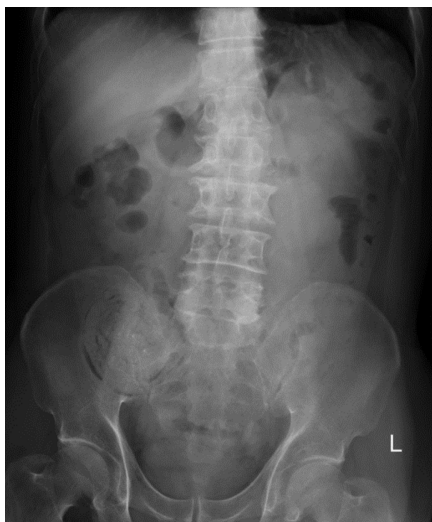## OUTCOME AND FOLLOW-UP

Postoperatively, the patient recovered from brief atelectasis. However, the wound did not respond well to local treatment with an aqua beta-iodine dressing. Fascial dehiscence occurred with bowel exposure. Therefore, wound debridement was performed using a rectus abdominis flap on post-operative day 12. After the operation, oral feeding was gradually advanced, and the patient tolerated it well. Subsequently, he was discharged in stable condition and followed up in our outpatient clinic.

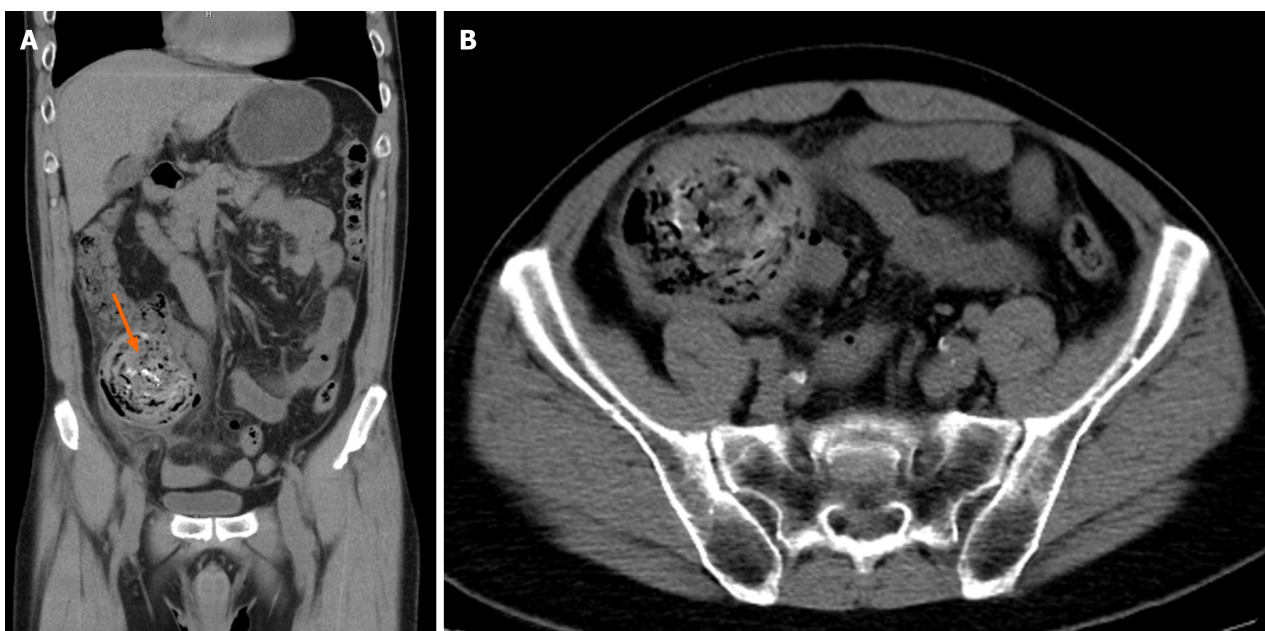
## DISCUSSION

Spontaneous cecal perforation is the sudden perforation of a previously clinically healthy colon in the absence of an underlying disease or injury. To date, fewer than 100 cases have been reported in the literature[2]. In spontaneous perforations, the mean age of affected patients is 65 years. Furthermore, men are more susceptible to perforation, with a ratio of 2:1 in older adult men and women, respectively[3]. Mortality rates associated with cecal perforation are high, ranging from 30% to 72%[4]. The prognosis of spontaneous cecal perforation is influenced by various factors, such as the timing of perforation, the extent of peritoneal contamination, and the timeliness of intervention.

In 1894, Berry classified spontaneous perforations as either stercoral or idiopathic. This classification is based on underlying etiological and pathological factors[5]. Maurer *et al*[6] established guidelines for identifying stercoral perforation according to the defect's form, size, its proximity to the mesentery, and the existence of fecalomas poking through the defect. At a microscopic level, pressure-induced necrosis or ulcer surrounded by chronic inflammatory response are observed near the perforation site. In this case, operative findings and histopathology report led us to conclude that the perforation was of the stercoral type. Stercoral perforation is characterized by a rounded or ovoid-shaped defect with underlying necrotic and inflammatory edges in the absence of significant injuries, obstructions, tumors, and diverticulosis[6]. This condition is commonly observed in chronically ill patients. The increase in intraluminal and intra-abdominal pressure during defecation contributes to its etiology[7]. Stercoral perforation is more frequently observed in the sigmoid colon in 47% of cases and the rectosigmoid colon in 30% of cases[8]. In other parts of the colon, it was observed in 33% of cases. However, our patient did not have a history of a significant change of bowel habits and a colonoscopy conducted 7 years prior reported no abnormal mucosal or mass lesions up to the ileocecal valve. According to the intraoperative findings, bezoar-induced perforation is the most reasonable cause.



**Figure 1** Plain radiograph of the patient's kidneys, ureters, and bladder. The kidneys, ureters, and bladder radiograph displaying a focal lesion in the right lower quadrant of the patient's abdomen.

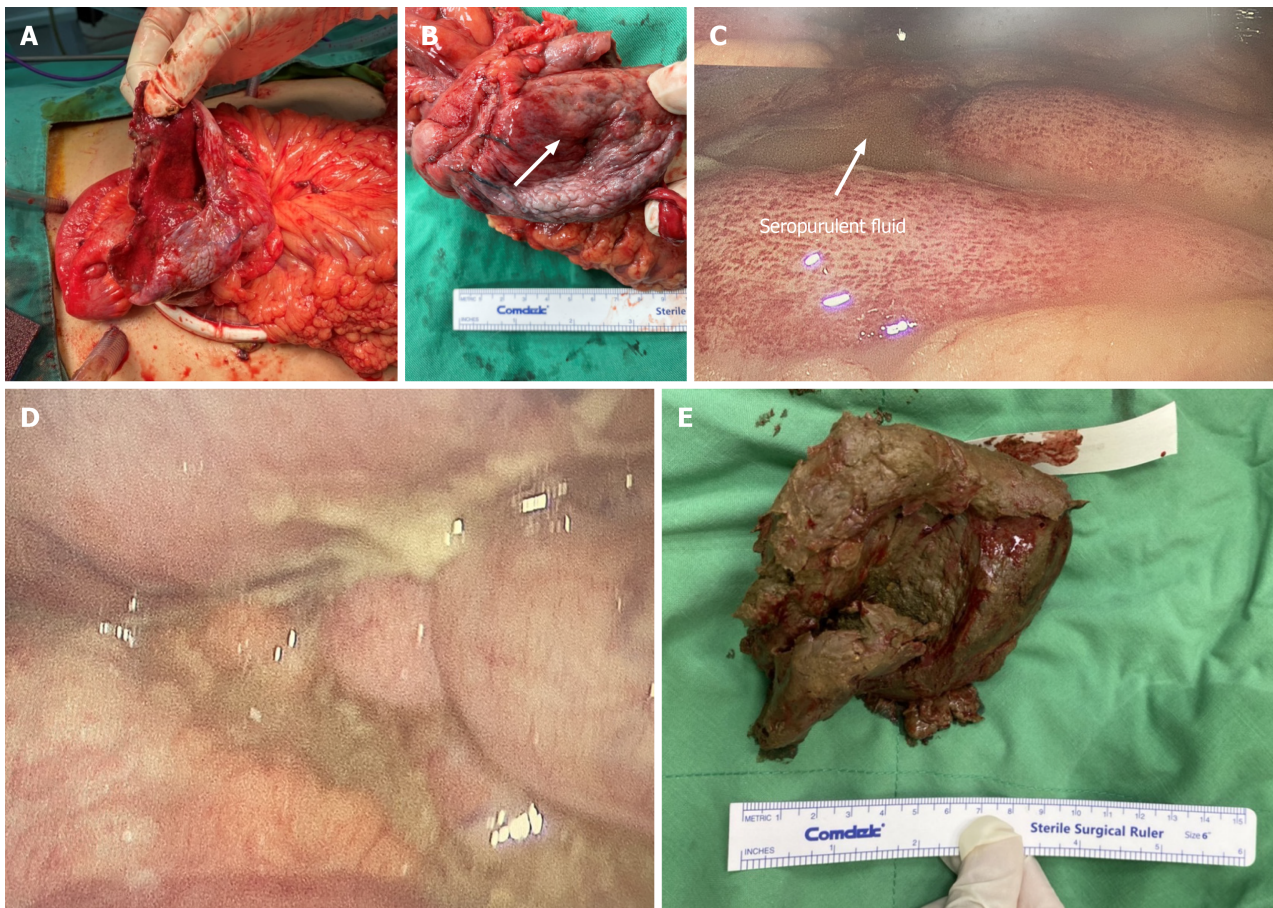


**Figure 2** Abdominal computed tomography imaging of the patient's abdomen. A: A suspected bezoar (approximately 7.6 cm) was seen in the dilated cecum (arrow); B: Pericolic fat stranding, mild proximal dilatation of the ileum, pneumoperitoneum and minimal ascites accompanied this lesion.

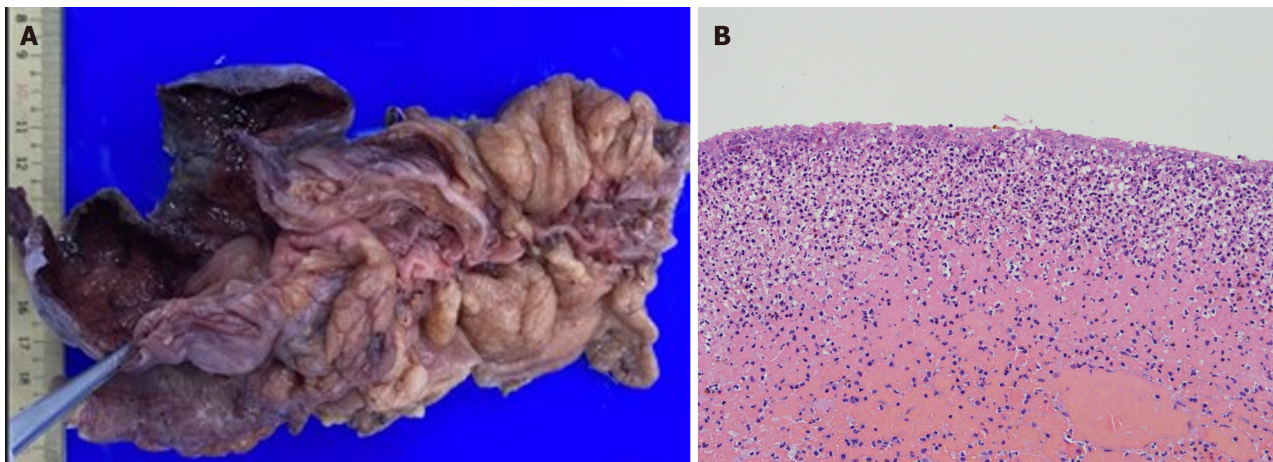
A bezoar is a firm, solid, enduring foreign object found in the gastrointestinal tract. They can be found in various parts of the gastrointestinal tract, such as the esophagus and colon. Four distinct types of bezoars have been identified based on their originating material: Phytobezoars, trichobezoars, concretions, and pharmacobezoars[9]. None of these described causes seemed to match this patient's condition. In a retrospective analysis study, alcohol consumption, hypertension, and diabetes were reported to serve as risk factors for bezoars[10]. Therefore, further investigation may be necessary to identify the specific reason of bezoar formation in this case.

Idiopathic perforation occurs because of the asymmetrical distribution of intraluminal pressure at the pelvic-rectal angle in the absence of obviously impacted stool or any identifiable cause of perforation[11]. The exact cause of spontaneous cecal perforation is unclear; however, it has been reported to be associated with certain conditions including hypothyroidism, intestinal hypomotility, chronic constipation, and fecal impaction[12]. Notably, steroids and non-steroidal anti-inflammatory drugs inhibit cyclo-oxygenase enzymes, resulting in a subsequent reduction in protective prostaglandins[13]. Fecal impaction induced by drugs such as opiates, antacids, codeine, amitriptyline, and tranquilizers is becoming more prevalent and could lead to spontaneous cecal perforation.





**Figure 3 Intraoperative photographs of gross findings.** A: A rounded perforation (7 cm × 5 cm in diameter) of the cecum was intraoperatively noted; B: The cecum was notably thin without any obvious tumorous lesions on the mucosa (as marked); C: Seropurulent fluid was freely present in the peritoneal cavity; D: Fecal contamination was observed in the peritoneal cavity; E: The bezoar extracted from the dilated cecum.



**Figure 4 Gross and histopathological examination of the cecal specimen.** A: A grossly rounded cecal perforation with ischemic necrosis was observed; B: Microscopically, the muscle layers show lymphoplasmic cell infiltration with crypt effacement and hemorrhage.

## CONCLUSION

Cecal perforation occurring spontaneously is an uncommon occurrence linked with heightened morbidity and mortality rates. Irrespective of the surgical approach, detecting it early and swiftly resorting to surgical intervention are key tactics linked with better results. Hence, it's imperative to strive for a timely diagnosis, particularly in the elderly, and promptly initiate surgical measures.

## ACKNOWLEDGEMENTS

The authors wish to acknowledge the assistance of the people at the Department of Surgery, Tri-Service General Hospital Songsang Branch. This report would not have been possible without their efforts in data collection and interprofessional collaboration in treating this patient.

## FOOTNOTES

**Author contributions:** Yu HC, Pu TW, Kang JC, Chen CY, Hu JM, and Su RY designed and performed the research; Yu HC and Pu TW analyzed the data and wrote the manuscript; and all authors have read and approved the final manuscript.

**Informed consent statement:** Informed written consent was obtained from the patient for publication of this report and any accompanying images.

**Conflict-of-interest statement:** All the authors report no relevant conflicts of interest for this article.

**CARE Checklist (2016) statement:** The authors have read the CARE Checklist (2016), and the manuscript was prepared and revised according to the CARE Checklist (2016).

**Open-Access:** This article is an open-access article that was selected by an in-house editor and fully peer-reviewed by external reviewers. It is distributed in accordance with the Creative Commons Attribution NonCommercial (CC BY-NC 4.0) license, which permits others to distribute, remix, adapt, build upon this work non-commercially, and license their derivative works on different terms, provided the original work is properly cited and the use is non-commercial. See: <https://creativecommons.org/licenses/by-nc/4.0/>

**Country/Territory of origin:** Taiwan

**ORCID number:** Hung-Chun Yu 0009-0007-5077-1187; Ta-Wei Pu 0000-0002-0538-407X; Jung-Cheng Kang 0000-0001-7511-5337; Chao-Yang Chen 0000-0002-2246-7635; Je-Ming Hu 0000-0002-7377-0984; Ruei-Yu Su 0000-0001-6728-8705.

**S-Editor:** Wang JJ

**L-Editor:** A

**P-Editor:** Xu ZH

## REFERENCES

- Patel VG, Kalakuntla V, Fortson JK, Weaver WL, Joel MD, Hammami A. Stercoral perforation of the sigmoid colon: report of a rare case and its possible association with nonsteroidal anti-inflammatory drugs. *Am Surg* 2002; **68**: 62-64 [PMID: 12467320]
- Makki AM, Hejazi S, Zaidi NH, Johari A, Altaf A. Spontaneous Perforation of Colon: A Case Report and Review of Literature. *Case Rep Clin Med* 2014; **3**: 392-397 [DOI: 10.4236/crcm.2014.37087]
- Galanis I, Dragoumis D, Kalogirou T, Lakis S, Kotakidou R, Atmatzidis K. Spontaneous perforation of solitary ulcer of transverse colon. *Indian J Pathol Microbiol* 2010; **53**: 138-140 [PMID: 20090246 DOI: 10.4103/0377-4929.59207]
- Laskin MD, Tessler K, Kives S. Cecal perforation due to paralytic ileus following primary caesarean section. *J Obstet Gynaecol Can* 2009; **31**: 167-171 [PMID: 19327217 DOI: 10.1016/s1701-2163(16)34102-0]
- Al Shukry S. Spontaneous perforation of the colon clinical review of five episodes in four patients. *Oman Med J* 2009; **24**: 137-141 [PMID: 22334860 DOI: 10.5001/omj.2009.30]
- Maurer CA, Renzulli P, Mazzucchelli L, Egger B, Seiler CA, Büchler MW. Use of accurate diagnostic criteria may increase incidence of stercoral perforation of the colon. *Dis Colon Rectum* 2000; **43**: 991-998 [PMID: 10910249 DOI: 10.1007/BF02237366]
- Dubinsky I. Stercoral perforation of the colon: case report and review of the literature. *J Emerg Med* 1996; **14**: 323-325 [PMID: 8782027 DOI: 10.1016/0736-4679(96)00044-3]
- Berry J. Dilatation and rupture of sigmoid flexure short report. *BMJ* 1894; **1**: 301
- Erdemir A, Ağalar F, Çakmakçı M, Ramadan S, Baloglu H. A rare cause of mechanical intestinal obstruction: Pharmacobezoars. *Ulus Cerrahi Derg* 2015; **31**: 92-93 [PMID: 26170758 DOI: 10.5152/UCD.2014.2749]
- Liu LN, Wang L, Jia SJ, Wang P. Clinical Features, Risk Factors, and Endoscopic Treatment of Bezoars: A Retrospective Analysis from a Single Center in Northern China. *Med Sci Monit* 2020; **26**: e926539 [PMID: 33027245 DOI: 10.12659/MSM.926539]
- Kurane SB, Kurane BT. Idiopathic colonic perforation in adult-a rare case. *Indian J Surg* 2011; **73**: 63-64 [PMID: 22211042 DOI: 10.1007/s12262-010-0127-z]
- Parish KL, Chapman WC, Williams LF Jr. Ischemic colitis. An ever-changing spectrum? *Am Surg* 1991; **57**: 118-121 [PMID: 1992867]
- Ervens J, Schiffmann L, Berger G, Hoffmeister B. Colon perforation with acute peritonitis after taking clindamycin and diclofenac following wisdom tooth removal. *J Craniomaxillofac Surg* 2004; **32**: 330-334 [PMID: 15458677 DOI: 10.1016/j.jcms.2004.05.007]



Published by **Baishideng Publishing Group Inc**  
7041 Koll Center Parkway, Suite 160, Pleasanton, CA 94566, USA

**Telephone:** +1-925-3991568

**E-mail:** [office@baishideng.com](mailto:office@baishideng.com)

**Help Desk:** <https://www.f6publishing.com/helpdesk>

<https://www.wjgnet.com>

