

World Journal of *Clinical Cases*

World J Clin Cases 2024 April 26; 12(12): 2000-2137



Contents

Thrice Monthly Volume 12 Number 12 April 26, 2024

EDITORIAL

- 2000** Protein C deficiency with venous and arterial thromboembolic events
Zhang N, Sun DK, Tian X, Zheng XY, Liu T
- 2004** Indication and surgical approach for reconstruction with endoprosthesis in bone-associated soft tissue sarcomas: Appropriate case management is vital
Öztürk R
- 2009** Comprehensive and personalized approach is a critical area for developing remote cardiac rehabilitation programs
Pepera G, Antoniou V, Su JJ, Lin R, Batalik L
- 2016** Pain management in chronic pancreatitis
Nag DS, Swain BP, Anand R, Barman TK, Vatsala
- 2023** Predicting intensive care unit-acquired weakness: A multilayer perceptron neural network approach
Ardila CM, González-Arroyave D, Zuluaga-Gómez M

MINIREVIEWS

- 2031** Autoantibodies related to ataxia and other central nervous system manifestations of gluten enteropathy
Velikova T, Vasilev G, Shumnalieva R, Chervenkov L, Miteva DG, Gulinac M, Priftis S, Lazova S

ORIGINAL ARTICLE

Retrospective Study

- 2040** Enhanced recovery after surgery in elderly patients with non-small cell lung cancer who underwent video-assisted thoracic surgery
Sun MH, Wu LS, Qiu YY, Yan J, Li XQ

Clinical Trials Study

- 2050** Transient elastography with controlled attenuation parameter for the diagnosis of colorectal polyps in patients with nonalcoholic fatty liver disease
Wang L, Li YF, Dong LF

META-ANALYSIS

- 2056** Systematic review and network meta-analysis of different non-steroidal anti-inflammatory drugs for juvenile idiopathic arthritis
Zeng T, Ye JZ, Qin H, Xu QQ

CASE REPORT

- 2065 Human immunodeficiency virus-associated dementia complex with positive 14-3-3 protein in cerebrospinal fluid: A case report
He YS, Qin XH, Feng M, Huang QJ, Zhang MJ, Guo LL, Bao MB, Tao Y, Dai HY, Wu B
- 2074 Multiorgan dysfunction syndrome due to high-dose cantharidin poisoning: A case report
Xu WL, Tang WJ, Yang WY, Sun LC, Zhang ZQ, Li W, Zang XX
- 2079 Overlapping infections of *Mycobacterium canariasense* and *Nocardia farcinica* in an immunocompetent patient: A case report
Huang HY, Bu KP, Liu JW, Wei J
- 2086 Basilic vein variation encountered during surgery for arm vein port: A case report
Hu CD, Lv R, Zhao YX, Zhang MH, Zeng HD, Mao YW
- 2092 Early embryonic failure caused by a novel mutation in the *TUBB8* gene: A case report
Zhang XY, Zhang XX, Wang L
- 2099 Thoracic spine infection caused by *Pseudomonas fluorescens*: A case report and review of literature
Li L, Zhang BH, Cao JF, Zhang LJ, Guo LL
- 2109 Bone block from lateral window - correcting vertical and horizontal bone deficiency in maxilla posterior site: A case report
Wang YL, Shao WJ, Wang M
- 2116 Small intestine angioleiomyoma as a rare cause of perforation: A case report
Hou TY, Tzeng WJ, Lee PH
- 2122 Crossed renal ectopia with rectal cancer: A case report
Tang ZW, Yang HF, Wu ZY, Wang CY
- 2128 Systemic lupus erythematosus in a 15-year-old female with multiple splenic nodules: A case report
Kang MI, Kwon HC

LETTER TO THE EDITOR

- 2134 Machine learning in liver surgery: Benefits and pitfalls
Calleja R, Durán M, Ayllón MD, Ciria R, Briceño J

ABOUT COVER

Peer Reviewer of *World Journal of Clinical Cases*, Eugen Javor, PharmD, Chief Pharmacist, Lecturer, Pharmacy Department, General Hospital Bjelovar, Bjelovar 43000, Croatia. eugen.javor@gmail.com

AIMS AND SCOPE

The primary aim of *World Journal of Clinical Cases* (WJCC, *World J Clin Cases*) is to provide scholars and readers from various fields of clinical medicine with a platform to publish high-quality clinical research articles and communicate their research findings online.

WJCC mainly publishes articles reporting research results and findings obtained in the field of clinical medicine and covering a wide range of topics, including case control studies, retrospective cohort studies, retrospective studies, clinical trials studies, observational studies, prospective studies, randomized controlled trials, randomized clinical trials, systematic reviews, meta-analysis, and case reports.

INDEXING/ABSTRACTING

The WJCC is now abstracted and indexed in Science Citation Index Expanded (SCIE, also known as SciSearch®), Journal Citation Reports/Science Edition, Current Contents®/Clinical Medicine, PubMed, PubMed Central, Reference Citation Analysis, China Science and Technology Journal Database, and Superstar Journals Database. The 2023 Edition of Journal Citation Reports® cites the 2022 impact factor (IF) for WJCC as 1.1; IF without journal self cites: 1.1; 5-year IF: 1.3; Journal Citation Indicator: 0.26; Ranking: 133 among 167 journals in medicine, general and internal; and Quartile category: Q4.

RESPONSIBLE EDITORS FOR THIS ISSUE

Production Editor: Hua-Ge Yin, Production Department Director: Xu Guo, Cover Editor: Jin-Lai Wang.

NAME OF JOURNAL

World Journal of Clinical Cases

ISSN

ISSN 2307-8960 (online)

LAUNCH DATE

April 16, 2013

FREQUENCY

Thrice Monthly

EDITORS-IN-CHIEF

Bao-Gan Peng, Salim Surani, Jerzy Tadeusz Chudek, George Kontogeorgos, Maurizio Serati

EDITORIAL BOARD MEMBERS

<https://www.wjgnet.com/2307-8960/editorialboard.htm>

PUBLICATION DATE

April 26, 2024

COPYRIGHT

© 2024 Baishideng Publishing Group Inc

INSTRUCTIONS TO AUTHORS

<https://www.wjgnet.com/bpg/gerinfo/204>

GUIDELINES FOR ETHICS DOCUMENTS

<https://www.wjgnet.com/bpg/GerInfo/287>

GUIDELINES FOR NON-NATIVE SPEAKERS OF ENGLISH

<https://www.wjgnet.com/bpg/gerinfo/240>

PUBLICATION ETHICS

<https://www.wjgnet.com/bpg/GerInfo/288>

PUBLICATION MISCONDUCT

<https://www.wjgnet.com/bpg/gerinfo/208>

ARTICLE PROCESSING CHARGE

<https://www.wjgnet.com/bpg/gerinfo/242>

STEPS FOR SUBMITTING MANUSCRIPTS

<https://www.wjgnet.com/bpg/GerInfo/239>

ONLINE SUBMISSION

<https://www.f6publishing.com>



Early embryonic failure caused by a novel mutation in the *TUBB8* gene: A case report

Xiao-Yu Zhang, Xing-Xing Zhang, Lei Wang

Specialty type: Medicine, research and experimental

Provenance and peer review: Unsolicited article; Externally peer reviewed.

Peer-review model: Single blind

Peer-review report's scientific quality classification

Grade A (Excellent): 0
Grade B (Very good): 0
Grade C (Good): C
Grade D (Fair): 0
Grade E (Poor): 0

P-Reviewer: Shah RA, India

Received: November 29, 2023

Revised: February 22, 2024

Accepted: March 21, 2024

Published online: April 26, 2024



Xiao-Yu Zhang, Xing-Xing Zhang, Lei Wang, Department of Reproductive Center, Zaozhuang Maternal and Child Healthcare Hospital, Zaozhuang 277000, Shandong Province, China

Corresponding author: Lei Wang, Doctor, Associate Chief Physician, Department of Reproductive Center, Zaozhuang Maternal and Child Healthcare Hospital, No. 3 Fuyuan Road, Xuecheng District, Zaozhuang 277000, Shandong Province, China. wzkwyb@126.com

Abstract

BACKGROUND

This study aimed to explore the relationship between gene mutations and early embryonic development arrest and to provide more possibilities for the diagnosis and treatment of repeated implantation failure.

CASE SUMMARY

Here, we collected and described the clinical data of a patient with early embryonic development stagnation after repeated *in vitro* fertilization attempts for primary infertility at the Department Reproductive Center of Zaozhuang Maternal and Child Healthcare Hospital. We also detected the whole-exon gene of the patient's spouse and parents, and conducted bioinformatics analysis to determine the pathogenesis of the gene.

CONCLUSION

A novel mutant of the *TUBB8* gene [c.602G>T(p.C201F)] was identified, and this mutant provided new data on the genotype-phenotype relationships of related diseases.

Key Words: Genes; Mutation; Embryonic development; Fertilization *in vitro*; Intracytoplasmic sperm injection; Case report

©The Author(s) 2024. Published by Baishideng Publishing Group Inc. All rights reserved.

Core Tip: A clinical case (28 years old) in which a new mutation in the *TUBB8* gene caused repeated arrest of early embryonic development to expand our understanding of the genetic basis of female infertility and lay the groundwork for future genetic counseling.

Citation: Zhang XY, Zhang XX, Wang L. Early embryonic failure caused by a novel mutation in the *TUBB8* gene: A case report. *World J Clin Cases* 2024; 12(12): 2092-2098

URL: <https://www.wjgnet.com/2307-8960/full/v12/i12/2092.htm>

DOI: <https://dx.doi.org/10.12998/wjcc.v12.i12.2092>

INTRODUCTION

With the development of assisted reproductive technology, an increasing number of couples are conceiving through *in vitro* fertilization (IVF) embryo transfer. However, there are still some couples who are unable to conceive successfully[1]. The normal progression of meiosis and mitosis is one of the basic conditions for oocyte maturation and early embryo development. In the process of cell division, homologous chromosomes are symmetrically arranged through the microtubule organizing center, and the chromosomes divide to form the next stage of cells under the traction of bipolar spindles. Spindle assembly and chromosome separation are inseparable from the basic role of tubulin, and *TUBB8* is a special subtype of tubulin that plays an important role in human oocytes and early embryonic cells[2,3]. Previous studies have shown that mutation of the *TUBB8* gene leads to disorders of oocyte maturation, fertilization and early embryo development stagnation[4,5]. This paper reports a clinical case in which a novel mutation in the *TUBB8* gene led to repeated early embryonic development arrest. This finding expands our understanding of the genetic basis of female infertility and lays the foundation for future genetic counseling.

CASE PRESENTATION

Chief complaints

A 2-year history of primary infertility after marriage.

History of present illness

The patient was a 28-year-old female with a 2-year history of primary infertility after marriage. Her menstrual history was as follows: menarche at age 14, a cycle of 7/-30 days, normal volume and color of menstrual blood, and no dysmenorrhea. The male partner was 26 years old. Results of the routine semen analysis were normal (sperm concentration 34.7×10^6 ; percentage of progressive motility 64.6%; sperm DNA fragmentation index: 14.38%) according to World Health Organization 5th Edition criteria.

History of past illness

In 2019, the patient underwent hysteroscopy and hysteroscopic endometrial polypectomy at another hospital due to abnormal echoes in the uterine cavity, and pathological examination of the uterine specimen indicated the presence of endometrial polyps.

Personal and family history

The patient had no pertinent personal or family history. Both partners had no bad living habits or hobbies, and were not engaged in work related to reproductive toxicity.

Physical examination

The patient had a negative vulva, a normal uterus, and a negative bilateral adnexal area. Her body mass index was 21.23 kg/m².

Laboratory examinations

The concentration of anti-Mullerian hormone (AMH) was 2.634 ng/mL (1 ng/mL = 7.14 pmol/L). There were no obvious abnormalities in basic hormone levels or thyroid function. The patient's karyotype was 46, XX, and the male partner's karyotype was 46, XY.

Imaging examinations

Hysterosalpingography revealed that the uterine cavity was normal, bilateral fallopian tubes were developed, and the spread of the pelvic contrast agent was diffuse and limited.

FINAL DIAGNOSIS

Primary infertility.

TREATMENT

In March 2021 and May 2021, the patient underwent two cycles of artificial insemination in the Department Reproductive Center. The first cycle was a natural cycle, and the second cycle was an ovulation induction cycle. Both cycles exhibited the development of dominant follicles and did not result in pregnancy.

From August 2021 to November 2022, 5 IVF cycles of assisted pregnancy treatment were performed in the Department Reproductive Center (Table 1).

Cycle 1: In August 2021, the short-acting long protocol in the luteal phase (GnRh-a long protocol) was used to promote ovulation. After ovulation during the mid-menstrual period, 0.1 mg of triptorelin acetate (Triptorelin®, 0.1 mg/piece, Ferring GmbH, Germany) was injected subcutaneously for 7 d, followed by 0.05 mg qd for 7 d. After 14 d, ultrasound and sex hormone examinations revealed that the ovarian follicles were in the basic state, gonadotropin (Gn) was activated, and recombinant follicle stimulating hormone was injected with recombinant follitropin β (Pouliquen®, 600 IU/piece, Merck & Co. Inc, United States) at 200 IU qd and Gn for 9 d. Three follicles were ≥ 18 mm, and nine follicles were ≥ 14 mm on the day of hCG trigger (trigger day). An intramuscular injection of 6000 IU of human chorionic gonadotropin (HCG) (2000 IU/tube, Lizhu Group, China) was administered, and 35.5 h later, oocyte retrieval surgery was performed. On the day of oocyte retrieval (D0), 12 oocytes were obtained. The male partner's semen volume on the trigger day and the sperm concentration after treatment showed no significant abnormalities, and routine IVF was performed. After 4–6 h of fertilization, the maturation of oocytes was observed after removing the extracellular granular cells: two oocytes were in the GV stage, two in the MI stage, and eight in the MII stage. However, due to the absence of second polar bodies in the perioocyte space of all MII oocytes, rescue intracytoplasmic spermatozoid injection (R-ICSI) fertilization was performed due to fertilization disorder. Five zygotes with two pronuclei (2PN) were observed on the first day (D1) after oocyte collection, and five zygotes were cleaved on the second day (D2). On the 3rd day (D3), one 8CII embryo was observed and frozen. Three 6CIII embryos and one 5CII embryo continued to incubate without forming a blastocyst. In December 2021, thawing cycle transplantation was performed, and artificial cycle preparation of the endometrium was carried out. On the second day of menstruation, 2 mg/d oral estradiol valerate (Bujiale® 1 mg/tablet, Bayer Vital GmbH, Germany) was given. On the 13th day of menstruation, ultrasound revealed 0.8 cm A-B of the endometrium, and an intramuscular injection of 40 mg qd progesterone (Xianju®, 20 mg/piece, Zhejiang Xianju Pharmaceutical, China) was administered. Three days later, one 10CIII embryo was transferred, but no pregnancy occurred (Figure 1A and B, the embryos).

Cycle 2: In the second cycle in January 2022, the antagonist protocol (GnRH-Ant protocol) was used to promote ovulation. Beginning on the third day of menstruation, recombinant follicle stimulating hormone (Jin Saiheng®, 75 IU/piece, Jin Sai Group, China) was administered subcutaneously for nine days. On the 6th day of Gn treatment, 0.25 mg of GnRH-Ant (Orgalutran®, Merck & Co. Inc, United States) was administered by intramuscular injection until the trigger day. Six follicles were ≥ 18 mm, and eight follicles were ≥ 14 mm on the trigger day. An intramuscular injection of HCG 2000 IU and a subcutaneous injection of triptorelin acetate 0.1 mg as a double trigger were administered, and the oocytes were harvested 35 h later. Fifteen oocytes were obtained by D0. Considering the fertilization disorder that occurred in the first cycle, ICSI fertilization was performed directly. The maturation of oocytes was observed after removing the granulosa cells outside the oocytes: one in the GV stage, one in the MI stage, and thirteen in the MII stage. Ten fertilized oocytes with 2PN were observed on D1, and nine fertilized oocytes were cleaved on D2. On D3, one 8CIII embryo, two 6CIII embryos, two 4CIII embryos, one 3CIII embryo, one 2CIII embryo, two IV embryos were observed, and no blastocysts formed after continuous feeding (Figure 1C and D, the embryos).

Cycle 3: Growth hormone (GH, Sai Zeng, Jin Lei®, 30 IU/piece, Jin Sai Group, China) at a dose of 2 IU was administered in the third cycle in May 2022. One oocyte (MII) was obtained in the natural cycle. The perivitelline space was large and the polar body was disrupted. ICSI fertilization was performed, and oocyte degeneration was observed on the first day (Figure 1E, the embryo).

Cycle 4: In June 2022, the luteal phase of the fourth cycle was designed to promote ovulation. Menotrophin (Li Zhu®, 75 IU/tube, Lizhu Group, China) was injected intramuscularly for 10 d, with four follicles ≥ 18 mm and eight follicles ≥ 14 mm on the trigger day. HCG at a dose of 6000 IU was injected intramuscularly for the trigger, and the oocytes were retrieved 35 h later. Twelve oocytes were obtained at D0, and ICSI was performed. Oocyte maturation was observed after removing the granulosa cells outside the oocytes: one in the MI stage, and eleven in the MII stage. Eight fertilized oocytes with 2PN were observed on D1, and eight fertilized oocytes with cleavage were observed on D2. On D3, there were two 6CIII embryos, four 5CIII embryos, and two IV embryos, and no blastocysts formed after continuous feeding (Figure 1F and G, the embryos).

Cycle 5: In November 2022, in the fifth natural cycle, one oocyte was obtained (MI). After continuous culture, the oocyte did not fertilized (Figure 1H, the embryo).

In August 2022, the whole exomes of the couple and the woman's parents were sequenced (Yikang Gene Testing Company). The results of high-throughput sequencing confirmed the presence of a *TUBB8* gene mutation in the woman [c.602G>T(p.C201F)], but no mutation was found in the man. Sanger sequencing of the woman's parents was used to verify the c.602G>T locus of the *TUBB8* gene. The results showed that the genotype of the patient's father was the same as that of the patient, and the patient's mother had no variation at this locus (Tables 2 and 3, and Figure 1I, the locus of the *TUBB8* gene).

OUTCOME AND FOLLOW-UP

The patient utilized donated oocytes at another hospital and is currently pregnant.

Table 1 Description and characteristics of assisted reproductive technology cycles

	Cycle 1	Cycle 2	Cycle 3	Cycle 4	Cycle 5
COH protocol	GnRH-A Long	GnRH-Ant	Natural cycle	Luteal phase	Natural cycle
Gonadotropin	r-FSH	r-FSH	-	HMG	-
Initiation dose (IU)	200	225	-	225	-
Total dose of gonadotropin (IU)	1975	2025	-	2025	-
Duration of gonadotropin (d)	9	9	-	9	-
E2 level on the day of HCG injection	6605.24	5822.55	189.60	2239.37	172.30
LH level on the day of HCG injection	1.54	0.57	4.87	1.86	4.04
P level on the day of HCG injection	2.05	2.56	0.28	7.38	0.21
No. of follicles (≥ 18 mm)	3	6	0	4	0
No. of follicles (≥ 14 mm)	9	8	1	8	1
Ovulation trigger (dose)	6000 IU (HCG)	2000 IU (HCG) + 0.2 mg (GnRH agonist)	0.1 mg (GnRH agonist)	6000 IU (HCG)	0.1 mg (GnRH agonist)
Interval between HCG administration and oocyte retrieval (h)	35.5 h	35 h	35 h	35 h	34 h
Number of retrieved oocytes	12	15	1	12	1
Fertilization mode	R-ICSI	ICSI	ICSI	ICSI	-
No. of MII	8	13	0	11	0
No. of GV	2	1	0	0	-
No. of 2PN	5	10	-	8	-
No. of D2 zygote	5	10	-	8	-
No. of D3 embryos	5	7	-	6	-
No. of blastocysts	0	0	-	0	-
No. of transferred embryos	1 (FET)	-	-	-	-
Pregnancy outcome	Not pregnant	No transferable embryos	No transferable embryos	No transferable embryos	No transferable embryos

COH: Controlled ovarian hyperstimulation; MII: Metaphase II; MI: Metaphase I; GV: Germinal vesicle; 2PN: 2 pronucleus; FET: Frozen Embryo Transfer.

Table 2 Results of sequencing mutation sites in the coding region of the *TUBB8* gene in the patient (female)

Gene	Chromosomal location	Variant naming	Frequency	Zygotic type	Source of variation
TUBB8	Chr 93730	NM_177987.3: c.602G>T(p.C201F)	Not included	Heterozygous	Unknown

Remarks: The variation verification result may be the complementary sequence of the reference sequence, and the variation C>A can also be expressed as G>T.

DISCUSSION

The patient suffered from primary infertility and had a history of infertility for 2 years. After excluding other infertility-related factors, she first underwent 2 cycles of artificial insemination that failed and then underwent IVF treatment. Both the number of follicles in the bilateral ovarian sinuses and the AMH levels suggested normal ovarian function. In the first cycle, the conventional short-term and long-term follicular phase scheme was used, and the fertilization disorder was remedied quickly. Despite the development of an embryo, the patient failed to conceive after transplantation. In subsequent treatments, whether an antagonist scheme, a luteal phase scheme, or the addition of growth hormone to improve the quality of oocytes was used, although the patient had mature oocytes, the subsequent cleavage of fertilized - eggs and early division of embryos were not satisfactory, and the development of all embryos was still stagnant in the cleavage stage, accompanied by embryo fragmentation. After five cycles of assisted reproductive technology, we found

Table 3 Results of mutation site verification in the patient's parents				
Relationship	Gene	Transcript	Verification site	Verification results
Father	TUBB8	NM_177987.3	c.602G>T	Heterozygous variation
Mother	TUBB8	NM_177987.3	c.602G>T	Without-variation

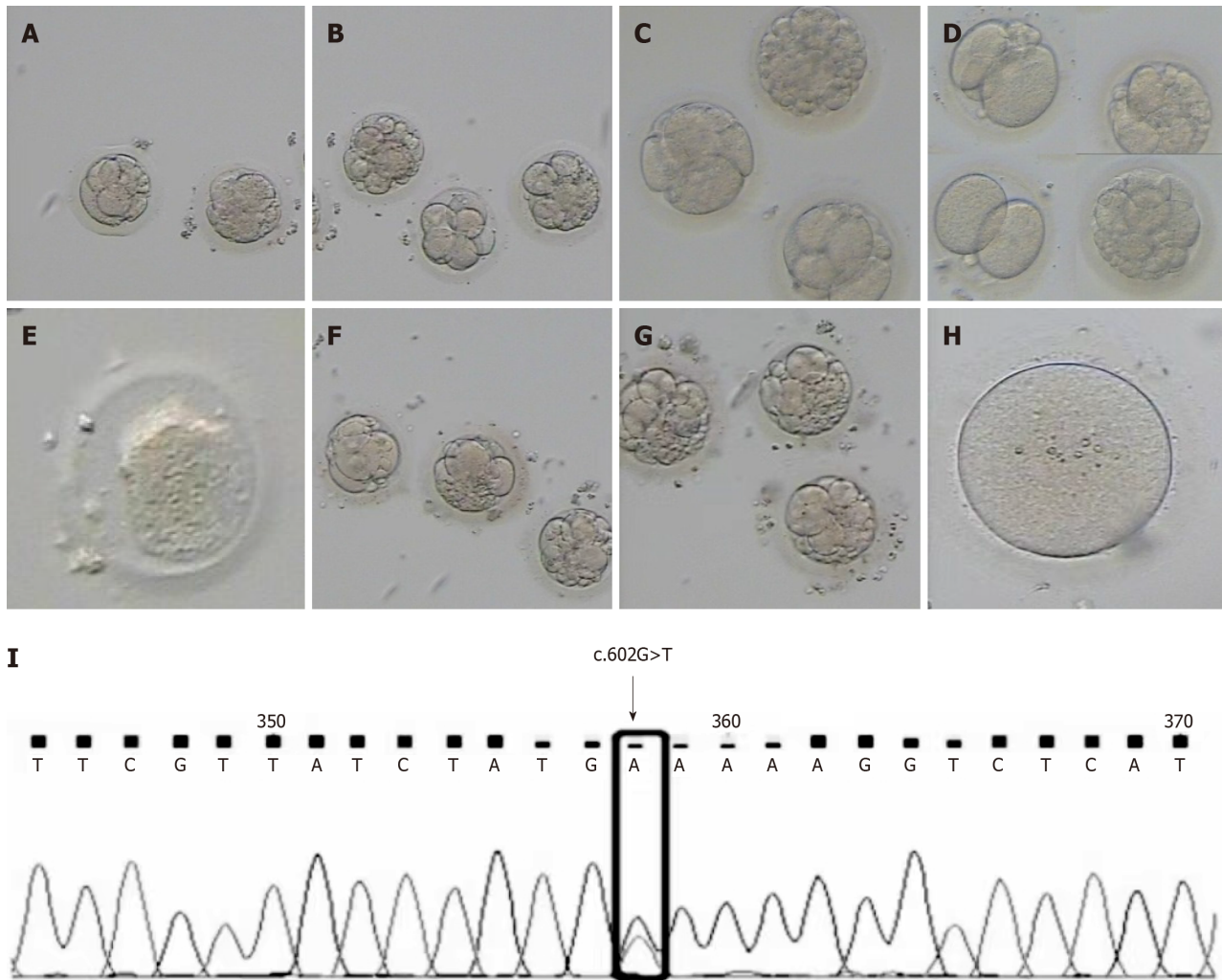


Figure 1 Embryos derived from each cycle of ovulation induction in the patient and the locus of the *TUBB8* gene mutation. A and B: Embryos of the first cycle; C and D: Embryos of the second cycle; E: Embryo of the third cycle; F and G: Embryos of the fourth cycle; H: Embryo of the fifth cycle; I: The locus of the *TUBB8* gene mutation.

that although the patient could produce mature oocytes, there were obstacles to fertilization of the oocytes and stagnation of early embryo development. By consulting the literature and tracking the results of previous similar research[6,7], we determined that maternal RNA and protein present in oocytes will still have an impact on embryo development after fertilized oocytes are formed, and maternal gene mutation may be one of the reasons for early embryo development stagnation[8]. We sequenced the whole exomes of the patient and her spouses and detected a mutation in the *TUBB8* gene [c.602G>T(p.C201F)] in the patient. The mutant gene was subsequently verified in the parents of the patient, and it was found that the *TUBB8* mutation was inherited from the father of the female patient.

The human β -tubulin family consists of nine β -tubulin isoforms[9], but *TUBB8* is the only gene specifically expressed in human oocytes and early embryos[4], and spindle assembly and chromosome separation are inseparable from their basic functions during meiosis and mitosis of early embryos[2]. The *TUBB8* gene is a highly conserved genotype that exists only in primates. Missense mutations of *TUBB8* may interfere with the maturation of human oocytes, which is a key prerequisite for fertilization and subsequent embryo development. To date, 109 unique *TUBB8* mutations have been reported, including 87 heterozygous mutations, 13 homozygous mutations and 9 compound heterozygous mutations, which exist in 8 families. According to these reports, *TUBB8* mutations account for approximately 31.96% of all cases of primary oocyte maturation stagnation[10], and different mutant genotypes are associated with different clinical phenotypes, including the following[11]: (1) Formation of fully developed immature oocytes; (2) formation of unfertilized MII oocytes; (3) formation of a fertilized oocyte that cannot be cleaved; and (4) stagnation of early embryo development,

including: (a) Oocytes that completely stagnate at the MI stage, (b) MII oocytes that cannot be fertilized, (c) fertilized oocytes that can be fertilized but the embryo does not cleave, and (d) embryos that can be fertilized and the embryo can cleave but then stagnate at the early stage to form embryos with a normal appearance but repeated implantation failures. Therefore, our results extend the mutation and phenotype spectrum of *TUBB8* in patients with oocyte maturation, fertilization and early embryonic development arrest. The heterozygous mutation of *TUBB8* described in this study c.602G>T(p.C201F) is a newly discovered variant, that has not been reported in previous literature. The clinical phenotype of this genotype is early embryonic development stagnation; that is, this mutation does not hinder the maturation and fertilization of oocytes, so we can see that this patient can form MII oocytes that can be fertilized and cleaved normally. However, the development of all the embryos stopped at the 2-8-cell stage, and they did not further develop into normal blastocysts, which was similar to the phenotypes of the mutations found by Yuan *et al*[6] and Jia *et al* [12]. Because the *TUBB8* gene plays an important role in the formation and assembly of spindles during oocyte meiosis, we speculate that the stagnation of early embryonic development in patients may be partially caused by defects in nuclear maturity[13].

There are two genetic modes of disease inheritance related to *TUBB8* gene mutations: autosomal dominant inheritance and autosomal recessive inheritance. To further explore the source of *TUBB8* mutations, we collected as much family gene information as possible. We tested the blood samples of the woman's parents (the patient was the only daughter), and it was verified that the patient's mutation was inherited from her father. Although dozens of pathogenic *TUBB8* gene mutations have been reported in the literature, there is still a lack of effective treatment methods. It has been reported that the duration of oocyte activation, the mode of calcium oscillation and calcium channel blockers affect the early embryonic development of mice[14-16]. Some studies have suggested that calcium supplementation may have a positive therapeutic effect on the embryonic development arrest caused by *TUBB8* gene mutation and ultimately overcome early embryonic development arrest[17]. Jia *et al*[12] proposed that intracellular injection of cDNA of the normal *TUBB8* gene can improve the spindle assembly of mouse cells, allowing the embryos to develop normally and enabling the birth of living offspring after injection; however the early embryo division mode of mice is different from that of humans, so there is still no experimental evidence to support the safety and effectiveness of intracellular injection of cDNA of the normal *TUBB8* gene into the human body. Therefore, for the treatment of patients, in view of the current medical means, the best choice is to use donated oocytes.

CONCLUSION

In summary, this study demonstrated that the *TUBB8* gene plays an important role in early human embryo development, and that mutation of this gene leads to early embryo development stagnation. In this patient, a novel *TUBB8* gene mutation, c.602G>T(p.C201F) was found, expanding the range of *TUBB8* gene mutations and providing new clues for genetic counseling, assisted reproductive risk prediction and optimization of the clinical treatment of infertility. This case also illustrates the importance of screening for *TUBB8* gene mutations in patients who have multicycle oocyte maturation disorder, fertilization failure or early embryo development stagnation.

ACKNOWLEDGEMENTS

We would like to thank all the patients and medical staff included in our study for their contributions to this work.

FOOTNOTES

Author contributions: Zhang XY contributed to study design and original draft preparation; Zhang XX contributed to data analysis and manuscript revision; Wang L contributed to supervision and critical review and final manuscript approval.

Supported by the Shandong Provincial Traditional Chinese Medicine Science and Technology Development Program, No. C-262; and the 2021 Science and Technology Innovation Research Project of Shandong Maternal and Child Health Association, No. 2021-19-24.

Informed consent statement: The patient provided written informed consent.

Conflict-of-interest statement: All authors have no competing interests to declare.

CARE Checklist (2016) statement: The authors have read the CARE Checklist (2016), and the manuscript was prepared and revised according to the CARE Checklist (2016).

Open-Access: This article is an open-access article that was selected by an in-house editor and fully peer-reviewed by external reviewers. It is distributed in accordance with the Creative Commons Attribution NonCommercial (CC BY-NC 4.0) license, which permits others to distribute, remix, adapt, build upon this work non-commercially, and license their derivative works on different terms, provided the original work is properly cited and the use is non-commercial. See: <https://creativecommons.org/licenses/by-nc/4.0/>

Country/Territory of origin: China

ORCID number: Lei Wang [0009-006-0198-2933](https://orcid.org/0009-006-0198-2933).

S-Editor: Liu JH

L-Editor: A

P-Editor: Zheng XM

REFERENCES

- 1 **Yatsenko SA**, Rajkovic A. Genetics of human female infertility†. *Biol Reprod* 2019; **101**: 549-566 [PMID: [31077289](#) DOI: [10.1093/biolre/iox084](#)]
- 2 **Yang P**, Yin C, Li M, Ma S, Cao Y, Zhang C, Chen T, Zhao H. Mutation analysis of tubulin beta 8 class VIII in infertile females with oocyte or embryonic defects. *Clin Genet* 2021; **99**: 208-214 [PMID: [33009822](#) DOI: [10.1111/cge.13855](#)]
- 3 **Beall S**, Brenner C, Segars J. Oocyte maturation failure: a syndrome of bad eggs. *Fertil Steril* 2010; **94**: 2507-2513 [PMID: [20378111](#) DOI: [10.1016/j.fertnstert.2010.02.037](#)]
- 4 **Feng R**, Sang Q, Kuang Y, Sun X, Yan Z, Zhang S, Shi J, Tian G, Luchniak A, Fukuda Y, Li B, Yu M, Chen J, Xu Y, Guo L, Qu R, Wang X, Sun Z, Liu M, Shi H, Wang H, Feng Y, Shao R, Chai R, Li Q, Xing Q, Zhang R, Nogales E, Jin L, He L, Gupta ML Jr, Cowan NJ, Wang L. Mutations in TUBB8 and Human Oocyte Meiotic Arrest. *N Engl J Med* 2016; **374**: 223-232 [PMID: [26789871](#) DOI: [10.1056/NEJMoa1510791](#)]
- 5 **Feng R**, Yan Z, Li B, Yu M, Sang Q, Tian G, Xu Y, Chen B, Qu R, Sun Z, Sun X, Jin L, He L, Kuang Y, Cowan NJ, Wang L. Mutations in TUBB8 cause a multiplicity of phenotypes in human oocytes and early embryos. *J Med Genet* 2016; **53**: 662-671 [PMID: [27273344](#) DOI: [10.1136/jmedgenet-2016-103891](#)]
- 6 **Yuan P**, Zheng L, Liang H, Li Y, Zhao H, Li R, Lai L, Zhang Q, Wang W. A novel mutation in the TUBB8 gene is associated with complete cleavage failure in fertilized eggs. *J Assist Reprod Genet* 2018; **35**: 1349-1356 [PMID: [29704226](#) DOI: [10.1007/s10815-018-1188-3](#)]
- 7 **Chen B**, Li B, Li D, Yan Z, Mao X, Xu Y, Mu J, Li Q, Jin L, He L, Kuang Y, Sang Q, Wang L. Novel mutations and structural deletions in TUBB8: expanding mutational and phenotypic spectrum of patients with arrest in oocyte maturation, fertilization or early embryonic development. *Hum Reprod* 2017; **32**: 457-464 [PMID: [27989988](#) DOI: [10.1093/humrep/dew322](#)]
- 8 **Mu J**, Wang W, Chen B, Wu L, Li B, Mao X, Zhang Z, Fu J, Kuang Y, Sun X, Li Q, Jin L, He L, Sang Q, Wang L. Mutations in NLRP2 and NLRP5 cause female infertility characterised by early embryonic arrest. *J Med Genet* 2019; **56**: 471-480 [PMID: [30877238](#) DOI: [10.1136/jmedgenet-2018-105936](#)]
- 9 **Sirajuddin M**, Rice LM, Vale RD. Regulation of microtubule motors by tubulin isotypes and post-translational modifications. *Nat Cell Biol* 2014; **16**: 335-344 [PMID: [24633327](#) DOI: [10.1038/ncb2920](#)]
- 10 **Wang AC**, Zhang YS, Wang BS, Zhao XY, Wu FX, Zhai XH, Sun JX, Mei SY. Mutation analysis of the TUBB8 gene in primary infertile women with arrest in oocyte maturation. *Gynecol Endocrinol* 2018; **34**: 900-904 [PMID: [29671363](#) DOI: [10.1080/09513590.2018.1464138](#)]
- 11 **Chen B**, Wang W, Peng X, Jiang H, Zhang S, Li D, Li B, Fu J, Kuang Y, Sun X, Wang X, Zhang Z, Wu L, Zhou Z, Lyu Q, Yan Z, Mao X, Xu Y, Mu J, Li Q, Jin L, He L, Sang Q, Wang L. The comprehensive mutational and phenotypic spectrum of TUBB8 in female infertility. *Eur J Hum Genet* 2019; **27**: 300-307 [PMID: [30297906](#) DOI: [10.1038/s41431-018-0283-3](#)]
- 12 **Jia Y**, Li K, Zheng C, Tang Y, Bai D, Yin J, Chi F, Zhang Y, Li Y, Tu Z, Wang Y, Pan J, Liang S, Guo Y, Ruan J, Kong P, Wu B, Hu Y, Wang H, Liu W, Teng X, Gao S. Identification and rescue of a novel TUBB8 mutation that causes the first mitotic division defects and infertility. *J Assist Reprod Genet* 2020; **37**: 2713-2722 [PMID: [32949002](#) DOI: [10.1007/s10815-020-01945-w](#)]
- 13 **Zhao L**, Guan Y, Wang W, Chen B, Xu S, Wu L, Yan Z, Li B, Fu J, Shi R, Shi J, Du J, Li Q, Zhang Z, Mu J, Zhou Z, Dong J, Jin L, He L, Sun X, Kuang Y, Wang L, Sang Q. Identification novel mutations in TUBB8 in female infertility and a novel phenotype of large polar body in oocytes with TUBB8 mutations. *J Assist Reprod Genet* 2020; **37**: 1837-1847 [PMID: [32524331](#) DOI: [10.1007/s10815-020-01830-6](#)]
- 14 **Saunders CM**, Larman MG, Parrington J, Cox LJ, Royse J, Blayney LM, Swann K, Lai FA. PLC zeta: a sperm-specific trigger of Ca(2+) oscillations in eggs and embryo development. *Development* 2002; **129**: 3533-3544 [PMID: [12117804](#) DOI: [10.1242/dev.129.15.3533](#)]
- 15 **Ozil JP**, Markoulaki S, Toth S, Matson S, Banrezes B, Knott JG, Schultz RM, Huneau D, Ducibella T. Egg activation events are regulated by the duration of a sustained [Ca2+]cyt signal in the mouse. *Dev Biol* 2005; **282**: 39-54 [PMID: [15936328](#) DOI: [10.1016/j.ydbio.2005.02.035](#)]
- 16 **He GF**, Yang LL, Luo SM, Ma JY, Ge ZJ, Shen W, Yin S, Sun QY. The role of L-type calcium channels in mouse oocyte maturation, activation and early embryonic development. *Theriogenology* 2017; **102**: 67-74 [PMID: [28750296](#) DOI: [10.1016/j.theriogenology.2017.07.012](#)]
- 17 **Fragouli E**, Wells D, Delhanty JD. Chromosome abnormalities in the human oocyte. *Cytogenet Genome Res* 2011; **133**: 107-118 [PMID: [21273765](#) DOI: [10.1159/000323801](#)]



Published by **Baishideng Publishing Group Inc**
7041 Koll Center Parkway, Suite 160, Pleasanton, CA 94566, USA

Telephone: +1-925-3991568

E-mail: office@baishideng.com

Help Desk: <https://www.f6publishing.com/helpdesk>

<https://www.wjgnet.com>

