

World Journal of *Clinical Cases*

World J Clin Cases 2023 November 6; 11(31): 7508-7740



Contents

Thrice Monthly Volume 11 Number 31 November 6, 2023

REVIEW

- 7508 Gut microbiome: New perspectives for type 2 diabetes prevention and treatment
Li SX, Guo Y

MINIREVIEWS

- 7521 Endoscopic management of benign biliary strictures: Looking for the best stent to place
Colombo M, Forcignanò E, Da Rio L, Spadaccini M, Andreozzi M, Giacchetto CM, Carrara S, Maselli R, Galtieri PA, Pellegatta G, Capogreco A, Massimi D, Khalaf K, Hassan C, Anderloni A, Repici A, Fugazza A
- 7530 Antibiotic resistance in patients with liver cirrhosis: Prevalence and current approach to tackle
Liakina V

ORIGINAL ARTICLE

Retrospective Study

- 7543 Analysis of risk factors for postoperative deep vein thrombosis after craniotomy and nomogram model construction
Su ZJ, Wang HR, Liu LQ, Li N, Hong XY
- 7553 Value of ultrasound and magnetic resonance imaging combined with tumor markers in the diagnosis of ovarian tumors
Yang Q, Zhang H, Ma PQ, Peng B, Yin GT, Zhang NN, Wang HB
- 7562 Measurement of combined flap thickness for reconstruction of decubitus ulcer using computed tomography
Kim EC, Park JD, Wee SY, Kim SY
- 7570 Does the advantage of transcutaneous oximetry measurements in diabetic foot ulcer apply equally to free flap reconstruction?
Lee DW, Hwang YS, Byeon JY, Kim JH, Choi HJ

Clinical Trials Study

- 7583 Effects of ulinastatin therapy in deep vein thrombosis prevention after brain tumor surgery: A single-center randomized controlled trial
Tao YN, Han Q, Jiao W, Yang LK, Wang F, Xue S, Shen M, Wang YH

Observational Study

- 7593 Network pharmacological and molecular docking study of the effect of Liu-Wei-Bu-Qi capsule on lung cancer
Yang Q, Li LY

- 7610** Efficacy of β 2-adrenergic receptor agonist combined with corticosteroid in the treatment of children with cough variant asthma

Cao JY, Wang YC, Deng XX

Randomized Controlled Trial

- 7619** Protective effect of sevoflurane on lung function of elderly chronic obstructive pulmonary disease patients undergoing total hip arthroplasty

Yao Y, Zhang MS, Li YB, Zhang MZ

CASE REPORT

- 7629** Sunitinib-induced hyperammonemic encephalopathy in metastatic gastrointestinal stromal tumors: A case report

Hayakawa T, Funakoshi S, Hamamoto Y, Hirata K, Kanai T

- 7635** Simultaneous lateral and subxiphoid access methods for safe and accurate resection of a superior vena cava aneurysm: A case report

Kim SP, Son J

- 7640** Ultrafast power Doppler imaging for ischemic encephalopathy: A case report

Huang LJ, Jiao JF, He Q, Luo JW, Guo Y

- 7647** Intermittent spontaneous ovulation in patients with premature ovarian failure: Three case reports and review of literature

Zhang WY, Wang HB, Deng CY

- 7656** Sneddon's syndrome concurrent with cerebral venous sinus thrombosis: A case report

Heng Y, Tang YF, Zhang XW, Duan JF, Shi J, Luo Q

- 7663** Carcinosarcoma of the deep lobe of the parotid gland in the parapharyngeal region: A case report

Tang YY, Zhu GQ, Zheng ZJ, Yao LH, Wan ZX, Liang XH, Tang YL

- 7673** Malignant peripheral nerve sheath tumor with hemophilic syndrome and bone marrow fibrosis: A rare case report

Li H, Wang L, Wu YH, Chen G, Li HX, Fan LF, Gu M, Jiang CH

- 7680** Comparison of drug concentrations in blood and gastric lavage fluid before and after gastric lavage: A case report

Zhou Y, Tong JL, Peng AH, Xu SY

- 7684** Recurred forehead osteoma disseminated after previous osteoma excision: A case report

Lee DY, Lim S, Yoon JS, Eo S

- 7690** Renal pelvis sarcomatoid carcinoma with renal vein tumor thrombus: A case report and literature review

Guan HY, Wang J, Wang JX, Chen QH, Lu J, He L

- 7699** Ultrasonographic identification of lateral femoral cutaneous nerve anatomical variation in persistent meralgia paresthetica: A case report

Park HW, Ji KS, Kim JH, Kim LN, Ha KW

- 7706** Biliary hemorrhage caused by a malignant small round cell tumor in the common bile duct: A case report
Jin YL, Ruan YJ, Lu GR
- 7712** Successive development of ischemic malignant strokes in a patient with multiple fusiform aneurysms: A case report
Shin DS, Yeo DK, Choi EJ
- 7718** Isolated axillary tumor deposit consistent with primary breast carcinoma: A case report
Li T, Zhang WH, Liu J, Mao YL, Liu S
- 7724** Multiple inflammatory pseudotumor formation after craniopharyngioma resection *via* an extended nasal endoscopic approach: A case report
Wu H, Ding YW, Yan ZC, Wei M, Wang XD, Zhang HZ
- 7732** Huge Bartholin's cyst managed by primary marsupialization: A case report
Li HY, Ding DC

LETTER TO THE EDITOR

- 7738** Do not forget diet and exercise during Ramadan
Ilias I, Tselebis A

ABOUT COVER

Editorial Board Member of *World Journal of Clinical Cases*, How-Ran Guo, DSc, MD, MSc, Full Professor, Department of Environmental and Occupational Health, College of Medicine, National Cheng Kung University, Tainan 70428, Taiwan. hrguo@mail.ncku.edu.tw

AIMS AND SCOPE

The primary aim of *World Journal of Clinical Cases* (*WJCC*, *World J Clin Cases*) is to provide scholars and readers from various fields of clinical medicine with a platform to publish high-quality clinical research articles and communicate their research findings online.

WJCC mainly publishes articles reporting research results and findings obtained in the field of clinical medicine and covering a wide range of topics, including case control studies, retrospective cohort studies, retrospective studies, clinical trials studies, observational studies, prospective studies, randomized controlled trials, randomized clinical trials, systematic reviews, meta-analysis, and case reports.

INDEXING/ABSTRACTING

The *WJCC* is now abstracted and indexed in Science Citation Index Expanded (SCIE, also known as SciSearch®), Journal Citation Reports/Science Edition, Current Contents®/Clinical Medicine, PubMed, PubMed Central, Reference Citation Analysis, China National Knowledge Infrastructure, China Science and Technology Journal Database, and Superstar Journals Database. The 2023 Edition of Journal Citation Reports® cites the 2022 impact factor (IF) for *WJCC* as 1.1; IF without journal self cites: 1.1; 5-year IF: 1.3; Journal Citation Indicator: 0.26; Ranking: 133 among 167 journals in medicine, general and internal; and Quartile category: Q4.

RESPONSIBLE EDITORS FOR THIS ISSUE

Production Editor: *Si Zhao*; Production Department Director: *Xiang Li*; Editorial Office Director: *Jin-Lei Wang*.

NAME OF JOURNAL

World Journal of Clinical Cases

ISSN

ISSN 2307-8960 (online)

LAUNCH DATE

April 16, 2013

FREQUENCY

Thrice Monthly

EDITORS-IN-CHIEF

Bao-Gan Peng, Salim Surani, Jerzy Tadeusz Chudek, George Kontogeorgos, Maurizio Serati

EDITORIAL BOARD MEMBERS

<https://www.wjgnet.com/2307-8960/editorialboard.htm>

PUBLICATION DATE

November 6, 2023

COPYRIGHT

© 2023 Baishideng Publishing Group Inc

INSTRUCTIONS TO AUTHORS

<https://www.wjgnet.com/bpg/gerinfo/204>

GUIDELINES FOR ETHICS DOCUMENTS

<https://www.wjgnet.com/bpg/GerInfo/287>

GUIDELINES FOR NON-NATIVE SPEAKERS OF ENGLISH

<https://www.wjgnet.com/bpg/gerinfo/240>

PUBLICATION ETHICS

<https://www.wjgnet.com/bpg/GerInfo/288>

PUBLICATION MISCONDUCT

<https://www.wjgnet.com/bpg/gerinfo/208>

ARTICLE PROCESSING CHARGE

<https://www.wjgnet.com/bpg/gerinfo/242>

STEPS FOR SUBMITTING MANUSCRIPTS

<https://www.wjgnet.com/bpg/GerInfo/239>

ONLINE SUBMISSION

<https://www.f6publishing.com>



Retrospective Study

Does the advantage of transcutaneous oximetry measurements in diabetic foot ulcer apply equally to free flap reconstruction?

Da Woon Lee, Yong Seon Hwang, Je Yeon Byeon, Jun Hyuk Kim, Hwan Jun Choi

Specialty type: Medicine, research and experimental

Provenance and peer review:

Unsolicited article; Externally peer reviewed.

Peer-review model: Single blind

Peer-review report's scientific quality classification

Grade A (Excellent): 0
Grade B (Very good): B, B
Grade C (Good): 0
Grade D (Fair): 0
Grade E (Poor): 0

P-Reviewer: Glumac S, Croatia;
Primadhi RA, Indonesia

Received: September 14, 2023

Peer-review started: September 14, 2023

First decision: September 19, 2023

Revised: September 25, 2023

Accepted: October 23, 2023

Article in press: October 23, 2023

Published online: November 6, 2023



Da Woon Lee, Yong Seon Hwang, Je Yeon Byeon, Jun Hyuk Kim, Hwan Jun Choi, Department of Plastic and Reconstructive Surgery, College of Medicine, Soonchunhyang University, Cheonan-si 31151, South Korea

Corresponding author: Hwan Jun Choi, MD, PhD, Professor, Surgeon, Department of Plastic and Reconstructive Surgery, College of Medicine, Soonchunhyang University, Suncheonhyang 6-gil 31, Dongnam-gu, Cheonan-si 31151, South Korea. iprskorea@gmail.com

Abstract

BACKGROUND

Transcutaneous oxygen pressure (T_{cp}O₂) is a precise method for determining oxygen perfusion in wounded tissues. The device uses either electrochemical or optical sensors.

AIM

To evaluate the usefulness of T_{cp}O₂ measurements on free flaps (FFs) in diabetic foot ulcers (DFUs).

METHODS

T_{cp}O₂ was measured in 17 patients with DFUs who underwent anterolateral thigh (ALT)-FF surgery and compared with 30 patients with DFU without FF surgery.

RESULTS

Significant differences were observed in the ankle-brachial index; duration of diabetes; and haemoglobin, creatinine, and C-reactive protein levels between the two groups. T_{cp}O₂ values were similar between two groups except on postoperative days 30 and 60 when the values in the ALT-FF group remained < 30 mmHg and did not increase > 50 mmHg.

CONCLUSION

Even if the flap is clinically stable, sympathectomy due to adventitia stripping during anastomosis and arteriovenous shunt progression due to diabetic polyneuropathy could lead to low T_{cp}O₂ values in the ALT-FF owing to its thick fat tissues, which is supported by the slow recovery of the sympathetic tone following FF. Therefore, T_{cp}O₂ measurements in patients with DFU who underwent FF reconstruction may be less accurate than in those who did not.

Key Words: Arteriovenous shunt; Surgical; Diabetic neuropathies; Free tissue flaps;

Sympathectomy; Blood gas monitoring; Transcutaneous; Diabetic angiopathies

©The Author(s) 2023. Published by Baishideng Publishing Group Inc. All rights reserved.

Core Tip: Transcutaneous oxygen pressure (TcPO₂) is measured low in free flap (FF) reconstruction for the following reasons. The flap itself is thick, making it difficult to accurately measure TcPO₂, the adventitia stripping that occurs during vessel anastomosis semi-permanently reducing the sympathetic tone of the entire vessel, and the arteriovenous shunt caused by performing FFs and the progression of diabetes, thought to occur. For this reason, long-term periodic TcPO₂ measurement is not useful when FF reconstruction is performed on diabetic foot ulcer.

Citation: Lee DW, Hwang YS, Byeon JY, Kim JH, Choi HJ. Does the advantage of transcutaneous oximetry measurements in diabetic foot ulcer apply equally to free flap reconstruction? *World J Clin Cases* 2023; 11(31): 7570-7582

URL: <https://www.wjgnet.com/2307-8960/full/v11/i31/7570.htm>

DOI: <https://dx.doi.org/10.12998/wjcc.v11.i31.7570>

INTRODUCTION

Free flap (FF) is a surgical procedure that involves transplanting a patient's own tissue to the recipient site, similar to free tissue transfer or transplantation. Among the preferred options for soft tissue reconstruction, anterolateral thigh FF (ALT-FF) is a popular surgical technique because of its high reliability and versatility, ease of harvest, and low donor-site morbidity. In addition, the redundancy of the thigh skin allows harvesting of a relatively large flap area to reconstruct the defect site[1].

Several devices are used for FF monitoring; however, no equipment guarantees flap survival[2]. Conventionally, flap monitoring includes skin warmth and color, capillary refill, and hand Doppler monitoring but is subjective and does not objectively guarantee flap survival. Proper blood flow is the most important factor in ensuring flap survival, and measuring tissue oxygen levels is the basis for ensuring proper circulation[3,4]. Oxygen plays an important role in the pathophysiological process of flap survival; therefore, quantifying oxygen concentration *in vivo* is important. In routine clinical settings, oximetry must be noninvasive, reliable, repeatable, and capable of directly measuring partial oxygen pressure. In particular, the instrument must be able to provide repeated measurements in the region of interest to monitor changes in oxygen tension during the observation period.

The measurement of transcutaneous oxygen pressure (TcPO₂) is a noninvasive and clinically approved method for measuring tissue perfusion. The necessary instrument was originally developed to measure the partial pressure of arterial oxygen and partial pressure of arterial carbon dioxide[5]. These electrodes contain heating coils that increase the temperature, thereby allowing a subsequent increase in integumentary tissue perfusion. The amount of oxygen was calculated from the amount of light absorbed[6]; TcPO₂ was quantitative and free of operator bias[7].

Diabetic foot ulcer (DFU) is one of the most catastrophic complications of diabetes, and peripheral artery disease (PAD) occurs as diabetic neuropathy progresses[8]. As the morbidity period of diabetes increases, sensory nerve function decreases, and wound healing is significantly delayed[9]. In this case, TcPO₂ was initially measured to determine the vascular status of DFU[10]. In patients with diabetes, TcPO₂ values are significantly lower than those in patients who are not, and studies have revealed that low TcPO₂ due to impaired tissue oxygenation may be the cause of DFUs[11,12]; perfusion disorders are indicated by a decrease in skin oxygenation before the appearance of clinical overt microangiopathy. The normal range of TcPO₂ metric value is approximately 60 mmHg regardless of electrode placement[13-15]. Moreover, TcPO₂ must be > 40 mmHg for adequate wound healing, and impaired wound healing occurs between 20 and 40 mmHg[16]. Additionally, wound healing generally fails when TcPO₂ values are < 20 mmHg[17]. In June 2007, the Trans-Atlantic Inter-Society Consensus suggested a standard TcPO₂ value > 30 mmHg for revascularization to prevent lower limb amputation[18,19].

Periodic measurement of TcPO₂ may predict the effects of DFU amputation and diabetic neuropathy treatment based on a decrease in its value[20-22]. Even when FF reconstruction is performed in DFU cases, vessel anastomosis is difficult owing to atherosclerosis, making the operation and surgical prognosis difficult to predict owing to impaired angiogenesis[23]. Therefore, research is required to determine the abovementioned advantages of TcPO₂ measurement when assessed periodically at the FF of the DFU for a longer period of time. In this study, we assumed that the reduced pattern of TcPO₂ would apply equally to FF reconstruction and we decided to conduct a study to determine whether the change in TcPO₂ levels would recover as wound healing occurred. Then, we intended to identify the numerical pattern of change in TcPO₂ and interpret its meaning as the FF was stabilized. Furthermore, we aimed to determine whether periodic TcPO₂ measurements are efficient for FF reconstruction in patients with DFU.

MATERIALS AND METHODS

Design

We retrospectively reviewed the records of patients who underwent FF reconstruction between 2021 and 2022 in Soonchunhyang Cheonan Hospital. The wounds of patients requiring FFs were all defective owing to DFU. All FFs were performed using ALT-FFs to minimize selection bias and unify results. ALT-FF was performed by three surgeons at a single institution. In addition to the FF group with DFU patients, a group of DFU patients who did not receive FFs was included to establish a control group.

Device

TcpO₂ was measured using the TCM400® (Radiometer Medical ApS, Copenhagen, Denmark) (Figure 1). The probes were placed at two locations, and measurements were subsequently performed. One location was the skin perforator of the flap, where the flap pedicle penetrated the skin, and the other was the most distal part of the flap (Figure 2). The contact liquid, supplied by the manufacturer, was applied to the retaining ring to secure the electroprobe. The electrode was measured for 10 min to obtain a stable plateau curve. In this study, the electroprobe setting temperature was adjusted to 41 °C. The room temperature was maintained between 18 °C and 24 °C in the same place before measurement.

Patients

In total, 22 records of patients with ALT-FF were obtained. Seventeen patients were included in this study after excluding the patients who dropped out and those with incomplete clinical databases. Thirty patients with DFU who did not undergo FF were included.

After the ALT-FF, TcpO₂ was measured on postoperative days (PODs) 1, 5, 10, 15, and 20 for short-term monitoring. Long-term monitoring was performed on PODs 30, 60, 90, and 180. The patients were divided into two groups, *i.e.*, short and long terms based on the measured POD. The changes in time and TcpO₂ value were then investigated. The location of the DFU was classified based on the angiosomes of the anterior tibial artery (ATA) and posterior tibial artery (PTA) in the group that did not receive FF; TcpO₂ was then subsequently measured (Figure 3). Clinical photographs were taken using an ILCE-7M4 (SONY, Tokyo, Japan) camera at a standard distance (40 cm) to assess the wounds and flaps.

Risk factor designation

Age, sex, glycosylated haemoglobin A, smoking history, preoperative ankle-brachial index (ABI) after hospitalisation, haemoglobin (Hb), creatinine (Cr), nephropathy, angiosome, duration of diabetes mellitus (DM), duration of hypertension (HTN), C-reactive protein (CRP), body mass index, and TcpO₂ values in the FF group and the group without FF were compared. These included variables identified as significant risk factors for DFU amputation in previous studies[24]. The TcpO₂ value of the FF group was based on the perforator when the flap was sufficiently stabilized on POD 30 compared with that of the control group.

Statistics

This study was performed using SPSS (version 26.0; IBM Corp., Armonk, NY, United States). Categorical variables were compared using Pearson's χ^2 , Fisher's exact, Student's *t*-, and Mann-Whitney *U* tests. Only variables with *P* < 0.05 were considered statistically significant.

RESULTS

Patient demographic characteristics

Based on the medical records, we reviewed 17 patients with DFU who received FFs (FF group) and 30 patients with DFU who did not receive FFs (DFU group). Table 1 presents the demographic characteristics of the FF and DFU groups. Several demographic risk factors were compared between the two groups. ABI, Hb, Cr, duration of DM, and CRP levels were significantly different between the two groups. The ABI group had a higher mean value than the FF group. The TcpO₂ value was 12.01 mmHg at POD 30 in the FF group and 14.50 mmHg in the DFU group, which was significantly low in both groups; no significant difference was noted between the two groups (*P* = 0.812).

In addition, the change in TcpO₂ value based on POD was investigated. A value < 10 mmHg was regarded as a 'very low' TcpO₂ value. On POD 30, ALT FF was successfully performed without complications, despite the very low TcpO₂ values in four patients (23.53%). The change in TcpO₂ value over time showed a significant difference for each POD in the FF group. A comparison of the perforator (branching off from vessels and extending into the skin and fat tissue) and distal portion of the flap based on POD showed no difference according to position (Table 2). However, a significant difference was observed when comparing the short- (until POD 20) and long-term (after POD 30) results through division. The short-term *P* value was 0.006, and the long-term *P* value was 0.002, showing significant changes as POD progressed. Upon short-term follow-up, a gradual increase was observed (Figure 4A), while upon long-term follow-up (POD 30 onwards), a gradual decrease was observed. A similar pattern was observed (Figure 4B). This pattern showed a similar trend in the perforator and distal portions of the flap. However, the TcpO₂ value was low (< 30 mmHg), except for PODs 30 and 60.

Table 1 Demographic characteristics of patients with diabetic foot ulcer with and without free flap

	Total (n = 47)	Free flap (n = 17)	DFU (n = 30)	P value
Sex				
Male	31 (65.96)	10 (58.82)	21 (70.00)	0.437
Female	16 (34.04)	7 (41.18)	9 (30.00)	
Age	61.36 ± 2.04	54.76 ± 3.62	65.10 ± 2.21	0.013
Smoking history				
Non-smoker	23 (48.94)	11 (64.71)	12 (40.00)	0.104
Smoker	24 (51.06)	6 (35.29)	18 (60.00)	
HbA1c	7.00 (6.00-9.10)	6.20 (5.60-9.00)	7.25 (6.10-9.20)	0.084
HTN				
None	17 (36.17)	9 (52.94)	8 (26.67)	0.072
HTN	30 (63.83)	8 (47.06)	22 (73.33)	
Nephropathy				
None	34 (72.34)	15 (88.24)	19 (63.33)	0.094
Nephropathy	13 (27.66)	2 (11.76)	11 (36.67)	
Angiosome				
ATA	26 (55.32)	7 (41.18)	19 (63.33)	0.138
PTA	21 (44.68)	10 (58.82)	11 (36.67)	
TcpO ₂	13.00 (6.00-22.00)	12.01 (8.01-15.01)	14.50 (6.00-22.00)	0.812
ABI				
Affected side	1.02 ± 0.03	1.14 ± 0.03	0.95 ± 0.05	0.002
Unaffected side	1.06 ± 0.03	1.13 ± 0.02	1.03 ± 0.04	0.024
Creatinine	1.07 (0.72-3.12)	0.74 (0.63-0.86)	1.98 (0.95-6.27)	0.001
Hb	11.10 ± 0.25	11.83 ± 0.31	10.68 ± 0.33	0.024
Duration of DM (yr)	10.00 (5.50-15.00)	3.00 (1.00-10.00)	13.50 (10.00-20.00)	< 0.001
Duration of HTN (yr)	10.50 (10.00-20.00)	11.00 (2.00-20.00)	10.00 (10.00-20.00)	0.666
CRP	11.24 (4.21-35.70)	3.50 (1.70-10.57)	27.78 (8.20-73.71)	< 0.001
BMI	23.96 ± 0.71	23.84 ± 1.28	24.03 ± 0.87	0.896

ABI: Ankle-brachial index; ATA: Anterior tibial artery; BMI: Body mass index; CRP: C-reactive protein; DFU: Diabetic foot ulcer; DM: Diabetes mellitus; Hb: Haemoglobin; HbA1c: Glycosylated haemoglobin A; HTN: Hypertension; TcpO₂: Transcutaneous oxygen pressure; PTA: Posterior tibial artery.

Treatments and outcomes

Case 1: A 61-year-old man presented with a necrotic DFU, 5 cm × 8 cm in size, on the dorsum of the left foot. The patient had been diagnosed with DM and HTN 20 years prior. The patient underwent reconstruction with an ALT-FF after removing the necrotic tissue and performing several debridements. End-to-end anastomosis was also performed on the dorsalis pedis artery and two vena comitans. Flap failure was not observed, and TcpO₂ was measured according to POD. Limb salvage was successfully performed, and no wound recurrence was noted until POD 360 (Figure 5).

Case 2: A 62-year-old man presented with multiple skin defects on the left ankle. The patient had been diagnosed with DM and HTN 3 years prior. The DFU was reconstructed with an ALT-FF after removing the necrotic tissue and performing several debridements. The end-to-side anastomosis was performed on the PTA; end-to-end anastomosis was performed on two vena comitans. Additionally, end-to-end anastomosis was performed in a flow-through manner (conserving vessels through performing end-to-end anastomosis on both sides of the recipient vessel) after identifying one dorsal recipient vein. Flap failure was not observed, and TcpO₂ was measured according to POD. Flap debulking was performed on POD 192 owing to discomfort during ankle joint movement. No wound recurrence was observed until POD 360 (Figure 6).

Table 2 Comparison of transcutaneous oxygen pressure values based on postoperative day in the group that received free flap

Value	Perforator	Distal	P value
POD 1	8.64 ± 10.72	8.27 ± 11.62	> 0.099
POD 5	18.64 ± 14.43	19.36 ± 16.11	> 0.99
POD 10	14.00 ± 16.35	16.73 ± 15.51	> 0.99
POD 15	13.82 ± 13.41	16.18 ± 13.40	> 0.99
POD 20	17.82 ± 18.21	31.00 ± 26.81	0.972
POD 30	45.86 ± 33.20	47.14 ± 23.13	> 0.99
POD 60	30.43 ± 21.95	35.57 ± 26.48	> 0.99
POD 90	18.71 ± 5.35	18.71 ± 17.37	> 0.99
POD 180	15.43 ± 11.10	19.57 ± 22.23	> 0.99
POD 360	12.86 ± 7.78	16.43 ± 13.78	> 0.99

POD: Postoperative day.



DOI: 10.12998/wjcc.v11.i31.7570 Copyright ©The Author(s) 2023.

Figure 1 Transcutaneous oxygen pressure measuring instrument (TCM400®).

DISCUSSION

In our study, the proportion of TcpO₂ levels in FFs that did not increase by more than 30 mmHg even after POD 30 was 35.3% (6/17). Before discussing, let us firstly mention the relationship between DFU and TcpO₂. Wound formation in DFU is mostly due to PAD, and there are several ways to examine the peripheral blood flow state[25]. TcpO₂, skin perfusion pressure, and fluorescence angiography were performed to identify regional tissue perfusion. The advantages and disadvantages of each device are listed in Table 3. The ABI is routinely used to screen for PAD. However, these results are less reliable in patients with diabetes with severe neuropathy and arterial calcification[34]. In such case, TcpO₂ may be helpful in predicting the risk of amputation and disease progression[35-37].

Various factors affect the measurement of TcpO₂. First, measurement of TcpO₂ is affected by the partial pressure of oxygen in the artery. TcpO₂ decreases in the presence of vascular injury and atherosclerosis[38]. Skin thickness also affects TcpO₂ measurements[39]. Therefore, thick fatty tissues and bones should be avoided. In addition, determining the area of good capillary phenomena remains achievable[40]. Finally, the temperature of the capillary under the measuring electroprobe also has an effect. The electroprobe for TcpO₂ uses heated metal electrodes placed directly on the skin. During the measurement, the skin temperature under the electrode increased by up to 44 °C, thereby dilating the blood vessels of the subdermal plexus and subsequently increasing the oxygen permeability.

Several limitations to TcpO₂ measurement have been noted during wound assessment. First, it requires a considerable amount of time for measurement, which lasts 10-15 min. Second, its sensitivity is low, although it does not cause pain to patients unlike the nerve conduction velocity method. Third, the presence of cellulitis or significant oedema in the tissue interferes with measurement[41]. Fourth, it reflects the state of blood flow only in parts of the skin and not in major blood vessels. Therefore, obtaining accurate values for thick tissues is difficult. Finally, TcpO₂ measurement is heavily

Table 3 Advantages and disadvantages of devices that determine blood flow status in diabetic foot ulcer

	Advantages	Limitations
Assessment of disease severity		
ABI (normal range 1.1-1.3)	Widely used, easy to measure	Unreliable in patients with severe PAD, DFU[26]
TBI (normal range 1.0-1.1)	Compensating for ABI limitations, easy to repeat measurement	Decreased accuracy at severe vessel calcification, limitation of diagnostic threshold[27]
Continuous wave Doppler	High accuracy in PAD diagnosis[28]	Decreased accuracy in DFU[28]
Pulse volume recording	Used in PAD diagnosis	Unable to determine exact location, many other variables [29]
Assessment of morphological distribution		
Duplex ultrasound	Noninvasive	Complemented by more detailed image required
Angiography	Detailed images can be provided, fast	Vulnerable to artifacts, risk for contrast nephropathy
Assessment of regional tissue perfusion		
TcpO ₂ (normal range 40-70 mmHg)	More sensitive than ABI	DFU, autonomic neuropathy, low accuracy for severe vascular calcification[12]
Skin perfusion pressure	Useful when ABI, TBI are not possible	Requires special equipment and further validation[30]
Fluorescence angiography	Low toxicity compared with angiography, good discriminatory ability[31]	Expensive, requires special equipment
Laser Doppler	Evaluate blood flux rather than blood flow	Vulnerable to motion artifacts and temperature changes, inter-operator variation
Hyperspectral imaging	Useful for determining the effect of DFU treatment	Lack of research on interpretation of results[32]
Molecular imaging		
PET and SPECT	High resolution	Expensive, requires special equipment
Contrast-enhanced ultrasound	Excellent for PAD discrimination[33]	Low accuracy for DFU[33]
Multi-modal MRI	Semi-quantitative evaluations based on relative patient conditions are possible	Take long time, no evidence of effectiveness for DFU

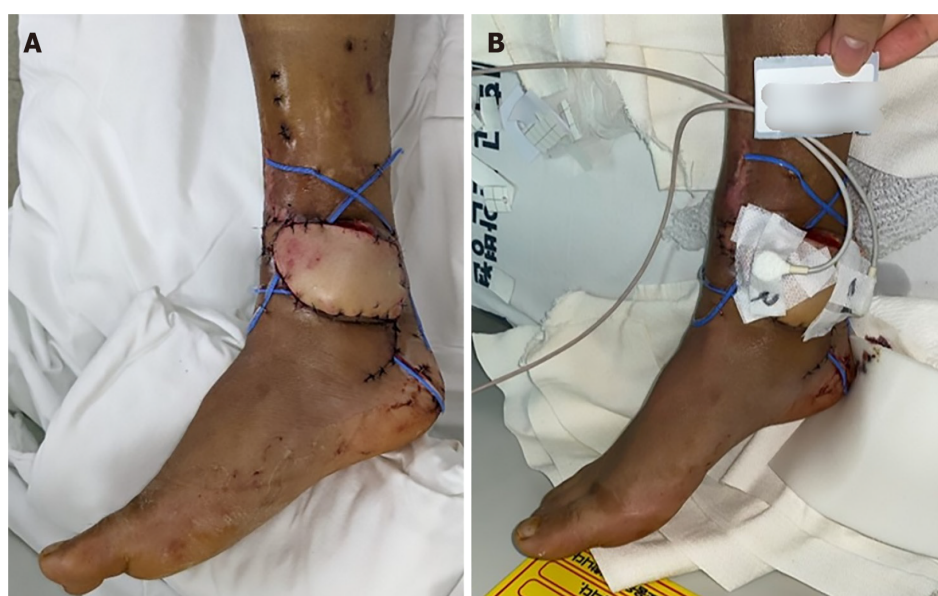ABI: Ankle-brachial index; DFU: Diabetic foot ulcer; MRI: Magnetic resonance imaging; PAD: Peripheral artery disease; PET: Positron emission tomography; SPECT: Single-photon emission computed tomography; TcpO₂: Transcutaneous oxygen pressure; TBI: Toe brachial index.

influenced by skin temperature. This measurement is possible only when skin perfusion is measured using a heated metal electrode.

According to our study, the percentage of TcpO₂ levels in FFs that did not increase > 30 mmHg, even after sufficient POD (POD 30), was 35.3% (6/17), which accounted for a fairly large percentage. No increase in the value was noted in these patients even though the flap thickness was significantly decreased. Almost all the TcpO₂ average values were < 30 mmHg except for PODs 30 and 60. In addition, the TcpO₂ value did not increase even though a significant temperature increase was observed when monitored with a thermometer. In addition, low TcpO₂ was measured regardless of which recipient artery (ATA or PTA) was used or whether the anastomosis method was end-to-end or end-to-side. Therefore, the following are reasons for the low TcpO₂ during measurement:

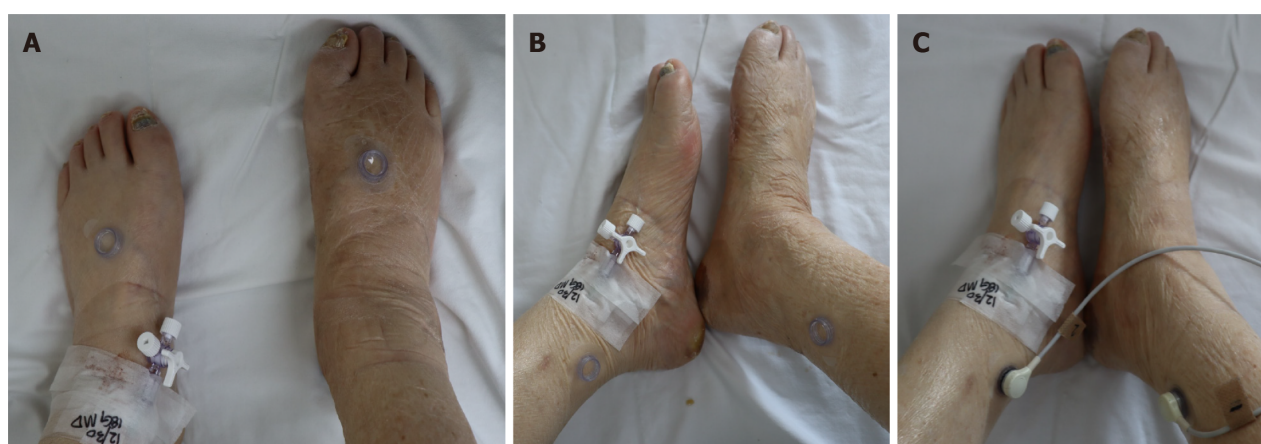First, mid-thigh tissue was used as the donor site in the case of ALT-FF performed in this study. The ALT-FF is usually at least 1-cm thick during flap elevation. The subcutaneous fat tissue of the thigh is thicker than the other tissues, making it difficult to accurately measure TcpO₂[42].

Second, since the electroprobe of TcpO₂ consumes oxygen during measurement, it is difficult to measure if the oxygen level that may present on the skin temperature is low. Moreover, the method is prone to calibration errors. In essence, the TcpO₂ value can be measured at 0 mmHg even if the skin flap has significant perfusion[6]. As the temperature of the electroprobe increased, the skin temperature also increased, thereby correcting the value of TcpO₂. However, in the FF of the DFU, the normal response of the flap skin temperature did not increase even when the electroprobe temperature increased. This may be due to insufficient sympathetic tone[43]. Moreover, this may also be due to the surgical removal of the arterial adventitia by many surgeons during artery anastomosis to prevent vasospasm[44]. Sympathetic innervation of the major vessels of the foot is most evident in the adventitia, which is the outermost layer of the artery (Figure 7)[45]. Nerve regeneration did not occur when a periarterial sympathectomy was performed. Based on these findings, the removal of the adventitia from the FF resulted in semi-permanent sympathetic nerve denervation. A significant TcpO₂ value could not be obtained if the dominance of the sympathetic nerve decreased and the temperature of the flap skin did not increase in response to the temperature of the sensor. Chao and Cheing[46] reported that when the sympathetic nerve



DOI: 10.12998/wjcc.v11.i31.7570 Copyright ©The Author(s) 2023.

Figure 2 A photographic image of transcutaneous oxygen pressure applied to an anterolateral thigh free flap patient. A: On postoperative day 1, free flap operation site surviving well; B: Place two probes on the skin perforator site (site marked 1 in the image) and the most distal part of flap (site marked 2 in the image), respectively.



DOI: 10.12998/wjcc.v11.i31.7570 Copyright ©The Author(s) 2023.

Figure 3 A photographic image of transcutaneous oxygen pressure applied to a diabetic foot ulcer patient without free flap reconstruction. A: Probe located in anterior tibial artery; B: Probe located in posterior tibial artery; C: Transcutaneous oxygen pressure measurement.

present in the adventitia is removed, the functions of the smooth muscle and endothelium, which are the vascular structures inside the adventitia, also decrease. Adventitial damage may result in extensive vascular insufficiency. In this study, the ABIs of the FF group were > 0.9 , and the average value was higher than that of the DFU group, regardless of whether a wound was present on the left or right side. This indicates that patients in the FF group did not have severe PAD or neuropathy compared with those in the DFU group. Nevertheless, the $TcpO_2$ value remains low even after a sufficient period of time. Thus, sympathectomy performed during anastomosis may not have been recoverable, and the recovery was insignificant. Furthermore, flap skin reperfusion was not restored. Additionally, if a low $TcpO_2$ value was observed even with a normal ABI, this finding suggested that diabetic neuropathy was caused by a decrease in sympathetic tone[47].

Third, as diabetic angiopathy progresses, an arteriovenous (AV) shunt develops in the peripheral blood vessels. The skin microcirculation consists of two horizontal plexus structures: The deeper subpapillary plexus and the superficial cutaneous plexus. Among these, the subpapillary plexus is responsible for more than 80% of blood flow[48]. Their actions are regulated by a complex interplay between neurogenic and neurovascular regulation[46]. Arteriovenous vessels have thicker walls and lower resistance than capillaries, allowing blood to flow at a relatively higher rate directly from the arterioles to the venules. In advanced DFU lesions, peripheral capillary resistance increases, and blood flow decreases owing to microvasculopathy caused by advanced diabetic polyneuropathy and vasodilation impairment. Therefore, AV shunting to the subpapillary system, which has a lower resistance than the capillaries, occurs more frequently than in the

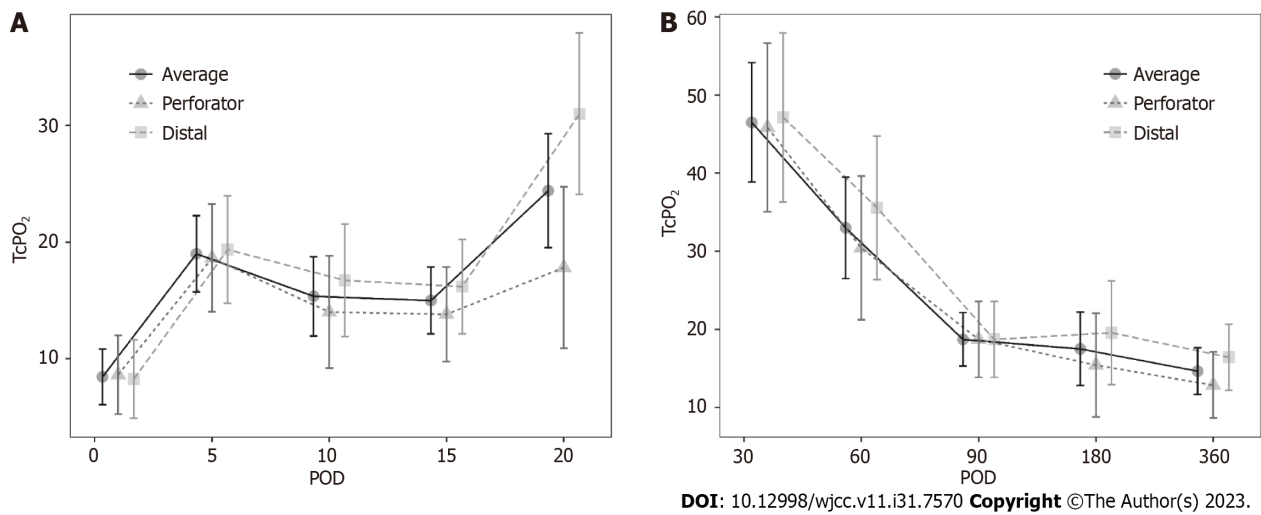
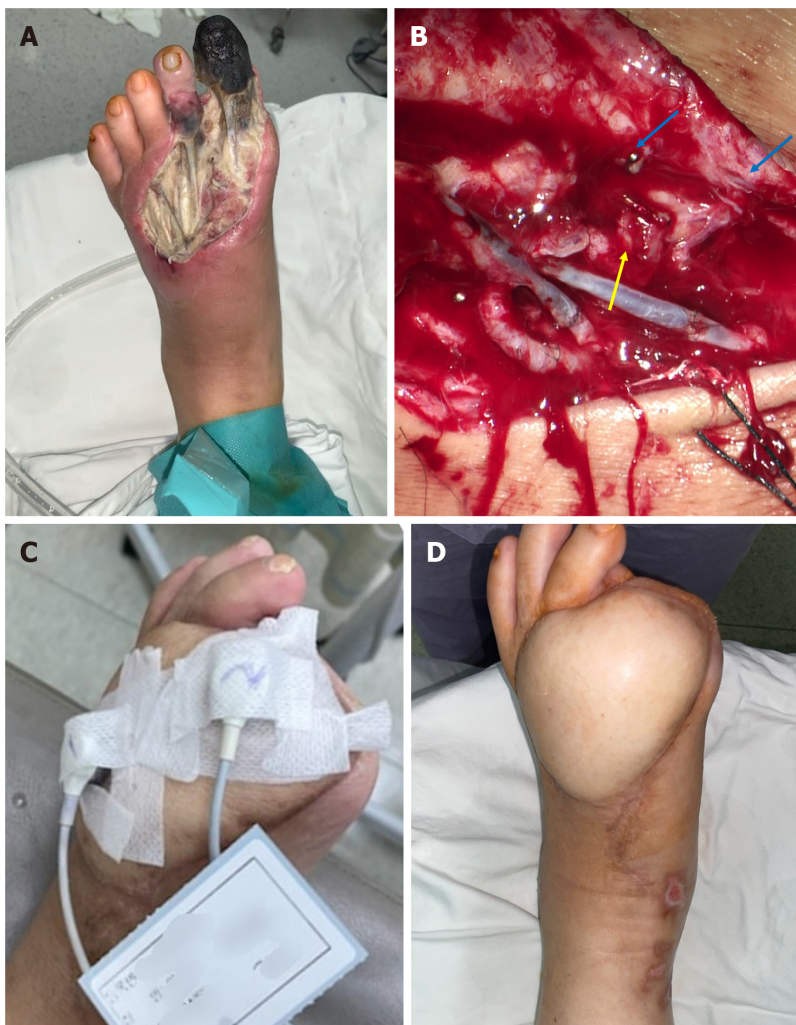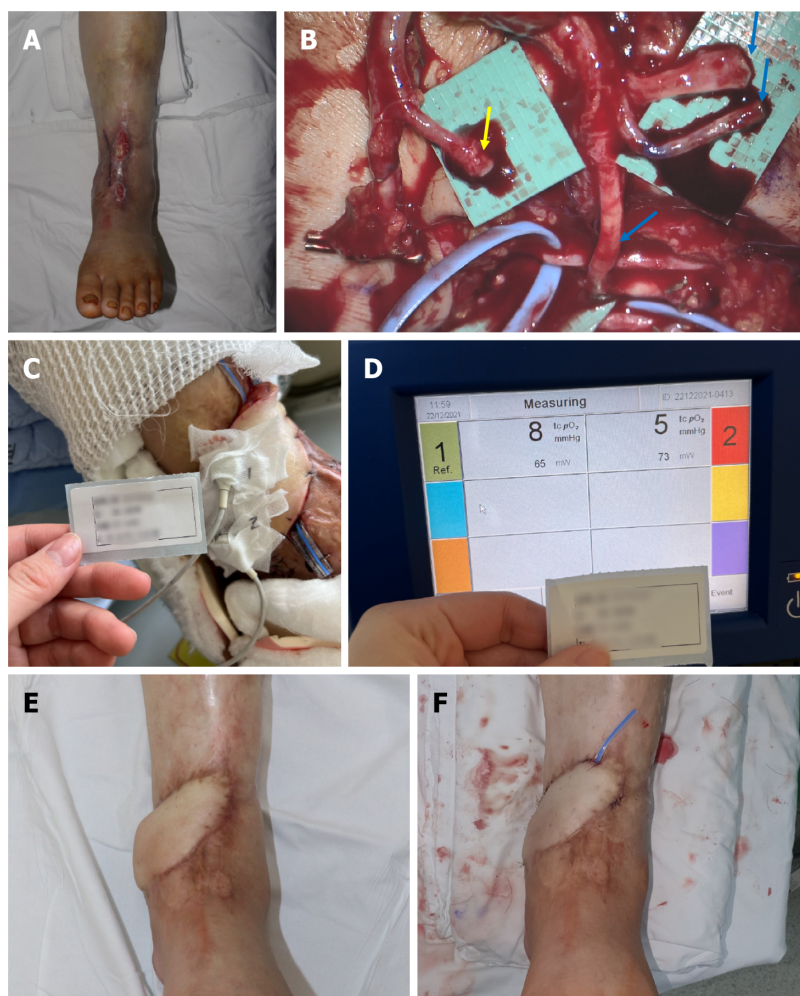


Figure 4 Change in transcutaneous oxygen pressure during the short-term and long-term period. A: Short-term period. Although the value is low, a gradual increasing pattern is observed; B: Long-term period. Although the value is low, a gradual decreasing trend is observed. POD: Postoperative day.



DOI: 10.12998/wjcc.v11.i31.7570 Copyright ©The Author(s) 2023.

Figure 5 Photographic findings of patient 1. A: Diabetic foot ulcer (DFU) on the left foot dorsum with necrotic tissue observed before debridement; B: One artery and two venae comitantes successfully undergo end-to-end anastomosis (yellow arrow: Artery, blue arrow: Vein); C: Transcutaneous oxygen pressure measured on postoperative day (POD) 30; D: Successfully reconstructed DFU wound on POD 360.



DOI: 10.12998/wjcc.v11.i31.7570 Copyright ©The Author(s) 2023.

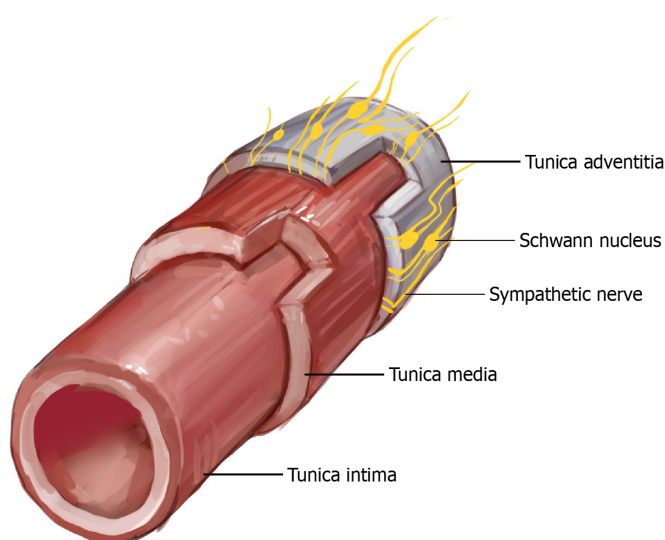
Figure 6 Photographic findings of patient 2. A: Preoperative findings, tendon, and periosteum exposed; B: The adventitia is stripped from the artery (yellow arrow), and the three veins are anastomosed (blue arrow); C and D: Transcutaneous oxygen pressure measured at postoperative day (POD) 1. Very low values of 8 and 5 mmHg are shown; E: Before flap debulking on POD 180; F: After flap debulking was performed on POD 192.

normal foot (Figure 8). Early venous enhancement occurs during the early inflammatory reaction of diabetic angiopathy, which supports the maldistribution of blood flow between the nutritional capillaries and subpapillary vessels, and the AV shunt caused by diabetic angiopathy occurs more peripherally[49]. An increased subpapillary AV shunt reduces the exchange of oxygen and metabolites between the capillaries and peripheral tissues, thus leading to ischemia and delayed wound healing. In this study, the FF group had an inadequate oxygen supply to the AV shunt and peripheral tissues. In addition, removal of the adventitia resulted in sympathectomy, whereas regeneration of the removed sympathetic nerve did not occur, resulting in failure to recover from the AV shunt. Even with flap operation, if blood flow was greater to the artery than before or after anastomosis, the theory that the AV shunt increases without the choke vessel opening would have been proven through cadaver and animal studies[50]. Thus, AV shunt can become more severe as diabetic angiopathy progresses. In summary, measuring TcpO₂ appropriately in FFs is difficult because of decreased sympathetic tone, malfunctioning vasculature, and AV shunting.

This study has a statistical limitation; it compared the data of only 17 patients with complete TcpO₂ values, which was insufficient to highlight the complete interpretation of the TcpO₂ numerical pattern. Measuring TcpO₂ at more frequent intervals is also necessary. Thus, a larger multi-institutional study with a larger number of patients is required. In addition, a prospective study may also be required to validate the effectiveness of the risk factors identified in our study for TcpO₂ pattern analysis. In particular, sympathectomy and AV shunt formation, which were suggested as the prime causes of low TcpO₂, require identification through additional experiments rather than proven only with TcpO₂ or ABI measurements.

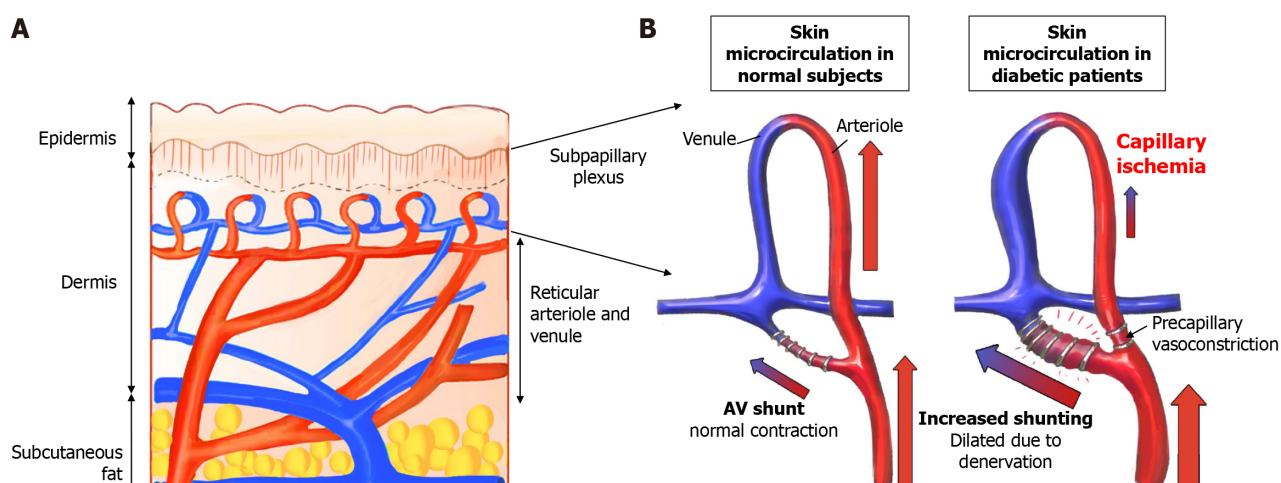
CONCLUSION

TcpO₂ helps assess the therapeutic effect and blood flow in patients with DFU and predicts vascular occlusion in FFs. However, when FF reconstruction was performed in patients with DFU, a successful flap was achieved even with low



DOI: 10.12998/wjcc.v11.i31.7570 Copyright ©The Author(s) 2023.

Figure 7 An illustration depicting intima, media, adventitia, and sympathetic innervation in a cross section of a vessel. Sympathetic nerves are mainly located in the outermost layer, the adventitia.



DOI: 10.12998/wjcc.v11.i31.7570 Copyright ©The Author(s) 2023.

Figure 8 Schematic illustration of the increase in a subpapillary arteriovenous shunt in diabetic patients. A: Cross-sectional structure of the skin; the subpapillary plexus is located in the lower layer of the epidermis; B: In a patient with diabetes, arteriovenous shunt is increased, and periphery blood flow is reduced.

TcpO₂; no significant increase in TcpO₂ was noted even after a long-term follow-up of > 1 year, which is thought to be owing to the thickness of the ALT-FF, sympathectomy owing to adventitia removal for intraoperative anastomosis, and diabetic AV shunt formation. TcpO₂ becomes low when sympathectomy was performed without regard to the presence of diabetic neuropathy. Therefore, TcpO₂ measurements in FFs after FF reconstruction may not be as useful as those with DFU who did not undergo FF reconstruction owing to the characteristics of FF operation and DFU.

ARTICLE HIGHLIGHTS

Research background

Patients with diabetes have lower transcutaneous oxygen pressure (TcpO₂) levels than those without diabetes, indicating that poor tissue oxygenation may lead to diabetic foot ulcers (DFUs). TcpO₂ measurements can help assess the risk of DFU amputation and the effectiveness of diabetic neuropathy treatment by showing changes in TcpO₂ levels.

Research motivation

Vessel anastomosis is challenging in free flap (FF) reconstruction for DFU cases because of atherosclerosis and narrowed vessel. Therefore, it is important to study the benefits of periodic TcpO₂ measurement at the FF site of the DFU for a longer period of time.

Research objectives

Our goal was to find out how TcpO₂ values changed over time and what it meant for the FF stability. We also wanted to see if TcpO₂ measurements were useful for FF reconstruction in DFU patients.

Research methods

We retrospectively reviewed the records of patients requiring FFs were all defective owing to DFU. In addition to the FF group with DFU patients, a group of DFU patients who did not receive FFs was included as a control group. We then examined how TcpO₂ value changed over time.

Research results

The FF group had higher levels of ankle-brachial index (ABI), haemoglobin, creatinine, diabetes mellitus duration, and C-reactive protein than the control group. Both groups had low TcpO₂ levels. TcpO₂ levels increased gradually in the short term, but decreased gradually in the long term (after postoperative day 30).

Research conclusions

There is no significant increase in TcpO₂ was noted even after a long-term follow-up of > 1 year. This may be due to the flap thickness, the sympathectomy from adventitia removal, and the diabetic arteriovenous (AV) shunts. Therefore, TcpO₂ measurements may not be very helpful for FF reconstruction in DFU patients, unlike in DFU patients who did not have FF reconstruction, because of the features of FF surgery and DFU.

Research perspectives

Future studies should measure TcpO₂ more frequently. A larger and multi-center study with more patients is needed. A prospective study may also confirm the risk factors we found for TcpO₂ pattern analysis. Especially, sympathectomy and AV shunt formation, which may cause low TcpO₂, need more experiments than just TcpO₂ or ABI measurements.

FOOTNOTES

Author contributions: Lee DW and Choi HJ contributed to the conceptualization and methodology of this study; Lee DW participated in the formal analysis, visualization, and writing-original draft preparation of this article; Byeon JY and Hwang YS involved in the investigation of this manuscript; Byeon JY and Kim JH contributed to the resources; Lee DW and Hwang YS participated in the data curation; Kim JH and Choi HJ contributed to the supervision; Choi HJ contributed to the project administration and funding acquisition; and all authors have read and agreed to the published version of the manuscript.

Supported by the National Research Foundation of Korea Grant funded by the Korean government (MSIT) (2020R1A2C1100891 and 2021R1G1A1008337); and the Soonchunhyang University Research Fund.

Institutional review board statement: The study protocol was approved by the Institutional Review Board (number:2022-12-043-003).

Informed consent statement: The patient provided informed consent for the publication.

Conflict-of-interest statement: All the authors report no relevant conflicts of interest for this article.

Data sharing statement: Data are available from the authors upon reasonable request.

Open-Access: This article is an open-access article that was selected by an in-house editor and fully peer-reviewed by external reviewers. It is distributed in accordance with the Creative Commons Attribution NonCommercial (CC BY-NC 4.0) license, which permits others to distribute, remix, adapt, build upon this work non-commercially, and license their derivative works on different terms, provided the original work is properly cited and the use is non-commercial. See: <https://creativecommons.org/licenses/by-nc/4.0/>

Country/Territory of origin: South Korea

ORCID number: Da Woon Lee 0000-0002-0266-8480; Yong Seon Hwang 0000-0001-6530-6973; Je Yeon Byeon 0000-0002-1948-0687; Hwan Jun Choi 0000-0002-0752-0389.

S-Editor: Wang JJ

L-Editor: A

P-Editor: Zhao S

REFERENCES

- 1 Lee JH, Choi HJ, Kwak SH, Lee DW, Tak MS, Kang JS. Anterolateral thigh free flaps with T-shaped pedicles and multiple venous anastomosis for extremity reconstruction. *Medicine (Baltimore)* 2021; **100**: e26575 [PMID: 34232203 DOI: 10.1097/MD.00000000000026575]
- 2 Furnas H, Rosen JM. Monitoring in microvascular surgery. *Ann Plast Surg* 1991; **26**: 265-272 [PMID: 2029137 DOI: 10.1097/0000637-199103000-00009]
- 3 Howell ST, Seaber AV, Urbaniak JR. Microcirculatory responses to vascular washout following ischemia. *Microsurgery* 1989; **10**: 264-268 [PMID: 2593795 DOI: 10.1002/micr.1920100403]
- 4 Carroll WR, Esclamado RM. Ischemia/reperfusion injury in microvascular surgery. *Head Neck* 2000; **22**: 700-713 [PMID: 11002326 DOI: 10.1002/1097-0347(200010)22:7<700::aid-hed10>3.0.co;2-h]
- 5 Hashimoto I, Nakanishi H, Takiwaki H, Takase MT, Yamano M, Sedo H. Flap monitoring by transcutaneous PO₂ and PCO₂: importance of transcutaneous PCO₂ in determining follow-up treatment for compromised free flaps. *J Reconstr Microsurg* 2007; **23**: 269-274 [PMID: 17876730 DOI: 10.1055/s-2007-985208]
- 6 Ballard JL, Bianchi C. Transcutaneous Oxygen Tension: Principles and Applications. In: AbuRahma AF, Bergan JJ. Noninvasive Vascular Diagnosis. London: Springer London, 2000: 403-409
- 7 Abe Y, Hashimoto I, Goishi K, Kashiwagi K, Yamano M, Nakanishi H. Transcutaneous PCO₂ Measurement at Low Temperature for Reliable and Continuous Free Flap Monitoring: Experimental and Clinical Study. *Plast Reconstr Surg Glob Open* 2013; **1**: 1-8 [PMID: 25289213 DOI: 10.1097/GOX.0b013e3182936cd0]
- 8 Yazdanpanah L, Nasiri M, Adarvishi S. Literature review on the management of diabetic foot ulcer. *World J Diabetes* 2015; **6**: 37-53 [PMID: 25685277 DOI: 10.4239/wjdv6.i1.37]
- 9 Ashcroft GS, Horan MA, Ferguson MW. The effects of ageing on cutaneous wound healing in mammals. *J Anat* 1995; **187**: 1-26 [PMID: 7591970]
- 10 Ladurner R, Küper M, Königsrainer I, Löb S, Wichmann D, Königsrainer A, Coerper S, Beckert S. Predictive value of routine transcutaneous tissue oxygen tension (tcpO₂) measurement for the risk of non-healing and amputation in diabetic foot ulcer patients with non-palpable pedal pulses. *Med Sci Monit* 2010; **16**: CR273-CR277 [PMID: 20512089]
- 11 Boyko EJ, Ahroni JH, Stensel V, Forsberg RC, Davignon DR, Smith DG. A prospective study of risk factors for diabetic foot ulcer. The Seattle Diabetic Foot Study. *Diabetes Care* 1999; **22**: 1036-1042 [PMID: 10388963 DOI: 10.2337/diacare.22.7.1036]
- 12 Williams DT, Price P, Harding KG. The influence of diabetes and lower limb arterial disease on cutaneous foot perfusion. *J Vasc Surg* 2006; **44**: 770-775 [PMID: 16930928 DOI: 10.1016/j.jvs.2005.06.040]
- 13 Cina C, Katsamouris A, Megerman J, Brewster DC, Strayhorn EC, Robison JG, Abbott WM. Utility of transcutaneous oxygen tension measurements in peripheral arterial occlusive disease. *J Vasc Surg* 1984; **1**: 362-371 [PMID: 6481885 DOI: 10.1067/mva.1984.avs0010362]
- 14 Clyne CA, Ryan J, Webster JH, Chant AD. Oxygen tension of the skin of ischemic legs. *Am J Surg* 1982; **143**: 315-318 [PMID: 7065353 DOI: 10.1016/0002-9610(82)90099-x]
- 15 Hauser CJ, Shoemaker WC. Use of a transcutaneous PO₂ regional perfusion index to quantify tissue perfusion in peripheral vascular disease. *Ann Surg* 1983; **197**: 337-343 [PMID: 6830339 DOI: 10.1097/0000658-198303000-00014]
- 16 Ruangsetakit C, Chinsakchai K, Mahawongkajit P, Wongwanit C, Mutirangura P. Transcutaneous oxygen tension: a useful predictor of ulcer healing in critical limb ischaemia. *J Wound Care* 2010; **19**: 202-206 [PMID: 20505593 DOI: 10.12968/jowc.2010.19.5.48048]
- 17 Quigley FG, Faris IB. Transcutaneous oxygen tension measurements in the assessment of limb ischaemia. *Clin Physiol* 1991; **11**: 315-320 [PMID: 1914435 DOI: 10.1111/j.1475-097x.1991.tb00660.x]
- 18 Norgren L, Hiatt WR, Dormandy JA, Nehler MR, Harris KA, Fowkes FG, Rutherford RB, TASC II Working Group. Inter-society consensus for the management of peripheral arterial disease. *Int Angiol* 2007; **26**: 81-157 [PMID: 17489079]
- 19 Faglia E, Clerici G, Caminiti M, Quarantiello A, Curci V, Morabito A. Predictive values of transcutaneous oxygen tension for above-the-ankle amputation in diabetic patients with critical limb ischemia. *Eur J Vasc Endovasc Surg* 2007; **33**: 731-736 [PMID: 17296318 DOI: 10.1016/j.ejvs.2006.12.027]
- 20 Iino K, Yoshinari M, Doi Y, Shinohara N, Iwase M, Fujishima M. Reduced tissue oxygenation and its reversibility by glycemic control in diabetic patients. *Diabetes Res Clin Pract* 1997; **34**: 163-168 [PMID: 9069568 DOI: 10.1016/s0168-8227(96)01349-6]
- 21 McNeely MJ, Boyko EJ, Ahroni JH, Stensel VL, Reiber GE, Smith DG, Pecoraro RF. The independent contributions of diabetic neuropathy and vasculopathy in foot ulceration. How great are the risks? *Diabetes Care* 1995; **18**: 216-219 [PMID: 7729300 DOI: 10.2337/diacare.18.2.216]
- 22 Berli MC, Wanivenhaus F, Kabelitz M, Götschi T, Böni T, Rancic Z, Waibel FWA. Predictors for reoperation after lower limb amputation in patients with peripheral arterial disease. *Vasa* 2019; **48**: 419-424 [PMID: 31063045 DOI: 10.1024/0301-1526/a000796]
- 23 Valentini V, Cassoni A, Marianetti TM, Mitro V, Gennaro P, Ialongo C, Iannetti G. Diabetes as main risk factor in head and neck reconstructive surgery with free flaps. *J Craniofac Surg* 2008; **19**: 1080-1084 [PMID: 18650736 DOI: 10.1097/SCS.0b013e3181763531]
- 24 Lee DW, Kwak SH, Kim JH, Choi HJ. Prediction of diabetic foot amputation using newly revised DIRECT coding system: Comparison of accuracy with that of five existing classification systems. *Int Wound J* 2023; **20**: 359-371 [PMID: 35811359 DOI: 10.1111/iwj.13884]
- 25 Forsythe RO, Hinchliffe RJ. Assessment of foot perfusion in patients with a diabetic foot ulcer. *Diabetes Metab Res Rev* 2016; **32** Suppl 1: 232-238 [PMID: 26813616 DOI: 10.1002/dmrr.2756]
- 26 Boyko EJ, Ahroni JH, Davignon D, Stensel V, Pigeon RL, Smith DG. Diagnostic utility of the history and physical examination for peripheral vascular disease among patients with diabetes mellitus. *J Clin Epidemiol* 1997; **50**: 659-668 [PMID: 9250264 DOI: 10.1016/s0895-4356(97)00005-x]
- 27 Hoyer C, Sandermann J, Petersen LJ. The toe-brachial index in the diagnosis of peripheral arterial disease. *J Vasc Surg* 2013; **58**: 231-238 [PMID: 23688630 DOI: 10.1016/j.jvs.2013.03.044]
- 28 Williams DT, Harding KG, Price P. An evaluation of the efficacy of methods used in screening for lower-limb arterial disease in diabetes. *Diabetes Care* 2005; **28**: 2206-2210 [PMID: 16123491 DOI: 10.2337/diacare.28.9.2206]
- 29 Lewis JE, Owens DR. The pulse volume recorder as a measure of peripheral vascular status in people with diabetes mellitus. *Diabetes Technol Ther* 2010; **12**: 75-80 [PMID: 20082588 DOI: 10.1089/dia.2009.0061]
- 30 Yamada T, Ohta T, Ishibashi H, Sugimoto I, Iwata H, Takahashi M, Kawanishi J. Clinical reliability and utility of skin perfusion pressure measurement in ischemic limbs--comparison with other noninvasive diagnostic methods. *J Vasc Surg* 2008; **47**: 318-323 [PMID: 18241755 DOI: 10.1016/j.jvs.2007.10.045]

- 31 **Perry D**, Bharara M, Armstrong DG, Mills J. Intraoperative fluorescence vascular angiography: during tibial bypass. *J Diabetes Sci Technol* 2012; **6**: 204-208 [PMID: [22401340](#) DOI: [10.1177/193229681200600125](#)]
- 32 **Jeffcoate WJ**, Clark DJ, Savic N, Rodmell PI, Hinchliffe RJ, Musgrove A, Game FL. Use of HSI to measure oxygen saturation in the lower limb and its correlation with healing of foot ulcers in diabetes. *Diabet Med* 2015; **32**: 798-802 [PMID: [25864911](#) DOI: [10.1111/dme.12778](#)]
- 33 **Thomas KN**, Cotter JD, Lucas SJ, Hill BG, van Rij AM. Reliability of contrast-enhanced ultrasound for the assessment of muscle perfusion in health and peripheral arterial disease. *Ultrasound Med Biol* 2015; **41**: 26-34 [PMID: [25308937](#) DOI: [10.1016/j.ultrasmedbio.2014.06.012](#)]
- 34 **Beutner F**, Teren A, Gielen S, Schuler G, Wirkner K, Tiller D, Loeffler M, Scholz M. Automated photoplethysmography-based determination of ankle-brachial index: a validation study against Doppler sonography. *Clin Res Cardiol* 2012; **101**: 875-883 [PMID: [22584382](#) DOI: [10.1007/s00392-012-0471-z](#)]
- 35 **Gazzaruso C**, Coppola A, Falcone C, Luppi C, Montalcini T, Baffero E, Gallotti P, Pujia A, Solerte SB, Pelissero G, Giustina A. Transcutaneous oxygen tension as a potential predictor of cardiovascular events in type 2 diabetes: comparison with ankle-brachial index. *Diabetes Care* 2013; **36**: 1720-1725 [PMID: [23404303](#) DOI: [10.2337/dc12-1401](#)]
- 36 **Gernigon M**, Marchand J, Ouedraogo N, Leftheriotis G, Piquet JM, Abraham P. Proximal ischemia is a frequent cause of exercise-induced pain in patients with a normal ankle to brachial index at rest. *Pain Physician* 2013; **16**: 57-64 [PMID: [23340534](#)]
- 37 **Pardo M**, Alcaraz M, Bernal FL, Felices JM, Achel GD, Canteras M. Transcutaneous oxygen tension measurements following peripheral transluminal angioplasty procedure has more specificity and sensitivity than ankle brachial index. *Br J Radiol* 2015; **88**: 20140571 [PMID: [25431933](#) DOI: [10.1259/bjr.20140571](#)]
- 38 **Matsen FA 3rd**, Wyss CR, Robertson CL, Oberg PA, Holloway GA. The relationship of transcutaneous PO₂ and laser Doppler measurements in a human model of local arterial insufficiency. *Surg Gynecol Obstet* 1984; **159**: 418-422 [PMID: [6495138](#)]
- 39 **de Meijer VE**, Van't Sant HP, Spronk S, Kusters FJ, den Hoed PT. Reference value of transcutaneous oxygen measurement in diabetic patients compared with nondiabetic patients. *J Vasc Surg* 2008; **48**: 382-388 [PMID: [18572360](#) DOI: [10.1016/j.jvs.2008.03.010](#)]
- 40 **Lamah M**, Mortimer PS, Dormandy JA. Quantitative study of capillary density in the skin of the foot in peripheral vascular disease. *Br J Surg* 1999; **86**: 342-348 [PMID: [10201776](#) DOI: [10.1046/j.1365-2168.1999.01039.x](#)]
- 41 **Ballard JL**, Eke CC, Bunt TJ, Killeen JD. A prospective evaluation of transcutaneous oxygen measurements in the management of diabetic foot problems. *J Vasc Surg* 1995; **22**: 485-90; discussion 490 [PMID: [7563410](#) DOI: [10.1016/s0741-5214\(95\)70018-8](#)]
- 42 **Luo S**, Raffoul W, Luo J, Luo L, Gao J, Chen L, Egloff DV. Anterolateral thigh flap: A review of 168 cases. *Microsurgery* 1999; **19**: 232-238 [PMID: [10413789](#) DOI: [10.1002/\(sici\)1098-2752\(1999\)19:5<232::aid-micr5>3.0.co;2-s](#)]
- 43 **Vetrugno R**, Liguori R, Cortelli P, Montagna P. Sympathetic skin response: basic mechanisms and clinical applications. *Clin Auton Res* 2003; **13**: 256-270 [PMID: [12955550](#) DOI: [10.1007/s10286-003-0107-5](#)]
- 44 **Turin SY**, Walton RL, Dumanian GA, Hijawi JB, LoGiudice JA, Alghoul M. Current Practices in the Management of Postoperative Arterial Vasospasm in Microsurgery. *J Reconstr Microsurg* 2018; **34**: 242-249 [PMID: [29284164](#) DOI: [10.1055/s-0037-1612601](#)]
- 45 **Dellon AL**, Höke A, Williams EH, Williams CG, Zhang Z, Rosson GD. The sympathetic innervation of the human foot. *Plast Reconstr Surg* 2012; **129**: 905-909 [PMID: [22456362](#) DOI: [10.1097/PRS.0b013e3182450be8](#)]
- 46 **Chao CY**, Cheing GL. Microvascular dysfunction in diabetic foot disease and ulceration. *Diabetes Metab Res Rev* 2009; **25**: 604-614 [PMID: [19681035](#) DOI: [10.1002/dmrr.1004](#)]
- 47 **Deng W**, Dong X, Zhang Y, Jiang Y, Lu D, Wu Q, Liang Z, Yang G, Chen B. Transcutaneous oxygen pressure (TcPO₂): a novel diagnostic tool for peripheral neuropathy in type 2 diabetes patients. *Diabetes Res Clin Pract* 2014; **105**: 336-343 [PMID: [25023217](#) DOI: [10.1016/j.diabres.2014.05.012](#)]
- 48 **Flynn MD**, Edmonds ME, Tooke JE, Watkins PJ. Direct measurement of capillary blood flow in the diabetic neuropathic foot. *Diabetologia* 1988; **31**: 652-656 [PMID: [3234641](#) DOI: [10.1007/bf00278747](#)]
- 49 **Byeon JY**, Kwak SH, Choi HJ, Kim JH, Lee DW. Clinical significance of early venous enhancement on CT angiography of the ischemic lower limbs. *Medicine (Baltimore)* 2022; **101**: e30560 [PMID: [36181004](#) DOI: [10.1097/MD.00000000000030560](#)]
- 50 **Gascoigne AC**, Taylor GI, Corlett RJ, Briggs C, Ashton MW. Increasing Perfusion Pressure Does Not Distend Perforators or Anastomoses but Reveals Arteriovenous Shuntings. *Plast Reconstr Surg Glob Open* 2020; **8**: e2857 [PMID: [32766035](#) DOI: [10.1097/GOX.0000000000002857](#)]



Published by **Baishideng Publishing Group Inc**
7041 Koll Center Parkway, Suite 160, Pleasanton, CA 94566, USA

Telephone: +1-925-3991568

E-mail: bpgoffice@wjgnet.com

Help Desk: <https://www.f6publishing.com/helpdesk>

<https://www.wjgnet.com>

