


World Journal of *Gastroenterology*

World J Gastroenterol 2019 July 28; 25(28): 3664-3837



**EDITORIAL**

- 3664** Role of sodium-glucose co-transporter-2 inhibitors in the management of nonalcoholic fatty liver disease
Kontana A, Tziomalos K

OPINION REVIEW

- 3669** Importance of fatigue and its measurement in chronic liver disease
Gerber LH, Weinstein AA, Mehta R, Younossi ZM
- 3684** Acute kidney injury spectrum in patients with chronic liver disease: Where do we stand?
Chancharoenthana W, Leelahavanichkul A

REVIEW

- 3704** Neoadjuvant and adjuvant treatment strategies for hepatocellular carcinoma
Akateh C, Black SM, Conteh L, Miller ED, Noonan A, Elliott E, Pawlik TM, Tsung A, Cloyd JM
- 3722** Surgical techniques and postoperative management to prevent postoperative pancreatic fistula after pancreatic surgery
Kawaida H, Kono H, Hosomura N, Amemiya H, Itakura J, Fujii H, Ichikawa D

MINIREVIEWS

- 3738** Current approaches to the management of patients with cirrhotic ascites
Garbuzenko DV, Arefyev NO
- 3753** Pyrrolizidine alkaloids-induced hepatic sinusoidal obstruction syndrome: Pathogenesis, clinical manifestations, diagnosis, treatment, and outcomes
Yang XQ, Ye J, Li X, Li Q, Song YH

ORIGINAL ARTICLE**Basic Study**

- 3764** Novel technique for endoscopic *en bloc* resection (EMR+) - Evaluation in a porcine model
Meier B, Wannhoff A, Klinger C, Caca K
- 3775** MiR-205 mediated APC regulation contributes to pancreatic cancer cell proliferation
Qin RF, Zhang J, Huo HR, Yuan ZJ, Xue JD

Case Control Study

- 3787** Comparison of outcomes between complete and incomplete congenital duodenal obstruction
Gfroerer S, Theilen TM, Fiegel HC, Esmaeili A, Rolle U

Retrospective Study

- 3798** Effect of low-dose aspirin administration on long-term survival of cirrhotic patients after splenectomy: A retrospective single-center study
Du ZQ, Zhao JZ, Dong J, Bi JB, Ren YF, Zhang J, Khalid B, Wu Z, Lv Y, Zhang XF, Wu RQ

Prospective Study

- 3808** Comparison of the use of wireless capsule endoscopy with magnetic resonance enterography in children with inflammatory bowel disease
Hijaz NM, Attard TM, Colombo JM, Mardis NJ, Friesen CA

SYSTEMATIC REVIEWS

- 3823** Systematic review of nutrition screening and assessment in inflammatory bowel disease
Li S, Ney M, Eslamparast T, Vandermeer B, Ismond KP, Kroeker K, Halloran B, Raman M, Tandon P

ABOUT COVER

Editorial board member of *World Journal of Gastroenterology*, Rakesh Kumar Tandon, MD, PhD, Doctor, Professor, Department of Gastroenterology, Pushpawati Singhanian Research Institute for Liver, Renal and Digestive Diseases, Sheikh Sarai-Phase II, New Delhi 110017, Delhi, India

AIMS AND SCOPE

World Journal of Gastroenterology (*World J Gastroenterol*, *WJG*, print ISSN 1007-9327, online ISSN 2219-2840, DOI: 10.3748) is a peer-reviewed open access journal. The *WJG* Editorial Board consists of 701 experts in gastroenterology and hepatology from 58 countries.

The primary task of *WJG* is to rapidly publish high-quality original articles, reviews, and commentaries in the fields of gastroenterology, hepatology, gastrointestinal endoscopy, gastrointestinal surgery, hepatobiliary surgery, gastrointestinal oncology, gastrointestinal radiation oncology, etc. The *WJG* is dedicated to become an influential and prestigious journal in gastroenterology and hepatology, to promote the development of above disciplines, and to improve the diagnostic and therapeutic skill and expertise of clinicians.

INDEXING/ABSTRACTING

The *WJG* is now indexed in Current Contents®/Clinical Medicine, Science Citation Index Expanded (also known as SciSearch®), Journal Citation Reports®, Index Medicus, MEDLINE, PubMed, PubMed Central, and Scopus. The 2019 edition of Journal Citation Report® cites the 2018 impact factor for *WJG* as 3.411 (5-year impact factor: 3.579), ranking *WJG* as 35th among 84 journals in gastroenterology and hepatology (quartile in category Q2). CiteScore (2018): 3.43.

RESPONSIBLE EDITORS FOR THIS ISSUE

Responsible Electronic Editor: Yan-Liang Zhang

Proofing Production Department Director: Yun-Xiaojuan Wu

NAME OF JOURNAL

World Journal of Gastroenterology

ISSN

ISSN 1007-9327 (print) ISSN 2219-2840 (online)

LAUNCH DATE

October 1, 1995

FREQUENCY

Weekly

EDITORS-IN-CHIEF

Subrata Ghosh, Andrzej S. Tarnawski

EDITORIAL BOARD MEMBERS

<http://www.wjgnet.com/1007-9327/editorialboard.htm>

EDITORIAL OFFICE

Ze-Mao Gong, Director

PUBLICATION DATE

July 28, 2019

COPYRIGHT

© 2019 Baishideng Publishing Group Inc

INSTRUCTIONS TO AUTHORS

<https://www.wjgnet.com/bpg/gerinfo/204>

GUIDELINES FOR ETHICS DOCUMENTS

<https://www.wjgnet.com/bpg/GerInfo/287>

GUIDELINES FOR NON-NATIVE SPEAKERS OF ENGLISH

<https://www.wjgnet.com/bpg/gerinfo/240>

PUBLICATION MISCONDUCT

<https://www.wjgnet.com/bpg/gerinfo/208>

ARTICLE PROCESSING CHARGE

<https://www.wjgnet.com/bpg/gerinfo/242>

STEPS FOR SUBMITTING MANUSCRIPTS

<https://www.wjgnet.com/bpg/GerInfo/239>

ONLINE SUBMISSION

<https://www.f6publishing.com>



Prospective Study

Comparison of the use of wireless capsule endoscopy with magnetic resonance enterography in children with inflammatory bowel disease

Nadia Mazen Hijaz, Thomas Mario Attard, Jennifer Marie Colombo, Neil Joseph Mardis, Craig Alan Friesen

ORCID number: Nadia M Hijaz (0000-0001-6678-8871); Thomas M Attard (0000-0002-7480-4437); Jennifer M Colombo (0000-0002-0550-8255); Neil J Mardis (0000-0003-4728-5851); Craig A Friesen (0000-0002-5871-0967).

Author contributions: Hijaz NM has designed the research study under the guidance of Attard TM and Colombo JM. Hijaz NM supervised the recruitment, safety and timed performance of every single aspect of study procedures. Hijaz NM has collected, processed, computed and summarized all the data. Attard TM and Colombo JM have participated in the capsule endoscopy reading of the study. Mardis NJ has participated in reading the magnetic resonance imaging of the study. Hijaz NM, Attard TM, Friesen CA analyzed the data statistically. Hijaz NM wrote the paper and then revised with guidance of Attard TA, Colombo JM, Friesen CA and Mardis NJ.

Supported by the donation of wireless Small bowel capsule and patency capsules from Giving imaging, Ltd Medtronic company with the funding agreement from Given investigator-initiated study No. 13-12.

Institutional review board statement: The study was reviewed and approved by the institutional review boards of Children's Mercy Hospital Pediatric Institutional Review Board, IRB #13080263.

Nadia Mazen Hijaz, Thomas Mario Attard, Jennifer Marie Colombo, Neil Joseph Mardis, Craig Alan Friesen, Division of Gastroenterology Hepatology and Nutrition, University of Missouri Kansas City, Children's Mercy Hospital Kansas City, Kansas City, MO 64108, United States

Corresponding author: Nadia Mazen Hijaz, MD, Assistant Professor, Doctor, Division of Gastroenterology Hepatology and Nutrition, University of Missouri Kansas City, Children's Mercy Hospital Kansas City, 2401 Gillham Road, Kansas City, MO 64108, United States. nmhijaz@cmh.edu

Telephone: +1-816-3023400

Fax: +1-816-3029735

Abstract

BACKGROUND

Magnetic resonance enterography (MRE) and wireless capsule endoscopy (WCE) are equally accepted modalities for noninvasive screening of small bowel involvement (SBI) in children with Crohn's disease (CD) and indeterminate colitis (IC) albeit there is a paucity of data comparing the two and thereby guiding the clinician in selecting the ideal diagnostic approach. Therefore, the goal of this study is to provide additional evidence for capsule endoscopy role in the evaluation of established Crohn's disease exacerbation compared to MRE in relation to Pediatric Crohn's Disease Activity Index (PCDAI), and histological indices.

AIM

To prospectively compare the findings of MRE and WCE and their agreement with PCDAI or histology in children with CD or IC.

METHODS

Consecutive patients diagnosed with CD and IC were screened for inclusion. After informed consent, patient's demographic and clinical data was abstracted. The current pediatric disease activity index (PCDAI) and endoscopic findings were included. Patients underwent MRE and WCE including preprocedural patency capsule within a maximum of 7 d of each other. Pathological presence of active small bowel disease in ileal and duodenal biopsies were collected if the endoscopy was performed within 2 mo of the WCE study. Patients who failed to pass the PC were excluded from the study. WCE was read by two different experienced gastroenterologists (Attard TM and Colombo JM) blinded to each other's findings and to the findings on MRE (Mardis NJ). Agreement between

Clinical trial registration statement:

The clinical trial is registered with ClinicalTrials.gov, using identifier NCT02182947. Details can be found at <https://clinicaltrials.gov/ct2/show/NCT02182947>.

Informed consent statement: All study participants, or their legal guardian, provided written consent prior to study enrollment.

Conflict-of-interest statement: All authors of this manuscript have no conflict of interest to disclose.

Data sharing statement: There is no additional data available.

CONSORT 2010 statement: Not applicable.

Open-Access: This is an open-access article that was selected by an in-house editor and fully peer-reviewed by external reviewers. It is distributed in accordance with the Creative Commons Attribution Non Commercial (CC BY-NC 4.0) license, which permits others to distribute, remix, adapt, build upon this work non-commercially, and license their derivative works on different terms, provided the original work is properly cited and the use is non-commercial. See: <http://creativecommons.org/licenses/by-nc/4.0/>

Manuscript source: Invited manuscript

Received: March 22, 2019

Peer-review started: March 22, 2019

First decision: April 16, 2019

Revised: May 4, 2019

Accepted: July 5, 2019

Article in press: July 5, 2019

Published online: July 28, 2019

P-Reviewer: Hosoe N, Rath T

S-Editor: Ma RY

L-Editor: A

E-Editor: Zhang YL



WCE reviewers, WCE and MRE findings and concordance between positive PCDAI and SBI based on MRE compared with WCE was computed.

RESULTS

Forty-five patients were included in the study, 18 withdrew and 27 (20 males and 20 CD), mean age (standard deviation) 13.46 (2.4) years, completed the study protocol. There were no instances of capsule retention. Concordance between gastroenterologist reviewers was excellent for the diagnosis of small intestinal CD with good correlation between the two Lewis scores ($r = 0.875$, $P < 0.001$). Concordance between WCE and MRE was poor (69%). In CD patients, when both MRE and WCE were compared using PCDAI > 10 as the standard reference reflecting active small intestinal CD, the sensitivity of MRE and WCE were 100% and 83% respectively and the specificity of MRE and WCE were 57.14% and 78.6%, respectively. If the histology in ileum or/and duodenum was used as the reference for active small bowel involvement, WCE had a higher specificity as compared to MRE (83.3% *vs* 50%). In patients with Crohn's disease, those with a positive PCDAI (> 10) were more likely to have a positive WCE as compared to those with a negative PCDAI (83% *vs* 21%; $P = 0.018$).

CONCLUSION

We suggest that MRE and WCE have a complementary role in the assessment of SBI in CD. WCE detected SBI with a much higher specificity while MRE had a higher sensitivity.

Key words: Crohn's disease; Wireless capsule endoscopy; Inflammatory bowel disease; Magnetic resonance enterography; Small bowel involvement; Small bowel disease; Indeterminate colitis; Pediatric; Children

©The Author(s) 2019. Published by Baishideng Publishing Group Inc. All rights reserved.

Core tip: There are a number of prospective adult studies and few in pediatrics comparing magnetic resonance imaging (MRE) to wireless capsule endoscopy (WCE) in identifying small bowel (SB) Crohn's disease (CD) that showed no significant difference in the diagnostic yield and accuracy of MRE and WCE in established non-stricturing Crohn's disease or suspected and established CD together. This study is the first prospective study in children with established inflammatory bowel disease in the United States assessing and comparing the roles of MRE and WCE in identifying SB disease involvement in relation to clinical and histological indices.

Citation: Hijaz NM, Attard TM, Colombo JM, Mardis NJ, Friesen CA. Comparison of the use of wireless capsule endoscopy with magnetic resonance enterography in children with inflammatory bowel disease. *World J Gastroenterol* 2019; 25(28): 3808-3822

URL: <https://www.wjgnet.com/1007-9327/full/v25/i28/3808.htm>

DOI: <https://dx.doi.org/10.3748/wjg.v25.i28.3808>

INTRODUCTION

Crohn's disease (CD) is a chronic inflammatory disorder primarily involving the gastrointestinal tract. Although any part of the gastrointestinal tract may be involved, proximal small intestinal involvement is more common in pediatric patients than in adult patients with a prevalence of up to 20% [1]. The effects of small intestinal involvement in CD are variable and may include obscure abdominal pain, nutritional sequelae resulting in growth delay, iron deficiency anemia, stricture formation, and potentially small bowel obstruction [1,2]. Proximal small bowel (SB) involvement in CD is associated with a more aggressive disease course and an increased need for surgery [3,4]. Therefore, accurate determination of SB involvement (SBI) in pediatric CD is crucial for optimal patient management [3,4].

Current clinical guidelines include suggested modalities to identify SBI and determine management plans [5]. Available options include small bowel series, computed tomography enterography (CTE), small bowel wireless capsule endoscopy (WCE), gadolinium enhanced magnetic resonance imaging (GAD MRI), and small

bowel contrast enhanced ultrasound (US). The choice of modality is largely determined by available resources, radiation exposure risk, physician and institutional preferences. MRE and contrast enhanced US are radiation free, while other radiologic modalities entail a risk of radiation exposure^[6]. WCE may entail a risk of capsule retention. The risk of capsule retention resulting in obstruction is increased in the context of stricturing or fistulizing disease in CD and has been estimated at 2.6%^[7] but may be greatly mitigated by patency capsule screening^[8]. Magnetic resonance enterography (MRE) and small intestine contrast ultrasound (SICUS) have diagnostic effectiveness comparable to other radiological modalities for evaluation of CD patients^[1,2,9]. However, both studies have their own limitations. MRE is limited by expense, the availability of the requisite equipment and software, variable expertise in interpretation of the findings, and (potentially) the need for sedation in pediatric population. SICUS is similarly affected by being operator dependent with the requisite need of accumulated expertise and heightened need for cooperation during the study that can limit its use in pediatric populations^[10].

Other diagnostic modalities have been evaluated in comparison to WCE in several pediatric and adult inflammatory bowel disease (IBD) studies. [Table 1](#) summarizes the adult and pediatric studies comparing different modalities to WCE. The studies conducted in children with IBD were mostly retrospective and aimed at evaluating the role of MRE and WCE for detection of SB disease. They concluded that MRE and WCE were comparable with similar sensitivities^[11]. Only three prospective studies (all European) in pediatric IBD have compared WCE and MRE modalities in identifying SB disease involvement. Two were studies in established CD^[9,12] and one in suspected CD^[13] and again, they suggested that the tests appear complementary for detection of active CD. The current study is the first prospective study in children with established IBD in the United States assessing the roles of MRE and WCE in identifying SB disease involvement in IBD. This study provides evidence for capsule endoscopy role in the evaluation of established disease exacerbation in patients with IBD in relation to MRE.

The primary goals of this study are to prospectively compare the diagnostic yield, concordance rate, sensitivity and specificity between MRE and WCE findings and their agreement with the Pediatric Crohn's Disease Activity Index (PCDAI) or with histological small bowel involvement in children with known IBD; CD or IC. Secondary goals are to assess the performance of each of the modalities (MRE, WCE and PCDAI) in relation to each other in order predict the results of the compared tests and to assess the correlation between Lewis capsule endoscopy score and PCDAI.

MATERIALS AND METHODS

Patient selection

This study was a prospective single blinded comparison study of a cohort of pediatric patients with established indeterminate colitis (IC) or CD at a tertiary referral pediatric IBD center. The diagnosis of CD was confirmed by using widely validated clinical, endoscopic, and histological criteria. The study was approved by the ethics committee of the hospital IRB #13080263 and written informed assent/consent was obtained from all children and their parents. Study participants were enrolled if they were 4-18 years of age inclusive with an established diagnosis of IC or CD and planned to have an MRE as part of standard of care. Patients were excluded if they had recent intestinal tract surgery, resection involving small bowel, gastrointestinal obstruction or ileus, swallowing disorders, esophageal stricture, nonsteroidal anti-inflammatory drugs or prokinetic medication use in the 4 wk prior to enrollment, inability to swallow the capsule, or if they had an electro-medical device or pacemaker. Demographic and clinical data were recorded including subject demographics, medical and surgical history, imaging results, initial disease presentation, and patient current clinical status which was used to calculate the PCDAI. The PCDAI score is considered positive (active disease) if ≥ 10 and negative (inactive disease) if < 10 ([Table 2](#)).

Patency capsule

All patients swallowed a patency capsule (PC; size 11 mm \times 26 mm) to assess small bowel patency. All patients with confirmed passage of PC in the first 40 h underwent WCE (PillcamTM SB Capsule, Given Imaging Ltd, Israel 11 mm \times 26 mm) within 1 wk of completion of MRE. Patients excluded from the study if they failed to swallow or pass the PC. WCE was read by two different experienced gastroenterologists, each with > 10 years of experience (Attard TM and Colombo JM) blinded to each other's findings and to the findings on MRE (Mardis NJ). The PCDAI was recorded from the

Table 1 Summary of studies comparing imaging modalities to capsule endoscopy

Author /year / type	Country	Age group/ total No.	Patient population	Modalities compared to CE	Results
Albert 2005 ^[14]	Germany	Adults/52	Established and suspected CD	MRE	Diagnostic yield of WCE is superior to MRE (+ve MRE 32/52 <i>vs</i> +ve WCE 25/27)
Golder 2006 prospective ^[15]	Germany	Adults/16	Established CD	MRE	Diagnostic yield of WCE is similar to that of MRE (+ve MRE 9/15 <i>vs</i> +ve WCE 11/15), but the WCE is superior in detecting proximal SB disease
Tillack 2008 prospective ^[16]	Germany	Adults/19	Established CD	MRE	Diagnostic yield of WCE is similar to that of MRE (+ve MRE 18/19 <i>vs</i> +ve WCE 18/19) but the WCE is superior in detecting proximal SB disease
Dionisio 2010 prospective Metanalysis ^[17]	Europe, Canada, Israel and United States	All ages/ 428	Established and suspected CD	CTE and SBFT and MRE	Diagnostic yield of WCE is superior to that of CTE and SBR in suspected CD but it is similar to MRE in suspected and established CD
Crook 2009 prospective ^[18]	Switzerland	Adults/5	Suspected CD	MRE	Diagnostic yield of WCE is similar to that of MRE and complementary to each other
Bocker 2010 prospective ^[19]	Germany	Adults/21	Established and suspected CD	MRE	Diagnostic yield of WCE is similar to that of MRE (+ve MRE 6/21 <i>vs</i> +ve WCE 9/21) but the WCE is superior in detecting proximal SB disease
Jensen 2011 prospective ^[20]	Denmark	Adults/93	Established and suspected CD	MRE	Diagnostic yield of WCE is similar to that of MRE(+ve MRE 24/80 <i>vs</i> +ve WCE 22/80) but the WCE is superior in detecting proximal SB disease
Wiarda 2011 prospective ^[21]	The Netherlands	Adults/38	Established and suspected CD	MRE	Diagnostic yield of WCE is similar that of MRE (+ve MRE 16/38 <i>vs</i> +ve WCE 6/25)
Kopylov 2015 prospective ^[22]	Israel	Adults/77	Established CD	MRE	Diagnostic yield of WCE is similar to that of MRE (+ve MRE 40/52 <i>vs</i> +ve WCE 42/52) but the WCE is superior in detecting proximal SB disease
Gonzalez Suarez 2017 retrospective ^[23]	Spain	Adults/47	Established and suspected CD	MRE	WCE is superior to MRE in detection of small bowel lesions mainly proximal(+ve WCE 36/47 <i>vs</i> +ve MRE 21/47)
Di Nardo 2010 prospective ^[24]	Italy	Peds/117	Established and suspected CD	MRI and SICUS	reclassifying indeterminate colitis (IC) into CD (60%), detection of CD lesions in known CD (41%) and establishing new diagnosis in suspected CD (50%)

Casciani 2011 prospective ^[13]	Italy	Peds/60	suspected CD	MRE	Diagnostic yield of WCE is similar to that of MRE (+ve MRE 19/37 vs +ve WCE 10/60)
Gralnek 2012 prospective ^[25]	Israel	Peds /18	Established and suspected CD	No studies compared	
Kovanlikaya 2013 ^[11] retrospective	United States	Peds/23	Established and suspected CD	MRE	Sensitivity of MRE 75% was similar to WCE 77.8%
Aloi 2015 prospective ^[9]	Italy	Peds/25	Established and suspected CD	MRE and SICUS	Diagnostic yield of WCE is similar to that of MRE and SICUS (+ve MRE 15/25 vs +ve SICUS 16/25 vs +ve WCE 16/25) but the WCE is superior in detecting proximal SB disease
Oliva 2016 prospective ^[12]	Italy	Peds/38	Established CD	MRE and SICUS	Diagnostic yield of WCE is similar to that of MRE and SICUS (+ve MRE 19/38 vs +ve WCE 19/38 vs +ve SICUS 21/38) but the CCE is superior in detecting proximal SB disease

WCE: Wireless capsule endoscopy; CCE: Colon capsule endoscopy; SBR: Small bowel radiography; CTE: Computed tomography enterography; MRE: Magnetic resonance enterography; SICUS: Small intestinal contrast ultrasonography; CD: Crohn's disease; IC: Indeterminate colitis; Peds: Pediatric; +ve: Positive.

most recent medical chart and laboratory data. Blood samples for hemoglobin and hematocrit, erythrocyte sedimentation rate, C-reactive protein (CRP), and albumin were collected within 7 d if these labs were not obtained in the last 2 wk prior to WCE.

MRE

MRE examinations were performed as a standard of care by using a whole body magnetic resonance imaging unit (Children's Mercy Hospital, Kansas City, MO, United States) with an 8-channel abdominal phased-array coil. A benefiber dissolved in liquid with weight-based dosing was used as the intraluminal oral contrast agent. Intravenous contrast was administered to reduce SB peristalsis and to prolong luminal distention. Axial and coronal T1 weighted images with fat suppression were performed. When the distention quality was inadequate, images were reobtained 30 minutes after the ingestion of a more appropriate dose for age of fiber water solution. Axial T2, axial diffusion and coronal true cine images were obtained.

One radiologist retrospectively reviewed the MRE for all subjects to provide a consistent assessment of the extent of SB activity for each subject. Patients with a MRE score of >3 were considered to have positive MRE study^[20]. The score was modified in this study to exclude counting colonic segment involvement in the overall radiological score (maximum score is 13). Evaluated findings included SB wall thickness (0-3 mm or 3-6 mm, > 6mm), SB wall enhancement after intravenous contrast media (none, mild or severe), mucosal and serosal enhancement suggestive of mesenteric fatty infiltration, strictures (defined as luminal narrowing to be less than 10 mm), increased mesenteric vascularity close to the inflamed bowel loop, mesenteric lymphadenopathy, the presence of fistula, stricture or abscess and the number of SB segments involved (duodenal, jejunal and ileal)^[9]. MRE score used is provided in [supplemental material](#).

WCE

The capsule images were independently interpreted by two gastroenterologists with > 10 years of experience in capsule studies. To optimize the visualization of the jejunum and ileum of the CE, after an overnight fast, patients ingested Polyethylene Glycol 3350 PEG before they swallowed the capsule (PEG doses adjusted based on age: 34 g in 480 mL clear liquid if age of the subject was < 5 year, 51 g in 720 mL if 5-10 years, 68 g in 960 mL if >10 years). The CE used in this study was the PillCam™ SB video capsule (Given Imaging, Medtronic Ltd, Yokneam, Israel). It measures 11 mm × 26 mm and it weighs less than 4 g. This capsule was ingested orally in all patients except for one patient who was scheduled to have endoscopy on the same day, so the capsule was deployed by esophagogastroduodenoscopy. Capsule retention is defined as a

Table 2 Highlights baseline characteristics of patient's demographics and clinical and endoscopic descriptions

	All patients CD and IC <i>n</i> = 27	CD <i>n</i> = 20
Age at diagnosis year	13.46 (2.40)	13.48 (2.02)
Male %	74%	75%
Medications ratio (%)		
Biological alone or combination therapy	12/27 (44.4%)	11/20 (55%)
Immune modulators with no biologic combination	8/27 (30%)	5/20 (25%)
5 ASA +/- steroids	4/27 (15%)	3/20 (15%)
Steroids alone	2/27 (7%)	0/20 (0%)
Antibiotic alone	1/27 (4%)	1/20 (5%)
Phenotype%		
Inflammatory	93%	93%
Strictureing	7%	7%
Duration of disease year	1.7 (2.32)	2.1 (2.57)
BMI percentile	57 (32.9)	58.18 (35.83)
PCDAI	10.2 (12.5)	9.8 (11.6)
SB transit time min	233 (115.4)	241(184.99)
Days between MRE and WCE days	4.19 (1.88)	4 (1.90)

Baseline characteristics of all patients expressed in mean (SD) and the ratio (percentage). CD Crohn's disease, IC indeterminate colitis, ASA amino salicylate, SB small bowel, BMI body mass index, MRE magnetic resonance enterography, PCDAI pediatric Crohn's disease activity index WCE wireless capsule endoscopy.

failure of the passage of the capsule from the gastrointestinal tract for ≥ 2 wk^[20]. The examination was incomplete if the capsule did not reach the cecum by the end of the study. Images were considered as negative (or inactive) if no abnormalities were seen and as positive (or active) if clear abnormalities of the SB mucosa (ulcerations > 3 , erosions, polyps, vascular lesions, and bleeding lesions were seen). White lesions within a crater with surrounding erythema were considered ulcers, whereas small superficial white lesions, even with surrounding erythema, were considered erosions^[24]. If no abnormalities or non-specific findings (such as erythematous spots or mucosal damage) were seen, the examination was considered non-specific or normal. All capsule readers were blinded to each other's findings or radiological MRE images but were aware of the patient's medical history and laboratory testing. In addition, evaluators used the capsule endoscopy data collection form including the Lewis scoring system that is automatically calculated and included in the RAPID™ software^[26]. The Lewis score is a WCE ranking of inflammatory activity into three levels based on erythema, stenosis, edema and erosions in small intestinal tertiles: (1) No disease or clinically insignificant disease ($LS < 135$); (2) Mild disease ($135 \leq LS \leq 790$); and (3) Moderate or severe disease ($LS > 790$). Any WCE with Lewis score more than 135 is considered positive^[26].

Histological findings

A subgroup of 15 of the 27 patients had pathology specimens available for review within 2 mo of the WCE study [mean 3.9 wk, standard deviation (SD) = 2.58]. Pathology specimens from the terminal ileum and duodenum were evaluated as they are considered the accepted reference standard to determine active CD in the SB.

Histology findings were considered positive if the subject had final impression of chronic active ileitis or duodenitis or if there was a description of at least one of the chronic changes (architectural changes, increase in lamina propria mononuclear cells and lamina propria PMNs) together with at least one of activity histology findings (epithelial damage, intraepithelial PMNs in surface epithelium, cryptitis, crypt abscess, erosions/ulcers, or granulomas) in either ileal or duodenal biopsies. This is based on the histological remission definition proposed by a systemic review with absence of neutrophils in crypt and lamina propria, basal and lamina propria plasma cells and eosinophils^[27] and the in the diagnosis guidelines for CD^[2]. The histology grading used is provided in the supplemental material.

Statistical analysis

Descriptive data was expressed as the mean [\pm standard deviation (SD)] for the continuous variables. Categorical data were expressed as frequencies and per-

centages. A Chi square with the Fisher correction was used to evaluate the differences for categorical variables when appropriate. Statistical significance is expressed as $P < 0.05$.

For each of the 2 methods evaluated (MRE and WCE), sensitivity, specificity, negative predictive value, positive predictive value, and accuracy were determined by the available PCDAI and histological findings from the terminal ileum and duodenum. The Fisher exact test was used to evaluate the performance of each method in relation to another. Exact binomial 95% confidence intervals were also reported. The sample size of 34 children was estimated as having an 80% power to detect 23% difference in IBD small intestinal MRE findings and WCE detection rate. This size was estimated based on our previous retrospective study^[24].

The Pearson correlation coefficient was utilized to assess agreement between Lewis capsule endoscopy score and PCDAI. All P values were 2 sided with statistical significance evaluated as statistical significance $P < 0.05$. All analyses were performed in SPSS Version 19.0 (SPSS Inc., Chicago, IL, United States).

RESULTS

Forty-five subjects with the diagnosis of CD or IC were enrolled. Twenty-seven patients completed all of the procedures of the study, 20 with CD (74%) and 7 with IC (26%). Eighteen patients were excluded because of inability to swallow PC (4/18), failure to pass PC (3/18) or failure to follow or complete study procedures (3/18), screen failure (1/18) or elective withdrawal from study (7/18).

Concordance between gastroenterologist reviewers for the diagnosis of small intestinal CD was excellent with strong correlation between the two Lewis score ($r = 0.875$, $P < 0.001$). The studies were incomplete in 3 patients. Two of these demonstrated active CD and one was negative. The patient with a negative incomplete study was excluded. There were no capsule retentions in any of the studies. All capsules passed within 2 wk of the WCE and no surgical interventions were needed. The mean small intestinal transit time was comparable (260.2 min, 218.2 min, $P = \text{NS}$) for WCE positive and negative studies respectively. The Pearson correlation coefficient between average Lewis score between both reviewers and PCDAI is very poor ($r = 0.12$, $P = \text{NS}$). Agreement rates for positive WCE, MRE, and PCDAI for the total subject group is shown in [Figure 1](#). Agreement rates for positive WCE, MRE, and SB Histology for the 14 patients in which the histology was available are shown in [Figure 2](#).

The concordance rate between WCE and MRE was poor (69%) in collectively matched positive and matched negative subjects. The concordance rate between MRE and WCE is shown in [Figure 3](#) in all subject patients (CD and IC) and in [Figure 4](#) in CD only patients.

Histology was available for fifteen patients within 2 mo of the WCE study (mean 3.9 wk and SD = 2.58) and 8 of them demonstrated active CD histology in the ileum and one in the duodenum. For one of the patients who has diagnosis of IC with positive histology, the WCE interpretation was discrepant between reviewers and this patient was dropped from the analysis leaving 14 patients analyzed in the histology comparison and 26 total patients. In CD patients, when both MRE and WCE were compared using PCDAI > 10 as the standard reference reflecting active small intestinal CD, the sensitivity of MRE and WCE were 100% and 83% respectively and the specificity of MRE and WCE were 57.14% and 78.6%, respectively. If the histology in ileum or/and duodenum was used as the reference for active small bowel involvement, WCE had a higher specificity as compared to MRE (83.3% *vs* 50%). See [Table 3](#).

When all IBD patients were taken collectively, there was no statistically significant relationship between the performance of either MRE or WCE with PCDAI or with each other. However, in patients with CD, those with a positive PCDAI (> 10) were more likely to have a positive WCE as compared to those with a negative PCDAI (83% *vs* 21%; $P = 0.018$). There was no significant difference in the frequency of a positive MRE comparing those with and without a positive PCDAI. See [Table 4](#).

DISCUSSION

There are several modalities available to screen for small intestinal involvement in IBD^[1]. However, there is no consensus on a gold standard and it remains controversial whether one of the available examinations is adequate for assessment of SB Crohn's alone or if it should be used in conjunction with other investigative modalities.

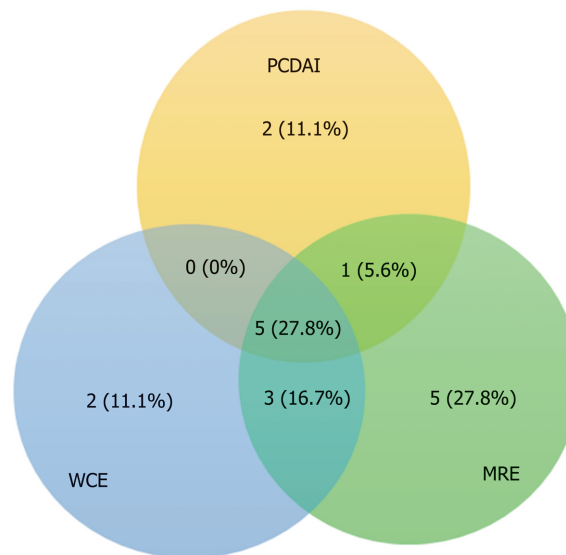


Figure 1 Concordance rate of positive small bowel involvement in the pediatric Crohn's disease activity index, positive magnetic resonance imaging, and wireless capsule endoscopy modalities in all patients $n = 26$. PCDAI: Pediatric Crohn's disease Activity Index; MRE: Magnetic resonance enterography; WCE: Wireless capsule endoscopy.

There are several prospective adult studies comparing MRE to WCE in identifying SB Crohn's which conclude that there is no significant difference in the diagnostic yield and accuracy of MRE and WCE in established non-stricturing CD^[15,16,28] or suspected and established CD together^[19,20,21]. However, proximal small bowel lesions were more often detected using WCE rather than MRE^[16,19,20,21]. Moreover, other prospective studies have shown superiority for WCE^[14,23].

The published pediatric studies are far more limited especially ones utilizing MRE as radiological modalities^[9,12,13] and they have evaluated heterogeneous groups of IBD patients^[9,13,24]. Because there is no consensus on the best screening tool for SB in CD, most of the previous studies evaluated the performance of WCE or imaging studies as the measure of diagnostic yield. It is noteworthy that this approach is suboptimal and simply suggests that a test can detect abnormalities rather than confirming its significance.

Our study is one of the first prospective studies in the United States to compare clinical, radiological and histological measures to WCE in assessing SB activity in pediatric IBD specifically CD and indeterminate colitis. The primary focus was on established Crohn's disease and did not include heterogeneous populations with suspected IBD^[9,24]. Our study demonstrates excellent inter-observer agreement in the interpretation of WCE, suggesting WCE is highly reproducible.

Because of the absence of a standard criteria for confirming proximal SB CD activity that is feasible and less invasive in children, this study used two different references to compare MRE with WCE. The first was the PCDAI as a global clinical standard for overall disease activity and the second was pathological findings in the ileum and duodenum as histological standards for SBI. We have used PCDAI because the evidence suggested its moderate correlation with pediatric CD activity and endoscopic scores^[29,30]. PCDAI < 10 is the standard definition of inactive CD that is used in clinical trials for clinical response to medical therapies^[29,30]. Pediatric onset CD runs a more aggressive active disease course, including more extensive disease location, more upper GI involvement and increased need for more aggressive medical therapy, in pediatric studies^[31-33]. This is also replicated in adult studies; proximal small bowel involvement should be considered as high risk in terms of CD-related surgery^[34-36]. In particular L4 (proximal SB not including TI) disease phenotype was associated with stricturing disease, and significantly increased risk for multiple surgeries^[37,38]. Pediatric phenotypes of CD at the time of diagnosis showed 50.9% were affected by CD proximal to the terminal ileum in United Kingdom^[39]. In Europe, isolated ileal disease (L1) is reported to be 16% in CD children, or proximal to terminal ileal (L4) in 24% and esophagogastrroduodenal (EGD) involvement in 30%^[33]. If pediatric CD mostly runs an aggressive and extensive course involving small bowel either in more than half of children, then using PCDAI can arguably be justified to reflect active small bowel disease. However, this is still a limitation in this study

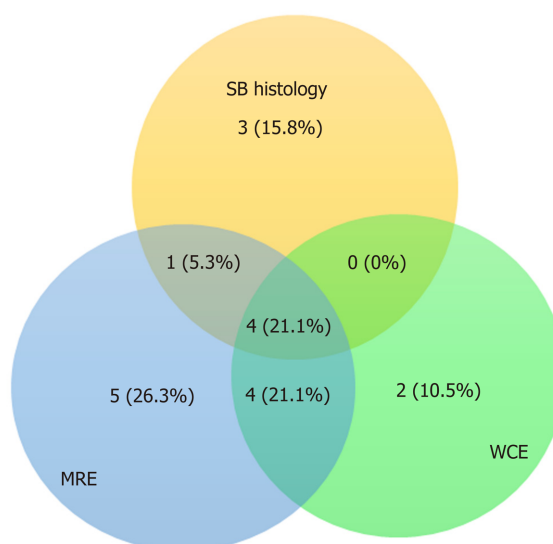


Figure 2 Concordance rate of positive small bowel involvement in wireless capsule endoscopy, magnetic resonance enterography and small bowel histology modalities in only patients with available histology $n = 14$. SB: Small bowel; WCE: Wireless capsule endoscopy; MRE: Magnetic resonance enterography.

because it does not exclude the possibility of bowel disease activity overall and it is not validated to accurately reflect SBI compared to other invasive reliable standards.

Pediatric prospective studies used ileocolonoscopy as the reference standard for identifying active CD in the terminal. Moreover, a consensus reference standard was used to determine active CD in the proximal bowel^[9,12]. This consensus is basically made up of clinical expert opinion reviewing the results of available images, labs and capsule endoscopy to decide jejunal and duodenal activity.

The current study showed near similar results for both references. However, there was relatively poor agreement between WCE and MRE in sensitivity or specificity. We found a higher sensitivity for MRE as compared to WCE with both standards. While WCE was more specific than MRE in detecting SB disease, the two modalities were comparable in test accuracy.

Our findings are consistent with previously reported pediatric studies which suggest that MRE and WCE are comparable in accuracy for detecting SB disease^[9,13]. In contrast, Oliva and colleagues, in a study of established CD in children, demonstrated slightly better accuracy of colon capsule endoscopy including SB images than MRE and SICUS.^[12] Our results are consistent with a recent systemic review by Giles revealing a pooled sensitivity and specificity for MRE for detecting active SB CD of 84% and 97%, respectively, with endoscopy as the reference test^[39]. However, the specificity of MRE is much lower in our study at 50%-57%, likely attributed to a smaller sample size.

MRE was found to be a sensitive and specific test with a decent diagnostic yield in a systemic review published in 2013^[40]. The higher sensitivity of MRE may be attributed to the low threshold being used in MRI scoring systems in few studies, the inclusion of colonic activity in some of the studies or localization of SB segments based on anatomic sectioning of the images^[16,20]. Detection of proximal small bowel inflammation in CD by MRE is challenging. Newer suggested scoring systems such as MRI global score MEGS provide potential accurate evaluation of the SB and strongly correlates with inflammation detected with fecal calprotectin and with pan-intestinal inflammatory activity^[41] but it is very time consuming and cumbersome limiting practicality^[42-44]. Moreover, terminal ileum MRI index of Activity (MaRIA) score has been developed but it did not address perfectly the activity of the proximal SB disease^[42].

Our study has uniquely modified the score reported by Jensen and discounted colonic involvement to accurately focus on scoring only small bowel findings in term of enhancement, thickening, vascular, lymphatic or fatty mesenteric changes or presence of SB complications (abscess, fistula, stricture) with same cut off > 3 to robust SB MRI score. Whether this modified score has a clinical significance is yet to be validated. This certainly suggests the need for standardizing MRI scoring, especially in children. Until a validated score is universally accepted, the possibility of MRE false positive results and the possibility of an overestimated positive yield MRE

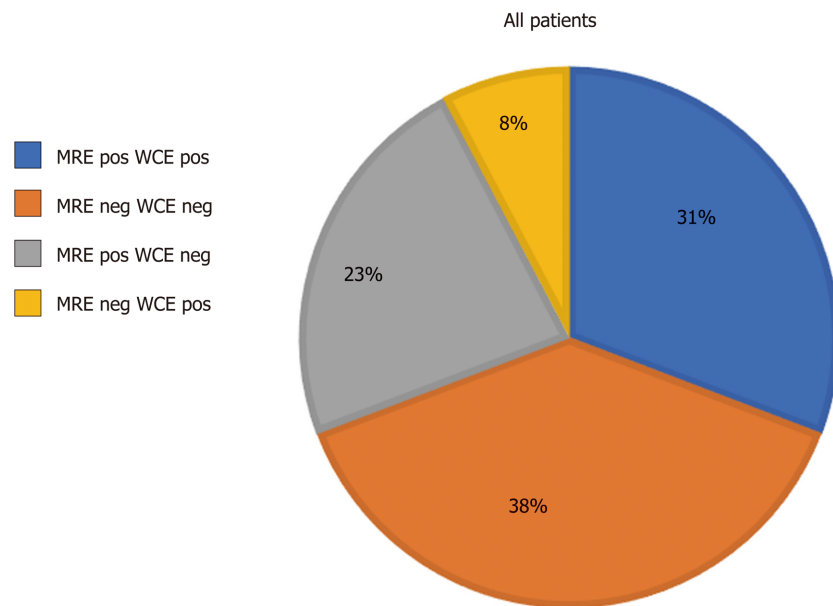


Figure 3 Concordance rate of magnetic resonance imaging and wireless capsule endoscopy in all patients.
WCE: Wireless capsule endoscopy; MRE: Magnetic resonance enterography; Pos: Positive; Neg: Negative.

should be taken into consideration.

In the current study, the specificity of WCE was higher than that of MRE (83% *vs* 50%) which contrasts with what has been reported in an established CD population (94% in WCE *vs* 89% in MRE)^[12]. Specificities of both WCE and MRE in the current study were lower than that reported in pediatric patients with suspected or established CD populations^[12,13] and disagreed with Aloï *et al*^[9] who found MRE to be more specific than WCE (89% *vs* 72%, respectively). Our results differed with other published studies likely because of the heterogeneity of populations used in their analysis and possibly to our small sample size. Therefore, WCE may be suggested as a unique confirmatory test in the assessment of mucosal disease activity. WCE has been suggested as a secondary test if MRE is inconclusive^[13]. Published expert recommendations state that a negative capsule endoscopy in CD likely excludes the presence of small bowel disease^[45].

We were able to make comparison of the performance of pairs of tools (WCE, MRE and PCDAI) with each other in patients with IBD (CD and IC) overall, and in patients with CD only. The performance of one test was not able to predict the results of the other test when WCE was compared to MRE or when MRE was compared to PCDAI. However, in patients with CD, those with a positive PCDAI (> 10) were more likely to have a positive WCE as compared to those with a negative PCDAI ($P = 0.018$). See [Table 4](#). This suggests that active disease defined with higher PCDAI score, will increase the predictive ability of WCE to be positive and it supports the use of PCDAI routinely in the assessment of SBI along with radiologic or endoscopic modalities.

This current study is limited by lack of an established reference or gold standard that can be used to compare modalities that may result in a confirmation bias. We therefore had to adopt several surrogate indices to determine if either diagnostic modality correlated with SB disease. Additionally, the current study only partially controls for timing of histology which might impact treatment measures that in turn could impact study results from MRE, SBC or both. It also lacks the evaluation of jejunal histology that can be affected in up to 20% of IBD patients. It is however explained by the assumption that histological changes may lag longer than endoscopic findings and microscopic inflammation persists in 25%-37% of cases of endoscopically quiescent CD^[27]. Finally, each subject acted as its own control as there was no use of control group population.

Future studies should continue to integrate the use of WCE, low risk imaging modalities and clinical parameters in defining of SBI in children with CD. It will be useful to integrate a composite of these modalities in a practical validated scoring measure that identify SBI in the least invasive approach.

Our study supports the use of the radiation free, less invasive and generally tolerated imaging modalities of WCE and MRE with each having a favorable role in the assessment of SBI in children with established CD. Although the unique ability of the capsule to detect mucosal changes, and similar unique ability of MRE to detect

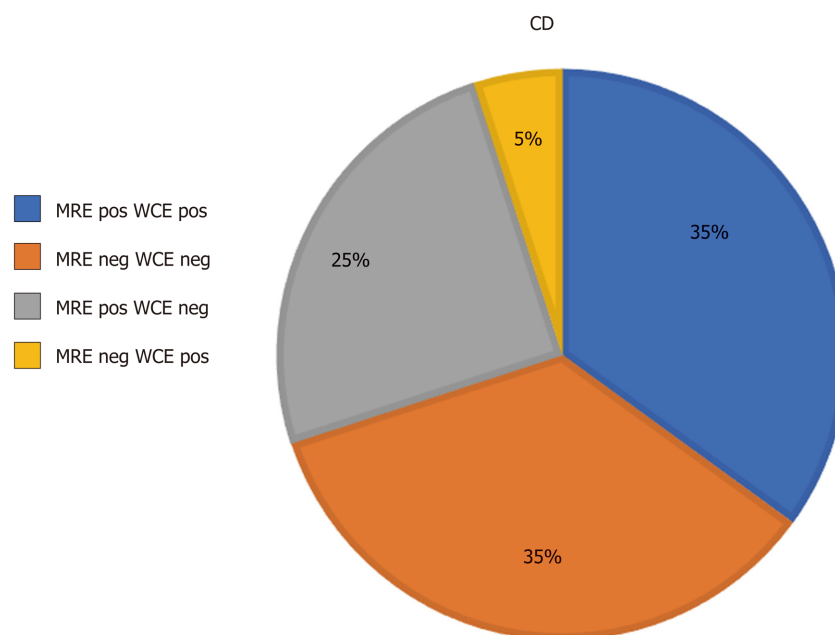


Figure 4 Concordance rate of magnetic resonance imaging and wireless capsule endoscopy in Crohn's disease patients. WCE: Wireless capsule endoscopy; MRE: Magnetic resonance enterography; Pos: Positive; Neg: Negative.

mural changes, there is still need for a standardized scoring system to describe the specificity of these findings. WCE more accurately detected small bowel disease with a much higher specificity while MRE had a higher sensitivity in pediatric IBD. Patients with active CD (PCDAI > 10) were more likely to have a positive WCE as compared to those with a negative PCDAI. Despite the disagreement between the two modalities, accuracy was comparable between MRE and WCE suggesting that they may have a complementary role in the assessment of small bowel disease.

Table 3 Magnetic resonance imaging and wireless capsule endoscopy positivity predictive of small bowel involvement in reference pediatric Crohn's disease activity index > 10 and to histology

	Reference standard is PCDAI > 10 indicate active CD					Reference standard is histology in ileum and duodenum			
	CD only patients (n = 20)					Histology available samples only (n = 14)			
	MRE		WCE			MRE		WCE	
	Value	95%CI	Value	95%CI		Value	95%CI	Value	95%CI
SEN	100%	54.07% to 100%	83.3%	35.88% to 99.58%		62.50%	24.49% to 91.48%	50.00%	15.70% to 84.30%
SP	57.14%	28.86% to 82.34%	78.6%	49.20% to 95.34%		50.00 %	11.81% to 88.19%	83.33 %	35.88% to 99.58%
PPV	50%	35.32% to 64.68%	62.5%	36.49% to 82.86%		62.50%	38.87% to 81.37%	80.00%	36.99% to 96.46%
NNP	100%		91.7%	64.29% to 98.53%		50.00 %	23.14% to 76.86%	55.56 %	36.43% to 73.17%
Accuracy	70%	45.72 to 88.11%	80.0%	56.34% to 94.27%		57.14%	28.86-82.34%	64.29%	35.14% to 87.24%

SEN: Sensitivity; SP: Specificity; PPN: Positive predictive value; NNP: Negative predictive value; MRE: Magnetic resonance enterography; PCDAI: Pediatric Crohn's Disease Activity Index; WCE: Wireless capsule endoscopy; CD: Crohn's disease.

Table 4 Fischer exact performance of each diagnostic test compared to other modality or pediatric Crohn's disease activity index

Studies compared	All patients (n = 26)	CD only (n = 20)
MRE and WCE	<i>P</i> = 0.428	<i>P</i> = 0.373
MRE and PCDAI	<i>P</i> = 0.395	<i>P</i> = 0.325
WCE and PCDAI	<i>P</i> = 0.1892	<i>P</i> = 0.0181

MRE: Magnetic resonance enterography; PCDAI: Pediatric Crohn's Disease Activity Index; WCE: Wireless capsule endoscopy; CD: Crohn's disease.

ARTICLE HIGHLIGHTS

Research background

Magnetic resonance enterography (MRE) and wireless capsule endoscopy (WCE) are equally accepted modalities for noninvasive screening of small bowel involvement (SBI) in children with Crohn's disease (CD) and indeterminate colitis (IC) and there is a paucity of data comparing the two in children. Thereby guiding the clinician in selecting the ideal diagnostic approach. Many prospective adult studies and few in pediatrics comparing MRE to WCE in identifying small bowel (SB) CD showed no significant difference in the diagnostic yield and accuracy of MRE and WCE in established non-stricturing CD or suspected and established CD together. The current study is the first prospective study in children with established IBD in the United States assessing the roles of MRE and WCE in identifying SB disease involvement in IBD. This study provides evidence for capsule endoscopy role whether it is superior or complementary in the evaluation of established disease exacerbation in patients with IBD in relation to MRE thereby guiding the clinician in selecting the ideal diagnostic approach.

Research motivation

Therefore, the goal of this study is to provide additional evidence and guidance for capsule endoscopy role in the evaluation of established CD exacerbation compared to MRE in relation to Pediatric Crohn's Disease Activity Index (PCDAI), and histological indices.

Research objectives

The primary goals of this study are to prospectively compare the diagnostic yield, concordance rate, sensitivity and specificity between MRE and WCE findings and their agreement with the PCDAI or with histological small bowel involvement in children with known IBD; CD or IC. Secondary goals are to assess the performance of each of the modalities (MRE, WCE and PCDAI) in relation to each other in order to predict the results of the compared tests and to assess the correlation between Lewis capsule endoscopy score and PCDAI.

Research methods

Consecutive patients diagnosed with CD and IC were screened for inclusion. After informed consent patient's demographic and clinical data was abstracted. The current pediatric disease activity index (PCDAI) and endoscopic findings were included. Patients underwent MRE and WCE including preprocedural patency capsule within a maximum of 7 d of each other. Pathological presence of active small bowel disease in ileal and duodenal biopsies were collected if the endoscopy was performed within 2 mo of the WCE study. Patients who failed to pass the PC were excluded from the study. WCE was read by two different experienced

gastroenterologists (Attard TM and Colombo JM) blinded to each other's findings and to the findings on MRE (Mardis NJ). Agreement between WCE reviewers, WCE and MRE findings and concordance between positive PCDAI and SBI based on MRE compared with WCE was computed.

Research results

In CD patients, when both MRE and WCE were compared using PCDAI > 10 as the standard reference reflecting active small intestinal CD, the sensitivity of MRE is higher than WCE but specificity of MRE were lower than WCE. If the histology in ileum or/and duodenum was used as the reference for active small bowel involvement which is usually the most reliable reported standard, WCE had a higher specificity as compared to MRE (83.3% *vs* 50%). Concordance between WCE and MRE was poor (69%) whether both agreed positively or negatively. While WCE was more specific than MRE in detecting SB disease, the two modalities were comparable in test accuracy. Specificities of both WCE and MRE in the current study were lower than that reported in pediatric patients with suspected or established CD populations. An active disease defined with higher PCDAI score > 10, will increase the predictive ability of WCE to be positive and it supports the use of PCDAI routinely in the assessment of SBI along with radiologic or endoscopic modalities. The argument remains to be elucidated on what is the gold standard that best identify the SBI in patients with IBD.

Research conclusions

Our study supports the use of the radiation free, less invasive and generally tolerated imaging modalities of WCE and MRE with each having a favorable role in the assessment of SBI in children with established CD. Although the unique ability of the capsule to detect mucosal changes and similar unique ability of MRE to detect mural changes, there is still need for a standardized scoring system to describe the specificity of these findings. WCE more accurately detected small bowel disease with a much higher specificity while MRE had a higher sensitivity in pediatric IBD. Patients with active CD (PCDAI > 10) were more likely to have a positive WCE as compared to those with a negative PCDAI. Despite the disagreement between the two modalities, accuracy was comparable between MRE and WCE suggesting that they may have a complementary role in the assessment of small bowel disease.

Research perspectives

Future studies should continue to integrate the use of WCE, low risk imaging modalities and clinical parameters in defining the best standard to identify SBI in children with CD. It will be useful to integrate a composite of these modalities in a practical validated scoring measure that identify SBI in the least invasive approach.

REFERENCES

- 1 Cuffari C, Dubinsky M, Darbari A, Sena L, Baldassano R. Crohn's jejunoileitis: the pediatrician's perspective on diagnosis and management. *Inflamm Bowel Dis* 2005; **11**: 696-704 [PMID: 15973125 DOI: 10.1097/01.MIB.0000166933.74477.69]
- 2 North American Society for Pediatric Gastroenterology, Hepatology, and Nutrition; Colitis Foundation of America, Bousvaros A, Antonioli DA, Colletti RB, Dubinsky MC, Glickman JN, Gold BD, Griffiths AM, Jevon GP, Higuchi LM, Hyams JS, Kirschner BS, Kugathasan S, Baldassano RN, Russo PA. Differentiating ulcerative colitis from Crohn disease in children and young adults: report of a working group of the North American Society for Pediatric Gastroenterology, Hepatology, and Nutrition and the Crohn's and Colitis Foundation of America. *J Pediatr Gastroenterol Nutr* 2007; **44**: 653-674 [PMID: 17460505 DOI: 10.1097/MPG.0b013e31805563f3]
- 3 Flamant M, Trang C, Maillard O, Sacher-Huvelin S, Le Rhun M, Galmiche JP, Bourreille A. The prevalence and outcome of jejunal lesions visualized by small bowel capsule endoscopy in Crohn's disease. *Inflamm Bowel Dis* 2013; **19**: 1390-1396 [PMID: 23552764 DOI: 10.1097/MIB.0b013e31828133c1]
- 4 Kopylov U, Nemeth A, Koulaouzidis A, Makins R, Wild G, Afif W, Bitton A, Johansson GW, Bessissow T, Eliakim R, Toth E, Seidman EG. Small bowel capsule endoscopy in the management of established Crohn's disease: clinical impact, safety, and correlation with inflammatory biomarkers. *Inflamm Bowel Dis* 2015; **21**: 93-100 [PMID: 25517597 DOI: 10.1097/MIB.0000000000000255]
- 5 Ladas SD, Triantafyllou K, Spada C, Riccioni ME, Rey JF, Niv Y, Delvaux M, de Franchis R, Costamagna G; ESGE Clinical Guidelines Committee. European Society of Gastrointestinal Endoscopy (ESGE): recommendations (2009) on clinical use of video capsule endoscopy to investigate small-bowel, esophageal and colonic diseases. *Endoscopy* 2010; **42**: 220-227 [PMID: 20195992 DOI: 10.1055/s-0029-1243968]
- 6 Levi Z, Fraser E, Krongrad R, Hazazi R, benjaminov O, meyerovitch J, Tal OB, Choen A, Niv Y, Fraser G. Factors associated with radiation exposure in patients with inflammatory bowel disease. *Aliment Pharmacol Ther* 2009; **30**: 1128-1136 [PMID: 19899197 DOI: 10.1111/j.1365-2036.2009.04140.x]
- 7 Liao Z, Gao R, Xu C, Li ZS. Indications and detection, completion, and retention rates of small-bowel capsule endoscopy: a systematic review. *Gastrointest Endosc* 2010; **71**: 280-286 [PMID: 20152309 DOI: 10.1016/j.gie.2009.09.031]
- 8 Herrerías JM, Leighton JA, Costamagna G, Infantolino A, Eliakim R, Fischer D, Rubin DT, Manten HD, Scapa E, Morgan DR, Bergwerk AJ, Koslowsky B, Adler SN. Agile patency system eliminates risk of capsule retention in patients with known intestinal strictures who undergo capsule endoscopy. *Gastrointest Endosc* 2008; **67**: 902-909 [PMID: 18355824 DOI: 10.1016/j.gie.2007.10.063]
- 9 Aloï M, Di Nardo G, Romano G, Casciani E, Civitelli F, Oliva S, Viola F, Maccioni F, Gualdi G, Cucchiara S. Magnetic resonance enterography, small-intestine contrast US, and capsule endoscopy to evaluate the small bowel in pediatric Crohn's disease: a prospective, blinded, comparison study.

- Gastrointest Endosc* 2015; **81**: 420-427 [PMID: 25115363 DOI: 10.1016/j.gie.2014.07.009]
- 10 **Pallotta N**, Tomei E, Viscido A, Calabrese E, Marcheggiano A, Caprilli R, Corazziari E. Small intestine contrast ultrasonography: an alternative to radiology in the assessment of small bowel disease. *Inflamm Bowel Dis* 2005; **11**: 146-153 [PMID: 15677908 DOI: 10.1097/00054725-200502000-00008]
 - 11 **Kovanlikaya A**, Watson E, Hayward J, Beneck D, Sockolow R, Solomon A, Christos P, Brill PW. Magnetic resonance enterography and wireless capsule endoscopy in the evaluation of patients with inflammatory bowel disease. *Clin Imaging* 2013; **37**: 77-82 [PMID: 23206611 DOI: 10.1016/j.clinimag.2012.03.011]
 - 12 **Oliva S**, Cucchiara S, Civitelli F, Casciani E, Di Nardo G, Hassan C, Papoff P, Cohen SA. Colon capsule endoscopy compared with other modalities in the evaluation of pediatric Crohn's disease of the small bowel and colon. *Gastrointest Endosc* 2016; **83**: 975-983 [PMID: 26363334 DOI: 10.1016/j.gie.2015.08.070]
 - 13 **Casciani E**, Masselli G, Di Nardo G, Poletti E, Bertini L, Oliva S, Floriani I, Cucchiara S, Gualdi G. MR enterography versus capsule endoscopy in paediatric patients with suspected Crohn's disease. *Eur Radiol* 2011; **21**: 823-831 [PMID: 20922391 DOI: 10.1007/s00330-010-1976-3]
 - 14 **Albert JG**, Martiny F, Krummnerl A, Stock K, Lesske J, Göbel CM, Lotterer E, Nietsch HH, Behrmann C, Fleig WE. Diagnosis of small bowel Crohn's disease: a prospective comparison of capsule endoscopy with magnetic resonance imaging and fluoroscopic enteroclysis. *Gut* 2005; **54**: 1721-1727 [PMID: 16020490 DOI: 10.1136/gut.2005.069427]
 - 15 **Gölder SK**, Schreyer AG, Endlicher E, Feuerbach S, Schölmerich J, Kullmann F, Seitz J, Rogler G, Herfarth H. Comparison of capsule endoscopy and magnetic resonance (MR) enteroclysis in suspected small bowel disease. *Int J Colorectal Dis* 2006; **21**: 97-104 [PMID: 15846497 DOI: 10.1007/s00384-005-0755-0]
 - 16 **Tillack C**, Seiderer J, Brand S, Göke B, Reiser MF, Schaefer C, Diepolder H, Ochsenkühn T, Herrmann KA. Correlation of magnetic resonance enteroclysis (MRE) and wireless capsule endoscopy (CE) in the diagnosis of small bowel lesions in Crohn's disease. *Inflamm Bowel Dis* 2008; **14**: 1219-1228 [PMID: 18484672 DOI: 10.1002/ibd.20466]
 - 17 **Dionisio PM**, Gurudu SR, Leighton JA, Leontiadis GI, Fleischer DE, Hara AK, Heigh RI, Shiff AD, Sharma VK. Capsule endoscopy has a significantly higher diagnostic yield in patients with suspected and established small-bowel Crohn's disease: a meta-analysis. *Am J Gastroenterol* 2010; **105**: 1240-8; quiz 1249 [PMID: 20029412 DOI: 10.1038/ajg.2009.713]
 - 18 **Crook DW**, Knuesel PR, Froehlich JM, Eigenmann F, Unterweger M, Beer HJ, Kubik-Huch RA. Comparison of magnetic resonance enterography and video capsule endoscopy in evaluating small bowel disease. *Eur J Gastroenterol Hepatol* 2009; **21**: 54-65 [PMID: 19086147 DOI: 10.1097/MEG.0b013e32830ce7a7]
 - 19 **Böcker U**, Dinter D, Litterer C, Hummel F, Knebel P, Franke A, Weiss C, Singer MV, Lohr JM. Comparison of magnetic resonance imaging and video capsule enteroscopy in diagnosing small-bowel pathology: localization-dependent diagnostic yield. *Scand J Gastroenterol* 2010; **45**: 490-500 [PMID: 20132082 DOI: 10.3109/00365520903567817]
 - 20 **Jensen MD**, Nathan T, Rafaelsen SR, Kjeldsen J. Diagnostic accuracy of capsule endoscopy for small bowel Crohn's disease is superior to that of MR enterography or CT enterography. *Clin Gastroenterol Hepatol* 2011; **9**: 124-129 [PMID: 21056692 DOI: 10.1016/j.cgh.2010.10.019]
 - 21 **Wiarda BM**, Mensink PB, Heine DG, Stolk M, Dees J, Hazenberg H, Stoker J, van der Woude CJ, Kuipers EJ. Small bowel Crohn's disease: MR enteroclysis and capsule endoscopy compared to balloon-assisted enteroscopy. *Abdom Imaging* 2012; **37**: 397-403 [PMID: 22120660 DOI: 10.1007/s00261-011-9816-8]
 - 22 **Kopylov U**, Yablecovitch D, Lahat A, Neuman S, Levhar N, Greener T, Klang E, Rozendorn N, Amitai MM, Ben-Horin S, Eliakim R. Detection of Small Bowel Mucosal Healing and Deep Remission in Patients With Known Small Bowel Crohn's Disease Using Biomarkers, Capsule Endoscopy, and Imaging. *Am J Gastroenterol* 2015; **110**: 1316-1323 [PMID: 26215531 DOI: 10.1038/ajg.2015.221]
 - 23 **González-Suárez B**, Rodríguez S, Ricart E, Ordás I, Rimola J, Díaz-González Á, Romero C, de Miguel CR, Jáuregui A, Araujo IK, Ramirez A, Gallego M, Fernández-Esparrach G, Ginés Á, Sendino O, Llach J, Panés J. Comparison of Capsule Endoscopy and Magnetic Resonance Enterography for the Assessment of Small Bowel Lesions in Crohn's Disease. *Inflamm Bowel Dis* 2018; **24**: 775-780 [PMID: 29506048 DOI: 10.1093/ibd/izz107]
 - 24 **Di Nardo G**, Oliva S, Ferrari F, Riccioni ME, Staiano A, Lombardi G, Costamagna G, Cucchiara S, Stronati L. Usefulness of wireless capsule endoscopy in paediatric inflammatory bowel disease. *Dig Liver Dis* 2011; **43**: 220-224 [PMID: 21093392 DOI: 10.1016/j.dld.2010.10.004]
 - 25 **Gralnek IM**, Cohen SA, Ephrath H, Napier A, Gobin T, Sherrod O, Lewis J. Small bowel capsule endoscopy impacts diagnosis and management of pediatric inflammatory bowel disease: a prospective study. *Dig Dis Sci* 2012; **57**: 465-471 [PMID: 21901253 DOI: 10.1007/s10620-011-1894-5]
 - 26 **Gralnek IM**, Defranchis R, Seidman E, Leighton JA, Legnani P, Lewis BS. Development of a capsule endoscopy scoring index for small bowel mucosal inflammatory change. *Aliment Pharmacol Ther* 2008; **27**: 146-154 [PMID: 17956598 DOI: 10.1111/j.1365-2036.2007.03556.x]
 - 27 **Bryant RV**, Winer S, Travis SP, Riddell RH. Systematic review: histological remission in inflammatory bowel disease. Is 'complete' remission the new treatment paradigm? An IOIBD initiative. *J Crohns Colitis* 2014; **8**: 1582-1597 [PMID: 25267173 DOI: 10.1016/j.crohns.2014.08.011]
 - 28 **Kopylov U**, Yung DE, Engel T, Vijayan S, Har-Noy O, Katz L, Oliva S, Avni T, Battat R, Eliakim R, Ben-Horin S, Koulaouzidis A. Diagnostic yield of capsule endoscopy versus magnetic resonance enterography and small bowel contrast ultrasound in the evaluation of small bowel Crohn's disease: Systematic review and meta-analysis. *Dig Liver Dis* 2017; **49**: 854-863 [PMID: 28512034 DOI: 10.1016/j.dld.2017.04.013]
 - 29 **Hyams J**, Markowitz J, Otley A, Rosh J, Mack D, Bousvaros A, Kugathasan S, Pfefferkorn M, Tolia V, Evans J, Treem W, Wyllie R, Rothbaum R, del Rosario J, Katz A, Mezzoff A, Oliva-Hemker M, Lerer T, Griffiths A; Pediatric Inflammatory Bowel Disease Collaborative Research Group. Evaluation of the pediatric Crohn disease activity index: a prospective multicenter experience. *J Pediatr Gastroenterol Nutr* 2005; **41**: 416-421 [PMID: 16205508 DOI: 10.1097/01.mpg.0000183350.46795.42]
 - 30 **Turner D**, Levine A, Walters TD, Focht G, Otley A, López VN, Baldassano R, Mack D, Hyams J, Griffiths AM. Which PCDAI Version Best Reflects Intestinal Inflammation in Pediatric Crohn Disease? *J Pediatr Gastroenterol Nutr* 2017; **64**: 254-260 [PMID: 27050050 DOI: 10.1097/MPG.0000000000001227]

- 31 **Abraham BP**, Mehta S, El-Serag HB. Natural history of pediatric-onset inflammatory bowel disease: a systematic review. *J Clin Gastroenterol* 2012; **46**: 581-589 [PMID: [22772738](#) DOI: [10.1097/MCG.0b013e318247c32f](#)]
- 32 **Pigneur B**, Seksik P, Viola S, Viala J, Beaugerie L, Girardet JP, Ruemmele FM, Cosnes J. Natural history of Crohn's disease: comparison between childhood- and adult-onset disease. *Inflamm Bowel Dis* 2010; **16**: 953-961 [PMID: [19834970](#) DOI: [10.1002/ibd.21152](#)]
- 33 **de Bie CI**, Paerregaard A, Kolacek S, Ruemmele FM, Koletzko S, Fell JM, Escher JC, EUROKIDS Porto IBD Working Group of ESPGHAN. Disease phenotype at diagnosis in pediatric Crohn's disease: 5-year analyses of the EUKIDS Registry. *Inflamm Bowel Dis* 2013; **19**: 378-385 [PMID: [22573581](#) DOI: [10.1002/ibd.23008](#)]
- 34 **Kim OZ**, Han DS, Park CH, Eun CS, Kim YS, Kim YH, Cheon JH, Ye BD, Kim JS. The Clinical Characteristics and Prognosis of Crohn's Disease in Korean Patients Showing Proximal Small Bowel Involvement: Results from the CONNECT Study. *Gut Liver* 2018; **12**: 67-72 [PMID: [28798284](#) DOI: [10.5009/gnl16500](#)]
- 35 **Freeman HJ**. Natural history and long-term clinical course of Crohn's disease. *World J Gastroenterol* 2014; **20**: 31-36 [PMID: [24415855](#) DOI: [10.3748/wjg.v20.i1.31](#)]
- 36 **Keh C**, Shatari T, Yamamoto T, Menon A, Clark MA, Keighley MR. Jejunal Crohn's disease is associated with a higher postoperative recurrence rate than ileocaecal Crohn's disease. *Colorectal Dis* 2005; **7**: 366-368 [PMID: [15932560](#) DOI: [10.1111/j.1463-1318.2005.00766.x](#)]
- 37 **Mao R**, Tang RH, Qiu Y, Chen BL, Guo J, Zhang SH, Li XH, Feng R, He Y, Li ZP, Zeng ZR, Eliakim R, Ben-Horin S, Chen MH. Different clinical outcomes in Crohn's disease patients with esophagogastrroduodenal, jejunal, and proximal ileal disease involvement: is L4 truly a single phenotype? *Therap Adv Gastroenterol* 2018; **11**: 1756284818777938 [PMID: [29899757](#) DOI: [10.1177/1756284818777938](#)]
- 38 **Lazarev M**, Huang C, Bitton A, Cho JH, Duerr RH, McGovern DP, Proctor DD, Regueiro M, Rioux JD, Schumm PP, Taylor KD, Silverberg MS, Steinhardt AH, Hutfless S, Brant SR. Relationship between proximal Crohn's disease location and disease behavior and surgery: a cross-sectional study of the IBD Genetics Consortium. *Am J Gastroenterol* 2013; **108**: 106-112 [PMID: [23229423](#) DOI: [10.1038/ajg.2012.389](#)]
- 39 **Van Limbergen J**, Russell RK, Drummond HE, Aldhous MC, Round NK, Nimmo ER, Smith L, Gillett PM, McGrogan P, Weaver LT, Bisset WM, Mahdi G, Arnott ID, Satsangi J, Wilson DC. Definition of phenotypic characteristics of childhood-onset inflammatory bowel disease. *Gastroenterology* 2008; **135**: 1114-1122 [PMID: [18725221](#) DOI: [10.1053/j.gastro.2008.06.081](#)]
- 40 **Giles E**, Barclay AR, Chippington S, Wilson DC. Systematic review: MRI enterography for assessment of small bowel involvement in paediatric Crohn's disease. *Aliment Pharmacol Ther* 2013; **37**: 1121-1131 [PMID: [23638954](#) DOI: [10.1111/apt.12323](#)]
- 41 **Klang E**, Amitai MM, Lahat A, Yablecovitch D, Avidan B, Neuman S, Levhar N, Rozendorn N, Weiss B, Ben-Horin S, Eliakim R, Kopylov U, Israeli IBD research Nucleus [IIRN]. Capsule Endoscopy Validation of the Magnetic Enterography Global Score in Patients with Established Crohn's Disease. *J Crohns Colitis* 2018; **12**: 313-320 [PMID: [29182750](#) DOI: [10.1093/ecco-jcc/jjx156](#)]
- 42 **Klang E**, Kopylov U, Eliakim R, Rozendorn N, Yablecovitch D, Lahat A, Ben-Horin S, Amitai MM. Diffusion-weighted imaging in quiescent Crohn's disease: correlation with inflammatory biomarkers and video capsule endoscopy. *Clin Radiol* 2017; **72**: 798.e7-798.e13 [PMID: [28506799](#) DOI: [10.1016/j.crad.2017.04.006](#)]
- 43 **Kopylov U**, Yung DE, Engel T, Avni T, Battat R, Ben-Horin S, Plevris JN, Eliakim R, Koulaouzidis A. Fecal calprotectin for the prediction of small-bowel Crohn's disease by capsule endoscopy: a systematic review and meta-analysis. *Eur J Gastroenterol Hepatol* 2016; **28**: 1137-1144 [PMID: [27415156](#) DOI: [10.1097/MEG.0000000000000692](#)]
- 44 **Kopylov U**, Klang E, Yablecovitch D, Lahat A, Avidan B, Neuman S, Levhar N, Greener T, Rozendorn N, Beytelman A, Yanai H, Dotan I, Chowers Y, Weiss B, Ben-Horin S, Amitai MM, Eliakim R; Israeli IBD research Nucleus (IIRN). Magnetic resonance enterography versus capsule endoscopy activity indices for quantification of small bowel inflammation in Crohn's disease. *Therap Adv Gastroenterol* 2016; **9**: 655-663 [PMID: [27582877](#) DOI: [10.1177/1756283X16649143](#)]
- 45 **Mergener K**, Ponchon T, Gralnek I, Pennazio M, Gay G, Selby W, Seidman EG, Cellier C, Murray J, de Franchis R, Rösch T, Lewis BS. Literature review and recommendations for clinical application of small-bowel capsule endoscopy, based on a panel discussion by international experts. Consensus statements for small-bowel capsule endoscopy, 2006/2007. *Endoscopy* 2007; **39**: 895-909 [PMID: [17968807](#) DOI: [10.1055/s-2007-966930](#)]



Published By Baishideng Publishing Group Inc
7041 Koll Center Parkway, Suite 160, Pleasanton, CA 94566, USA
Telephone: +1-925-2238242
Fax: +1-925-2238243
E-mail: bpgoffice@wjgnet.com
Help Desk: <http://www.f6publishing.com/helpdesk>
<http://www.wjgnet.com>

