

World Journal of *Clinical Cases*

World J Clin Cases 2021 December 6; 9(34): 10392-10745



Contents

Thrice Monthly Volume 9 Number 34 December 6, 2021

OPINION REVIEW

- 10392** Regulating monocyte infiltration and differentiation: Providing new therapies for colorectal cancer patients with COVID-19

Bai L, Yang W, Qian L, Cui JW

REVIEW

- 10400** Role of circular RNAs in gastrointestinal tumors and drug resistance

Xi SJ, Cai WQ, Wang QQ, Peng XC

MINIREVIEWS

- 10418** Liver injury associated with acute pancreatitis: The current status of clinical evaluation and involved mechanisms

Liu W, Du JJ, Li ZH, Zhang XY, Zuo HD

- 10430** Association between celiac disease and vitiligo: A review of the literature

Zhang JZ, Abudoureyimu D, Wang M, Yu SR, Kang XJ

- 10438** Role of immune escape in different digestive tumours

Du XZ, Wen B, Liu L, Wei YT, Zhao K

ORIGINAL ARTICLE

Basic Study

- 10451** Magnolol protects against acute gastrointestinal injury in sepsis by down-regulating regulated on activation, normal T-cell expressed and secreted

Mao SH, Feng DD, Wang X, Zhi YH, Lei S, Xing X, Jiang RL, Wu JN

Case Control Study

- 10464** Effect of Nephritis Rehabilitation Tablets combined with tacrolimus in treatment of idiopathic membranous nephropathy

Ly W, Wang MR, Zhang CZ, Sun XX, Yan ZZ, Hu XM, Wang TT

Retrospective Cohort Study

- 10472** Lamb's tripe extract and vitamin B₁₂ capsule plus celecoxib reverses intestinal metaplasia and atrophy: A retrospective cohort study

Wu SR, Liu J, Zhang LF, Wang N, Zhang LY, Wu Q, Liu JY, Shi YQ

- 10484** Clinical features and survival of patients with multiple primary malignancies

Wang XK, Zhou MH

Retrospective Study

- 10494** Thoracoscopic segmentectomy and lobectomy assisted by three-dimensional computed-tomography bronchography and angiography for the treatment of primary lung cancer
Wu YJ, Shi QT, Zhang Y, Wang YL
- 10507** Endoscopic ultrasound fine needle aspiration *vs* fine needle biopsy in solid lesions: A multi-center analysis
Moura DTH, McCarty TR, Jirapinyo P, Ribeiro IB, Farias GFA, Madruga-Neto AC, Ryou M, Thompson CC
- 10518** Resection of bilateral occipital lobe lesions during a single operation as a treatment for bilateral occipital lobe epilepsy
Lyu YE, Xu XF, Dai S, Feng M, Shen SP, Zhang GZ, Ju HY, Wang Y, Dong XB, Xu B
- 10530** Improving rehabilitation and quality of life after percutaneous transhepatic cholangiography drainage with a rapid rehabilitation model
Xia LL, Su T, Li Y, Mao JF, Zhang QH, Liu YY
- 10540** Combined lumbar muscle block and perioperative comprehensive patient-controlled intravenous analgesia with butorphanol in gynecological endoscopic surgery
Zhu RY, Xiang SQ, Chen DR
- 10549** Teicoplanin combined with conventional vancomycin therapy for the treatment of pulmonary methicillin-resistant *Staphylococcus aureus* and *Staphylococcus epidermidis* infections
Wu W, Liu M, Geng JJ, Wang M
- 10557** Application of narrative nursing in the families of children with biliary atresia: A retrospective study
Zhang LH, Meng HY, Wang R, Zhang YC, Sun J

Observational Study

- 10566** Comparative study for predictability of type 1 gastric variceal rebleeding after endoscopic variceal ligation: High-frequency intraluminal ultrasound study
Kim JH, Choe WH, Lee SY, Kwon SY, Sung IK, Park HS
- 10576** Effects of WeChat platform-based health management on health and self-management effectiveness of patients with severe chronic heart failure
Wang ZR, Zhou JW, Liu XP, Cai GJ, Zhang QH, Mao JF
- 10585** Early cardiopulmonary resuscitation on serum levels of myeloperoxidase, soluble ST2, and hypersensitive C-reactive protein in acute myocardial infarction patients
Hou M, Ren YP, Wang R, Lu LX

Prospective Study

- 10595** Remimazolam benzenesulfonate anesthesia effectiveness in cardiac surgery patients under general anesthesia
Tang F, Yi JM, Gong HY, Lu ZY, Chen J, Fang B, Chen C, Liu ZY

Randomized Clinical Trial

- 10604** Effects of lower body positive pressure treadmill on functional improvement in knee osteoarthritis: A randomized clinical trial study
Chen HX, Zhan YX, Ou HN, You YY, Li WY, Jiang SS, Zheng MF, Zhang LZ, Chen K, Chen QX

SYSTEMATIC REVIEWS

- 10616** Effects of hypoxia on bone metabolism and anemia in patients with chronic kidney disease
Kan C, Lu X, Zhang R

META-ANALYSIS

- 10626** Intracuff alkalinized lidocaine to prevent postoperative airway complications: A meta-analysis
Chen ZX, Shi Z, Wang B, Zhang Y

CASE REPORT

- 10638** Rarely fast progressive memory loss diagnosed as Creutzfeldt-Jakob disease: A case report
Xu YW, Wang JQ, Zhang W, Xu SC, Li YX
- 10645** Diagnosis, fetal risk and treatment of pemphigoid gestationis in pregnancy: A case report
Jiao HN, Ruan YP, Liu Y, Pan M, Zhong HP
- 10652** Histology transformation-mediated pathological atypism in small-cell lung cancer within the presence of chemotherapy: A case report
Ju Q, Wu YT, Zhang Y, Yang WH, Zhao CL, Zhang J
- 10659** Reversible congestive heart failure associated with hypocalcemia: A case report
Wang C, Dou LW, Wang TB, Guo Y
- 10666** Excimer laser coronary atherectomy for a severe calcified coronary ostium lesion: A case report
Hou FJ, Ma XT, Zhou YJ, Guan J
- 10671** Comprehensive management of malocclusion in maxillary fibrous dysplasia: A case report
Kaur H, Mohanty S, Kochhar GK, Iqbal S, Verma A, Bhasin R, Kochhar AS
- 10681** Intravascular papillary endothelial hyperplasia as a rare cause of cervicthoracic spinal cord compression: A case report
Gu HL, Zheng XQ, Zhan SQ, Chang YB
- 10689** Proximal true lumen collapse in a chronic type B aortic dissection patient: A case report
Zhang L, Guan WK, Wu HP, Li X, Lv KP, Zeng CL, Song HH, Ye QL
- 10696** Tigecycline sclerotherapy for recurrent pseudotumor in aseptic lymphocyte-dominant vasculitis-associated lesion after metal-on-metal total hip arthroplasty: A case report
Lin IH, Tsai CH

- 10702** Acute myocardial infarction induced by eosinophilic granulomatosis with polyangiitis: A case report
Jiang XD, Guo S, Zhang WM
- 10708** Aggressive natural killer cell leukemia with skin manifestation associated with hemophagocytic lymphohistiocytosis: A case report
Peng XH, Zhang LS, Li LJ, Guo XJ, Liu Y
- 10715** Chronic lymphocytic leukemia/small lymphocytic lymphoma complicated with skin Langerhans cell sarcoma: A case report
Li SY, Wang Y, Wang LH
- 10723** Severe mediastinitis and pericarditis after endobronchial ultrasound-guided transbronchial needle aspiration: A case report
Koh JS, Kim YJ, Kang DH, Lee JE, Lee SI
- 10728** Obturator hernia - a rare etiology of lateral thigh pain: A case report
Kim JY, Chang MC
- 10733** Tracheal tube misplacement in the thoracic cavity: A case report
Li KX, Luo YT, Zhou L, Huang JP, Liang P
- 10738** Peri-implant keratinized gingiva augmentation using xenogeneic collagen matrix and platelet-rich fibrin: A case report
Han CY, Wang DZ, Bai JF, Zhao LL, Song WZ

ABOUT COVER

Editorial Board Member of *World Journal of Clinical Cases*, Gagan Mathur, MBBS, MD, Associate Professor, Director, Staff Physician, Department of Pathology, Saint Luke's Health System, Kansas City, MO 64112, United States. gmathur@saint-lukes.org

AIMS AND SCOPE

The primary aim of *World Journal of Clinical Cases* (WJCC, *World J Clin Cases*) is to provide scholars and readers from various fields of clinical medicine with a platform to publish high-quality clinical research articles and communicate their research findings online.

WJCC mainly publishes articles reporting research results and findings obtained in the field of clinical medicine and covering a wide range of topics, including case control studies, retrospective cohort studies, retrospective studies, clinical trials studies, observational studies, prospective studies, randomized controlled trials, randomized clinical trials, systematic reviews, meta-analysis, and case reports.

INDEXING/ABSTRACTING

The WJCC is now indexed in Science Citation Index Expanded (also known as SciSearch®), Journal Citation Reports/Science Edition, Scopus, PubMed, and PubMed Central. The 2021 Edition of Journal Citation Reports® cites the 2020 impact factor (IF) for WJCC as 1.337; IF without journal self cites: 1.301; 5-year IF: 1.742; Journal Citation Indicator: 0.33; Ranking: 119 among 169 journals in medicine, general and internal; and Quartile category: Q3. The WJCC's CiteScore for 2020 is 0.8 and Scopus CiteScore rank 2020: General Medicine is 493/793.

RESPONSIBLE EDITORS FOR THIS ISSUE

Production Editor: Yan-Xia Xing; Production Department Director: Yun-Jie Ma; Editorial Office Director: Jin-Lei Wang.

NAME OF JOURNAL

World Journal of Clinical Cases

ISSN

ISSN 2307-8960 (online)

LAUNCH DATE

April 16, 2013

FREQUENCY

Thrice Monthly

EDITORS-IN-CHIEF

Dennis A Bloomfield, Sandro Vento, Bao-Gan Peng

EDITORIAL BOARD MEMBERS

<https://www.wjgnet.com/2307-8960/editorialboard.htm>

PUBLICATION DATE

December 6, 2021

COPYRIGHT

© 2021 Baishideng Publishing Group Inc

INSTRUCTIONS TO AUTHORS

<https://www.wjgnet.com/bpg/gerinfo/204>

GUIDELINES FOR ETHICS DOCUMENTS

<https://www.wjgnet.com/bpg/GerInfo/287>

GUIDELINES FOR NON-NATIVE SPEAKERS OF ENGLISH

<https://www.wjgnet.com/bpg/gerinfo/240>

PUBLICATION ETHICS

<https://www.wjgnet.com/bpg/GerInfo/288>

PUBLICATION MISCONDUCT

<https://www.wjgnet.com/bpg/gerinfo/208>

ARTICLE PROCESSING CHARGE

<https://www.wjgnet.com/bpg/gerinfo/242>

STEPS FOR SUBMITTING MANUSCRIPTS

<https://www.wjgnet.com/bpg/GerInfo/239>

ONLINE SUBMISSION

<https://www.f6publishing.com>



Retrospective Study

Resection of bilateral occipital lobe lesions during a single operation as a treatment for bilateral occipital lobe epilepsy

Yan-En Lyu, Xiao-Fei Xu, Shuang Dai, Min Feng, Shao-Ping Shen, Guo-Zhen Zhang, Hong-Yan Ju, Yao Wang, Xiao-Bo Dong, Bin Xu

ORCID number: Yan-En Lyu 0000-0003-1796-2057; Xiao-Fei Xu 0000-0002-8575-2038; Shuang Dai 0000-0002-0940-6299; Min Feng 0000-0003-1767-8769; Shao-Ping Shen 0000-0002-6073-225X; Guo-Zhen Zhang 0000-0002-2613-976X; Hong-Yan Ju 0000-0001-7148-7985; Yao Wang 0000-0003-1074-5375; Xiao-Bo Dong 0000-0003-3891-7503; Bin Xu 0000-0001-6076-2144.

Author contributions: Lyu YE and Xu XF contributed conception, design and final approval of manuscript; Lyu YE, Xu XF, Dai S, Shen SP and Dong XB performed the research; Xu B, Zhang GZ and Ju HY contributed provision of study materials or patients; Lyu YE, Xu XF, Feng M and Wang Y contributed data collection and analysis; Lyu YE, Xu XF, Dai S, Feng M and Wang Y contributed manuscript writing.

Institutional review board

statement: The ethics committee of Beijing university of Chinese medicine dongzhimen hospital approved this study. All patients provided written consent for surgery after being informed of the potential benefits and risks.

Informed consent statement:

Informed consent for inclusion was waived because the analysis was

Yan-En Lyu, Min Feng, Yao Wang, Seventh Clinical School of Medicine, Beijing University of Chinese Medicine, Tongchuan 727031, Shaanxi Province, China

Yan-En Lyu, Shuang Dai, Shao-Ping Shen, Guo-Zhen Zhang, Hong-Yan Ju, Xiao-Bo Dong, Bin Xu, Neurosurgery and Epilepsy Centre, Dongzhimen Hospital, Beijing University of Chinese Medicine, Beijing 100700, China

Xiao-Fei Xu, Neurosurgery and Epilepsy Centre, General Hospital of Beijing Military Commanding Regain, Beijing 100700, China

Corresponding author: Xiao-Fei Xu, MD, Doctor, Neurosurgery and Epilepsy Centre, General Hospital of Beijing Military Commanding Regain, No. 5 Nancangmen, Dongcheng District, Beijing 100700, China. xuxiaofei0002@126.com

Abstract

BACKGROUND

Neurosurgical treatment of severe bilateral occipital lobe epilepsy usually involves two operations several mos apart.

AIM

To evaluate surgical resection of bilateral occipital lobe lesions during a single operation as a treatment for bilateral occipital lobe epilepsy.

METHODS

This retrospective case series included patients with drug-refractory bilateral occipital lobe epilepsy treated surgically between March 2006 and November 2015.

RESULTS

Preoperative evaluation included scalp video-electroencephalography (EEG), magnetic resonance imaging, and PET-CT. During surgery (bilateral occipital craniotomy), epileptic foci and important functional areas were identified by EEG (intracranial cortical electrodes) and cortical functional mapping, respectively. Patients were followed up for at least 5 years to evaluate treatment outcome (Engel grade) and visual function. The 20 patients (12 males) were aged 4-30 years (median age, 12 years). Time since onset was 3-20 years (median, 8 years), and episode frequency was 4-270/mo (median, 15/mo). Common manifestations were

retrospective.

Conflict-of-interest statement: We have no financial relationships to disclose.

Data sharing statement: No additional data are available.

Country/Territory of origin: China

Specialty type: Medicine, research and experimental

Provenance and peer review: Unsolicited article; Externally peer reviewed.

Peer-review report's scientific quality classification

Grade A (Excellent): 0

Grade B (Very good): 0

Grade C (Good): C

Grade D (Fair): 0

Grade E (Poor): 0

Open-Access: This article is an open-access article that was selected by an in-house editor and fully peer-reviewed by external reviewers. It is distributed in accordance with the Creative Commons Attribution NonCommercial (CC BY-NC 4.0) license, which permits others to distribute, remix, adapt, build upon this work non-commercially, and license their derivative works on different terms, provided the original work is properly cited and the use is non-commercial. See: <http://creativecommons.org/licenses/by-nc/4.0/>

Received: June 7, 2021

Peer-review started: June 7, 2021

First decision: June 25, 2021

Revised: August 9, 2021

Accepted: October 6, 2021

Article in press: October 6, 2021

Published online: December 6, 2021

P-Reviewer: Bazhanova ED

S-Editor: Wang LL

L-Editor: A

P-Editor: Wang LL



elementary visual hallucinations (65.0%), flashing lights (30.0%), blurred vision (20.0%) and visual field defects (20.0%). Most patients were free of disabling seizures (Engel grade I) postoperatively (18/20, 90.0%) and at 1 year (18/20, 90.0%), 3 years (17/20, 85.0%) and ≥ 5 years (17/20, 85.0%). No patients were classified Engel grade IV (no worthwhile improvement). After surgery, there was no change in visual function in 13/20 (65.0%), development of a new visual field defect in 3/20 (15.0%), and worsening of a preexisting defect in 4/20 (20.0%).

CONCLUSION

Resection of bilateral occipital lobe lesions during a single operation may be applicable in bilateral occipital lobe epilepsy.

Key Words: Drug-resistant epilepsy; Occipital lobe epilepsy; Bilateral lesions; One-stage surgery; Treatment outcome; Visual fields

©The Author(s) 2021. Published by Baishideng Publishing Group Inc. All rights reserved.

Core Tip: The main finding of this case series of patients treated surgically for bilateral occipital lobe epilepsy is that bilateral resection during a single operation was a very effective treatment, with the vast majority of patients (85%) free of disabling seizures at 5 years after neurosurgery and no patients exhibiting no worthwhile improvement. Two interesting additional observations in this study were a reduction in the number and sizes of facial sebaceous adenoma lesions in one patient and the resolution of drug-resistant psoriatic lesions in another patient after surgery.

Citation: Lyu YE, Xu XF, Dai S, Feng M, Shen SP, Zhang GZ, Ju HY, Wang Y, Dong XB, Xu B. Resection of bilateral occipital lobe lesions during a single operation as a treatment for bilateral occipital lobe epilepsy. *World J Clin Cases* 2021; 9(34): 10518-10529

URL: <https://www.wjgnet.com/2307-8960/full/v9/i34/10518.htm>

DOI: <https://dx.doi.org/10.12998/wjcc.v9.i34.10518>

INTRODUCTION

Occipital lobe epilepsy[1] is an uncommon form of epilepsy that accounts for only 2%-13% of cases of symptomatic focal epilepsy[1-6]. The symptoms of occipital lobe epilepsy are mainly visual and oculomotor manifestations and include visual illusion, elementary visual hallucinations, blinking, a sensation of eye movement, nausea, dizziness, ictal blindness, and contralateral eye and head deviation[1,5-9]. The diagnosis of occipital lobe epilepsy can be challenging because of the rapid spread of the seizure to the frontal, temporal and parietal lobes and the midbrain tegmentum[5,6,10]. Therefore, achieving a definitive diagnosis generally requires the use of scalp electroencephalograms (EEGs), magnetic resonance imaging (MRI), fluorodeoxyglucose positron emission tomography (FDG-PET), single-photon emission computed tomography (SPECT), and/or video-EEG monitoring with intracranial electrodes[4,7,9,11-13].

Although pharmacologic therapies are available for focal epilepsy[14], some cases are resistant to drugs and require neurosurgical intervention[7,15-18]. A small number of reports have described the surgical management of intractable occipital lobe epilepsy, and the techniques used included lesionectomy, corticectomy, and lobectomy[7-9,15,17,19-29]. However, the majority of previous clinical investigations have focused on patients with unilateral occipital lobe epilepsy, and there are very few published studies describing the surgical management of patients with bilateral occipital lobe epilepsy[30]. Generally, the neurosurgical management of bilateral occipital lobe epilepsy involves resection of the lesion on one side, a 6 mo recovery period, and finally resection of the lesion on the other side. Although this approach is considered relatively safe, it requires two surgical procedures spaced 6 mo apart. The surgical treatment of bilateral occipital lobe epilepsy during a single operation would have several potential advantages, such as a reduced number of surgeries and hospitalizations, a shorter treatment time, lower treatment costs, and decreased psycho-

logical stress for the patients and their families. However, to the best of our knowledge, no previous studies have reported the treatment of bilateral occipital lobe epilepsy using a single surgical procedure.

MATERIALS AND METHODS

Study design and patients

This retrospective case series included 20 patients with bilateral occipital lobe epilepsy refractory to medical therapy who were treated surgically at the Epilepsy Center, General Hospital of the Beijing Military Command Region and the Epilepsy Center, Dongzhimen Hospital affiliated to Beijing University of Chinese Medicine between March 2006 and November 2015. The inclusion criteria were: (1) A diagnosis of bilateral occipital lobe epilepsy based on the medical history, seizure characteristics, EEG, and imaging investigations; (2) Frequent occurrence of seizures that severely affected the quality of life; (3) Seizures refractory to drug therapy; and (4) Bilateral occipital lobe lesions were treated surgically during a single operation. The diagnosis of bilateral occipital lobe epilepsy was based on the following features: (1) Scalp video-EEG monitoring showed abnormal firing in both sides of the occipital lobe, with some seizures originating from the left side and other episodes originating from the right side; (2) Imaging examinations showed abnormalities of the bilateral occipital lobe (a negative result did not exclude bilateral occipital lobe epilepsy); and (3) The form of the episode was related to the side of the occipital lobe in which it originated, and the seizure side was sometimes on the left and sometimes on the right. The exclusion criteria were: (1) A definitive diagnosis of bilateral occipital lobe epilepsy could not be made; (2) Epileptogenic lesions outside the occipital lobe; (3) Infrequent occurrence of episodes that did not merit surgery; and (4) Other serious diseases or contraindications to surgery.

The ethics committee of Beijing university of Chinese medicine dongzhimen hospital approved this study. All patients provided written consent for surgery after being informed of the potential benefits and risks. Informed consent for inclusion was waived because the analysis was retrospective.

Baseline demographic and clinical characteristics

Preoperative evaluation: All patients underwent scalp video-EEG for 48-170 h to record abnormal discharges during the interictal period as well as more than five seizures. The patients were also evaluated using MRI (3D thin-layer T1-weighted and T2-weighted scanning and T2-FLAIR imaging). In addition, PET-CT was used for individual patients with an unclear diagnosis based on video-EEG and MRI.

Neurosurgery: All operations were presided over by the same senior chief physician who had many years of clinical neurosurgery experience, including the resection of epileptogenic lesions under video-EEG monitoring. Surgery for each patient was planned and carried out by a multi-disciplinary team of doctors and nurses. The bilateral occipital lobe lesions were resected during a single surgical procedure in all patients.

First, a bilateral occipital craniotomy was performed (Figure 1A and B). Intracranial cortical electrodes (AD-Tech Medical, Oak Creek, WI, United States) were placed on the surface of the bilateral occipital lobe (Figure 1C), and EEG monitoring (128-channel video EEG monitoring system; Nicolet, Natus Medical Incorporated, United States) was carried out to determine the epileptic foci. Next, the important functional areas that needed protecting during surgery were identified by cortical functional mapping, and the scope of the resection and the areas to be protected were determined. Then the lesions in the bilateral occipital lobe were surgically resected (Figure 1D). During surgery, particular attention was paid to the following: (1) To ensure full exposure of the bilateral occipital lobe, the lower level of the incision was extended to reach the level of the transverse sinus so that the sinus confluence and part of the transverse sinus were exposed; (2) The bone flap was removed without a midline bone bridge; (3) Great care was taken to avoid severe bleeding caused by injury to the sagittal sinus, sinus confluence, and transverse sinuses; (4) The locations and numbers of cortical electrodes were determined according to the results of preoperative EEG monitoring to avoid the omission of epileptogenic foci; and (5) The location and scope of the resection were determined according to the results of cortical EEG monitoring and cortical function mapping to optimize complete resection of the epileptogenic lesions while protecting brain function to the maximal extent. In general, the resected area of

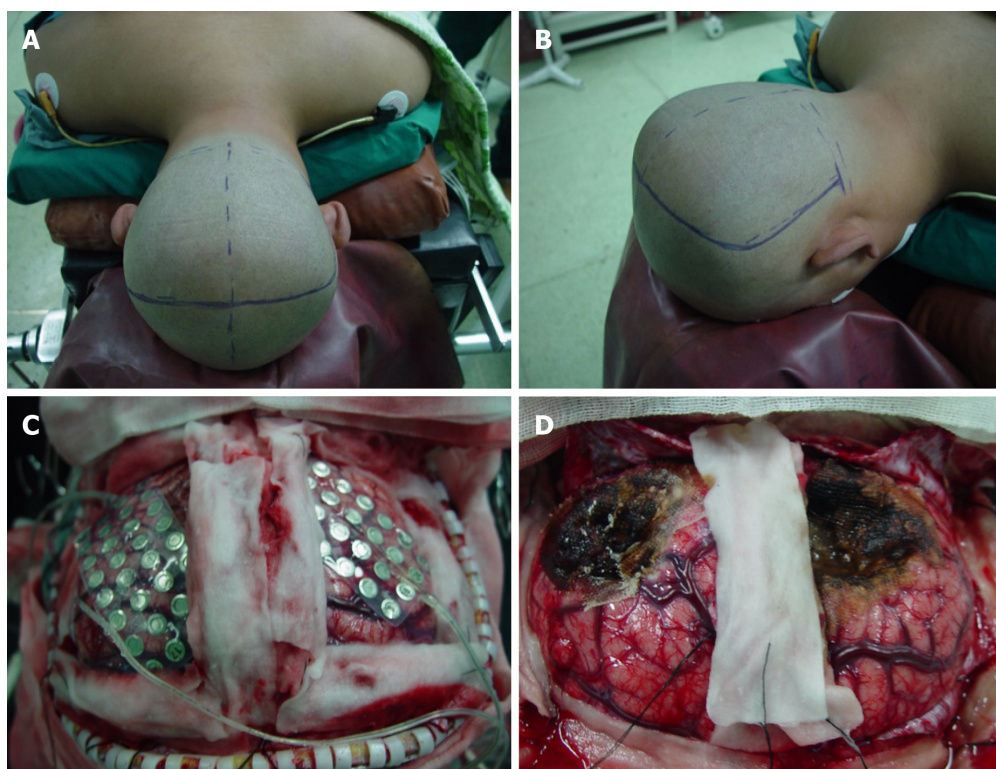


Figure 1 Surgical resection of bilateral occipital lesions. A and B: The extent of the bilateral occipital craniotomy; C: Intracranial cortical electrodes were placed on the surface of the bilateral occipital lobe during surgery to enable monitoring of the electroencephalography; D: Photograph taken after resection of the lesions in the bilateral occipital lobe.

the occipital lobe could be extended to the temporo-occipital junction laterally, to the posterior part of the parietal lobe, and to below the precuneus. When the occipital lobe showed definite morphologic changes, the epileptogenic foci surrounding the lesions were removed as much as possible. If the lesion was located outside the calcarine fissure, individually tailored cortical resection was used to minimize injury to the visual cortex.

Follow-up and outcome measures

All patients underwent reexamination and postoperative follow-up at least once each year for a minimum of 5 years to evaluate the effects of treatment on the incidence of seizures and visual function (including visual fields). The outcome of epilepsy surgery was graded I-IV according to the Engel classification[31]. Visual function in cooperative patients was assessed by clinical examination of vision and the visual fields. The visual function of patients who could not cooperate with a full vision examination, for example, due to young age, was assessed from their behavioral activity and information provided by the parents. In addition, any other notable changes in physical or psychological status during follow-up were recorded.

Statistical analysis

A descriptive statistical approach was used for the analysis, which was performed using SPSS 22.0 (IBM Corp., Armonk, NY, United States). Data are presented as *n* (%) or median (range).

RESULTS

Baseline clinical characteristics of the study participants

The baseline clinical characteristics of the 20 patients (12 males) with bilateral occipital lobe epilepsy included in the study are presented in Table 1. The patients were aged 4-30 years with a median age of 12 years. The time since disease onset ranged from 3-20 years, and all patients had been experiencing frequent episodes of drug-refractory epilepsy (median frequency of 15 episodes per mo). The most common clinical

Table 1 Baseline clinical characteristics of the 20 patients treated surgically for bilateral occipital lobe epilepsy

Clinical characteristic	Value
Gender, <i>n</i> (%)	
Male	12 (60.0)
Female	8 (40.0)
Age (yr), median (range)	12 (4-30)
Age at disease onset (yr), median (range)	5 (1-11)
Frequency of epilepsy (episodes per mo), median (range)	15 (4-270)
Time since disease onset (yr), median (range)	8 (3-20)
Pathology, <i>n</i> (%)	
Inflammation	6 (30.0)
Cortical dysplasia	5 (25.0)
Dysplasia	3 (15.0)
Nodular sclerosis	2 (10.0)
Vascular malformation	2 (10.0)
Multiple nodular sclerosis	1 (5.0)
Lobe atrophy	1 (5.0)
Clinical manifestations, <i>n</i> (%)	
Elementary visual hallucinations	13 (65.0)
Flashing lights	6 (30.0)
Blurred vision	4 (20.0)
Field defect	4 (20.0)
Blindness	3 (15.0)
Visual illusion	3 (15.0)
Blinking	2 (10.0)
Sensation of eye movement	1 (5.0)
Deja vu	1 (5.0)
Dizziness	1 (5.0)
Nausea	0 (0.0)
Fear	0 (0.0)
Epigastric rising sensation	0 (0.0)

manifestations (see [Table 1](#)) were elementary visual hallucinations (13/20, 65.0%), flashing lights (6/20, 30.0%), blurred vision (4/20, 20.0%) and visual field defects (4/20, 20.0%).

Outcome of epilepsy surgery assessed using the Engel classification

All patients underwent resection of bilateral occipital lesions, and the hospitalization time ranged from 15-20 d. The surgical outcomes are presented in [Table 2](#). The vast majority of patients were seizure-free (Engel grade I) in the postoperative period (18/20, 90.0%) and at 1 year (18/20, 90.0%), 3 years (17/20, 85.0%) and ≥ 5 years (17/20, 85.0%). Importantly, no patients were classified as Engel grade IV (no worthwhile improvement) at any of the follow-up time points.

Postoperative changes in visual function

Visual field changes after surgery are summarized in [Table 3](#). After the operation, 13 patients (65.0%) showed no change in visual function, three patients (15.0%) developed a new visual field defect, and four patients (20.0%) exhibited worsening of a defect that had been present preoperatively. Four patients (20.0%) had partial visual

Table 2 Surgical outcomes assessed using the Engel classification

Follow-up time point and outcome	n (%)
Postoperative period	
Engel grade I	18 (90.0)
Engel grade II	1 (5.0)
Engel grade III	1 (5.0)
1 yr	
Engel grade I	18 (90.0)
Engel grade II	1 (5.0)
Engel grade III	1 (5.0)
3 yr	
Engel grade I	17 (85.0)
Engel grade II	2 (10.0)
Engel grade III	1 (5.0)
5 yr or more	
Engel grade I	17 (85.0)
Engel grade II	2 (10.0)
Engel grade III	1 (5.0)

Table 3 Visual field changes after surgery

Parameter	n (%)
Visual field before surgery	
Normal	9 (45.0)
Quadrantanopia	2 (10.0)
Hemianopsia	0 (0.0)
Other types of defect	9 (45.0)
Visual field change after surgery	
Normal to normal	6 (30.0)
Normal to defect	3 (15.0)
Worsening of defect	4 (20.0)
No change in defect	7 (35.0)

field loss or increased visual field loss after surgery, and one patient (5.0%) experienced temporary postoperative blindness with the recovery of visual acuity within the subsequent mo. One patient (5.0%) had severe visual impairment before surgery that did not change postoperatively. Two patients (10.0%) showed a notable improvement in visual acuity after surgery. One was a 10-year-old boy who complained of dizziness when wearing glasses to correct his vision before surgery; the patient no longer needed glasses after surgery, which had the added benefit of avoiding the occurrence of dizzy spells. The other was a 16-year-old girl with poor vision preoperatively; after surgery, her vision improved sufficiently such that she no longer needed assistance or the use of handrails to walk or ascend/descend stairs.

Other postoperative changes

A 7-year-old boy with facial sebaceous adenoma exhibited a substantial reduction in lesion number and size after surgery. In addition, a 30-year-old male had postoperative resolution of multiple psoriatic lesions that had been resistant to medical treatment for many years.

Case 1: A 15-year-old male patient had a history of asphyxia at birth associated with cyanosis and lethargy on the fourth day after birth. An episode of right limb rigidity developed on day 55 after birth, but this resolved after treatment. Absence seizures began to occur when the patient was 4 years old, and at the age of 6 years, the patient started to experience episodes approximately once per mo in which the eyeballs and head turned to the left, and the right limbs twitched. The patient was given various medications, including carbamazepine and dianxianling, but the seizures were not fully controlled. One mo before admission, the patient experienced an episode in which he was described as suddenly falling backward with flexion of the left limbs, erthyphoria of both eyes, and foaming at the mouth; the episode persisted for about one minute. The patient was admitted on August 20, 2007. Physical examination was unremarkable. Video-EEG monitoring revealed abnormal discharges in the bilateral occipital regions, with episodes originating from different areas of the bilateral occipital lobe (Figure 2A). MRI demonstrated abnormal signals in the bilateral occipital lobe (Figure 2B and C), and T2-T2 imaging showed irregular high signals in the bilateral occipital lobe that were suggestive of ischemic changes (Figure 2D). After a thorough preoperative evaluation, it was decided that bilateral occipital lobe surgery should be performed as the treatment strategy. After adequate preoperative preparation, a bilateral occipital craniotomy was performed under general anesthesia, and a subdural grid electrode was placed (Figure 2E and F). The intracranial electrode detected abnormal discharges that originated in both the left and right sides of the occipital lobe (Figure 2G-I). Bilateral resection was performed after the determination of the origins of the seizures and localization of cortical function. Postoperative cranial CT demonstrated the changes following bilateral occipital lobe surgery (Figure 2J). The patient recovered well after surgery with good limb function and no defects in vision or the visual fields. The patient has not experienced any seizures during the 12 years since surgery was performed.

Case 2: An 11-year-old male patient (an elder twin) presented with a history of convulsions that began three d after birth. He was diagnosed as having a subarachnoid hemorrhage secondary to dystocia and was hospitalized for 11 d at XXX Hospital to receive treatment. At the age of 5 years, the patient began to experience transient facial convulsions characterized by small movements such as winking. The episodes occurred once every mo for several mos and were not associated with falling to the ground or loss of consciousness. A diagnosis of epilepsy was made on the basis of EEG investigations. By 9 years of age, the patient was experiencing seizures that were more frequent (typical interval of 5-7 d, with a maximum of 7 episodes in one day) and severe (all grand mal seizures). Treatment with oral Depakine (valproate sodium) was ineffective, so the medication was changed to Topamax (topiramate, 100 mg/d). However, the symptoms had worsened further by the time the patient was 10 years old, with typical convulsive episodes lasting 1-2 minutes and involving turning of both eyes, upper limb flexion, clenching of both hands, and loss of consciousness but no vomiting or urinary/fecal incontinence. By this stage, the seizures were frequently occurring (4-5 times/d), and the patient was showing poorer physical and intellectual development than his peers. There were no hereditary or similar diseases in the family, and the patient's brother developed normally. At presentation, physical examination indicated that the patient had a short stature for his age (113 cm), but otherwise, the findings were unremarkable. Scalp video-EEG detected a total of 4 episodes in 24 h, with two originating in the left occipital lobe and two originating in the right occipital lobe (Figure 3A and B). MRI showed bilateral occipital dysplasia and a high signal on T2-FLAIR imaging that was obvious on the right side (Figure 3C-E). After bilateral occipital craniotomy and subdural grid electrode placement (Figure 3F), the EEG recording detected a total of 4 episodes in 24 h, with two episodes originating on each side. This confirmed the diagnosis of bilateral occipital lobe epilepsy. After surgical resection of the identified lesions, cranial CT was performed (Figure 3I). The patient was completely blind immediately after surgery, but visual function showed partial recovery by the time of discharge and was fully restored at 1 mo. The patient recovered well after surgery with good limb function and no complications. No seizures have occurred during the 12 years since surgery.

DISCUSSION

The main finding of this case series of patients treated surgically for bilateral occipital lobe epilepsy is that bilateral resection during a single operation was a very effective

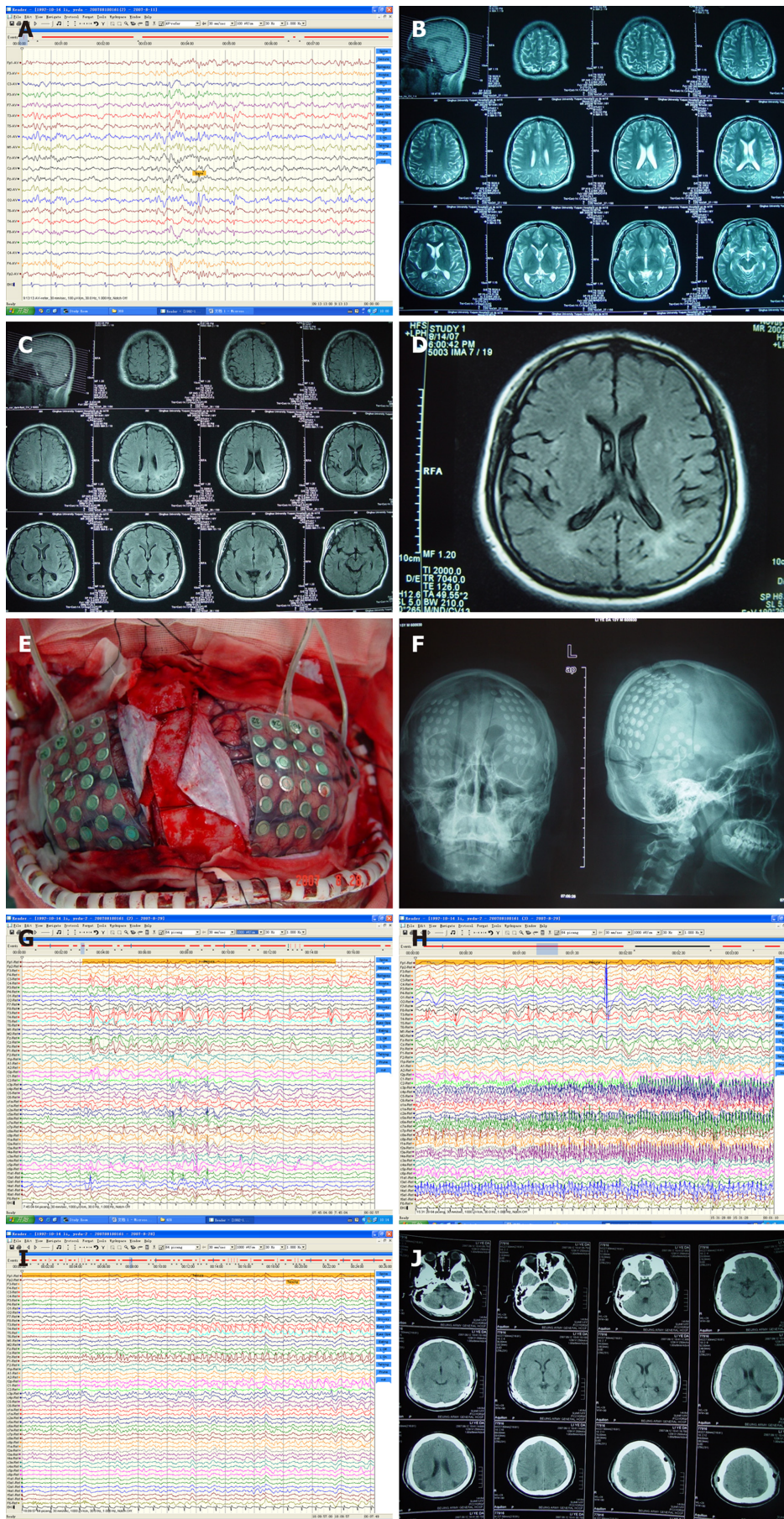


Figure 2 Clinical findings in a 15-year-old male patient with bilateral occipital lobe epilepsy. A: Scalp video-electroencephalography (EEG) recordings demonstrated abnormal discharges in the right occipital region during the interictal period; B and C: magnetic resonance imaging (MRI) revealed abnormal

signals in the bilateral occipital lobe; D: T2-FLAIR MRI showed irregular high signals in the bilateral occipital lobe that suggested ischemic changes; E: A subdural grid electrode was placed during surgery under general anesthesia; F: Anteroposterior and lateral head X-rays (taken after closure of the craniotomy) showing the position of the subdural grid electrode; G-I: Representative EEG recordings made using the subdural grid electrode showing abnormal discharges arising from both sides of the occipital lobe; The upper half of each trace shows recordings obtained from the left occipital lobe, and the lower half of each trace shows recordings obtained from the right occipital lobe; J: Postoperative cranial computed tomography.

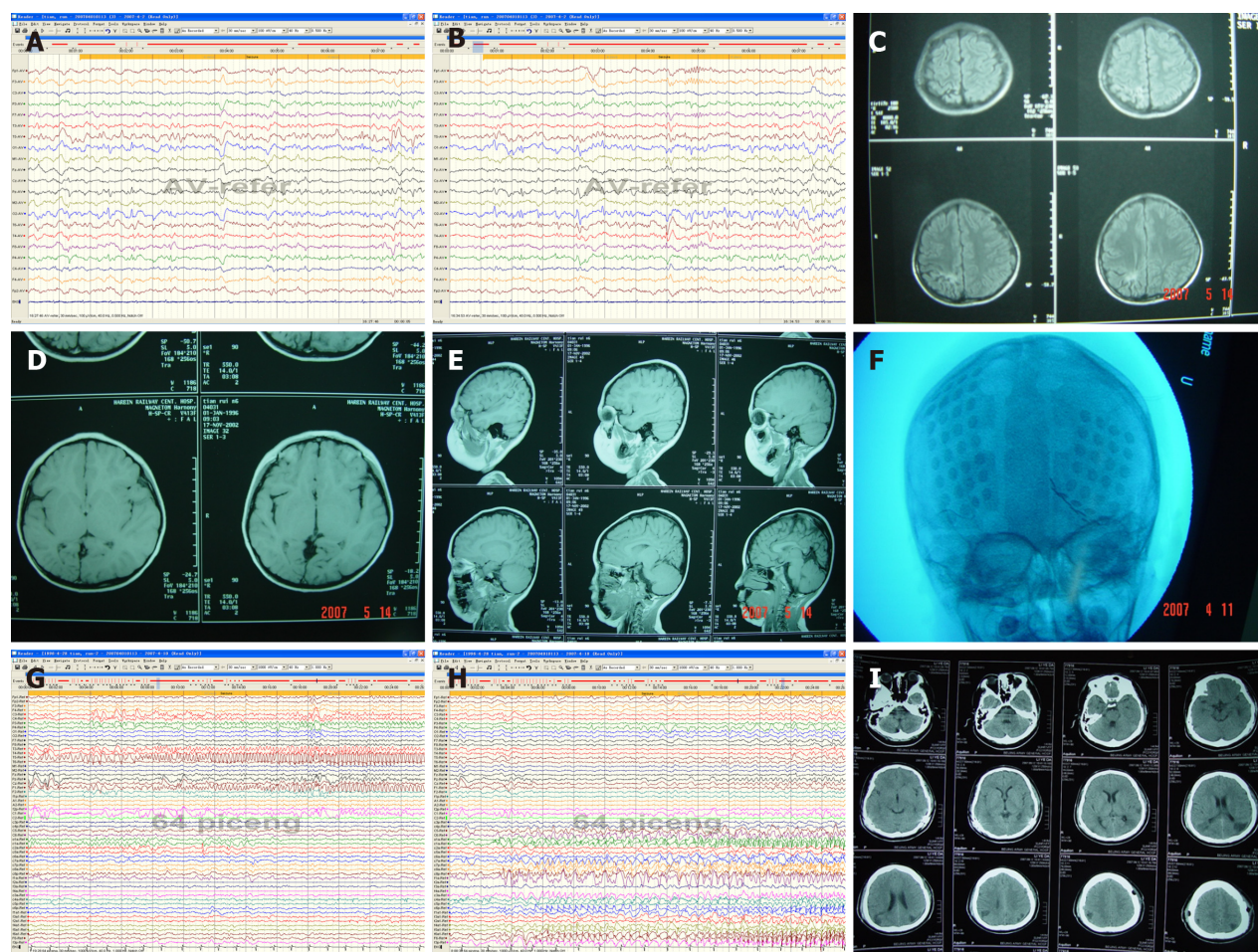


Figure 3 Clinical findings in an 11-year-old male patient with bilateral occipital lobe epilepsy. A: Representative scalp video-electroencephalography (EEG) recording demonstrating abnormal discharges originating in the left occipital region during the interictal period; B: Representative scalp video-EEG recording demonstrating abnormal discharges originating in the right occipital region during the interictal period; C-E: magnetic resonance imaging showing bilateral occipital dysplasia and a high signal on T2-FLAIR imaging that was obvious on the right side; F: Anteroposterior X-ray illustrating the position of the subdural grid electrode; G and H: Representative EEG recordings made using the subdural grid electrode showing abnormal discharges arising from both the left (G) and right (H) sides of the occipital lobe; I: Postoperative cranial computed tomography.

treatment, with most patients (85%) free of disabling seizures at 5 years after neurosurgery and no patients exhibiting no worthwhile improvement. Furthermore, most patients (65%) showed no visual field changes after surgery, although 15% developed a new visual field defect, and 20% exhibited worsening of a preexisting defect. Taken together, our results indicate that the resection of bilateral occipital lobe lesions during a single operation is an effective and safe treatment for bilateral occipital lobe epilepsy.

The clinical manifestations of bilateral occipital lobe epilepsy in our cohort of 20 patients were elementary visual hallucinations, flashing lights, blurred vision, visual field defects, blindness, visual illusions, blinking, a sensation of eye movement, dizziness, and déjà vu. These manifestations are typical of the visual and oculomotor symptoms of occipital lobe epilepsy reported by others[1,7-9,15,19-30]. Although the pathology underlying occipital lobe epilepsy can vary, the pathologic diagnoses made in our patients have also been reported previously[7-9,19-29].

In the present study, 90% of the patients were classified as seizure-free (Engel grade I) postoperatively and at the 1-year follow-up, while 85% were considered seizure-free

at 3 years and ≥ 5 years. In previous clinical research, the proportions of patients with occipital lobe epilepsy achieving a postoperative seizure-free status were reported to be 100% [27], 71% [7], 69% [23], 67% [28], 64% [8], 63% [24], 62% [9], 60% [29], 58% [21], 55% [26], 50% [19,25], and 46% [20,22]. Thus, the effectiveness of our surgical technique was at least comparable to that described in the above studies and in a recent meta-analysis [16]. This would imply that resecting epileptic foci from both sides of the occipital lobe during a single operation does not compromise the clinical effectiveness of surgery.

Lesions to the occipital lobe, which plays a central role in visual function, can result in visual field defects [32]. Thus, occipital lobe surgery for epilepsy is associated with a substantial risk of aggravating existing visual field defects or creating new ones [26]. In previous clinical research, surgical treatment of occipital lobe epilepsy was reported to induce new visual field defects or worsen preexisting visual field defects in 81% [9], 76% [7], 62% [8], 57% [25], 50% [28], 42% [23], and 30% [24] of cases. In the present study, only 15% of patients developed a new visual field defect, and only 20% exhibited aggravation of a preexisting defect. Notably, two of the patients in the present study exhibited substantial improvements in visual function after surgery (as described in the Results section), suggesting that the removal of lesions improved the functioning of remaining healthy brain tissue. Thus, the safety of our technique regarding the preservation of the visual fields appears to be, at the very least, comparable to that described in earlier studies, and some patients may show better visual function after one-stage surgery.

Two interesting additional observations in this study were a reduction in the number and sizes of facial sebaceous adenoma lesions in one patient and the resolution of drug-resistant psoriatic lesions in another patient after surgery. The reasons for these unexpected findings are not known. However, psychological distress is prevalent in people with epilepsy [33], and stress is acknowledged as an aggravating factor for psoriasis [34,35]. Thus, it is possible that the successful surgical treatment of drug-resistant epilepsy had other beneficial effects mediated *via* reduced levels of psychologic stress.

This study has some limitations. First, this was a retrospective analysis and hence was potentially prone to selection bias and information bias. Second, this was a two-center study with a small sample size, so the generalizability of our findings is not known. Third, we did not include a comparator group in which a two-stage (conventional) surgical resection was carried out. A prospective, randomized clinical trial with a comparator group is needed to confirm our results.

CONCLUSION

In conclusion, the resection of bilateral occipital lobe lesions during a single operation is an effective and safe treatment for bilateral occipital lobe epilepsy. The use of this approach would provide several benefits over conventional two-stage treatment, including a shorter treatment cycle, fewer operations/hospitalizations, and lower cost.

ARTICLE HIGHLIGHTS

Research background

Neurosurgical treatment of severe bilateral occipital lobe epilepsy usually involves two operations several months apart.

Research motivation

The surgical treatment of bilateral occipital lobe epilepsy during a single operation would have several potential advantages, such as a reduced number of surgeries and hospitalizations, a shorter treatment time, lower treatment costs, and decreased psychological stress for the patients and their families.

Research objectives

To evaluate surgical resection of bilateral occipital lobe lesions during a single operation as a treatment for bilateral occipital lobe epilepsy.

Research methods

This retrospective case series included patients with drug-refractory bilateral occipital

lobe epilepsy treated surgically between March 2006 and November 2015.

Research results

Most patients were free of disabling seizures (Engel grade I) postoperatively (18/20, 90.0%) and at 1 year (18/20, 90.0%), 3 years (17/20, 85.0%) and \geq 5 years (17/20, 85.0%). No patients were classified Engel grade IV (no worthwhile improvement). After surgery, there was no change in visual function in 13/20 (65.0%), development of a new visual field defect in 3/20 (15.0%), and worsening of a preexisting defect in 4/20 (20.0%).

Research conclusions

Resection of bilateral occipital lobe lesions during a single operation may be applicable in bilateral occipital lobe epilepsy.

Research perspectives

A prospective, randomized clinical trial with a comparator group is needed to confirm our results.

ACKNOWLEDGEMENTS

The authors thank all the patients and their families for their agreement to participate in this study.

REFERENCES

- Adcock JE, Panayiotopoulos CP. Occipital lobe seizures and epilepsies. *J Clin Neurophysiol* 2012; **29**: 397-407 [PMID: 23027097 DOI: 10.1097/WNP.0b013e31826c98fe]
- Dai AI, Akcali A, Varan C, Demiryurek AT. Prevalence of resistant occipital lobe epilepsy associated with celiac disease in children. *Childs Nerv Syst* 2014; **30**: 1091-1098 [PMID: 24566676 DOI: 10.1007/s00381-014-2387-6]
- Boesebeck F, Schulz R, May T, Ebner A. Lateralizing semiology predicts the seizure outcome after epilepsy surgery in the posterior cortex. *Brain* 2002; **125**: 2320-2331 [PMID: 12244088 DOI: 10.1093/brain/awf236]
- Yun CH, Lee SK, Lee SY, Kim KK, Jeong SW, Chung CK. Prognostic factors in neocortical epilepsy surgery: multivariate analysis. *Epilepsia* 2006; **47**: 574-579 [PMID: 16529624 DOI: 10.1111/j.1528-1167.2006.00470.x]
- Traianou A, Patrikelis P, Kosmidis MH, Kimiskidis VK, Gatzonis S. The neuropsychological profile of parietal and occipital lobe epilepsy. *Epilepsy Behav* 2019; **94**: 137-143 [PMID: 30909077 DOI: 10.1016/j.yebeh.2019.02.021]
- Gómez-Porro P, Aledo-Serrano A, Toledano R, García-Morales I, Gil-Nagel A. Genetic (idiopathic) generalized epilepsy with occipital semiology. *Epileptic Disord* 2018; **20**: 434-439 [PMID: 30361187 DOI: 10.1684/epd.2018.0994]
- Yang PF, Jia YZ, Lin Q, Mei Z, Chen ZQ, Zheng ZY, Zhang HJ, Pei JS, Tian J, Zhong ZH. Intractable occipital lobe epilepsy: clinical characteristics, surgical treatment, and a systematic review of the literature. *Acta Neurochir (Wien)* 2015; **157**: 63-75 [PMID: 25278241 DOI: 10.1007/s00701-014-2217-3]
- Heo W, Kim JS, Chung CK, Lee SK. Relationship between cortical resection and visual function after occipital lobe epilepsy surgery. *J Neurosurg* 2018; **129**: 524-532 [PMID: 29076788 DOI: 10.3171/2017.5.JNS162963]
- Kun Lee S, Young Lee S, Kim DW, Soo Lee D, Chung CK. Occipital lobe epilepsy: clinical characteristics, surgical outcome, and role of diagnostic modalities. *Epilepsia* 2005; **46**: 688-695 [PMID: 15857434 DOI: 10.1111/j.1528-1167.2005.56604.x]
- Santangelo G, Trojano L, Vitale C, Improta I, Alineri I, Meo R, Bilo L. Cognitive dysfunctions in occipital lobe epilepsy compared to temporal lobe epilepsy. *J Neuropsychol* 2017; **11**: 277-290 [PMID: 26393407 DOI: 10.1111/jnp.12085]
- Craciun L, Taussig D, Ferrand-Sorbets S, Pasqualini E, Biraben A, Delalande O, Dorison N, Fohlen M, Dorfmueller G, Chipaux M. Investigation of paediatric occipital epilepsy using stereo-EEG reveals a better surgical outcome than in adults, especially when the supracalcarine area is affected. *Epileptic Disord* 2018; **20**: 346-363 [PMID: 30378548 DOI: 10.1684/epd.2018.1000]
- Wong CH, Mohamed A, Wen L, Eberl S, Somerville E, Fulham M, Bleasel AF. Metabolic changes in occipital lobe epilepsy with automatisms. *Front Neurol* 2014; **5**: 135 [PMID: 25101053 DOI: 10.3389/fneur.2014.00135]
- Wang J, Wang Q, Wang M, Luan G, Zhou J, Guan Y, Yan Z. Occipital Lobe Epilepsy With Ictal Fear: Evidence From a Stereo-Electroencephalography (sEEG) Case. *Front Neurol* 2018; **9**: 644

- [PMID: 30131760 DOI: 10.3389/fneur.2018.00644]
- 14 Iyer A, Marson A. Pharmacotherapy of focal epilepsy. *Expert Opin Pharmacother* 2014; **15**: 1543-1551 [PMID: 24856909 DOI: 10.1517/14656566.2014.922544]
 - 15 Aznarez PB, Cabeza MP, Quintana ASA, Lara-Almunia M, Sanchez JA. Evolution of patients with surgically treated drug-resistant occipital lobe epilepsy. *Surg Neurol Int* 2020; **11**: 222 [PMID: 32874725 DOI: 10.25259/SNI_251_2020]
 - 16 Harward SC, Chen WC, Rolston JD, Haglund MM, Englot DJ. Seizure Outcomes in Occipital Lobe and Posterior Quadrant Epilepsy Surgery: A Systematic Review and Meta-Analysis. *Neurosurgery* 2018; **82**: 350-358 [PMID: 28419330 DOI: 10.1093/neuros/nyx158]
 - 17 Lang JD, Grell L, Hagge M, Onugoren MD, Gollwitzer S, Graf W, Schwarz M, Coras R, Blümcke I, Sommer B, Rössler K, Buchfelder M, Schwab S, Stefan H, Hamer HM. Long-term outcome after epilepsy surgery in older adults. *Seizure* 2018; **57**: 56-62 [PMID: 29604610 DOI: 10.1016/j.seizure.2018.02.012]
 - 18 Angus-Leppan H, Clay TA. Adult occipital lobe epilepsy: 12-years on. *J Neurol* 2021; [DOI: 10.1007/s00415-021-10557-y]
 - 19 Kuzniecky R, Gilliam F, Morawetz R, Faught E, Palmer C, Black L. Occipital lobe developmental malformations and epilepsy: clinical spectrum, treatment, and outcome. *Epilepsia* 1997; **38**: 175-181 [PMID: 9048669 DOI: 10.1111/j.1528-1157.1997.tb01094.x]
 - 20 Salanova V, Andermann F, Olivier A, Rasmussen T, Quesney LF. Occipital lobe epilepsy: electroclinical manifestations, electrocorticography, cortical stimulation and outcome in 42 patients treated between 1930 and 1991. Surgery of occipital lobe epilepsy. *Brain* 1992; **115** (Pt 6): 1655-1680 [PMID: 1486456 DOI: 10.1093/brain/115.6.1655]
 - 21 Williamson PD, Thadani VM, Darcey TM, Spencer DD, Spencer SS, Mattson RH. Occipital lobe epilepsy: clinical characteristics, seizure spread patterns, and results of surgery. *Ann Neurol* 1992; **31**: 3-13 [PMID: 1543348 DOI: 10.1002/ana.410310103]
 - 22 Aykut-Bingol C, Bronen RA, Kim JH, Spencer DD, Spencer SS. Surgical outcome in occipital lobe epilepsy: implications for pathophysiology. *Ann Neurol* 1998; **44**: 60-69 [PMID: 9667593 DOI: 10.1002/ana.410440112]
 - 23 Binder DK, Von Lehe M, Kral T, Bien CG, Urbach H, Schramm J, Clusmann H. Surgical treatment of occipital lobe epilepsy. *J Neurosurg* 2008; **109**: 57-69 [PMID: 18590433 DOI: 10.3171/JNS/2008/109/7/0057]
 - 24 Ibrahim GM, Fallah A, Albert GW, Withers T, Otsubo H, Ochi A, Akiyama T, Donner EJ, Weiss S, Snead OC 3rd, Drake JM, Rutka JT. Occipital lobe epilepsy in children: characterization, evaluation and surgical outcomes. *Epilepsy Res* 2012; **99**: 335-345 [PMID: 22260921 DOI: 10.1016/j.eplepsyres.2011.12.015]
 - 25 Jobst BC, Williamson PD, Thadani VM, Gilbert KL, Holmes GL, Morse RP, Darcey TM, Duhaime AC, Bujarski KA, Roberts DW. Intractable occipital lobe epilepsy: clinical characteristics and surgical treatment. *Epilepsia* 2010; **51**: 2334-2337 [PMID: 20662891 DOI: 10.1111/j.1528-1167.2010.02673.x]
 - 26 Kivelev J, Koskela E, Setälä K, Niemelä M, Hernesniemi J. Long-term visual outcome after microsurgical removal of occipital lobe cavernomas. *J Neurosurg* 2012; **117**: 295-301 [PMID: 22702480 DOI: 10.3171/2012.5.JNS112102]
 - 27 Usui N, Mihara T, Baba K, Matsuda K, Tottori T, Umeoka S, Kondo A, Nakamura F, Terada K, Usui K, Inoue Y. Versive seizures in occipital lobe epilepsy: lateralizing value and pathophysiology. *Epilepsy Res* 2011; **97**: 157-161 [PMID: 21885252 DOI: 10.1016/j.eplepsyres.2011.08.004]
 - 28 Tandon N, Alexopoulos AV, Warbel A, Najm IM, Bingaman WE. Occipital epilepsy: spatial categorization and surgical management. *J Neurosurg* 2009; **110**: 306-318 [PMID: 19046038 DOI: 10.3171/2008.4.17490]
 - 29 Urbach H, Binder D, von Lehe M, Podlogar M, Bien CG, Becker A, Schramm J, Kral T, Clusmann H. Correlation of MRI and histopathology in epileptogenic parietal and occipital lobe lesions. *Seizure* 2007; **16**: 608-614 [PMID: 17560810 DOI: 10.1016/j.seizure.2007.04.009]
 - 30 Clarke DF, Tindall K, Lee M, Patel B. Bilateral occipital dysplasia, seizure identification, and ablation: a novel surgical technique. *Epileptic Disord* 2014; **16**: 238-243 [PMID: 24842711 DOI: 10.1684/epd.2014.0658]
 - 31 Engel J. Surgical treatment of the epilepsies. . New York: Raven Press; 1993.
 - 32 Ogawa K, Ishikawa H, Suzuki Y, Oishi M, Kamei S. Clinical study of the visual field defects caused by occipital lobe lesions. *Cerebrovasc Dis* 2014; **37**: 102-108 [PMID: 24435066 DOI: 10.1159/000356848]
 - 33 Kotwas I, McGonigal A, Bastien-Toniazzo M, Bartolomei F, Micoulaud-Franchi JA. Stress regulation in drug-resistant epilepsy. *Epilepsy Behav* 2017; **71**: 39-50 [PMID: 28494323 DOI: 10.1016/j.yebeh.2017.01.025]
 - 34 Rousset L, Halioua B. Stress and psoriasis. *Int J Dermatol* 2018; **57**: 1165-1172 [PMID: 29729012 DOI: 10.1111/ijd.14032]
 - 35 Stewart TJ, Tong W, Whitfield MJ. The associations between psychological stress and psoriasis: a systematic review. *Int J Dermatol* 2018; **57**: 1275-1282 [PMID: 29516474 DOI: 10.1111/ijd.13956]



Published by **Baishideng Publishing Group Inc**
7041 Koll Center Parkway, Suite 160, Pleasanton, CA 94566, USA

Telephone: +1-925-3991568

E-mail: bpgoffice@wjgnet.com

Help Desk: <https://www.f6publishing.com/helpdesk>

<https://www.wjgnet.com>

