

Systematic review of macular ganglion cell complex analysis using spectral domain optical coherence tomography for glaucoma assessment

Amit Meshi, Dafna Goldenberg, Sharon Armarnik, Ori Segal, Noa Geffen

Amit Meshi, Sharon Armarnik, Ori Segal, Noa Geffen, Department of Ophthalmology, Meir Medical Center, Kfar Saba 4428164, Israel

Amit Meshi, Sharon Armarnik, Ori Segal, Noa Geffen, Sackler Faculty of Medicine, Tel Aviv University, Tel Aviv 6423906, Israel

Dafna Goldenberg, Department of Ophthalmology, Tel Aviv Medical Center, Sackler Faculty of Medicine, Tel Aviv University, Tel Aviv 6423906, Israel

Author contributions: Meshi A and Geffen N contributed equally to this work; each one substantially contributed to study design and to writing, to acquisition, analysis and interpretation of the data and performed critical revisions; Goldenberg D participated in the acquisition of the data and in writing, contributed significantly to the analysis of the technical data and performed critical revisions; Armarnik S participated in the acquisition of the data, in writing and approved the final version of the article to be published; Segal O performed critical revision and participated in the acquisition of the data; all authors approved the final version of the article.

Conflict-of-interest: All authors have no conflict of interest related to this work.

Data sharing: No additional data are available.

Open-Access: This article is an open-access article which was selected by an in-house editor and fully peer-reviewed by external reviewers. It is distributed in accordance with the Creative Commons Attribution Non Commercial (CC BY-NC 4.0) license, which permits others to distribute, remix, adapt, build upon this work non-commercially, and license their derivative works on different terms, provided the original work is properly cited and the use is non-commercial. See: <http://creativecommons.org/licenses/by-nc/4.0/>

Correspondence to: Noa Geffen, MD, Glaucoma Consultant, Department of Ophthalmology, Meir Medical Center, 59 Tschernihovsky St., Kfar Saba 4428164, Israel. noatal1122@gmail.com

Telephone: +972-54-2211710

Fax: +972-77-5610362

Received: August 15, 2014

Peer-review started: August 17, 2014

First decision: October 14, 2014

Revised: February 9, 2015

Accepted: April 1, 2015

Article in press: April 7, 2015

Published online: May 12, 2015

Abstract

AIM: To review the use of spectral domain optical coherence tomography (SD-OCT) for macular retinal ganglion cells (RGC) and ganglion cell complex (GCC) measurement in glaucoma assessment, specifically for early detection and detection of disease progression.

METHODS: A systematic review was performed by searching PubMed, Medline, and Web of Science for articles published in English through July 2014 describing the various macular SD-OCT scanning strategies developed for glaucoma assessment. The review focused on papers evaluating the use of macular RGC/GCC SD-OCT to detect early glaucoma and its progression. The search included keywords corresponding to the index test (macular ganglion cell/RGC/GCC/Spectral domain OCT), the target condition (glaucoma), and diagnostic performance. The RGC/GCC SD-OCT scanning strategies used to assess glaucoma of most commonly used SD-OCT instruments were described and compared. These included the Cirrus high definition-OCT (Carl Zeiss Meditec, Inc., Dublin, CA, United States), RTVue (Optovue, Inc., Fremont, CA, United States), Spectralis (Heidelberg Engineering, Heidelberg, Germany) and the 3D OCT 2000 (Topcon Corporation, Tokyo, Japan). Studies focusing on the ability of RGC/GCC SD-OCT to detect early glaucomatous damage and on the correlation between glaucomatous progression and RGC/GCC measurement by SD-OCT were reviewed.

RESULTS: According to the literature, macular RGC/GCC SD-OCT has high diagnostic power of preperimetric glaucoma, reliable discrimination ability to differentiate between healthy eyes and glaucomatous eyes, with

good correlation with visual field damage. The current data suggests that it may serve as a sensitive detection tool for glaucomatous structural progression even with mild functional progression as the rate of change of RGC/GCC thickness was found to be significantly higher in progressing than in stable eyes. Glaucoma assessment with RGC/GCC SD-OCT was comparable with and sometimes better than circumferential retinal nerve fiber layer thickness measurement.

CONCLUSION: An increasing body of evidence supports using macular RGC/GCC thickness as an indicator for early glaucoma. This might be a useful tool for monitoring disease progression.

Key words: Glaucoma; Optical coherence tomography; Spectral domain optical coherence tomography; Retinal ganglion cell; Ganglion cell complex

© **The Author(s) 2015.** Published by Baishideng Publishing Group Inc. All rights reserved.

Core tip: Glaucoma is an optic neuropathy characterized by structural changes followed by functional deficits. Diagnosing early signs of the disease and detecting its progression are challenging. This review focuses on the most common macular retinal ganglion cells/ganglion cell complex spectral domain optical coherence tomography (SD-OCT) scanning strategies developed for glaucoma assessment (Cirrus high definition-OCT, RTVue, Spectralis and 3D OCT 2000) described in the literature published through July 2014; specifically, studies that assessed the ability to diagnose early glaucoma and glaucoma progression. The findings highlight the central role of macular SD-OCT in identifying subjects with early and progressive anatomical and functional glaucomatous damage.

Meshi A, Goldenberg D, Armarnik S, Segal O, Geffen N. Systematic review of macular ganglion cell complex analysis using spectral domain optical coherence tomography for glaucoma assessment. *World J Ophthalmol* 2015; 5(2): 86-98 Available from: URL: <http://www.wjgnet.com/2218-6239/full/v5/i2/86.htm> DOI: <http://dx.doi.org/10.5318/wjo.v5.i2.86>

INTRODUCTION

Glaucoma is the leading cause of irreversible loss of vision, globally. In 2013, glaucoma was estimated to affect 64.3 million people 40-80 years-of-age, with this number increasing to 76.0 million by 2020 and 111.8 million by 2040^[1]. Glaucoma is an optic neuropathy characterized by loss of retinal ganglion cells (RGC), thinning of the circumferential retinal nerve fiber layer (cpRNFL) and the neuroretinal rim, and increased cupping^[2,3]. It is often asymptomatic until the later stages and structural alterations usually appear before functional changes and prior to repeatable visual field

deficits^[4-6]. Early detection of the disease can lead to earlier treatment that might improve prognosis. The primary challenges in glaucoma assessment are diagnosing early signs of the disease and detecting disease progression.

Various tools are used for glaucoma assessment. Optical coherence tomography (OCT) has become a main modality. OCT is a micron-level, diagnostic method that uses 800-840 nm wavelength infrared light to provide high-resolution, non-invasive neural imaging. It is based on the principle of Michelson interferometry^[7]. An interference pattern is produced by splitting a beam of light into two. The two bouncing beams, one beam from the targeted tissue and the other from a reference mirror, and then recombined through the use of semi-transparent mirrors^[8].

OCT has become a well-established tool for diagnosing and monitoring diseases of the retina, choroid^[8-11] and optic nerve head (ONH)^[12-14], as well as anterior-segment conditions^[15,16]. Time-domain (TD) and more recently spectral-domain (SD) OCT have significantly improved the ability to manage patients with retinal diseases and glaucoma^[17].

OCT is commonly used for glaucoma to assess ONH and retinal nerve fiber layer (RNFL) thickness^[18]. RNFL thickness measurements with OCT have good reproducibility, an established structural-functional relationship and can detect glaucoma progression^[19,20]. OCT has improved the ability to discriminate healthy eyes from those with glaucoma^[17,20,21]. However, cpRNFL thickness measurement with OCT is limited by significant variations in the shape and size of the ONH, refractive error, axial length and peripapillary atrophy. Healthy eyes sometimes have unusual anatomical features that confuse currently available diagnostic software, and they are mistakenly classified as abnormal^[18]. Myopia is a very good example of this problem, as it is commonly associated with high variability in RNFL. Several studies reported that the average RNFL becomes thinner as the degree of myopia increases^[22-24]. Moreover, RNFL thickness frequently varies by sector in patients with myopia, as their temporal RNFL tends to be much thicker^[25,26]. Thus, caution should be taken while observing RNFL thickness in eyes with various cpRNFL abnormalities and pathologies, such as myopia, as normative data provided by OCT may be unreliable in these cases.

Glaucoma evaluation by macular imaging was first suggested by Zeimer *et al.*^[27]. The macula has several physiological and anatomical advantages. As the RNFL is comprised of RGC axons, assessing the RGC may be a more direct way to measure ocular damage due to glaucoma than measurement of the cpRNFL thickness. The macula is the only place where more than one RGC body is found in the ganglion cell layer of the retina and because the body of the cell is much larger than the soma, it might be easier to detect glaucoma related cellular damage^[27,28]. Additionally, more than half of all the RGC in the retina are in the macula. Thus, macular

Table 1 Properties of the various spectral domain optical coherence tomography instruments

	Cirrus HD-OCT (Carl Zeiss Meditec, Inc., Dublin CA, United States)	RTVue (Optovue, Inc., Fremont, CA, United States)	Spectralis (Heidelberg Engineering, Heidelberg, Germany)	3D OCT 2000 (Topcon Corporation, Tokyo, Japan)
Macular layer measured	GCIP	GCC	The entire retina (from =BM to ILM)	Macular RNFL GCIP (GCL+) GCC (GCL++)
Maps provided	Thickness map, deviation map and sectors	Thickness map, deviation map and significance map	Thickness map, asymmetry map, hemisphere asymmetry map and mean thickness map	Thickness map, significance map, average thickness asymmetry map
Grid dimensions (mm)	6 × 6	7 × 7	8 × 8	6 × 6

OCT: Optical coherence tomography; GCIP: Combined retinal ganglion cell (RGC) and inner plexiform layer (IPL); RNFL: Retinal nerve fiber layer; GCC: Ganglion cell complex = macular RNFL + GCIP; BM: Bruchs membrane; ILM: Internal limiting membrane.

scanning allows most of the RGC to be sampled. In general, the shape of the RGC layer in the macular area is more consistent among healthy individuals than the RNFL in the ONH area. The macular RGC might provide a more sensitive measure than the cpRNFL because variations in this layer are likelier be result from pathological changes rather than normal variations^[29].

MATERIALS AND METHODS

A systematic review was performed by searching PubMed, Medline, and Web of Science for articles published in English through July 2014 describing the various macular SD-OCT scanning strategies developed for glaucoma assessment. The search included keywords corresponding to the index test macular/RGC/ganglion cell complex (GCC) SD-OCT, the target condition (glaucoma), and diagnostic performance. Studies were included if they met the following criteria: (1) the study assessed diagnostic performance of macular/RGC/GCC SD-OCT in glaucoma patients; (2) the study evaluated early detection of glaucoma; and (3) the study assessed glaucoma progression. Relevant references used in included studies were also evaluated.

RESULTS

Using RGC/GCC OCT to assess glaucoma is a relatively new concept. Systematic review of the literature revealed an increasing number of papers dealing with this subject. SD-OCT has enabled measurements of the RGC in the macula and the retinal GCC, including the RNFL^[30,31]. GCC thickness is defined by the distance from the internal limiting membrane to the outer boundary of the inner plexiform layer (IPL), which comprises the inner 3 layers of the retina (RNFL, ganglion cell layer and inner plexiform layer). Glaucoma affects all of these three layers^[32]. Another way to evaluate glaucomatous macular damage is to measure the entire retinal thickness rather than ganglion cell layer alone, as is done by the Spectralis OCT (Heidelberg Engineering, Heidelberg, Germany). Kita *et al.*^[33] introduced a new parameter, the ratio of macular GCC thickness divided by the corresponding total retinal thickness (G/T). In a study conducted on a Japanese population to

differentiate between healthy eyes and those with open angle glaucoma, a decreased G/T ratio was found in the early stages of glaucoma. However, Holló *et al.*^[34] showed that the diagnostic accuracy of the G/T ratio in Europeans was consistently lower than measurements of RNFL thickness and GCC parameters provided by several software.

Most commonly used SD-OCT instruments for glaucoma assessment

Various macular scanning strategies were developed for glaucoma assessment using SD-OCT. The most commonly used SD-OCT instruments are Cirrus HD-OCT (Carl Zeiss Meditec, Inc., Dublin, CA, United States), RTVue (Optovue, Inc., Fremont, CA, United States), Spectralis (Heidelberg Engineering, Heidelberg, Germany) and 3D OCT 2000 (Topcon Corporation, Tokyo, Japan).

The macular scanning methodology for glaucoma assessment employed by each of the devices is explained below. Table 1 compares the properties of the various SD-OCT instruments.

Cirrus HD-OCT (Carl Zeiss Meditec, Inc., Dublin, CA, United States):

The Cirrus HD-OCT evaluates the thickness of the ganglion cell and IPL combined (Figure 1A), using the Macular Cube 200 × 200 or 512 × 128 scan patterns. The scan generates data in a 6 mm × 6 mm grid that consists of 200 frames of horizontal linear B-scans with 200 A-scan lines per B-scan. The segmentation software calculates the thickness of the macular ganglion cell-inner plexiform layer from an elliptical annulus centered on the fovea (thickness map) (Figure 1B) and calculates the thicknesses of the combined ganglion cell and IPL. The results are compared to normative data (Deviation map) (Figure 1C). The ganglion cell analysis segmentation algorithm divides the elliptical annulus of the Thickness Map into 6 equal sectors expressed in micrometers. Each spoke represents the average number of pixels along that spoke that lie within the measurement annulus (Figure 1D)^[29,35-38].

RTVue (Optovue, Inc., Fremont, CA, United States):

The RTVue measures the GCC by scanning 1

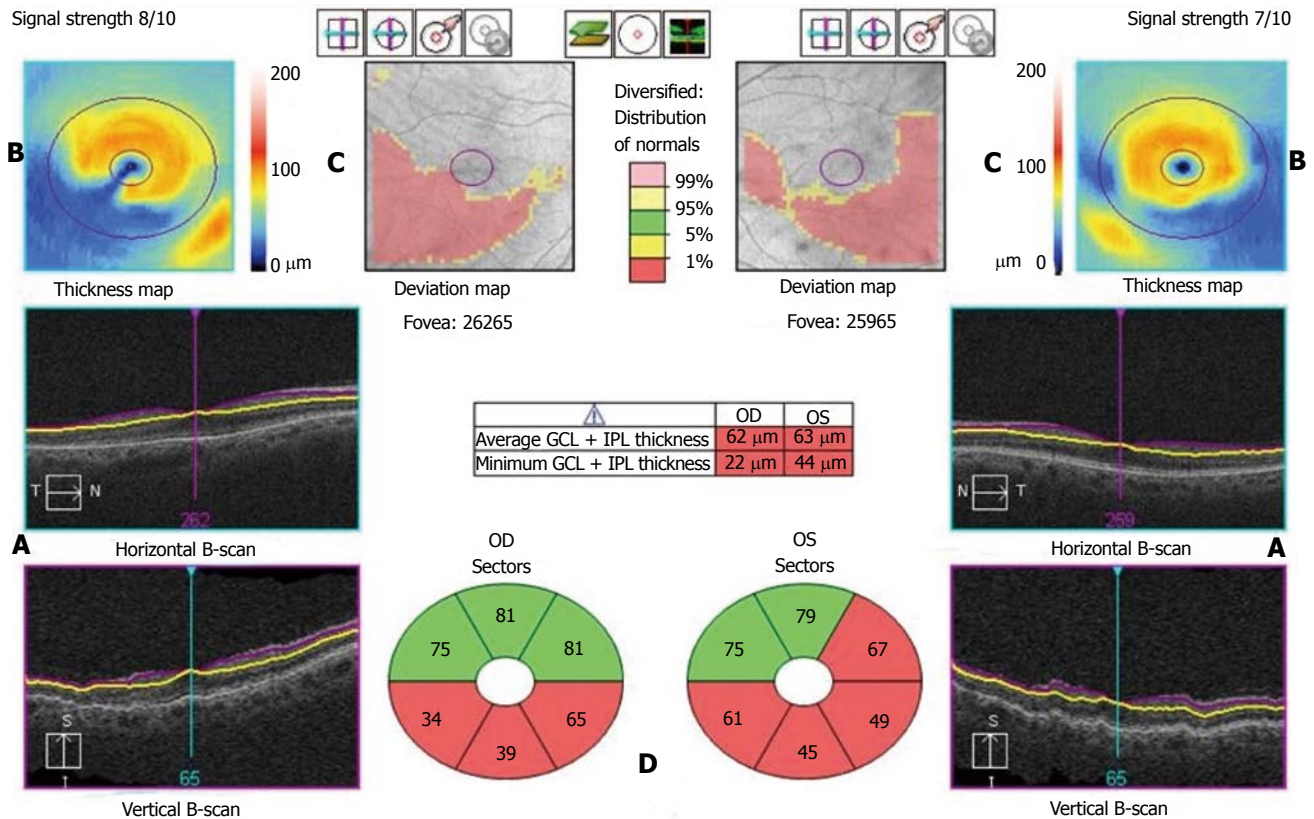


Figure 1 Cirrus HD-optical coherence tomography. A: Segmentation. Horizontal and vertical B-scans. The purple line represents the inner boundary of the ganglion cell layer and the yellow line represents the outer boundary of the inner plexiform layer; B: Thickness map. Calculation of the ganglion cell layer (GCL) + inner plexiform layer (IPL) thickness data from an elliptical annulus, 6 mm \times 6 mm grid, centered on the fovea; C: Deviation map. Comparison of the GCL + IPL thickness results to a normative database; D: Sectors. Ganglion cell analysis segmentation algorithm that divides the elliptical annulus of the thickness map into 6 equal sectors expressed in micrometers. Each spoke represents the average of the pixels along that spoke that lie within the measurement annulus.

horizontal line and 15 vertical lines at 0.5 mm intervals covering a 7 mm² region centered on the fovea. It obtains 14928 A-scans within 0.6 s. The OCT scans are processed to provide a map of the thickness of the GCC (Figure 2A). It also provides pattern-based parameters of focal loss volume (FLV) and global loss volume (GLV). GLV corresponds to the total deviation map and FLV to the pattern deviation map that is used with visual field tests^[18]. A deviation map is calculated by comparing the thickness map to the normative databases (Figure 2B)^[39,40]. RTVue also provides a significance map that illustrates the areas where there is a statistically significant change from normal (Figure 2C).

Spectralis (Heidelberg Engineering, Heidelberg, Germany): The Spectralis OCT measures the entire retinal thickness rather than ganglion cell layer. It uses 61 lines (30° \times 25° OCT volume scan) to measure the retinal thickness in the posterior pole for each eye in a central 20° area. A color-coded thickness map for an 8 \times 8 grid centered on the foveal pit is shown (Figure 3A). The grid is symmetrical to the fovea-to-disc axis of each eye. The Spectralis examines asymmetry between the eyes (Figure 3B). It also displays the asymmetry between the superior and the inferior hemisphere of each eye (hemisphere asymmetry) (Figure 3C)^[41,42]. It also provides a mean thickness map (Figure 3D).

3D OCT 2000 (Topcon, Inc., Tokyo, Japan): The Topcon 3D OCT 2000 measures the RNFL thickness, the RGC with the IPL (GCIP), and the GCC. It uses raster scanning of a 7 mm² area that is centered on the fovea with a scan density of 128 (horizontal) \times 512 (vertical) scans (Figure 4A). The boundaries of the anatomical layers are determined by the program software (version 8.00; Topcon, Inc., Tokyo, Japan) using a validated, automated segmentation algorithm. The macular inner retinal layers (MIRL) analysis software detects the center of the fovea at the macular cube automatically, and selects a 6 mm \times 6 mm region centered at the foveal center. The software divides the macular square into a 6 \times 6 grid containing 100 cells of 0.6 mm \times 0.6 mm, to assess regional abnormalities in MIRL thickness. Average regional thickness of GCC, GCIP and RNFL in each cell is calculated and compared to the normative database of the device^[43,44] (Figure 4B).

Table 2 summarizes the characteristics of the major studies reviewed in this paper.

DISCUSSION

Comparing results between different SD-OCT devices

The literature comparing results between different SD-OCT devices is relatively sparse. Previous studies revealed that cpRNFL measurements from healthy

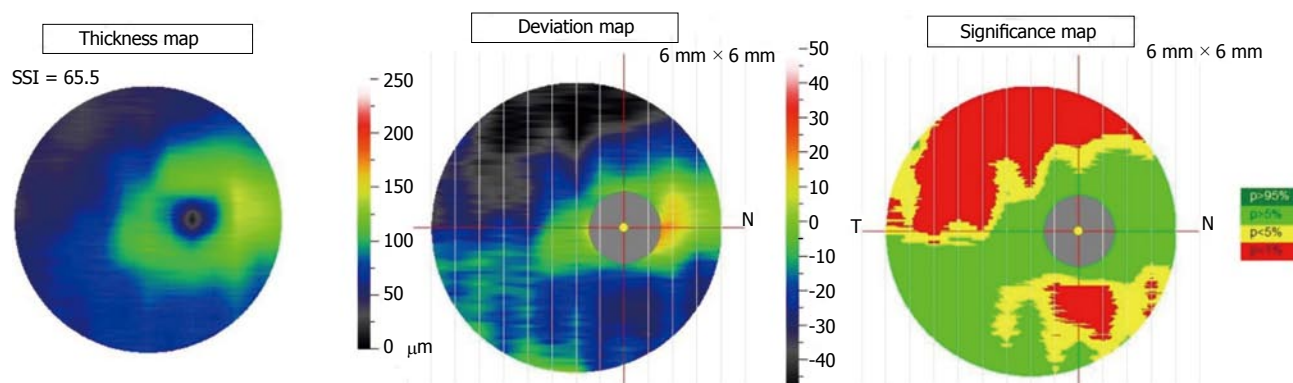


Figure 2 RTVue. A: Thickness map. The thickness map is color coded where thicker regions of the ganglion cell complex are displayed in hot colors (yellow and orange), and thinner areas are displayed in cooler colors (blue and green); B: Deviation map. Calculated based on comparing the thickness map to the normative databases. The deviation map shows the percent loss from normal as determined by the normative database; C: Significance map. Shows regions where the change from normal reaches statistical significance. The significance map is color-coded where green represents values within the normal range ($P = 0.05-0.95$), yellow indicates borderline results ($P < 0.05$), and red represents outside normal limits ($P < 0.01$).

Asymmetry analysis single exam report OU
SPECTRALIS® Tracking laser tomography

HEIDELBERG
ENGINEERING

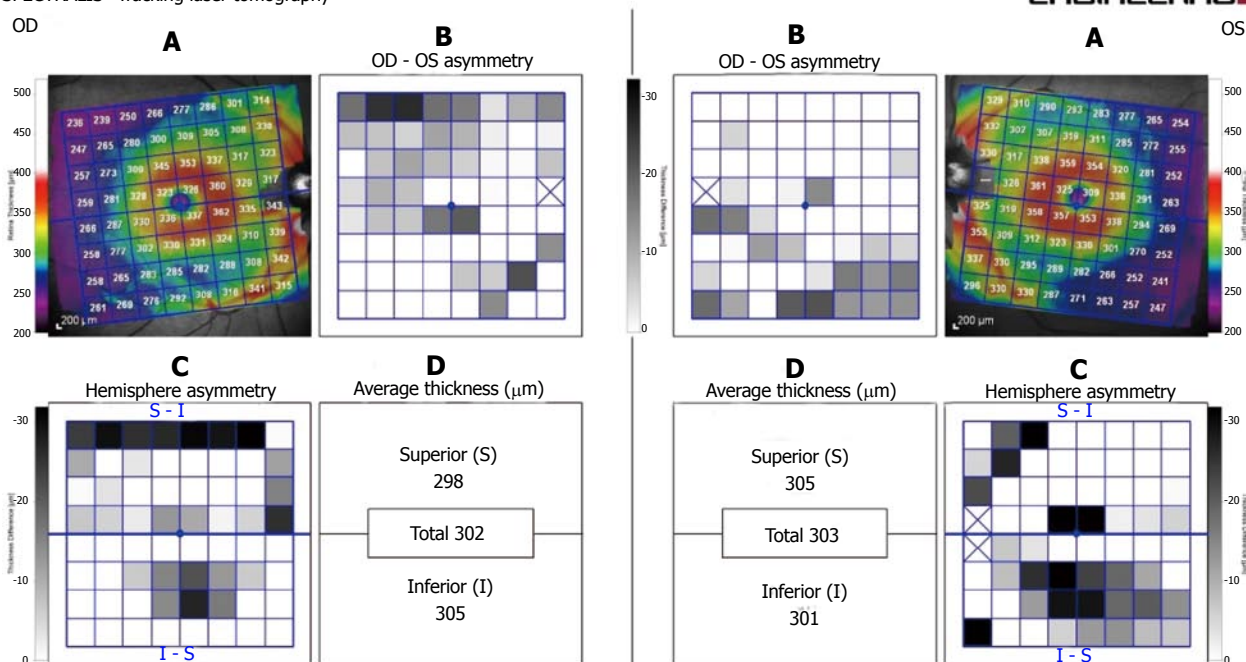


Figure 3 Spectralis. A: Thickness map - the entire retinal thickness in the posterior pole displayed as a color coded thickness map for an 8×8 grid centered on the foveal pit positioned symmetrically to the fovea-disc axis; B: Asymmetry map - examination by grid of the asymmetry between the thicknesses in the corresponding cell of the fellow eye. Asymmetry color scale - darker grey indicates larger differences. The closer the value is to zero (white color), the better the symmetry; C: Hemisphere analysis - displays the asymmetry between the superior and the inferior hemisphere of each eye. The fovea-disc axis is the horizontal symmetry line. The lower half compares the inferior to the superior; D: Mean thickness - represents the mean retinal thickness for the superior and inferior hemisphere, as well as the total mean thickness over the entire 8×8 grid.

controls using several devices varied and could not be interchanged^[45,46]. Nonetheless, the diagnostic performance of most devices was similar when measuring cpRNFL thickness for glaucoma detection^[47]. The Cirrus OCT and 3D OCT devices demonstrated similar accuracy when detecting a localized RNFL defect^[48]. Furthermore, review of the literature revealed only a few papers that compared RGC/GCC SD-OCT measurements from different OCT devices in glaucoma patients. Kim *et al.*^[48] compared the GCC parameters

between Cirrus OCT and 3D OCT. Among the macular GCC parameters of the 3D OCT device, inferior macular RNFL thickness had the highest sensitivity (81.2% at a specificity of 80%) and the largest area under the curve (AUC) (0.89)^[48].

Akashi *et al.*^[49] compared the macular analysis results of the Cirrus, RTVue and 3D OCT in glaucoma patients. They found that the use of average GCC thickness for diagnosing glaucoma stages did not differ significantly among the three SD-OCT instruments.

Table 2 Summary of major studies investigating macular spectral domain optical coherence tomography for glaucoma assessment

Ref.	SD-OCT instrument	Patients	Type of glaucoma assessment	Main outcomes
Tan <i>et al</i> ^[39]	RTVue	310 eyes: 125 normal, 76 PPG, 109 PG	Glaucoma detection	GCC thickness had significantly higher diagnostic power than macular retinal thickness in differentiating between PPG and normal eyes
Kim <i>et al</i> ^[43]	3D OCT 2000	204 eyes: 64 normal, 68 PPG, 72 early PG	Glaucoma detection	GCC thickness steadily decreased from normal to PPG to early glaucoma. GCIP and GCC, but not mNFL were significantly different between PPG and controls and had similar discrimination ability as cpRNFL analysis
Lee <i>et al</i> ^[44]	3D OCT 2000	63 early PG eyes, 33 with and 30 without paracentral VF defects	Assessment of paracentral VF defects	Regional structural assessment of MIRL was a better indicator of paracentral scotoma than cpRNFL measurements (AROC 0.77 <i>vs</i> 0.644, respectively)
Akashi <i>et al</i> ^[49]	Cirrus, RTVue, 3D OCT 2000	232 eyes: 87 normal, 145 PG	Glaucoma detection ability in different SD-OCT instruments	Diagnosis of glaucoma with average GCC thicknesses was similar between the three SD-OCT instruments. RTVue exhibited better diagnostic abilities than Cirrus and 3D OCT 2000 for superior GCC thickness
Rolle <i>et al</i> ^[50]	RTVue	271 eyes: 163 with positive family history of POAG, 108 eyes without	Glaucoma detection	RNFL superior, GCC average, GCC superior and GCC inferior were significantly thinner and the GLV was higher in healthy eyes with a positive family history of POAG than in normal eyes without history
Kim <i>et al</i> ^[51]	Spectralis	106 PG eyes	Assessment of macular thickness and visual field defects	A significant relationship between VFS and MRT values was found and was strongest in the arcuate region. About 17% structural loss was necessary to detect functional loss
Inuzuka <i>et al</i> ^[52]	Cirrus	67 PG eyes	Glaucoma detection	GCC thickness of the inner or outer sector of the parafovea decreased as the corresponding hemifield defect increased. GCC thickness changes in apparently normal hemifield correlated with progression of the glaucomatous defects
Seong <i>et al</i> ^[53]	RTVue	167 eyes: 65 normal, 102 NTG	NTG assessment	MIRL thickness was strongly correlated and glaucoma discrimination ability was comparable with cpRNFL thickness in early VF defects. cpRNFL had better diagnostic ability than MIRL in eyes with advanced or peripheral VF defects
Na <i>et al</i> ^[55]	RTVue	173 eyes: 68 normal, 105 PPG	Glaucoma detection	PPG patients had significantly reduced GCC thickness in all sectors compared to healthy subjects. Superior GCC thickness average was best for detecting localized RNFL defects
Rao <i>et al</i> ^[56]	RTVue	106 eyes: 34 PPG, 72 with large physiologic optic disc cupping	Glaucoma detection	GCC parameters had moderate diagnostic ability to differentiate PPG from large physiologic cups. Inferior quadrant GCC thickness had the best AROC (0.75)
Iverson <i>et al</i> ^[57]	RTVue	97 eyes: 23 normal, 74 PPG	Glaucoma detection	GCC thickness had high specificity (91%) in normal eyes and moderate specificity (77%) in glaucoma suspects. About half of GCC measurements classified as outside normal limits were not replicable
Mwanza <i>et al</i> ^[58]	Cirrus	99 eyes: 49 normal, 50 early PG	Glaucoma detection	GCIP parameters were significantly thinner in the glaucoma compared to the control group. Diagnosis based on at least 1 abnormal GCIP parameter yielded 88% sensitivity and 81.6% specificity
Kim <i>et al</i> ^[60]	RTVue	186 PG eyes	Structural-functional relationship	All GCC parameters significantly correlated with best corrected visual acuity in severe, but not in early-to-moderate glaucoma patients
Leung <i>et al</i> ^[62]	Cirrus	222 eyes: 72 normal, 150 PG	Impact of age on glaucoma progression evaluation	Age-related change in macular measurements affected analysis of glaucoma progression. This was more substantial in macular than in cpRNFL progression
Sung <i>et al</i> ^[65]	Cirrus	98 advanced PG eyes	Glaucoma progression detection	Difference in the rate of change of average macular thickness was significant between progressors and non-progressors, but not in average cpRNFL thickness
Na <i>et al</i> ^[66]	Cirrus	279 PG eyes	Glaucoma progression detection	Differences in the rate of change of average macular and cpRNFL thickness were significant between progressors and non-progressors
Naghizadeh <i>et al</i> ^[67]	RTVue	68 eyes: 17 normal, 51 PG	Glaucoma progression detection	GLV and FLV detected structural progression even with mild functional progression. Progression rates were significantly different between progressing and stable eyes
Anraku <i>et al</i> ^[68]	RTVue	56 PG eyes	Glaucoma progression detection	Baseline GCC (average and inferior hemifield) were significantly thinner in fast progressors compared to slow progressors

SD-OCT: Spectral-domain optical coherence tomography; PPG: Pre-perimetric glaucoma; PG: Perimetric glaucoma; GCC: Ganglion cell complex; GCIP: Combined retinal ganglion cell and inner plexiform layer; mNFL: Macular nerve fiber layer; cpRNFL: Circumpapillary retinal nerve fiber layer; VF: Visual fields; MIRL: Macular inner retinal layers; AROC: Area under the receiver operating characteristics curve; POAG: Primary open-angle glaucoma; GLV: Global loss volume; VFS: Visual field sensitivity; MRT: Mean retinal thickness; NTG: Normal tension glaucoma; FLV: Focal loss volume.

However, the RTVue provided better measurement of the superior hemi-field GCC thickness than did Cirrus and 3D-OCT.

Early detection of glaucoma using macular SD-OCT

Diagnosing the early signs of the disease can be challenging and macular analysis with SD-OCT for this

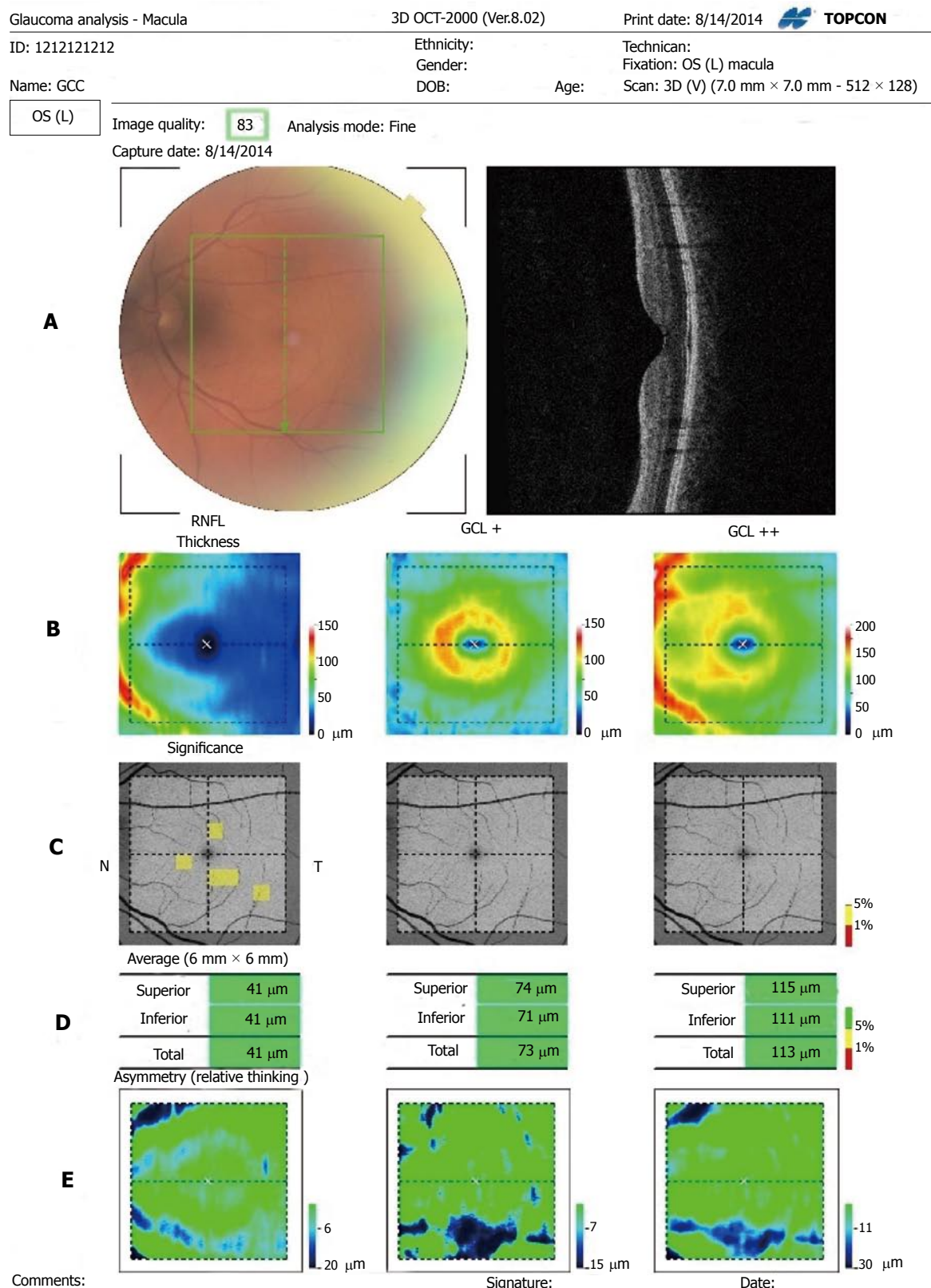


Figure 4 Three dimensions optical coherence tomography 2000. A: Segmentation: 7 mm² area centered on the fovea with a scan density of 512 vertical × 128 horizontal scans; B: Thickness map. Average regional thickness is calculated for RNFL, GCL+ (GCL + IPL), GCL++ (RNFL + GCL + IPL). Each cell is calculated and compared to the normative database of the device; C: Significance map. From left to right, 10 × 10 grid comparison maps covering 6 mm × 6 mm area of RNFL, GCL+ and GCL++ are shown. The comparison result is displayed with the color in the legend on the right. The background image is red free image; D: Average thickness. From left to right, three average thicknesses of RNFL, GCL+ and GCL++. The top is "Superior" which means average in the upper half area, the middle is "Inferior" which means average in the lower half area, and the bottom is "Total" which means average in the total area. Each average thickness is compared to the normative data and displayed according to color; E: Asymmetry map. From left to right, subtraction thickness maps covering 6 mm × 6 mm area of RNFL, GCL+ and GCL++ are shown. The subtraction is performed between two points which symmetrically lie with respect to the center horizontal line. In the upper half, the value in each point is calculated such that thickness of the point is subtracted from the thickness of the corresponding line-symmetry point below and vice versa. Blue indicates that the thickness of the point is thinner than that of the corresponding point. RNFL: Retinal nerve fiber layer; GCL: Ganglion cell layer; IPL: Inner plexiform layer.

purpose has recently received much attention. Tan *et al.*^[39] measured macular retinal thickness and GCC thickness with the RTVue OCT. They reported that the mean GCC had significantly higher diagnostic power than the macular retinal thickness for both SD-OCT and TD-OCT for discriminating between normal eyes and those with perimetric glaucoma. They also found that the diagnostic powers of the best GCC parameters were equal to that of the mean TD-OCT RNFL.

Kim *et al.*^[43] compared the GCC thickness measured by 3D OCT 2000 in three groups: healthy eyes, eyes with pre-perimetric glaucoma (PPG) and eyes with early glaucoma. They found that all GCC parameters decreased from normal to PPG and from PPG to early glaucoma. The values of the GCIP and GCC parameters differed significantly among the three groups ($P < 0.001$). However, the RNFL thickness of the macula between the healthy eyes and those with PPG was not significantly different ($P > 0.05$).

Rolle *et al.*^[50] used RTVue OCT to study early structural changes of RNFL and GCC in patients with a family history of primary open angle glaucoma (POAG). They included 163 eyes of first and second degree relatives (85 healthy, 40 with ocular hypertension and 38 with PPG) and 108 eyes of subjects with no family history (60 healthy and 48 PPG). They found that RNFL superior, GCC average, GCC superior, and GCC inferior were thinner ($P < 0.05$) in healthy eyes of patients with a family history of glaucoma than in normal eyes with no such history. They also showed that subjects with a glaucomatous sibling had significantly thinner RNFL and GCC than those with a single parent affected by the disease. These findings highlight the central role of SD-OCT in identifying individuals with early anatomical damage from glaucoma, even in eyes that appear normal.

The correlation between early glaucomatous visual field (VF) defects and macular ganglion cell layer assessment by OCT was investigated. Kim *et al.*^[51] evaluated the point-wise relationships between visual field sensitivity (VFS), measured by standard automated perimetry (SAP) and macular thickness, as determined by Spectralis-OCT, in glaucoma patients. They examined the correlation between the retinal sensitivities of 16 central test points from the SAP (Humphrey field analyzer) and Spectralis macular volume scans. They measured the macular thickness in 4 square cells in an 8×8 posterior pole retinal thickness map. The values were averaged for a mean retinal thickness (MRT) value, which corresponded to the 16 central test points in the SAP. A significant relationship between the MRT values and the corresponding VFS of each 16 central test point was found. They also showed that the level of the relationship varied among different sectors of the macula, showing the most significant relationship in the arcuate region. The study revealed that substantial structural loss (approximately 17%) appears to be necessary for detection of functional loss, using SD-OCT. Kim *et al.*^[51] concluded that from

a clinical point of view, structural evaluation may be a more sensitive measure of ocular health in early stage glaucoma, whereas the functional evaluation may be a more sensitive and accurate measure of glaucoma progression at moderate-to-advanced stages. Inuzuka *et al.*^[52] examined the relationship between GCC thickness and its corresponding superior or inferior visual hemifield defects. They found that the thickness of the GCC at the inner and outer sectors of the parafovea decreased significantly as the corresponding hemifield defect increased. They also demonstrated that the GCC thickness correlated with changes in the corresponding hemifield that seemed normal. Their findings suggest that in glaucoma patients, changes in the GCC thickness occur before the VF worsens, even when the hemifield appears normal. This correlated with the severity of the disease. Thus, macular GCC thickness is an important indicator for glaucoma risk and may be a useful parameter for monitoring changes in patients with early or pre-perimetric glaucoma.

There is an increasing body of evidence to support the hypothesis that MIRL parameters are comparable to those of cpRNFL thickness in terms of the ability to diagnose glaucoma early. This is especially useful when cpRNFL measurements are not reliable, such as in eyes with extremely small or large optic discs, in tilted optic discs or peripapillary atrophy. Seong *et al.*^[53] used the RTVue OCT to compare the ability of MIRL thickness and cpRNFL thickness measurements to detect glaucoma. They showed that MIRL thickness was strongly correlated with cpRNFL thickness, and that MIRL thickness was able to discern glaucoma similar to cpRNFL thickness with early VF defects. However, cpRNFL measurement was better at diagnosing glaucoma than MIRL measurements in eyes with advanced or peripheral VF defects. Similar correlations between VF mean sensitivity, GCC, and cpRNFL thickness in glaucomatous eyes were reported by Cho *et al.*^[54]. Na *et al.*^[55] showed that pre-perimetric glaucoma patients with localized RNFL defects observed in red-free fundus photography had significantly thinner GCC measured by RTVue OCT, in all sectors compared to healthy individuals. The superior average GCC thickness was the best GCC parameter for detecting localized RNFL defects. It had similar area under receiver operating characteristic curve (AROC) values (0.84) to that of cpRNFL average thickness (0.89). Lee *et al.* compared MIRL and cpRNFL measurements in discriminating between eyes with and without paracentral scotoma^[44]. They included 63 eyes with early glaucoma with (33 eyes) or without (30 eyes) paracentral VF defects. Differences between the groups were significant in all of the MIRL parameters, but only in some cpRNFL parameters. The AROC for discriminating between groups was better for MIRL (0.77) than for cpRNFL (0.644) parameters. This study suggested that regional structural assessment of MIRL was a stronger indicator of scotoma in the paracentral area than cpRNFL measurements. On the other

hand, using various scanning protocols of the RTVue OCT, including GCC parameters, Rao *et al.*^[56] found only moderate diagnostic abilities in differentiating PPG eyes from eyes with large physiologic cups. The GCC parameter with best AUC was inferior quadrant GCC thickness (0.75). Including subjects with large physiologic cups as the control group in this study might have obscured the differences between normal and abnormal eyes.

High specificity of macular analysis is needed to avoid false positive identification of glaucoma among healthy eyes. Iverson *et al.*^[57] conducted a prospective, longitudinal study and found a high specificity (91%) for GCC thickness parameters in normal eyes, but only moderate specificity (77%) in glaucoma suspects, during the course of 43 mo of follow-up. Approximately half of the GCC measurements classified as outside normal limits were not replicable on subsequent scans. Mwanza *et al.*^[58] examined the diagnostic performance of GCIP thickness (Cirrus HD-OCT) between early glaucoma patients and normal controls. GCIP parameters were significantly thinner in the glaucoma group compared with controls. The best discriminant was the minimum, with 82% sensitivity and 87.8% specificity. Its performance was similar to that of the best RNFL and ONH parameters. The diagnosis was based on at least 1 abnormal GCIP parameter and yielded sensitivity and specificity values of 88% and 81.6%, respectively. Thus, confirmation of suspected SD-OCT abnormalities is essential for differentiating long-term variability from reproducible loss.

Macular SD-OCT has also a role in advanced glaucoma patients, although the evidence is sparse. Delbarre *et al.*^[59] used the Cirrus HD-OCT to evaluate the diagnostic ability of segmentation of the various internal macular layers compared to cpRNFL with the various stages of glaucoma disease: early, moderate and advanced. For the entire study population, the minimum GCIP index provided greater diagnostic ability than the other parameters. There was no statistically significant difference with the cpRNFL parameter in the early POAG group, whereas in the advanced POAG group, minimum GCIP and GCC gave the largest AUC indices. Kim *et al.*^[60] assessed the relationship between visual acuity and mGCC thickness, as measured by RTVue, in open-angle glaucoma patients^[60]. They noted significant correlations only in eyes with severe glaucoma. In the severe glaucoma group all GCC parameters significantly correlated with best corrected visual acuity, however no correlation was found in the early-to-moderate disease group.

Detection of glaucoma progression with macular SD-OCT

The average cpRNFL thickness was evaluated in the first study that reported using OCT for glaucoma progression analysis^[61]. Clinicians were able to evaluate disease progression using specially designed statistical software. Guided Progression Analysis first became available in 2008, with the introduction of time-domain OCT

(version 5.0, Stratus OCT, Carl Zeiss Meditec). The use of eye tracking (Spectralis OCT, Heidelberg Engineering) and cpRNFL thickness profiles from the same location in RNFL thickness maps (Cirrus HD-OCT, Carl Zeiss Meditec) are some of the strategies used to enhance the ability to detect changes with SD-OCT.

The macula has the highest density of ganglion cells in the retina. Measurements of the macular nerve fibers and ganglion cell and inner plexiform layer thicknesses are useful for monitoring glaucoma progression^[62]. However, most OCT progression studies conducted to date were limited to cpRNFL measurements; few evaluated measurements of macular thickness.

Both time-domain and SD-OCT instruments have been used to obtain macular measurements for the detection of glaucomatous damage^[63]. Repeatability of measurements is very important when evaluating progression. Mwanza *et al.*^[29] found higher reproducibility of macular ganglion cell layer thickness measurements with the SD-OCT than with the TD-OCT. Although the TD-OCT did not show significant differences in the rate of change of average macular thickness (an average of six radial scan lines, each 6 mm long) between eyes with and without evidence of progression in the VF and/or optic disc stereophotographs (defined as progressors and nonprogressors, respectively)^[64], a study that used the SD-OCT had different results. Using similar definitions of progressors and non-progressors, Sung *et al.*^[65] followed 98 patients with advanced glaucoma for a mean of 2.2 years and reported a significant difference in the rate of change of average macular thickness, but not in average cpRNFL thickness, between the two groups. However, in a study evaluating 162 patients with mild glaucoma followed for the same period, significant differences in the rates of change of cpRNFL and macular thicknesses between progressors and nonprogressors were found^[66]. In terms of progression as determined by optic disc/RNFL photographic or VF assessment, the thickness of the ganglion cell layer had similar sensitivity to RNFL and to total macular thickness. The enhanced measurement reproducibility and denser scanning afforded by SD-OCT may increase detection of structural progression. However, additional studies confirming this hypothesis have yet to be published.

As mentioned above, the RTVue GCC map includes FLV and GLV patterns, based on parameters. Naghizadeh *et al.*^[67] found that compared to ONH, RNFL thickness, or average GCC parameters, GLV and FLV provide better detection of early structural changes due to glaucoma progression. They reported that these parameters detected structural progression even with mild functional progression and that both parameters demonstrated different progression rates between stable and progressing eyes.

Anraku *et al.*^[68] investigated the functional impact of the baseline mGCC thickness. They assessed the association of the baseline mGCC thickness with the progression of VF loss in 56 POAG patients^[68] who

were followed for more than 2 years after baseline OCT measurements. They found that the baseline mGCC thickness (average and inferior hemifield) was significantly thinner in the fast progressors than in the slow progressors. In a multivariate analysis, only mGCC thickness of the inferior hemifield was associated with disease progression ($P = 0.007$). They concluded that baseline mGCC thickness can be predictive of progressive VF loss in POAG.

However, using OCT parameters to track disease progress is somewhat limited. Some changes to the optic disc, RNFL and macular thicknesses detected by the OCT may not be due to glaucoma^[63]. Prospective studies have reported age-related RNFL and thinning of the macula as additional causes^[62].

Detecting a decrease in macular thickness is not necessarily a sign of glaucoma progression. A prospective study followed 150 eyes in 90 glaucoma patients 3 times a year for an average of 3.8 years. Trend analyses showed progression of the inner macular thickness in 50% and in total macular thickness, in 30% of eyes^[62]. After considering changes due to age, progression decreased to 20.0% and 16.0% for inner retinal thickness and total macular thickness, respectively. These findings underscore the affects of changes due to aging on macular and RNFL measurements.

In cases of advanced optic neuropathy, OCT also has limitations related to detecting RNFL thinning^[63]. Changes in RNFL thickness are associated with initial measurements (the rate of decrease in RNFL thickness is increased when the eye has a thicker RNFL)^[62]. RNFL thickness is not less than 30 μm even when the eye has end-stage optic neuropathy and no light perception^[69].

Measurements of OCT are related to the signal-to-noise ratio (or signal strength) of OCT images^[56,70,71]. The signal strength of OCT images may decrease over time if cataract, vitreous opacities or other entities that may affect the opacity of the media. Rao *et al.*^[71] investigated the relationship between scan quality and diagnostic accuracy with SD-OCT using the RTVue OCT in glaucoma patients. The diagnostic ability was dependent on the scan quality even when the signal strength index (SSI) values were within the manufacturer-recommended limits. Scan quality had a greater effect on the diagnostic accuracy of ONH and cpRNFL than on GCC parameters. The sensitivity of all SD-OCT parameters, including GCC, for diagnosing glaucoma increased as the SSI increased. Thus, when interpreting a diagnosis of glaucoma and disease progression, the possible effect of the signal-to-noise ratio of the image series should always be considered.

Changes in the GCC demonstrated by OCT may also reflect pathologies other than glaucoma. The technology was found to be beneficial for detecting toxic effects of oral isotretinoin therapy^[72] and for demonstrating macular retinopathy related to sickle cell anemia^[73]. GCC OCT was used to detect optic chiasmal compression neuropathy^[74], early macular retinal ganglion cell loss related to dominant optic atrophy^[75] and was also used

in migraine patients with aura^[76]. Bayhan *et al.*^[77] used it to follow patients with Parkinson's disease, whereas Narayanan *et al.*^[78] found it beneficial in multiple sclerosis especially with prolonged disease duration and in relapsing remitting eyes.

Future research directions

OCT is a relatively new, evolving technology. It continue to undergo improvements that will enhance our ability to understand the structural pathogenesis of glaucoma and to offer more objective and accurate detection of structural glaucomatous damage and changes over time.

A variety of OCT devices are used to capture the retinal layers. Finding a tool that allows comparison between the results of different GCC OCT devices may be beneficial. We should aspire to develop an algorithm that allows combining the visual field test points with the GCC sectors demonstrated by OCT in order to better investigate the structural-functional aspects of glaucoma progression.

A normative database that incorporates age, sex, axial length and population origin will be required to take full advantage of this technology.

An increasing body of evidence supports using RGC/GCC macular GCC thickness as an indicator for early glaucoma and a valuable tool for monitoring disease progression.

COMMENTS

Background

Optical coherence tomography (OCT) has become a well-established tool for diagnosing and monitoring glaucoma. Limitations in optic nerve head assessment with OCT have driven investigators to look for novel OCT scanning strategies for glaucoma evaluation. Spectral domain (SD) OCT has enabled measurements of the retinal ganglion cells (RGC) in the macula and the retinal ganglion cell complex (GCC), including the retinal nerve fiber layer (RNFL), which are primarily affected in glaucoma and can be directly assessed by this method. Using RGC/GCC SD-OCT in glaucoma is a relatively new concept and the aim of this study was to systematically review the current literature published on this subject.

Research frontiers

New macular segmentation strategies using SD-OCT were developed in recent years for glaucoma assessment, focusing on the measurement of RGC and GCC thickness. Several SD-OCT instruments, including Cirrus HD-OCT (Carl Zeiss Meditec, Inc., Dublin, CA, United States), RTVue (Optovue, Inc., Fremont, CA, United States), Spectralis (Heidelberg Engineering, Heidelberg, Germany) and 3D OCT 2000 (Topcon Corporation, Tokyo, Japan), incorporate sophisticated glaucoma evaluation tools based on these parameters.

Innovations and breakthroughs

To the best of our knowledge, this is the first systematic review of the current data regarding the use of macular RGC/GCC SD-OCT for glaucoma assessment and no published paper thus far has summarized the current data in this field.

Applications

This systematic review may support clinicians to use macular RGC/GCC SD-OCT measurements as a routine adjunctive test to detect early glaucoma and to monitor glaucoma progression in established glaucoma patients.

Terminology

Glaucoma is an optic neuropathy characterized by loss of RGC, thinning of the RNFL and the neuroretinal rim, and increased cupping. RGC layer is an inner retinal layer which is thicker at the macula. GCC thickness is defined by

the distance from the internal limiting membrane, the inner most retinal layer, to the outer boundary of the inner plexiform layer (IPL), which comprises the inner 3 layers of the retina (retinal nerve fiber layer, ganglion cell layer and IPL). Glaucoma affects all of these three layers. OCT is a micron-level, diagnostic method that uses 800-840 nm wavelength infrared light to provide high-resolution, non-invasive neural imaging.

Peer-review

This manuscript is very good and well summarized about macular GCC analysis by various kinds of SD-OCT.

REFERENCES

- 1 **Tham YC**, Li X, Wong TY, Quigley HA, Aung T, Cheng CY. Global prevalence of glaucoma and projections of glaucoma burden through 2040: a systematic review and meta-analysis. *Ophthalmology* 2014; **121**: 2081-2090 [PMID: 24974815 DOI: 10.1016/j.ophtha.2014.05.013]
- 2 **Jonas JB**, Dichtl A. Evaluation of the retinal nerve fiber layer. *Surv Ophthalmol* 1996; **40**: 369-378 [PMID: 8779083]
- 3 **Hood DC**, Raza AS. On improving the use of OCT imaging for detecting glaucomatous damage. *Br J Ophthalmol* 2014; **98** Suppl 2: ii1-ii9 [PMID: 24934219 DOI: 10.1136/bjophthalmol-2014-305156]
- 4 **Quigley HA**, Katz J, Derick RJ, Gilbert D, Sommer A. An evaluation of optic disc and nerve fiber layer examinations in monitoring progression of early glaucoma damage. *Ophthalmology* 1992; **99**: 19-28 [PMID: 1741133]
- 5 **Sommer A**, Katz J, Quigley HA, Miller NR, Robin AL, Richter RC, Witt KA. Clinically detectable nerve fiber atrophy precedes the onset of glaucomatous field loss. *Arch Ophthalmol* 1991; **109**: 77-83 [PMID: 1987954]
- 6 **Zeyen TG**, Caprioli J. Progression of disc and field damage in early glaucoma. *Arch Ophthalmol* 1993; **111**: 62-65 [PMID: 8424726]
- 7 **Jaffe GJ**, Caprioli J. Optical coherence tomography to detect and manage retinal disease and glaucoma. *Am J Ophthalmol* 2004; **137**: 156-169 [PMID: 14700659]
- 8 **Trichonas G**, Kaiser PK. Optical coherence tomography imaging of macular oedema. *Br J Ophthalmol* 2014; **98** Suppl 2: ii24-ii29 [PMID: 24934220 DOI: 10.1136/bjophthalmol-2014-305305]
- 9 **Huang D**, Swanson EA, Lin CP, Schuman JS, Stinson WG, Chang W, Hee MR, Flotte T, Gregory K, Puliafito CA. Optical coherence tomography. *Science* 1991; **254**: 1178-1181 [PMID: 1957169]
- 10 **Folgar FA**, Jaffe GJ, Ying GS, Maguire MG, Toth CA. Comparison of optical coherence tomography assessments in the comparison of age-related macular degeneration treatments trials. *Ophthalmology* 2014; **121**: 1956-1965 [PMID: 24835760 DOI: 10.1016/j.ophtha.2014.04.020]
- 11 **Spaide RF**, Koizumi H, Pozzoni MC. Enhanced depth imaging spectral-domain optical coherence tomography. *Am J Ophthalmol* 2008; **146**: 496-500 [PMID: 18639219 DOI: 10.1016/j.ajo.2008.05.032]
- 12 **Patel NB**, Lim M, Gajjar A, Evans KB, Harwerth RS. Age-associated changes in the retinal nerve fiber layer and optic nerve head. *Invest Ophthalmol Vis Sci* 2014; **55**: 5134-5143 [PMID: 25052998 DOI: 10.1167/iovs.14-14303]
- 13 **Shin HY**, Park HY, Jung Y, Choi JA, Park CK. Glaucoma diagnostic accuracy of optical coherence tomography parameters in early glaucoma with different types of optic disc damage. *Ophthalmology* 2014; **121**: 1990-1997 [PMID: 24935284 DOI: 10.1016/j.ophtha.2014.04.030]
- 14 **Kratz A**, Lim R, Goldberg I. Optic nerve head assessment: comparison of Cirrus optic coherence tomography and Heidelberg Retinal Tomograph 3. *Clin Experiment Ophthalmol* 2014; **42**: 734-744 [PMID: 24716836 DOI: 10.1111/ceo.12344]
- 15 **Fukuda S**, Beheregaray S, Kasaragod D, Hoshi S, Kishino G, Ishii K, Yasuno Y, Oshika T. Noninvasive evaluation of phase retardation in blebs after glaucoma surgery using anterior segment polarization-sensitive optical coherence tomography. *Invest Ophthalmol Vis Sci* 2014; **55**: 5200-5206 [PMID: 25074775 DOI: 10.1167/iovs.14-14474]
- 16 **Seager FE**, Jefferys JL, Quigley HA. Comparison of dynamic changes in anterior ocular structures examined with anterior segment optical coherence tomography in a cohort of various origins. *Invest Ophthalmol Vis Sci* 2014; **55**: 1672-1683 [PMID: 24557354 DOI: 10.1167/iovs.13-13641]
- 17 **Sung KR**, Kim JS, Wollstein G, Folio L, Kook MS, Schuman JS. Imaging of the retinal nerve fibre layer with spectral domain optical coherence tomography for glaucoma diagnosis. *Br J Ophthalmol* 2011; **95**: 909-914 [PMID: 21030413 DOI: 10.1136/bjo.2010.186924]
- 18 **Grewal DS**, Tanna AP. Diagnosis of glaucoma and detection of glaucoma progression using spectral domain optical coherence tomography. *Curr Opin Ophthalmol* 2013; **24**: 150-161 [PMID: 23328662 DOI: 10.1097/ICU.0b013e32835d9e27]
- 19 **Huang ML**, Chen HY. Development and comparison of automated classifiers for glaucoma diagnosis using Stratus optical coherence tomography. *Invest Ophthalmol Vis Sci* 2005; **46**: 4121-4129 [PMID: 16249489 DOI: 10.1167/iovs.05-0069]
- 20 **Horn FK**, Mardin CY, Laemmer R, Baleanu D, Juenemann AM, Kruse FE, Tornow RP. Correlation between local glaucomatous visual field defects and loss of nerve fiber layer thickness measured with polarimetry and spectral domain OCT. *Invest Ophthalmol Vis Sci* 2009; **50**: 1971-1977 [PMID: 19151389 DOI: 10.1167/iovs.08-2405]
- 21 **Leung CK**, Cheung CY, Weinreb RN, Qiu Q, Liu S, Li H, Xu G, Fan N, Huang L, Pang CP, Lam DS. Retinal nerve fiber layer imaging with spectral-domain optical coherence tomography: a variability and diagnostic performance study. *Ophthalmology* 2009; **116**: 1257-1263, 1263e1-e3 [PMID: 19464061 DOI: 10.1016/j.ophtha.2009.04.013]
- 22 **Bendschneider D**, Tornow RP, Horn FK, Laemmer R, Roessler CW, Juenemann AG, Kruse FE, Mardin CY. Retinal nerve fiber layer thickness in normals measured by spectral domain OCT. *J Glaucoma* 2010; **19**: 475-482 [PMID: 20051888 DOI: 10.1097/IJG.0b013e3181c4b0c7]
- 23 **Budenz DL**, Anderson DR, Varma R, Schuman J, Cantor L, Savell J, Greenfield DS, Patella VM, Quigley HA, Tielsch J. Determinants of normal retinal nerve fiber layer thickness measured by Stratus OCT. *Ophthalmology* 2007; **114**: 1046-1052 [PMID: 17210181 DOI: 10.1016/j.ophtha.2006.08.046]
- 24 **Wang G**, Qiu KL, Lu XH, Sun LX, Liao XJ, Chen HL, Zhang MZ. The effect of myopia on retinal nerve fibre layer measurement: a comparative study of spectral-domain optical coherence tomography and scanning laser polarimetry. *Br J Ophthalmol* 2011; **95**: 255-260 [PMID: 20584713 DOI: 10.1136/bjo.2009.176768]
- 25 **Leung CK**, Mohamed S, Leung KS, Cheung CY, Chan SL, Cheng DK, Lee AK, Leung GY, Rao SK, Lam DS. Retinal nerve fiber layer measurements in myopia: An optical coherence tomography study. *Invest Ophthalmol Vis Sci* 2006; **47**: 5171-5176 [PMID: 17122099 DOI: 10.1167/iovs.06-0545]
- 26 **Kim MJ**, Lee EJ, Kim TW. Peripapillary retinal nerve fibre layer thickness profile in subjects with myopia measured using the Stratus optical coherence tomography. *Br J Ophthalmol* 2010; **94**: 115-120 [PMID: 19692369 DOI: 10.1136/bjo.2009.162206]
- 27 **Zeimer R**, Asrani S, Zou S, Quigley H, Jampel H. Quantitative detection of glaucomatous damage at the posterior pole by retinal thickness mapping. A pilot study. *Ophthalmology* 1998; **105**: 224-231 [PMID: 9479279]
- 28 **Ojima T**, Tanabe T, Hangai M, Yu S, Morishita S, Yoshimura N. Measurement of retinal nerve fiber layer thickness and macular volume for glaucoma detection using optical coherence tomography. *Jpn J Ophthalmol* 2007; **51**: 197-203 [PMID: 17554482 DOI: 10.1007/s10384-006-0433-y]
- 29 **Mwanza JC**, Oakley JD, Budenz DL, Chang RT, Knight OJ, Feuer WJ. Macular ganglion cell-inner plexiform layer: automated detection and thickness reproducibility with spectral domain-optical coherence tomography in glaucoma. *Invest Ophthalmol Vis Sci* 2011; **52**: 8323-8329 [PMID: 21917932 DOI: 10.1167/iovs.11-7962]
- 30 **Savini G**, Carbonelli M, Parisi V, Barboni P. Repeatability of

- optic nerve head parameters measured by spectral-domain OCT in healthy eyes. *Ophthalmic Surg Lasers Imaging* 2011; **42**: 209-215 [PMID: 21410092 DOI: 10.3928/15428877-20110224-02]
- 31 **Mathers K**, Rosdahl JA, Asrani S. Correlation of macular thickness with visual fields in glaucoma patients and suspects. *J Glaucoma* 2014; **23**: e98-104 [PMID: 23661046 DOI: 10.1097/IJG.0b013e31829539c3]
 - 32 **Ohkubo S**, Higashide T, Udagawa S, Sugiyama K, Hangai M, Yoshimura N, Mayama C, Tomidokoro A, Araie M, Iwase A, Fujimura T. Focal relationship between structure and function within the central 10 degrees in glaucoma. *Invest Ophthalmol Vis Sci* 2014; **55**: 5269-5277 [PMID: 25082882 DOI: 10.1167/iov.14-14153]
 - 33 **Kita Y**, Kita R, Takeyama A, Takagi S, Nishimura C, Tomita G. Ability of optical coherence tomography-determined ganglion cell complex thickness to total retinal thickness ratio to diagnose glaucoma. *J Glaucoma* 2013; **22**: 757-762 [PMID: 22668980 DOI: 10.1097/IJG.0b013e31825af58a]
 - 34 **Holló G**, Naghizadeh F, Vargha P. Accuracy of macular ganglion-cell complex thickness to total retina thickness ratio to detect glaucoma in white Europeans. *J Glaucoma* 2013; **23**: e132-e137 [PMID: 24247997]
 - 35 **Mwanza JC**, Durbin MK, Budenz DL, Sayyad FE, Chang RT, Neelakantan A, Godfrey DG, Carter R, Crandall AS. Glaucoma diagnostic accuracy of ganglion cell-inner plexiform layer thickness: comparison with nerve fiber layer and optic nerve head. *Ophthalmology* 2012; **119**: 1151-1158 [PMID: 22365056 DOI: 10.1016/j.ophtha.2011.12.014]
 - 36 **Kotowski J**, Folio LS, Wollstein G, Ishikawa H, Ling Y, Bilonick RA, Kagemann L, Schuman JS. Glaucoma discrimination of segmented cirrus spectral domain optical coherence tomography (SD-OCT) macular scans. *Br J Ophthalmol* 2012; **96**: 1420-1425 [PMID: 22914498 DOI: 10.1136/bjophthalmol-2011-301021]
 - 37 **Sato S**, Hirooka K, Baba T, Tenkumo K, Nitta E, Shiraga F. Correlation between the ganglion cell-inner plexiform layer thickness measured with cirrus HD-OCT and macular visual field sensitivity measured with micropertimetry. *Invest Ophthalmol Vis Sci* 2013; **54**: 3046-3051 [PMID: 23580483 DOI: 10.1167/iov.12-11173]
 - 38 **Mwanza JC**, Durbin MK, Budenz DL, Girkin CA, Leung CK, Liebmann JM, Peace JH, Werner JS, Wollstein G. Profile and predictors of normal ganglion cell-inner plexiform layer thickness measured with frequency-domain optical coherence tomography. *Invest Ophthalmol Vis Sci* 2011; **52**: 7872-7879 [PMID: 21873658 DOI: 10.1167/iov.11-7896]
 - 39 **Tan O**, Chopra V, Lu AT, Schuman JS, Ishikawa H, Wollstein G, Varma R, Huang D. Detection of macular ganglion cell loss in glaucoma by Fourier-domain optical coherence tomography. *Ophthalmology* 2009; **116**: 2305-2314.e1-e2 [PMID: 19744726 DOI: 10.1016/j.ophtha.2009.05.025]
 - 40 **Garas A**, Vargha P, Holló G. Reproducibility of retinal nerve fiber layer and macular thickness measurement with the RTVue-100 optical coherence tomograph. *Ophthalmology* 2010; **117**: 738-746 [PMID: 20079538 DOI: 10.1016/j.ophtha.2009.08.039]
 - 41 **Asrani S**, Rosdahl JA, Allingham RR. Novel software strategy for glaucoma diagnosis: asymmetry analysis of retinal thickness. *Arch Ophthalmol* 2011; **129**: 1205-1211 [PMID: 21911669 DOI: 10.1001/archophthalmol.2011.242]
 - 42 **Kim KY**, Kwak HW, Kim M, Kim YG, Yu SY. New profiles of posterior pole retinal thickness map in healthy Korean eyes measured by spectral-domain optical coherence tomography. *Retina* 2013; **33**: 2139-2148 [PMID: 23609125 DOI: 10.1097/IAE.0b013e318289930e]
 - 43 **Kim YJ**, Kang MH, Cho HY, Lim HW, Seong M. Comparative study of macular ganglion cell complex thickness measured by spectral-domain optical coherence tomography in healthy eyes, eyes with preperimetric glaucoma, and eyes with early glaucoma. *Jpn J Ophthalmol* 2014; **58**: 244-251 [PMID: 24610541 DOI: 10.1007/s10384-014-0315-7]
 - 44 **Lee J**, Hangai M, Kimura Y, Takayama K, Kee C, Yoshimura N. Measurement of macular ganglion cell layer and circumpapillary retinal nerve fiber layer to detect paracentral scotoma in early glaucoma. *Graefes Arch Clin Exp Ophthalmol* 2013; **251**: 2003-2012 [PMID: 23620092 DOI: 10.1007/s00417-013-2344-1]
 - 45 **Leite MT**, Rao HL, Weinreb RN, Zangwill LM, Bowd C, Sample PA, Tafreshi A, Medeiros FA. Agreement among spectral-domain optical coherence tomography instruments for assessing retinal nerve fiber layer thickness. *Am J Ophthalmol* 2011; **151**: 85-92.e1 [PMID: 20970108 DOI: 10.1016/j.ajo.2010.06.041]
 - 46 **Kanamori A**, Nakamura M, Tomioka M, Kawaka Y, Yamada Y, Negi A. Agreement among three types of spectral-domain optical coherent tomography instruments in measuring parapapillary retinal nerve fibre layer thickness. *Br J Ophthalmol* 2012; **96**: 832-837 [PMID: 22334136 DOI: 10.1136/bjophthalmol-2011-301084]
 - 47 **Leite MT**, Rao HL, Zangwill LM, Weinreb RN, Medeiros FA. Comparison of the diagnostic accuracies of the Spectralis, Cirrus, and RTVue optical coherence tomography devices in glaucoma. *Ophthalmology* 2011; **118**: 1334-1339 [PMID: 21377735 DOI: 10.1016/j.ophtha.2010.11.029]
 - 48 **Kim KE**, Ahn SJ, Kim DM. Comparison of two different spectral domain optical coherence tomography devices in the detection of localized retinal nerve fiber layer defects. *Jpn J Ophthalmol* 2013; **57**: 347-358 [PMID: 23539100 DOI: 10.1007/s10384-013-0239-7]
 - 49 **Akashi A**, Kanamori A, Nakamura M, Fujihara M, Yamada Y, Negi A. Comparative assessment for the ability of Cirrus, RTVue, and 3D-OCT to diagnose glaucoma. *Invest Ophthalmol Vis Sci* 2013; **54**: 4478-4484 [PMID: 23737470 DOI: 10.1167/iov.12-11268]
 - 50 **Rolle T**, Dallorto L, Briamonte C, Penna RR. Retinal nerve fibre layer and macular thickness analysis with Fourier domain optical coherence tomography in subjects with a positive family history for primary open angle glaucoma. *Br J Ophthalmol* 2014; **98**: 1240-1244 [PMID: 24782474 DOI: 10.1136/bjophthalmol-2013-304519]
 - 51 **Kim JM**, Sung KR, Yoo YC, Kim CY. Point-wise relationships between visual field sensitivity and macular thickness determined by spectral-domain optical coherence tomography. *Curr Eye Res* 2013; **38**: 894-901 [PMID: 23594170 DOI: 10.3109/02713683.2013.787433]
 - 52 **Inuzuka H**, Kawase K, Yamada H, Oie S, Kokuzawa S, Yamamoto T. Macular ganglion cell complex thickness in glaucoma with superior or inferior visual hemifield defects. *J Glaucoma* 2014; **23**: 145-149 [PMID: 24042125 DOI: 10.1097/IJG.0b013e31826a7e20]
 - 53 **Seong M**, Sung KR, Choi EH, Kang SY, Cho JW, Um TW, Kim YJ, Park SB, Hong HE, Kook MS. Macular and peripapillary retinal nerve fiber layer measurements by spectral domain optical coherence tomography in normal-tension glaucoma. *Invest Ophthalmol Vis Sci* 2010; **51**: 1446-1452 [PMID: 19834029 DOI: 10.1167/iov.09-4258]
 - 54 **Cho JW**, Sung KR, Hong JT, Um TW, Kang SY, Kook MS. Detection of glaucoma by spectral domain-scanning laser ophthalmoscopy/optical coherence tomography (SD-SLO/OCT) and time domain optical coherence tomography. *J Glaucoma* 2011; **20**: 15-20 [PMID: 20436370 DOI: 10.1097/IJG.0b013e3181d1d332]
 - 55 **Na JH**, Lee K, Lee JR, Baek S, Yoo SJ, Kook MS. Detection of macular ganglion cell loss in preperimetric glaucoma patients with localized retinal nerve fibre defects by spectral-domain optical coherence tomography. *Clin Experiment Ophthalmol* 2013; **41**: 870-880 [PMID: 23777476 DOI: 10.1111/ceo.12142]
 - 56 **Rao HL**, Addepalli UK, Chaudhary S, Kumbar T, Senthil S, Choudhari NS, Garudadri CS. Ability of different scanning protocols of spectral domain optical coherence tomography to diagnose preperimetric glaucoma. *Invest Ophthalmol Vis Sci* 2013; **54**: 7252-7257 [PMID: 24114539 DOI: 10.1167/iov.13-12731]
 - 57 **Iverson SM**, Feuer WJ, Shi W, Greenfield DS. Frequency of abnormal retinal nerve fibre layer and ganglion cell layer SDOCT scans in healthy eyes and glaucoma suspects in a prospective longitudinal study. *Br J Ophthalmol* 2014; **98**: 920-925 [PMID: 24627246 DOI: 10.1136/bjophthalmol-2013-303877]
 - 58 **Mwanza JC**, Budenz DL, Godfrey DG, Neelakantan A, Sayyad FE, Chang RT, Lee RK. Diagnostic performance of optical coherence

- tomography ganglion cell--inner plexiform layer thickness measurements in early glaucoma. *Ophthalmology* 2014; **121**: 849-854 [PMID: 24393348 DOI: 10.1016/j.ophtha.2013.10.044]
- 59 **Delbarre M**, El Chehab H, Francoz M, Zerrouk R, Marechal M, Marill AF, Giraud JM, May F, Renard JP. [Diagnostic use of macular layer analysis by SD-OCT in primary open angle glaucoma]. *J Fr Ophthalmol* 2013; **36**: 723-731 [PMID: 24119452 DOI: 10.1016/j.jfo.2013.08.002]
 - 60 **Kim JH**, Lee HS, Kim NR, Seong GJ, Kim CY. Relationship between visual acuity and retinal structures measured by spectral domain optical coherence tomography in patients with open-angle glaucoma. *Invest Ophthalmol Vis Sci* 2014; **55**: 4801-4811 [PMID: 25034596 DOI: 10.1167/iops.13-13052]
 - 61 **Wollstein G**, Schuman JS, Price LL, Aydin A, Stark PC, Hertzmark E, Lai E, Ishikawa H, Mattox C, Fujimoto JG, Paunescu LA. Optical coherence tomography longitudinal evaluation of retinal nerve fiber layer thickness in glaucoma. *Arch Ophthalmol* 2005; **123**: 464-470 [PMID: 15824218 DOI: 10.1001/archoph.123.4.464]
 - 62 **Leung CK**, Ye C, Weinreb RN, Yu M, Lai G, Lam DS. Impact of age-related change of retinal nerve fiber layer and macular thicknesses on evaluation of glaucoma progression. *Ophthalmology* 2013; **120**: 2485-2492 [PMID: 23993360 DOI: 10.1016/j.ophtha.2013.07.021]
 - 63 **Leung CK**. Diagnosing glaucoma progression with optical coherence tomography. *Curr Opin Ophthalmol* 2014; **25**: 104-111 [PMID: 24370973 DOI: 10.1097/ICU.0000000000000024]
 - 64 **Medeiros FA**, Zangwill LM, Alencar LM, Bowd C, Sample PA, Susanna R, Weinreb RN. Detection of glaucoma progression with stratus OCT retinal nerve fiber layer, optic nerve head, and macular thickness measurements. *Invest Ophthalmol Vis Sci* 2009; **50**: 5741-5748 [PMID: 19815731 DOI: 10.1167/iops.09-3715]
 - 65 **Sung KR**, Sun JH, Na JH, Lee JY, Lee Y. Progression detection capability of macular thickness in advanced glaucomatous eyes. *Ophthalmology* 2012; **119**: 308-313 [PMID: 22182800 DOI: 10.1016/j.ophtha.2011.08.022]
 - 66 **Na JH**, Sung KR, Lee JR, Lee KS, Baek S, Kim HK, Sohn YH. Detection of glaucomatous progression by spectral-domain optical coherence tomography. *Ophthalmology* 2013; **120**: 1388-1395 [PMID: 23474248 DOI: 10.1016/j.ophtha.2012.12.014]
 - 67 **Naghizadeh F**, Garas A, Vargha P, Holló G. Detection of early glaucomatous progression with different parameters of the RTVue optical coherence tomograph. *J Glaucoma* 2014; **23**: 195-198 [PMID: 22922666 DOI: 10.1097/IJG.0b013e31826a9707]
 - 68 **Anraku A**, Enomoto N, Takeyama A, Ito H, Tomita G. Baseline thickness of macular ganglion cell complex predicts progression of visual field loss. *Graefes Arch Clin Exp Ophthalmol* 2014; **52**: 109-115 [PMID: 24253499 DOI: 10.1007/s00417-013-2527-9]
 - 69 **Chan CK**, Miller NR. Peripapillary nerve fiber layer thickness measured by optical coherence tomography in patients with no light perception from long-standing nonglaucomatous optic neuropathies. *J Neuroophthalmol* 2007; **27**: 176-179 [PMID: 17895816 DOI: 10.1097/WNO.0b013e31814b1ac4]
 - 70 **Samarawickrama C**, Pai A, Huynh SC, Burlutsky G, Wong TY, Mitchell P. Influence of OCT signal strength on macular, optic nerve head, and retinal nerve fiber layer parameters. *Invest Ophthalmol Vis Sci* 2010; **51**: 4471-4475 [PMID: 20445116 DOI: 10.1167/iops.09-3892]
 - 71 **Rao HL**, Addepalli UK, Yadav RK, Senthil S, Choudhari NS, Garudadri CS. Effect of scan quality on diagnostic accuracy of spectral-domain optical coherence tomography in glaucoma. *Am J Ophthalmol* 2014; **157**: 719-727.e1 [PMID: 24345321 DOI: 10.1016/j.ajo.2013.12.012]
 - 72 **Ucak H**, Aykut V, Ozturk S, Cicek D, Erden I, Demir B. Effect of oral isotretinoin treatment on retinal nerve fiber layer thickness. *J Cutan Med Surg* 2014; **18**: 236-242 [PMID: 25008440]
 - 73 **Brasileiro F**, Martins TT, Campos SB, Andrade Neto JL, Bravo-Filho VT, Araújo AS, Arantes TE. Macular and peripapillary spectral domain optical coherence tomography changes in sickle cell retinopathy. *Retina* 2015; **35**: 257-263 [PMID: 25072646]
 - 74 **Akashi A**, Kanamori A, Ueda K, Matsumoto Y, Yamada Y, Nakamura M. The detection of macular analysis by SD-OCT for optic chiasmal compression neuropathy and nasotemporal overlap. *Invest Ophthalmol Vis Sci* 2014; **55**: 4667-4672 [PMID: 25015351 DOI: 10.1167/iops.14-14766]
 - 75 **Barboni P**, Savini G, Cascavilla ML, Caporali L, Milesi J, Borrelli E, La Morgia C, Valentino ML, Triolo G, Lembo A, Carta A, De Negri A, Sadun F, Rizzo G, Parisi V, Pierro L, Bianchi Marzoli S, Zeviani M, Sadun AA, Bandello F, Carelli V. Early macular retinal ganglion cell loss in dominant optic atrophy: genotype-phenotype correlation. *Am J Ophthalmol* 2014; **158**: 628-636.e3 [PMID: 24907432 DOI: 10.1016/j.ajo.2014.05.034]
 - 76 **Ekinci M**, Ceylan E, Çağatay HH, Keleş S, Hüseyinoğlu N, Tanyildiz B, Cakici O, Kartal B. Retinal nerve fibre layer, ganglion cell layer and choroid thinning in migraine with aura. *BMC Ophthalmol* 2014; **14**: 75 [PMID: 24885597 DOI: 10.1186/1471-2415-14-75]
 - 77 **Bayhan HA**, Aslan Bayhan S, Tanik N, Gürdal C. The association of spectral-domain optical coherence tomography determined ganglion cell complex parameters and disease severity in Parkinson's disease. *Curr Eye Res* 2014; **39**: 1117-1122 [PMID: 24655112 DOI: 10.3109/02713683.2014.894080]
 - 78 **Narayanan D**, Cheng H, Bonem KN, Saenz R, Tang RA, Frishman LJ. Tracking changes over time in retinal nerve fiber layer and ganglion cell-inner plexiform layer thickness in multiple sclerosis. *Multi Scler* 2014; **20**: 1331-1341 [PMID: 24639478 DOI: 10.1177/1352458514523498]

P- Reviewer: Bhattacharya SK, Hong YJ, Tzamalís A **S- Editor:** Ji FF

L- Editor: A **E- Editor:** Wu HL





Published by **Baishideng Publishing Group Inc**

8226 Regency Drive, Pleasanton, CA 94588, USA

Telephone: +1-925-223-8242

Fax: +1-925-223-8243

E-mail: bpgoffice@wjgnet.com

Help Desk: <http://www.wjgnet.com/esps/helpdesk.aspx>

<http://www.wjgnet.com>

