



Revision surgery for otosclerosis: An overview

Sertac Yetiser

Sertac Yetiser, Department of ORL and HNS, Anadolu Medical Center, Gebze, 41400 Kocaeli, Turkey

Author contributions: Yetiser S designed the study, analyzed the data and wrote the paper.

Conflict-of-interest: The author declares that he has no competing interests.

Open-Access: This article is an open-access article which was selected by an in-house editor and fully peer-reviewed by external reviewers. It is distributed in accordance with the Creative Commons Attribution Non Commercial (CC BY-NC 4.0) license, which permits others to distribute, remix, adapt, build upon this work non-commercially, and license their derivative works on different terms, provided the original work is properly cited and the use is non-commercial. See: <http://creativecommons.org/licenses/by-nc/4.0/>

Correspondence to: Sertac Yetiser, MD, Professor, Department of ORL and HNS, Anadolu Medical Center, Cumhuriyet mahallesi, 2255 sokak No:3, Gebze, 41400 Kocaeli, Turkey. syetiser@yahoo.com

Telephone: +90-532-3248433

Fax: +90-262-6540529

Received: September 15, 2014

Peer-review started: September 16, 2014

First decision: November 1, 2014

Revised: November 4, 2014

Accepted: December 3, 2014

Article in press: December 10, 2014

Published online: February 28, 2015

Abstract

Stapes surgery for otosclerosis has been proved to be a very satisfying procedure. However, the condition is difficult for the patients with no or little hearing gain after surgery and for those who had sudden or gradual hearing loss after a successful air-bone gap closure in the follow-up period. The issue of re-exploring the middle ear is challenging. A general review of this subject from several points of view remains lacking. In this study, articles related with the revision surgery for otosclerosis have been reviewed after a PubMed research and common and/or contradictory points were documented. The aim of this study is to give an insight to diagnostic and therapeutic approaches for

the clinicians in patients who need a revision surgery. In conclusion, prosthesis problems, loose prosthesis in stapedotomy and migrated prosthesis in stapedectomy are the most common causes for revision surgery. Most important indicators which effect better hearing outcome following revision surgery are those ears with the presence of incus, with no obliteration of oval window, with small fenestra stapedotomy and the experience of surgeon. The risk of neurosensorial hearing loss in revision cases is not high but the hearing gain is limited as compared to primary cases. The rate of 10 dB air-bone gap closure is around 60%-70% at most and even less promising results have been reported. Patient's demands and expectations have to be clarified in a realistic way.

Key words: Otosclerosis; Stapedotomy; Stapedectomy; Revision

© **The Author(s) 2015.** Published by Baishideng Publishing Group Inc. All rights reserved.

Core tip: It is very difficult for the patients with otosclerosis having no or little hearing gain after surgery and for those who had sudden or gradual hearing loss after a successful air-bone gap closure in the follow-up period. The issue of re-exploring the middle ear is challenging. A general review of this subject from several points of view remains lacking. In this study, articles related with revision surgery for otosclerosis have been reviewed after a PubMed research and common and/or contradictory points were documented.

Yetiser S. Revision surgery for otosclerosis: An overview. *World J Otorhinolaryngol* 2015; 5(1): 21-29 Available from: URL: <http://www.wjgnet.com/2218-6247/full/v5/i1/21.htm> DOI: <http://dx.doi.org/10.5319/wjo.v5.i1.21>

INTRODUCTION

Revision surgery for otosclerosis is always difficult

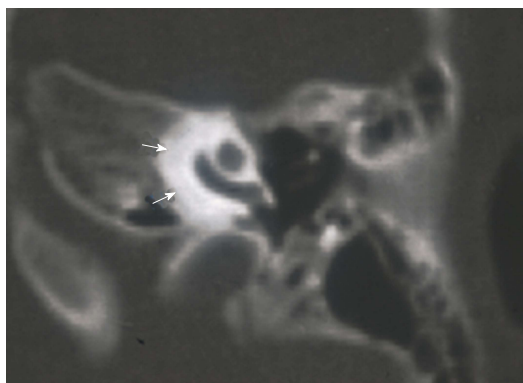


Figure 1 CT appearance of cochlear otosclerosis. Note for perilymphatic decalcification (marked with arrows).

to decide and also challenging for both the surgeon and the patient. Difficulties of re-operation are higher and the success rate is less predictable. Before going back to the operating room, all related issues about the primary intervention (type of otosclerotic focus, facial nerve dehiscence, the length, diameter and the type of prosthesis, type of anesthesia, balance problem, graft for oval window, operation time, bleeding, the technique, type of laser, etc.) and about the patient (his age, occupation, his opinion about the secondary surgery, his current psychological status, hearing level, any possible cause for hearing loss, etc.) have to be looked at. The details which have to be reviewed before surgical planning are numerous. What type of anesthesia will be used, what if the revision side is the better hearing one, what if the patient has an associated balance problem. An option of hearing aid has to be frankly discussed with the patient. The aim of this review study is to enlighten this subject from its all aspects.

EPIDEMIOLOGY, INCIDENCE AND ETIOLOGY

The incidence of revision surgery for otosclerosis has been declined over the years. Major indications for re-exploring the middle ear are usually for patients who had no hearing recovery after stapes surgery at the early period or those who had sudden or gradual conductive or neurosensorial hearing loss in the long run. Revision surgery is also needed for patients with intractable or chronic and recurrent balance problems after surgery and no relief with medical treatment whether they have hearing loss or not. For those with stable and long term hearing loss, chance of hearing restoration is quite low. There seems to be no common understanding in the literature deciding the surgery in terms of hearing loss. Most surgeons are not willing to operate the patients with less than 20 dB air-bone gap and discrimination score less than 60%. Some of the air-bone gaps are very mild

and could be resolved easily by medical measures. On the other hand, cochlear otosclerosis could be the main cause for those with slowly progressive sensorineural hearing loss and there is no indication for revision surgery. Cochlear otosclerosis causes progressive damage to the organ of Corti and stria vascularis. Venous congestion and abnormal blood circulation leads to hyalinisation of spiral ligament^[1]. Ear drum looks like more reddish than it was before. Increased blood flow of the promontrium vessels gives a typical finding to the tympanic membrane, so-called "Schwartz sign"^[2]. Linear perilymphatic decalcification as seen on the temporal bone CT scanning is diagnostic finding (Figure 1)^[3].

Prosthesis dislocation from oval window, incus erosion and incus-prosthesis detachment, short prosthesis, postoperative fibrosis in the middle ear and re-ankylosis, perilymphatic fistula, insufficient fenestra and too tight prosthesis, footplate resclerosis, incus subluxation, facial nerve dehiscence and prosthesis friction, reparative granuloma, vestibular symptoms due to long prosthesis, malleus-incus fixation, neurosensorial hearing loss are some of the main causes of revision surgery. However, the incidence of the causes for revision surgery has greatly changed over the years mostly due to the technique and the materials used for hearing restoration. One of frequent causes of revision surgery during the era of wire-gel foam or wire-adipose tissue prosthesis was perilymphatic fistula presenting with neurosensorial hearing loss and prolonged unsteadiness^[4,5]. However, common causes of re-operation, more recently are due to re-fixation of prosthesis, prosthesis coming off the oval window for some reason, and incus necrosis presenting with gradual or sudden conductive hearing loss^[6-10].

Fisch *et al*^[11] have reported that in almost 80%-85% of cases, revision surgery is related with either prosthesis (too tight or fixed, too loose, too long, too short, bended, etc.) or oval window problems (fibrosis, narrowing, granulation tissue, new bone formation, fistula). In addition to problems like inadequate crimping of prosthesis to incus or prosthesis detachment or overlooked incus mobility problems, one of the most common causes of revision surgery is substantially incudo-malleal ankylosis or malleal-epitympanic fixation especially for patients who have limited hearing gain after primary surgery. For this reason, some clinicians claim that a malleo-stapedotomy or disconnection of malleus head after drilling attical bone could be necessary and superior canaloplasty incision should always be included during classic end-aural approach to inspect the anterior malleal ligament and incudo-malleal articulation, as well^[11-13]. However, 46% incidence of incus-malleus ankylosis claimed by Fisch *et al*^[11] had not been supported by others^[14-17]. The incidence is about 2% for Lippey *et al*^[18] and 10% for Causse *et al*^[19]. On the other hand, histopathological investigations on fixed malleus head revealed normal

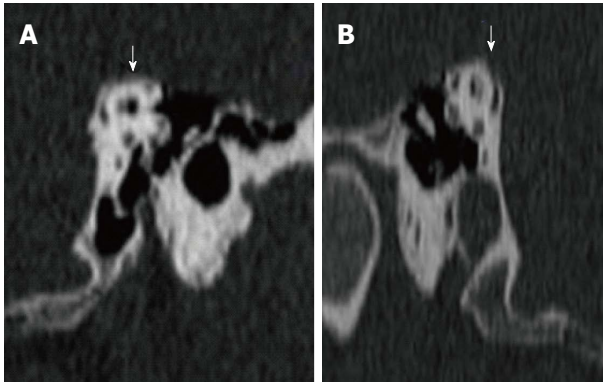


Figure 2 Bilateral superior semicircular canal dehiscence of A and B (marked with arrows).

bone or tympanosclerotic focus^[20]. But, of course it has primary importance to control the mobility of incus and malleus during primary surgery. Some authors proposed Laser-Doppler-Interferometer to objectively distinguish otosclerosis and malleus fixation before the surgery^[21]. A constant minimum 10 dB air-bone gap could always be present even after a perfect stapes surgery if such malleus problem is overlooked.

Malleus fixation can be an acquired problem due to tympanosclerotic process of childhood otitis media or it can be congenital. It can be found as an isolated problem in 80% of incidence. However, it may be associated with incudo-malleal fixation in 15% of cases^[22]. However, its co-existence with otosclerosis is an interesting subject. Malleus fixation associated with otosclerosis was first reported by Guild^[23]. Nandapalan *et al*^[24] have found a kind of hyalinization process in anterior and superior malleal ligaments in 30% of otosclerotic temporal bones. This high incidence was not supported by other studies. Subotic *et al*^[25] have reviewed 1108 normal temporal bones and reported 14 congenital malleus fixations. Oktay *et al*^[26] have found no relation between hyalinization of anterior malleal ligament and otosclerosis. Vincent *et al*^[22] have reported that 30% of patients with malleus fixation have a history of otitis media in the past. If it is a congenital abnormality, it should be related with an anomaly of Meckel cartilage during 7th month of fetal life probably due to cessation of resorption of some embryonic mesenchymal tissue^[27]. Genetic aspect and the type of transmission is not clear although familial cases have recently been reported^[28].

Probabilities for the presence of air-bone gap after primary surgery are listed below: (1) Middle ear stiffness: clots, too much gel foam in the middle ear, adipose tissue placed around the prosthesis could be the reason. But, they have a minor effect; (2) Eustachian dysfunction and associated ventilation problems: this is a temporary condition; (3) Problems of tympanic membrane: tympanic membrane which is not flexible yet, tiny perforations or restored ear

drum with underlay fascia or perichondrium may affect hearing; (4) Edema of the external auditory canal: restoration of hearing is expected after resolution of the edema; (5) Immobile prosthesis: hearing gain is very little if the prosthesis is too tight in the oval window fenestra; (6) Loose prosthesis: the attachment of prosthesis to incus is too floppy; (7) Prosthesis out of oval window or too short prosthesis: there is no hearing gain. It is even worse; (8) Prosthesis with small caliber: little air-bone gap can be found; (9) Incudo-malleal ankyloses: sometimes, this is overlooked and again there is no hearing gain; (10) Partial dislocation (subluxation) of incus; incus can be dislocated, if it is forced too much during insertion of prosthesis. Air-bone gap is mild; (11) Oval and round window abnormalities: hearing gain could be very limited in case of obliterative otosclerosis; (12) Dehiscence of superior semicircular canal: one of the interesting clinical entity that may mimic otosclerosis is superior semicircular canal dehiscence^[29-31]. Those patients have low frequency conductive hearing loss because of absorption of sound energy through the bony defect which is defined as "third window effect". Stapes surgery will not restore the hearing in those patients. Therefore, patients with conductive hearing loss should be evaluated with temporal bone CT (Figure 2); (13) Otosclerosis with cavitations: hearing gain could be very limited due to "third window effect"^[32]; (14) Large vestibular aqueduct: there is no enough air-bone gap closure because of "third window effect"^[33]; (15) Pressure of dehiscence facial nerve: bulging facial nerve can press the prosthesis and can hamper its mobility; (16) Inner ear pressure: inner ear pressure can affect the mobility of stapes in cases with stapes gusher; (17) Meniere and otosclerosis: an attack of Meniere can lead to temporary hearing loss, even though it is very rare^[34]; (18) Pneumolabyrinth: air in the labyrinth can cause limited gain, if too much perilymph is aspirated; and (19) Audiometric inaccuracy: technical problems (inadequate testing conditions, masking problems, etc.) or patients' faulty guidance (too much tinnitus, medico-legal conditions, etc.) may lead to pre or postoperative faulty audiograms.

PATIENT COUNSELLING AND SURGICAL PLANNING

One of the important subjects before deciding a revision surgery is the patient's demand and his expectations which have to be truly clarified in a realistic way. Hearing loss after primary surgery is very frustrating for both the patient and the surgeon. Surgeons experience has utmost importance. But, it is a mutual understanding that the risks are higher in revision cases. One of the first things to do is to calm down the patient, explain the situation and wait for a couple of months for a more reliable audiogram.

The patient should be evaluated with temporal bone CT scanning and MRI during this waiting period. Age seems to be unimportant for decision making^[35]. A detailed history of the patient is necessary. Every pieces of information should be explored before the surgery. Each steps of the primary surgery from the beginning or even the diagnosis of otosclerosis should be checked again, especially if there is no hearing gain or the gain is very little. Those are the main questions which have to be reviewed thoroughly: (1) What are the hearing level and word recognition scores before and after the primary surgery; (2) What is the operation time, the technique, (stapedectomy/stapedotomy) and type of anesthesia? (If it is local, what are intraoperative hearing and balance findings?); (3) What is the age of patient, gender, occupation, associated health problems and date of diagnosis of otosclerosis; (4) What is the type of prosthesis, length and diameter; (5) What are the otosclerotic and the footplate findings; (6) How did the hearing loss happen (sudden, progressive, etc.)? What are the possible causes and associate symptoms? What is the duration from primary surgery and hearing loss; (7) How is the facial nerve, the graft over the footplate, any associated problem (bleeding, perilymph leakage, etc.); (8) How is the intra or postoperative balance; (9) What is the method used to open the footplate (laser, pick, drilling)? What are the particular findings (obliteration, floating footplate, fragile/thin footplate, etc.); and (10) What are the patient's thoughts about the primary and revision surgery.

PROSTHESIS PROBLEMS (FIXATION-DISLOCATION)

Prosthesis problems are generally related with lateralization of the prosthesis or prosthesis re-fixation at the oval window which are presented with conductive type hearing loss being more evident at higher frequencies^[36]. Fibrosis around the oval window and re-stenosis may intervene with the mobility of the prosthesis. Fibrosis is mostly related with mucosal injury and foreign body reaction (silicone blocks, gel foam, wire prosthesis, etc.). A kind of soft tissue quickly coats the prosthesis and envelops all around it. However, its effect on hearing is questionable. Sim *et al*^[37] have investigated the influence of postoperative tissue formation on sound transmission with laser Doppler and electron microscopy and have found that this is negligible. Hearing loss is pretty much related with re-stenosis and can be seen as early as a year after primary surgery. Nadol points out that new lesions can be related with drilling around the otosclerotic lesion. He recommends less possible drilling^[8]. The incidence of extensive and obliterative otosclerosis is about 7%-11%^[38-40]. Re-stenosis of oval window is one

of the major problems. Sheehy reported that 10% of his revisions were because of oval window re-stenosis and 75% of them were primary obliterative cases^[41].

The incidence of primary round window otosclerosis is less than 1%^[8]. However, round window narrowing and obliteration due to otosclerotic focus extending from oval window have been found in 23% of cases. Therefore, it is an important precaution to always inspect the round window during primary surgery. On the other hand, round window abnormalities may mimic otosclerosis. Borrmann *et al*^[42] have reported non-syndromal round window atresia with otosomal dominant penetrance in 2 members of the family. Identification of severe obliteration of round window will prevent unnecessary stapes surgery. However, what is best to do if the otosclerotic lesion is extending to the round window. Studies indicate an increased risk of neurosensorial hearing loss during cleaning process of round window^[43,44].

It was commonly seen in revision cases of the earlier period that prosthesis displacement was mostly related with wire-gel foam and wire-adipose prosthesis. Prosthesis-incus attachment was somehow functional and often times, prosthesis sliding out of the intact incus was not case. On the contrary, dislocation was more common at the inferior side of oval window in which the stapedectomy was the common technique^[14,15]. Prosthesis coming off incus while it is still in place at oval window in cases of stapedotomy is usually associated with incus necrosis or oval window re-stenosis. This is called as "lateralized piston" and is seen in 18.5% of stapes surgery revision^[45].

INCUS PROBLEMS

Incus problems can be seen with almost every types of prosthesis. Incus necrosis is not the result of reduction of vascular supply or mucosal disruption due to very tight holding of prosthesis as believed once but it is because of vibratory movements at the prosthesis-incus contact site due to flaccid prosthesis or re-stenosis of the oval window constricting the prosthesis^[7]. Fibrosis or adhesions can also disturb synchronous movement of incus and the prosthesis and give rise to increase of friction and a kind of different phase of the piston movement^[8,46]. This is known as "Loose-wire syndrome". The characteristic sign is the short term improvement of patient's hearing following Valsalva maneuver.

The impact of incus necrosis on hearing after revision stapes surgery is not predictable. All techniques of ossicular reconstruction should be considered in case of incus necrosis. One option is to lengthen the long arm of incus with bone cement and secure the prosthesis if its movement in the fenestra is fine (Figure 3)^[47]. However, if the long arm of incus is completely gone, if incus is luxated or

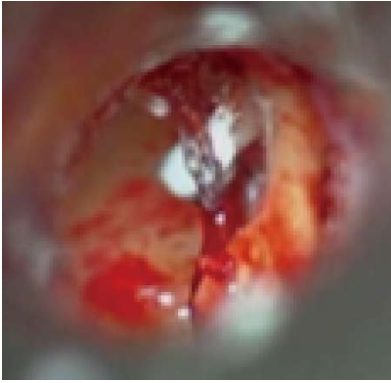

Figure 3 Revision stapes surgery due to incus necrosis. Bone cement was used to reconstruct the incus. Titanium prosthesis was placed over the fixed incus.

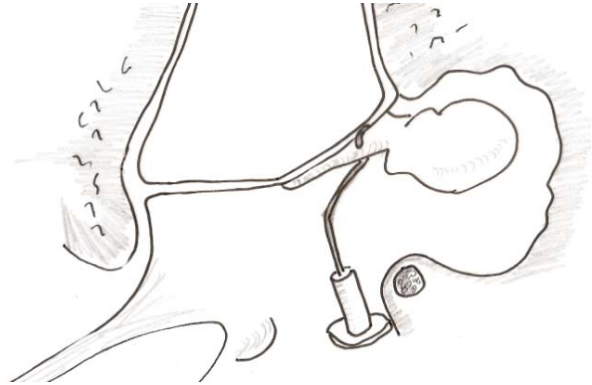


Figure 4 Ossicular reconstructions between the mobile malleus and stapes footplate fenestra if incus is not available due to dislocation or extensive necrosis.

head of malleus is fixed at epitympanium, surgeon must consider to by-pass the incus with or without removal of head of malleus (Figure 4)^[48]. Placement of the prosthesis between the mobile malleus handle and stapes footplate or a TORP between the ear drum and oval window may be required^[13,49]. If it is not possible to use any ossicles then TORP is the only option. Sheehy has reported that he had to use TORP in 20% of revision cases. He had 64% of 10 dB air-bone gap closure and 95% of 20 dB air-bone gap closure^[49]. Prosthesis can be inserted to malleus anterior or posterior to the processus brevis without stripping the ear drum from malleus handle. Attachment of the prosthesis to the neck of malleus at the back of the processus is preferred. But, if fixed malleus head is resected then prosthesis is attached in front of the processus. Mangham *et al*^[50] have compared the hearing results with incus vs malleus reconstruction and have reported that results of reconstructive procedures with malleus (with incus by-pass) are much better. Ghonim *et al*^[51] have reported 10 dB air-bone gap closure in 58.3% of cases and 20 dB air-bone gap closure in 83.3% of cases in which malleus was re-located and incus was transferred between the malleus and footplate.

Malleus diameter is about 3.5 mm and fine attachment is very important. This will prevent prosthesis dislocation and excessive movement in the vestibule synchronous with the movement of the ear drum. Titanium clips and wire pistons are used for this purpose^[52,53]. In case of narrow oval window, the wire prosthesis is angulated which has to be little bit far away from the upper part of the oval window where utricle is located. Malleus-oval window pistons can provide 10 dB air-bone gap closure^[22]. Hausler *et al*^[54] proposed titanium malleus prosthesis when ideal angulation and placement of wire prosthesis is not possible. Seidman and Babu reported considerable hearing gain in patients with incus-malleus fixation by epitympanic liberation of the malleus with laser and incus transposition

without insertion of prosthesis and removal of malleus head^[55].

OSSICULAR RECONSTRUCTION IN REVISION SURGERY

When the middle ear explored, one should pay much attention to long arm of incus, prosthesis-oval window relation, mobility of the ossicles and prosthesis and finally, should inspect the site of leakage in patients with vertigo. What the surgeon must do if there is nothing particular in the middle ear. Should he change the prosthesis, anyway or should he replace with the new one although the old prosthesis still looks good after restoration of the problem? Exchanging the prosthesis probably has least importance for additional hearing. However, Jahnke *et al*^[56] have reported better hearing when they replaced the old one with titanium as compared to those in which the old one was left (69.4% vs 76.2%).

Laser is very effective in revision cases especially in those with extensive granulation tissue or fibrosis^[57,58]. Laser helps for less bleeding during surgery. However, it is important to remove the old prosthesis before using laser and not to shoot directly the prosthesis. Teflon prosthesis, silicone blocks could melt and get sticky, granulation tissue around the metal piston may increase the heat, hydroxyl-appetite could break. It has been reported that KTP laser is not suitable for patients with middle ear implant in the presence of blood and granulation tissue^[59,60]. Haberkamp *et al*^[57] have reviewed revision cases with or without CO₂ laser and have reported that laser allows positive identification of the oval window and assures placement of prosthesis. However, its role on better hearing outcome is not clear. Silverstein *et al*^[61] have found no difference in comparison of hearing outcome of patients following revision stapes surgery with and without laser. On the other hand, Wiet *et al*^[62] have found better hearing outcome in those with

Table 1 Studies regarding the hearing after revision stapes surgery

Ref.	No. of cases	10 dB AC-BC gap (%)	20 dB AC-BC gap (%)
Crabtree <i>et al</i> ^[67]	35	46	-
Sheehy <i>et al</i> ^[41]	258	44	71
Pearman <i>et al</i> ^[68]	95	58	73
Derlacki ^[14]	217	65	72
Glasscock <i>et al</i> ^[15]	82	39	64
Bhardwaj <i>et al</i> ^[69]	120	46.5	-
Lesinski ^[7]	57	66	89
Farrior <i>et al</i> ^[6]	102	58	85
Langman <i>et al</i> ^[17]	66	61	84
Somers <i>et al</i> ^[70]	332	40	64
De La Cruz <i>et al</i> ^[71]	356	59.8	77.5
Lippy <i>et al</i> ^[72]	483	71	-
Gros <i>et al</i> ^[73]	63	52.4	-
Babighian <i>et al</i> ^[74]	78	54	-
Bakhos <i>et al</i> ^[10]	89	52	-

laser surgery.

HEARING RESULTS FOLLOWING REVISION SURGERY

It should be kept in mind that hearing restoration after revision stapes surgery is not as successful as primary surgery. The rate of 10 dB air-bone gap closure is around 60%-70% at most and even less promising results have been reported^[7,63]. A realistic approach is to tell the patient that the chance of better hearing is about 60%, but also the hearing may not change or even may get worse. Pedersen have reported 17% worsening in a series of 186 revision cases^[9]. Palva *et al*^[64] have reported 23% worsening in 76 revision cases. Richards *et al*^[65] have reported hearing loss in the counter lateral ear in some of the revision cases which was termed as "sympathic cochleolabyrinthitis". The role of age in revision cases has been investigated, but no difference in hearing gain have been found between elder and young patients^[26,66]. Glasscock *et al*^[15] have reported that those cases with better hearing results following primary surgery also have better results following revision surgery. On the other hand, long term follow-up studies demonstrate that early hearing gains are prone to decline over the years. Lippy have reported that 72% air-bone gap closure rate drops to 50% in 10 years. Besides, those with multiple interventions have even worse results. Table 1 shows hearing results of several studies following revision surgery. The rate of 10 dB air-bone gap closure after revision surgery ranges between 39%-71%^[3,4,7,11,12,14,38,67-74].

REVISION SURGERY FOR POST-OPERATIVE BALANCE PROBLEM

Besides its audiological gain, stapes surgery also

means an intervention to the closed labyrinth system. Patients usually have abnormal caloric responses lasting for a long time^[75]. Increased utricular activity and dysfunction of sensorial organization have been documented by subjective visual horizontal test and posturography^[76-78]. Decrease in perilymphatic amount, mechanical effects of aspiration, dryness, heat, prosthesis irritation, air or blood infiltrating to the vestibule and probable enzymatic reactions could possibly alter the micromechanics of the labyrinth. An irritative nystagmus beating toward the counter lateral ear is seen for 3-4 d following surgery which disappears in normal condition^[79,80]. There is usually no relation with the transient vertigo and hearing gain after surgery. However, persistent nystagmus is indicative of chronic vestibular irritation. Vestibular exercises and medical therapy can provide relief of symptoms in some patients or symptoms may disappear with no obvious reason. Some patients get used to it. However, symptoms sometimes could be unbearable. One of the challenging problems is to decide for re-operation in patients with post-operative vertigo resistive to medical therapy and normal hearing.

The most definite cause for prolonged unsteadiness is the presence perilymphatic fistula. The incidence is about 10% and is due to inadequate sealing around the prosthesis in the oval window^[12]. It is less seen in patients with oval window grafting^[81]. Nakashima *et al*^[2] have reported the incidence of perilymph fistula was 22% in patients with gel-foam sealing and 4% in patients with tissue sealing. Sheehy and Perkins have reported 3.5%, 1.9% and 0.6% of fistula rate with gel-foam, adipose tissue and fascia, respectively^[38]. Tinnitus, aural fullness, neurosensorial hearing loss and vertigo which is more evident when the patients lie on the non-operated side or with Valsalva maneuver is found. Nystagmus as seen on tympanogram and pneumolabyrinth on MRI support the perilymphatic fistula^[82]. Another possibility for post-operative balance problem is the irritation of long prosthesis which is presented with similar symptoms (Figure 5). Symptoms are worse with head movement and after Valsalva maneuver. However, hearing loss may not always accompany the vestibular problem. In less than 1% of cases, progressive hearing loss and vertigo could be related with reparative granuloma^[83,84]. If medical treatment including anti-vertiginous drugs, prophylactic antibiotics, diuretics, steroids fails, the middle ear re-exploration is indicated.

CONCLUSION

Prosthesis problems, loose prosthesis in stapedotomy and migrated prosthesis in stapedectomy are the most common causes for revision surgery. Most important indicators which effect better hearing outcome following revision surgery are those ears with the presence of incus, with no obliteration of oval window, with small fenestra stapedotomy and

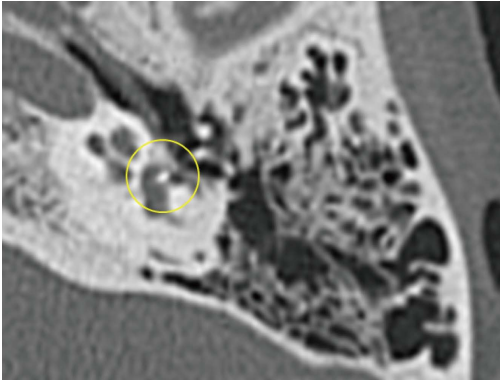


Figure 5 Temporal bone tomography with long prosthesis inside the vestibule (marked with yellow circle).

the experience of surgeon^[9]. Obliterative cases have the worst outcome. Finally, the risk of neurosensorial hearing loss in revision cases is not high but the hearing gain is limited as compared to primary cases.

REFERENCES

- Doherty JK**, Linthicum FH. Spiral ligament and stria vascularis changes in cochlear otosclerosis: effect on hearing level. *Otol Neurotol* 2004; **25**: 457-464 [PMID: 15241221 DOI: 10.1097/00129492-200407000-00010]
- Nakashima T**, Sone M, Fujii H, Teranishi M, Yamamoto H, Otake H, Sugiura M, Naganawa S. Blood flow to the promontory in cochlear otosclerosis. *Clin Otolaryngol* 2006; **31**: 110-115 [PMID: 16620329 DOI: 10.1111/j.1749-4486.2006.01151.x]
- Vartiainen E**, Saari T. Value of computed tomography (CT) in the diagnosis of cochlear otosclerosis. *Clin Otolaryngol Allied Sci* 1993; **18**: 462-464 [PMID: 8877220 DOI: 10.1111/j.1365-2273.1993.tb00614.x]
- Lippy WH**, Schuring AG. Stapedectomy revision following sensorineural hearing loss. *Otolaryngol Head Neck Surg* 1984; **92**: 580-582 [PMID: 6438590]
- Lippy WL**, Schuring AG. Stapedectomy revision of the wire-Gelfoam prosthesis. *Otolaryngol Head Neck Surg* 1983; **91**: 9-13 [PMID: 6405357]
- Farrior J**, Sutherland A. Revision stapes surgery. *Laryngoscope* 1991; **101**: 1155-1161 [PMID: 1943416 DOI: 10.1288/00005537-199111000-00003]
- Lesinski SG**. Causes of conductive hearing loss after stapedectomy or stapedotomy: a prospective study of 279 consecutive surgical revisions. *Otol Neurotol* 2002; **23**: 281-288 [PMID: 11981382 DOI: 10.1097/00129492-200205000-00009]
- Nadol JB**. Histopathology of residual and recurrent conductive hearing loss after stapedectomy. *Otol Neurotol* 2001; **22**: 162-169 [PMID: 11300263 DOI: 10.1097/00129492-200103000-00008]
- Durko M**, Kaczmarczyk D, Durko T. Revision stapes surgery: retrospective analysis of surgical findings in a series of 21 otosclerosis patients. *Adv Otorhinolaryngol* 2007; **65**: 273-277 [PMID: 17245058 DOI: 10.1159/000098842]
- Bakhos D**, Lescanne E, Charretier C, Robier A. A review of 89 revision stapes surgeries for otosclerosis. *Eur Ann Otorhinolaryngol Head Neck Dis* 2010; **127**: 177-182 [PMID: 21036120 DOI: 10.1016/j.anorl.2010.07.012]
- Fisch U**, Acar GO, Huber AM. Malleostapedotomy in revision surgery for otosclerosis. *Otol Neurotol* 2001; **22**: 776-785 [PMID: 11698795 DOI: 10.1097/00129492-200111000-00011]
- Pedersen CB**. Revision surgery in otosclerosis--an investigation of the factors which influence the hearing result. *Clin Otolaryngol Allied Sci* 1996; **21**: 385-388 [PMID: 8932938 DOI: 10.1046/j.1365-2273.1996.00792.x]
- Dalchow CV**, Dünne AA, Sesterhenn A, Teymoortash A, Werner JA. Malleostapedotomy: the Marburg experience. *Adv Otorhinolaryngol* 2007; **65**: 215-221 [PMID: 17245050 DOI: 10.1159/000098825]
- Derlacki EL**. Revision stapes surgery: problems with some solutions. *Laryngoscope* 1985; **95**: 1047-1053 [PMID: 3839878 DOI: 10.1288/00005537-198509000-00005]
- Glasscock ME**, McKennan KX, Levine SC. Revision stapedectomy surgery. *Otolaryngol Head Neck Surg* 1987; **96**: 141-148 [PMID: 3120087]
- Hammerschlag PE**, Fishman A, Scheer AA. A review of 308 cases of revision stapedectomy. *Laryngoscope* 1998; **108**: 1794-1800 [PMID: 9851493 DOI: 10.1097/00005537-199812000-00006]
- Langman AW**, Lindeman RC. Revision stapedectomy. *Laryngoscope* 1993; **103**: 954-958 [PMID: 8361314 DOI: 10.1288/00005537-199309000-00002]
- Lippy WH**, Schuring AG, Ziv M. Stapedectomy for otosclerosis with malleus fixation. *Arch Otolaryngol* 1978; **104**: 388-389 [PMID: 666645 DOI: 10.1001/archotol.1978.00790070026006]
- Causse J**, Causse JB. Eighteen-year report on stapedectomy. I. Problems of stapedial fixation. *Clin Otolaryngol Allied Sci* 1980; **5**: 49-59 [PMID: 6892692 DOI: 10.1111/j.1365-2273.1980.tb01626.x]
- Martin C**, Timoshenko AP, Dumollard JM, Tringali S, Peoc'h M, Prades JM. Malleus head fixation: histopathology revisited. *Acta Otolaryngol* 2006; **126**: 353-357 [PMID: 16608785 DOI: 10.1080/0016480500390345]
- Huber A**, Koike T, Wada H, Nandapalan V, Fisch U. Fixation of the anterior malleal ligament: diagnosis and consequences for hearing results in stapes surgery. *Ann Otol Rhinol Laryngol* 2003; **112**: 348-355 [PMID: 12731630 DOI: 10.1177/000348940311200409]
- Vincent R**, Lopez A, Sperling NM. Malleus ankylosis: a clinical, audiometric, histologic, and surgical study of 123 cases. *Am J Otol* 1999; **20**: 717-725 [PMID: 10565714]
- Lindsay J**, Farrior JB, Guilford F, Hough J, Ruedi PL. Panel on footplate pathology, techniques and prognosis. *Arch Otolaryngol* 1963; **78**: 520-538 [PMID: 14065018 DOI: 10.1001/archotol.1963.00750020532013]
- Nandapalan V**, Pollak A, Langner A, Fisch U. The anterior and superior malleal ligaments in otosclerosis: a histopathologic observation. *Otol Neurotol* 2002; **23**: 854-861 [PMID: 12438846 DOI: 10.1097/00129492-200211000-00008]
- Subotic R**, Mladina R, Risavi R. Congenital bony fixation of the malleus. *Acta Otolaryngol* 1998; **118**: 833-836 [PMID: 9870629 DOI: 10.1080/00016489850182530]
- Oktay MF**, Cureoglu S, Schachern PA, Gulbahce E, Paparella MM, Hayasi H. Histologic changes in the anterior malleal ligament and the head of the malleus in otosclerosis. *Otolaryngol Head Neck Surg* 2006; **134**: 232-235 [PMID: 16455369 DOI: 10.1016/j.otohns.2005.10.005]
- Ritter FN**. The histopathology of the congenital fixed malleus syndrome. *Laryngoscope* 1971; **81**: 1304-1313 [PMID: 5569679 DOI: 10.1288/00005537-197108000-00013]
- Miller ME**, Kirsch C, Canalis RF. Congenital familial fixation of the malleus. *Ann Otol Rhinol Laryngol* 2010; **119**: 319-324 [PMID: 20524577]
- Halmagyi GM**, Aw ST, McGarvie LA, Todd MJ, Bradshaw A, Yavor RA, Fagan PA. Superior semicircular canal dehiscence simulating otosclerosis. *J Laryngol Otol* 2003; **117**: 553-557 [PMID: 12901812 DOI: 10.1258/002221503322113003]
- Merchant SN**, Rosowski JJ, McKenna MJ. Superior semicircular canal dehiscence mimicking otosclerotic hearing loss. *Adv Otorhinolaryngol* 2007; **65**: 137-145 [PMID: 17245035 DOI: 10.1159/000098790]
- Minor LB**, Carey JP, Cremer PD, Lustig LR, Streubel SO, Ruckenstein MJ. Dehiscence of bone overlying the superior canal as a cause of apparent conductive hearing loss. *Otol Neurotol* 2003; **24**: 270-278 [PMID: 12621343 DOI: 10.1097/00129492-200303000-00023]
- Makarem AO**, Hoang TA, Lo WW, Linthicum FH, Fayad JN. Cavitating otosclerosis: clinical, radiologic, and histopathologic

- correlations. *Otol Neurotol* 2010; **31**: 381-384 [PMID: 20195188 DOI: 10.1097/mao.0b013e3181d275e8]
- 33 **Van Rompaey V**, Potvin J, van den Hauwe L, Van de Heyning P. Third mobile window associated with suspected otosclerotic foci in two patients with an air-bone gap. *J Laryngol Otol* 2011; **125**: 89-92 [PMID: 20727242 DOI: 10.1017/s0022215110001544]
 - 34 **Muchnik C**, Hildesheimer M, Rubinstein M, Arenberg IK. Low frequency air-bone gap in Menière's disease without middle ear pathology. A preliminary report. *Am J Otol* 1989; **10**: 1-4 [PMID: 2719083]
 - 35 **Lippy WH**, Wingate J, Burkey JM, Rizer FM, Schuring AG. Stapedectomy revision in elderly patients. *Laryngoscope* 2002; **112**: 1100-1103 [PMID: 12160281 DOI: 10.1097/00005537-200206000-00030]
 - 36 **Sheehy JL**, Perkins JH. Stapedectomy: gelfoam compared with tissue grafts. *Laryngoscope* 1976; **86**: 436-444 [PMID: 1256216 DOI: 10.1288/00005537-197603000-00013]
 - 37 **Sim JH**, Chatzimichalis M, Huber AM. The influence of postoperative tissue formation on sound transmission after stapes surgery. *Hear Res* 2010; **263**: 38-42 [PMID: 19766180 DOI: 10.1016/j.heares.2009.08.012]
 - 38 **Gristwood RE**, Venables WN. Otosclerotic obliteration of oval window niche: an analysis of the results of surgery. *J Laryngol Otol* 1975; **89**: 1185-1217 [PMID: 1082467 DOI: 10.1017/s0022215100081573]
 - 39 **Amedee RG**, Lewis ML. Obliterative otosclerosis. *Laryngoscope* 1987; **97**: 922-924 [PMID: 3613791 DOI: 10.1288/00005537-198708000-00007]
 - 40 **Raman R**, Mathew J, Idikula J. Obliterative otosclerosis. *J Laryngol Otol* 1991; **105**: 899-900 [PMID: 1761942 DOI: 10.1017/s0022215100117773]
 - 41 **Sheehy JL**, Nelson RA, House HP. Revision stapedectomy: a review of 258 cases. *Laryngoscope* 1981; **91**: 43-51 [PMID: 7453465 DOI: 10.1288/00005537-198101000-00007]
 - 42 **Borrmann A**, Arnold W. Non-syndromal round window atresia: an autosomal dominant genetic disorder with variable penetrance? *Eur Arch Otorhinolaryngol* 2007; **264**: 1103-1108 [PMID: 17476517 DOI: 10.1007/s00405-007-0305-1]
 - 43 **Shea JJ**, Farrior JB. Stapedectomy and round window closure. *Laryngoscope* 1987; **97**: 10-12 [PMID: 3796166 DOI: 10.1288/00005537-198701000-00004]
 - 44 **Harris JP**, Keithley EM. Inner ear inflammation and round window otosclerosis. *Am J Otol* 1993; **14**: 109-112 [PMID: 8503480]
 - 45 **Lagleyre S**, Calmels MN, Escude B, Deguine O, Fraysse B. Revision stapes surgery: the "lateralized piston syndrome". *Otol Neurotol* 2009; **30**: 1138-1144 [PMID: 19953702 DOI: 10.1097/MAO.0b013e3181c0e80f]
 - 46 **Gibbin KP**. The histopathology of the incus after stapedectomy. *Clin Otolaryngol Allied Sci* 1979; **4**: 343-354 [PMID: 487633 DOI: 10.1111/j.1365-2273.1979.tb01763.x]
 - 47 **Tange RA**. Repair of the ossicular chain with an ionomer cement by an inadequate incus after prior stapes surgery for otosclerosis. *Eur Arch Otorhinolaryngol* 1996; **253**: 313-315 [PMID: 8737793 DOI: 10.1007/bf00171151]
 - 48 **Martin C**, Oletski A, Prades JM. Surgery of idiopathic malleus fixation. *Otol Neurotol* 2009; **30**: 165-169 [PMID: 19180677 DOI: 10.1097/mao.0b013e318191a66d]
 - 49 **Sheehy JL**. Stapedectomy: incus bypass procedures. A report of 203 operations. *Laryngoscope* 1982; **92**: 258-262 [PMID: 7070169 DOI: 10.1288/00005537-198203000-00007]
 - 50 **Mangham CA**. Long-term impact of incus necrosis on revision stapes surgery: incus versus malleus reconstruction. *Otol Neurotol* 2009; **30**: 1145-1151 [PMID: 19887980 DOI: 10.1097/MAO.0b013e3181c2a009]
 - 51 **Ghonim MR**, Shabana YK, Elkotb MY. Outcome of malleo-stapedotomy using the malleus relocation technique during revision stapes surgery. *J Laryngol Otol* 2011; **125**: 441-444 [PMID: 21054909 DOI: 10.1017/s0022215110002264]
 - 52 **Kwok P**, Fisch U, Nussbaumer M, Herkenhoff S, Strutz J. Morphology of the malleus handle and the comparison of different prostheses for malleostapedotomy. *Otol Neurotol* 2009; **30**: 1175-1185 [PMID: 19300298 DOI: 10.1097/MAO.0b013e31819e6361]
 - 53 **Kohan D**, Sorin A. Revision stapes surgery: the malleus to oval window wire-piston technique. *Laryngoscope* 2003; **113**: 1520-1524 [PMID: 12972927 DOI: 10.1097/00005537-200309000-00020]
 - 54 **Häusler R**, Steinhart U. A new self-fixing and articulated malleus grip stapedectomy prosthesis. *Adv Otorhinolaryngol* 2007; **65**: 197-201 [PMID: 17245046 DOI: 10.1159/000098807]
 - 55 **Seidman MD**, Babu S. A new approach for malleus/incus fixation: no prosthesis necessary. *Otol Neurotol* 2004; **25**: 669-673 [PMID: 15353993 DOI: 10.1097/00129492-200409000-00004]
 - 56 **Jahnke K**, Solzbacher D, Dost P. Revision stapes surgery. *Adv Otorhinolaryngol* 2007; **65**: 314-319 [PMID: 17245064 DOI: 10.1159/000098851]
 - 57 **Haberkamp TJ**, Harvey SA, Khafagy Y. Revision stapedectomy with and without the CO2 laser: an analysis of results. *Am J Otol* 1996; **17**: 225-229 [PMID: 8723952]
 - 58 **McGee TM**, Diaz-Ordaz EA, Kartush JM. The role of KTP laser in revision stapedectomy. *Otolaryngol Head and Neck Surg* 1993; **109**: 839-843 [PMID: 8247562]
 - 59 **Wanamaker HH**, Silverstein H. Compatibility of the argon and KTP lasers with middle ear implants. *Laryngoscope* 1993; **103**: 609-613 [PMID: 8388975 DOI: 10.1288/00005537-199306000-00006]
 - 60 **Gerlinger I**, Pytel J, Liktov B, Lujber L. Effect of KTP laser on implants used in middle-ear surgery. *J Laryngol Otol* 2002; **116**: 502-506 [PMID: 12238668 DOI: 10.1258/002221502760132575]
 - 61 **Silverstein H**, Bendet E, Rosenberg S, Nichols M. Revision stapes surgery with and without laser: a comparison. *Laryngoscope* 1994; **104**: 1431-1438 [PMID: 7990630 DOI: 10.1288/00005537-199412000-00002]
 - 62 **Wiet RJ**, Kubek DC, Lemberg P, Byskosh AT. A meta-analysis review of revision stapes surgery with argon laser: effectiveness and safety. *Am J Otol* 1997; **18**: 166-171 [PMID: 9093671]
 - 63 **Han WW**, Incesulu A, McKenna MJ, Rauch SD, Nadol JB, Glynn RJ. Revision stapedectomy: intraoperative findings, results, and review of the literature. *Laryngoscope* 1997; **107**: 1185-1192 [PMID: 9292601 DOI: 10.1097/00005537-199709000-00006]
 - 64 **Palva T**, Ramsay H. Revision surgery for otosclerosis. *Acta Otolaryngol* 1990; **110**: 416-420 [PMID: 2284916 DOI: 10.3109/0016489009122568]
 - 65 **Richards ML**, Moorhead JE, Antonelli PJ. Sympathetic cochleolabyrinthitis in revision stapedectomy surgery. *Otolaryngol Head Neck Surg* 2002; **126**: 273-280 [PMID: 11956535 DOI: 10.1067/mhn.2002.122702]
 - 66 **Meyer TA**, Lambert PR. Primary and revision stapedectomy in elderly patients. *Curr Opin Otolaryngol Head Neck Surg* 2004; **12**: 387-392 [PMID: 15377949]
 - 67 **Crabtree JA**, Britton BH, Powers WH. An evaluation of revision stapes surgery. *Laryngoscope* 1980; **90**: 224-227 [PMID: 7354690 DOI: 10.1288/00005537-198002000-00006]
 - 68 **Pearman K**, Dawes JD. Post-stapedectomy conductive deafness and results of revision surgery. *J Laryngol Otol* 1982; **96**: 405-410 [PMID: 7077135 DOI: 10.1017/s0022215100092665]
 - 69 **Bhardwaj BK**, Kacker SK. Revision stapes surgery. *J Laryngol Otol* 1988; **102**: 20-24 [PMID: 3343556 DOI: 10.1017/s0022215100103858]
 - 70 **Somers T**, Govaerts P, de Varebeke SJ, Offeciers E. Revision stapes surgery. *J Laryngol Otol* 1997; **111**: 233-239 [PMID: 9156059 DOI: 10.1017/s0022215100136989]
 - 71 **De La Cruz A**, Fayad JN. Revision stapedectomy. *Otolaryngol Head Neck Surg* 2000; **123**: 728-732 [PMID: 11112966 DOI: 10.1067/mhn.2000.111285]
 - 72 **Lippy WH**, Battista RA, Berenholz L, Schrung AG, Burkey JM. Twenty-year review of revision stapedectomy. *Otol Neurotol* 2003; **24**: 560-566 [PMID: 12851545 DOI: 10.1097/00129492-200307000-00005]
 - 73 **Gros A**, Vatovec J, Zargi M, Jenko K. Success rate in revision stapes surgery for otosclerosis. *Otol Neurotol* 2005; **26**: 1143-1148 [PMID: 16272932 DOI: 10.1097/01.mao.0000172414.64907.9d]

- 74 **Babighian GG**, Albu S. Failures in stapedotomy for otosclerosis. *Otolaryngol Head Neck Surg* 2009; **141**: 395-400 [PMID: 19716020 DOI: 10.1016/j.otohns.2009.03.028]
- 75 **Birch L**, Elbrønd O. Stapedectomy and vertigo. *Clin Otolaryngol Allied Sci* 1985; **10**: 217-223 [PMID: 4053423 DOI: 10.1111/j.1365-2273.1985.tb00244.x]
- 76 **Tribukait A**, Bergenius J. The subjective visual horizontal after stapedotomy: evidence for an increased resting activity in otolithic afferents. *Acta Otolaryngol* 1998; **118**: 299-306 [PMID: 9655202 DOI: 10.1080/00016489850183368]
- 77 **Ozmen AO**, Aksoy S, Ozmen S, Saraç S, Sennaroğlu L, Gürsel B. Balance after stapedotomy: analysis of balance with computerized dynamic posturography. *Clin Otolaryngol* 2009; **34**: 212-217 [PMID: 19531169 DOI: 10.1111/j.1749-4486.2009.01915.x]
- 78 **Parnes S**, Black FO, Wall C, O'Leary DP, Feltyberger E. Vestibular system abnormalities in otosclerotic subjects. *Otolaryngology* 1978; **86**: ORL-98-ORL106 [PMID: 114928]
- 79 **Koizuka I**, Sakagami M, Doi K, Takeda N, Matsunaga T. Nystagmus measured by ENG after stapes surgery. *Acta Otolaryngol Suppl* 1995; **520** Pt 2: 258-259 [PMID: 8749133 DOI: 10.3109/00016489509125242]
- 80 **Kujala J**, Aalto H, Hirvonen TP. Video-oculography findings in patients with otosclerosis. *Otol Neurotol* 2005; **26**: 1134-1137 [PMID: 16272930 DOI: 10.1097/01.mao.0000179525.40156.fa]
- 81 **Sooy FA**, Owens E, Neufeld ES. Comparison of wire-vein and wire-gelfoam prostheses in stapedectomy for otosclerosis. *Ann Otol Rhinol Laryngol* 1973; **82**: 149-152 [PMID: 4702350 DOI: 10.1177/000348947308200210]
- 82 **Bordure P**, Legent F, Calais C, Loheac D, Beauvillain C. [Pneumolabyrinth and perilymphatic fistula after stapedectomy]. *Ann Otolaryngol Chir Cervicofac* 1990; **107**: 359-362 [PMID: 2256607]
- 83 **Seicshnaydre MA**, Sismanis A, Hughes GB. Update of reparative granuloma: survey of the American Otological Society and the American Neurotology Society. *Am J Otol* 1994; **15**: 155-160 [PMID: 8172294]
- 84 **Gacek RR**. The diagnosis and treatment of poststapedectomy granuloma. *Ann Otol Rhinol Laryngol* 1970; **79**: 970-975 [PMID: 5506041 DOI: 10.1177/000348947007900516]

P- Reviewer: Nakashima T, Riga M **S- Editor:** Tian YL

L- Editor: A **E- Editor:** Lu YJ





Published by **Baishideng Publishing Group Inc**

8226 Regency Drive, Pleasanton, CA 94588, USA

Telephone: +1-925-223-8242

Fax: +1-925-223-8243

E-mail: bpgoffice@wjgnet.com

Help Desk: <http://www.wjgnet.com/esps/helpdesk.aspx>

<http://www.wjgnet.com>

