

Endocrine hypertension: An overview on the current etiopathogenesis and management options

Reena M Thomas, Ewa Ruel, Prapimporn Ch Shantavasinkul, Leonor Corsino

Reena M Thomas, Ewa Ruel, Leonor Corsino, Division of Endocrinology, Metabolism and Nutrition, Department of Medicine, Duke University Medical Center, Durham, NC 27710, United States

Prapimporn Ch Shantavasinkul, Division of Nutrition and Biochemical Medicine, Department of Medicine, Ramathibodi Hospital, Faculty of Medicine, Mahidol University, Bangkok 10400, Thailand

Author contributions: Thomas RM, Ruel E, Shantavasinkul PC and Corsino L had made substantial contributions to the drafting of the article or revising it critically for important intellectual content.

Supported by NIH/NIDDK training to Dr. Ruel, No. T32DK007012-36A1; a visiting scholar grant from Mahidol University, Thailand to Dr. Shantavasinkul.

Conflict-of-interest: The authors report no conflict of interest.

Open-Access: This article is an open-access article which was selected by an in-house editor and fully peer-reviewed by external reviewers. It is distributed in accordance with the Creative Commons Attribution Non Commercial (CC BY-NC 4.0) license, which permits others to distribute, remix, adapt, build upon this work non-commercially, and license their derivative works on different terms, provided the original work is properly cited and the use is non-commercial. See: <http://creativecommons.org/licenses/by-nc/4.0/>

Correspondence to: Leonor Corsino, MD, MHS, FACE, Assistant Professor of Medicine, Division of Endocrinology, Metabolism and Nutrition, Duke University Medical Center, Box 3451, Durham, NC 27710,

United States. leonor.corsinonunez@dm.duke.edu

Telephone: +1-919-6843841

Fax: +1-919-6681559

Received: October 4, 2014

Peer-review started: October 5, 2014

First decision: November 14, 2014

Revised: December 6, 2014

Accepted: March 4, 2015

Article in press: March 6, 2015

Published online: May 23, 2015

primary aldosteronism, pheochromocytoma, cushing's syndrome, hyperparathyroidism and hypo- and hyperthyroidism. They comprise 5%-10% of the causes of secondary hypertension. Primary hyperaldosteronism, the most common of the endocrine cause of hypertension often presents with resistant or difficult to control hypertension associated with either normo- or hypokalemia. Pheochromocytoma, a great mimicker of many conditions, is associated with high morbidity and mortality if left untreated. A complete history including pertinent family history, physical examination along with a high index of suspicion with focused biochemical and radiological evaluation is important to diagnose and effectively treat these conditions. The cost effective targeted genetic screening for current known mutations associated with pheochromocytoma are important for early diagnosis and management in family members. The current review focuses on the most recent evidence regarding causes, clinical features, methods of diagnosis, and management of these conditions. A multidisciplinary approach involving internists, endocrinologists and surgeons is recommended in optimal management of these conditions.

Key words: Primary aldosteronism; Hyperaldosteronism; Adrenal; Adenoma; Pheochromocytoma

© The Author(s) 2015. Published by Baishideng Publishing Group Inc. All rights reserved.

Core tip: This is an invited manuscript to present a summary of the most recent information on the etiology, diagnosis and management of endocrine diseases as a cause of secondary hypertension.

Thomas RM, Ruel E, Shantavasinkul PC, Corsino L. Endocrine hypertension: An overview on the current etiopathogenesis and management options. *World J Hypertens* 2015; 5(2): 14-27 Available from: URL: <http://www.wjgnet.com/2220-3168/full/v5/i2/14.htm> DOI: <http://dx.doi.org/10.5494/wjh.v5.i2.14>

Abstract

Endocrine causes of secondary hypertension include

INTRODUCTION

Secondary hypertension, a term used for the hypertension for which there is an identifiable cause, accounts for 10% of all patients with hypertension^[1,2]. Endocrine conditions as a cause of secondary hypertension comprise 5%-10% of all patients with hypertension^[2]. Although this form of hypertension is rare, identification and treatment of the underlying cause, might lead to the cure or significant improvement of the hypertension, thereby decreasing the cardiovascular risk and morbidities associated with hypertension.

The endocrine conditions causing secondary hypertension are primary aldosteronism, pheochromocytoma, Cushing's syndrome, acromegaly, hyperparathyroidism, congenital adrenal hyperplasia, hypothyroidism, hyperthyroidism and renin-secreting tumors. Current evidence shows no benefit of screening for endocrine causes of hypertension in all patients presenting with hypertension. However, it is important to maintain a high index of clinical suspicion based on the knowledge of the clinical features and presentation of these conditions.

In this review, we will focus on the etiopathogenesis, diagnosis and treatment of the most common endocrine causes of hypertension-primary hyperaldosteronism (PAH) and pheochromocytoma.

PAH

Introduction

PAH is one of the most common causes of secondary hypertension^[3]. As such, it is recommended that this condition be considered in the differential diagnosis of patients with uncontrolled hypertension. With the advent of more refined testing, it is widely quoted to account for 5%-13% of the population with age of onset between 30 and 60^[3]. A recent prospective study of 1180 patients with newly diagnosed hypertension found a prevalence of primary hyperaldosteronism of 4.8%^[4]. PAH is due to either idiopathic hyperaldosteronism (IHA) or due to aldosterone producing adenoma (APA). IHA involves bilateral adrenals and accounts for an estimated 60%-66% of diagnosis. APA, the classic case first discovered by Conn over 60 years ago, is a unilateral adrenal adenoma and makes up the majority of remaining cases of primary hyperaldosteronism (30%-35%)^[3,5]. However, the prospective study described above found that the exact make up of what constitutes the majority of primary hyperaldosteronism diagnosis varies depending on access to confirmatory testing, notably adrenal vein sampling (AVS). More patients were diagnosed with bilateral than unilateral disease if there was no access to AVS and vice versa^[4]. Thus, depending on access to an academic center with AVS expertise, the prevalence of bilateral vs unilateral disease will differ. Additionally, 2% of cases of primary hyperaldosteronism involve a unilateral hyperplasia also

known as primary adrenal hyperplasia. This is thought to be a micro or macronodular area of hyperplasia in the zona glomerulosa of the adrenal gland that is limited to only one rather than both adrenals^[3]. Further, 2% of patients have a familial hyperaldosteronism syndrome type 1 or 2^[3]. Type 1 is glucocorticoid-remediable aldosteronism (GRA) and type 2 familial aldosterone-producing adenoma or IHA^[6]. These are further discussed in the section on genetic disorders. The remaining rare categories of aldosterone producers (1%) are adrenocortical carcinoma, or ectopic production of aldosterone such as ovarian or renal source^[5,7].

Clinical presentation: The classic patient with primary hyperaldosteronism presents with difficult to control hypertension and hypokalemia. If severe, hypokalemia may be accompanied by muscle weakness, cramping, headaches, palpitations, and polyuria. Hypokalemia may be unmasked with the addition of diuretics. The presentation of hyperaldosteronism varies and many patients may present with hypertension without hypokalemia. A higher index of suspicion is necessary in order to make the diagnosis.

Screening for PAH should be considered for hypertensive patients with the following presentation: hypokalemia, difficult to control hypertension on 3 or more anti-hypertensive drugs or hypertension of ≥ 160 mmHg systolic and ≥ 100 mmHg diastolic, or those with hypertension and an incidental adrenal mass, young onset of hypertension, or those being evaluated for other causes of secondary hypertension^[3]. The Endocrine Society Guidelines published in 2008 echoed these recommendations adding that screening should also include those with hypertension and diuretic-induced hypokalemia, those with family history of early onset hypertension or stroke at age < 40 , as well as all hypertensive patients with a first degree relatives with primary hyperaldosteronism^[8].

APA: Patients with APA tend to be younger and present with severe symptoms in terms of degree and frequency of hypertension and hypokalemia, respectively. Biochemical analysis reveals higher plasma levels of aldosterone (> 25 ng/dL plasma aldosterone)^[9,10].

Cardiovascular and renal effects: Recent evidence has called attention to the increase of cardiovascular events associated with hyperaldosteronism. Specifically, in a study with case matched patients with essential hypertension, those with hyperaldosteronism had more cardiovascular events and increased left ventricular hypertrophy independent of blood pressure levels^[11]. These left ventricle changes appeared to be reversible post adrenalectomy^[12].

A recent prospective Italian study > 1100 patients found that urine albumin was significantly increased as compared to patients with essential hypertension, presumably highlighting increased renal damage with

PAH^[13].

Diagnosis

The biochemical hallmarks of primary hyperaldosteronism are low potassium, high aldosterone, and low renin. Hypokalemia itself, while helpful in recognizing the disease, is not required, with only 9%-37% of patients presenting with hypokalemia^[14]. Normal potassium cannot rule out hyperaldosteronism as some patients with primary hyperaldosteronism will have normal potassium levels^[15]. Additionally, most patients with hypertension who have hypokalemia do not have PAH^[16]. Low renin and elevated aldosterone are hallmarks. However, low renin on its own can be found in patients taking beta-blockers, high sodium intake, steroids, licorice or with low renin essential hypertension^[16]. Further, plasma and urine aldosterone levels are subject to confounders including incomplete urine assays, influence of hypokalemia and diurnal variation^[16].

The diagnosis for primary hyperaldosteronism traditionally includes the following 3 steps: (1) screening; (2) confirmation; and (3) diagnosis of subtype^[3,8]. Debate over exact cutoffs for screening, the need for confirmatory testing and the best way to distinguish APA from other subtypes is ongoing.

Screening: Initial screening of patients suspected to have hyperaldosteronism should be conducted with a morning (preferably 8-10 am) plasma aldosterone and renin values. For proper interpretation, aldosterone and renin testing should be performed in the morning on a seated ambulatory patient^[8]. Though plasma aldosterone to renin ratio is considered a screening test, some physicians forgo additional lab testing once this screen is obtained^[17]. It is important to note, however, that debate exists over the exact cutoffs for the ratio, with a recent study finding a ratio of 32 ng/mL per hour^[18]. Some experts advocate for the use of both a ratio and an aldosterone level. For example, using a plasma aldosterone to plasma renin activity ratio of more than 30 ng/mL per hour and a plasma aldosterone of more than 20 ng/dL combination is 90% sensitive and 91% specific, with a positive predictive value of 69% and negative predictive value of 98%^[16]. Physicians need to be aware that false positives and negatives do occur^[19]. Testing in general is affected by medications (including many anti-hypertensive, oral contraceptives, and selective serotonin reuptake inhibitors), renal function, upright posture, age, sex and pregnancy^[19,20]. Thus, tests should be interpreted with caution and in many cases repeated to confirm results. Additionally, biochemical results may be laboratory and assay dependent. There exists variability in assays and units used in reporting various cut offs^[8,20]. Further, laboratories measuring renin must be able to detect renin at its lowest range; this has been found to be a limitation of some laboratories^[8]. It is critical that providers become familiar with their own laboratories units and measurement assays while interpreting their

results.

Impact of medications on screening: Ideally, hypertensive drugs interfering with renin and aldosterone measurements should be discontinued at least 2 wk prior to laboratory testing. However, for those patients with severe hypertension who are on multiple anti-hypertensives, this may not be safe and tolerable. Several studies suggest that anti-hypertensives need not be discontinued for screening^[15,21], but the debate continues. Experts in the field suggest that if discontinuation of all antihypertensive medications is not feasible because of the concern of patient safety, providers should discontinue mineralocorticoid receptor antagonist such as spironolactone, eplerenone and amiloride for at least 4 wk prior to testing and use other medications to control hypertension^[8]. The Endocrine Society practice guidelines suggest the following medications (verapamil, hydralazine, prazosin hydrochloride, doxazosin and terazosin) as alternatives during screening because of their minimal impact on screening assays^[8].

Confirmatory testing: While an increased ratio of plasma aldosterone to plasma renin is highly suggestive of the diagnosis, some experts advocate for confirmatory testing. For patients with severe cardiac or renal disease, confirmatory testing may not be advised. Currently there are no gold standard confirmatory tests^[8]. The Endocrine Society guidelines suggest the following as potential confirmatory test: oral sodium loading test, saline infusion test, fludrocortisone suppression test, and the captopril challenge test^[8]. The selection of a confirmatory test should be based on cost, time, morbidity and conflicting data on sensitivity and specificity of the test^[17].

A recent study in Japan of 120 cases examined the diagnostic relevance of captopril challenge and saline infusion testing to confirm positive screening test and concluded that most patients with positive screens also had positive confirmatory testing. The study challenges the point that not all cases may require confirmatory testing to establish the diagnosis^[22].

Salt loading test is one of the most commonly used confirmatory tests. Once blood pressure is stable and potassium is replete, the patient is given oral salt tablets for 3 d. Subsequently, a 24 h urine aldosterone is measured. Careful monitoring of blood pressure and potassium is required. The test is considered positive when the 24 h urine aldosterone level is > 12 µg/24 h or 33 nmol/d with a concomitant 24 h urine sodium excretion of > 200 mmol/d (approximately 6 g/d). This test provides > 90% sensitivity and specificity^[23].

Intravenous saline infusion test involves the infusion 2 L of normal saline over 4 h after an overnight fast and drawing plasma aldosterone level post infusion. Plasma aldosterone levels above 10 ng/dL or 277 pmol/L (as compared to less than 5 ng/dL or 139 pmol/L for controls) is considered confirmatory for a diagnosis of primary hyperaldosteronism^[24].

The fludrocortisone suppression test and the captopril challenge test are not widely used in clinical practice due to cardiovascular concerns, the need to follow the patient closely during the test, challenges in interpreting the results, and risk for false negative and equivocal results^[25].

Imaging modalities

Localization of the source of primary hyperaldosteronism is key to the treatment. Only unilateral adenomas or APA are treated with surgery. Imaging helps to distinguish between unilateral vs bilateral disease. Recent research has focused on how to best utilize computerized tomography (CT) scan vs AVS in order to correctly identify those patients who may potentially be cured with surgery^[5,26,27].

CT imaging: Adrenal CT imaging alone cannot reliably distinguish a unilateral source of hyperaldosteronism, especially in older patients^[5,9]. In a prospective study of 203 patients with primary hyperaldosteronism selected for AVS, CT scan could identify unilateral vs bilateral aldosterone source in about half (53%) of the cases^[5]. CT can also create confusion if it reveals normal adrenals, bilateral large nodules or bilateral small < 1 cm adrenal nodules^[26]. Specifically, a small growth noted on adrenal gland with another on the other may be falsely categorized a patient as having bilateral hyperplasia whereas in reality the smaller growth is non-functioning and the patient has a unilateral adenoma that warrants referral for surgery^[5].

Traditionally, unilateral adenomas appear as small nodules < 2 cm in diameter and are hypodense. In contrast, it should be noted that adrenal carcinomas are usually > 4 cm in diameter and are heterogeneous on CT scan. IHA can appear as bilateral nodules on CT scan. However, sometimes, the CT scan can be read as normal. Given the caveats of adrenal CT scans, imaging must often be combined with other test modalities with most favoring AVS for biochemical confirmation of laterality prior to surgical intervention.

Scintigraphy: Scintigraphy iodomethyl-nor-cholesterol (NP-59) uptake also known as dexamethasone-suppression DS adrenal scintigraphy can be considered for adenomas > 1.5 cm in diameter. However, a definitive distinction of unilateral vs bilateral source of aldosterone cannot be made as tracer uptake for the most part correlates with tumor volume and less so with tumor secretion^[28]. This imaging is not useful in cases with microadenomas. Imaging with scintigraphy does not reliably replace adrenal venous sampling in characterizing nodule function^[28].

AVS: Selective AVS is the most reliable technique used to distinguish a true unilateral adenoma (APA) from bilateral disease notably IHA^[29]. AVS is critical in categorizing certain patients correctly. In a prospective

study of 203 patients selected for AVS to determine if the diagnosis could be made based solely on CT showed that 48 patients (24.7%) would have had inappropriate surgery and 42 patients (21.7%) would have been denied needed for surgery based on CT scan results alone^[5]. AVS may be helpful for patients when adrenal CT is normal, shows micronodularity (unilateral or bilateral < 1 cm) or a combination of micro and macronodules^[5,26]. In a recent radiological study, matching patients who underwent CT vs CT and AVS found that for tumors larger than 1 cm, CT can reliably predict unilateral disease and thus obviate the need for AVS. This study concluded that AVS is helpful when CT study is equivocal or shows bilateral disease^[27]. An algorithm based partly on age of more or less than age 40, together with the nodule's appearance, size and uni-laterality as seen on CT scan may best guide next steps, including referral for AVS^[26]. Based on this algorithm, it should be noted that patients younger than age 40 with a unilateral hypo-dense nodule > 1 cm on adrenal CT scan who have a very high probability of unilateral adenoma may proceed to surgery without AVS^[26]. An expert consensus statement has defined the following exceptions to recommending AVS: age < 40 years with marked PA and a clear unilateral adrenal adenoma and a normal contralateral adrenal gland on CT, unacceptable high risks of adrenal surgery (*i.e.*, due to multiple comorbidities), those with suspected adrenocortical carcinoma and those with proven Familial Hyperaldosteronism- I or with Familial Hyperaldosteronism-III^[30].

In AVS, adrenal veins are accessed *via* the femoral vein. Blood samples are taken from both adrenal veins and compared to that found in the inferior vena cava (IVC) at the level below the renal veins. The right adrenal vein may be particularly challenging to access. The left adrenal sample is accessed from the inferior phrenic vein next to the adrenal vein^[5]. During the study, cosyntropin or ACTH is infused throughout the procedure to minimize fluctuations in aldosterone levels due to stress^[26]. Using a radioimmunoassay, aldosterone and cortisol concentrations of the right and left adrenal glands as well as the IVC are measured. To account for dilution, the aldosterone concentration is then corrected using cortisol so that an aldosterone/cortisol ratio is obtained. The ratios of aldosterone to cortisol from each side are then compared^[5]. Traditionally, the cut off for distinguishing a unilateral source of aldosterone is a lateralization ratio of > 5^[31]. However, a recent study found a lateralization ratio of more than > 4 as indicative of APA^[5]. Others suggest a cortisol-corrected aldosterone ratio from high side to low side more than 4:1 is indicative of unilateral aldosterone excess; a ratio less than 3:1 is suggestive of bilateral aldosterone hypersecretion^[8].

There are several complications that may occur during AVS. These can be as high as 5%. These complications are: groin hematoma, adrenal hemorrhage, dissection

of adrenal vein and paroxysmal atrial fibrillation. Theoretically, Addisonian crisis could also occur^[5]. There is a major limitation of AVS including the access to institutions that perform this specialized, highly skilled procedure. A recent international study of AVS, found that many referral centers worldwide, do not use AVS^[32], mainly because of lack of skilled professionals with experience conducting the procedure. In a recent study, the failure rate of AVS was low at 4.4%. However, the study relied on one angiographer to perform the vast majority of procedures^[5]. In general, the failure rate can be greater than 25%^[33].

Management

Medical management: Medical management should be provided to all patients with demonstrated bilateral disease. Additionally, medical management is an option for patients with unilateral disease who do not undergo surgery. It has been noted that those with IHA are more likely to require multi drug treatment as compared to APA^[34].

The main stay of treatment of PAH is spironolactone, a competitive aldosterone receptor antagonist^[34]. Spironolactone should be started in patients without contraindications. The starting dose is 12.5-25 mg per day. It is recommended that the prescribing provider follow the patient's blood pressure and potassium levels closely. The follow up should be close for the first couple of weeks after starting this medication. Spironolactone should be titrated slowly until blood pressure is controlled to a maximum dose of 100 mg per day^[8]. Spironolactone has multiple side effects that may affect quality of life particularly for male patients, the most notable side effect being gynecomastia. In general, side effects as noted by patients may include breast tenderness, breast engorgement, decreased libido, muscle cramps, erectile dysfunction, menstrual irregularities and loss of axillary hair^[35].

Eplerenone, a selective aldosterone receptor antagonist, has fewer side effects as compared to spironolactone but is more costly. Due to minimal affinity for the androgen, estrogen and progesterone receptors, this drug does not result in significant androgen effects such as gynecomastia that is associated with spironolactone. In a small study comparing, blood pressure in patients with bilateral IHA, eplerenone dosed at 50-400 mg per day was shown to be just as effective as spironolactone. Furthermore, 2 patients had gynecomastia reversed by switching from spironolactone to eplerenone^[34]. In a recent prospective study evaluating long term follow up of patients and renal function, they included: adrenalectomy (86 cases), eplerenone (18 cases) and spironolactone (65 cases), spironolactone was just as good at preserving Glomerular Filtration Rate (GFR) and urine albumin excretion as patients who had an adrenalectomy, however patients on eplerenone required on average more anti-hypertensive medications^[36]. The starting dose for eplerenone is 25 mg per day or twice a day.

Both, spironolactone and eplerenone, should be used with caution in patients with chronic kidney disease stage 3 because of the risk of hyperkalemia. They should be avoided in patients with end stage renal disease and chronic kidney disease stage 4. Amiloride, a sodium channel blocker can also correct hypokalemia and improve blood pressure without the side effects of spironolactone. Muscle cramps have been noted as side effect^[35].

Calcium channel blockers can decrease aldosterone secretion and have variable success at lowering blood pressure. Angiotensin converting enzyme inhibitors may also improve blood pressure. It is postulated that IHA would be more responsive to treatment since APAs are autonomous and would therefore be less likely to respond to angiotensin II. Angiotensin II inhibitors have a role as additional agents in treatment^[37]. In a small study looking at long term follow up of patients with APA who chose medical therapy, with a follow up time between 5-17 years, blood pressure was at goal for 75% of participants. The majority patients ($n = 24$) were receiving a potassium-sparing diuretic plus an additional blood pressure medication. All had resolution of hypokalemia. In the time of follow up, none had a malignant transformation and none experienced stroke, myocardial infarction or heart failure^[35].

Surgery: Once potassium and blood pressure are controlled, laparoscopic adrenalectomy is indicated for unilateral source of aldosteronism. AVS should be considered prior to surgery as discussed in detail above. The laparoscopic approach is preferred because it offers faster recovery from surgery with associated shorter length of stay and lower morbidity^[38].

A recent study, found that adrenalectomy (the majority of which was done laparoscopically) did have lower overall medical costs compared to medical treatment^[39]. Further, surgery for APA has been shown to normalize hypokalemia and improve if not normalize blood pressure. In one third to half of patients it can offer a cure by normalizing blood pressure^[40].

In contrast, for bilateral disease or IHA, unilateral or bilateral adrenalectomy is not indicated. Surgery for IHA in general does not correct the hypertension. In some select cases of bilateral disease, those with poorly controlled hypertension on more than three drugs, with incomplete lateralization on AVS, a unilateral adrenalectomy may be considered. In some cases, blood pressure may improve and the patient may be able to take fewer anti-hypertensive drugs post surgery^[5,41].

Surgical outcome and post-operative follow up:

Thirty to 60% of patients with a unilateral aldosterone tumor can be cured and achieve normal blood pressure after surgery. However, many may still require at least one blood pressure medication post surgery^[42].

In general, mineralocorticoid receptor antagonist and potassium supplements are discontinued post

op. During the first month post surgery a generous salt diet is encouraged to stimulate the contralateral adrenal gland. Blood pressure normalizes within 6 mo but can take up to one year post surgery^[42]. Patients that are more likely to have persistent hypertension despite adrenalectomy include: older age, chronic hypertension > 5 years, larger tumor size, significant family history of hypertension and those with additional secondary hypertension^[40,43-47]. Also, one study found that higher creatinine levels also predicts persistent hypertension post surgery^[48].

Recently, a score card of low, medium or high likelihood of hypertension resolution post surgery was recently developed using a predictive regression model that compiled data from 100 patients with primary hyperaldosteronism who underwent adrenalectomy. Based on 4 predictors: ≤ 2 or fewer anti-hypertensive drugs (2 points), body mass index ≤ 25 kg/m² (1 point), hypertension of ≤ 6 years (1 point) and female sex (1 point), the likelihood of a cure was low (27% cured), medium or high (75% cured)^[49]. Using data from 91 Japanese patients, this score card was validated in an Asian population^[50].

PAH and associated genetic disorders: A minority of patients (1%-2%) with PAH have a familial syndrome type I or II. Type I is GRA and type II familial aldosterone-producing adenoma or IHA^[6]. Recently, a new genetic form, familial hyperaldosteronism type III has also been identified^[51].

Type I (GRA) is an autosomal dominant condition characterized by variable degree of aldosterone excess, increased steroids (18-hydroxycortisol and 18-oxocortisol), and suppression of disease with glucocorticoid treatment. It is due to a chimeric gene duplication between the CYP11B1 (11 β -hydroxylase) and CYP11B2 (aldosterone synthase) genes. Genetic testing should be targeted to those with hypertension at age < 20 that is resistant, accompanied by hypokalemia, family history of hypertension, and cerebral hemorrhage at a young age^[52]. The Endocrine Society guidelines recommend genetic testing to rule out GRA for those patients who have onset of hypertension at age < 20, and those with a family history primary hyperaldosteronism or stroke at age < 40^[8].

Type II familial hyperaldosteronism is an autosomal dominant condition that does not suppressed with exogenous glucocorticoids and has been linked to locus 7p22^[6]. Type III familial hyperaldosteronism involves a germline mutation in the gene coding for ion channel KCNJ5^[51].

Conclusion

Primary hyperaldosteronism is found in 5%-13% of population^[3] Prevalence has increased with the advent of more refined screening and confirmatory studies. However, specific screening cutoffs vary by institution. The majority of patients fall into one of two categories:

APA, which is unilateral and should be surgically removed, and IHA which is bilateral and requires medical management.

The cost and morbidity of chronic medication, as well as new evidence that hyperaldosteronism itself aside from blood pressure may increase cardiac events and possibly renal dysfunction, needs to be considered. AVS is the most reliable technique used to distinguish a true unilateral adenoma (APA) from bilateral disease notably IHA. However, this procedure is highly specialized and is not available at every institution. With the advent of safe, less invasive, and shorter surgery, laparoscopic adrenalectomy for APA is preferred as it offers the best chance for a cure.

PHEOCHROMOCYTOMA

Introduction

Pheochromocytoma is a tumor of the adrenal medulla (chromaffin cells) that secretes excess catecholamines, epinephrine, norepinephrine, and dopamine. Paraganglioma is a tumor derived from extra-adrenal chromaffin cells of the sympathetic nervous system. Pheochromocytomas and catecholamine secreting paragangliomas account for 0.2%-0.6% of all causes of hypertension in the population^[53-55]. Both of these tumors have similar clinical presentations and management. However, it is important to classify them separately because of the implications of genetic testing, risk of malignancy and associated neoplasms. In this review, we will focus mainly on pheochromocytomas arising from the adrenal gland.

Clinical presentation

Pheochromocytoma is often referred as the great mimicker of other conditions. The average age of presentation of pheochromocytoma is approximately 40-50 years with equally distribution between men and women^[56]. Patients can present with different symptoms that can vary greatly between patients as well as within family members in familial syndromes associated with pheochromocytoma. The classic triad for pheochromocytoma: episodic headache, sweating and tachycardia are not always present in most patients^[57,58]. The most common sign, found in about 80%-90% of patients with pheochromocytoma, is hypertension^[59].

Types of hypertension in pheochromocytoma^[54,60]: (1) Sustained hypertension - found in about 50% of the patients with pheochromocytoma; (2) Paroxysmal hypertension - found in 45% of the patients; and (3) Normotension in 5%-15% of the patients.

The type of hypertension is often dependent on the pattern of catecholamine secretion from the tumor - which is either continuous, episodic or both. There is an inversion of the circadian BP rhythm and increased blood pressure variability due to high circulating levels of catecholamines^[61].

Paroxysm or “spell” can be triggered by physical activity (exercise or postural changes) as well as from tumor manipulation^[60]. In addition, the biochemical phenotype of the tumor, *i.e.*, type of catecholamine secreted influences the type of hypertension. Patient with high levels of norepinephrine and epinephrine more likely have sustained hypertension while patients with high levels of dopamine are often normotensive^[62,63]. Orthostatic hypotension may occur more commonly in patients with sustained hypertension than in those with paroxysmal and normotensive hypertension. The mechanism for orthostatic hypotension is thought to be due to decreased blood volume caused by persistent vasoconstriction and diminished sympathetic reflex^[64].

Characteristic symptoms include headache (90% of symptomatic patients), pallor and anxiety, feeling of doom, generalized sweating, fever, nausea or vomiting. Rarely secondary erythrocytosis, new onset diabetes mellitus and isolated dilated cardiomyopathy are associated with pheochromocytoma^[57,65-68].

Pheochromocytomas represent one of the main causes of hypertensive crisis in the hospital. These crises are precipitated by postural changes, physical stress, surgery and invasive procedures in undiagnosed patients. Further, it can be precipitated by the use of medications such as corticosteroids, histamine, metoclopramide, phenothiazines, tricyclic antidepressants or anesthetic agents^[69]. The clinical presentation during a crisis will depend on the effect of the catecholamine release on the target organs^[65].

Diagnosis

Clinicians should keep a high index of clinical suspicion in young adults (< 25 years) with new-onset hypertension, people with clinical features typical of pheochromocytoma, a history of resistant hypertension, an incidental adrenal adenoma, severe hypertension during general anesthesia or during sedation, idiopathic cardiomyopathy and in patients with a family history of pheochromocytoma.

The cornerstone for diagnosis of pheochromocytoma is the measurement of urine and plasma fractionated metanephrines. Most pheochromocytomas have fluctuating levels of catecholamines, but the metabolism of catecholamines into metanephrines is constant^[57,70,71].

There is no consensus regarding the “best test” for diagnosis. However, most endocrinologists favor choosing the best test based on the degree of clinical suspicion. If clinical suspicion is high (family history, genetic syndrome, past history of pheochromocytoma, positive adrenal gland imaging characteristics) then plasma fractionated metanephrines are measured (sensitivity is 96%-100% and specificity 85%-89%)^[71-73]. If clinical suspicion is low (resistant hypertension, hyperadrenergic spells, no classical imaging characteristics of adrenal gland), then 24-h urinary fractionated catecholamines and metanephrines (sensitivity 98% and specificity 98%) should be measured^[72,74,75]. Twenty-four hour

urinary creatinine should be measured simultaneously with urinary metanephrines to confirm that urine collection is completed^[76]. For plasma metanephrines measurement, blood sample collection in the supine position is recommended after 30 min in recumbent position before sampling^[76]. If the blood sample collection is obtained in a seated position, the clinician should be aware of the potential for false positive result from sympathoadrenal activation of the upright position^[77,78]. In patients with positive test results from seated sampling, repeat testing with samples obtained in supine position might be necessary^[76]. The reference interval of plasma metanephrines should be used as established in the same position of blood draw to avoid the inaccurate interpretation. Caffeine intake and medications that interfere with the catecholamine or metanephrine levels should be avoided at least 24 h before the diagnostic work up for pheochromocytoma^[79,80].

Imaging modalities

CT imaging: Adrenal pheochromocytomas with a size larger than 0.5 cm as well as metastatic pheochromocytomas can be detected by CT scan with high sensitivity of 85%-94% (Figure 1)^[81]. Ninety-five percent of tumors are within the abdomen and pelvis and 10% of tumors are extra-adrenal^[68]. Pheochromocytomas have a varied appearance on a non-contrast CT ranging from low density to soft-tissue attenuation. An attenuation threshold of 10 Hounsfield units (HU) on a non-contrast CT has a sensitivity of 71% and a specificity of 98% to differentiate a benign from malignant tumor^[82]. Approximately two thirds of pheochromocytomas are solid and the rest are complex or cystic^[83]. Hemorrhage and calcifications in a pheochromocytoma can be found in approximately 10% of all pheochromocytomas and it may increase the density of the pheochromocytoma^[83]. CT with low-osmolar contrast is safe in patients with pheochromocytoma not on alpha-or beta-blockers^[84]. Pheochromocytomas can show either homogenous or variable enhancement (depending on the solid and cystic components) on contrast enhanced CT scan. The characteristic appearance seen on contrast CT scan of a pheochromocytoma include increased contrast uptake (40-50 HU) with delayed washout with necrosis and calcifications^[81,85].

Magnetic resonance imaging: Magnetic resonance imaging (MRI) are more expensive and lacks the spatial resolution offered by CT scan. The classical imaging description for pheochromocytoma is a “light bulb” bright lesion on T2-weighted imaging comparable to signal intensity of CSF in 11%-65% of pheochromocytomas^[86,87]. This variability in the appearance on T2-weighted imaging is due to the water content present in cystic or necrotic components of the tumor. T1-weighted imaging of pheochromocytomas are typically isointense to muscle and hypointense to liver^[81]. MRI gadolinium enhancement on MRI is variable

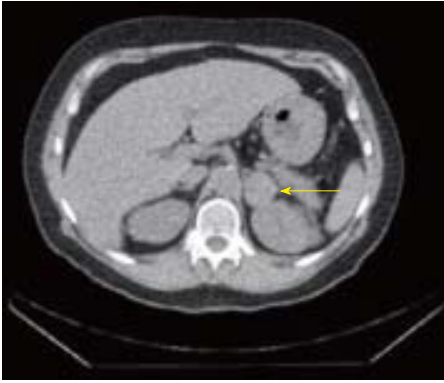


Figure 1 Computerized tomography scan of the abdomen demonstrating left adrenal nodule 3.5 cm.

depending on the presence of cystic-necrotic areas, which do not enhance^[88].

Functional imaging is indicated in-patient with large (> 10 cm) adrenal pheochromocytomas, extra-adrenal pheochromocytomas, metastatic disease and tumor recurrence assessment. Functional imaging examinations are performed using ¹³¹I- and ¹²³I-metaiodobenzylguanidine (MIBG) (Figure 2), ¹¹¹In-pentetreotide (Octreoscan, Covidien), and several PET ligands including ¹⁸F-fluorodopamine, ¹⁸F-dihydroxyphenylalanine (DO-PA), and ¹⁸F-FDG (FDG)^[81,89]. FDG-PET is more sensitive than ¹²³I-MIBG and CT/MRI for detection of metastatic disease^[90,91].

Management

Pre-operative management: A detailed history, physical examination and cardiac evaluation of patients is necessary as part of the preparation for surgery.

Medical management: Appropriate and optimal pharmacological therapy to block the effects of released catecholamines, is of critical importance in the pre-operative phase of the surgical management of pheochromocytoma^[92]. The main goals for therapy includes: normalization of blood pressure, heart rate, restores volume depletion and prevention of intraoperative hypertensive crisis.

Phenoxybenzamine (Dibenzylamine), a long lasting, non-selective, irreversible, and noncompetitive alpha-receptor blocker. This medication reduces blood pressure fluctuations, eases vasoconstriction and prevents intraoperative hypertensive crisis^[93]. Phenoxybenzamine is usually started at a dose of 10 mg twice a day with increments of 10-20 mg every 2-3 d until clinical symptoms from pheochromocytoma are controlled or side effects of the medication appears, which usually takes 7-14 d. Maximum dose is 1 mg/kg per day^[76]. The side effects of this medication are postural hypotension with reflex tachycardia, dizziness, syncope and nasal congestion. Selective, competitive, short-acting alpha-blockers like doxazosin (Cardura), prazosin (Minipress) and terazosin (Hytrin) are preferred in

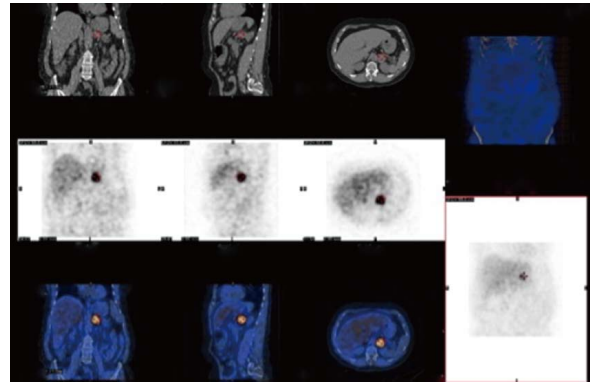


Figure 2 I-123-metaiodobenzylguanidine-SPECT images demonstrated focal increased tracer activity in the left adrenal nodule compatible with metaiodobenzylguanidine avid tumor.

some institutions as they are associated with less reflex tachycardia and a lower incidence of postoperative hypotension as compared to phenoxybenzamine. However, because of the short half life of these selective alpha-1 blockers, these medications should be given on the morning of the surgery. In a study, comparing the use of these different classes of alpha blockers in the preoperative management of laparoscopic resection of pheochromocytoma, phenoxybenzamine use was associated with better decrease in intra-operative hypertension at the expense of prolonged post-operative hypotension requiring the use of vasopressors. In contrast, patients treated with doxazosin had no clinically significant differences in post surgical outcomes^[94].

Once optimal α -blockade is achieved, β -blockers are used for the management of catecholamine-induced tachyarrhythmias. These medications should not be used in the absence of α -blockers as they will exacerbate epinephrine-induced vasoconstriction by blocking the vasodilator component (β_2). The most commonly used β -blockers are the non-selective β -receptor blocker propranolol (Inderal LA) (20-40 mg - 3 times a day) and the cardio selective β_1 blockers atenolol (Tenormin) (25-50 mg per a day)^[76].

Calcium channel blockers are the second line anti-hypertensive medications use to supplement α -blockers^[95]. They block norepinephrine mediated calcium influx into vascular smooth muscle and help in controlling hypertension and tachyarrhythmia. In addition, they might prevent catecholamine induced coronary vasospasm^[96,97]. The calcium channel blockers used are amlodipine (Norvasc) in a dose of 10-20 mg, nicardipine (Cardene) in a dose from 60-90 mg per day, nifedipine SR (Adalat) in a dose of 30-90 mg and verapamil ER (Isoptin SR, Calan SR) in a dose from 180-540 mg per day^[98].

Metyrosine (alpha-methyl-para-tyrosine, Demser) is an analog of tyrosine that is a competitive inhibitor of tyrosine hydroxylase, the rate limiting enzyme in catecholamine biosynthesis. Metyrosine is added to α - and β -blockers in patients with extensive metastatic

disease or large tumor burden^[99]. This medication incompletely depletes the catecholamine stores after 3 d of treatment. The recommended dose in all surgical candidates is 250 mg orally every 8-12 h with increments of dose by 250 to 500 mg every 2-3 d up to a total of 1.5 to 2 g per day. The medication is usually initiated 1-3 wk prior to surgery^[98]. Metyrosine helps to control blood pressure during induction of anesthesia and surgical manipulation of the tumor^[100,101]. The side effects of this medication include depression, anxiety, sedation, extra-pyramidal signs, crystalluria and galactorrhea^[102].

Optimizing cardiovascular function prior to surgery with normalization of blood pressure 10-14 d prior to surgery, initiating a normal or high-salt diet (usually 3 d after alpha-blockers are initiated) and expansion of blood volume by initiating pre-operative isotonic intravenous fluids minimizes protracted post-operative hypotension or shock from sudden diffuse vasodilatation at time of tumor removal^[98]. In patients with resistant hypertension or hypertensive crisis, sodium nitroprusside or phentolamine infusion, can be used preoperatively.

Intra-operative management: The intra-operative management of hypertension or hypertensive crisis along with prevention of postoperative hypotension is important for successful and safe surgical resection of pheochromocytoma. Nitroprusside (Nitropress), an intravenous vasodilator is the preferred medication for intraoperative control of hypertension due to its rapid onset and short duration of action. Nicardipine (Cardene) is a calcium channel blocker that may be used as an alternative. Intravenous magnesium sulfate is used in some centers, in a dose of 40-60 mg/kg before intubation followed by an infusion of 2 g/h. Magnesium sulfate inhibits catecholamine release, enhances vasodilatation, blocks catecholamine receptors and stabilizes the myocardium from arrhythmias^[103].

Surgery: Surgical resection is the only curative treatment of pheochromocytomas. Laparoscopic adrenalectomy is a well-established approach in intra-adrenal pheochromocytomas 6 cm or less in diameter, with no malignant features. This approach has been shown to improve surgical outcomes, reduced hospital stay and is better for patient comfort and recovery time compared to open adrenalectomy^[104,105]. Laparoscopic adrenalectomy is also often used in tumors above 6 cm in diameter but often these procedures are converted to open procedure intraoperative^[106,107]. More recently, experienced surgeons have preferred retroperitoneal endoscopic approach for adrenalectomy, as this provides direct access to the adrenal glands without requiring mobilization of adjacent organs (liver or pancreas), better in bilateral tumors and avoid repositioning as compared to the transabdominal approach^[108,109].

Postoperative management: Potential postoperative

complications after pheochromocytoma resection include tachyarrhythmias, splenic injury (left sided lesions), renal impairment, hypoglycemia and persistent hypotension. These complications have been shown to correlate with preoperative systolic blood pressure, urinary metanephrines and tumor size^[110,111]. Postoperative hypoglycemia is related to catecholamine-induced depletion of glycogen stores, overstimulation of insulin production by pre-operative α -blockade and hyperinsulinemia after loss of catecholamine inhibitory effect on the β 2-receptors of the pancreatic islet cell^[112,113].

Hemodynamic and blood glucose monitoring with optimal blood pressure, tachyarrhythmias and intravenous fluids (including glucose) are critical for a smooth postoperative course.

Surgical outcome and post-operative follow up:

Surgical removal of pheochromocytoma does not always lead to a long-term cure of hypertension. Some studies report 80% of patients may become normotensive. However, postoperative hypertension may persist due to residual tumor, metastatic disease or intra operative injury to the renal artery or most commonly due to acquired renovascular changes due to pre-operative hypertension.

Plasma fractionated catecholamines or urinary metanephrines should be measured two weeks after surgery, and thereafter every three months for the first year and then annually. Regular blood pressure monitoring and optimal management of hypertension should be done.

Pheochromocytoma and associated genetic disorders:

Most of the pheochromocytomas are sporadic although 15%-20% of patients with pheochromocytoma have an associated familial disease. These patients tend to have bilateral adrenal pheochromocytomas or have paragangliomas. The frequency of pheochromocytomas in some of the autosomal dominant familial disorders are 10% to 20% in Von Hippel-Lindau syndrome, 50% in Multiple endocrine neoplasia type 2, and 0.1% to 5.7% in neurofibromatosis type 1. Genetic testing should be considered if a patient has bilateral pheochromocytomas, onset less than 45 years, paragangliomas, family history of pheochromocytomas or clinical findings with strong evidence for hereditary syndrome^[114,115]. A sequential genetic testing algorithm, based on these findings, tailored for cost efficacy has been proposed^[116].

Pheochromocytoma and pregnancy:

Pheochromocytoma is a rare cause of hypertension in pregnancy with a frequency of 0.002% of all pregnancies and untreated it carries a high maternal and fetal mortality of around 50%^[117]. Early detection and proper treatment during pregnancy decrease the maternal and fetal mortality to < 5% and 15% respectively. The clinical features of pheochromocytoma in pregnancy are similar to non-pregnant patients. The characteristics of

Table 1 Key clinical features, screening and confirmatory tests, radiological and management modalities for primary aldosteronism and pheochromocytoma

	Primary aldosteronism	Pheochromocytoma
Clinical features	Difficult to control HTN	Episodes or paroxysmal hypertension
Common Symptoms	on 3 or more hypertensive agents	Headache
	Young age of onset of HTN	Sweating
		Palpitations
Signs	With or without hypokalemia	Hypertension
	Asymptomatic <i>vs</i> Symptomatic	Tachycardia
	Muscle weakness, cramping, headaches, palpitations, and polyuria	Orthostatic hypotension
		Heart failure
Screening tests	AM plasma aldosterone to renin ratio > 30 +/- Aldosterone > 20 ng/dL	24-h urine fractionated metanephrines
Confirmatory tests	Oral sodium loading test with 24 h aldosterone level > 12 µg/24 h Saline infusion test Fludrocortisone suppression test Captopril challenge test	Plasma fractionated metanephrines (high suspicion) Same as above
Radiology	Adrenal protocol CT +/- Scintigraphy Adrenal vein sampling	Adrenal protocol CT/MRI ¹²³ I-MIBG scan/ ¹¹¹ In-pentetreotide/FDG-PET
Treatment	For bilateral disease (or for those with unilateral disease who are unable to undergo surgery)	Pre-op preparation (10-14 d prior to surgery)
Medical	Spirinolactone (best choice)	Phenoxybenzamine
	Eplerenone	Alpha-blockers blockers-Doxazocin, Prazocin or Terazosin
	Amiloride	Calcium channel blockers
		Beta-blockers
		Metyrosine
Surgical	For unilateral source of aldosteronism: Laparoscopic adrenalectomy	Laparoscopic/retro-peritoneal adrenalectomy of adrenal pheochromocytoma

CT: Computed tomography; MRI: Magnetic resonance imaging; FDG-PET: Fluorodeoxyglucose-positron emission tomography.

hypertension that should lead to a clinical consideration of pheochromocytoma are severe hypertension diagnosed in the first and second trimesters, uncontrolled hypertension in the third trimester, unexplained postural hypotension or cardiogenic shock in the antepartum period. Plasma free metanephrines and urinary fractionated metanephrines assessment are the first recommended tests in the diagnostic workup. MRI without gadolinium as well as ultrasonography is imaging modalities of choice. Pre-operative management is similar to non-pregnant adults. Laparoscopic adrenalectomy is the surgery of choice in the first 24 wk of gestation. If the tumor is diagnosed in the third trimester, the patient should be managed until the fetus is viable with medication management and caesarean section with tumor removal in the same session or at a later stage is then preferred since vaginal delivery is possibly associated with higher mortality^[117].

Conclusion

In summary, both primary hyperaldosteronism and pheochromocytoma are important causes of endocrine hypertension that carry significant mortality and morbidity, if left untreated. A high index of clinical suspicion, a systematic approach to diagnosis, localization and management of both these conditions is important. Personalized approach with multidisciplinary team of internists, endocrinologists and surgeons

is recommended in optimal management of these conditions.

Key clinical features, investigations and management modalities of primary hyperaldosteronism and pheochromocytoma are summarized in Table 1.

REFERENCES

- Vega J, Bisognano JD. The prevalence, incidence, prognosis, and associated conditions of resistant hypertension. *Semin Nephrol* 2014; **34**: 247-256 [PMID: 25016397 DOI: 10.1016/j.semnephrol.2014.04.002]
- Velasco A, Vongpatanasin W. The evaluation and treatment of endocrine forms of hypertension. *Curr Cardiol Rep* 2014; **16**: 528 [PMID: 25119722 DOI: 10.1007/s11886-014-0528-x]
- Young WF. Primary aldosteronism: renaissance of a syndrome. *Clin Endocrinol (Oxf)* 2007; **66**: 607-618 [PMID: 17492946 DOI: 10.1111/j.1365-2265.2007.02775.x]
- Rossi GP, Bernini G, Caliumi C, Desideri G, Fabris B, Ferri C, Ganzaroli C, Giacchetti G, Letizia C, Maccario M, Mallamaci F, Mannelli M, Mattarello MJ, Moretti A, Palumbo G, Parenti G, Porteri E, Semplicini A, Rizzoni D, Rossi E, Boscaro M, Pessina AC, Mantero F. A prospective study of the prevalence of primary aldosteronism in 1,125 hypertensive patients. *J Am Coll Cardiol* 2006; **48**: 2293-2300 [PMID: 17161262 DOI: 10.1016/j.jacc.2006.07.059]
- Young WF, Stanson AW, Thompson GB, Grant CS, Farley DR, van Heerden JA. Role for adrenal venous sampling in primary aldosteronism. *Surgery* 2004; **136**: 1227-1235 [PMID: 15657580 DOI: 10.1016/j.surg.2004.06.051]

- 6 **So A**, Duffy DL, Gordon RD, Jeske YW, Lin-Su K, New MI, Stowasser M. Familial hyperaldosteronism type II is linked to the chromosome 7p22 region but also shows predicted heterogeneity. *J Hypertens* 2005; **23**: 1477-1484 [PMID: 16003173]
- 7 **Abdelhamid S**, Müller-Lobeck H, Pahl S, Remberger K, Bönhof JA, Walb D, Röckel A. Prevalence of adrenal and extra-adrenal Conn syndrome in hypertensive patients. *Arch Intern Med* 1996; **156**: 1190-1195 [PMID: 8639013]
- 8 **Funder JW**, Carey RM, Fardella C, Gomez-Sanchez CE, Mantero F, Stowasser M, Young WF, Montori VM. Case detection, diagnosis, and treatment of patients with primary aldosteronism: an endocrine society clinical practice guideline. *J Clin Endocrinol Metab* 2008; **93**: 3266-3281 [PMID: 18552288 DOI: 10.1210/jc.2008-0104]
- 9 **Phillips JL**, Walther MM, Pezzullo JC, Rayford W, Choyke PL, Berman AA, Linehan WM, Doppman JL, Gill Jr JR. Predictive value of preoperative tests in discriminating bilateral adrenal hyperplasia from an aldosterone-producing adrenal adenoma. *J Clin Endocrinol Metab* 2000; **85**: 4526-4533 [PMID: 11134103 DOI: 10.1210/jcem.85.12.7086]
- 10 **Espinier EA**, Ross DG, Yandle TG, Richards AM, Hunt PJ. Predicting surgically remedial primary aldosteronism: role of adrenal scanning, posture testing, and adrenal vein sampling. *J Clin Endocrinol Metab* 2003; **88**: 3637-3644 [PMID: 12915648 DOI: 10.1210/jc.2002-022051]
- 11 **Milliez P**, Girerd X, Plouin PF, Blacher J, Safar ME, Mourad JJ. Evidence for an increased rate of cardiovascular events in patients with primary aldosteronism. *J Am Coll Cardiol* 2005; **45**: 1243-1248 [PMID: 15837256 DOI: 10.1016/j.jacc.2005.01.015]
- 12 **Rossi GP**, Sacchetto A, Visentin P, Canali C, Graniero GR, Palatini P, Pessina AC. Changes in left ventricular anatomy and function in hypertension and primary aldosteronism. *Hypertension* 1996; **27**: 1039-1045 [PMID: 8621194]
- 13 **Rossi GP**, Bernini G, Desideri G, Fabris B, Ferri C, Giacchetti G, Letizia C, Maccario M, Mannelli M, Matterello MJ, Montemurro D, Palumbo G, Rizzoni D, Rossi E, Pessina AC, Mantero F. Renal damage in primary aldosteronism: results of the PAPY Study. *Hypertension* 2006; **48**: 232-238 [PMID: 16801482 DOI: 10.1161/01.HYP.0000230444.01215.6a]
- 14 **Mulatero P**, Stowasser M, Loh KC, Fardella CE, Gordon RD, Mosso L, Gomez-Sanchez CE, Veglio F, Young WF. Increased diagnosis of primary aldosteronism, including surgically correctable forms, in centers from five continents. *J Clin Endocrinol Metab* 2004; **89**: 1045-1050 [PMID: 15001583 DOI: 10.1210/jc.2003-031337]
- 15 **Hiramatsu K**, Yamada T, Yukimura Y, Komiya I, Ichikawa K, Ishihara M, Nagata H, Izumiyama T. A screening test to identify aldosterone-producing adenoma by measuring plasma renin activity. Results in hypertensive patients. *Arch Intern Med* 1981; **141**: 1589-1593 [PMID: 7030245]
- 16 **Weinberger MH**, Fineberg NS. The diagnosis of primary aldosteronism and separation of two major subtypes. *Arch Intern Med* 1993; **153**: 2125-2129 [PMID: 8379804]
- 17 **Aronova A**, Iii TJ, Zarnegar R. Management of hypertension in primary aldosteronism. *World J Cardiol* 2014; **6**: 227-233 [PMID: 24944753 DOI: 10.4330/wjcv.6.i5.227]
- 18 **Ducher M**, Mounier-Véhier C, Baguet JP, Tartière JM, Sosner P, Régnier-Le Coz S, Perez L, Fourcade J, Jabourek O, Lejeune S, Stolz A, Fauvel JP. Aldosterone-to-renin ratio for diagnosing aldosterone-producing adenoma: a multicentre study. *Arch Cardiovasc Dis* 2012; **105**: 623-630 [PMID: 23199617 DOI: 10.1016/j.acvd.2012.07.006]
- 19 **Stowasser M**, Ahmed AH, Pimenta E, Taylor PJ, Gordon RD. Factors affecting the aldosterone/renin ratio. *Horm Metab Res* 2012; **44**: 170-176 [PMID: 22147655 DOI: 10.1055/s-0031-1295460]
- 20 **Tomaschitz A**, Pilz S. Aldosterone to renin ratio--a reliable screening tool for primary aldosteronism? *Horm Metab Res* 2010; **42**: 382-391 [PMID: 20225167 DOI: 10.1055/s-0030-1248326]
- 21 **Gallay BJ**, Ahmad S, Xu L, Toivola B, Davidson RC. Screening for primary aldosteronism without discontinuing hypertensive medications: plasma aldosterone-renin ratio. *Am J Kidney Dis* 2001; **37**: 699-705 [PMID: 11273868]
- 22 **Nanba K**, Tamanaha T, Nakao K, Kawashima ST, Usui T, Tagami T, Okuno H, Shimatsu A, Suzuki T, Naruse M. Confirmatory testing in primary aldosteronism. *J Clin Endocrinol Metab* 2012; **97**: 1688-1694 [PMID: 22419718 DOI: 10.1210/jc.2011-2504]
- 23 **Bravo EL**, Tarazi RC, Dustan HP, Fouad FM, Textor SC, Gifford RW, Vidt DG. The changing clinical spectrum of primary aldosteronism. *Am J Med* 1983; **74**: 641-651 [PMID: 6340491]
- 24 **Mulatero P**, Milan A, Fallo F, Regolisti G, Pizzolo F, Fardella C, Mosso L, Marafetti L, Veglio F, Maccario M. Comparison of confirmatory tests for the diagnosis of primary aldosteronism. *J Clin Endocrinol Metab* 2006; **91**: 2618-2623 [PMID: 16670162 DOI: 10.1210/jc.2006-0078]
- 25 **Lim PO**, Farquharson CA, Shiels P, Jung RT, Struthers AD, MacDonald TM. Adverse cardiac effects of salt with fludrocortisone in hypertension. *Hypertension* 2001; **37**: 856-861 [PMID: 11244008]
- 26 **Young WF**, Stanson AW, Grant CS, Thompson GB, van Heerden JA. Primary aldosteronism: adrenal venous sampling. *Surgery* 1996; **120**: 913-919; discussion 913-919 [PMID: 8957473]
- 27 **Zarnegar R**, Bloom AI, Lee J, Kerlan RK, Wilson MW, Laberge JM, Gordon RL, Kebebew E, Clark OH, Duh QY. Is adrenal venous sampling necessary in all patients with hyperaldosteronism before adrenalectomy? *J Vasc Interv Radiol* 2008; **19**: 66-71 [PMID: 18192469 DOI: 10.1016/j.jvir.2007.08.022]
- 28 **Nomura K**, Kusakabe K, Maki M, Ito Y, Aiba M, Demura H. Iodomethylnorcholesterol uptake in an aldosteronoma shown by dexamethasone-suppression scintigraphy: relationship to adenoma size and functional activity. *J Clin Endocrinol Metab* 1990; **71**: 825-830 [PMID: 2401712 DOI: 10.1210/jcem-71-4-825]
- 29 **Stowasser M**, Gordon RD. Primary aldosteronism--careful investigation is essential and rewarding. *Mol Cell Endocrinol* 2004; **217**: 33-39 [PMID: 15134798 DOI: 10.1016/j.mce.2003.10.006]
- 30 **Rossi GP**, Auchus RJ, Brown M, Lenders JW, Naruse M, Plouin PF, Satoh F, Young WF. An expert consensus statement on use of adrenal vein sampling for the subtyping of primary aldosteronism. *Hypertension* 2014; **63**: 151-160 [PMID: 24218436 DOI: 10.1161/hypertensionaha.113.02097]
- 31 **Doppman JL**, Gill JR, Miller DL, Chang R, Gupta R, Friedman TC, Choyke PL, Feuerstein IM, Dwyer AJ, Jicha DL. Distinction between hyperaldosteronism due to bilateral hyperplasia and unilateral aldosteronoma: reliability of CT. *Radiology* 1992; **184**: 677-682 [PMID: 1509049 DOI: 10.1148/radiology.184.3.1509049]
- 32 **Rossi GP**, Barisa M, Allolio B, Auchus RJ, Amar L, Cohen D, Degenhart C, Deinum J, Fischer E, Gordon R, Kickuth R, Kline G, Lacroix A, Magill S, Miotto D, Naruse M, Nishikawa T, Omura M, Pimenta E, Plouin PF, Quinkler M, Reincke M, Rossi E, Rump LC, Satoh F, Schultze Kool L, Seccia TM, Stowasser M, Tanabe A, Trerotola S, Vonend O, Widimsky J, Wu KD, Wu VC, Pessina AC. The Adrenal Vein Sampling International Study (AVIS) for identifying the major subtypes of primary aldosteronism. *J Clin Endocrinol Metab* 2012; **97**: 1606-1614 [PMID: 22399502 DOI: 10.1210/jc.2011-2830]
- 33 **Young WF**, Klee GG. Primary aldosteronism. Diagnostic evaluation. *Endocrinol Metab Clin North Am* 1988; **17**: 367-395 [PMID: 3042391]
- 34 **Karagiannis A**, Tziomalos K, Kakafika AI, Athyros VG, Harsoulis F, Mikhailidis DP. Medical treatment as an alternative to adrenalectomy in patients with aldosterone-producing adenomas. *Endocr Relat Cancer* 2008; **15**: 693-700 [PMID: 18586836 DOI: 10.1677/erc-08-0094]
- 35 **Ghose RP**, Hall PM, Bravo EL. Medical management of aldosterone-producing adenomas. *Ann Intern Med* 1999; **131**: 105-108 [PMID: 10419425]
- 36 **Fourkoti V**, Vonend O, Diederich S, Fischer E, Lang K, Endres S, Beuschlein F, Willenberg HS, Rump LC, Allolio B, Reincke M, Quinkler M. Effectiveness of eplerenone or spironolactone treatment in preserving renal function in primary aldosteronism. *Eur J Endocrinol* 2013; **168**: 75-81 [PMID: 23033260 DOI: 10.1530/eje-12-0631]
- 37 **Stokes GS**, Monaghan JC, Ryan M, Woodward M. Efficacy of an angiotensin II receptor antagonist in managing hyperaldosteronism.

- J Hypertens* 2001; **19**: 1161-1165 [PMID: 11403366]
- 38 **Assalia A**, Gagner M. Laparoscopic adrenalectomy. *Br J Surg* 2004; **91**: 1259-1274 [PMID: 15376201 DOI: 10.1002/bjs.4738]
 - 39 **Sywak M**, Pasiaka JL. Long-term follow-up and cost benefit of adrenalectomy in patients with primary hyperaldosteronism. *Br J Surg* 2002; **89**: 1587-1593 [PMID: 12445071 DOI: 10.1046/j.1365-2168.2002.02261.x]
 - 40 **Sawka AM**, Young WF, Thompson GB, Grant CS, Farley DR, Leibson C, van Heerden JA. Primary aldosteronism: factors associated with normalization of blood pressure after surgery. *Ann Intern Med* 2001; **135**: 258-261 [PMID: 11511140]
 - 41 **Blumenfeld JD**, Sealey JE, Schluskel Y, Vaughan ED, Sos TA, Atlas SA, Müller FB, Acevedo R, Ulick S, Laragh JH. Diagnosis and treatment of primary hyperaldosteronism. *Ann Intern Med* 1994; **121**: 877-885 [PMID: 7978702]
 - 42 **Carey RM**. Primary aldosteronism. *J Surg Oncol* 2012; **106**: 575-579 [PMID: 22806599 DOI: 10.1002/jso.23206]
 - 43 **Lumachi F**, Ermani M, Basso SM, Armanini D, Iacobone M, Favia G. Long-term results of adrenalectomy in patients with aldosterone-producing adenomas: multivariate analysis of factors affecting unresolved hypertension and review of the literature. *Am Surg* 2005; **71**: 864-869 [PMID: 16468537]
 - 44 **Meyer A**, Brabant G, Behrend M. Long-term follow-up after adrenalectomy for primary aldosteronism. *World J Surg* 2005; **29**: 155-159 [PMID: 15650803 DOI: 10.1007/s00268-004-7496-z]
 - 45 **Harris DA**, Au-Yong I, Basnyat PS, Sadler GP, Wheeler MH. Review of surgical management of aldosterone secreting tumours of the adrenal cortex. *Eur J Surg Oncol* 2003; **29**: 467-474 [PMID: 12798753]
 - 46 **Pang TC**, Bambach C, Monaghan JC, Sidhu SB, Bune A, Delbridge LW, Sywak MS. Outcomes of laparoscopic adrenalectomy for hyperaldosteronism. *ANZ J Surg* 2007; **77**: 768-773 [PMID: 17685956 DOI: 10.1111/j.1445-2197.2007.04225.x]
 - 47 **Gockel I**, Heintz A, Polta M, Junginger T. Long-term results of endoscopic adrenalectomy for Conn's syndrome. *Am Surg* 2007; **73**: 174-180 [PMID: 17305298]
 - 48 **Fukudome Y**, Fujii K, Arima H, Ohya Y, Tsuchihashi T, Abe I, Fujishima M. Discriminating factors for recurrent hypertension in patients with primary aldosteronism after adrenalectomy. *Hypertens Res* 2002; **25**: 11-18 [PMID: 11924716]
 - 49 **Zarnegar R**, Young WF, Lee J, Sweet MP, Kebebew E, Farley DR, Thompson GB, Grant CS, Clark OH, Duh QY. The aldosteronoma resolution score: predicting complete resolution of hypertension after adrenalectomy for aldosteronoma. *Ann Surg* 2008; **247**: 511-518 [PMID: 18376197 DOI: 10.1097/SLA.0b013e318165c075]
 - 50 **Utsumi T**, Kawamura K, Imamoto T, Kamiya N, Komiya A, Suzuki S, Nagano H, Tanaka T, Nihei N, Naya Y, Suzuki H, Tatsuno I, Ichikawa T. High predictive accuracy of Aldosteronoma Resolution Score in Japanese patients with aldosterone-producing adenoma. *Surgery* 2012; **151**: 437-443 [PMID: 22000827 DOI: 10.1016/j.surg.2011.08.001]
 - 51 **Zennaro MC**, Boulkroun S, Fernandes-Rosa FL. An update on novel mechanisms of primary aldosteronism. *J Endocrinol* 2015; **224**: R63-R77 [PMID: 25424518 DOI: 10.1530/joe-14-0597]
 - 52 **Gates LJ**, Benjamin N, Haites NE, MacConnachie AA, McLay JS. Is random screening of value in detecting glucocorticoid-remediable aldosteronism within a hypertensive population? *J Hum Hypertens* 2001; **15**: 173-176 [PMID: 11317201 DOI: 10.1038/sj.jhh.1001152]
 - 53 **Ariton M**, Juan CS, Avruskin TW. Pheochromocytoma: clinical observations from a Brooklyn tertiary hospital. *Endocr Pract* 2000; **6**: 249-252 [PMID: 11421540 DOI: 10.4158/EP.6.3.249]
 - 54 **Manger WM**. The protean manifestations of pheochromocytoma. *Horm Metab Res* 2009; **41**: 658-663 [PMID: 19242899 DOI: 10.1055/s-0028-1128139]
 - 55 **Omura M**, Saito J, Yamaguchi K, Kakuta Y, Nishikawa T. Prospective study on the prevalence of secondary hypertension among hypertensive patients visiting a general outpatient clinic in Japan. *Hypertens Res* 2004; **27**: 193-202 [PMID: 15080378]
 - 56 **Guerrero MA**, Schreinemakers JM, Vriens MR, Suh I, Hwang J, Shen WT, Gosnell J, Clark OH, Duh QY. Clinical spectrum of pheochromocytoma. *J Am Coll Surg* 2009; **209**: 727-732 [PMID: 19959041 DOI: 10.1016/j.jamcollsurg.2009.09.022]
 - 57 **Lenders JW**, Eisenhofer G, Mannelli M, Pacak K. Pheochromocytoma. *Lancet* 2005; **366**: 665-675 [PMID: 16112304 DOI: 10.1016/s0140-6736(05)67139-5]
 - 58 **Baguet JP**, Hammer L, Mazzucco TL, Chabre O, Mallion JM, Sturm N, Chaffanjon P. Circumstances of discovery of pheochromocytoma: a retrospective study of 41 consecutive patients. *Eur J Endocrinol* 2004; **150**: 681-686 [PMID: 15132724]
 - 59 **Calhoun DA**, Jones D, Textor S, Goff DC, Murphy TP, Toto RD, White A, Cushman WC, White W, Sica D, Ferdinand K, Giles TD, Falkner B, Carey RM. Resistant hypertension: diagnosis, evaluation, and treatment. A scientific statement from the American Heart Association Professional Education Committee of the Council for High Blood Pressure Research. *Hypertension* 2008; **51**: 1403-1419 [PMID: 18391085 DOI: 10.1161/hypertensionaha.108.189141]
 - 60 **Zelinka T**, Eisenhofer G, Pacak K. Pheochromocytoma as a catecholamine producing tumor: implications for clinical practice. *Stress* 2007; **10**: 195-203 [PMID: 17514588 DOI: 10.1080/10253890701395896]
 - 61 **Zelinka T**, Strauch B, Petrák O, Holaj R, Vranková A, Weissarová H, Pacák K, Widimský J. Increased blood pressure variability in pheochromocytoma compared to essential hypertension patients. *J Hypertens* 2005; **23**: 2033-2039 [PMID: 16208146]
 - 62 **Ito Y**, Fujimoto Y, Obara T. The role of epinephrine, norepinephrine, and dopamine in blood pressure disturbances in patients with pheochromocytoma. *World J Surg* 1992; **16**: 759-763; discussion 763-764 [PMID: 1413846]
 - 63 **Proye C**, Fossati P, Fontaine P, Lefebvre J, Decoux M, Wemeau JL, Dewailly D, Rwamasirabo E, Cecat P. Dopamine-secreting pheochromocytoma: an unrecognized entity? Classification of pheochromocytomas according to their type of secretion. *Surgery* 1986; **100**: 1154-1162 [PMID: 3787474]
 - 64 **Streeten DH**, Anderson GH. Mechanisms of orthostatic hypotension and tachycardia in patients with pheochromocytoma. *Am J Hypertens* 1996; **9**: 760-769 [PMID: 8862222]
 - 65 **Mazza A**, Armigliato M, Marzola MC, Schiavon L, Montemurro D, Vescovo G, Zuin M, Chondrogiannis S, Ravenni R, Opocher G, Colletti PM, Rubello D. Anti-hypertensive treatment in pheochromocytoma and paraganglioma: current management and therapeutic features. *Endocrine* 2014; **45**: 469-478 [PMID: 23817839 DOI: 10.1007/s12020-013-0007-y]
 - 66 **Drénou B**, Le Tulzo Y, Cautlet-Maugendre S, Le Guerrier A, Leclercq C, Guilhem I, Lecoq N, Faucher R, Thomas R. Pheochromocytoma and secondary erythrocytosis: role of tumour erythropoietin secretion. *Nouv Rev Fr Hematol* 1995; **37**: 197-199 [PMID: 7567437]
 - 67 **La Batide-Alanore A**, Chatellier G, Plouin PF. Diabetes as a marker of pheochromocytoma in hypertensive patients. *J Hypertens* 2003; **21**: 1703-1707 [PMID: 12923403 DOI: 10.1097/01.hjh.0000084729.53355.ce]
 - 68 **Bravo EL**. Pheochromocytoma: new concepts and future trends. *Kidney Int* 1991; **40**: 544-556 [PMID: 1787652]
 - 69 **Yu R**, Nissen NN, Chopra P, Dhall D, Phillips E, Wei M. Diagnosis and treatment of pheochromocytoma in an academic hospital from 1997 to 2007. *Am J Med* 2009; **122**: 85-95 [PMID: 19114176 DOI: 10.1016/j.amjmed.2008.08.021]
 - 70 **Chen H**, Sippel RS, O'Dorisio MS, Vinik AI, Lloyd RV, Pacak K. The North American Neuroendocrine Tumor Society consensus guideline for the diagnosis and management of neuroendocrine tumors: pheochromocytoma, paraganglioma, and medullary thyroid cancer. *Pancreas* 2010; **39**: 775-783 [PMID: 20664475 DOI: 10.1097/MPA.0b013e3181ebb4f0]
 - 71 **Lenders JW**, Pacak K, Walther MM, Linehan WM, Mannelli M, Friberg P, Keiser HR, Goldstein DS, Eisenhofer G. Biochemical diagnosis of pheochromocytoma: which test is best? *JAMA* 2002; **287**: 1427-1434 [PMID: 11903030]
 - 72 **Sawka AM**, Jaeschke R, Singh RJ, Young WF. A comparison of biochemical tests for pheochromocytoma: measurement of fractionated plasma metanephrines compared with the combination of 24-hour urinary metanephrines and catecholamines. *J Clin*

- Endocrinol Metab* 2003; **88**: 553-558 [PMID: 12574179 DOI: 10.1210/jc.2002-021251]
- 73 **Sawka AM**, Prebtani AP, Thabane L, Gafni A, Levine M, Young WF. A systematic review of the literature examining the diagnostic efficacy of measurement of fractionated plasma free metanephrines in the biochemical diagnosis of pheochromocytoma. *BMC Endocr Disord* 2004; **4**: 2 [PMID: 15225350 DOI: 10.1186/1472-6823-4-2]
- 74 **Kudva YC**, Sawka AM, Young WF. Clinical review 164: The laboratory diagnosis of adrenal pheochromocytoma: the Mayo Clinic experience. *J Clin Endocrinol Metab* 2003; **88**: 4533-4539 [PMID: 14557417 DOI: 10.1210/jc.2003-030720]
- 75 **Perry CG**, Sawka AM, Singh R, Thabane L, Bajnarek J, Young WF. The diagnostic efficacy of urinary fractionated metanephrines measured by tandem mass spectrometry in detection of pheochromocytoma. *Clin Endocrinol (Oxf)* 2007; **66**: 703-708 [PMID: 17388796 DOI: 10.1111/j.1365-2265.2007.02805.x]
- 76 **Lenders JW**, Duh QY, Eisenhofer G, Gimenez-Roqueplo AP, Grebe SK, Murad MH, Naruse M, Pacak K, Young WF Jr; Endocrine Society.. Pheochromocytoma and paraganglioma: an endocrine society clinical practice guideline. *J Clin Endocrinol Metab* 2014; **99**: 1915-1942 [PMID: 24893135 DOI: 10.1210/jc.2014-1498]
- 77 **Lenders JW**, Willemssen JJ, Eisenhofer G, Ross HA, Pacak K, Timmers HJ, Sweep CG. Is supine rest necessary before blood sampling for plasma metanephrines? *Clin Chem* 2007; **53**: 352-354 [PMID: 17200132 DOI: 10.1373/clinchem.2006.076489]
- 78 **Deutschbein T**, Unger N, Jaeger A, Broecker-Preuss M, Mann K, Petersenn S. Influence of various confounding variables and storage conditions on metanephrine and normetanephrine levels in plasma. *Clin Endocrinol (Oxf)* 2010; **73**: 153-160 [PMID: 20039892 DOI: 10.1111/j.1365-2265.2009.03761.x]
- 79 **Eisenhofer G**, Goldstein DS, Walther MM, Friberg P, Lenders JW, Keiser HR, Pacak K. Biochemical diagnosis of pheochromocytoma: how to distinguish true- from false-positive test results. *J Clin Endocrinol Metab* 2003; **88**: 2656-2666 [PMID: 12788870 DOI: 10.1210/jc.2002-030005]
- 80 **Grassi G**, Seravalle G, Calhoun DA, Bolla G, Mancia G. Cigarette smoking and the adrenergic nervous system. *Clin Exp Hypertens A* 1992; **14**: 251-260 [PMID: 1541039]
- 81 **Ilias I**, Pacak K. Current approaches and recommended algorithm for the diagnostic localization of pheochromocytoma. *J Clin Endocrinol Metab* 2004; **89**: 479-491 [PMID: 14764749 DOI: 10.1210/jc.2003-031091]
- 82 **Boland GW**, Lee MJ, Gazelle GS, Halpern EF, McNicholas MM, Mueller PR. Characterization of adrenal masses using unenhanced CT: an analysis of the CT literature. *AJR Am J Roentgenol* 1998; **171**: 201-204 [PMID: 9648789 DOI: 10.2214/ajr.171.1.9648789]
- 83 **Park BK**, Kim CK, Kwon GY, Kim JH. Re-evaluation of pheochromocytomas on delayed contrast-enhanced CT: washout enhancement and other imaging features. *Eur Radiol* 2007; **17**: 2804-2809 [PMID: 17549484 DOI: 10.1007/s00330-007-0695-x]
- 84 **Baid SK**, Lai EW, Wesley RA, Ling A, Timmers HJ, Adams KT, Kozupa A, Pacak K. Brief communication: radiographic contrast infusion and catecholamine release in patients with pheochromocytoma. *Ann Intern Med* 2009; **150**: 27-32 [PMID: 19124817]
- 85 **Leung K**, Stamm M, Raja A, Low G. Pheochromocytoma: the range of appearances on ultrasound, CT, MRI, and functional imaging. *AJR Am J Roentgenol* 2013; **200**: 370-378 [PMID: 23345359 DOI: 10.2214/ajr.12.9126]
- 86 **Jacques AE**, Sahdev A, Sandrasagara M, Goldstein R, Berney D, Rockall AG, Chew S, Reznick RH. Adrenal phaeochromocytoma: correlation of MRI appearances with histology and function. *Eur Radiol* 2008; **18**: 2885-2892 [PMID: 18641999 DOI: 10.1007/s00330-008-1073-z]
- 87 **Varghese JC**, Hahn PF, Papanicolaou N, Mayo-Smith WW, Gaa JA, Lee MJ. MR differentiation of phaeochromocytoma from other adrenal lesions based on qualitative analysis of T2 relaxation times. *Clin Radiol* 1997; **52**: 603-606 [PMID: 9285420]
- 88 **Krestin GP**, Steinbrich W, Friedmann G. Adrenal masses: evaluation with fast gradient-echo MR imaging and Gd-DTPA-enhanced dynamic studies. *Radiology* 1989; **171**: 675-680 [PMID: 2717737 DOI: 10.1148/radiology.171.3.2717737]
- 89 **Havekes B**, Lai EW, Corssmit EP, Romijn JA, Timmers HJ, Pacak K. Detection and treatment of pheochromocytomas and paragangliomas: current standing of MIBG scintigraphy and future role of PET imaging. *Q J Nucl Med Mol Imaging* 2008; **52**: 419-429 [PMID: 19088695]
- 90 **Timmers HJ**, Kozupa A, Chen CC, Carrasquillo JA, Ling A, Eisenhofer G, Adams KT, Solis D, Lenders JW, Pacak K. Superiority of fluorodeoxyglucose positron emission tomography to other functional imaging techniques in the evaluation of metastatic SDHB-associated pheochromocytoma and paraganglioma. *J Clin Oncol* 2007; **25**: 2262-2269 [PMID: 17538171 DOI: 10.1200/jco.2006.09.6297]
- 91 **Timmers HJ**, Chen CC, Carrasquillo JA, Whatley M, Ling A, Eisenhofer G, King KS, Rao JU, Wesley RA, Adams KT, Pacak K. Staging and functional characterization of pheochromocytoma and paraganglioma by 18F-fluorodeoxyglucose (18F-FDG) positron emission tomography. *J Natl Cancer Inst* 2012; **104**: 700-708 [PMID: 22517990 DOI: 10.1093/jnci/djs188]
- 92 **Pacak K**, Eisenhofer G, Ahlman H, Bornstein SR, Gimenez-Roqueplo AP, Grossman AB, Kimura N, Mannelli M, McNicol AM, Tischler AS. Pheochromocytoma: recommendations for clinical practice from the First International Symposium. October 2005. *Nat Clin Pract Endocrinol Metab* 2007; **3**: 92-102 [PMID: 17237836 DOI: 10.1038/ncpendmet0396]
- 93 **Bravo EL**, Tagle R. Pheochromocytoma: state-of-the-art and future prospects. *Endocr Rev* 2003; **24**: 539-553 [PMID: 12920154 DOI: 10.1210/er.2002-0013]
- 94 **Weingarten TN**, Cata JP, O'Hara JF, Prybilla DJ, Pike TL, Thompson GB, Grant CS, Warner DO, Bravo E, Sprung J. Comparison of two preoperative medical management strategies for laparoscopic resection of pheochromocytoma. *Urology* 2010; **76**: 508.e6-508.11 [PMID: 20546874 DOI: 10.1016/j.urology.2010.03.032]
- 95 **Lebuffe G**, Dosseh ED, Tek G, Tytgat H, Moreno S, Tavernier B, Vallet B, Proye CA. The effect of calcium channel blockers on outcome following the surgical treatment of phaeochromocytomas and paragangliomas. *Anaesthesia* 2005; **60**: 439-444 [PMID: 15819762 DOI: 10.1111/j.1365-2044.2005.04156.x]
- 96 **Proye C**, Thevenin D, Cecat P, Petillot P, Carnaille B, Verin P, Sautier M, Racadot N. Exclusive use of calcium channel blockers in preoperative and intraoperative control of pheochromocytomas: hemodynamics and free catecholamine assays in ten consecutive patients. *Surgery* 1989; **106**: 1149-1154 [PMID: 2588118]
- 97 **Takahashi S**, Nakai T, Fujiwara R, Kutsumi Y, Tamai T, Miyabo S. Effectiveness of long-acting nifedipine in pheochromocytoma. *Jpn Heart J* 1989; **30**: 751-757 [PMID: 2614935]
- 98 **Pacak K**. Preoperative management of the pheochromocytoma patient. *J Clin Endocrinol Metab* 2007; **92**: 4069-4079 [PMID: 17989126 DOI: 10.1210/jc.2007-1720]
- 99 **Sjoerdsma A**, Engelman K, Spector S, Udenfriend S. Inhibition of catecholamine synthesis in man with alpha-methyl-tyrosine, an inhibitor of tyrosine hydroxylase. *Lancet* 1965; **2**: 1092-1094 [PMID: 4158803]
- 100 **Steinsapir J**, Carr AA, Prisant LM, Bransome ED. Metyrosine and pheochromocytoma. *Arch Intern Med* 1997; **157**: 901-906 [PMID: 9129550]
- 101 **Perry RR**, Keiser HR, Norton JA, Wall RT, Robertson CN, Travis W, Pass HI, Walther MM, Linehan WM. Surgical management of pheochromocytoma with the use of metyrosine. *Ann Surg* 1990; **212**: 621-628 [PMID: 1978640]
- 102 **Young WF**. Pheochromocytoma: issues in diagnosis & amp; treatment. *Compr Ther* 1997; **23**: 319-326 [PMID: 9195121]
- 103 **James MF**. The use of magnesium sulfate in the anesthetic management of pheochromocytoma. *Anesthesiology* 1985; **62**: 188-190 [PMID: 3970373]
- 104 **Hansen P**, Bax T, Swannstrom L. Laparoscopic adrenalectomy: history, indications, and current techniques for a minimally invasive approach to adrenal pathology. *Endoscopy* 1997; **29**: 309-314 [PMID: 9255537 DOI: 10.1055/s-2007-1004195]

- 105 **Bulus H**, Uslu HY, Karakoyun R, Koçak S. Comparison of laparoscopic and open adrenalectomy. *Acta Chir Belg* 2013; **113**: 203-207 [PMID: 24941717]
- 106 **Conzo G**, Musella M, Corcione F, De Palma M, Ferraro F, Palazzo A, Napolitano S, Milone M, Pasquali D, Sinisi AA, Colantuoni V, Santini L. Laparoscopic adrenalectomy, a safe procedure for pheochromocytoma. A retrospective review of clinical series. *Int J Surg* 2013; **11**: 152-156 [PMID: 23267853 DOI: 10.1016/j.ijssu.2012.12.007]
- 107 **Cheah WK**, Clark OH, Horn JK, Siperstein AE, Duh QY. Laparoscopic adrenalectomy for pheochromocytoma. *World J Surg* 2002; **26**: 1048-1051 [PMID: 12045856 DOI: 10.1007/s00268-002-6669-x]
- 108 **Huyghe E**, Crenn G, Duly-Bouhanick B, Vezzosi D, Bennet A, Atallah F, Mazerolles M, Salloum A, Thoulouzan M, Delaunay B, Grunenwald S, Amar J, Plante P, Chamontin B, Caron P, Soulié M. Retroperitoneoscopic adrenalectomy: comparison of retrograde and antegrade approach among a series of 279 cases. *Urology* 2013; **81**: 85-91 [PMID: 23273074 DOI: 10.1016/j.urolgy.2012.08.059]
- 109 **Dickson PV**, Alex GC, Grubbs EG, Ayala-Ramirez M, Jimenez C, Evans DB, Lee JE, Perrier ND. Posterior retroperitoneoscopic adrenalectomy is a safe and effective alternative to transabdominal laparoscopic adrenalectomy for pheochromocytoma. *Surgery* 2011; **150**: 452-458 [PMID: 21878230 DOI: 10.1016/j.surg.2011.07.004]
- 110 **Plouin PF**, Duclos JM, Soppelsa F, Boubilil G, Chatellier G. Factors associated with perioperative morbidity and mortality in patients with pheochromocytoma: analysis of 165 operations at a single center. *J Clin Endocrinol Metab* 2001; **86**: 1480-1486 [PMID: 11297571 DOI: 10.1210/jcem.86.4.7392]
- 111 **Kinney MA**, Narr BJ, Warner MA. Perioperative management of pheochromocytoma. *J Cardiothorac Vasc Anesth* 2002; **16**: 359-369 [PMID: 12073213 DOI: 10.1053/jcan.2002.124150]
- 112 **Reynolds C**, Wilkins GE, Schmidt N, Doll WA, Blix PM. Hyperinsulinism after removal of a pheochromocytoma. *Can Med Assoc J* 1983; **129**: 349-353 [PMID: 6871802]
- 113 **Meeke RI**, O'Keeffe JD, Gaffney JD. Pheochromocytoma removal and postoperative hypoglycaemia. *Anaesthesia* 1985; **40**: 1093-1096 [PMID: 4073425]
- 114 **Neumann HP**, Bausch B, McWhinney SR, Bender BU, Gimm O, Franke G, Schipper J, Klisch J, Althoefer C, Zerres K, Januszewicz A, Eng C, Smith WM, Munk R, Manz T, Glaesker S, Apel TW, Treier M, Reineke M, Walz MK, Hoang-Vu C, Brauckhoff M, Klein-Franke A, Klose P, Schmidt H, Maier-Woelfle M, Peczkowska M, Szmigielski C, Eng C. Germ-line mutations in nonsyndromic pheochromocytoma. *N Engl J Med* 2002; **346**: 1459-1466 [PMID: 12000816 DOI: 10.1056/NEJMoa020152]
- 115 **Erlic Z**, Rybicki L, Peczkowska M, Golcher H, Kann PH, Brauckhoff M, Müssig K, Muresan M, Schäffler A, Reisch N, Schott M, Fassnacht M, Opocher G, Klose S, Fottner C, Forrer F, Plöckinger U, Petersenn S, Zabolotny D, Kollukch O, Yaremchuk S, Januszewicz A, Walz MK, Eng C, Neumann HP. Clinical predictors and algorithm for the genetic diagnosis of pheochromocytoma patients. *Clin Cancer Res* 2009; **15**: 6378-6385 [PMID: 19825962 DOI: 10.1158/1078-0432.CCR-09-1237]
- 116 **Welander J**, Söderkvist P, Gimm O. Genetics and clinical characteristics of hereditary pheochromocytomas and paragangliomas. *Endocr Relat Cancer* 2011; **18**: R253-R276 [PMID: 22041710 DOI: 10.1530/ERC-11-0170]
- 117 **Lenders JW**. Pheochromocytoma and pregnancy: a deceptive connection. *Eur J Endocrinol* 2012; **166**: 143-150 [PMID: 21890650 DOI: 10.1530/eje-11-0528]

P- Reviewer: Minuto MN, Sugawara A, Tanriverdi F
S- Editor: Song XX **L- Editor:** A **E- Editor:** Lu YJ





Published by **Baishideng Publishing Group Inc**

8226 Regency Drive, Pleasanton, CA 94588, USA

Telephone: +1-925-223-8242

Fax: +1-925-223-8243

E-mail: bpgoffice@wjgnet.com

Help Desk: <http://www.wjgnet.com/esps/helpdesk.aspx>

<http://www.wjgnet.com>

