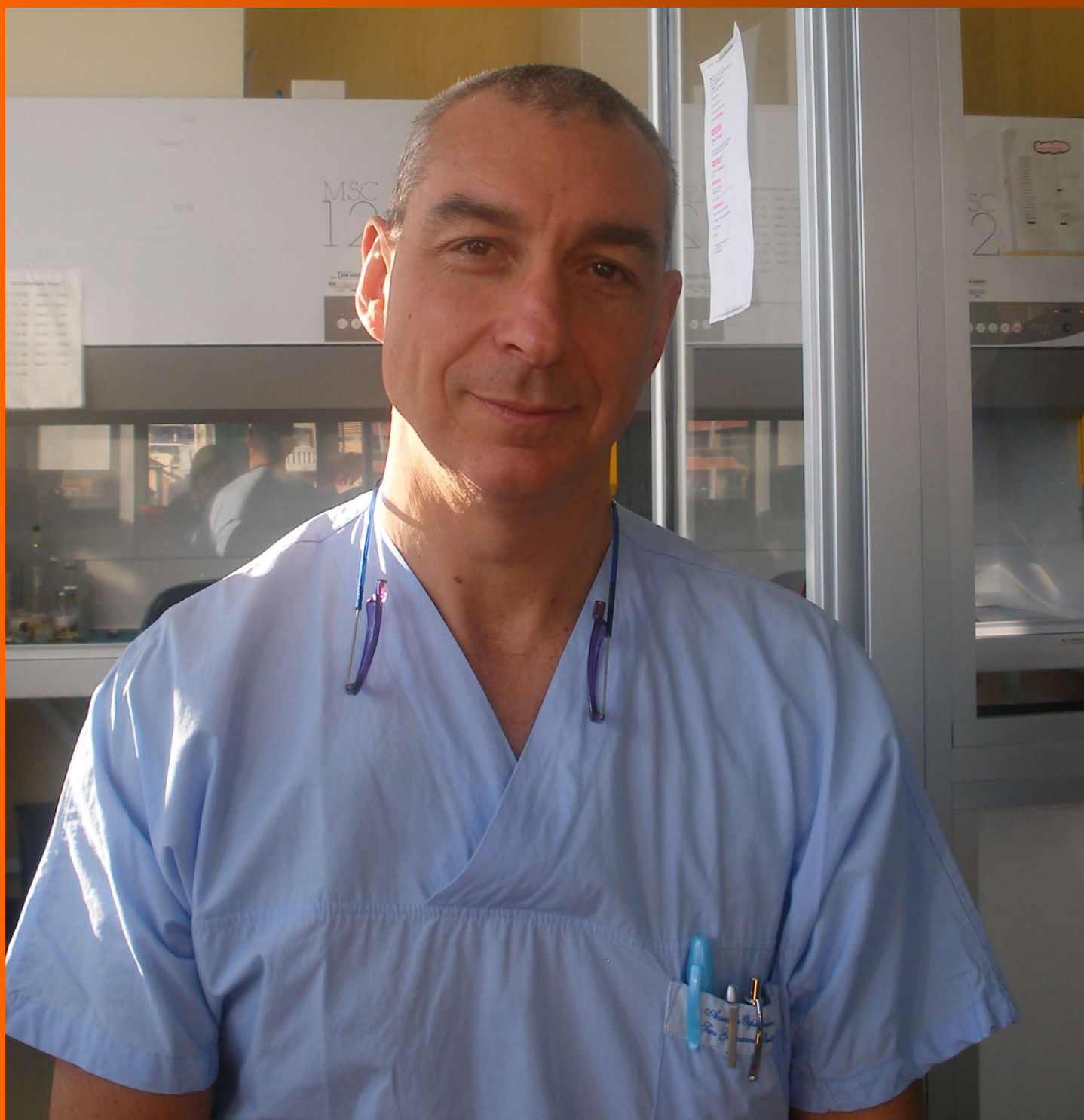

World Journal of *Transplantation*

World J Transplant 2017 August 24; 7(4): 222-249



**ORIGINAL ARTICLE****Observational Study**

- 222 Histopathological analysis of infiltrating T cell subsets in acute T cell-mediated rejection in the kidney transplant

Salcido-Ochoa F, Hue SSS, Peng S, Fan Z, Li RL, Iqbal J, Allen Jr JC, Loh AHL

- 235 Lymphocyte recovery is an independent predictor of relapse in allogeneic hematopoietic cell transplantation recipients for acute leukemia

Damlaj M, Ghazi S, Mashaqbeh W, Gmati G, Salama H, Abuelgasim KA, Rather M, Hajeer A, Al-Zahrani M, Jazieh AR, Hejazi A, Al Askar A

CASE REPORT

- 243 *De novo* intraocular amyloid deposition after hepatic transplantation in familial amyloidotic polyneuropathy

Gama IF, Almeida LD

Contents

World Journal of Transplantation
Volume 7 Number 4 August 24, 2017

ABOUT COVER

Editorial Board Member of *World Journal of Transplantation*, Alessandro Busca, MD, Doctor, Stem Cell Transplant Unit, Department of Hematology, AOU San Giovanni Battista, Corso Bramante 88, Turin 10126, Italy

AIM AND SCOPE

World Journal of Transplantation (*World J Transplant*, *WJT*, online ISSN 2220-3230, DOI: 10.5500) is a peer-reviewed open access academic journal that aims to guide clinical practice and improve diagnostic and therapeutic skills of clinicians.

WJT covers topics concerning organ and tissue donation and preservation; tissue injury, repair, inflammation, and aging; immune recognition, regulation, effector mechanisms, and opportunities for induction of tolerance, thoracic transplantation (heart, lung), abdominal transplantation (kidney, liver, pancreas, islets), transplantation of tissues, cell therapy and islet transplantation, clinical transplantation, experimental transplantation, immunobiology and genomics, and xenotransplantation. The current columns of *WJT* include editorial, frontier, diagnostic advances, therapeutics advances, field of vision, mini-reviews, review, topic highlight, medical ethics, original articles, case report, clinical case conference (Clinicopathological conference), and autobiography.

AIM AND SCOPE

World Journal of Transplantation is now indexed in PubMed, PubMed Central.

FLYLEAF

I-IV Editorial Board

EDITORS FOR THIS ISSUE

Responsible Assistant Editor: *Xiang Li*
Responsible Electronic Editor: *Ya-Jing Lu*
Proofing Editor-in-Chief: *Lian-Sheng Ma*

Responsible Science Editor: *Fang-Fang Ji*
Proofing Editorial Office Director: *Ze-Mao Gong*

NAME OF JOURNAL
World Journal of Transplantation

ISSN
ISSN 2220-3230 (online)

LAUNCH DATE
December 24, 2011

FREQUENCY
Bimonthly

EDITOR-IN-CHIEF
Maurizio Salvadori, MD, Professor, Renal Unit, Careggi University Hospital, Florence 50139, Italy

EDITORIAL BOARD MEMBERS
All editorial board members resources online at <http://www.wjgnet.com/2220-3230/editorialboard.htm>

EDITORIAL OFFICE
Xiu-Xia Song, Director

World Journal of Transplantation
Baishideng Publishing Group Inc
7901 Stoneridge Drive, Suite 501, Pleasanton, CA 94588, USA
Telephone: +1-925-2238242
Fax: +1-925-2238243
E-mail: editorialoffice@wjgnet.com
Help Desk: <http://www.fjopublishing.com/helpdesk>
<http://www.wjgnet.com>

PUBLISHER
Baishideng Publishing Group Inc
7901 Stoneridge Drive, Suite 501, Pleasanton, CA 94588, USA
Telephone: +1-925-2238242
Fax: +1-925-2238243
E-mail: bpgoffice@wjgnet.com
Help Desk: <http://www.fjopublishing.com/helpdesk>
<http://www.wjgnet.com>

PUBLICATION DATE
August 24, 2017

COPYRIGHT

© 2017 Baishideng Publishing Group Inc. Articles published by this Open-Access journal are distributed under the terms of the Creative Commons Attribution Non-commercial License, which permits use, distribution, and reproduction in any medium, provided the original work is properly cited, the use is non commercial and is otherwise in compliance with the license.

SPECIAL STATEMENT

All articles published in journals owned by the Baishideng Publishing Group (BPG) represent the views and opinions of their authors, and not the views, opinions or policies of the BPG, except where otherwise explicitly indicated.

INSTRUCTIONS TO AUTHORS

<http://www.wjgnet.com/bpg/gerinfo/204>

ONLINE SUBMISSION

<http://www.fjopublishing.com>

***De novo* intraocular amyloid deposition after hepatic transplantation in familial amyloidotic polyneuropathy**

Ivo Filipe Gama, Leonor Duarte Almeida

Ivo Filipe Gama, Leonor Duarte Almeida, Ophthalmology Department, Santa Maria University Hospital (North Lisbon Hospital Center), 1649-035 Lisbon, Portugal

Author contributions: Gama IF and Almeida LD designed the report; Almeida LD evaluated and followed-up the patient; Gama IF performed the complimentary exams and collected all clinical data; Gama IF and Almeida LD wrote the paper.

Institutional review board statement: The retrospective review and publication of patient's clinical data were approved by the Santa Maria University Hospital Ethics Committee.

Informed consent statement: The patient gave written consent for publication of his clinical data.

Conflict-of-interest statement: The authors declare that they have no conflicts of interest to disclose and they did not receive any funding for this paper.

Open-Access: This article is an open-access article which was selected by an in-house editor and fully peer-reviewed by external reviewers. It is distributed in accordance with the Creative Commons Attribution Non Commercial (CC BY-NC 4.0) license, which permits others to distribute, remix, adapt, build upon this work non-commercially, and license their derivative works on different terms, provided the original work is properly cited and the use is non-commercial. See: <http://creativecommons.org/licenses/by-nc/4.0/>

Manuscript source: Invited manuscript

Correspondence to: Ivo Filipe Gama, MD, Ophthalmology Department, Santa Maria University Hospital (North Lisbon Hospital Center), Av. Prof. Egas Moniz, 1649-035 Lisbon, Portugal. ivo.gama@chln.min-saude.pt
Telephone: +351-93-9160876

Received: September 15, 2016
Peer-review started: September 17, 2016
First decision: October 21, 2016
Revised: May 29, 2017
Accepted: June 19, 2017
Article in press: June 20, 2017
Published online: August 24, 2017

Abstract

The familial amyloid polyneuropathy (FAP) is a rare autosomal-dominant systemic amyloidosis. Amyloid deposition occurs more frequently and extensively in the vitq. The increase in intraocular pressure (IOP) is a result of deposition of transthyretin (TTR) in trabecular meshwork. Rarely, the amyloid deposition in anterior segment can be more exuberant than in posterior segment. A 42 years old man, with FAP (Val30Met mutation), liver transplantation in 1997. He was asymptomatic, without any significant ocular abnormality until 2011. In 2011 he had an episode of pain in right eye (RE). Scalloped pupils, pupillary amyloid deposits and subtle vitreous opacities were detected. The IOP was 40 mmHg in RE and 28 mmHg in left eye (LE) with open angle. Optical coherence tomography detected a temporal superior retinal nerve fiber layer defect in LE and perimetry was normal. Topical timolol was initiated, and brimonidine was subsequently added to improve IOP control, which was achieved with topical medication until last evaluation. No progression occurred since 2011. Actually, with longer life expectancies, there is an increased risk of ocular involvement in FAP, even after liver transplantation. Although rare, a more exuberant amyloid deposition in anterior segment *vs* posterior segment can occur, and supports an important role of amyloid production in ciliary pigment epithelium in these patients. Medical control of IOP and a stable course are unusual in this secondary glaucoma. Ophthalmologists have an important task in the follow-up of patients and early diagnosis of risk factors for secondary glaucoma, such as scalloped pupils with amyloid deposits.

Key words: Familial amyloid polyneuropathy; Glaucoma; Scalloped pupils; Pupillary amyloid deposits; Liver transplantation

© The Author(s) 2017. Published by Baishideng Publishing Group Inc. All rights reserved.

Core tip: Ocular manifestations of familial amyloidotic

polyneuropathy (FAP) can appear after liver transplantation due to *de novo* ocular production of amyloid. Rarely, amyloid deposition in vitreous is relatively less exuberant than in anterior segment. Our case illustrates this asymmetry of amyloid deposition and emphasizes the association between scalloped pupils and glaucoma, a major ocular complication of FAP. Our case had a stable course, with excellent visual function and the intraocular pressure was controlled by medical therapy, which are unusual in this type of glaucoma. This case-report also highlights the importance of the long-term ophthalmological follow-up in FAP patients.

Gama IF, Almeida LD. *De novo* intraocular amyloid deposition after hepatic transplantation in familial amyloidotic polyneuropathy. *World J Transplant* 2017; 7(4): 243-249 Available from: URL: <http://www.wjgnet.com/2220-3230/full/v7/i4/243.htm> DOI: <http://dx.doi.org/10.5500/wjt.v7.i4.243>

INTRODUCTION

Transthyretin (TTR)-related familial amyloid polyneuropathy (FAP) is a group of autosomal-dominant diseases of variable penetrance caused by the deposition of polymerized mutated TTR in the peripheral nerves, gastrointestinal tract, heart, ocular tissues, and other organs. These protein aggregates have affinity for Congo red stain and apple-green birefringence when viewed under polarized light^[1-3]. They are caused by mutations of TTR gene (18q11.2-12.1)^[2]. Peripheral neuropathy is progressive and frequently the first manifestation of the disease^[1-3]. Type 1 FAP, the Portuguese type (FAP1) was described for the first time in 1952 by Corino de Andrade^[4]. FAP1 is the most frequent type of FAP and caused by a mutational substitution of the valine for methionine in position 30 of TTR gene (Val30Met)^[2].

There are many ophthalmological manifestations of FAP caused by deposition of amyloid in various intra-ocular tissues: Vitreous, iris, pupillary border, anterior capsule and trabecular meshwork. The pupillary margin may have a scalloped/indented configuration (scalloped pupils) and pupils may be slow or nonreactive to both light and near stimulation, caused by disturbance of autonomic innervation^[1-3,5-8]. Fleck deposits resembling pseudoexfoliation (PEX) may be found on the anterior lens capsule and pupillary margin^[1-3,7]. *Pseudopodia lentis* is a hallmark of vitreous amyloidosis, where multiple small dots or footplates are formed on the posterior lens surface^[2]. Trabecular meshwork deposition of amyloid causes obstruction of aqueous humor outflow and subsequent elevation of intra-ocular pressure (IOP)^[9]. Secondary glaucoma can develop rapidly with high IOP, which if left untreated it can lead to severe damage^[3,9]. Other manifestations include dry eye by decreased tear production, conjunctival microaneurysms and reduced corneal sensitivity with subsequent neurotrophic corneal

ulcers^[2].

TTR is a normal constituent of blood plasma, acts as a thyroxine transport protein and is important in vitamin A transport^[2,3]. TTR is synthesized mainly in liver (90%), but there is also intra-ocular production^[1,3,6,7,10-12]. Retinal pigment epithelium (RPE) is a source of TTR synthesis in rat eyes^[10]. Recently, it was demonstrated that TTR production also occurs in the ciliary pigment epithelium (CPE)^[12].

Liver transplantation (LT) improved the quality and survival of FAP patients, but does not prevent ocular manifestations of FAP, because of persistent intra-ocular production of amyloidotic TTR (ATTR). A case of vitreous amyloidosis appearing 2 years after LT was described and mutant protein ATTR was detected in aqueous humor of a Japanese patient after LT^[13,14].

Secondary glaucoma is a major complication of FAP, which can be the first ocular manifestation and cause irreversible visual loss. Thus, early diagnosis is fundamental to avoid rapid progression of glaucoma^[9].

The authors want to emphasize the importance of the recognition of ophthalmological signs that are associated with increased risk of ocular hypertension and glaucoma in FAP1 patients after LT as well as to report an unusual asymmetric pattern of intraocular amyloid deposition, with a case report and bibliographic revision.

CASE REPORT

A 42-year-old man had a diagnosis of FAP since 1995, with a positive genetic test for ATTR Val30Met mutation, and was subjected to LT in 1997. The peripheral neuropathy improved after LT. His brother and mother had type 1 FAP. The patient did not have any other previous ophthalmological diagnosis besides myopia. No FAP-related ophthalmological abnormalities were detected on routine ophthalmology evaluations for 14 years after LT.

In November 2011, he had an episode of ocular pain in right eye (RE) and attended the emergency room. Best-corrected visual acuity was 20/20 in RE and left eye (LE). Pupils were isochoric with slow pupillary responses to light and near stimulation. Ocular movements were normal. Biomicroscopy showed bilateral whitish fleck flocculent deposits of amyloid in the pupillary borders, scalloped pupils and few deposits in anterior vitreous (Figure 1). The detection of abnormalities led to the measurement of intraocular pressure (IOP) by Goldmann applanation tonometry (GAT), being 40 mmHg in RE and 28 mmHg in LE. Gonioscopy showed open angles - Shaffer grade of 4. Fundoscopy and retinography showed few vitreous opacities and clearly visible normal posterior poles, with normal appearing optic discs (Figures 2 and 3). Central corneal thickness was 559 μ m in RE and 550 μ m in LE. Ophthalmic ultrasound (US) showed few vitreous opacities bilaterally (Figure 4). Optical coherence tomography (OCT) only showed a superior-temporal

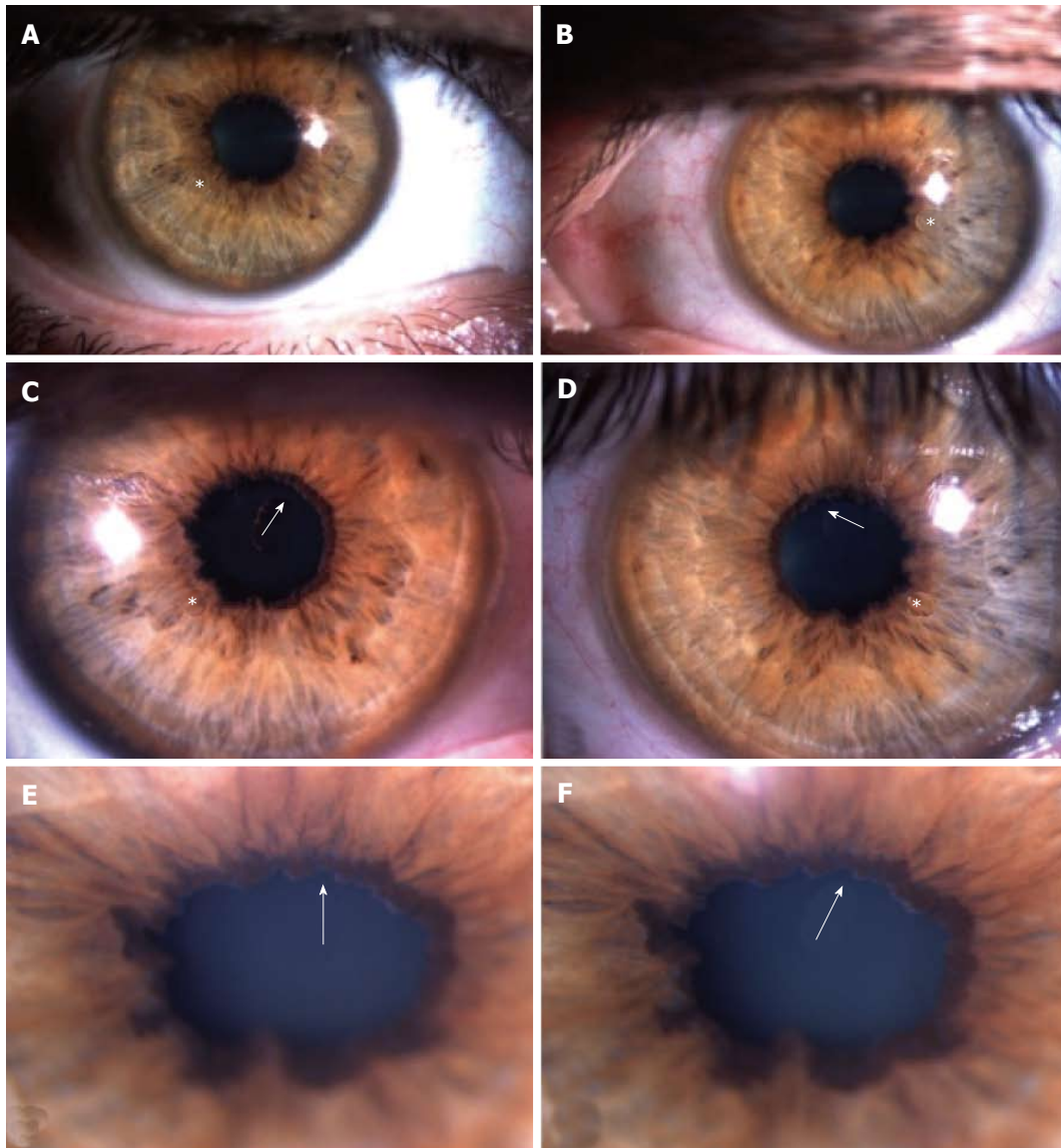


Figure 1 Slit-lamp photos showing scalloped pupils (asterisks) and amyloid deposition in the pupillary border (arrows) in both eyes. A and B: Slit-lamp photos of anterior segment of right (A) and left eyes (B) at low magnification; C and D: Slit-lamp photos at higher magnification to show pupillary margins of right (C) and left (D) eyes with more detail, in order to highlight the irregular pupillary margins, the scalloped pupils (asterisks) with amyloid deposits (arrows); E and F: Slit-lamp photos of the right eye (E and F) at the highest magnification to enhance visualization of the pupillary amyloid deposits (arrows), which resemble those seen in pseudoexfoliation syndrome.

peripapillary retinal fiber layer retinal nerve fiber layer (RNFL) defect in LE (Figure 5). Automated perimetry was unremarkable in both eyes (Figure 6). Topical monotherapy with timolol 0.5% was initiated at that time, and the IOP lowered to 26 mmHg in RE and to 21 mmHg in LE. To optimize IOP control, brimonidine was associated with timolol further lowering the IOP to 14 mmHg in both eyes. The patient was followed up closely in the glaucoma clinic until present, with controlled IOP. Last CSP and OCT exams excluded glaucoma progression.

DISCUSSION

Although ATTR levels after LT decline to < 1% of pre-transplant levels, FAP patients are still at risk of

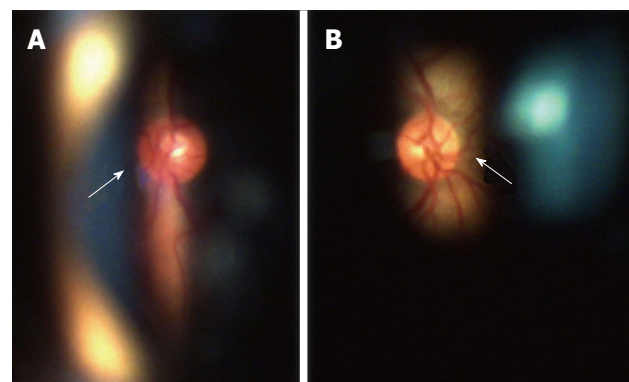


Figure 2 Fundoscopy of right (A) and left (B) eyes showed normal-appearing optic discs (arrows) and absence of abnormalities in posterior pole and peripheral retina. Ocular fundus was perfectly visible due to mild amyloid deposition in the vitreous.

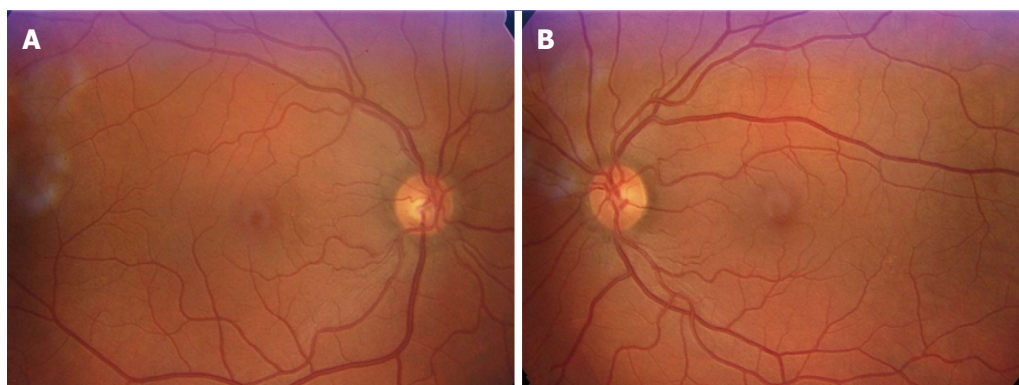


Figure 3 Retinography of right eye (A) and left eye (B) showed normal posterior poles, which were clearly visible due to the mild amyloid deposition in the vitreous, with only few opacities, which did not compromise visual acuity.

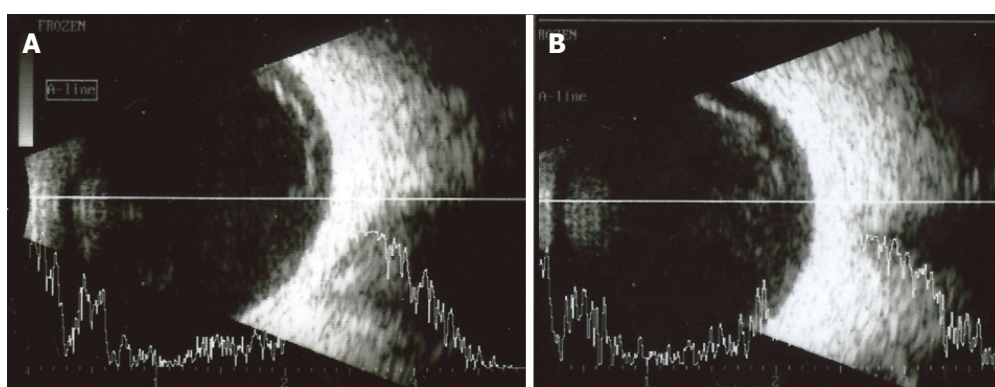


Figure 4 Ophthalmic ultrasound of right (A) and left (B) eyes showing some vitreous opacities corresponding to amyloid deposits in the vitreous. This amyloid deposition in the vitreous is relatively mild compared to the degree of amyloid deposition in anterior segment.

ophthalmological complications of the disease because of continued intra-ocular production in RPE and CPE and continued amyloid deposition in various ocular tissues, such as vitreous, pupil, anterior lens capsule and trabecular meshwork^[1,3,6,7,10,12-18].

LT improved survival and consequently there is increased risk of ocular complications of FAP in transplantation era, because ocular manifestations are dependent of the duration of systemic disease. Glaucoma is a major ocular complication of FAP and a major cause of visual loss in these patients^[1,3,19,20].

The study of Kimura *et al*^[1] reported glaucoma in 24% of all FAP patients and in 17% of patients with Val30Met mutation, but the prevalence of glaucoma differs in various studies, from 5.4% to 27%^[1,20,21]. Glaucoma is secondary to amyloid deposition in trabecular meshwork and if not recognized or treated adequately can have a rapid progression and devastating visual consequences in these patients, who have already a great morbidity from the systemic disease^[1,3,19,20]. The pathophysiology of glaucoma in FAP1 after LT is related to the deposition of amyloid fibrillar aggregates in intertrabecular spaces of corneoscleral and uveoscleral meshworks and degeneration of endothelium cells of trabecular meshwork^[6]. The trabecular outflow resistance increases, which raises IOP. Perivascular deposition of

amyloid in conjunctival and scleral tissues can increase episcleral pressure and, consequently, the outflow resistance, but this mechanism is mainly dependent on systemic production of ATTR, playing an important role only before LT^[6].

Most of the ophthalmological studies of FAP are focused in vitreous opacities (VO) and there are only few studies about secondary glaucoma. In the study of Kimura *et al*^[1], VO were found in 35% of patients and amyloid deposition in pupil and anterior lens capsule in 31% of patients. Scalloped pupils are caused by autonomic abnormalities, which are associated with a higher degree of amyloid deposition in anterior segment and can also predict glaucoma^[3]. They occur in 8% of FAP patients and glaucoma in 20% of patients. Glaucoma was diagnosed in all cases (100%) with scalloped pupils and in 57% of cases with amyloid deposition in anterior segment (pupil and anterior lens capsule). Only 49% of cases with VO had glaucoma^[1]. Vitreous opacities are a classic ocular manifestation of FAP, but accordingly to the studies of Kimura *et al*^[1] and Sandgren *et al*^[3], the association between VO and glaucoma is weaker than between glaucoma and pupillary abnormalities (scalloped pupils, ATTR deposition in pupillary margin)^[1,3]. This finding is supported by our clinical case.

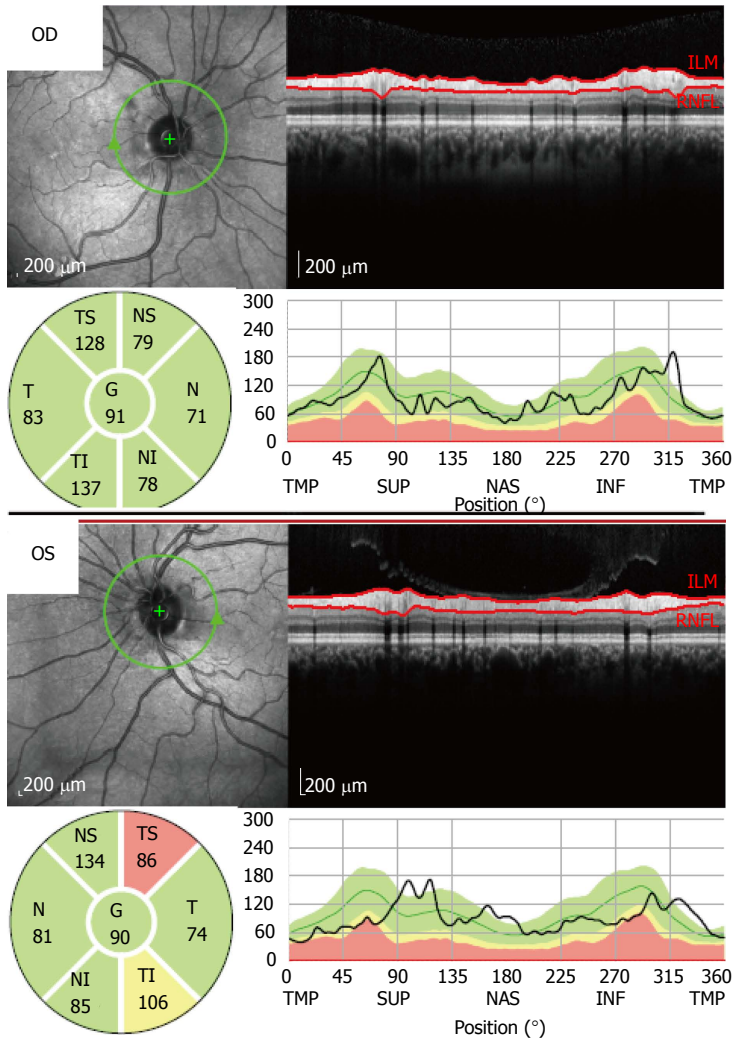


Figure 5 Optical coherence tomography showed a localized defect in the temporal-superior area of the peripapillary retinal nerve fiber layer of the left eye (OS). In the right eye (OD), the retinal nerve fiber layer thickness was normal in all peripapillary locations.

Sandgren *et al.*^[3,7] suggested that amyloid deposits in pupil and anterior lens capsule are more precocious than in the vitreous, which can explain the existence of rare cases, such as our case, which have much more ATTR deposition in anterior segment than in vitreous. These rare cases, such as our clinical case, corroborate the hypothesis raised by the study from Kawaji *et al.*^[12] postulating that the ATTR accumulated in anterior segment may have origin in CPE. This hypothesis can explain this asymmetry between ATTR deposition in anterior and posterior segments, as occurred our clinical case^[12].

Amyloid is transported in the aqueous. Thus, pupillary amyloid deposits are an indirect sign of exuberant amyloid deposition in anterior segment, including the trabecular meshwork. This results in an increased resistance to aqueous humor outflow^[19]. Kimura *et al.*^[1] have found that pupillary amyloid deposits have preceded the diagnosis of glaucoma by an average period of 2.55 ± 1.43 years (range 0.2-4.0 years). In the presented clinical case, the recognition of the pupillary abnormalities raised the clinical suspicion of glaucoma that was confirmed by appropriate investigation. Preperimetric glaucoma was confirmed by the finding of a localized defect of nerve fiber layer without perimetric functional repercussion.

Most cases of glaucoma secondary to FAP are

usually refractory to medical treatment and have a fast progression and bad prognosis. This type of glaucoma usually requires surgical treatment^[8]. Tube shunts, specially the Ahmed valve have been extensively used for surgical treatment of FAP1-related glaucoma in Portugal^[8]. Recently minimal invasive options for glaucoma treatment are available for primary open-angle glaucoma and some types of secondary glaucoma, having the advantage of being less traumatic to the eye. However, prospective studies of efficacy in FAP-related glaucoma are lacking. Our clinical case had an unusual clinical course, with a good IOP control with medical treatment and stable visual fields and RNFL thicknesses.

Pars plana vitrectomy can be performed if vitreous opacities impair visual acuity, but this was not the case of our patient. Also, glaucoma can occur or be aggravated after pars plana vitrectomy in FAP patients, which is an important aspect to consider when managing ocular manifestations of FAP patients also affected by secondary glaucoma.

In an era that FAP patients have a greater life expectancy with liver transplant, there is an increased probability of serious ocular disease caused by FAP, such as glaucoma that requires a regular ophthalmologic follow-up.

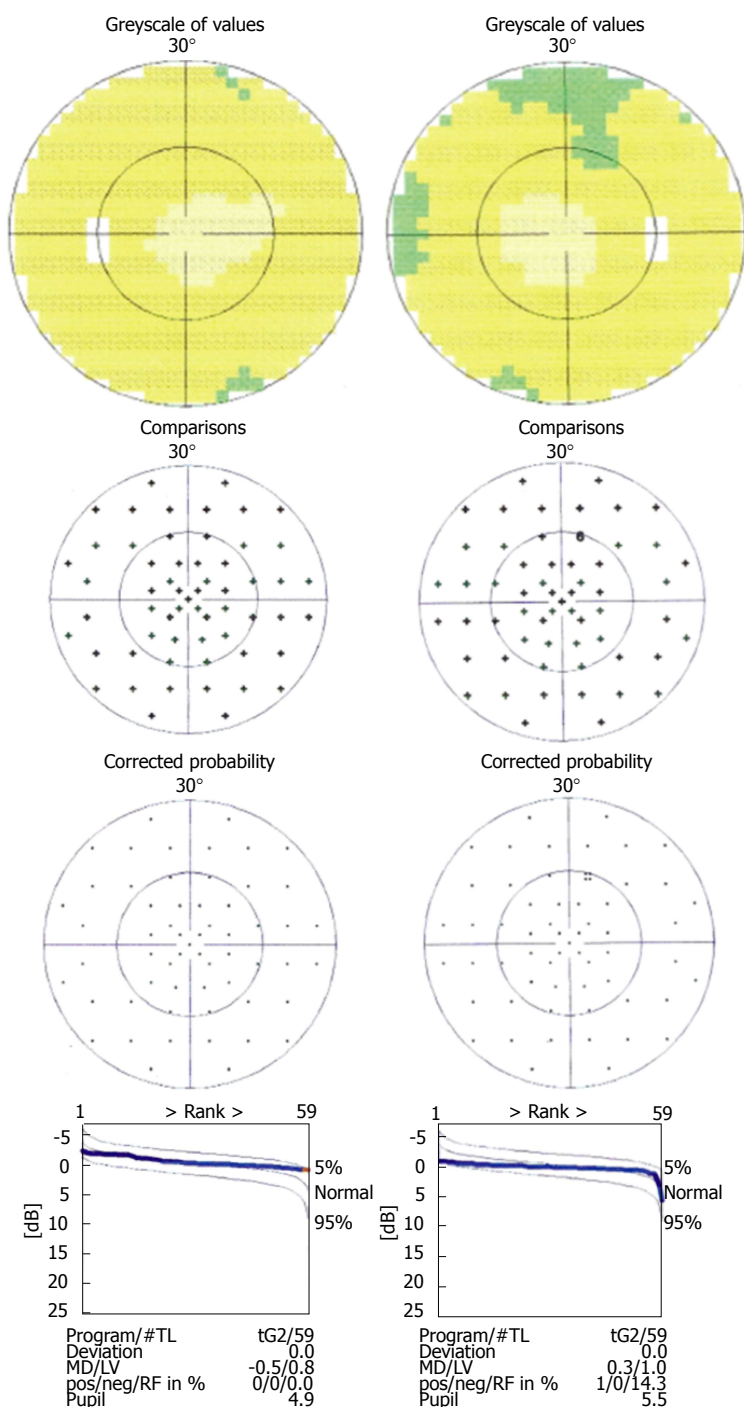


Figure 6 Computerized static perimetry of right eye (at the right) and left eye (at the left) (tendency-oriented perimetry, TOP - 30° program, Octopus 101 perimeter, Haag-Streit Diagnostics, Switzerland) in November 2011, showed the absence of clinically significant abnormalities in the visual fields - preperimetric glaucoma.

COMMENTS

Case characteristics

A 41-year-old man with type 1 familial amyloid polyneuropathy (FAP) subjected to liver transplantation in 1997, presented with ocular pain.

Clinical diagnosis

Ophthalmological examination showed ocular hypertension, scalloped pupils associated to exuberant amyloid pupillary deposits, which contrasted with the mild vitreous opacities on ultrasound.

Differential diagnosis

FAP-related secondary open-angle glaucoma, FAP-related secondary ocular hypertension, pseudoexfoliation glaucoma, ocular hypertension associated to pseudoexfoliation syndrome.

Imaging diagnosis

Ocular ultrasound showed mild vitreous opacities due to amyloid deposition. Retinography showed normal posterior poles. Optical coherence tomography only showed a peripapillary temporal-superior retinal nerve fiber layer defect in OS. Perimetry did not show significant visual field abnormalities.

Treatment

Treatment with topical timolol and brimonidine achieved intraocular pressure (IOP) control. This treatment was continued, permitting disease stabilization with IOP control. This is a rare clinical course of this disease.

Related reports

De novo intraocular amyloid synthesis and deposition occurs after liver transplantation, having the potential to cause serious ocular complications. Most reported cases of FAP-related secondary glaucoma with scalloped

pupils have exuberant vitreous amyloid deposition. The asymmetry between exuberant amyloid deposition in anterior segment vs mild vitreous deposition that was reported in this clinical case is rare, and suggests a role of ciliary pigment epithelium in intraocular amyloid synthesis. This clinical case had a rare clinical course.

Term explanation

FAP-related glaucoma after liver transplantation is a secondary type of glaucoma, caused by an increase in trabecular outflow resistance associated to trabecular amyloid deposition, with amyloid fibrillar aggregates in intertrabecular spaces of corneoscleral and uveoscleral meshworks and degeneration of endothelium cells of trabecular meshwork.

Experiences and lessons

Rarely, amyloid deposition in anterior segment can be much more exuberant than vitreous deposition. This asymmetry supports a significant role of the ciliary pigmented epithelium in the intraocular amyloid synthesis in these cases. Pupillary amyloid deposition and scalloped pupils have a stronger correlation to glaucoma than other ocular manifestations. Rarely, FAP-related glaucoma can be stable and well controlled by medical treatment alone.

Peer-review

This case is very rare and an interesting case.

REFERENCES

- Kimura A, Ando E, Fukushima M, Koga T, Hirata A, Arimura K, Ando Y, Negi A, Tanihara H. Secondary glaucoma in patients with familial amyloidotic polyneuropathy. *Arch Ophthalmol* 2003; **121**: 351-356 [PMID: 12617705 DOI: 10.1001/archophth.121.3.351]
- Rutar TRM. Diseases of the Vitreous. In: Albert DM, Miller JW, Azar DT BB, ed. *Albert & Jakobiec's Principles and Practice of Ophthalmology*. 3rd ed. Philadelphia: W. B. Saunders Company, 2008: 2391-2398
- Sandgren O, Kjellgren D, Suhr OB. Ocular manifestations in liver transplant recipients with familial amyloid polyneuropathy. *Acta Ophthalmol* 2008; **86**: 520-524 [PMID: 18435819 DOI: 10.1111/j.1600-0420.2007.01098.x]
- Andrade C. A peculiar form of peripheral neuropathy; familial atypical generalized amyloidosis with special involvement of the peripheral nerves. *Brain* 1952; **75**: 408-427 [PMID: 12978172 DOI: 10.1093/brain/75.3.408]
- Lessell S, Wolf PA, Benson MD, Cohen AS. Scalloped pupils in familial amyloidosis. *N Engl J Med* 1975; **293**: 914-915 [PMID: 1177989 DOI: 10.1056/NEJM197510302931808]
- Rosa AM, Quadrado MJ, Ferrão J. Manifestações Oculares de Polineuropatia Amiloidótica Familiar Tipo I em Doentes Submetidos a Transplante Hepático. *Oftalmol (Port Ophthalmol Soc Journal)* 2009; **33**: 177-183
- Sandgren O. Ocular amyloidosis, with special reference to the hereditary forms with vitreous involvement. *Surv Ophthalmol* 1995; **40**: 173-196 [PMID: 8599154 DOI: 10.1016/S0039-6257(95)80025-5]
- Sampaio I, Queirós J, Borges P, Reimão P, Beirão M. MMAC. Glaucoma em Doentes Portugueses com Polineuropatia Amiloidótica Familiar. *Oftalmol (Port Ophthalmol Soc Journal)* 2011; **35**: 311-318
- Doft BH, Machemer R, Skinner M, Buettner H, Clarkson J, Crock J, McLeod D, Michels R, Scott J, Wilson D. Pars plana vitrectomy for vitreous amyloidosis. *Ophthalmology* 1987; **94**: 607-611 [PMID: 3627709 DOI: 10.1016/S0161-6420(87)33402-5]
- Cavallaro T, Martone RL, Dwork AJ, Schon EA, Herbert J. The retinal pigment epithelium is the unique site of transthyretin synthesis in the rat eye. *Invest Ophthalmol Vis Sci* 1990; **31**: 497-501 [PMID: 1690688]
- Futa R, Inada K, Nakashima H, Baba H, Kojima Y, Okamura R, Araki S. Familial amyloidotic polyneuropathy: ocular manifestations with clinicopathological observation. *Jpn J Ophthalmol* 1984; **28**: 289-298 [PMID: 6098757]
- Kawaji T, Ando Y, Nakamura M, Yamamoto K, Ando E, Takano A, Inomata Y, Hirata A, Tanihara H. Transthyretin synthesis in rabbit ciliary pigment epithelium. *Exp Eye Res* 2005; **81**: 306-312 [PMID: 16129098 DOI: 10.1016/j.exer.2005.02.003]
- Munar-Qués M, Salva-Ladaria L, Mulet-Perera P, Solé M, López-Andreu FR, Saraiva MJ. Vitreous amyloidosis after liver transplantation in patients with familial amyloid polyneuropathy: ocular synthesis of mutant transthyretin. *Amyloid* 2000; **7**: 266-269 [PMID: 11132095 DOI: 10.3109/13506120009146440]
- Haraoka K, Ando Y, Ando E, Sun X, Nakamura M, Terazaki H, Misumi S, Tanoue Y, Tajiri T, Shoji S, Ishizaki T, Okabe H, Tanihara H. Presence of variant transthyretin in aqueous humor of a patient with familial amyloidotic polyneuropathy after liver transplantation. *Amyloid* 2002; **9**: 247-251 [PMID: 12557753 DOI: 10.3109/13506120209114101]
- Ando E, Ando Y, Haraoka K. Ocular amyloid involvement after liver transplantation for polyneuropathy. *Ann Intern Med* 2001; **135**: 931-932 [PMID: 11712896 DOI: 10.7326/0003-4819-135-10-200111200-00025]
- Ando Y, Ando E, Tanaka Y, Yamashita T, Tashima K, Suga M, Uchino M, Negi A, Ando M. De novo amyloid synthesis in ocular tissue in familial amyloidotic polyneuropathy after liver transplantation. *Transplantation* 1996; **62**: 1037-1038 [PMID: 8878404]
- Hara R, Kawaji T, Ando E, Ohya Y, Ando Y, Tanihara H. Impact of liver transplantation on transthyretin-related ocular amyloidosis in Japanese patients. *Arch Ophthalmol* 2010; **128**: 206-210 [PMID: 20142544 DOI: 10.1001/archophth.2009.390]
- Neto E, Ferreira A, Almeida L, Pinto F GM. Paramiloidose ocular após transplante hepático. *Oftalmol (Port Ophthalmol Soc Journal)* 2009; **33**: 51-56
- Silva-Araújo AC, Tavares MA, Cotta JS, Castro-Correia JF. Aqueous outflow system in familial amyloidotic polyneuropathy, Portuguese type. *Graefes Arch Clin Exp Ophthalmol* 1993; **231**: 131-135 [PMID: 8385054]
- Tsukahara S, Matsuo T. Secondary glaucoma accompanied with primary familial amyloidosis. *Ophthalmologica* 1977; **175**: 250-262 [PMID: 896156]
- Ando E, Ando Y, Okamura R, Uchino M, Ando M, Negi A. Ocular manifestations of familial amyloidotic polyneuropathy type I: long-term follow up. *Br J Ophthalmol* 1997; **81**: 295-298 [PMID: 9215058 DOI: 10.1136/bjo.81.4.295]

P- Reviewer: Hong YJ, Nowak MS S- Editor: Ji FF L- Editor: A
E- Editor: Lu YJ





Published by **Baishideng Publishing Group Inc**
7901 Stoneridge Drive, Suite 501, Pleasanton, CA 94588, USA
Telephone: +1-925-223-8242
Fax: +1-925-223-8243
E-mail: bpgoffice@wjgnet.com
Help Desk: <http://www.f6publishing.com/helpdesk>
<http://www.wjgnet.com>

