

World Journal of *Gastrointestinal Surgery*

World J Gastrointest Surg 2017 July 27; 9(7): 161-173





ORIGINAL ARTICLE

Retrospective Cohort Study

- 161 Perforation associated with endoscopic submucosal dissection for duodenal neoplasm without a papillary portion

Matsuda Y, Sakamoto K, Kataoka N, Yamaguchi T, Tomita M, Makimoto S

Retrospective Study

- 167 Analysis of risk factors - especially different types of plexitis - for postoperative relapse in Crohn's disease

Milassin Á, Sejben A, Tiszlavicz L, Reisz Z, Lázár G, Szűcs M, Bor R, Bálint A, Rutka M, Szepes Z, Nagy F, Farkas K, Molnár T

Contents

World Journal of Gastrointestinal Surgery

Volume 9 Number 7 July 27, 2017

ABOUT COVER

Editorial Board Member of *World Journal of Gastrointestinal Surgery*, Eelco de Bree, MD, PhD, Associate Professor, Department of Surgical Oncology, University Hospital, Heraklion 71110, Greece

AIM AND SCOPE

World Journal of Gastrointestinal Surgery (*World J Gastrointest Surg*, *WJGS*, online ISSN 1948-9366, DOI: 10.4240) is a peer-reviewed open access academic journal that aims to guide clinical practice and improve diagnostic and therapeutic skills of clinicians.

WJGS covers topics concerning micro-invasive surgery; laparoscopy; hepatic, biliary, pancreatic and splenic surgery; surgical nutrition; portal hypertension, as well as associated subjects. The current columns of *WJGS* include editorial, frontier, diagnostic advances, therapeutics advances, field of vision, mini-reviews, review, topic highlight, medical ethics, original articles, case report, clinical case conference (Clinicopathological conference), and autobiography. Priority publication will be given to articles concerning diagnosis and treatment of gastrointestinal surgery diseases. The following aspects are covered: Clinical diagnosis, laboratory diagnosis, differential diagnosis, imaging tests, pathological diagnosis, molecular biological diagnosis, immunological diagnosis, genetic diagnosis, functional diagnostics, and physical diagnosis; and comprehensive therapy, drug therapy, surgical therapy, interventional treatment, minimally invasive therapy, and robot-assisted therapy.

We encourage authors to submit their manuscripts to *WJGS*. We will give priority to manuscripts that are supported by major national and international foundations and those that are of great basic and clinical significance.

INDEXING/ABSTRACTING

World Journal of Gastrointestinal Surgery is now indexed in Emerging Sources Citation Index (Web of Science), PubMed, and PubMed Central.

FLYLEAF

I-III Editorial Board

EDITORS FOR THIS ISSUE

Responsible Assistant Editor: *Xiang Li*
Responsible Electronic Editor: *Huan-Liang Wu*
Proofing Editor-in-Chief: *Lian-Sheng Ma*

Responsible Science Editor: *Fang-Fang Ji*
Proofing Editorial Office Director: *Jin-Lei Wang*

NAME OF JOURNAL

World Journal of Gastrointestinal Surgery

ISSN

ISSN 1948-9366 (online)

LAUNCH DATE

November 30, 2009

FREQUENCY

Monthly

EDITOR-IN-CHIEF

Timothy M Pawlik, MD, Director, Professor, Department of Surgery, Johns Hopkins University, School of Medical, Baltimore, MD 21287, United States

EDITORIAL BOARD MEMBERS

All editorial board members resources online at <http://www.wjgnet.com/1948-9366/editorialboard.htm>

EDITORIAL OFFICE

Xiu-Xia Song, Director

World Journal of Gastrointestinal Surgery

Baishideng Publishing Group Inc
7901 Stoneridge Drive, Suite 501, Pleasanton, CA 94588, USA
Telephone: +1-925-2238242
Fax: +1-925-2238243
E-mail: editorialoffice@wjgnet.com
Help Desk: <http://www.wjgnet.com/helpdesk>
<http://www.wjgnet.com>

PUBLISHER

Baishideng Publishing Group Inc
901 Stoneridge Drive, Suite 501,
Pleasanton, CA 94588, USA
Telephone: +1-925-2238242
Fax: +1-925-2238243
E-mail: bpoffice@wjgnet.com
Help Desk: <http://www.wjgnet.com/helpdesk>
<http://www.wjgnet.com>

PUBLICATION DATE

July 27, 2017

COPYRIGHT

© 2017 Baishideng Publishing Group Inc. Articles published by this Open-Access journal are distributed under the terms of the Creative Commons Attribution Non-commercial License, which permits use, distribution, and reproduction in any medium, provided the original work is properly cited, the use is non commercial and is otherwise in compliance with the license.

SPECIAL STATEMENT

All articles published in journals owned by the Baishideng Publishing Group (BPG) represent the views and opinions of their authors, and not the views, opinions or policies of the BPG, except where otherwise explicitly indicated.

INSTRUCTIONS TO AUTHORS

<http://www.wjgnet.com/bpg/gerinfo/204>

ONLINE SUBMISSION

<http://www.wjgnet.com>

Retrospective Cohort Study

Perforation associated with endoscopic submucosal dissection for duodenal neoplasm without a papillary portion

Yasuhiro Matsuda, Kazuki Sakamoto, Naoki Kataoka, Tomoyuki Yamaguchi, Masafumi Tomita, Shinichiro Makimoto

Yasuhiro Matsuda, Kazuki Sakamoto, Naoki Kataoka, Tomoyuki Yamaguchi, Masafumi Tomita, Shinichiro Makimoto, Department of Surgery, Kishiwada Tokushukai Hospital, Kishiwada City, Osaka 596-8522, Japan

Author contributions: Matsuda Y designed the research and wrote the paper; Sakamoto K designed the research and provided treatment; Sakamoto K, Kataoka N, Yamaguchi T, Tomita M and Makimoto S provided treatment and analyzed the data.

Institutional review board statement: The study was reviewed and approved by the Institutional Review Board of Kishiwada Tokushukai Hospital for ethical issues.

Informed consent statement: Patients were not required to give informed consent to the study because the analysis used anonymous clinical data that were obtained after each patient agreed to treatment without additional invasion.

Conflict-of-interest statement: The authors certify that there is no conflict of interest with any financial organization regarding the material discussed in the manuscript.

Data sharing statement: Dataset available from the corresponding author at my-salsa@air.ocn.ne.jp.

Open-Access: This article is an open-access article which was selected by an in-house editor and fully peer-reviewed by external reviewers. It is distributed in accordance with the Creative Commons Attribution Non Commercial (CC BY-NC 4.0) license, which permits others to distribute, remix, adapt, build upon this work non-commercially, and license their derivative works on different terms, provided the original work is properly cited and the use is non-commercial. See: <http://creativecommons.org/licenses/by-nc/4.0/>

Manuscript source: Unsolicited manuscript

Correspondence to: Yasuhiro Matsuda, MD, Department of Surgery, Kishiwada Tokushukai Hospital, 4-27-1 Kamori-chou, Kishiwada city, Osaka 596-8522,

Japan. my-salsa@air.ocn.ne.jp
Telephone: +81-72-4459915
Fax: +81-72-4459791

Received: December 27, 2016

Peer-review started: December 30, 2016

First decision: January 28, 2017

Revised: May 26, 2017

Accepted: June 6, 2017

Article in press: June 8, 2017

Published online: July 27, 2017

Abstract**AIM**

To investigate predictors of perforation after endoscopic resection (ER) for duodenal neoplasms without a papillary portion.

METHODS

This was a single-center, retrospective, cohort study conducted between April 2003 and September 2014. A total of 54 patients (59 lesions) underwent endoscopic mucosal resection (EMR) ($n = 36$) and endoscopic submucosal dissection (ESD) ($n = 23$). Clinical features, outcomes, and predictors of perforation were investigated.

RESULTS

Cases of perforation occurred in eight (13%) patients (95%CI: 4.7%-22.6%). Three ESD cases required surgical management because they could not be repaired by clipping. Delayed perforation occurred in two ESD cases, which required surgical management, although both patients underwent prophylactic clipping. All patients with perforation who required surgery had no postoperative complications and were discharged at an

average of 13.2 d after ER. Perforation after ER showed a significant association with a tumor size greater than 20 mm ($P = 0.014$) and ESD ($P = 0.047$).

CONCLUSION

ESD for duodenal neoplasms exceeding 20 mm may be associated with perforation. ESD alone is not recommended for tumor treatment, and LECS should be considered as an alternative.

Key words: Duodenal neoplasm; Endoscopic submucosal dissection; Laparoscopic and endoscopic cooperative surgery

© **The Author(s) 2017.** Published by Baishideng Publishing Group Inc. All rights reserved.

Core tip: Duodenal neoplasms are relatively rare, and endoscopic mucosal resection (EMR) or endoscopic submucosal dissection (ESD) of the duodenum poses a high risk of complications. In our study, 54 patients (59 lesions) underwent EMR ($n = 36$) and ESD ($n = 23$). Cases of perforation occurred in eight (13%) patients (95%CI: 4.7%-22.6%), and perforation showed a significant association with a tumor size greater than 20 mm ($P = 0.014$) and ESD ($P = 0.047$). ESD for duodenal neoplasms exceeding 20 mm may be associated with perforation. ESD alone is not recommended as a treatment for tumor treatment, and laparoscopic and endoscopic cooperative surgery should be considered as an alternative.

Matsuda Y, Sakamoto K, Kataoka N, Yamaguchi T, Tomita M, Makimoto S. Perforation associated with endoscopic submucosal dissection for duodenal neoplasm without a papillary portion. *World J Gastrointest Surg* 2017; 9(7): 161-166 Available from: URL: <http://www.wjgnet.com/1948-9366/full/v9/i7/161.htm> DOI: <http://dx.doi.org/10.4240/wjgs.v9.i7.161>

INTRODUCTION

Duodenal neoplasms are relatively rare. Duodenal polyps are found in 4.6% of patients referred for upper gastrointestinal endoscopy^[1]. Primary adenocarcinoma represents only 0.3% of all gastrointestinal tract malignant neoplasms and 0.042% of all malignant neoplasms^[2,3]. Therefore, no method of treatment for duodenal neoplasm has been established.

Recently, cases of endoscopic resection (ER) for superficial neoplasms without lymph node metastasis have been reported. ER may consist of endoscopic mucosal resection (EMR) or endoscopic submucosal dissection (ESD). However, ER for the duodenum poses a high risk of complications, such as perforation and bleeding, due to the abundant blood vessels in the submucosal layer and thin muscle layer in the duodenum compared with the digestive tract^[4-7]. Specifically, patients with perforation undergo emergency

surgery in many cases, and it is unclear whether ER for duodenal tumors is appropriate. In this study, we investigated predictors of perforation after ER for duodenal neoplasms without a papillary portion.

MATERIALS AND METHODS

Patients

This study included a retrospective cohort of 54 patients (59 lesions) in a single center. We recruited patients (without ampullary duodenal tumors) who underwent ER between April 2003 and September 2014. These patients were preoperatively diagnosed with adenoma or carcinoma. The database included patient information such as age, sex, treatment method (EMR or ESD), prophylactic clipping (applied or not applied), and tumor characteristics, such as histological diagnosis (adenoma or carcinoma), location (pre-ampulla or post-ampulla), size (under 20 mm or over 20 mm), and type (polypoid or superficial). When a patient had multiple duodenal tumors, the largest lesion was included in the analysis. When a tumor was located on the opposite side of the ampulla of Vater, it was categorized as post-ampullary. The clinical features of complications (perforation and bleeding) were investigated.

All patients were provided with an explanation of the endoscopic procedure before treatment, including complications and alternative treatments, and written informed consent was obtained.

Endoscopic resection techniques

The endoscopic procedures were performed with a single-channel endoscope (GIF-Q240 or PCF-PQ260I; Olympus Medical Systems Co., Tokyo, Japan) or a double balloon sigmoid scope (EN-450T5/W; FUJIFILM, Saitama, Japan) by carbon dioxide insufflation. The choice of scope depended on the distance to the lesion.

EMR was indicated for small lesions (< 2 cm) or pedunculated lesions. Simple snarectomy was performed after the injection of 0.4% sodium hyaluronate solution (MucoUp; Johnson and Johnson K.K., Tokyo, Japan). The mucosa bulge is important for the safety of the procedure because the wall of the duodenum is thin. ESD was indicated for large lesions (≥ 2 cm) or flattened lesions. The ESD technique consisted of three steps. First, the periphery of the lesion was marked using a 2.0 mm short needle knife with a water jet function (Flush Knife, DK2618JB20; FUJIFILM, Saitama, Japan). Second, MucoUp was injected into the submucosal layer to achieve sufficient mucosal elevation. Third, a mucosal incision and submucosal dissection were performed with the Flush Knife (1.5 mm or 2.0 mm). Additionally, an electric current generator (VIO300D; ERBE, Tübingen, Germany) was used for hemostasis.

Prophylactic clipping using hemoclips (HX-110/610; Olympus Medical Systems Co.) was performed for mucosal defects after ER.

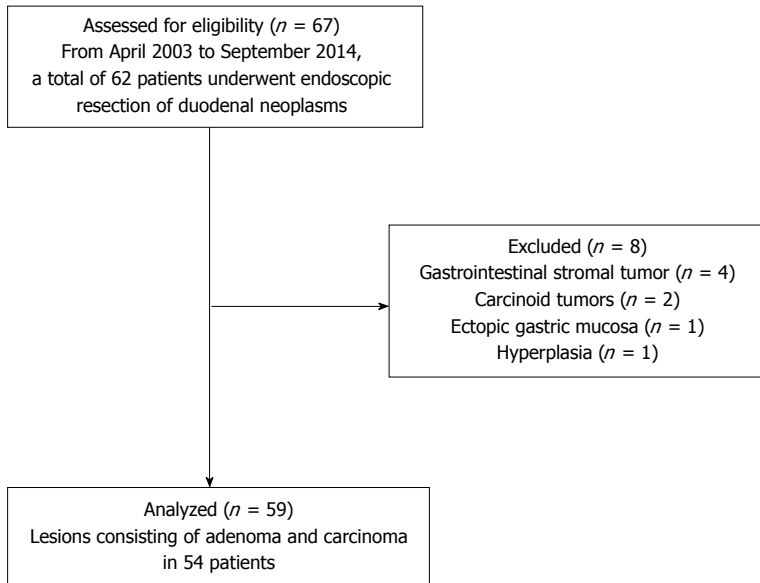


Figure 1 Flow diagram of patients with duodenal neoplasms treated by endoscopic resection.

Definition of complications

Intraoperative perforation was defined as the ability to recognize a perforation during the EMR and ESD procedures. Delayed perforation was defined as the inability to recognize a perforation during the EMR and ESD procedures, and patients had no symptoms immediately after the procedures. The diagnosis of delayed perforation is reached using enhanced computed tomography, which was performed for patients with abdominal pain. Delayed bleeding was defined in patients who required endoscopic hemostasis or transfusion after ER.

Statistical analysis

All statistical analyses were performed with the Statistical Package for the Social Sciences (SPSS 22.0 Package; SPSS Inc., Chicago, Illinois, United States). Continuous variables are expressed as the means and were analyzed using Student's *t* test. Categorical variables were compared with a χ^2 test or, if appropriate, Fisher's exact test. A probability value of $< 5\%$ was considered statistically significant.

RESULTS

From April 2003 to September 2014, a total of 62 patients underwent ER of duodenal tumors. Four cases with gastrointestinal stromal tumors, two cases with carcinoid tumors, one case with an ectopic gastric mucosa, and one case with a hyperplasia were excluded. As a result, 59 lesions due to adenoma and carcinoma in 54 patients were analyzed (Figure 1).

The 59 cases included 39 males and 20 females. The average age was 61.3 years (range 40-79 years). Thirty-eight lesions were diagnosed as adenoma, and 21 lesions were diagnosed as carcinoma. The accuracy of the preoperative biopsy was 96.6% (57/59). Thirty-five lesions were located in the pre-ampulla region,

and 24 were in the post-ampulla region. The average tumor size was 14.2 mm (95%CI: 11.6-16.8 mm). The macroscopic types included 12 polypoid and 47 superficial tumors. All lesions were confined to the mucosa. Thirty-six lesions underwent EMR. Piecemeal EMR was performed in four cases, and en-bloc EMR was performed in 32 cases. Among the piecemeal EMR cases, three lesions were removed in two pieces, and one lesion was removed in four pieces. Twenty-three lesions underwent ESD. Prophylactic clipping was applied in 46 patients.

Complications included perforation and bleeding (Table 1). Perforation occurred in eight (13%) patients (95%CI: 4.7%-22.6%). Four lesions were located in the pre-ampulla region, and four lesions were in the post-ampulla region. The mean size of lesion in cases of perforation was 22.9 mm, which was significantly different from the non-perforated group ($P < 0.05$). Intraoperative perforation occurred in six cases, and delayed perforation occurred two cases. Intraoperative perforation occurred in two EMR cases and ESD four cases. All cases in the EMR group and one case in the ESD group underwent conservative management after clipping. Three ESD cases required surgical management because they could not be repaired by clipping. Delayed perforation occurred in two ESD cases, and these patients required surgical management, even though both patients received prophylactic clipping. Perforation after ER was significantly associated with tumor size greater than 20 mm and ESD (Table 2). Bleeding occurred in two (3.4%) cases. One required endoscopic hemostasis, and the other patient received a transfusion after ER.

For the surgical procedures, three cases consisted of suturing and covering with omentum. Two patients underwent Billroth I anastomosis after pyloric ring resection and partial duodenum resection. No patients with perforation who required surgery had postoperative

Table 1 Clinical features and outcomes of patients with complications

Case	Age (yr)	Sex	Method	Complication	Clipping	Treatment	Hospital stay after ER (d)	Tumor characteristics		
								Location	Size (mm)	Type
1	65	M	EMR	IP	Possible	Conservative	7	Post-ampulla	17	Is
2	60	M	EMR	IP	Possible	Conservative	6	Post-ampulla	9	IIa
3	55	M	ESD	DP	Possible	Surgical	12	Post-ampulla	24	IIa
4	60	M	ESD	Bleeding	Possible	Transfusion	9	Pre-ampulla	20	IIa
5	67	M	EMR	Bleeding	Possible	Hemostasis	11	Pre-ampulla	55	Isp
6	40	M	ESD	IP	Impossible	Surgical	11	Pre-ampulla	20	IIa
7	55	M	ESD	IP	Possible	Conservative	18	Pre-ampulla	13	IIc
8	64	M	ESD	IP	Impossible	Surgical	16	Post-ampulla	30	IIa
9	44	F	ESD	IP	Impossible	Surgical	12	Pre-ampulla	30	IIa
10	72	F	ESD	DP	Possible	Surgical	15	Pre-ampulla	40	IIa

ER: Endoscopic resection; EMR: Endoscopic mucosal resection; ESD: Endoscopic submucosal dissection; IP: Intraoperative perforation; DP: Delayed perforation.

Table 2 Predictors of perforation

		Perforation		P value
		Did not occur	Occurred	
Sex	M	33	6	0.704
	F	18	2	
Histological diagnosis	Adenoma	33	5	1.000
	Carcinoma	18	3	
Tumor location	Pre-ampulla	31	4	0.704
	Post-ampulla	20	4	
Tumor size	Under 20 mm	42	3	0.014
	Over 20 mm	9	5	
Macroscopic type	Polypoid	11	1	0.482
	Superficial	40	7	
Resection method	EMR	34	2	0.047
	ESD	17	6	
Prophylactic clipping ¹	Not applied	10	0	1.000
	Applied	41	5	

¹Excluded three cases in which clipping were impossible due to perforation. EMR: Endoscopic mucosal resection; ESD: Endoscopic submucosal dissection; M: Male; F: Female.

complications. The patients were discharged at an average of 13.2 d after ER.

DISCUSSION

The reported incidence of malignant degeneration of duodenal tubulovillous polyps ranges from 35% to 85%, and accurately differentiating cancer from adenoma is difficult based on biopsy findings alone^[8]. Even if the histopathological examination of a biopsy specimen reveals an adenoma, it is possible to diagnose an adenoma as carcinoma after ER. In our study, the accuracy of preoperative biopsy was 96.6% (57/59). An ER should be performed if no metastasis is present in the lymph nodes and distant organs; however, an adenoma in the duodenum presents the possibility of carcinoma. Nagatani *et al.*^[9] reported that the incidence of lymph node metastasis was 0% in cases of intramucosal cancer and 5% in cases of submucosal cancer. Shinoda *et al.*^[10] reported no cases of lymph node metastasis among 273 cases of early duodenal cancer. Therefore, an early duodenal neoplasm can

be treated by ER, unless lymph node metastasis is revealed.

Some reports address ER for duodenal tumors, but none address standard therapy. The surgical methods include piecemeal EMR, *en-bloc* EMR, and ESD. Piecemeal EMR is possible in most tumors that exceed 20 mm, but commonly results in recurrence^[11,12]. *En-bloc* EMR can be performed for tumors exceeding 10 mm, although the resection margins may be histologically positive^[8]. Additionally, lesions larger than 20 mm cannot be safely removed *en-bloc* and closed by any currently available method^[4,6,13]. Therefore, EMR is not an ideal treatment for duodenal neoplasms larger than 20 mm. ESD can be performed for tumors exceeding 20 mm and achieves higher rates of *en-bloc* and curative resection than EMR^[5]. In one study, the negative margin rate was 100% for the lateral resection margin in ESD^[8]. However, ESD is associated with a higher rate of complications, such as perforation and bleeding, than EMR^[5]. Jung *et al.*^[14] reported that the perforation rates after ESD were very high (35.7%). For example, perforation rates associated with gastric ESD have been reported to be between 1.2% and 8.7%. Inoue *et al.*^[7] reported that the incidence of delayed perforation was significantly associated with post-ampullary tumor location and resection method (both piecemeal EMR and ESD). In our study, ER of tumors exceeding 20 mm and ESD presented a high risk of perforation. We examined EMR and ESD because piecemeal EMR was only performed in four cases, and therefore the statistical power was insufficient. Additionally, the results were not significantly different according to the tumor location.

As described earlier, ER of a duodenal tumor tends to cause complications (especially perforation), and appropriate treatments for perforation are lacking. Abundant blood vessels in the submucosal layer and a thin muscle layer in the duodenum are thought to be related to a high risk of complications. In addition, exposure of the duodenal wall to pancreatic juice and bile may increase the risk of delayed perforation^[5]. Taku *et al.*^[15] reported that conservative treatment is possible

when patients with perforation are stable. Krishna *et al.*^[16] reported that if perforation is suspected, abdominal CT should be performed to evaluate the indication for surgery. We have suggested that patients could be evaluated immediately by abdominal CT and receive emergency surgery, if necessary, when abdominal pain or high fever is present.

Prophylactic clipping is not sufficient to prevent perforation after ESD. Recently, a new device (the over-the-scope clip) has been developed for the prevention of perforation after ER, but this method requires further evaluation^[17]. We suggest that laparoscopic and endoscopic cooperative surgery (LECS) should be the therapeutic strategy for tumors exceeding 20 mm.

Toyonaga *et al.*^[18] reported the use of an endo linear stapler for wedge resection. However, it is not possible to appropriately resect tumors of the posterior duodenum using this method (*i.e.*, resection with an inappropriate margin or unnecessary resection of the duodenal wall)^[18,19]. Sato *et al.*^[20] reported LECS of a duodenal carcinoid tumor. Recently, others have reported laparoscopic local excision of a tumor followed by closure of the defect using a hand-sewn technique^[21-25]. We performed endoscopic total layer resection or ESD of a duodenal tumor followed by this procedure in three cases. All patients had no complications and were discharged in approximately one week. More cases should be evaluated in the future because the sample size of duodenal neoplasms was relatively small.

In conclusion, ESD for a duodenal tumor exceeding 20 mm may be associated with complications (especially perforation). ESD alone is not recommended for tumor treatment, and LECS should be considered as an alternative.

COMMENTS

Background

Duodenal neoplasms are relatively rare. Primary adenocarcinoma represents only 0.3% of all gastrointestinal tract malignant neoplasms and 0.042% of all malignant neoplasms. Therefore, no method of treatment for duodenal neoplasm has been established.

Research frontiers

Recently, cases of endoscopic resection (ER) for superficial neoplasms without lymph node metastasis have been reported. ER may consist of endoscopic mucosal resection or endoscopic submucosal dissection (ESD). However, ER for the duodenum poses a high risk of complications. Patients with perforation undergo emergency surgery in many cases. It is unclear whether ER for duodenal tumors is appropriate.

Innovations and breakthroughs

The authors investigated predictors of perforation after ER for duodenal neoplasms without a papillary portion.

Applications

ESD for a duodenal tumor exceeding 20 mm may be associated with complications (especially perforation). ESD alone is not recommended for tumor treatment, and LECS should be considered as an alternative.

Peer-review

This paper presents a unique comparison of endoscopic mucosal dissection

with endoscopic submucosal dissection in the management of non-ampullary duodenal tumours.

REFERENCES

- 1 Jepsen JM, Persson M, Jakobsen NO, Christiansen T, Skoubo-Kristensen E, Funch-Jensen P, Kruse A, Thommesen P. Prospective study of prevalence and endoscopic and histopathologic characteristics of duodenal polyps in patients submitted to upper endoscopy. *Scand J Gastroenterol* 1994; **29**: 483-487 [PMID: 8079103 DOI: 10.3109/00365529409092458]
- 2 Moss WM, McCart PM, Juler G, Miller DR. Primary adenocarcinoma of the duodenum. *Arch Surg* 1974; **108**: 805-807 [PMID: 4545398 DOI: 10.1001/archsurg.1974.01350300047013]
- 3 Spira IA, Ghazi A, Wolff WI. Primary adenocarcinoma of the duodenum. *Cancer* 1977; **39**: 1721-1726 [PMID: 322840 DOI: 10.1002/1097-0142(197704)39:4<1721::AID-CNCR2820390450>3.0.CO;2-M]
- 4 Alexander S, Bourke MJ, Williams SJ, Bailey A, Co J. EMR of large, sessile, sporadic nonampullary duodenal adenomas: technical aspects and long-term outcome (with videos). *Gastrointest Endosc* 2009; **69**: 66-73 [PMID: 18725157 DOI: 10.1016/j.gie.2008.04.061]
- 5 Honda T, Yamamoto H, Osawa H, Yoshizawa M, Nakano H, Sunada K, Hanatsuka K, Sugano K. Endoscopic submucosal dissection for superficial duodenal neoplasms. *Dig Endosc* 2009; **21**: 270-274 [PMID: 19961529 DOI: 10.1111/j.1443-1661.2009.00908.x]
- 6 Fanning SB, Bourke MJ, Williams SJ, Chung A, Kariyawasam VC. Giant laterally spreading tumors of the duodenum: endoscopic resection outcomes, limitations, and caveats. *Gastrointest Endosc* 2012; **75**: 805-812 [PMID: 22305507 DOI: 10.1016/j.gie.2011.11.038]
- 7 Inoue T, Uedo N, Yamashina T, Yamamoto S, Hanaoka N, Takeuchi Y, Higashino K, Ishihara R, Iishi H, Tatsuta M, Takahashi H, Eguchi H, Ohigashi H. Delayed perforation: a hazardous complication of endoscopic resection for non-ampullary duodenal neoplasm. *Dig Endosc* 2014; **26**: 220-227 [PMID: 23621427 DOI: 10.1111/den.12104]
- 8 Endo M, Abiko Y, Oana S, Kudara N, Chiba T, Suzuki K, Koizuka H, Uesugi N, Sugai T. Usefulness of endoscopic treatment for duodenal adenoma. *Dig Endosc* 2010; **22**: 360-365 [PMID: 21175499 DOI: 10.1111/j.1443-1661.2010.01014.x]
- 9 Nagatani K, Takkekoshi T, Baba Y, Kaku S, Koizumi K, Fujii A, Ogata E, Ohta H, Nishi M, Kato Y, Yanagisawa A. Indications for endoscopic treatment of early duodenal cancer: Based on cases reported in the literature. *Endosc Digest* 1993; **7**: 969-976
- 10 Shinoda M, Makino A, Wada M, Kabeshima Y, Takahashi T, Kawakubo H, Shito M, Sugiura H, Omori T. Successful endoscopic submucosal dissection for mucosal cancer of the duodenum. *Dig Endosc* 2010; **22**: 49-52 [PMID: 20078665 DOI: 10.1111/j.1443-1661.2009.00917.x]
- 11 Apel D, Jakobs R, Spiethoff A, Riemann JF. Follow-up after endoscopic snare resection of duodenal adenomas. *Endoscopy* 2005; **37**: 444-448 [PMID: 15844023 DOI: 10.1055/s-2005-861287]
- 12 Lépilliez V, Chemaly M, Ponchon T, Napoleon B, Saurin JC. Endoscopic resection of sporadic duodenal adenomas: an efficient technique with a substantial risk of delayed bleeding. *Endoscopy* 2008; **40**: 806-810 [PMID: 18828076 DOI: 10.1055/s-2008-1077619]
- 13 Ahmad NA, Kochman ML, Long WB, Furth EE, Ginsberg GG. Efficacy, safety, and clinical outcomes of endoscopic mucosal resection: a study of 101 cases. *Gastrointest Endosc* 2002; **55**: 390-396 [PMID: 11868015 DOI: 10.1067/mge.2002.121881]
- 14 Jung JH, Choi KD, Ahn JY, Lee JH, Jung HY, Choi KS, Lee GH, Song HJ, Kim DH, Kim MY, Bae SE, Kim JH. Endoscopic submucosal dissection for sessile, nonampullary duodenal adenomas. *Endoscopy* 2013; **45**: 133-135 [PMID: 23364841 DOI: 10.1055/s-0032-1326178]
- 15 Taku K, Sano Y, Fu KI, Saito Y, Matsuda T, Uraoka T, Yoshino T, Yamaguchi Y, Fujita M, Hattori S, Ishikawa T, Saito D, Fujii T, Kaneko E, Yoshida S. Iatrogenic perforation associated with therapeutic colonoscopy: a multicenter study in Japan. *J Gastroenterol Hepatol* 2007; **22**: 1409-1414 [PMID: 17593224 DOI: 10.1111/

- j.1440-1746.2007.05022.x]
- 16 **Krishna RP**, Singh RK, Behari A, Kumar A, Saxena R, Kapoor VK. Post-endoscopic retrograde cholangiopancreatography perforation managed by surgery or percutaneous drainage. *Surg Today* 2011; **41**: 660-666 [PMID: 21533938 DOI: 10.1007/s00595-009-4331-z]
 - 17 **Gubler C**, Bauerfeind P. Endoscopic closure of iatrogenic gastrointestinal tract perforations with the over-the-scope clip. *Digestion* 2012; **85**: 302-307 [PMID: 22614286 DOI: 10.1159/000336509]
 - 18 **Toyonaga T**, Nakamura K, Araki Y, Shimura H, Tanaka M. Laparoscopic treatment of duodenal carcinoid tumor. Wedge resection of the duodenal bulb under endoscopic control. *Surg Endosc* 1998; **12**: 1085-1087 [PMID: 9685548 DOI: 10.1007/s004649900786]
 - 19 **Matsui H**, Okamoto Y, Ishii A, Ishizu K, Kondoh Y, Aoki J, Yamazaki H, Ogoshi K, Makuuchi H. Endoscopy-assisted totally laparoscopic resection of a submucosal tumor of the duodenum. *Tokai J Exp Clin Med* 2008; **33**: 100-104 [PMID: 21318976]
 - 20 **Sato T**, Fukunaga T, Ohyama S, Ueno M, Oya M, Yamamoto J, Saiura A, Yamaguchi T, Muto T, Kato Y. Endoscopic total layer resection with laparoscopic sentinel node dissection and defect closure for duodenal carcinoid. *Hepatogastroenterology* 2005; **52**: 678-679 [PMID: 15966180]
 - 21 **Yi NJ**, Kim YW, Han HS, Fleischer GD. Duodenal polypectomy of Brunner's gland hyperplasia using a novel laparoscopic technique. A case report. *Surg Endosc* 2002; **16**: 1493 [PMID: 12140625 DOI: 10.1007/s00464-002-4501-1]
 - 22 **Lee JH**, Han HS, Kim YW, Min SK, Lee HK. Laparoscopic wedge resection with handsewn closure for gastroduodenal tumors. *J Laparoendosc Adv Surg Tech A* 2003; **13**: 349-353 [PMID: 14733696 DOI: 10.1089/109264203322656397]
 - 23 **Bowers SP**, Smith CD. Laparoscopic resection of posterior duodenal bulb carcinoid tumor. *Am Surg* 2003; **69**: 792-795 [PMID: 14509329]
 - 24 **Orsenigo E**, Di Palo S, Vignali A, Staudacher C. Laparoscopic excision of duodenal schwannoma. *Surg Endosc* 2007; **21**: 1454-1456 [PMID: 17177083 DOI: 10.1007/s00464-006-9073-z]
 - 25 **Kyuno D**, Ohno K, Katsuki S, Fujita T, Konno A, Murakami T, Waga E, Takanashi K, Kitaoka K, Komatsu Y, Sasaki K, Hirata K. Laparoscopic-endoscopic cooperative surgery is a safe and effective treatment for superficial nonampullary duodenal tumors. *Asian J Endosc Surg* 2015; **8**: 461-464 [PMID: 26708586 DOI: 10.1111/ases.12211]

P- Reviewer: Dumitrascu DL, Tovey FI **S- Editor:** Kong JX
L- Editor: A **E- Editor:** Wu HL





Published by **Baishideng Publishing Group Inc**
7901 Stoneridge Drive, Suite 501, Pleasanton, CA 94588, USA
Telephone: +1-925-223-8242
Fax: +1-925-223-8243
E-mail: bpgoffice@wjgnet.com
Help Desk: <http://www.f6publishing.com/helpdesk>
<http://www.wjgnet.com>

