


World Journal of *Gastrointestinal Surgery*

World J Gastrointest Surg 2018 August 27; 10(5): 49-56





MINIREVIEWS

- 49 Approach to pseudomyxoma peritonei

Rizvi SA, Syed W, Shergill R

Contents

World Journal of Gastrointestinal Surgery
Volume 10 Number 5 August 27, 2018

ABOUT COVER

Ying Chai, MD, Chief Doctor, Professor, Surgeon, Chair of Thoracic Surgery, Second Affiliated Hospital, Zhejiang University School of Medicine, Zhejiang University, Hangzhou 310009, Zhejiang Province, China

AIM AND SCOPE

World Journal of Gastrointestinal Surgery (*World J Gastrointest Surg*, *WJGS*, online ISSN 1948-9366, DOI: 10.4240) is a peer-reviewed open access academic journal that aims to guide clinical practice and improve diagnostic and therapeutic skills of clinicians.

WJGS covers topics concerning micro-invasive surgery; laparoscopy; hepatic, biliary, pancreatic and splenic surgery; surgical nutrition; portal hypertension, as well as associated subjects. The current columns of *WJGS* include editorial, frontier, diagnostic advances, therapeutics advances, field of vision, mini-reviews, review, topic highlight, medical ethics, original articles, case report, clinical case conference (Clinicopathological conference), and autobiography. Priority publication will be given to articles concerning diagnosis and treatment of gastrointestinal surgery diseases. The following aspects are covered: Clinical diagnosis, laboratory diagnosis, differential diagnosis, imaging tests, pathological diagnosis, molecular biological diagnosis, immunological diagnosis, genetic diagnosis, functional diagnostics, and physical diagnosis; and comprehensive therapy, drug therapy, surgical therapy, interventional treatment, minimally invasive therapy, and robot-assisted therapy.

We encourage authors to submit their manuscripts to *WJGS*. We will give priority to manuscripts that are supported by major national and international foundations and those that are of great basic and clinical significance.

INDEXING/ABSTRACTING

World Journal of Gastrointestinal Surgery is now abstracted and indexed in Emerging Sources Citation Index (Web of Science), PubMed, PubMed Central, China National Knowledge Infrastructure (CNKI), and Superstar Journals Database.

EDITORS FOR THIS ISSUE

Responsible Assistant Editor: *Xiang Li*
Responsible Electronic Editor: *Han Song*
Proofing Editor-in-Chief: *Lian-Sheng Ma*

Responsible Science Editor: *Fang-Fang Ji*
Proofing Editorial Office Director: *Jin-Lei Wang*

NAME OF JOURNAL

World Journal of Gastrointestinal Surgery

ISSN

ISSN 1948-9366 (online)

LAUNCH DATE

November 30, 2009

FREQUENCY

Monthly

EDITORIAL BOARD MEMBERS

All editorial board members resources online at <http://www.wjgnet.com/1948-9366/editorialboard.htm>

EDITORIAL OFFICE

Jin-Lei Wang, Director
World Journal of Gastrointestinal Surgery
Baishideng Publishing Group Inc
7901 Stoneridge Drive, Suite 501, Pleasanton, CA 94588, USA

Telephone: +1-925-2238242

Fax: +1-925-2238243

E-mail: editorialoffice@wjgnet.com

Help Desk: <http://www.f0publishing.com/helpdesk>

<http://www.wjgnet.com>

PUBLISHER

Baishideng Publishing Group Inc
7901 Stoneridge Drive, Suite 501,

Pleasanton, CA 94588, USA

Telephone: +1-925-2238242

Fax: +1-925-2238243

E-mail: bpgoffice@wjgnet.com

Help Desk: <http://www.f0publishing.com/helpdesk>

<http://www.wjgnet.com>

PUBLICATION DATE

August 27, 2018

COPYRIGHT

© 2018 Baishideng Publishing Group Inc. Articles pub-

lished by this Open-Access journal are distributed under the terms of the Creative Commons Attribution Non-commercial License, which permits use, distribution, and reproduction in any medium, provided the original work is properly cited, the use is non commercial and is otherwise in compliance with the license.

SPECIAL STATEMENT

All articles published in journals owned by the Baishideng Publishing Group (BPG) represent the views and opinions of their authors, and not the views, opinions or policies of the BPG, except where otherwise explicitly indicated.

INSTRUCTIONS TO AUTHORS

<http://www.wjgnet.com/bpg/gerinfo/204>

ONLINE SUBMISSION

<http://www.wjgnet.com/esps/>

Approach to pseudomyxoma peritonei

Syed Ali Rizvi, Wajahat Syed, Ravi Shergill

Syed Ali Rizvi, Wajahat Syed, Undergraduate Medicine, McMaster University, Hamilton, ON L8S 4L8, Canada

Ravi Shergill, Department of Radiology, McMaster University, Hamilton, ON L8S 4L8, Canada

ORCID number: Syed Ali Rizvi (0000-0001-8668-3436); Wajahat Syed (0000-0002-6272-6355); Ravi Shergill (0000-0001-5099-6836).

Author contributions: Rizvi SA drafted the initial manuscript, conceived of the idea, and performed analysis and interpretation of the data; Syed W and Shergill R assisted with data analysis and making critical revisions related to important intellectual content of the manuscript.

Conflict-of-interest statement: There is no conflict of interest associated with any of the authors who contributed their efforts in this manuscript.

Open-Access: This article is an open-access article which was selected by an in-house editor and fully peer-reviewed by external reviewers. It is distributed in accordance with the Creative Commons Attribution Non Commercial (CC BY-NC 4.0) license, which permits others to distribute, remix, adapt, build upon this work non-commercially, and license their derivative works on different terms, provided the original work is properly cited and the use is non-commercial. See: <http://creativecommons.org/licenses/by-nc/4.0/>

Manuscript source: Unsolicited manuscript

Correspondence to: Syed Ali Rizvi, BSc, Medical Student, Undergraduate Medicine, McMaster University, 1280 Main Street West, Hamilton, ON L8S 4L8, Canada. ali.rizvi@medportal.ca
Telephone: +1-647-7722061

Received: June 27, 2018

Peer-review started: June 30, 2018

First decision: July 8, 2018

Revised: August 1, 2018

Accepted: August 6, 2018

Article in press: August 6, 2018

Published online: August 27, 2018

Abstract

Pseudomyxoma peritonei (PMP) is a mucinous tumour of the appendix that spreads into the peritoneal cavity in the form of gelatinous deposits. The incidence of PMP is believed to be approximately 1-3 out of a million per year. Nonetheless, due to its indolent nature, it is usually discovered at an advanced stage and severely impacts quality of life. Curative treatment for PMP is complete cytoreductive surgery (CRS) with hyperthermic intraperitoneal chemotherapy (HIPEC). An extensive literature review was conducted searching EMBASE, MEDLINE, PubMed, and Google Scholar databases for PMP in aims to delineate a clinical approach to diagnosis and treatment. Literature was limited to the years 2007-2018. We found the 5-year overall survival with CRS and HIPEC estimated to be between 23%-82% and rates of major complications as high as 24%. Therefore, it is important to appropriately stage and select patients that should undergo CRS with HIPEC. Modalities like MDCT radiological scores have been shown to have sensitivity and specificity of 94% and 81%, respectively, in being able to predict resectability and survival. Despite treatment, the disease often recurs. Tumor markers have significant potential for establishing prognosis pre-operatively, and this paper will review the most recent evidence in support of them.

Key words: Pseudomyxoma peritonei; Cytoreductive surgery; Hyperthermic intraperitoneal chemotherapy; Mucocoele; Appendix

© **The Author(s) 2018.** Published by Baishideng Publishing Group Inc. All rights reserved.

Core tip: This paper highlights the most recent evidence in the clinical approach to pseudomyxoma peritonei. Diagnosis, treatment, complications of treatment, overall survival, and post-operative follow-up will be explored.

Rizvi SA, Syed W, Shergill R. Approach to pseudomyxoma

peritonei. *World J Gastrointest Surg* 2018; 10(5): 49-56 Available from: URL: <http://www.wjgnet.com/1948-9366/full/v10/i5/49.htm> DOI: <http://dx.doi.org/10.4240/wjgs.v10.i5.49>

INTRODUCTION

Although neoplasms of the appendix are rare, they carry a significant disease burden. Upwards of 58% of malignant tumors arising from the appendix are mucinous in origin^[1]. When these mucinous tumours are able to penetrate through the appendicular wall and spread into the peritoneal cavity in the form of gelatinous deposits, the condition is termed pseudomyxoma peritonei (PMP)^[1]. The incidence of PMP is believed to be approximately 1-3 out of a million. Nonetheless, due to its indolent nature, it is usually discovered at an advanced stage and severely impacts quality of life^[2]. PMP is targeted *via* a multidisciplinary approach involving surgical oncologists, pathologists, radiation and medical oncologists. Curative treatment for PMP is complete cytoreductive surgery (CRS), with hyperthermic intraperitoneal chemotherapy (HIPEC)^[3]. However, this procedure is not without its significant post-operative morbidity and mortality. Recent studies have developed preoperative tools to assess for appropriate surgical candidates who will benefit from this treatment. This review will outline an approach to diagnosis, pre-operative assessment, treatment, and post-operative follow-up for PMP.

LITERATURE SEARCH STRATEGY

An extensive literature review was conducted searching EMBASE, MEDLINE, PubMed, and Google Scholar databases using the following key words: "pseudomyxoma peritonei", "cytoreductive surgery", "hyperthermic intraperitoneal chemotherapy", "mucocoele", and "appendix." Papers were limited to the years 2007-2018. The reference lists of all retrieved articles were manually reviewed to further identify potentially relevant studies.

PATHOGENESIS

The pathological process of PMP starts similar to most primary tumors of the alimentary tract^[1]. Neoplastic transformation of the goblet cells results in the formation of a primary mucinous tumor. As mucin levels increase within the mucocoele, there is eventual rupture^[2]. The rupturing of the mucocoele is the initiating event that leads to the development of PMP^[4]. The rupture allows tumor cells to access the peritoneal cavity, and given their lack of cell adhesion molecules, they passively circulate with ease. This seeding of tumor cells eventually leads to bulky mucinous deposits all along the abdominal cavity, which causes an increase in intraabdominal pressure. This pressure can lead to compression of visceral organs and even bowel obstruction. PMP deposits are consistently seen within the greater omentum, lesser omentum, and

beneath the right hemi-diaphragm^[4]. However, the tumor is absent on the peritoneal surfaces of the intestine and mesentery due to peristaltic activity.

DISEASE BURDEN

The exact incidence of the disease is unknown but has been estimated at 1-3 out of a million, per year^[5].

CLINICAL PRESENTATION

PMP is typically diagnosed between the ages of 40-55, and is often found incidentally in patients undergoing laparotomy, laparoscopy, or imaging for other medical conditions. Due to its indolent nature and non-specific symptoms, most are found with advanced disease. The clinical presentation of the disease is dependent on the progression of the disease, as is the prognosis^[6]. Localized disease typically presents with appendicitis-like symptoms or a pelvic mass due to mucinous deposits on adjacent organs. More advanced disease presents with abdominal distension, bowel obstruction, and ascites. The classic sign termed "jelly belly" is an increase in abdominal girth caused by an accumulation of gelatinous ascites. Figure 1 demonstrates mucinous ascites on computed tomography (CT). This is often in the late stage when most of the abdomen is filled with tumour and mucinous ascites. Often the chief complaint is a new-onset hernia due to increased intra-abdominal pressure^[7].

HISTOLOGY

In 1995, Ronnett *et al*^[8] attempted to correlate the histology of PMP with prognosis. Their classification scheme is summarized in Table 1. Diffuse peritoneal adenomucinous (DPAM) is classic PMP with mucinous ascites on the surface of the peritoneum without invasion and has an indolent course. Peritoneal mucinous adenocarcinoma (PMCA) represents a class with a higher percentage of malignant cells, and thus has a worse prognosis. The third group, PMCA with intermediate features (PMCA-I), is described as a hybrid between DPAM and PMCA and has features of both^[8]. Figure 2 depicts histology of the three types of PMP in further detail.

Misdraji *et al*^[9] found this classification to be correlated with and representative of the disease prognosis. Ninety-six percent of those with DPAM were found to be disease-free 52 mo after treatment, whereas only 33% of those with features of PMCA were disease-free^[9]. They concluded that tumors limited to the appendicular wall or mesoappendix are curable with appendectomy (T1). However, anything beyond the muscularis propria is at risk for dissemination and the development of PMP.

To further simplify classification, the World Health Organization proposed a classification scheme based on histogenesis and clinical behavior. The WHO classification divides PMP into two groups^[10]: low and high grade.

Table 1 Classification of pseudomyxoma peritonei

System	Classification
Ronnett <i>et al</i> ^[8]	DPAM: PMP with mucinous ascites on the surface of peritoneum. No invasion. Indolent course. Best prognosis PMCA: Higher percentage of malignant cells. Poorer prognosis PMCA-I: Intermediate hybrid between DPAM and PMCA
WHO	Low grade: Mucin pools with low grade dysplasia. Eighty-three percent of five-year OS High Grade: Mucin pools with high grade dysplasia. More likely for rupture and spillage into the peritoneal cavity. Sixty-eight percent of five-year OS

PMP: Pseudomyxoma peritonei; DPAM: Diffuse peritoneal adenomucinosis; PMCA: Peritoneal mucinous carcinomatosis; PMCA-I: Peritoneal mucinous carcinomatosis-intermediate; OS: Overall survival; WHO: World Health Organization.

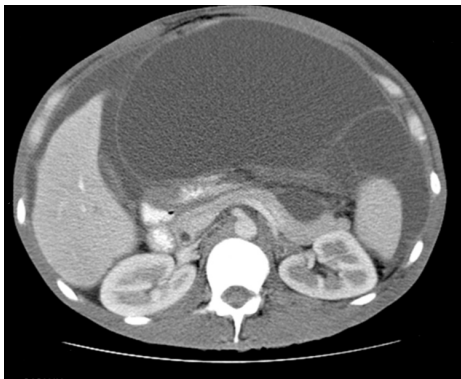


Figure 1 Mucinous ascites on computed tomography^[24]. This computed tomography scan demonstrates mucinous ascites. We also see characteristic findings of pseudomyxoma peritonei: Scalloping of the liver and spleen.

DIAGNOSIS

CT is the primary mechanism of diagnosis for PMP. CT is able to identify an appendiceal mucocoele in the early course of this disease. This is often seen as a calcified mass near the ileocecal valve^[11]. Progressive disease is seen on CT as a characteristic pattern of high density mucinous patches with bowel and mesenteric sparing. Figure 3 demonstrates PMP on CT. What is interesting to note is that the primary tumor is rarely visualized at this stage^[11]. CT is as good as magnetic resonance imaging (MRI) in describing both location and morphology of the mucocoele^[11]. However, MRI is more sensitive at identifying whether the mucocoele is mucin- or fluid-filled^[11].

The diagnostic challenge with PMP is being able to identify resectable versus unresectable disease. CRS with HIPEC is associated with significant postoperative complications, and mortality is estimated to be 15%-20%^[3]. It is therefore imperative that we select only appropriate candidates for surgery. A study published by Bouquot *et al*^[3] aimed to create a preoperative score based on CT findings that would assess the extent of the disease and predict resectability. They suggest that perihepatic involvement, especially involvement of the hepatic pedicle, lesser omentum, and vena cava are associated with incomplete CRS. The MDCT score is a simple preoperative radiographic score that measures tumor burden in the perihepatic region and is able to predict resectability and survival in PMP patients. The

sensitivity and specificity of this score is 94% and 81% respectively, although it requires further study and refinement. It is evident by this study that thickness of the tumour burden and involvement of the right upper quadrant on CT are poor prognostic factors and should be taken into consideration before committing to CRS and HIPEC.

Despite treatment with CRS combined with HIPEC, disease often recurs. Tumor markers have been found to have prognostic value in PMP. Although not diagnostic, they can be used like CEA in colorectal carcinoma in post-operative follow-up to monitor for recurrence.

Taflampas *et al*^[12] analyzed recurrence and survival correlated with pre-operative levels of CEA, CA-125, and CA19-9 in 519 patients who underwent CRS with HIPEC for PMP. They found that overall survival (OS) and disease-free survival were lower when preoperative levels of all three tumor markers were elevated.

Rangarajan *et al*^[13] conducted a retrospective study looking at pre-operative inflammatory markers in predicting survival in patients undergoing CRS and HIPEC for PMP. Their study included 699 patients who underwent CRS and HIPEC between 1994 and 2015 for PMP. They found that patients with an elevated neutrophil-lymphocyte ratio (NLR, an inflammatory marker) had poor long-term survival. As NLR is both inexpensive and easily calculated, it has strong potential to be used in determining prognosis for patients with PMP.

Additionally, Bong *et al*^[14] conducted a study aimed at examining the prognostic significance of inflammatory markers in patients undergoing CRS/HIPEC for colorectal peritoneal carcinomatosis. Although distinct from PMP, the findings of this study illustrate the effectiveness of CRS/HIPEC for peritoneal carcinomatosis. They looked at NLR, platelet-lymphocyte ratio (PLR) and CEA. Their study found that preoperative levels of PLR and CEA were significant prognostic factors for peritoneal carcinomatosis for patients undergoing CRS/HIPEC^[11]. An elevated PLR was associated with shorter OS. Furthermore, there is increasing evidence that suggests platelets facilitate tumor development by promoting tumor cell proliferation, angiogenesis, and metastasis^[11]. Furthermore, Di Fabio *et al*^[15] found that there was a significant decrease in CEA levels post-operatively after significant tumor burden had been removed *via* CRS and HIPEC.

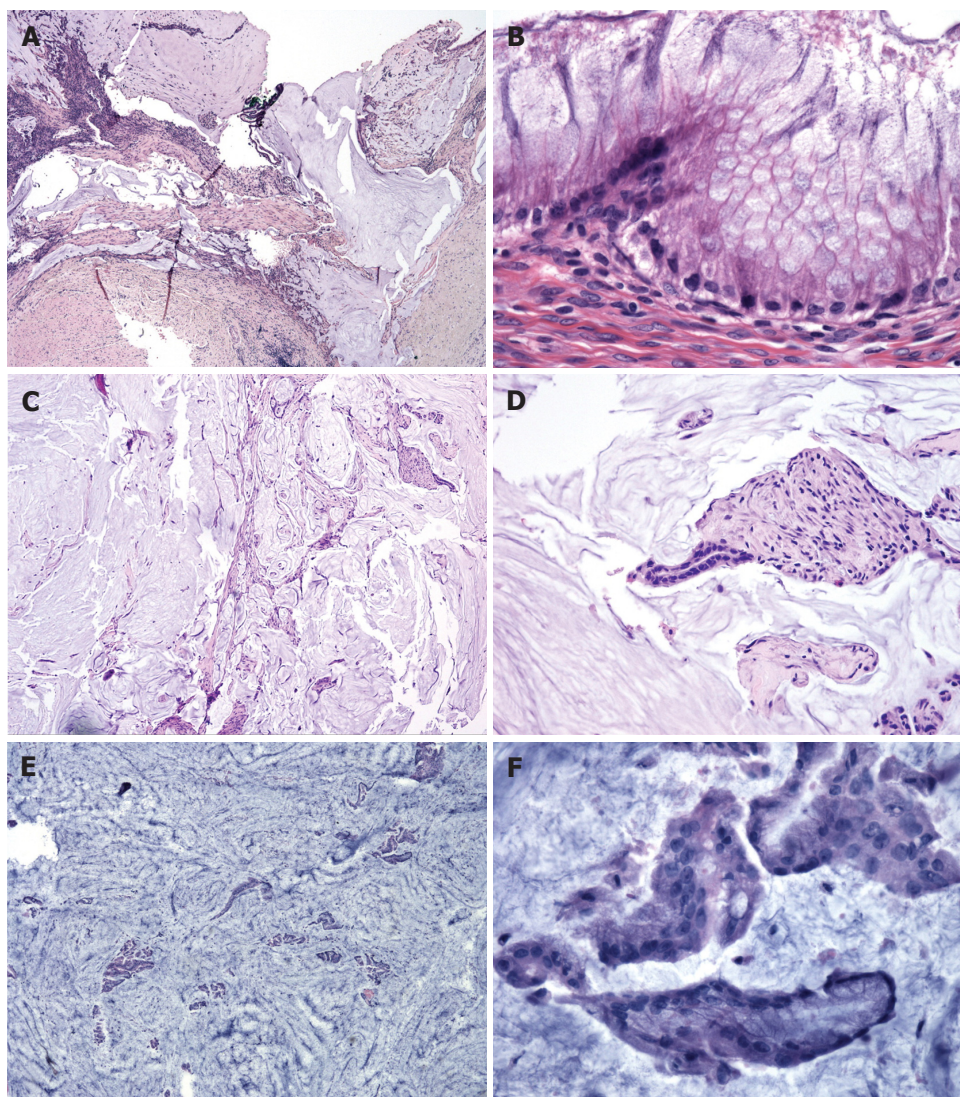


Figure 2 Histological classification of pseudomyxoma peritonei^[25]. This figure highlights some of the characteristic findings in the different histological types of pseudomyxoma peritonei. A, B: Disseminated peritoneal adenomucinosis (DPAM) is demonstrated in (A and B) with paucicellular mucin pools (A) and scant strips of low-grade neoplastic epithelium (B); C, D: Peritoneal mucinous carcinomatosis-intermediate (PMCA-I) is demonstrated in (C and D). PMCA-I is less cellular than PMCA, but the degree of atypia exceeds that of DPAM (D); E, F: Highlight PMCA, with mucin cells with abundant epithelium (E) and malignant cytological features (F).

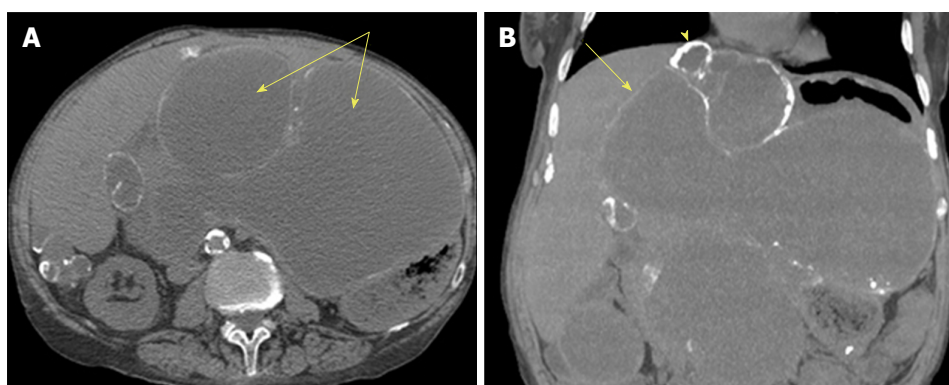


Figure 3 Computed tomography of pseudomyxoma peritonei^[26]. This is an axial computed tomography scan. A: Cystic accumulations of mucus (arrows) surrounded by calcified rims; B: A coronal reconstruction representing cystic accumulations in the upper abdomen and the liver.

In summary, tumor markers have significant potential in establishing prognosis pre-operatively, and with

further investigation and research, may eventually be used for diagnostic purposes.

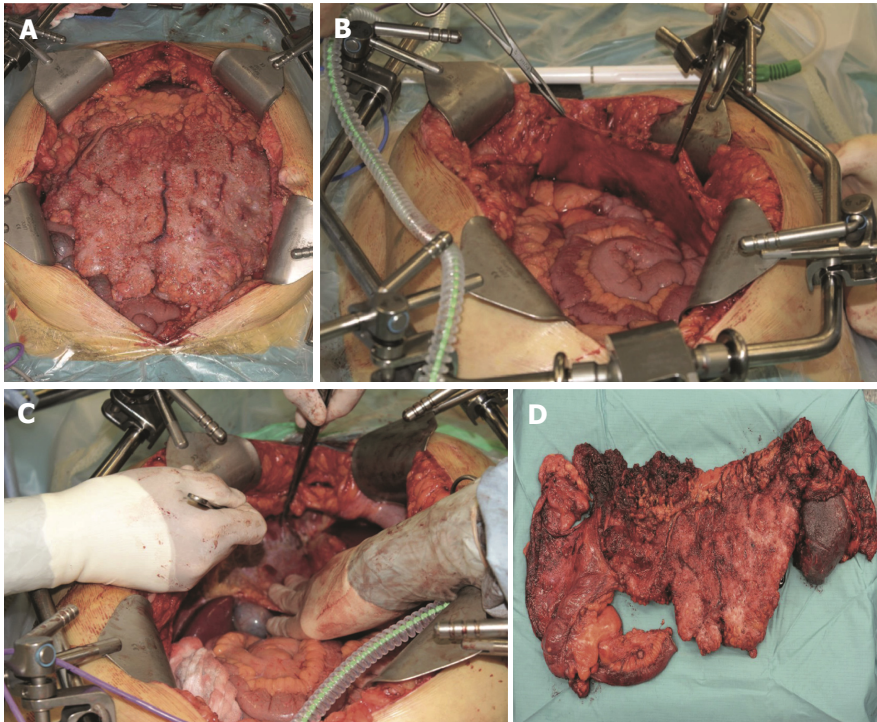


Figure 4 Intraoperative pictures of cytoreductive surgery^[11]. This is a figure depicting various stages of cytoreductive surgery. A: A view of a pseudomyxoma patient's abdominal cavity immediately after laparotomy; B: Stripping of the right anterior peritoneum; C: Depicts stripping of the right subphrenic peritoneum; D: An image of the resected terminal ileum, colon, and spleen affected by pseudomyxoma peritonei.

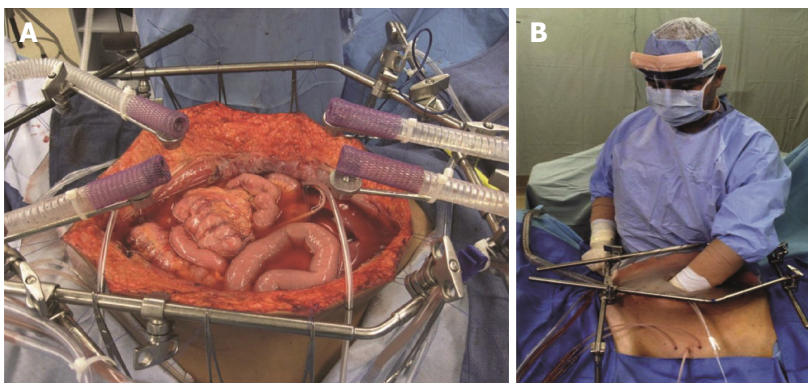


Figure 5 Hyperthermic intraperitoneal chemotherapy after complete cytoreductive surgery^[27]. This figure demonstrates the hyperthermic intraperitoneal chemotherapy (HIPEC) setup after cytoreductive surgery has been completed. A: HIPEC administered using an open technique; B: After placement of tubes, drains and temperature probes, the skin edges are elevated onto the rim of the self-retaining retractor using a running suture. A plastic sheet covers the abdomen to prevent splashing and loss of chemotherapy agent. A slit in the sheet allows the surgeon to access the abdominal cavity. Continuous mixing by the surgeon ensures all abdominal surfaces are uniformly coated with doses of heated chemotherapy.

Table 2 Cytoreductive score

Score	Tumor burden
CC0	No residual tumor
CC1	Residual tumor < 2.5 mm
CC2	Residual tumor between 2.6 mm and 2.5 cm
CC3	Residual tumor > 2.5 cm

TREATMENT AND OUTCOME

Initially described by Sugarbaker *et al.*^[16] in 1995, CRS consists of six resections that aim to decrease tumor

burden from peritoneal surfaces. The resections include: greater omentectomy-splenectomy, left upper quadrant peritonectomy, right upper quadrant peritonectomy, lesser omentectomy-cholecystectomy, pelvic peritonectomy with resection of the sigmoid colon, and antrectomy^[16]. The current practice is to follow CRS with HIPEC (Figures 4 and 5).

The goal of CRS is to remove all visible tumor. Thus, the amount of tumor burden resected is used to score the effectiveness of the procedure. Table 2 depicts the scoring system^[17]. The importance of this grading system is that tumors larger than 2.5 cm, if not resected during

Table 3 Five-year overall survival

Ref.	Year	Type of study	No. of patients	Five-year OS (%)
Baratti <i>et al</i> ^[27]	2018	Retrospective	265	74.5
Pallas <i>et al</i> ^[28]	2017	Retrospective	100	43
Chia <i>et al</i> ^[29]	2016	Systematic Review	NA	13-23
Moran <i>et al</i> ^[30]	2015	Retrospective	956	84
Gupta <i>et al</i> ^[10]	2014	Retrospective	791	68-83
Chua <i>et al</i> ^[31]	2012	Retrospective	2020	82
Smeenk <i>et al</i> ^[20]	2007	Retrospective	103	59.5

NA: Not available; OS: Overall survival.

Table 4 Complications of complete cytoreductive surgery/hyperthermic intraperitoneal chemotherapy

Ref.	Year	Type of study	No. of patients	Complication(s)
Hamilton <i>et al</i> ^[32]	2016	Retrospective	42	Intrabdominal abscess: 9.5%
				Bleeding: 9.1%
Chua <i>et al</i> ^[18]	2012	Retrospective	2020	Pleural effusion: 7.1%
				Anastomotic leak: 7.1%
Chua <i>et al</i> ^[31]	2009	Systematic Review	NA	Renal failure: 2.4%
				Post-op mortality 2%
Chua <i>et al</i> ^[31]	2009	Systematic Review	NA	Major complications grade III/IV: 24%
				Recurrence: 19%
Chua <i>et al</i> ^[31]	2009	Systematic Review	NA	Hematological toxicity: 28%
				Reoperation rates: 23%
Chua <i>et al</i> ^[31]	2009	Systematic Review	NA	Sepsis: 14%
				Fistula: 23%
Chua <i>et al</i> ^[31]	2009	Systematic Review	NA	Abscess: 37%
				Ileus: 86%
Chua <i>et al</i> ^[31]	2009	Systematic Review	NA	Perforation: 10%
				Anastomotic leak: 9%
Chua <i>et al</i> ^[31]	2009	Systematic Review	NA	DVT/PE: 9%
				Renal insufficiency: 7%

NA: Not available; DVT/PE: Deep vein thrombosis/pulmonary embolism.

CRS, will not be eliminated by HIPEC^[18]. Resections are deemed complete if surgeons are able to achieve CC0 or CC1.

Once the abdominal cavity has been entered and CRS completed, the surgeon has an open abdomen. The coliseum technique describes elevating the edges of the abdomen with retractors to essentially create a barrel. The chemotherapeutic agent most often used is mitomycin C (MMC). It is heated to 41-42 degrees Celsius outside of the abdomen. Once the target temperature is achieved, the abdomen is manually perfused by the surgeon or assisted for 90 min. After 90 min, MMC is flushed out from the abdomen and the abdomen is washed with normal saline^[19].

The rationale for heating the chemotherapy was described by Sugarbaker *et al*^[17]. In essence, it increases tissue penetration, cytotoxicity of the chemotherapeutic, and heat has an inherent anti-tumor effect. Furthermore, the manual distribution of chemotherapy for 90 min allows for all surfaces of the abdomen and pelvis to be adequately exposed to the chemotherapeutic agent. Ninety minutes is described to be ideal as it is enough time to cause cytotoxicity to cancer cells without causing disturbances to renal function and hemodynamics^[19].

The initial management of PMP was debulking

surgery. However, CRS/HIPEC has been shown to be superior in the long-term. Järvinen *et al*^[7] showed in a retrospective analysis of 120 patients from 1984-2011 that the 5-year OS was similar: 67% for debulking group and 69% for CRS/HIPEC. However, the reoperation rates were much higher in debulking, 54% compared to 9%^[7]. Very few studies have actually done a direct comparison. In the last 30 years, there have been several single center and multicenter reports that detail the outcomes of CRS and HIPEC, but no randomized control trials have been published. Nonetheless, CRS and HIPEC are accepted as first-line treatment for selected PMP patients.

In 2007, Smeenk *et al*^[20] conducted a retrospective study in the Netherlands on 103 patients who underwent CRS/HIPEC for PMP between 1996-2004. They found the 5-year OS to be 59.5%^[20]. Our paper aimed to look at more recent literature and studies published that outline the success, defined by five-year OS in patients who underwent CRS/HIPEC.

Gupta *et al*^[10] analyzed the outcomes following CRS and HIPEC for appendiceal tumours. They looked at five-year OS and disease-free survival (DFI). It was found that CRS and HIPEC achieve 83% five-year OS if the tumor is low grade, and 68% if the tumor is high

grade^[10].

Table 3 illustrates the five-year OS reported over the years for CRS/HIPEC for patients with PMP. All authors reported that the five-year OS is highly dependent on the pathology of the disease. Nonetheless, Chua *et al.*^[18] looked at an outstanding 2020 patients who underwent CRS/HIPEC for PMP and found that the five-year OS was 82%. This, along with the reported outcomes from other studies, highlights that CRS with HIPEC is an effective tool for the treatment of PMP.

Table 4 outlines both surgical and nonsurgical complications associated with CRS and HIPEC. Chua *et al.*^[18] found the rates of major complications to be as high as 24%. Sugarbaker *et al.*^[17] outlined that hematological (28%) and gastrointestinal (26%) to be the major complications associated with CRS/HIPEC. Complications seen include neutropenia, sepsis, pleural effusion, respiratory insufficiency, increased risk for thromboembolism, anastomotic leak, bowel perforation, fistula formation, abscess, and wound dehiscence^[21].

Thromboembolism risk, including DVT and PE, should be taken into consideration, and post-operative patients should be started on anti-thrombotic treatment. Anastomotic leak seems to be the major gastrointestinal complication. This may be associated with intraperitoneal HIPEC. Potential for further study includes assessing whether creating a temporary stoma and revisiting a primary anastomosis at a later date decreases the amount of anastomotic leak.

In the absence of a more effective way of treating PMP and other peritoneal carcinomatosis, the morbidity and mortality needs to be weighed against benefits of survival. More radical surgical procedures (*i.e.*, Whipple) have similar complications to CRS/HIPEC but not nearly as significant of a benefit.

Bevan *et al.*^[4] recommend a baseline CT scan to be completed 3 mo post-operatively and then every 6 mo to monitor for recurrence. Routine bloodwork looking at tumor markers discussed in this review can also be compared with that of baseline to facilitate the detection of recurrence. Our recommendation is to do baseline CT, CEA, NLR, and PLR at 3 mo, and then every 6 mo post-operatively.

Despite these outcomes after CRS and HIPEC, there is significant recurrence of the disease. Yan *et al.*^[22] found recurrence to be as high as 28%, and the majority of these patients underwent repeat surgery. Lord *et al.*^[5] conducted a retrospective analysis of 512 patients undergoing CRS with HIPEC for PMP, and they found that 26.4% (137/512) developed recurrence and 25.5% (35/137) underwent repeat surgery. Complete tumor removal was achieved in 20/35 (57.1%). They found that there was no significant difference in early post-operative complications in comparison to primary CRS surgery. The five-year OS in the 375 without recurrence was found to be 90.9%, and the 35 that had repeat CRS had a five-year OS of 79%^[5,23]. The literature suggests that if recurrence does occur, a second CRS procedure is feasible; however, the data

are limited due to small sample sizes. Continued data collection is needed to draw stronger conclusions on how to approach a patient with recurrence.

REFERENCES

- 1 **Ramaswamy V.** Pathology of Mucinous Appendiceal Tumors and Pseudomyxoma Peritonei. *Indian J Surg Oncol* 2016; **7**: 258-267 [PMID: 27065718 DOI: 10.1007/s13193-016-0516-2]
- 2 **Amini A,** Masoumi-Moghaddam S, Ehteda A, Morris DL. Secreted mucins in pseudomyxoma peritonei: pathophysiological significance and potential therapeutic prospects. *Orphanet J Rare Dis* 2014; **9**: 71 [PMID: 24886459 DOI: 10.1186/1750-1172-9-71]
- 3 **Bouquot M,** Dohan A, Gayat E, Barat M, Glehen O, Pocard M, Rousset P, Eveno C. Prediction of Resectability in Pseudomyxoma Peritonei with a New CT Score. *Ann Surg Oncol* 2018; **25**: 694-701 [PMID: 29192372 DOI: 10.1245/s10434-017-6275-7]
- 4 **Bevan KE,** Mohamed F, Moran BJ. Pseudomyxoma peritonei. *World J Gastrointest Oncol* 2010; **2**: 44-50 [PMID: 21160816 DOI: 10.4251/wjgo.v2.i1.44]
- 5 **Lord AC,** Shihab O, Chandrakumaran K, Mohamed F, Cecil TD, Moran BJ. Recurrence and outcome after complete tumour removal and hyperthermic intraperitoneal chemotherapy in 512 patients with pseudomyxoma peritonei from perforated appendiceal mucinous tumours. *Eur J Surg Oncol* 2015; **41**: 396-399 [PMID: 25216980 DOI: 10.1016/j.ejso.2014.08.476]
- 6 **Dixit A,** Robertson JH, Mudan SS, Akle C. Appendiceal mucocoeles and pseudomyxoma peritonei. *World J Gastroenterol* 2007; **13**: 2381-2384 [PMID: 17511043 DOI: 10.3748/wjg.v13.i16.2381]
- 7 **Järvinen P,** Ristimäki A, Kantonen J, Aronen M, Huhtanen R, Järvinen H, Lepistö A. Comparison of serial debulking and cytoreductive surgery with hyperthermic intraperitoneal chemotherapy in pseudomyxoma peritonei of appendiceal origin. *Int J Colorectal Dis* 2014; **29**: 999-1007 [PMID: 24965858 DOI: 10.1007/s00384-014-1933-8]
- 8 **Ronnett BM,** Zahn CM, Kurman RJ, Kass ME, Sugarbaker PH, Shmookler BM. Disseminated peritoneal adenomucinosis and peritoneal mucinous carcinomatosis. A clinicopathologic analysis of 109 cases with emphasis on distinguishing pathologic features, site of origin, prognosis, and relationship to "pseudomyxoma peritonei". *Am J Surg Pathol* 1995; **19**: 1390-1408 [PMID: 7503361 DOI: 10.1097/00000478-199512000-00006]
- 9 **Misraji J,** Yantiss RK, Graeme-Cook FM, Balis UJ, Young RH. Appendiceal mucinous neoplasms: a clinicopathologic analysis of 107 cases. *Am J Surg Pathol* 2003; **27**: 1089-1103 [PMID: 12883241 DOI: 10.1097/00000478-200308000-00006]
- 10 **Gupta A,** Chandrakumaran K, Cecil TD, Mohamed F, Moran BJ. Tumour grade and complete tumour removal affects survival after cytoreductive surgery and HIPEC for Pseudomyxoma Peritonei (PMP) of appendiceal origin. PMI Basingstoke Basingstoke and North Hampshire Hospital, 2014. Available from: URL: <https://www.acpgbi.org.uk/content/uploads/2015/11/SP016-Colorectal-Cancer-Gupta-Tripartite-2014.pdf>
- 11 **Järvinen P.** Diagnosis and Treatment of Pseudomyxoma Peritonei. Helsingin Yliopisto, 2014: 72
- 12 **Taflampas P,** Dayal S, Chandrakumaran K, Mohamed F, Cecil TD, Moran BJ. Pre-operative tumour marker status predicts recurrence and survival after complete cytoreduction and hyperthermic intraperitoneal chemotherapy for appendiceal Pseudomyxoma Peritonei: Analysis of 519 patients. *Eur J Surg Oncol* 2014; **40**: 515-520 [PMID: 24462284 DOI: 10.1016/j.ejso.2013.12.021]
- 13 **Rangarajan K,** Chandrakumaran K, Dayal S, Mohamed F, Moran BJ, Cecil TD. The pre-operative neutrophil-lymphocyte ratio predicts overall and disease-free survival following cytoreductive surgery (CRS) and hyperthermic intraperitoneal chemotherapy (HIPEC) in patients with pseudomyxoma peritonei of appendiceal origin. *Int J Hyperthermia* 2018; **34**: 559-563 [PMID: 29063804 DOI: 10.1080/02656736.2017.1384073]
- 14 **Bong TSH,** Tan GHC, Chia C, Soo KC, Teo MCC. Preoperative

- platelet-lymphocyte ratio is an independent prognostic marker and superior to carcinoembryonic antigen in colorectal peritoneal carcinomatosis patients undergoing cytoreductive surgery and hyperthermic intraperitoneal chemotherapy. *Int J Clin Oncol* 2017; **22**: 511-518 [PMID: 28138878 DOI: 10.1007/s10147-017-1092-3]
- 15 **Di Fabio F**, Aston W, Mohamed F, Chandrakumaran K, Cecil T, Moran B. Elevated tumour markers are normalized in most patients with pseudomyxoma peritonei 7 days after complete tumour removal. *Colorectal Dis* 2015; **17**: 698-703 [PMID: 25704482 DOI: 10.1111/codi.12924]
 - 16 **Sugarbaker PH**. Pseudomyxoma peritonei. A cancer whose biology is characterized by a redistribution phenomenon. *Ann Surg* 1994; **219**: 109-111 [PMID: 8129480 DOI: 10.1097/0000658-199402000-00001]
 - 17 **Sugarbaker PH**, Ryan DP. Cytoreductive surgery plus hyperthermic perioperative chemotherapy to treat peritoneal metastases from colorectal cancer: standard of care or an experimental approach? *Lancet Oncol* 2012; **13**: e362-e369 [PMID: 22846841 DOI: 10.1016/S1470-2045(12)70210-3]
 - 18 **Chua TC**, Moran BJ, Sugarbaker PH, Levine EA, Glehen O, Gilly FN, Baratti D, Deraco M, Elias D, Sardi A, Liauw W, Yan TD, Barrios P, Gómez Portilla A, de Hingh IH, Ceelen WP, Pelz JO, Piso P, González-Moreno S, Van Der Speeten K, Morris DL. Early- and long-term outcome data of patients with pseudomyxoma peritonei from appendiceal origin treated by a strategy of cytoreductive surgery and hyperthermic intraperitoneal chemotherapy. *J Clin Oncol* 2012; **30**: 2449-2456 [PMID: 22614976 DOI: 10.1200/JCO.2011.39.7166]
 - 19 **Pablo CC**, Esquivel J, Sugarbaker PH. Cytoreductive surgery and intraperitoneal chemotherapy for the treatment of peritoneal surface malignancy. *Clin Transl Oncol* 2003; **5**: 192-198
 - 20 **Smeenk RM**, Verwaal VJ, Antonini N, Zoetmulder FA. Survival analysis of pseudomyxoma peritonei patients treated by cytoreductive surgery and hyperthermic intraperitoneal chemotherapy. *Ann Surg* 2007; **245**: 104-109 [PMID: 17197972 DOI: 10.1097/01.sla.0000231705.40081.1a]
 - 21 **Feng XH**, Zhai LM, Tan WF, Zhao W, Liu F, He JZ. The controlling effect of pH on oxidation of Cr(III) by manganese oxide minerals. *J Colloid Interface Sci* 2006; **298**: 258-266 [PMID: 16423363 DOI: 10.1245/ASO.2006.03.079]
 - 22 **Yan TD**, Black D, Savady R, Sugarbaker PH. A systematic review on the efficacy of cytoreductive surgery and perioperative intraperitoneal chemotherapy for pseudomyxoma peritonei. *Ann Surg Oncol* 2007; **14**: 484-492 [PMID: 17054002 DOI: 10.1245/s10434-006-9182-x]
 - 23 CT scan pseudomyxoma peritonei - UpToDate. Available from: URL: https://www.uptodate.com/contents/image?imageKey=RAD IOL%2F88749topicKey=ONC%2F2527source=outline_link
 - 24 **Penha D**. Pseudomyxoma Peritonei – What every radiologist should know. European Congress of Radiology, 2013: C-1666 [DOI: 10.1594/ecr2013/C-1666]
 - 25 **Archives of Pathology Laboratory Medicine**. Display Figures. Available from: URL: <http://www.archivesofpathology.org/action/showFullPopup?id=i1543-2165-135-10-1261-f04doi=10.5858%2Farpa.2011-0034-RA>
 - 26 **Sugarbaker PH**, Van der Speeten K. Surgical technology and pharmacology of hyperthermic perioperative chemotherapy. *J Gastrointest Oncol* 2016; **7**: 29-44 [PMID: 26941982 DOI: 10.3978/j.issn.2078-6891.2015.105]
 - 27 **Baratti D**, Kusamura S, Milione M, Bruno F, Guaglio M, Deraco M. Validation of the Recent PSOGI Pathological Classification of Pseudomyxoma Peritonei in a Single-Center Series of 265 Patients Treated by Cytoreductive Surgery and Hyperthermic Intraperitoneal Chemotherapy. *Ann Surg Oncol* 2018; **25**: 404-413 [PMID: 29159742 DOI: 10.1245/s10434-017-6252-1]
 - 28 **Pallas N**, Karamveri C, Kyziridis D, Hristakis C, Kyriakopoulos V, Kalakonas A, Vaikos D, Tentes AK. Cytoreductive surgery and hyperthermic intraperitoneal chemotherapy (HIPEC) for colorectal and appendiceal carcinomas with peritoneal carcinomatosis. *J BUON* 2017; **22**: 1547-1553 [PMID: 29332351]
 - 29 **Chia CS**, Seshadri RA, Kepenekian V, Vaudoyer D, Passot G, Glehen O. Survival outcomes after cytoreductive surgery and hyperthermic intraperitoneal chemotherapy for peritoneal carcinomatosis from gastric cancer: a systematic review. *Pleura Peritoneum* 2016; **1**: 65-77 [DOI: 10.1515/pp-2016-0010]
 - 30 **Moran B**, Cecil T, Chandrakumaran K, Arnold S, Mohamed F, Venkatasubramanian A. The results of cytoreductive surgery and hyperthermic intraperitoneal chemotherapy in 1200 patients with peritoneal malignancy. *Colorectal Dis* 2015; **17**: 772-778 [PMID: 25880479 DOI: 10.1111/codi.12975]
 - 31 **Chua TC**, Yan TD, Saxena A, Morris DL. Should the treatment of peritoneal carcinomatosis by cytoreductive surgery and hyperthermic intraperitoneal chemotherapy still be regarded as a highly morbid procedure?: a systematic review of morbidity and mortality. *Ann Surg* 2009; **249**: 900-907 [PMID: 19474692 DOI: 10.1097/SLA.0b013e3181a45d86]
 - 32 **Hamilton TD**, Taylor EL, Cannell AJ, McCart JA, Govindarajan A. Impact of Major Complications on Patients' Quality of Life After Cytoreductive Surgery and Hyperthermic Intraperitoneal Chemotherapy. *Ann Surg Oncol* 2016; **23**: 2946-2952 [PMID: 27094685 DOI: 10.1245/s10434-016-5231-2]

P- Reviewer: Bramhall S, Fusai G, Kato J, Seow-Choen F
S- Editor: Ji FF **L- Editor:** Filipodia **E- Editor:** Song H





Published by **Baishideng Publishing Group Inc**
7901 Stoneridge Drive, Suite 501, Pleasanton, CA 94588, USA
Telephone: +1-925-223-8242
Fax: +1-925-223-8243
E-mail: bpgoffice@wjgnet.com
Help Desk: <http://www.f6publishing.com/helpdesk>
<http://www.wjgnet.com>

