

# World Journal of *Transplantation*

*World J Transplant* 2018 September 10; 8(5): 122-197



**REVIEW**

- 122 Thrombotic microangiopathy after renal transplantation: Current insights in *de novo* and recurrent disease  
*Abbas F, El Kossi M, Kim JJ, Sharma A, Halawa A*

**MINIREVIEWS**

- 142 Early urological complications after kidney transplantation: An overview  
*Buttigieg J, Agius-Anastasi A, Sharma A, Halawa A*
- 150 Introduction of everolimus in kidney transplant recipients at a late posttransplant stage  
*Uchida J, Iwai T, Nakatani T*

**ORIGINAL ARTICLE****Basic Study**

- 156 Interaction of immunosuppressants with HCV antivirals daclatasvir and asunaprevir: combined effects with mycophenolic acid  
*de Ruiter PE, Gadjradj Y, de Knecht R, Metselaar HJ, Ijzermans JNM, van der Laan LJW*

**Retrospective Cohort Study**

- 167 Trends of characteristics and outcomes of donors and recipients of deceased donor liver transplantation in the United States: 1990 to 2013  
*Ayloo S, Pentakota SR, Molinari M*

- 178 Treatment with plasmapheresis, immunoglobulins and rituximab for chronic-active antibody-mediated rejection in kidney transplantation: Clinical, immunological and pathological results  
*Mella A, Gallo E, Messina M, Caorsi C, Amoroso A, Gontero P, Verri A, Maletta F, Barreca A, Fop F, Biancone L*

**Randomized Clinical Trial**

- 188 Clinical features and determinants of  $VO_{2peak}$  in *de novo* heart transplant recipients  
*Rolid K, Andreassen AK, Yardley M, Bjørkelund E, Karason K, Wigh JP, Dall CH, Gustafsson F, Gullestad L, Nytrøen K*

**ABOUT COVER**

Editorial Board Member of *World Journal of Transplantation*, Felix Cantarovich, MD, Professor, Clinical renal transplantation, Catholic University Argentine, 9 rue Parent de Rosan, Paris 75016, France

**AIM AND SCOPE**

*World Journal of Transplantation* (*World J Transplant*, *WJT*, online ISSN 2220-3230, DOI: 10.5500) is a peer-reviewed open access academic journal that aims to guide clinical practice and improve diagnostic and therapeutic skills of clinicians.

*WJT* covers topics concerning organ and tissue donation and preservation; tissue injury, repair, inflammation, and aging; immune recognition, regulation, effector mechanisms, and opportunities for induction of tolerance, thoracic transplantation (heart, lung), abdominal transplantation (kidney, liver, pancreas, islets), transplantation of tissues, cell therapy and islet transplantation, clinical transplantation, experimental transplantation, immunobiology and genomics, and xenotransplantation. The current columns of *WJT* include editorial, frontier, diagnostic advances, therapeutics advances, field of vision, mini-reviews, review, topic highlight, medical ethics, original articles, case report, clinical case conference (Clinicopathological conference), and autobiography.

**AIM AND SCOPE**

*World Journal of Transplantation* (*WJT*) is now abstracted and indexed in PubMed, PubMed Central, China National Knowledge Infrastructure (CNKI), and Superstar Journals Database.

**EDITORS FOR THIS ISSUE**

**Responsible Assistant Editor:** *Xiang Li*  
**Responsible Electronic Editor:** *Shu-Yu Yin*  
**Proofing Editor-in-Chief:** *Lian-Sheng Ma*

**Responsible Science Editor:** *Ying Dou*  
**Proofing Editorial Office Director:** *Jin-Lai Wang*

**NAME OF JOURNAL**  
*World Journal of Transplantation*

**ISSN**  
ISSN 2220-3230 (online)

**LAUNCH DATE**  
December 24, 2011

**EDITOR-IN-CHIEF**  
**Maurizio Salvadori, MD, Professor**, Renal Unit, Careggi University Hospital, Florence 50139, Italy

**EDITORIAL BOARD MEMBERS**  
All editorial board members resources online at <http://www.wjgnet.com/2220-3230/editorialboard.htm>

**EDITORIAL OFFICE**  
Jin-Lai Wang, Director  
*World Journal of Transplantation*  
Baishideng Publishing Group Inc  
7901 Stoneridge Drive, Suite 501, Pleasanton, CA 94588, USA

Telephone: +1-925-2238242  
Fax: +1-925-2238243  
E-mail: [editorialoffice@wjgnet.com](mailto:editorialoffice@wjgnet.com)  
Help Desk: <http://www.f6publishing.com/helpdesk>  
<http://www.wjgnet.com>

**PUBLISHER**  
Baishideng Publishing Group Inc  
7901 Stoneridge Drive, Suite 501,  
Pleasanton, CA 94588, USA  
Telephone: +1-925-2238242  
Fax: +1-925-2238243  
E-mail: [bpgoffice@wjgnet.com](mailto:bpgoffice@wjgnet.com)  
Help Desk: <http://www.f6publishing.com/helpdesk>  
<http://www.wjgnet.com>

**PUBLICATION DATE**  
September 10, 2018

**COPYRIGHT**  
© 2018 Baishideng Publishing Group Inc. Articles

published by this Open-Access journal are distributed under the terms of the Creative Commons Attribution Non-commercial License, which permits use, distribution, and reproduction in any medium, provided the original work is properly cited, the use is non commercial and is otherwise in compliance with the license.

**SPECIAL STATEMENT**  
All articles published in journals owned by the Baishideng Publishing Group (BPG) represent the views and opinions of their authors, and not the views, opinions or policies of the BPG, except where otherwise explicitly indicated.

**INSTRUCTIONS TO AUTHORS**  
<http://www.wjgnet.com/bpg/gerinfo/204>

**ONLINE SUBMISSION**  
<http://www.f6publishing.com>

## Early urological complications after kidney transplantation: An overview

Jesmar Buttigieg, Andrei Agius-Anastasi, Ajay Sharma, Ahmed Halawa

Jesmar Buttigieg, Renal Division, Mater Dei Hospital, Msida MSD2090, Malta

Jesmar Buttigieg, Ajay Sharma, Ahmed Halawa, Faculty of Health and Science, Institute of Learning and Teaching, University of Liverpool, Liverpool L69 3BX, United Kingdom

Andrei Agius-Anastasi, Department of Medicine, Mater Dei Hospital, Msida MSD2090, Malta

Ajay Sharma, Department of Transplantation, Royal Liverpool University Hospital, Liverpool L7 8XP, United Kingdom

Ahmed Halawa, Department of Transplantation, Sheffield Teaching Hospitals, Sheffield S10 2JF, United Kingdom

ORCID number: Jesmar Buttigieg (0000-0001-8180-0162); Andrei Agius-Anastasi (0000-0002-7143-2869); Ajay Sharma (0000-0003-4050-6586); Ahmed Halawa (0000-0002-7305-446X).

**Author contributions:** All authors equally contributed to this paper with conception and design of the study, literature review and analysis, drafting and critical revision and editing, and final approval of the final version.

**Conflict-of-interest statement:** No potential conflicts of interest.

**Open-Access:** This article is an open-access article which was selected by an in-house editor and fully peer-reviewed by external reviewers. It is distributed in accordance with the Creative Commons Attribution Non Commercial (CC BY-NC 4.0) license, which permits others to distribute, remix, adapt, build upon this work non-commercially, and license their derivative works on different terms, provided the original work is properly cited and the use is non-commercial. See: <http://creativecommons.org/licenses/by-nc/4.0/>

**Manuscript source:** Unsolicited manuscript

**Correspondence to:** Ahmed Halawa, FRCS (Gen Surg), MD, MSc, Surgeon, Consultant Transplant Surgeon, Department of Transplantation, Sheffield Teaching Hospitals, Glossop Rd, Sheffield S10 2JF, United Kingdom. [ahmed.halawa@liverpool.ac.uk](mailto:ahmed.halawa@liverpool.ac.uk)  
Telephone: +44-114-2269696

Received: June 16, 2018

Peer-review started: June 16, 2018

First decision: July 8, 2018

Revised: July 21, 2018

Accepted: August 6, 2018

Article in press: August 6, 2018

Published online: September 10, 2018

### Abstract

Urological complications, especially urine leaks, remain the most common type of surgical complication in the early post-transplant period. Despite major advances in the field of transplantation, a small minority of kidney transplants are still being lost due to urological problems. Many of these complications can be traced back to the time of retrieval and implantation. Serial ultrasound examination of the transplanted graft in the early post-operative period is of key importance for early detection. The prognosis is generally excellent if recognized and managed in a timely fashion. The purpose of this narrative review is to discuss the different presentations, compare various ureterovesical anastomosis techniques and provide a basic overview for the management of post-transplant urological complications.

**Key words:** Anastomotic leak; Urinoma/s; Postoperative complications; Ureterostomy; Nephrostomy

© **The Author(s) 2018.** Published by Baishideng Publishing Group Inc. All rights reserved.

**Core tip:** Urological complications, especially urine leaks, remain the most common type of surgical complication following kidney transplantation. Preservation of the peri-ureteric tissue during kidney retrieval, Lich-Gregoir ureteroneocystostomy technique and routine prophylactic ureteral stenting has been shown to decrease the incidence of these complications. Routine post-operative allograft ultrasound is important for their early detection.



The majority of recipients can be effectively managed percutaneously, avoiding the morbidity associated with open surgery. The prognosis is generally excellent if recognized and treated successfully in a timely manner.

Buttigieg J, Agius-Anastasi A, Sharma A, Halawa A. Early urological complications after kidney transplantation: An overview. *World J Transplant* 2018; 8(5): 142-149 Available from: URL: <http://www.wjgnet.com/2220-3230/full/v8/i5/142.htm> DOI: <http://dx.doi.org/10.5500/wjt.v8.i5.142>

## INTRODUCTION

Kidney transplantation remains the best renal replacement modality for most patients with end-stage kidney disease<sup>[1]</sup>. Yet, as with everything else in the medical field, it is not devoid of risk. The patients who manage to get a kidney transplant in a timely fashion face a constant struggle for successful long-lasting survival. The vast majority of graft failure is attributed to alloimmune-mediated injury, recurrent glomerulonephritis, infections, cardiovascular mortality and malignancy<sup>[2,3]</sup>. Nonetheless, a number of renal allografts are lost due to urological complications, especially in the early post-transplant period. The purpose of this review is to discuss different presentations and provide an evidence-based management plan for patients who present with such complications.

## OUTLINE OF SURGICAL AND UROLOGICAL COMPLICATIONS

Complications in the immediate post-transplant period can be broadly subdivided into vascular, urological, fluid collections and wound healing problems. Vascular complications encompass hemorrhage, thrombosis, aneurysm, dissection and stenosis, while urological complications mainly involve leaks and/or obstruction of the collecting system<sup>[4,5]</sup>. In essence, hematomas form due to poor tissue handling, insecure knot tying and inadequate hemostasis. The lymphoceles result from severed lymph channels, which should be tied or clipped rather than diathermied, leading to extravasation of lymph. Urine leaks can result in the formation of urinomas. These collections can compress vascular structures or urine outflow, causing transplant dysfunction. In addition, urine leaks are associated with increased risk of surgical site infection, which can lead to peri-nephric abscesses<sup>[6,7]</sup>. Wound healing complications are generally more common when mammalian target of rapamycin (mTOR)-based immunosuppression is used<sup>[8]</sup>.

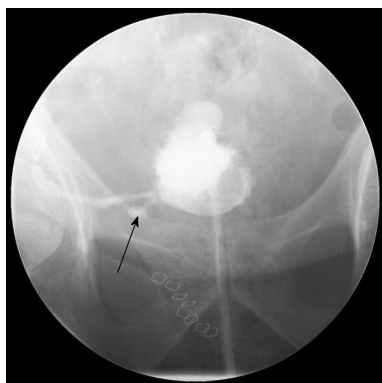Ultrasonography is the first-line imaging modality for graft evaluation in the immediate post-transplant period, especially when suspecting vascular problems, fluid collections and/or obstruction<sup>[9,10]</sup>. Apart from being non-invasive, it can provide some additional information on the graft function by measuring the intra-renal

resistivity indices<sup>[11]</sup>. Differentiating between different types of collections on ultrasound can be difficult. A urinoma usually appears as a well-defined, rapidly enlarging non-echoic fluid collection without septations, whereas a hematoma usually has a complex and echogenic appearance with numerous septations<sup>[9,12]</sup>. Computed tomography may assist in the diagnosis by further elucidating the ultrasound findings such as the extent or exact relationship of the fluid collection to the transplanted kidney<sup>[10]</sup>. <sup>99m</sup>Tc-MAG-3 radionuclide isotope scan is useful to confirm the presence of a urine leak outside the anatomical space of the urinary tract, as the radionuclide tracer accumulates in the excreted urine as opposed to other types of fluid collections<sup>[13]</sup>. A cystogram can provide additional information to establish the exact site of urine leak, especially if it is at the ureterovesical junction (Figure 1). Antegrade pyelography performed during nephrostomy tube insertion remains the investigation of choice to identify the exact site and extent of urine leak. Ultrasound and/or computed tomography-guided needle aspiration followed by biochemical and bacteriological analysis is essential in diagnosing the exact etiology of fluid collections<sup>[4]</sup>. A fluid creatinine well above the serum level indicates a urine leak as opposed to a lymphocele which has levels similar to that of serum. Gram stain and cultures are important because any fluid collection can potentially become infected<sup>[6]</sup>.

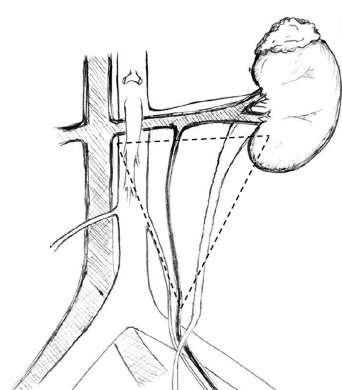
## RISK FACTORS AND PRESENTATION OF URINE LEAKS

The incidence of urological complications following kidney transplantation as portrayed in early studies (*i.e.*, including patients between 1970-1990s) ranged between 4.2% to 14.1%<sup>[14-18]</sup>, while in later studies (*i.e.*, including patients between 1990-2000), it ranged between 3.7% to 6.0%<sup>[19-21]</sup>. The incidence of urine leaks described in studies that included patients between the 1990s and 2000 ranged between 1.5% to 6.0%<sup>[19-23]</sup>. This variability is probably a reflection of the different transplantation era, diagnostic tools and surgical proficiency. Indeed, the incidence of urological complications has been shown to diminish considerably with increasing center experience<sup>[24]</sup>. These complications are associated with significant patient morbidity, including graft loss and mortality<sup>[17,25]</sup>.

Urine leaks generally present in the immediate or early post-transplant period (3 mo)<sup>[26]</sup>. Clinical presentation can include pain and swelling in the transplant area, rising creatinine, oliguria and/or signs of systemic infection<sup>[27]</sup>. In the immediate post-transplant period, urine leaks can manifest *via* the drains or through the wound, leading to delayed healing and increased risk of infection<sup>[7,28]</sup>. In addition, leaking urine can translocate into the retroperitoneal space, pelvis and occasionally in the pre-sacral and scrotal area<sup>[29]</sup>. The leaking of infected urine could lead to peri-nephric infections and abscess



**Figure 1** A cystogram showing urinary leak (arrow) at the anastomosis between the newly implanted graft ureter and urinary bladder.



**Figure 2** The golden triangle. Bordered by the lower pole of the kidney on the left, the junction between the renal vein and the inferior vena cava on the right and gonadal vein.

formation. This is important considering that urinary tract infections occur in about 23% of patients receiving a kidney transplant<sup>[30]</sup>.

Most urological complications can be traced back to technical errors during retrieval, bench dissection or implantation<sup>[28]</sup>. The vast majority of leaks occur at the distal portion of the ureter, most commonly at the site of the ureteroneocystostomy<sup>[26]</sup>. Distal ureteral ischemia and necrosis secondary to compromised blood supply is thought to be the main culprit for early ureteral complications in most patients in the absence of technical difficulties during the transplant operation<sup>[31]</sup>. In contrast to the native ureters, which derive their blood supply *via* both renal arteries and pelvic collaterals, the transplanted ureter depends solely on the blood supplied by the branches of the renal artery that traverse in peri-ureteric tissues. This area, also known as the "golden triangle" (Figure 2), contains important arterial branches, such as the lower polar artery, which supplies the distal ureter. Indeed, the importance of preserving the peri-ureteral connective tissue in order to prevent disastrous urinary complications is well documented in the literature<sup>[14,32-35]</sup>. Male donors, male recipients, African American recipients, Taguchi technique, graft arterial reconstruction, multiple renal arteries and recipient diabetes were established as

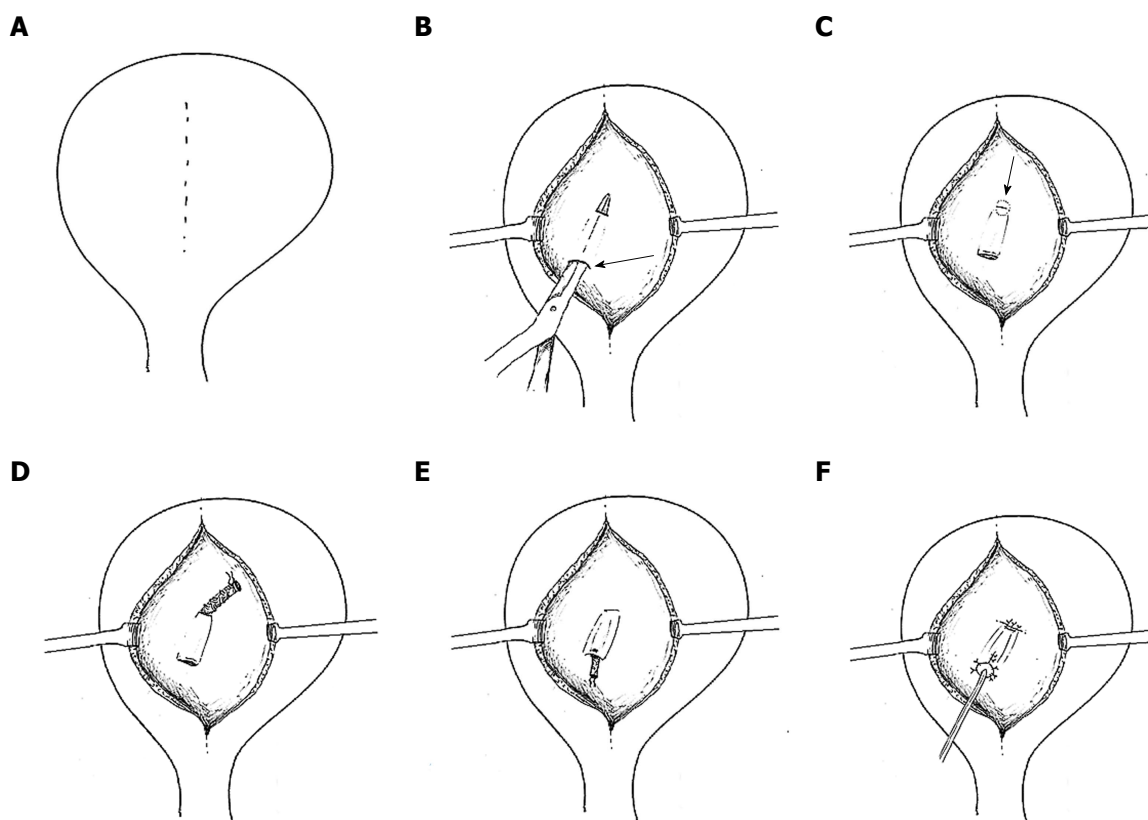
independent risk factors for urinary complications<sup>[36-39]</sup>. We believe that gentle handling of the ureter and peri-ureteric tissue, and keeping the length of the ureter as short as possible without tension is of key importance. A ureter that appears ischemic after reperfusion should be resected proximally until an adequately perfused area is reached. In this situation, achieving a tension-free urinary anastomosis may require special techniques, such as ipsilateral uretero-ureterostomy (joining the transplant ureter to the native ureter of that side), pyelovesicostomy, psoas hitch, Boari flap or fashioning of an ileal ureter, in that order of priority. In general, the risk of urinary complications following laparoscopic donor nephrectomy has decreased substantially over time, now comparable to open nephrectomy<sup>[40]</sup>.

The ureterovesical anastomosis associated with the lowest rate of complications continues to be a subject of debate. The Leadbetter-Politano technique (Figure 3) was primarily used in the early days of kidney transplantation<sup>[41]</sup>. This has been largely superseded by the less technically demanding Lich-Gregoir technique (Figure 4)<sup>[42]</sup>. The Taguchi technique (Figure 5) has been associated with unacceptably higher incidence of complications compared to the Lich-Gregoir technique<sup>[43,44]</sup>. In a recent meta-analysis, which included two randomized controlled studies and 24 observational studies, the Lich-Gregoir technique was found to significantly reduce the incidence of ureteral leaks when compared to the Leadbetter-Politano and Taguchi techniques<sup>[45]</sup>. The incidence of ureteral stricture and reflux, however, did not differ significantly. The use of a shorter ureter and the avoidance of a separate cystostomy are two hypothetical advantages over the Leadbetter-Politano technique<sup>[46]</sup>. A modification of the Lich-Gregoir technique, using a short muscular tunnel over the distal ureter, has been shown to reduce complications in two separate retrospective studies<sup>[46,47]</sup>. In one Chinese study, primary termino-terminal ipsilateral ureteroureterostomy, was associated with significantly less urinary fistulas when compared to the established Lich-Gregoir technique<sup>[23]</sup>.

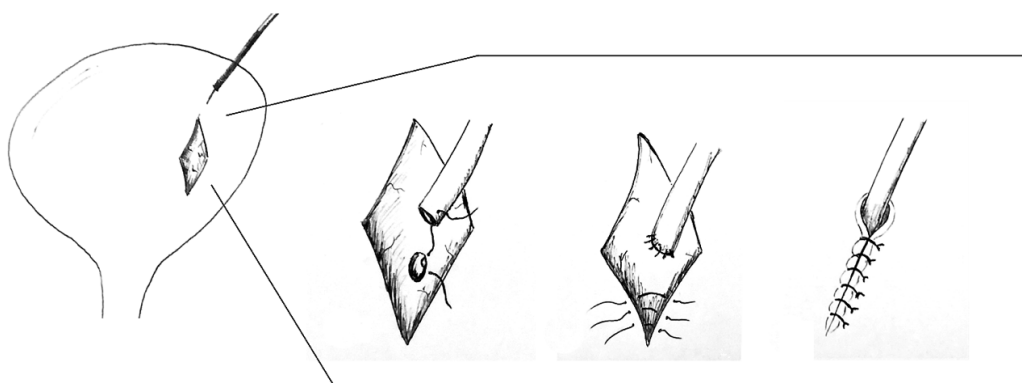
Currently, many centers have adopted the routine use of ureteric stent during kidney transplantation. A meta-analysis, which included seven randomized controlled studies, confirmed that routine prophylactic stenting is generally well tolerated and significantly reduces major urological complications<sup>[48]</sup>. In a recently published Cochrane database systematic review, it was established that 13 transplant recipients need to be treated (with using JJ stent) in order to prevent one major urological complication<sup>[48]</sup>. Despite some opposition due to the higher incidence of urinary tract infections, current evidence recommends the routine use of prophylactic stenting.

## MANAGEMENT OF URINARY LEAKS

In general, one can select between two main approaches



**Figure 3 Leadbetter-Politano technique.** A: A longitudinal bladder incision is performed to gain access to the interior of the bladder; B: A second cystotomy is done to introduce the neo-ureter in the bladder. Subsequently, an Overholt is inserted from the second cystotomy and tunnelled close to the bladder wall for about 3 cm; C: A new hiatus is created at the end of the tunnel; D: The neo-ureter is pulled through the mucosal tunnel and the new mucosal hiatus using a free suture as a guide rail; E: Closure of the second cystotomy and then sub-mucosal transposition of distal neo-ureter; F: Fixation of the neo-ureter orifice and closure of the bladder mucosa.



**Figure 4 Lich-Gregoir technique.** A: Bladder wall incision through the detrusor muscle is performed, leaving a very thin layer of muscle and uroepithelium unbreached; B: The distal part is completely incised to create a neo-ureter-bladder anastomosis; C: Suturing of the neo-ureter is performed via the same access used to introduce it into the bladder; D: The ureter is positioned in the groove and in direct contact to the uroepithelium, followed by closure of the muscle over the ureter while carefully avoiding constriction of the neo-ureter.

(conservative vs reconstructive surgery) depending on the site, cause and extent of the leak. One has to keep in mind that these treatment strategies are not based on robust scientific evidence and tend to vary between centers based on anecdotal experiences. The current best available evidence is merely based on retrospective studies.

A conservative approach typically involves insertion of a percutaneous nephrostomy followed by antegrade

stenting of the collecting system (unless already performed during the transplant operation), together with a Foley catheter replacement. Retrograde stenting of a transplant ureter is technically demanding and often impossible, even by the most skilled urologists, because of the atypical position of the ureteric orifice. Antegrade stenting, although generally easier, can still pose technical challenge in the absence of pelvi-caliceal dilatation. Interventional radiologists and transplant surgeons



**Figure 5 Taguchi technique.** A suture is positioned at the distal end of the neo-ureter and subsequently introduced in the bladder *via* a cystostomy. The neo-ureter is later fixed to the bladder wall by bringing the suture out through the bladder wall and closed.

can work together to manage difficult cases<sup>[49]</sup>. This procedure diverts the urinary flow away from the leaking site and, thereby, fully decompresses the collecting system in order to allow for healing to take place. The Foley catheter is usually removed once the leak has resolved. Many centers report stent deployment for a period of 6-12 wk<sup>[14,33,35,46]</sup>. The presence of recurrent urinary tract infection may hasten the time for stent removal.

Surgical exploration is required if the urine leak fails to resolve following maximal decompression, especially when dealing with major urine extravasations or necrotic ureters. During the surgical procedure, the necrotic ureter should be resected proximally until healthy tissue is reached, followed by re-implantation. If the remaining viable ureter is short, an ipsilateral uretero-ureterostomy, pyelovesicostomy, psoas hitch, Boari flap or fashioning of an ileal ureter are alternative techniques that could be employed for tension-free ureteric anastomosis<sup>[50]</sup>. A psoas hitch (Figure 6) involves extensive dissection and mobilization of the urinary bladder to allow mobilization towards the transplant ureter, usually up to 5 cm. Subsequently, the bladder is anchored to the ipsilateral psoas muscle. Alternatively, a Boari flap (Figure 7) can be fashioned to attain an additional 10 cm. If required, this can be used in conjunction with the psoas hitch technique to bridge larger gaps between the short transplant ureter and the bladder. Contracted or atrophic urinary bladders in anuric patients seriously limit these options. In this circumstance, an ipsilateral uretero-ureterostomy can be an alternative option if the cause of native kidney failure was not reflux disease. A pyelovesicostomy or an ileal ureter can be fashioned, the latter being preferred for larger gaps, in situations where no donor or recipient ureter can be salvaged<sup>[51]</sup>. Both these techniques are devoid of an anti-reflux mechanism. In all cases, serial ultrasound examinations together with close monitoring of the transplant excretory function is of chief importance to anticipate any secondary ureteral strictures.

Traditionally, urine leaks have been corrected by open reconstruction. Over the last two decades, advances in interventional radiology have allowed several patients to be effectively managed percutaneously, avoiding

the morbidity associated with open surgery<sup>[49,52]</sup>. This conservative approach has been shown to be successful in a number of retrospective studies, with a success rate varying between 30% and 87%<sup>[19,21,53-55]</sup>. This considerable inter-center variability is probably related to different baseline characteristics. We believe that the outcome largely depends on the etiology, site and extent of the urine leak. In general, small leaks at the ureter implantation site tend to do well with conservative management, while extensive leaks, especially if related to ureter necrosis, do better with open surgery. When in doubt, we treat conservatively in the first instance and then proceed to surgical reconstruction only if the patient fails to respond. The type of surgery is frequently dictated by the intra-operative findings and the overall state of the patient. Surgical reconstruction is usually successful in the majority of cases<sup>[19,21,23,55]</sup>. Nonetheless, some patients required more than one surgical procedure for complete resolution<sup>[23]</sup>.

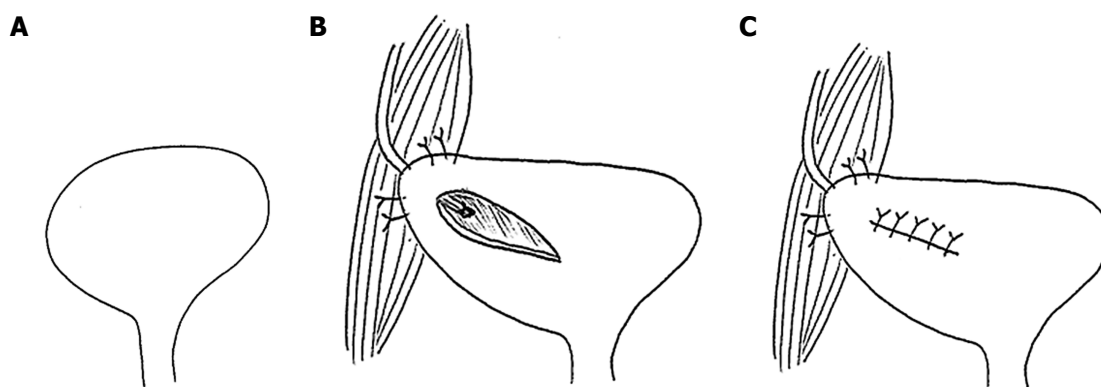
## LIMITATION

This narrative review is intended to provide a general overview of the early urological complications after kidney transplantation. Although we performed an extensive literature search, this review lacks the scientific rigor of article selection found in a systematic review, and is therefore susceptible to selection bias. In addition, the selected articles have not been subjected to quality evaluation.

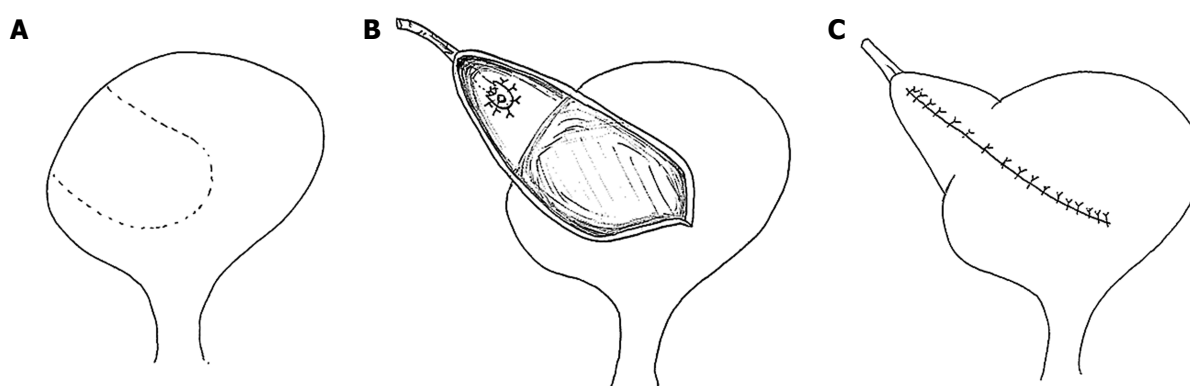
## CONCLUSION

Urological complications, especially urine leaks, remain the most common type of surgical complication following kidney transplantation. The preservation of peri-ureteric tissue during kidney retrieval, employing the Lich-Gregoir ureteroneocystostomy technique and routine prophylactic ureteral stenting, have been associated with lower incidence of such complications. Serial ultrasound examination of the transplanted graft in the early post-operative period is of key importance for early detection of these potential complications. The first line





**Figure 6 Psoas hitch.** A: A psoas hitch procedure is used to bridge the gap between the urinary bladder and a short ureter; B: Mobilization of the urinary bladder is achieved by dissecting the attachments of the urinary bladder, which is subsequently hitched to the Psoas muscle; C: Ureter implantation is performed via a transverse incision, which is later closed.



**Figure 7 Boari flap.** A: A Boari flap is used when a Psoas hitch is not enough to bridge the gap between the bladder and a short ureter to allow for a tension-free anastomosis. A U-shaped flap composed of all tissue layers is created. The base should be proportional to the length of the flap to avoid ischemia; B: The ureter is implanted to the apex of the flap via end-to-end anastomosis or a sub-mucosal tunnel; C: The bladder incision together with the flap are subsequently closed.

management of urine leaks is usually percutaneous urinary decompression. Failing this approach, surgical intervention is usually required, especially if dealing with major leaks or necrotic ureters. Although urological complications are associated with significant morbidity and occasionally mortality, the prognosis is generally excellent if recognized and treated successfully in a timely manner.

## REFERENCES

- 1 **Wolfe RA**, Ashby VB, Milford EL, Ojo AO, Ettenger RE, Agodoa LY, Held PJ, Port FK. Comparison of mortality in all patients on dialysis, patients on dialysis awaiting transplantation, and recipients of a first cadaveric transplant. *N Engl J Med* 1999; **341**: 1725-1730 [PMID: 10580071 DOI: 10.1056/NEJM199912023412303]
- 2 **Sellarés J**, de Freitas DG, Mengel M, Reeve J, Einecke G, Sis B, Hidalgo LG, Famulski K, Matas A, Halloran PF. Understanding the causes of kidney transplant failure: the dominant role of antibody-mediated rejection and nonadherence. *Am J Transplant* 2012; **12**: 388-399 [PMID: 22081892 DOI: 10.1111/j.1600-6143.2011.03840.x]
- 3 **Opelz G**, Döhler B. Association of HLA mismatch with death with a functioning graft after kidney transplantation: a collaborative transplant study report. *Am J Transplant* 2012; **12**: 3031-3038 [PMID: 22900931 DOI: 10.1111/j.1600-6143.2012.04226.x]
- 4 **Humar A**, Matas AJ. Surgical complications after kidney transplantation. *Semin Dial* 2005; **18**: 505-510 [PMID: 16398714 DOI: 10.1111/j.1525-139X.2005.00097.x]
- 5 **Haberal M**, Boyvat F, Akdur A, Kirnap M, Özçelik Ü, Yaruğ Karakayalı F. Surgical Complications After Kidney Transplantation. *Exp Clin Transplant* 2016; **14**: 587-595 [PMID: 27934557]
- 6 **Rao PS**, Ravindran A, Elsamaloty H, Modi KS. Emphysematous urinoma in a renal transplant patient. *Am J Kidney Dis* 2001; **38**: E29 [PMID: 11684581 DOI: 10.1053/ajkd.2001.28626]
- 7 **Capocasale E**, De Vecchi E, Mazzoni MP, Dalla Valle R, Pellegrino C, Ferretti S, Sianesi M, Iaria M. Surgical site and early urinary tract infections in 1000 kidney transplants with antimicrobial perioperative prophylaxis. *Transplant Proc* 2014; **46**: 3455-3458 [PMID: 25498071 DOI: 10.1016/j.transproceed.2014.07.071]
- 8 **Pengel LH**, Liu LQ, Morris PJ. Do wound complications or lymphoceles occur more often in solid organ transplant recipients on mTOR inhibitors? A systematic review of randomized controlled trials. *Transpl Int* 2011; **24**: 1216-1230 [PMID: 21955006 DOI: 10.1111/j.1432-2277.2011.01357.x]
- 9 **Kolofousi C**, Stefanidis K, Cokkinos DD, Karakitsos D, Antypa E, Piperopoulos P. Ultrasonographic features of kidney transplants and their complications: an imaging review. *ISRN Radiol* 2012; **2013**: 480862 [PMID: 24967275 DOI: 10.5402/2013/480862]
- 10 **Vernuccio F**, Gondalia R, Churchill S, Bashir MR, Marin D. CT evaluation of the renal donor and recipient. *Abdom Radiol (NY)* 2018 [PMID: 29508012 DOI: 10.1007/s00261-018-1508-1]
- 11 **Schwarz C**, Mühlbacher J, Böhmig GA, Puric M, Pablik E, Unger L, Kristo I, Soliman T, Berlakovich GA. Impact of ultrasound examination shortly after kidney transplantation. *Eur Surg* 2017; **49**: 140-144 [PMID: 28596786 DOI: 10.1007/s10353-017-0467-z]
- 12 **Park SB**, Kim JK, Cho KS. Complications of renal transplantation: ultrasonographic evaluation. *J Ultrasound Med* 2007; **26**: 615-633 [PMID: 17460004 DOI: 10.7863/jum.2007.26.5.615]
- 13 **Irshad A**, Ackerman S, Sosnouski D, Anis M, Chavin K, Baliga P. A

- review of sonographic evaluation of renal transplant complications. *Curr Probl Diagn Radiol* 2008; **37**: 67-79 [PMID: 18295078 DOI: 10.1067/j.cpradiol.2007.06.001]
- 14 **Streeter EH**, Little DM, Cranston DW, Morris PJ. The urological complications of renal transplantation: a series of 1535 patients. *BJU Int* 2002; **90**: 627-634 [PMID: 12410737 DOI: 10.1046/j.1464-410X.2002.03004.x]
  - 15 **Jaskowski A**, Jones RM, Murie JA, Morris PJ. Urological complications in 600 consecutive renal transplants. *Br J Surg* 1987; **74**: 922-925 [PMID: 3311278 DOI: 10.1002/bjs.1800741015]
  - 16 **Loughlin KR**, Tilney NL, Richie JP. Urologic complications in 718 renal transplant patients. *Surgery* 1984; **95**: 297-302 [PMID: 6367124]
  - 17 **Rigg KM**, Proud G, Taylor RM. Urological complications following renal transplantation. A study of 1016 consecutive transplants from a single centre. *Transpl Int* 1994; **7**: 120-126 [PMID: 8179799 DOI: 10.1111/j.1432-2277.1994.tb01231.x]
  - 18 **Mäkisalo H**, Eklund B, Salmela K, Isoniemi H, Kyllönen L, Höckerstedt K, Halme L, Ahonen J. Urological complications after 2084 consecutive kidney transplantations. *Transplant Proc* 1997; **29**: 152-153 [PMID: 9122938 DOI: 10.1016/S0041-1345(96)00044-9]
  - 19 **Buresley S**, Samhan M, Moniri S, Codaj J, Al-Mousawi M. Postrenal transplantation urologic complications. *Transplant Proc* 2008; **40**: 2345-2346 [PMID: 18790231 DOI: 10.1016/j.transproceed.2008.06.036]
  - 20 **Yigit B**, Tellioglu G, Berber I, Aydin C, Kara M, Yanaral F, Titiz I. Surgical treatment of urologic complications after renal transplantation. *Transplant Proc* 2008; **40**: 202-204 [PMID: 18261587 DOI: 10.1016/j.transproceed.2007.11.024]
  - 21 **Samhan M**, Al-Mousawi M, Hayati H, Abdulhalim M, Nampoory MR. Urologic complications after renal transplantation. *Transplant Proc* 2005; **37**: 3075-3076 [PMID: 16213309 DOI: 10.1016/j.transproceed.2005.07.047]
  - 22 **Lempinen M**, Stenman J, Kyllönen L, Salmela K. Surgical complications following 1670 consecutive adult renal transplantations: A single center study. *Scand J Surg* 2015; **104**: 254-259 [PMID: 25567856 DOI: 10.1177/1457496914565419]
  - 23 **Nie ZL**, Zhang KQ, Li QS, Jin FS, Zhu FQ, Huo WQ. Treatment of urinary fistula after kidney transplantation. *Transplant Proc* 2009; **41**: 1624-1626 [PMID: 19545693 DOI: 10.1016/j.transproceed.2008.10.103]
  - 24 **Dalgic A**, Boyvat F, Karakayali H, Moray G, Emiroglu R, Haberal M. Urologic complications in 1523 renal transplantations: The Baskent University experience. *Transplant Proc* 2006; **38**: 543-547 [PMID: 16549170 DOI: 10.1016/j.transproceed.2005.12.116]
  - 25 **Thomalla JV**, Leapman SB, Filo RS. The use of internalised ureteric stents in renal transplant recipients. *Br J Urol* 1990; **66**: 363-368 [PMID: 2224430 DOI: 10.1111/j.1464-410X.1990.tb14955.x]
  - 26 **Kumar A**, Verma BS, Srivastava A, Bhandari M, Gupta A, Sharma R. Evaluation of the urological complications of living related renal transplantation at a single center during the last 10 years: impact of the Double-J\* stent. *J Urol* 2000; **164**: 657-660 [PMID: 10953120 DOI: 10.1016/S0022-5347(05)67275-8]
  - 27 **Sabnis RB**, Singh AG, Ganpule AP, Chhabra JS, Tak GR, Shah JH. The development and current status of minimally invasive surgery to manage urological complications after renal transplantation. *Indian J Urol* 2016; **32**: 186-191 [PMID: 27555675 DOI: 10.4103/0970-1591.185100]
  - 28 **Hamouda M**, Sharma A, Halawa A. Urine Leak After Kidney Transplant: A Review of the Literature. *Exp Clin Transplant* 2018; **16**: 90-95 [PMID: 29409437]
  - 29 **Son H**, Heiba S, Kostakoglu L, Machac J. Extraperitoneal urine leak after renal transplantation: the role of radionuclide imaging and the value of accompanying SPECT/CT - a case report. *BMC Med Imaging* 2010; **10**: 23 [PMID: 20961409 DOI: 10.1186/1471-2342-10-23]
  - 30 **Sui W**, Lipsky MJ, Matulay JT, Robins DJ, Onyeji IC, James MB, Theofanides MC, Wenske S. Timing and Predictors of Early Urologic and Infectious Complications After Renal Transplant: An Analysis of a New York Statewide Database. *Exp Clin Transplant* 2017 [PMID: 28697717 DOI: 10.6002/ect.2016.0357]
  - 31 **Karam G**, Maillet F, Parant S, Soullilou JP, Giral-Classe M. Ureteral necrosis after kidney transplantation: risk factors and impact on graft and patient survival. *Transplantation* 2004; **78**: 725-729 [PMID: 15371676 DOI: 10.1097/01.TP.0000131953.13414.99]
  - 32 **Zavos G**, Pappas P, Karatzas T, Karidis NP, Bokos J, Stravodimos K, Theodoropoulou E, Boletis J, Kostakis A. Urological complications: analysis and management of 1525 consecutive renal transplantations. *Transplant Proc* 2008; **40**: 1386-1390 [PMID: 18589113 DOI: 10.1016/j.transproceed.2008.03.103]
  - 33 **Shoskes DA**, Hanbury D, Cranston D, Morris PJ. Urological complications in 1,000 consecutive renal transplant recipients. *J Urol* 1995; **153**: 18-21 [PMID: 7966766 DOI: 10.1097/00005392-19950100-000008]
  - 34 **Mahdavi-Zafarghani R**, Taghavi R. Urological complications following renal transplantation: assessment in 500 recipients. *Transplant Proc* 2002; **34**: 2109-2110 [PMID: 12270332 DOI: 10.1016/S0041-1345(02)02870-1]
  - 35 **Dinckan A**, Tekin A, Turkyilmaz S, Kocak H, Gurkan A, Erdogan O, Tuncer M, Demirbas A. Early and late urological complications corrected surgically following renal transplantation. *Transpl Int* 2007; **20**: 702-707 [PMID: 17511829 DOI: 10.1111/j.1432-2277.2007.00500.x]
  - 36 **Englesbe MJ**, Dubay DA, Gillespie BW, Moyer AS, Pelletier SJ, Sung RS, Magee JC, Punch JD, Campbell DA Jr, Merion RM. Risk factors for urinary complications after renal transplantation. *Am J Transplant* 2007; **7**: 1536-1541 [PMID: 17430402 DOI: 10.1111/j.1600-6143.2007.01790.x]
  - 37 **Rahnemai-Azar AA**, Gilchrist BF, Kayler LK. Independent risk factors for early urologic complications after kidney transplantation. *Clin Transplant* 2015; **29**: 403-408 [PMID: 25683841 DOI: 10.1111/ctr.12530]
  - 38 **Slagt IK**, Ijzermans JN, Visser LJ, Weimar W, Roodnat JJ, Terkivatan T. Independent risk factors for urological complications after deceased donor kidney transplantation. *PLoS One* 2014; **9**: e91211 [PMID: 24608797 DOI: 10.1371/journal.pone.0091211]
  - 39 **Mazzucchi E**, Souza GL, Hisano M, Antonopoulos IM, Piovesan AC, Nahas WC, Lucon AM, Srougi M. Primary reconstruction is a good option in the treatment of urinary fistula after kidney transplantation. *Int Braz J Urol* 2006; **32**: 398-403; discussion 403-4 [PMID: 16953905 DOI: 10.1590/S1677-55382006000400003]
  - 40 **Philosophie B**, Kuo PC, Schweitzer EJ, Farney AC, Lim JW, Johnson LB, Jacobs S, Flowers JL, Cho ES, Bartlett ST. Laparoscopic versus open donor nephrectomy: comparing ureteral complications in the recipients and improving the laparoscopic technique. *Transplantation* 1999; **68**: 497-502 [PMID: 10480406 DOI: 10.1097/00007890-199908270-00009]
  - 41 **POLITANO VA**, LEADBETTER WF. An operative technique for the correction of vesicoureteral reflux. *J Urol* 1958; **79**: 932-941 [PMID: 13539988 DOI: 10.1016/S0022-5347(17)66369-9]
  - 42 **Konnak JW**, Herwig KR, Turcotte JG. External ureteroneocystostomy in renal transplantation. *J Urol* 1972; **108**: 380-381 [PMID: 4559504 DOI: 10.1016/S0022-5347(17)60747-X]
  - 43 **Lee RS**, Bakthavatsalam R, Marsh CL, Kuhr CS. Ureteral complications in renal transplantation: a comparison of the Lich-Gregoir versus the Taguchi technique. *Transplant Proc* 2007; **39**: 1461-1464 [PMID: 17580162 DOI: 10.1016/j.transproceed.2006.11.017]
  - 44 **Zargar MA**, Shahrokh H, Mohammadi Fallah MR, Zargar H. Comparing Taguchi and anterior Lich-Gregoir ureterovesical reimplantation techniques for kidney transplantation. *Transplant Proc* 2005; **37**: 3077-3078 [PMID: 16213310 DOI: 10.1016/j.transproceed.2005.08.006]
  - 45 **Alberts VP**, Idu MM, Legemate DA, Laguna Pes MP, Minnee RC. Ureterovesical anastomotic techniques for kidney transplantation: a systematic review and meta-analysis. *Transpl Int* 2014; **27**: 593-605 [PMID: 24606191 DOI: 10.1111/tri.12301]
  - 46 **Butterworth PC**, Horsburgh T, Veitch PS, Bell PR, Nicholson ML. Urological complications in renal transplantation: impact of a change of technique. *Br J Urol* 1997; **79**: 499-502 [PMID: 9126075 DOI: 10.1046/j.1464-410X.1997.00117.x]
  - 47 **Thrasher JB**, Temple DR, Spees EK. Extravesical versus Leadbetter-Politano ureteroneocystostomy: a comparison of urological

- complications in 320 renal transplants. *J Urol* 1990; **144**: 1105-1109 [PMID: 2231880 DOI: 10.1016/S0022-5347(17)39669-6]
- 48 **Wilson CH**, Rix DA, Manas DM. Routine intraoperative ureteric stenting for kidney transplant recipients. *Cochrane Database Syst Rev* 2013; **(6)**: CD004925 [PMID: 23771708 DOI: 10.1002/14651858.CD004925.pub3]
- 49 **Titton RL**, Gervais DA, Hahn PF, Harisinghani MG, Arellano RS, Mueller PR. Urine leaks and urinomas: diagnosis and imaging-guided intervention. *Radiographics* 2003; **23**: 1133-1147 [PMID: 12975505 DOI: 10.1148/rgr.235035029]
- 50 **Charlesworth M**, Marangoni G, Ahmad N. High ureteric injury following multiorgan recovery: successful kidney transplant with Boari flap ureterocystostomy reconstruction. *Arab J Nephrol Transplant* 2011; **4**: 155-158 [PMID: 22026340 DOI: 10.4314/ajnt.v4i3.71028]
- 51 **Shokeir AA**, Shamaa MA, Bakr MA, el-Diasty TA, Ghoneim MA. Salvage of difficult transplant urinary fistulae by ileal substitution of the ureter. *Scand J Urol Nephrol* 1993; **27**: 537-540 [PMID: 8159928 DOI: 10.3109/00365599309182291]
- 52 **Iezzi R**, la Torre MF, Santoro M, Dattesi R, Nestola M, Posa A, Romagnoli J, Citterio F, Bonomo L. Interventional radiological treatment of renal transplant complications: a pictorial review. *Korean J Radiol* 2015; **16**: 593-603 [PMID: 25995689 DOI: 10.3348/kjr.2015.16.3.593]
- 53 **Matalon TA**, Thompson MJ, Patel SK, Ramos MV, Jensik SC, Merkel FK. Percutaneous treatment of urine leaks in renal transplantation patients. *Radiology* 1990; **174**: 1049-1051 [PMID: 2305088 DOI: 10.1148/radiology.174.3.174-3-1049]
- 54 **Campbell SC**, Streem SB, Zelch M, Hodge E, Novick AC. Percutaneous management of transplant ureteral fistulas: patient selection and long-term results. *J Urol* 1993; **150**: 1115-1117 [PMID: 8371367 DOI: 10.1016/S0022-5347(17)35701-4]
- 55 **Alcaraz A**, Bujons A, Pascual X, Juaneda B, Martí J, de la Torre P, Guirado L, Díaz JM, Ribal MJ, Solá R, Villavicencio H. Percutaneous management of transplant ureteral fistulae is feasible in selected cases. *Transplant Proc* 2005; **37**: 2111-2114 [PMID: 15964353 DOI: 10.1016/j.transproceed.2005.03.118]

**P- Reviewer:** Boteon YL, Kim JS **S- Editor:** Ji FF

**L- Editor:** Filipodia **E- Editor:** Yin SY





Published by **Baishideng Publishing Group Inc**  
7901 Stoneridge Drive, Suite 501, Pleasanton, CA 94588, USA  
Telephone: +1-925-223-8242  
Fax: +1-925-223-8243  
E-mail: [bpgoffice@wjgnet.com](mailto:bpgoffice@wjgnet.com)  
Help Desk: <http://www.f6publishing.com/helpdesk>  
<http://www.wjgnet.com>

