

# World Journal of *Gastroenterology*

*World J Gastroenterol* 2019 February 28; 25(8): 888-1036



**REVIEW**

- 888** Current and future pharmacological therapies for managing cirrhosis and its complications  
*Kockerling D, Nathwani R, Forlano R, Manousou P, Mullish BH, Dhar A*

**MINIREVIEWS**

- 909** Outcomes of per oral endoscopic pyloromyotomy in gastroparesis worldwide  
*Mekaroonkamol P, Shah R, Cai Q*

**ORIGINAL ARTICLE****Basic Study**

- 923** Dbx2 exhibits a tumor-promoting function in hepatocellular carcinoma cell lines *via* regulating Shh-Gli1 signaling  
*Hu YT, Li BF, Zhang PJ, Wu D, Li YY, Li ZW, Shen L, Dong B, Gao J, Zhu X*
- 941** Dynamic changes of key metabolites during liver fibrosis in rats  
*Yu J, He JQ, Chen DY, Pan QL, Yang JF, Cao HC, Li LJ*
- 955** Procyanidin B2 protects against diet-induced obesity and non-alcoholic fatty liver disease *via* the modulation of the gut microbiota in rabbits  
*Xing YW, Lei GT, Wu QH, Jiang Y, Huang MX*

**Case Control Study**

- 967** Triggers of histologically suspected drug-induced colitis  
*Brechmann T, Günther K, Neid M, Schmiegell W, Tannapfel A*

**Retrospective Study**

- 980** Women on the liver transplantation waitlist are at increased risk of hospitalization compared to men  
*Rubin JB, Sinclair M, Rahimi RS, Tapper EB, Lai JC*
- 989** Two-year delay in ulcerative colitis diagnosis is associated with anti-tumor necrosis factor alpha use  
*Kang HS, Koo JS, Lee KM, Kim DB, Lee JM, Kim YJ, Yoon H, Jang HJ*
- 1002** Big-data analysis: A clinical pathway on endoscopic retrograde cholangiopancreatography for common bile duct stones  
*Zhang W, Wang BY, Du XY, Fang WW, Wu H, Wang L, Zhuge YZ, Zou XP*

**Observational Study**

- 1012** Lethal-7-related polymorphisms are associated with susceptibility to and prognosis of gastric cancer  
*Jia ZF, Cao DH, Wu YH, Jin MS, Pan YC, Cao XY, Jiang J*

**EVIDENCE-BASED MEDICINE**

- 1024** Establishing a model to measure and predict the quality of gastrointestinal endoscopy  
*Wang LW, Lin H, Xin L, Qian W, Wang TJ, Zhang JZ, Meng QQ, Tian B, Ma XD, Li ZS*

**CASE REPORT**

- 1031** Crohn's-like acute severe colitis associated with Hermansky-Pudlak syndrome: A case report  
*Giroit P, Le Berre C, De Maissin A, Freyssinet M, Trang-Poisson C, Bourreille A*

**ABOUT COVER**

Editorial board member of *World Journal of Gastroenterology*, Yoshihiro Ikura, DSc, MD, Chief Doctor, Professor, Department of Pathology, Takatsuki General Hospital, Takatsuki 569-1192, Osaka, Japan

**AIMS AND SCOPE**

*World Journal of Gastroenterology* (*World J Gastroenterol*, *WJG*, print ISSN 1007-9327, online ISSN 2219-2840, DOI: 10.3748) is a peer-reviewed open access journal. The *WJG* Editorial Board consists of 642 experts in gastroenterology and hepatology from 59 countries.

The primary task of *WJG* is to rapidly publish high-quality original articles, reviews, and commentaries in the fields of gastroenterology, hepatology, gastrointestinal endoscopy, gastrointestinal surgery, hepatobiliary surgery, gastrointestinal oncology, gastrointestinal radiation oncology, etc. *WJG* is dedicated to become an influential and prestigious journal in gastroenterology and hepatology, to promote the development of above disciplines, and to improve the diagnostic and therapeutic skill and expertise of clinicians.

**INDEXING/ABSTRACTING**

The *WJG* is now indexed in Current Contents®/Clinical Medicine, Science Citation Index Expanded (also known as SciSearch®), Journal Citation Reports®, Index Medicus, MEDLINE, PubMed, PubMed Central, Scopus and Directory of Open Access Journals. The 2018 edition of Journal Citation Report® cites the 2017 impact factor for *WJG* as 3.300 (5-year impact factor: 3.387), ranking *WJG* as 35<sup>th</sup> among 80 journals in gastroenterology and hepatology (quartile in category Q2).

**RESPONSIBLE EDITORS FOR THIS ISSUE**

Responsible Electronic Editor: *Shu-Yu Yin*

Proofing Editorial Office Director: *Ze-Mao Gong*

**NAME OF JOURNAL**

*World Journal of Gastroenterology*

**ISSN**

ISSN 1007-9327 (print) ISSN 2219-2840 (online)

**LAUNCH DATE**

October 1, 1995

**FREQUENCY**

Weekly

**EDITORS-IN-CHIEF**

Subrata Ghosh, Andrzej S Tarnawski

**EDITORIAL BOARD MEMBERS**

<http://www.wjgnet.com/1007-9327/editorialboard.htm>

**EDITORIAL OFFICE**

Ze-Mao Gong, Director

**PUBLICATION DATE**

February 28, 2019

**COPYRIGHT**

© 2019 Baishideng Publishing Group Inc

**INSTRUCTIONS TO AUTHORS**

<https://www.wjgnet.com/bpg/gerinfo/204>

**GUIDELINES FOR ETHICS DOCUMENTS**

<https://www.wjgnet.com/bpg/GerInfo/287>

**GUIDELINES FOR NON-NATIVE SPEAKERS OF ENGLISH**

<https://www.wjgnet.com/bpg/gerinfo/240>

**PUBLICATION MISCONDUCT**

<https://www.wjgnet.com/bpg/gerinfo/208>

**ARTICLE PROCESSING CHARGE**

<https://www.wjgnet.com/bpg/gerinfo/242>

**STEPS FOR SUBMITTING MANUSCRIPTS**

<https://www.wjgnet.com/bpg/GerInfo/239>

**ONLINE SUBMISSION**

<https://www.f6publishing.com>



## Outcomes of per oral endoscopic pyloromyotomy in gastroparesis worldwide

Parit Mekaroonkamol, Rushikesh Shah, Qiang Cai

**ORCID number:** Parit Mekaroonkamol (0000-0002-3206-3431); Rushikesh Shah (0000-0001-5472-9196); Qiang Cai (0000-0002-9931-5410).

**Author contributions:** All authors have contributed to this study.

**Conflict-of-interest statement:** All the Authors have no conflict of interest related to the manuscript.

**Open-Access:** This article is an open-access article which was selected by an in-house editor and fully peer-reviewed by external reviewers. It is distributed in accordance with the Creative Commons Attribution Non Commercial (CC BY-NC 4.0) license, which permits others to distribute, remix, adapt, build upon this work non-commercially, and license their derivative works on different terms, provided the original work is properly cited and the use is non-commercial. See: <http://creativecommons.org/licenses/by-nc/4.0/>

**Manuscript source:** Invited manuscript

**Received:** October 30, 2018

**Peer-review started:** November 1, 2018

**First decision:** November 29, 2018

**Revised:** January 10, 2019

**Accepted:** January 26, 2019

**Article in press:** January 26, 2019

**Published online:** February 28, 2019

**Parit Mekaroonkamol, Rushikesh Shah, Qiang Cai**, Division of Digestive Diseases, Emory University School of Medicine, Atlanta, GA 30322, United States

**Corresponding author:** Qiang Cai, MD, PhD, Professor, Division of Digestive Diseases, Emory University School of Medicine, 1365 Clifton Road, B1262, Atlanta, GA 30322, United States. [qcai@emory.edu](mailto:qcai@emory.edu)

**Telephone:** +1-4047782714

**Fax:** +1-4047782578

### Abstract

Per oral endoscopic pyloromyotomy (POP), also known as gastric per-oral endoscopic myotomy (GPOEM), is a novel procedure with promising potential for the treatment of gastroparesis. As more data emerge and the procedure is becoming more recognized in clinical practice, its safety and efficacy need to be carefully evaluated. Appropriate patient selection for favorable clinical success prediction after GPOEM also needs additional research. This review aims to systemically summarize the existing data on clinical outcomes of POP. Symptomologic responses to the procedure, its adverse effects, procedural techniques, and predictive factors of clinical success are also discussed.

**Key words:** Gastroparesis; Per oral endoscopic pyloromyotomy; Gastric per-oral endoscopic myotomy; Pyloromyotomy; Outcomes

©The Author(s) 2019. Published by Baishideng Publishing Group Inc. All rights reserved.

**Core tip:** Per oral endoscopic pyloromyotomy (POP), or gastric per oral endoscopic myotomy is a viable therapeutic modality for patients with medically refractory gastroparesis. POP has demonstrated promising mid-term clinic outcomes in up to 18 mo follow-up period. However, most published studies were single-center and retrospective. Duration of the disease, prior response to intrapyloric botulinum injection, and increased pyloric cross-sectional area has been described as predictive factors for POP outcome. Impedance planimetry can be used to evaluate pyloric dysfunction. However, the reliability of these factors still needs clinical validation.

**Citation:** Mekaroonkamol P, Shah R, Cai Q. Outcomes of per oral endoscopic pyloromyotomy in gastroparesis worldwide. *World J Gastroenterol* 2019; 25(8): 909-922

**URL:** <https://www.wjgnet.com/1007-9327/full/v25/i8/909.htm>

**DOI:** <https://dx.doi.org/10.3748/wjg.v25.i8.909>

## INTRODUCTION

Gastroparesis is a chronic disabling disease with a complex pathophysiology that is still poorly understood. Its rising prevalence and hospitalization rate are alarmingly concerning<sup>[1]</sup>. The three main etiology cited for gastroparesis include idiopathic, diabetic related and post-surgical. Gastroparesis clinically manifests as recurrent postprandial nausea and vomiting, early satiety post prandial bloating and upper abdominal pain<sup>[2]</sup>. In severe cases, it can also lead to weight loss and malnutrition<sup>[3]</sup>. The diagnosis of gastroparesis is suspected by constellation of these clinical symptoms. The diagnosis is further confirmed based on normal upper endoscopy ruling out any structural obstruction and 4 h gastric emptying study proving impaired gastric emptying<sup>[2]</sup>. Gastroparesis, due to recurrent debilitating nature of disease has significant negative impact on patients' quality of life, economic burden, and health care utilization while only with limited therapeutic options<sup>[4]</sup>. Only few prokinetic medications are available for symptomatic control. Most of which have limited long-term usage due to their side effects or tachyphylaxis<sup>[5]</sup>. Metoclopramide and domperidone, a D2 dopamine receptor antagonist, are the most widely used but only metoclopramide is Food and Drug Administration (FDA) approved in the United States while domperidone is available in Europe, Canada, Mexico, and New Zealand<sup>[5,6]</sup>. Metoclopramide also carries a significant risk of extrapyramidal adverse effects, including tardive dyskinesia when taken longer than 12 wk. Other groups of medication, such as 5-HT<sub>3</sub> receptor antagonists, phenothiazines, and muscarinic cholinergic receptor antagonist, have been used off-label for symptomatic relieve but they do not have effect of gastric motility. While medications and dietary modification are the first line treatment, approximately 30% of patients do not respond to conservative management<sup>[7]</sup>. These limitations of medical therapy highlights the need for an alternate therapeutic option<sup>[8]</sup>.

Non-medical treatments of gastroparesis include gastric electric stimulator, surgical pyloroplasty, botulinum toxin injection, and transpyloric stenting. The concept of neurostimulation and pylorus-directed therapies stem from a physiologic knowledge of gastric emptying that involves both gastric motility and pyloric clearance<sup>[9]</sup>. Gastric motility is driven by the interstitial cells of Cajal, the pacemaker of the gut, which rhythmically generate a slow wave impulse spanning from the greater curvature toward the pylorus. Gastric electrical stimulator was developed based on the principle that the amplitude, frequency, and direction of these electrical activities help control the gastric emptying function<sup>[10-12]</sup>.

Although the efficacy of gastric electrical stimulation was promising in the early open-label studies but their results were not consistently reproduced in subsequent randomized control trials, which raises concern for the true clinical impact of this modality on gastroparesis<sup>[7,13-20]</sup>. In addition, gastric electrical stimulator requires surgery for placement and has been only approved based on the humanitarian device exception rule, rather than an effective therapy by the United States FDA<sup>[21]</sup>. Implantation and device-associated adverse effects such as pocket infection, sepsis, pulmonary embolism, stroke, or even death have been reported<sup>[21]</sup>.

Even though the pylorus lacks slow-wave impulses, its tone and phasic contraction determines the outlet phase of gastric emptying<sup>[11]</sup>. Abnormal physiologic characteristics of the pylorus such as narrow cross-sectional area, diameter, increased pressure, distensibility, and prolonged phasic contraction or increased tone have been shown to delay gastric emptying<sup>[9,11,22-24]</sup>. Other pathophysiology, including antroduodenal hypomotility, impaired fundic accommodation, and pylorospasm, all of which also interact with one another, are believed to play major roles in gastroparesis<sup>[25]</sup>.

Therefore, mechanical disruption of the pyloric muscle is believed to have effects on global gastric emptying as well. This notion of pylorus-directed therapy was strengthened by recent studies on surgical pyloroplasty, transpyloric stenting, and intrapyloric botulinum injection that improved both symptoms score and gastric emptying time<sup>[26-33]</sup>. However, the efficacy of intrapyloric botulinum injection was not demonstrated in subsequent randomized controlled trials and is no longer recommended by American College of Gastroenterology, while transpyloric stenting is only a temporizing measure and not a long term solution<sup>[8,34,35]</sup>.

With the significant advancement in the field of submucosal endoscopy in the last few years, per oral endoscopic pyloromyotomy (POP), also known as gastric per oral endoscopic myotomy (GPOEM), has emerged as a pylorus-directed therapy for gastroparesis. The procedure was conceptually originated from POEM, a similar endoscopic procedure for treatment of achalasia. They both use submucosal tunneling technique to reach and dissect the target muscles, lower esophageal sphincter in achalasia and pyloric ring in gastroparesis<sup>[36]</sup>. The submucosal space offers a safe conduit to carry out pyloromyotomy via endoscopy, rather than surgery<sup>[37-39]</sup>. Due to



its minimally-invasive nature and its promising outcomes, this novel procedure has quickly gained popularity worldwide. The first human case of POP was performed by Khashab *et al*<sup>[39]</sup> in 2013 without any adverse event and demonstrated significant clinical improvement at 12-wk follow up. Subsequently in 2014, the first human case of POP was performed successfully in Europe and later in 2015, a case series of 7 patients was published on POP outcomes<sup>[37]</sup>. Since then, many single-center and a few multicenter studies have been published reporting short term outcomes on POP in gastroparesis patients, mostly in retrospective fashion (Table 1)<sup>[39-42]</sup>. The reported symptomatic responses and clinical outcomes have been very promising<sup>[2,37,40,43-48]</sup>. This review aims to examine current evidence on clinical outcome of POP.

## PROCEDURAL TECHNIQUES

The procedural steps of POP follow the established sequence of POEM (Figure 1) as: (1) Mucosotomy to create an entry to submucosal plane; (2) submucosal tunnel is created using submucosal dissection technique; (3) myotomy of the targeted muscle; and (4) mucosal defect closure. However, POP is generally considered more technical demanding than POEM for a few reasons: (1) The direction of the submucosal tunnel is curved, as opposed to a straight tube in esophagus; (2) there is more movement in the procedural field from antral contractility, compared to a aperistaltic esophagus; (3) identification of the targeted muscle, the pyloric ring in POP, is more difficult than identifying lower esophageal sphincter in POEM due to both aforementioned reasons rendering risk for tunnel deviation from the desired axis; (4) the wall of duodenal bulb is much thinner than gastric cardia, increasing risk for perforation; and (5) the maneuverability of the scope is more limited due to an inevitable loop in the stomach.

In addition, due to its novelty, there is a lack of standardized technique for POP. Extent and depth of pyloromyotomy may vary depending on endoscopist's preference and how well the pyloric ring can be identified in the submucosal tunnel. Most report suggested performing the procedure in supine position as it will be easier to orient the scope direction but left lateral decubitus position may be required when a large gastric loop is present<sup>[49]</sup>. Prolonged period of clear liquid diet for 2-3 d both before and after POP was recommended as a routine pre- and post-procedure protocol to maximize visualization and reduce the risk of procedure-related infection<sup>[2,49]</sup>. Generous irrigation should be exercised to clean the stomach content and mucosotomy site. Gentamycin rinse was advocated by some centers<sup>[47]</sup>. Other technical variations among endoscopists include site of mucosal entry (lesser *vs* greater curve), mucosotomy closure tools (clips *vs* suture), depth of pyloromyotomy, and the need for fluoroscopy<sup>[2,45,50-52]</sup>. Though general anesthesia is recommended in all studies but conscious sedation in endoscopy suite can be safely and successfully performed as well<sup>[49]</sup>. Intravenous antibiotic prophylaxis is routinely administered though there is no high-quality evidence to support the practice. Proper antibiotic, dosing, and duration are still not yet refined. How much impact on these minor variations have on clinical response is also not known.

In the early studies, mucosal entry was performed mainly on the greater curve or anterior wall of the stomach and full thickness myotomy was reported<sup>[37,53,54]</sup>. However, subsequent studies verified that submucosal tunnel can be safely and effectively performed regardless of the site of mucosal entry and selective circular myotomy can achieve clinical success without the perforation risk in full thickness myotomy<sup>[41,47,48,55,56]</sup>. While mucosotomy on the greater curve makes the scope more in a neutral position and allows greater maneuverability, performing a mucosal entry on the lesser curve has its own advantages that are: (1) Shorter scope length to mucosotomy site by minimizing the gastric loop; (2) shorter length of the submucosal tunnel, reducing the risk of tunneling in the wrong direction; and (3) the procedural field is not a dependent area when the patient is on supine position, therefore blood and food would not interfere with the endoscopic visualization<sup>[48,49,55]</sup>.

Though the type of endoscopic knife and injectant used during POP have been heterogeneous in various reports, which included triangle-tip knife (KD-640 L, Olympus, Tokyo, Japan), hybrid knife (ERBE, Germany), a hook knife (KD-620LR; Olympus, Japan), mixed methylene blue/indigo carmine with hypertonic saline, normal saline, or hydroxy-ethyl starch, but common devices that are considered mandatory are silicone-base transparent over-the-scope cap and carbon dioxide for insufflation during the procedure. The cap facilitates submucosal entry, creates a working space in the submucosal tunnel, and also helps with hemostasis from small vessels in the tunnel. Due to submucosal nature of the procedure, pneumoperitoneum can occur. Carbon dioxide, which is absorbed 160 times faster than nitrogen gas in room air is essential to minimize this risk<sup>[57]</sup>. For hemostasis, soft coagulation mode

Table 1 Clinical outcomes of per oral endoscopic pyloromyotomy

	Type	N	Etiology of gastroparesis	Definition of refractory gastroparesis	Average Procedure duration (min)	Outcome measurement	Clinical response definition	Clinical response rate N (%)	GCSI improvement	Subscale	Adverse event	Follow-up period (mo) (Additional treatment during follow up)
Shlomovitz <i>et al</i> <sup>[37]</sup>	Retrospective	7	2 PSG; 4 IG; 1 patient with normal GES	Not defined	90-120	GES (3M); Gastroparesis; Symptoms	Symptomatic improvement	85.7%	NA	Nausea and epigastric burn significantly improved	One prepyloric ulcer with GI bleed	6.5 (2-11) (1 patient required Laparoscopic pyloroplasty at 7 mo, also no response after the procedure)
Chung <i>et al</i> <sup>[41]</sup>	Retrospective	8	4 DG; 4 PSG	Not defined		GOOSS; GES	NA	NA	NA	Nausea; Vomiting; Abdominal pain	1 bleeding prepyloric ulcer; 1 dumping syndrome	7
Khashab <i>et al</i> <sup>[45]</sup>	Retrospective	30	11 DG; 12 PSG; 7 IG	Presence of symptoms despite dietary; Modification and treatment with prokinetics and antiemetics	72 ± 42	GES (3M); Gastroparesis Symptoms (Graded self-reported symptomatic responses: Resolved, improved, unchanged or worse)	Reduction in gastroparesis symptoms with absence of recurrent hospitalization	86%	NA	97% improve nausea; 63% improve in vomiting; 73% improve in abdominal pain; 93% maintain or gain weight	6.7% 1 capnoperitonum; 1 prepyloric ulcer	5.5
Gonzalez <i>et al</i> <sup>[2]</sup> France	Retrospective	29	7 DG 5 PSG; 15 IG; 2 Other (Scleroderma)	Symptoms > 6 mo despite Rx and fail "all" prokinetic drug, GCSI > 1.5	47	GES (2M); GCSI	Improvement in GCSI and GES	79% (3M); 69% (6M)	3.3 to 1.1	All GCSI	5 pneumoperitoneum; 2 Bleeding; 1 perigastric abscess (patient ate 2 h post-procedure) 1 delayed prepyloric stricture	6



Dacha <i>et al</i> <sup>[43]</sup>	Retrospective	16	9 DG; 1 PSG; 5 IG; 1 PIG	Patients who failed to respond to dietary modification, prokinetic medication, or electrical stimulator	49.7 ± 22.1	GES; GCSI; SF36	A decrease in mean GCSI with an improvement of at least 2 subsets of cardinal symptoms and no gastroparesis-related hospitalization	81%	3.4 to 1.5	N/V and early satiety significantly improved but not bloating	none	12
Rodriguez <i>et al</i> <sup>[48]</sup>	Prospective observation	47	12 DG; 8 PSG; 27 IG	Patients with ongoing symptoms after at least 6 mo of medical therapy	41.2 ± 28.5	GES; GCSI	improvement in post-procedure GCSI, a decrease in the total number of gastroparesis medications used, and improved GES at 90-day	Not reported	3.6 to 3.3	All 3 subscales were significantly improved but N/V and bloating improved the most	none	3 (1 pt had lap total gastrectomy at 9 mo)
Alleman <i>et al</i> <sup>[55]</sup>	Retrospective	57	Not reported	Not clearly defined	41	GCSI	Improved GCSI	Not reported	4.6 to 3.3	Not reported	Not reported	3
Malik <i>et al</i> <sup>[47]</sup>	Case series	13	1 DG; 8 PSG; 4 IG	Not clearly defined	± 23	GES; PAGI-SYM; EndoFLIP	Improved GCSI, CPGAS, and GES	72.7%	2.1 to 1.9	Vomiting, retching, and loss of appetite improved the most by 29, 24, and 24%. None was statistically significant; Abd distension was actually worse	1 pulm embolism	3
Mekaroonkamol <i>et al</i> <sup>[62]</sup>	Retrospective	30	12 DG; 5 PSG; 12 IG; 1 PIG	Patients who failed to respond or could not tolerate to dietary modification, prokinetic medication, or electrical stimulator	48.3 ± 16.5	GES (2M); GCSI; SF36; ER visit rate; Hospitalization rate	Decrease in at least 1 averaged point of GCSI with more than a 25% decrease in at least 2 subscales > 25% increase in the mean SF-36 score with at least 50% increase in 3 categories	83.3%	3.6 to 1.4	Nausea and early satiety significantly improved; Pain only improved up to 6 mo but not thereafter	1 tension capnoperitoneum (3.3%)	18

Jacques <i>et al</i> <sup>[61]</sup>	Prospective	20	10 DG; 1 PSG; 4 IG; 5 Other (including 3 Sjogren, 1 Parkinson's, and 1 systemic sclerosis)	Symptoms > 6 mo despite medication n, GCSI > 2.6 OR refractory vomiting, uncontrolled post-prandial hypoglycemia, need for oral medication, Fail at least 2 out of 3 prokinetic drug	56.5	GES (3M); GCSI; PAGI-QoL; GIQLI; EndoFLIP; Abdominal pain score	A decrease of more than 0.75 point of GCSI	90%	3.5 to 1.3	All 9 subscale of GCSI except for retching	4 perforation, including 1 required surgical intervention1 case of epistaxis	3
Kahaleh <i>et al</i> <sup>[58]</sup>	Retrospective	33	7 DG; 12 PSG; 13 IG; 1 Other	Not clearly defined	77.6 (37-255)	GES; GCSI	Improvement in GCSI and GES	85%	3.3 to 0.8	All subscale including abdominal pain significantly improved	1 bleeding and 1 ulcer	11.5
Hustak <i>et al</i> <sup>[59]</sup>	Prospective	7	2 DG; 4 PSG; 1 IG	Not clearly defined	70	GES; GCSI	Improvement in GCSI of > 40% and GES	100%	3.26 to 1.24	Not reported	1 bleeding ulcer	12
Mekaroonkamol <i>et al</i> <sup>[62]</sup>	Retrospective	40	15 DG; 5 PSG; 18 IG; 1 PIG; 1 Other (Ehlers Danlos)	Patients who failed to respond or could not tolerate to dietary modification, prokinetic medication, or electrical stimulator	Not reported	GES (2M); GCSI; SF36	Decrease in at least 1 averaged point of GCSI with more than a 25% decrease in at least 2 subscales	Not reported	3.6 to 1.9	Only nausea/vomiting and early satiety improved, but not for bloating	1 capnoperiteum; 1 COPD exacerbation; 1 myotomy dehiscence	18

<sup>1</sup>Multicenter trial, two centers in the United States were involved.

<sup>2</sup>Abstract only publications.

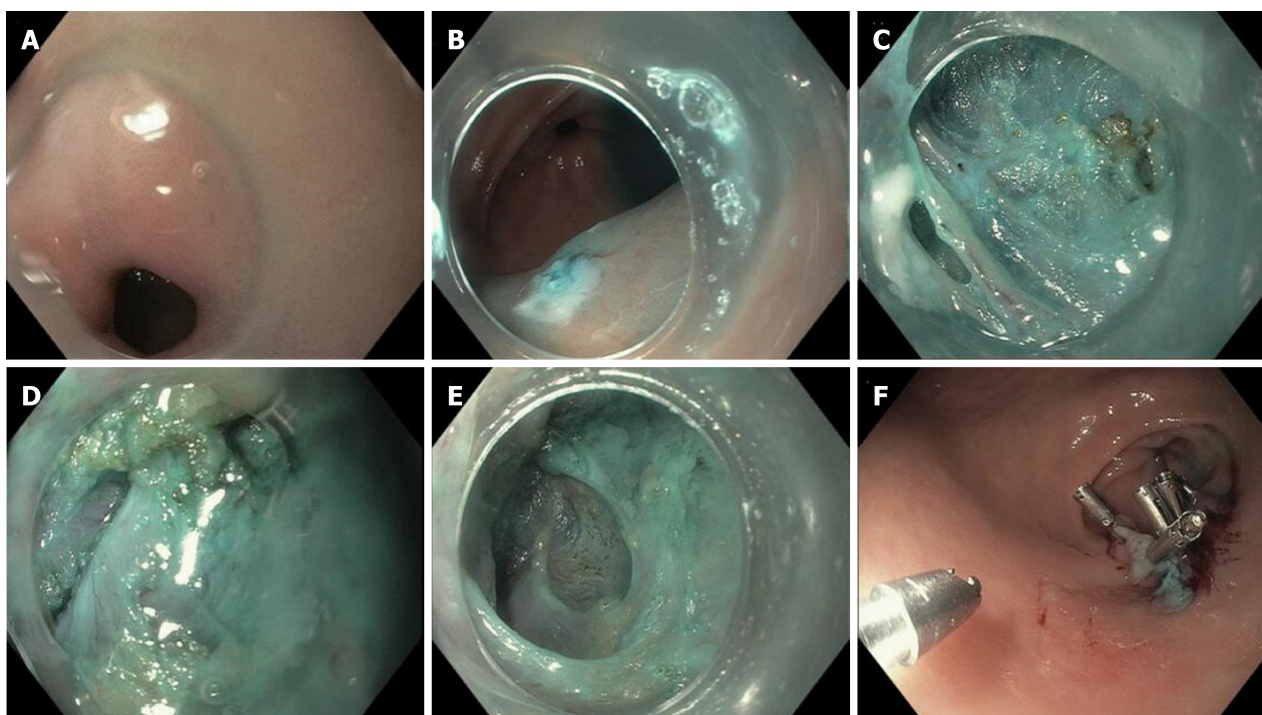
DG: Diabetic gastroparesis; PSG: Post-surgical gastroparesis; IG: Idiopathic gastroparesis; PIG: Post-infectious gastroparesis; GES: Gastric emptying scintigraphy; GCSI: Gastroparesis cardinal symptoms index; GOOSS: Gastric outlet obstruction scoring system; SF36: Short form 36; PAGI-SYM: Patient Assessment of Gastrointestinal Symptoms; N/V: Nausea and vomiting; EndoFLIP: Endoscopic functional luminal imaging probe; CPGAS: Clinical Patient Grading Assessment Score; COPD: Chronic obstructive pulmonary disease.

(ERBE, Germany) for ablation of small vessels with a diameter less than 5 mm and coag-grasper (FD-411QR; Olympus, Japan) for bleeding control from a large vessel are generally used<sup>[49,55,56]</sup>.

## OUTCOME OF PER ORAL ENDOSCOPIC PYLOROMYOTOMY

### Studied population

Since Kawai and colleagues proved that the concept of pyloromyotomy can be performed endoscopically using submucosal technique similar to that of POEM procedure in 2014<sup>[42]</sup>, multiple centers have performed POP for patients with refractory gastroparesis. Most studies have been reported from The United States and France with some reports from Korea, Brazil, Australia, India, Venezuela, Mexico, and Czech Republic<sup>[2,37,40,43,45,46,48,49,54-56,58,59]</sup>. This may be in part due to high prevalence of the disease with only one approved medication for symptomatic treatment in the United States. However, as more data on its safety and efficacy emerges, it can be anticipated the procedure will become available in other centers with expertise in submucosal



**Figure 1** The procedural steps of per oral endoscopic pyloromyotomy. A: Pre-pyloric area in the stomach; B: Mucosotomy site in prepyloric area; C: Submucosal tunnel creation; D: Pyloric ring; E: Myotomy; F: Closure of mucosotomy site with endoclips.

endoscopy as well.

Based on an electronic search of PubMed, Medline, Cochrane and Scopus databases for articles containing the terms “Endoscopic pyloromyotomy”, “POP”, or “GPOEM” between January 2013 and September 2018, there have been 13 publications on clinical outcome of POP, including 3 abstract-only publications as described in Table 1. Three case reports were excluded as the data on their clinical outcome was not available<sup>[40,54,60]</sup>. All published study, except for a study by Jacques *et al*<sup>[61]</sup> were retrospective studies.

Across all publications, 291 patients underwent POP<sup>[2,37,41,43,45,47,48,55,56,58,59,61,62]</sup>. Etiology of gastroparesis were diabetes ( $n = 69$ ), post-surgery ( $n = 61$ ), idiopathic ( $n = 93$ ), post-infection ( $n = 1$ ), and other causes ( $n = 10$ ), which included systemic sclerosis, Sjogren syndrome, and Ehlers Danlos syndrome as described in Table 1. The inclusion criteria of all study were similar, which was patients with refractory gastroparesis, except for Two small studies where responses to medical therapy was not mentioned in the inclusion criteria and assumingly all patients with gastroparesis were included<sup>[37,41]</sup>. There were also minor differences in how each group defined “refractory”. While most studies required only presence of symptoms despite dietary and prokinetics treatment, Gonzalez *et al*<sup>[2]</sup> and Jacques *et al*<sup>[61]</sup> set more strict inclusion criteria. Both studies required persistent gastroparetic symptoms of longer than 6 mo while on medical therapy. Gonzalez *et al*<sup>[2]</sup> required gastroparesis cardinal symptoms index (GCSI) of  $> 1.5$  after all prokinetic medications, while Jacques *et al*<sup>[61]</sup> required GCSI of  $> 2.6$  after failing at least 2 out of 3 prokinetics. Studies from Dacha *et al*<sup>[43]</sup> and Mekaroonkamol *et al*<sup>[56]</sup> were conducted by the same group from Emory University, United States. They excluded patients whose predominant symptom was abdominal pain<sup>[43,56]</sup>. Using the previous pylorus-directed therapy to predict response of POP, Rodriguez *et al*<sup>[48]</sup> included only those who had symptomatic improvement after intrapyloric botulinum injection. This heterogeneity among inclusion criteria needs to be considered when comparing outcomes between each study.

### Outcome measurements

Despite some difference on baseline characteristics of studied population, the clinical outcomes among published data have consistently suggested high clinical response rate ranging from 69%-100%. However, outcome measurements and follow-up duration are quite heterogeneous across all studies (Table 1). Gastric emptying scintigraphy (GES) was included as one of the parameters to measure clinical success in almost all of the studies even though it may not be the best tool to evaluate clinical success as it has been shown to have poor correlation with clinical symptoms<sup>[63-66]</sup>. We believe that clinical success of POP in gastroparesis cannot be solely based upon GES.

Most studies have also included objective scoring system to track improvement in clinical symptoms. Different symptomatology were evaluated. Khashab *et al*<sup>[45]</sup> used patient-report score to evaluate nausea, vomiting, and abdominal pain, while Shlomovitz *et al*<sup>[37]</sup> used a questionnaire-based scoring system to evaluate gastroparesis-related symptoms including epigastric burning and pain. Although GCSI was most commonly used scoring system, but other validated tools such as standardized short form 36 (SF36) and Patient Assessment of Gastrointestinal Symptoms (PAGI-SYM) were also used<sup>[43,47,48,56,58]</sup>. Due to significant heterogeneity in outcome measurements, not all clinical endpoints are comparable across all studies.

### Technical success

Although POP is more technically demanding compared to its predecessor POEM procedure due to number of aforementioned reasons, including how well pyloric ring can be identified, complete pyloromyotomy was achieved in all patients reported in published studies (100% technical success rate) with procedural time ranging from 40-120 min<sup>[43,45,47,48,51,52]</sup>. However, it is noteworthy that only highly skilled endoscopist who had extensive experience with POEM and submucosal endoscopy performed the procedures. This number may also be subjected to reporting bias and publication bias. Trainees participated in a few studies with varying degree of hands-on involvement depending on the endoscopist's discretion<sup>[43,56]</sup>. The wide range of procedural time was possibly related to the learning curve of the procedure, difficulty in submucosal tunneling, and time needed to identify pyloric ring.

### Clinical success

One of the challenges in evaluating clinical success of any gastroparesis treatment is the lack of validated objective measurements that correlate well with clinical symptoms. GCSI was the main outcome measurement in most studies with other patient-report scoring systems utilized as note above<sup>[43,47,48,56,58]</sup>. Although recall bias could not be completely eliminated, clinical response rate of POP has been very encouraging with significantly improved symptoms and quality of life ranging from 73%-100% at up to 18-mo follow-up period<sup>[37,43,45,47,56]</sup>. All studies but one showed significant drop in total GCSI after POP<sup>[43,48,61,67]</sup>. The symptoms that improve the most were nausea and vomiting, while bloating and abdominal distension were not consistently improved among existing studies<sup>[37,43,45,47,48,56,58]</sup>. Although Rodriguez *et al*<sup>[48]</sup> and Kahaleh *et al*<sup>[58]</sup> reported significant improvement in bloating in their patient population after POP, but other studies could not reproduce the results with one study even showed worsened abdominal distension after the procedure<sup>[43,45,47,56]</sup>.

Abdominal pain is a common symptom in gastroparesis with some patients even have pain-predominant disease. However, pain is not one of the cardinal symptoms included in GCSI. Many studies evaluated this component by using indirect surrogate such as PAGI-DYM, SF36, or direct questioning. Improvement in abdominal pain has been reported in 56%-73% of patients after POP but the follow-up period in these studies were only up to 11.5 mo<sup>[45,48,58]</sup>. One study showed that the improvement in pain did not sustain and lasted for only 6 mo<sup>[56]</sup>. While Long term data is required to better understand the effect of POP on pain symptoms in gastroparesis.

Improvement in post procedure gastric emptying quantified by GES was included as the only objective parameter to measure clinical success in most studies. A 4-h study with retention percentage of more than 10%-20% at 4-h was generally required. GES was repeated 2-3 mo after POP in most studies. However, there was significant variability in post-procedure improvement in gastric retention. Post procedure GES was completed in as low as 34% to 100% of the studied patients<sup>[48,56,61]</sup>. Hustak *et al*<sup>[59]</sup> and Jacques *et al*<sup>[61]</sup> reported GES improvement in 100% patients, while Mekaroonkamol *et al*<sup>[56]</sup> reported GES improvement in 78% of study subjects and normalized GES in 48% patients. A few studies reported significant improvement in GES at 2-h retention but statistical significant improvement was not observed at 4-h<sup>[2,37,47]</sup>. Relatively smaller sample size in these studies may have contributed to this discrepancy. Interestingly, irrespective of the degree of improvement in GES, clinical response measured in terms of GCSI remains > 70% in all studies<sup>[2,37,43,47,48,56,61]</sup>.

Despite the difference in each symptom responses to POP, overall quality of life of the patients with gastroparesis was shown to have improved after the procedure in 70%-78% of the patients<sup>[43,47,56]</sup>. Out of 8 aspects of quality of life assessed in SF36, the domains showing significant improvement included vitality, general health, social functioning, and mental health. In addition, frequency in emergency room visits, gastroparesis-related hospitalization rate, and anti-emetic medication requirement have significantly reduced post-POP, when compared to the control group<sup>[43,56]</sup>. The mean length of hospital stay was 1-3.3 d<sup>[43,45,47,48]</sup>. Majority of the patients were able to tolerate oral diet and significantly gained weight<sup>[43,45,48]</sup>.

The physiologic changes in gastric motility that led to these observed differences in



clinical responses of each symptom is not yet known. However, it has been hypothesized that the affected location in gastric dysmotility may play a role when categorizing gastroparesis into two different subtypes: (1) Fundic-predominant (proximal retention), characterized by bloating, early satiety, and abdominal pain, which are the result of visceral hypersensitivity and impaired relaxation of the fundus post-prandially<sup>[68-70]</sup>; and (2) Antral-predominant (distal retention) gastroparesis which is a result of pyloric dysfunction and impaired antral contraction causing delayed emptying from distal stomach and manifest with nausea/vomiting. It is expected that gastroparesis with distal retention from pyloric dysfunction would respond better to POP<sup>[43,71]</sup>. However, differentiating these 2 subtypes objectively remains difficult creating yet another challenge in appropriate patient selection for the procedure. Endoscopic functional luminal imaging probe (EndoFLIP) is a system which was first described in clinical practice in 2007. Impedance planimetry (IP) is a technique which allows to study the relationship of cross sectional area and pressure during volume distention in GI lumen. EndoFLIP uses multi-detector IP system to produce 3-dimensional images of any distensible organ within GI tract<sup>[72]</sup>. EndoFLIP recordings allow dynamic imaging of sphincter distention with a cylindrical balloon of variable diameter with instant cross sectional area measurement along with direct calculations of pyloric sphincter pressures<sup>[73]</sup>. While EndoFLIP has shown to have widely useful in esophageal disorder, its use across other gastrointestinal motility disorder has been increasing as well<sup>[72]</sup>. EndoFLIP directed therapy could have a significant role here in future but it currently remains under investigation. Considering these conflicting data on symptomatic response and the fact that most patients with gastroparesis have mixed symptoms, our practice is to advise the patient that not all symptoms will respond equally with nausea/vomiting has more likelihood of improvement than bloating and pain. The decision to proceed with the procedure should always be individualized.

Two cases were reported to undergo subsequent surgical intervention after no response to POP. One had laparoscopic total gastrectomy at 9 mo after POP<sup>[48]</sup>, while the other underwent laparoscopic pyloroplasty 7 mo after the procedure, which also did not yield any significant clinical improvement<sup>[37]</sup>. The result was not surprising as both interventions offer the same therapeutic mechanism. However, one study reported a repeat POP in a patient who initially improved but had gastroparesis symptoms recurred 24 mo after the index procedure. The patient had significant clinical response even after a repeat pyloromyotomy<sup>[62]</sup>.

### Adverse events

Post-procedural hemorrhage, pyloric ulcer, and tension capnoperitoneum have been reported as serious adverse events of POP with complication rate ranging from 0-6.7%<sup>[43,45,47,48,58]</sup>.

**Bleeding:** Bleeding has been reported as an adverse event by multiple studies<sup>[2,49,58,59]</sup>. All peri-procedural bleeding were controlled endoscopically and/or medically (with proton pump inhibitors) without any further interventions. Many studies have also reported pyloric ulcer after the procedure<sup>[37,45,49]</sup>. These ulcers at the incision site may be the cause of GI bleeding. Causal relationship was not established between ulcer the source of bleeding in published studies except Hustak *et al*<sup>[59]</sup> and Chung *et al*<sup>[49]</sup> where bleeding was attributed to the ulcer.

**Perforation:** Perforation has been reported in a recent study by Jacques *et al*<sup>[61]</sup>. While capnoperitoneum/pneumoperitoneum has been reported by a few previous studies. Despite high rate of perforation in animal studies<sup>[53,74,75]</sup>, incidence of procedure-related perforation in humans was rare. This can be explained by the difference in separability of gastric muscle layers between human and porcine model. Recently, Jacques *et al*<sup>[61]</sup> reported 20% rate of perforation (4/20 patients, only 1 required surgical intervention, while others were managed conservatively). The reason for such high rate of perforation in this study remains unknown but full-thickness myotomy approach as well as extension of myotomy into duodenal side in a retrograde manner could have contributed. Allemang *et al*<sup>[55]</sup> recommends against extending myotomy into duodenal side to minimize risk of perforation. At our center, we performed selective circular pyloromyotomy as the pyloric ring without duodenal extension to minimize the risk of perforation<sup>[43,56]</sup>.

**Capnoperitoneum/pneumoperitoneum:** In contrast to perforation, capnoperitoneum/pneumoperitoneum is encountered with reported incidence rate ranging from 0-17%<sup>[2,32,56]</sup>. Most cases are managed with either conservative treatment and resolved on its own. If severe, affecting patient ventilation or hemodynamics, it can be treated with needle decompression as described by Gonzalez *et al*<sup>[2]</sup> and Mekaroonsakamol *et al*<sup>[56]</sup>. At our institute, needle decompression kit is in the procedure

room and both physician and trainee staff are trained in needle decompression for tension capnoperitoneum if required during or after the procedure. There has not been any significant morbidity or mortality reported till date as a consequence of capnoperitoneum/pneumoperitoneum.

**Other reported adverse events:** One case of post-procedure pulmonary embolism in the setting of known hypercoagulable state and prior thrombotic event was reported<sup>[47]</sup>. There was one reported death but it was not procedural-related. Other adverse events included one case of post-procedure dysphagia and one case of pneumonia<sup>[37,48]</sup>. Regarding infection risk, there was one reported case of peri-gastric intraperitoneal abscess, which was successfully treated with antibiotics alone<sup>[2]</sup>.

Surgical pyloroplasty with or without gastric pacemaker has shown successful outcomes in gastroparesis. A study comparing outcomes of POP with surgical pyloroplasty showed POP has average shorter operative time, less intraprocedural blood loss and less length of stay. Overall complication rates as well as need for post procedure intensive care unit admissions were also significantly lower for POP arm<sup>[76]</sup>. However, data in this area remains limited and till date there is no randomized controlled trial comparing surgical outcomes with endoscopic pyloromyotomy.

### Predictive factors

The existing data on safety and efficacy of endoscopic pyloromyotomy in gastroparesis is limited by its small size and the retrospective nature of published studies, making it difficult to determine its validity. There is still significant lack of clarity on selecting appropriate patients for this intervention. At our center, we offer POP to the patients with refractory gastroparesis who have failed or not a candidate for medical treatment (prokinetic agents), who are not on narcotics regularly and who do not have pain predominant disease due to concern for overlapping functional pain, which is unlikely to respond to pylorus-directed therapy.

Multiple clinical parameters were evaluated as potential predictive factors of POP. Gonzalez *et al*<sup>[2]</sup> reported diabetes and female gender as predictors of poorer outcomes, but this was not shown in subsequent studies<sup>[48,61,62]</sup>. Outcomes of POP between diabetic *vs* non-diabetic gastroparesis remain conflicting. Jacques *et al*<sup>[61]</sup> showed favorable outcomes in diabetic gastroparesis post POP with the use of EndoFLIP. Pyloric physiology after POP including pyloric pressure, pyloric distensibility as well as pyloric diameter was shown to have improved more in diabetic patients as compared to non-diabetic cohort<sup>[61]</sup>. In contrast, Rodriguez *et al*<sup>[48]</sup> showed best response of POP were achieved in idiopathic and post-surgical gastroparesis while diabetic gastroparesis patients with advanced macrovascular changes such as nephropathy had worse outcomes. Mekaroonkamol *et al*<sup>[56]</sup> performed a comparative analysis between diabetic and non-diabetic cohort. Multivariate linear regression models did not show a significant association between etiology of gastroparesis and clinical improvement, rather there was a significant correlation between the duration of disease and a decrease in GCSI. Exact impact of diabetes and etiology of gastroparesis on outcomes of POP remain unclear at this point.

Certain characteristics of the pylorus such as its diameter, cross-sectional area, distensibility, and compliance are known to relate to severity of gastroparesis symptoms<sup>[22,23,77]</sup>; for example, decreased pyloric diameter and cross-sectional area is associated with post-prandial fullness and early satiety<sup>[22]</sup>. Such association can explain the clinical response of POP and suggested the possible utility of pyloric measurements as a predicting tool for the procedure.

The factors predicting favorable response to POP remains unknown. Few studies have used EndoFLIP as a surrogate marker to assess pyloric sphincter indices in assessing response to POP. Malik *et al*<sup>[47]</sup> showed that while average pyloric pressure decreases, cross-sectional area as well as pyloric diameter increase significantly after POP. The only parameter associated with clinical success was increased cross-sectional area after POP, which is consistent with a prior study by the same group that found the cross sectional area to have an inverse correlation with symptoms of gastroparesis<sup>[22]</sup>. However, only a few patients (4/9) had a complete EndoFLIP measurement in this study. In contrast, the study by Jacques *et al*<sup>[61]</sup> showed with EndoFLIP use, increase in pyloric channel diameter and distensibility index was most marked in diabetic patients as well as distensibility index < 9.2 mm<sup>2</sup>/mmHg was associated with favorable outcomes after POP. Hence, the approach of using pyloric physiologic measurements to predict outcome of POP appear to be physiologically sound, further studies to validate its use are warranted.

As Malik *et al*<sup>[47]</sup> showed prior response to intrapyloric botulinum injection can be a good predictor for clinical success after POP, Rodriguez *et al*<sup>[48]</sup> took a similar approach by selecting patients for POP based on their response to intrapyloric botulinum injection, which is the least invasive pylorus directed therapy prior to

subjecting patients to either endoscopic or surgical pyloroplasty. Although the study had significant improvement in post procedure GCSI and GES, the clinical response rate was similar to other studies where clinical improvement from intrapyloric botulinum injection was not used as an inclusion criteria. There was also no direct comparison of patients who received intrapyloric botulinum injection vs those who didn't. Hence, it is difficult to draw any clinical conclusion on the benefit of pre-POP botulinum toxin injection, especially when 2 large randomized control trials did not demonstrate the benefit of this intervention in gastroparesis treatment and there was also a theoretical risk of submucosal fibrosis from such injection, potentially complicating a subsequent POP.

Since POP is relatively newer intervention, appropriate learning curve for POP is not yet well defined. Recently study by Suresh *et al*<sup>[78]</sup> looked into learning curve for POP and suggested about 18 procedures were required to achieve procedural efficiency (defined as < 60 min) and continued improvement in efficiency as furthermore procedures were performed. However, outcomes of procedure based on endoscopist's experience were not assessed in this study. When compared to data about learning curve for laparoscopic pyloromyotomy, about 30 cases are required to develop procedural efficiency however outcomes did not differ based on operator's experience<sup>[79]</sup>.

## CONCLUSION

POP has shown a promising outcome as a minimally invasive option for treatment of refractory gastroparesis. In experienced hands in high volume center, it is technically feasible with a low risk of adverse events. It significantly reduces gastroparesis symptoms at least in up to 18-mo period with nausea/vomiting being the most-responsive symptoms. In addition, it can improve quality of life and reduce hospitalization rate. Predictors of clinical outcomes and utility of pyloric physiologic measurements need to be further investigated. While initial data has shown promising results, future large multicenter trials with sham group comparison will be helpful in further assessing outcomes of POP as a standard of care approach for gastroparesis.

## REFERENCES

1. Wang YR, Fisher RS, Parkman HP. Gastroparesis-related hospitalizations in the United States: Trends, characteristics, and outcomes, 1995-2004. *Am J Gastroenterol* 2008; **103**: 313-322 [PMID: 18047541 DOI: 10.1111/j.1572-0241.2007.01658.x]
2. Gonzalez JM, Benezech A, Vitton V, Barthet M. G-POEM with antro-pyloromyotomy for the treatment of refractory gastroparesis: Mid-term follow-up and factors predicting outcome. *Aliment Pharmacol Ther* 2017; **46**: 364-370 [PMID: 28504312 DOI: 10.1111/apt.14132]
3. Parkman HP, Camilleri M, Farrugia G, McCallum RW, Bharucha AE, Mayer EA, Tack JF, Spiller R, Horowitz M, Vinik AI, Galligan JJ, Pasricha PJ, Kuo B, Szarka LA, Marciani L, Jones K, Parrish CR, Sandroni P, Abell T, Ordog T, Hasler W, Koch KL, Sanders K, Norton NJ, Hamilton F. Gastroparesis and functional dyspepsia: Excerpts from the AGA/ANMS meeting. *Neurogastroenterol Motil* 2010; **22**: 113-133 [PMID: 20003077 DOI: 10.1111/j.1365-2982.2009.01434.x]
4. Lacy BE, Crowell MD, Mathis C, Bauer D, Heinberg LJ. Gastroparesis: Quality of Life and Health Care Utilization. *J Clin Gastroenterol* 2018; **52**: 20-24 [PMID: 27775961 DOI: 10.1097/MCG.0000000000000728]
5. Parkman HP, Hasler WL, Fisher RS; American Gastroenterological Association. American Gastroenterological Association technical review on the diagnosis and treatment of gastroparesis. *Gastroenterology* 2004; **127**: 1592-1622 [PMID: 15521026 DOI: 10.1053/j.gastro.2004.09.055]
6. Schey R, Saadi M, Midani D, Roberts AC, Parupalli R, Parkman HP. Domperidone to Treat Symptoms of Gastroparesis: Benefits and Side Effects from a Large Single-Center Cohort. *Dig Dis Sci* 2016; **61**: 3545-3551 [PMID: 27530760 DOI: 10.1007/s10620-016-4272-5]
7. Williams PA, Nikitina Y, Kedar A, Lahr CJ, Helling TS, Abell TL. Long-term effects of gastric stimulation on gastric electrical physiology. *J Gastrointest Surg* 2013; **17**: 50-5; discussion p.55-6 [PMID: 22956404 DOI: 10.1007/s11605-012-2020-5]
8. Camilleri M, Parkman HP, Shafi MA, Abell TL, Gerson L; American College of Gastroenterology. Clinical guideline: Management of gastroparesis. *Am J Gastroenterol* 2013; **108**: 18-37; quiz 38 [PMID: 23147521 DOI: 10.1038/ajg.2012.373]
9. Mearin F, Camilleri M, Malagelada JR. Pyloric dysfunction in diabetics with recurrent nausea and vomiting. *Gastroenterology* 1986; **90**: 1919-1925 [PMID: 3699409 DOI: 10.1016/0016-5085(86)90262-3]
10. Bortolotti M. Gastric electrical stimulation for gastroparesis: A goal greatly pursued, but not yet attained. *World J Gastroenterol* 2011; **17**: 273-282 [PMID: 21253385 DOI: 10.3748/wjg.v17.i3.273]
11. Huizinga JD, Lammers WJ. Gut peristalsis is governed by a multitude of cooperating mechanisms. *Am J Physiol Gastrointest Liver Physiol* 2009; **296**: G1-G8 [PMID: 18988693 DOI: 10.1152/ajpgi.90380.2008]
12. Soffer EE. Gastric electrical stimulation for gastroparesis. *J Neurogastroenterol Motil* 2012; **18**: 131-137 [PMID: 22523722 DOI: 10.5056/jnm.2012.18.2.131]
13. Abell T, McCallum R, Hocking M, Koch K, Abrahamsson H, Leblanc I, Lindberg G, Konturek J, Nowak T, Quigley EM, Tougas G, Starkebaum W. Gastric electrical stimulation for medically refractory



- gastroparesis. *Gastroenterology* 2003; **125**: 421-428 [PMID: [12891544](#) DOI: [10.1016/S0016-5085\(03\)00878-3](#)]
- 14 **Abell TL**, Van Cutsem E, Abrahamsson H, Huizinga JD, Konturek JW, Galmiche JP, Voeller G, Filez L, Everts B, Waterfall WE, Domschke W, Bruley des Varannes S, Familoni BO, Bourgeois IM, Janssens J, Tougas G. Gastric electrical stimulation in intractable symptomatic gastroparesis. *Digestion* 2002; **66**: 204-212 [PMID: [12592096](#) DOI: [10.1159/000068359](#)]
  - 15 **Ahuja NK**, Clarke JO. Pyloric Therapies for Gastroparesis. *Curr Treat Options Gastroenterol* 2017; **15**: 230-240 [PMID: [28124202](#) DOI: [10.1007/s11938-017-0124-4](#)]
  - 16 **McCallum RW**, Snape W, Brody F, Wo J, Parkman HP, Nowak T. Gastric electrical stimulation with Enterra therapy improves symptoms from diabetic gastroparesis in a prospective study. *Clin Gastroenterol Hepatol* 2010; **8**: 947-54; quiz e116 [PMID: [20538073](#) DOI: [10.1016/j.cgh.2010.05.020](#)]
  - 17 **Gourcerol G**, Huet E, Vandaele N, Chaput U, Leblanc I, Bridoux V, Michot F, Leroi AM, Ducrotté P. Long term efficacy of gastric electrical stimulation in intractable nausea and vomiting. *Dig Liver Dis* 2012; **44**: 563-568 [PMID: [22387288](#) DOI: [10.1016/j.dld.2012.01.013](#)]
  - 18 **Levinthal DJ**, Bielefeldt K. Systematic review and meta-analysis: Gastric electrical stimulation for gastroparesis. *Auton Neurosci* 2017; **202**: 45-55 [PMID: [27085627](#) DOI: [10.1016/j.autneu.2016.03.004](#)]
  - 19 **Abell TL**, Johnson WD, Kedar A, Runnels JM, Thompson J, Weeks ES, Minocha A, Griswold ME. A double-masked, randomized, placebo-controlled trial of temporary endoscopic mucosal gastric electrical stimulation for gastroparesis. *Gastrointest Endosc* 2011; **74**: 496-503.e3 [PMID: [21872708](#) DOI: [10.1016/j.gie.2011.05.022](#)]
  - 20 **Frøkjær JB**, Ejlskjær N, Rask P, Andersen SD, Gregersen H, Drewes AM, Funch-Jensen P. Central neuronal mechanisms of gastric electrical stimulation in diabetic gastroparesis. *Scand J Gastroenterol* 2008; **43**: 1066-1075 [PMID: [18609155](#) DOI: [10.1080/00365520802028221](#)]
  - 21 **Bielefeldt K**. Adverse events of gastric electrical stimulators recorded in the Manufacturer and User Device Experience (MAUDE) Registry. *Auton Neurosci* 2017; **202**: 40-44 [PMID: [26850819](#) DOI: [10.1016/j.autneu.2016.01.003](#)]
  - 22 **Malik Z**, Sankineni A, Parkman HP. Assessing pyloric sphincter pathophysiology using EndoFLIP in patients with gastroparesis. *Neurogastroenterol Motil* 2015; **27**: 524-531 [PMID: [25712043](#) DOI: [10.1111/nmo.12522](#)]
  - 23 **Snape WJ**, Lin MS, Agarwal N, Shaw RE. Evaluation of the pylorus with concurrent intraluminal pressure and EndoFLIP in patients with nausea and vomiting. *Neurogastroenterol Motil* 2016; **28**: 758-764 [PMID: [26813266](#) DOI: [10.1111/nmo.12772](#)]
  - 24 **Camilleri M**, Malagelada JR, Brown ML, Becker G, Zinsmeister AR. Relation between antral motility and gastric emptying of solids and liquids in humans. *Am J Physiol* 1985; **249**: G580-G585 [PMID: [4061646](#) DOI: [10.1152/ajpgi.1985.249.5.G580](#)]
  - 25 **Rao SS**, Vemuri S, Harris B, Schulze K. Fundic balloon distension stimulates antral and duodenal motility in man. *Dig Dis Sci* 2002; **47**: 1015-1019 [PMID: [12018896](#) DOI: [10.1023/A:1015077721427](#)]
  - 26 **Davis BR**, Sarosiek I, Bashashati M, Alvarado B, McCallum RW. The Long-Term Efficacy and Safety of Pyloroplasty Combined with Gastric Electrical Stimulation Therapy in Gastroparesis. *J Gastrointest Surg* 2017; **21**: 222-227 [PMID: [27896652](#) DOI: [10.1007/s11605-016-3327-4](#)]
  - 27 **Sarosiek I**, Forster J, Lin Z, Cherry S, Sarosiek J, McCallum R. The addition of pyloroplasty as a new surgical approach to enhance effectiveness of gastric electrical stimulation therapy in patients with gastroparesis. *Neurogastroenterol Motil* 2013; **25**: 134-e80 [PMID: [23113904](#) DOI: [10.1111/nmo.12032](#)]
  - 28 **Hibbard ML**, Dunst CM, Swanström LL. Laparoscopic and endoscopic pyloroplasty for gastroparesis results in sustained symptom improvement. *J Gastrointest Surg* 2011; **15**: 1513-1519 [PMID: [21720926](#) DOI: [10.1007/s11605-011-1607-6](#)]
  - 29 **Masquís S**, Velanovich V. Pyloroplasty with fundoplication in the treatment of combined gastroesophageal reflux disease and bloating. *World J Surg* 2007; **31**: 332-336 [PMID: [17219264](#) DOI: [10.1007/s00268-006-0723-z](#)]
  - 30 **Arts J**, van Gool S, Caenepeel P, Verbeke K, Janssens J, Tack J. Influence of intrapyloric botulinum toxin injection on gastric emptying and meal-related symptoms in gastroparesis patients. *Aliment Pharmacol Ther* 2006; **24**: 661-667 [PMID: [16907899](#) DOI: [10.1111/j.1365-2036.2006.03019.x](#)]
  - 31 **Bromer MQ**, Friedenberg F, Miller LS, Fisher RS, Swartz K, Parkman HP. Endoscopic pyloric injection of botulinum toxin A for the treatment of refractory gastroparesis. *Gastrointest Endosc* 2005; **61**: 833-839 [PMID: [15933684](#) DOI: [10.1016/S0016-5107\(05\)00328-7](#)]
  - 32 **Khashab MA**, Besharati S, Ngamruengphong S, Kumbhari V, El Zein M, Stein EM, Tieu A, Mullin GE, Dhalla S, Nandwani MC, Singh V, Canto MI, Kalloo AN, Clarke JO. Refractory gastroparesis can be successfully managed with endoscopic transpyloric stent placement and fixation (with video). *Gastrointest Endosc* 2015; **82**: 1106-1109 [PMID: [26253017](#) DOI: [10.1016/j.gie.2015.06.051](#)]
  - 33 **Clarke JO**, Snape WJ. Pyloric sphincter therapy: Botulinum toxin, stents, and pyloromyotomy. *Gastroenterol Clin North Am* 2015; **44**: 127-136 [PMID: [25667028](#) DOI: [10.1016/j.gtc.2014.11.010](#)]
  - 34 **Arts J**, Holvoet L, Caenepeel P, Bisschops R, Sifrim D, Verbeke K, Janssens J, Tack J. Clinical trial: A randomized-controlled crossover study of intrapyloric injection of botulinum toxin in gastroparesis. *Aliment Pharmacol Ther* 2007; **26**: 1251-1258 [PMID: [17944739](#) DOI: [10.1111/j.1365-2036.2007.03467.x](#)]
  - 35 **Friedenberg FK**, Palit A, Parkman HP, Hanlon A, Nelson DB. Botulinum toxin A for the treatment of delayed gastric emptying. *Am J Gastroenterol* 2008; **103**: 416-423 [PMID: [18070232](#) DOI: [10.1111/j.1572-0241.2007.01676.x](#)]
  - 36 **Inoue H**, Minami H, Kobayashi Y, Sato Y, Kaga M, Suzuki M, Satodate H, Odaka N, Itoh H, Kudo S. Peroral endoscopic myotomy (POEM) for esophageal achalasia. *Endoscopy* 2010; **42**: 265-271 [PMID: [20354937](#) DOI: [10.1055/s-0029-1244080](#)]
  - 37 **Shlomovitz E**, Pescarus R, Cassera MA, Sharata AM, Reavis KM, Dunst CM, Swanström LL. Early human experience with per-oral endoscopic pyloromyotomy (POP). *Surg Endosc* 2015; **29**: 543-551 [PMID: [25106716](#) DOI: [10.1007/s00464-014-3720-6](#)]
  - 38 **Pasricha PJ**, Hawari R, Ahmed I, Chen J, Cotton PB, Hawes RH, Kalloo AN, Kantsevoy SV, Gostout CJ. Submucosal endoscopic esophageal myotomy: a novel experimental approach for the treatment of achalasia. *Endoscopy* 2007; **39**: 761-764 [PMID: [17703382](#) DOI: [10.1016/j.gie.2007.03.093](#)]
  - 39 **Khashab MA**, Stein E, Clarke JO, Saxena P, Kumbhari V, Chander Roland B, Kalloo AN, Stavropoulos S, Pasricha P, Inoue H. Gastric peroral endoscopic myotomy for refractory gastroparesis: First human endoscopic pyloromyotomy (with video). *Gastrointest Endosc* 2013; **78**: 764-768 [PMID: [24120337](#) DOI: [10.1016/j.gie.2013.07.019](#)]

- 40 **Chaves DM**, de Moura EG, Mestieri LH, Artifon EL, Sakai P. Endoscopic pyloromyotomy via a gastric submucosal tunnel dissection for the treatment of gastroparesis after surgical vagal lesion. *Gastrointest Endosc* 2014; **80**: 164 [PMID: 24836745 DOI: 10.1016/j.gie.2014.03.045]
- 41 **Chung H**, Dallemagne B, Perretta S, Lee SK, Shin SK, Park JC, Marescaux J, Lee YC. Endoscopic pyloromyotomy for postesophagectomy gastric outlet obstruction. *Endoscopy* 2014; **46** Suppl 1 UCTN: E345-E346 [PMID: 25090473 DOI: 10.1055/s-0034-1377599]
- 42 **Kawai M**, Peretta S, Burckhardt O, Dallemagne B, Marescaux J, Tanigawa N. Endoscopic pyloromyotomy: A new concept of minimally invasive surgery for pyloric stenosis. *Endoscopy* 2012; **44**: 169-173 [PMID: 22271027 DOI: 10.1055/s-0031-1291475]
- 43 **Dacha S**, Mekaroonkamol P, Li L, Shahnava N, Sakaria S, Keilin S, Willingham F, Christie J, Cai Q. Outcomes and quality-of-life assessment after gastric per-oral endoscopic pyloromyotomy (with video). *Gastrointest Endosc* 2017; **86**: 282-289 [PMID: 28161449 DOI: 10.1016/j.gie.2017.01.031]
- 44 **Jacques J**, Legros R, Monteil J, Loustaud-Ratti V, Sautereau D. Gastric peroral endoscopic pyloromyotomy as a salvage therapy for refractory gastroparesis: A case series of different subtypes. *Neurogastroenterol Motil* 2017; **29** [PMID: 28028897 DOI: 10.1111/nmo.12932]
- 45 **Khashab MA**, Ngamruengphong S, Carr-Locke D, Bapaye A, Benias PC, Serouya S, Dorwat S, Chaves DM, Artifon E, de Moura EG, Kumbhari V, Chavez YH, Bukhari M, Hajjiyeva G, Ismail A, Chen YI, Chung H. Gastric per-oral endoscopic myotomy for refractory gastroparesis: Results from the first multicenter study on endoscopic pyloromyotomy (with video). *Gastrointest Endosc* 2017; **85**: 123-128 [PMID: 27354102 DOI: 10.1016/j.gie.2016.06.048]
- 46 **Mekaroonkamol P**, Li LY, Dacha S, Xu Y, Keilin SD, Willingham FF, Cai Q. Gastric peroral endoscopic pyloromyotomy (G-POEM) as a salvage therapy for refractory gastroparesis: A case series of different subtypes. *Neurogastroenterol Motil* 2016; **28**: 1272-1277 [PMID: 27197717 DOI: 10.1111/nmo.12854]
- 47 **Malik Z**, Kataria R, Modayil R, Ehrlich AC, Schey R, Parkman HP, Stavropoulos SN. Gastric Per Oral Endoscopic Myotomy (G-POEM) for the Treatment of Refractory Gastroparesis: Early Experience. *Dig Dis Sci* 2018; **63**: 2405-2412 [PMID: 29468376 DOI: 10.1007/s10620-018-4976-9]
- 48 **Rodriguez JH**, Haskins IN, Strong AT, Plescia RL, Allemang MT, Butler RS, Cline MS, El-Hayek K, Ponsky JL, Kroh MD. Per oral endoscopic pyloromyotomy for refractory gastroparesis: Initial results from a single institution. *Surg Endosc* 2017; **31**: 5381-5388 [PMID: 28567693 DOI: 10.1007/s00464-017-5619-5]
- 49 **Chung H**, Khashab MA. Gastric Peroral Endoscopic Myotomy. *Clin Endosc* 2018; **51**: 28-32 [PMID: 29397648 DOI: 10.5946/ce.2018.001]
- 50 **Li L**, Spandorfer R, Qu C, Yang Y, Liang S, Chen H, Xue H, Cai Q. Gastric per-oral endoscopic myotomy for refractory gastroparesis: A detailed description of the procedure, our experience, and review of the literature. *Surg Endosc* 2018; **32**: 3421-3431 [PMID: 29435752 DOI: 10.1007/s00464-018-6112-5]
- 51 **Xue HB**, Fan HZ, Meng XM, Cristofaro S, Mekaroonkamol P, Dacha S, Li LY, Fu XL, Zhan SH, Cai Q. Fluoroscopy-guided gastric peroral endoscopic pyloromyotomy (G-POEM): A more reliable and efficient method for treatment of refractory gastroparesis. *Surg Endosc* 2017; **31**: 4617-4624 [PMID: 28409375 DOI: 10.1007/s00464-017-5524-y]
- 52 **Koul A**, Dacha S, Mekaroonkamol P, Li X, Li L, Shahnava N, Keilin S, Willingham FF, Christie J, Cai Q. Fluoroscopic gastric peroral endoscopic pyloromyotomy (G-POEM) in patients with a failed gastric electrical stimulator. *Gastroenterol Rep (Oxf)* 2018; **6**: 122-126 [PMID: 29780600 DOI: 10.1093/gastro/gox040]
- 53 **Chaves DM**, Gusmon CC, Mestieri LH, de Moura EG, Veras MM, Pessorusso FC, Sakai P. A new technique for performing endoscopic pyloromyotomy by gastric submucosal tunnel dissection. *Surg Laparosc Endosc Percutan Tech* 2014; **24**: e92-e94 [PMID: 24887546 DOI: 10.1097/SLE.0b013e31829cec0e]
- 54 **Hernández-Mondragón OV**, Solórzano-Pineda OM, Blancas-Valencia JM, González-Martínez MA, Villanueva-Pérez RM. Gastric per-oral endoscopic pyloromyotomy in the treatment of refractory gastroparesis: Report on the first case performed in Mexico. *Rev Gastroenterol Mex* 2018; **83**: 459-461 [PMID: 28684033 DOI: 10.1016/j.rgmx.2017.03.006]
- 55 **Allemang MT**, Strong AT, Haskins IN, Rodriguez J, Ponsky JL, Kroh M. How I Do It: Per-Oral Pyloromyotomy (POP). *J Gastrointest Surg* 2017; **21**: 1963-1968 [PMID: 28752406 DOI: 10.1007/s11605-017-3510-2]
- 56 **Mekaroonkamol P**, Dacha S, Wang L, Li X, Jiang Y, Li L, Li T, Shahnava N, Sakaria S, LeVert F, Keilin S, Willingham F, Christie J, Cai Q. Gastric PerOral Endoscopic Pyloromyotomy Reduces Symptoms, Increases Quality of Life, and Reduces Healthcare Usage For Patients With Gastroparesis. *Clin Gastroenterol Hepatol* 2019; **17**: 82-89 [PMID: 29660525 DOI: 10.1016/j.cgh.2018.04.016]
- 57 **ASGE Technology Committee**. Lo SK, Fujii-Lau LL, Enestvedt BK, Hwang JH, Konda V, Manfredi MA, Maple JT, Murad FM, Pannala R, Woods KL, Banerjee S. The use of carbon dioxide in gastrointestinal endoscopy. *Gastrointest Endosc* 2016; **83**: 857-865 [PMID: 26946413 DOI: 10.1016/j.gie.2016.01.046]
- 58 **Kahaleh M**, Gonzalez JM, Xu MM, Andalib I, Gaidhane M, Tyberg A, Saumoy M, Baptista Marchena AJ, Barthet M. Gastric peroral endoscopic myotomy for the treatment of refractory gastroparesis: A multicenter international experience. *Endoscopy* 2018; **50**: 1053-1058 [PMID: 29649841 DOI: 10.1055/a-0596-7199]
- 59 **Hustak R**, Vackova Z, Rabekova Z, Spicak J, Martinek J. Su1269 per-oral endoscopic pyloromyotomy (g-poem) in the treatment of refractory gastroparesis: mid-term single centre experience. *Gastrointestinal Endoscopy* 2018; **87**: AB304-AB305. [DOI: 10.1016/j.gie.2018.04.1656]
- 60 **Bapaye A**, Dubale N, Pujari R, Kulkarni A, Jajoo Naval R, Vyas V, Mahadik M. Peroral endoscopic pyloromyotomy for delayed postoperative gastroparesis. *Endoscopy* 2015; **47**: E581-E582 [PMID: 26649470 DOI: 10.1055/s-0034-1393368]
- 61 **Jacques J**, Pagnon L, Hure F, Legros R, Crepin S, Fauchais AL, Palat S, Ducrotté P, Marin B, Fontaine S, Boubaddi NE, Clement MP, Sautereau D, Loustaud-Ratti V, Gourcerol G, Monteil J. Peroral endoscopic pyloromyotomy is efficacious and safe for refractory gastroparesis: Prospective trial with assessment of pyloric function. *Endoscopy* 2019; **51**: 40-49 [PMID: 29895073 DOI: 10.1055/a-0628-6639]
- 62 **Mekaroonkamol P**, Patel V, Shah R, Li B, Tao J, Guan Q, Chen H, Shahnava N, Sakaria S, Dacha S. 838 duration of the disease, rather than the etiology of gastroparesis, is the key predictive factor for clinical response after gastric per oral endoscopic pyloromyotomy (GPOEM). *Gastrointest Endosc* 2018; **87**: AB119-AB120 [DOI: 10.1016/j.gie.2018.04.1311]
- 63 **Camilleri M**, Szarka LA. POEMs for gastroparesis. *Gastrointest Endosc* 2017; **85**: 129-131 [PMID: 27354102 DOI: 10.1016/j.gie.2016.06.048]

- 27986106 DOI: [10.1016/j.gie.2016.07.012](https://doi.org/10.1016/j.gie.2016.07.012)
- 64 **Horowitz M**, Harding PE, Maddox AF, Wishart JM, Akkermans LM, Chatterton BE, Shearman DJ. Gastric and oesophageal emptying in patients with type 2 (non-insulin-dependent) diabetes mellitus. *Diabetologia* 1989; **32**: 151-159 [PMID: [2753246](https://pubmed.ncbi.nlm.nih.gov/2753246/) DOI: [10.1007/BF00265086](https://doi.org/10.1007/BF00265086)]
  - 65 **Horowitz M**, Harding PE, Maddox A, Maddern GJ, Collins PJ, Chatterton BE, Wishart J, Shearman DJ. Gastric and oesophageal emptying in insulin-dependent diabetes mellitus. *J Gastroenterol Hepatol* 1986; **1**: 97-113 [DOI: [10.1111/j.1440-1746.1986.tb00104.x](https://doi.org/10.1111/j.1440-1746.1986.tb00104.x)]
  - 66 **Khayyam U**, Sachdeva P, Gomez J, Ramzan Z, Smith MS, Maurer AH, Fisher RS, Parkman HP. Assessment of symptoms during gastric emptying scintigraphy to correlate symptoms to delayed gastric emptying. *Neurogastroenterol Motil* 2010; **22**: 539-545 [PMID: [20082665](https://pubmed.ncbi.nlm.nih.gov/20082665/) DOI: [10.1111/j.1365-2982.2009.01454.x](https://doi.org/10.1111/j.1365-2982.2009.01454.x)]
  - 67 **Mekaroonkamol P**, Dacha S, Wang L, Li X, Jiang Y, Li L, Li T, Shahnavaz N, Sakaria S, LeVert F, Keilin S, Willingham FF, Christie J, Cai Q. Patient-Reported Quality of Life Assessment and Utilization of Health Care After Gastric Peroral Endoscopic Pyloromyotomy (GPOEM). *Am J Gastroenterol* 2017; **112**: S429-S490 [DOI: [10.1038/ajg.2017.304](https://doi.org/10.1038/ajg.2017.304)]
  - 68 **Abell TL**, Camilleri M, Donohoe K, Hasler WL, Lin HC, Maurer AH, McCallum RW, Nowak T, Nusynowitz ML, Parkman HP, Shreve P, Szarka LA, Snape WJ, Ziessman HA; American Neurogastroenterology and Motility Society and the Society of Nuclear Medicine. Consensus recommendations for gastric emptying scintigraphy: A joint report of the American Neurogastroenterology and Motility Society and the Society of Nuclear Medicine. *Am J Gastroenterol* 2008; **103**: 753-763 [PMID: [18028513](https://pubmed.ncbi.nlm.nih.gov/18028513/) DOI: [10.1111/j.1572-0241.2007.01636.x](https://doi.org/10.1111/j.1572-0241.2007.01636.x)]
  - 69 **Gonlachanvit S**, Maurer AH, Fisher RS, Parkman HP. Regional gastric emptying abnormalities in functional dyspepsia and gastro-oesophageal reflux disease. *Neurogastroenterol Motil* 2006; **18**: 894-904 [PMID: [16961692](https://pubmed.ncbi.nlm.nih.gov/16961692/) DOI: [10.1111/j.1365-2982.2006.00811.x](https://doi.org/10.1111/j.1365-2982.2006.00811.x)]
  - 70 **Maurer AH**, Parkman HP. Update on gastrointestinal scintigraphy. *Semin Nucl Med* 2006; **36**: 110-118 [PMID: [16517233](https://pubmed.ncbi.nlm.nih.gov/16517233/) DOI: [10.1053/j.semnuclmed.2005.12.003](https://doi.org/10.1053/j.semnuclmed.2005.12.003)]
  - 71 **Mekaroonkamol P**, Li L, Cai Q. The role of pyloric manometry in gastric per-oral endoscopic pyloromyotomy (G-POEM): Response to Jacques *et al.* *Neurogastroenterol Motil* 2017; **29** [PMID: [28028900](https://pubmed.ncbi.nlm.nih.gov/28028900/) DOI: [10.1111/nmo.12949](https://doi.org/10.1111/nmo.12949)]
  - 72 **Ata-Lawenko RM**, Lee YY. Emerging Roles of the Endolumenal Functional Lumen Imaging Probe in Gastrointestinal Motility Disorders. *J Neurogastroenterol Motil* 2017; **23**: 164-170 [PMID: [28013295](https://pubmed.ncbi.nlm.nih.gov/28013295/) DOI: [10.5056/jnm16171](https://doi.org/10.5056/jnm16171)]
  - 73 **Kwiatek MA**, Pandolfino JE, Hirano I, Kahrilas PJ. Esophagogastric junction distensibility assessed with an endoscopic functional luminal imaging probe (EndoFLIP). *Gastrointest Endosc* 2010; **72**: 272-278 [PMID: [20541755](https://pubmed.ncbi.nlm.nih.gov/20541755/) DOI: [10.1016/j.gie.2010.01.069](https://doi.org/10.1016/j.gie.2010.01.069)]
  - 74 **Geyl S**, Legros R, Charissou A, Mesturoux L, Couquet CY, Carrier P, Brayette A, El-Ouali Z, Loustaud-Ratti V, Sautereau D, Monteil J, Jacques J. Peroral endoscopic pyloromyotomy accelerates gastric emptying in healthy pigs: Proof of concept. *Endosc Int Open* 2016; **4**: E796-E799 [PMID: [27556100](https://pubmed.ncbi.nlm.nih.gov/27556100/) DOI: [10.1055/s-0042-108192](https://doi.org/10.1055/s-0042-108192)]
  - 75 **Jung Y**, Lee J, Gromski MA, Kato M, Rodriguez S, Chuttani R, Matthes K. Assessment of the length of myotomy in peroral endoscopic pyloromyotomy (G-POEM) using a submucosal tunnel technique (video). *Surg Endosc* 2015; **29**: 2377-2384 [PMID: [25424365](https://pubmed.ncbi.nlm.nih.gov/25424365/) DOI: [10.1007/s00464-014-3948-1](https://doi.org/10.1007/s00464-014-3948-1)]
  - 76 **Landreneau JP**, Strong AT, El-Hayek K, Tu C, Villamere J, Ponsky JL, Kroh MD, Rodriguez JH. Laparoscopic pyloroplasty versus endoscopic per-oral pyloromyotomy for the treatment of gastroparesis. *Surg Endosc* 2018 [PMID: [30019220](https://pubmed.ncbi.nlm.nih.gov/30019220/) DOI: [10.1007/s00464-018-6342-6](https://doi.org/10.1007/s00464-018-6342-6)]
  - 77 **Gourcerol G**, Tissier F, Melchior C, Touchais JY, Huet E, Prevost G, Leroi AM, Ducrotte P. Impaired fasting pyloric compliance in gastroparesis and the therapeutic response to pyloric dilatation. *Aliment Pharmacol Ther* 2015; **41**: 360-367 [PMID: [25523288](https://pubmed.ncbi.nlm.nih.gov/25523288/) DOI: [10.1111/apt.13053](https://doi.org/10.1111/apt.13053)]
  - 78 **Suresh S**, Tyberg A, Martinez MG, Zamarripa F, Lambroza A, Gaidhane M, Nieto J, Kahaleh M. Su1280 gastric peroral endoscopic myotomy: a specific learning curve. *Gastrointest Endosc* 2018; **87**: AB309-AB310 [DOI: [10.1016/j.gie.2018.04.1667](https://doi.org/10.1016/j.gie.2018.04.1667)]
  - 79 **Kim SS**, Lau ST, Lee SL, Waldhausen JH. The learning curve associated with laparoscopic pyloromyotomy. *J Laparoendosc Adv Surg Tech A* 2005; **15**: 474-477 [PMID: [16185119](https://pubmed.ncbi.nlm.nih.gov/16185119/) DOI: [10.1089/lap.2005.15.474](https://doi.org/10.1089/lap.2005.15.474)]

P- Reviewer: Chedid MF, Chiba T, Garbuzenko DV

S- Editor: Yan JP L- Editor: A E- Editor: Yin SY





Published By Baishideng Publishing Group Inc  
7901 Stoneridge Drive, Suite 501, Pleasanton, CA 94588, USA  
Telephone: +1-925-2238242  
Fax: +1-925-2238243  
E-mail: [bpgoffice@wjgnet.com](mailto:bpgoffice@wjgnet.com)  
Help Desk: <http://www.f6publishing.com/helpdesk>  
<http://www.wjgnet.com>

