



国内版

国际版

Community-acquired pneumonia complicated by rhabdomyolysis: A clinical anal



All

Images

Videos

翻译成中文

关闭取词

32,700 Results

Any time ▾

Community acquired methicillin-resistant Staphylococcus ...

<https://www.ncbi.nlm.nih.gov/pmc/articles/PMC2831021>

CA-MRSA commonly causes **skin and soft tissue infections**. In the current case report, we describe **community acquired pneumonia** due to MRSA which is until now infrequently seen. Further, this patient's **clinical course** was **complicated by rhabdomyolysis** which is even more uncommon.

Cited by: 1

Author: Poorani Nallam Goundan, Anurag Mehr...

Publish Year: 2010

Community acquired methicillin-resistant Staphylococcus ...

<https://casesjournal.biomedcentral.com/articles/10.1186/1757-1626-3-61> ▾

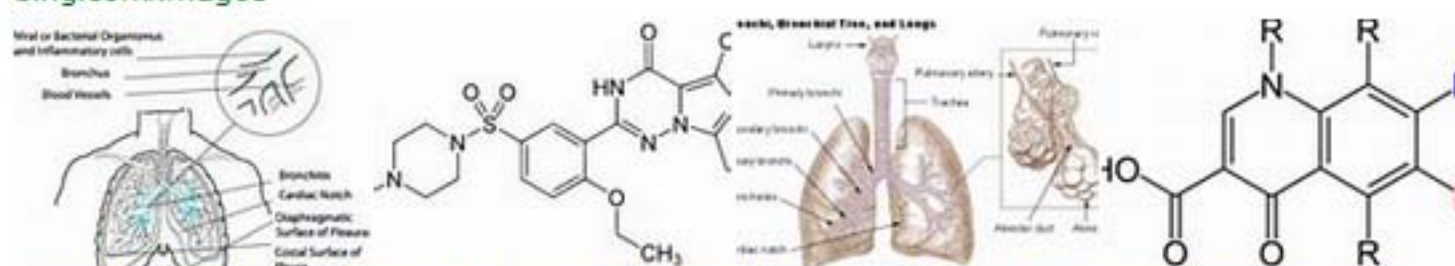
Feb 14, 2010 · Community-acquired methicillin resistant Staphylococcus aureus (CA-MRSA) is considered an underreported entity in India. In this case report, the authors describe a thirty-five year old immunocompetent male presenting with severe respiratory distress requiring intubation. On further work up, a CT thorax showed features consistent with necrotizing **pneumonia**.

Cited by: 1

Author: Poorani Nallam Goundan, Anurag Mehr...

Publish Year: 2010

Images of community-acquired pneumonia complicated by r...

<bing.com/images>

See more images of community-acquired pneumonia complicated by rhabdomyolysis a clinical analysis of 11 cases

Community acquired methicillin-resistant Staphylococcus ...

https://www.researchgate.net/publication/41806556_Community_acquired_methicillin...

PDF | Community-acquired methicillin resistant Staphylococcus aureus (CA-MRSA) is considered an underreported entity in India. In this case report, the authors describe a thirty-five year old ...

[PDF] CASE REPORT Open Access Community acquired ...

<https://casesjournal.biomedcentral.com/track/pdf/10.1186/1757-1626-3-61>

It also is a rare reporting of **rhabdomyolysis** due to CA-MRSA. Introduction CA-MRSA commonly causes skin and soft tissue infections. In the current case report, we describe community **acquired pneumonia** due to MRSA which is until now infrequently seen. Further, this **patient's clinical course** was **complicated by rhabdomyolysis** which is even more uncommon.

Cited by: 1

Author: Poorani Nallam Goundan, Anurag Mehr...

Publish Year: 2010

Community-acquired pneumonia complicated by rhabdomyolysis: A clinical analysis of 11 cases

Bo Zhao, Rui Zheng

Abstract

BACKGROUND

It has been found in clinics that community-acquired pneumonia (CAP) can be complicated with rhabdomyolysis (RM), and that RM symptoms are subtle and easy to miss. Most local and international studies have been published as case reports. Due to the relatively low incidence of RM caused by CAP, we need more systematic researches to understand the characteristics of RM caused by CAP to improve its diagnosis and treatment.

AIM

To investigate the clinical characteristics of patients with community-acquired

Match Overview

1	Internet 14 words crawled on 19-Mar-2014 ijcem.com	<1%
2	Crossref 13 words Sato, Kazuhiko, Yoshio Mizuno, Hiromi Fuchikami, Masahiro Kato, Takahiro Shimo, Jun Kubota, Naoko Takeda, Yuko I	<1%
3	Crossref 12 words P Cascales, V Fernández-Cornejo, F Sanchez-Del Campo, M de Torre, M.R Sanchez-Eixeres, N Soriano, F Gonzalez. "	<1%



All

Images

Videos

关闭取词

51,100 Results

Any time ▾

Community acquired methicillin-resistant Staphylococcus ...

<https://www.ncbi.nlm.nih.gov/pmc/articles/PMC2831021>

CA-MRSA commonly causes skin and soft tissue infections. In the current case report, we describe community acquired pneumonia due to MRSA which is until now infrequently seen. Further, this patient's clinical course was complicated by rhabdomyolysis which is even more uncommon.

Cited by: 1

Author: Poorani Nallam Goundan, Anurag Mehrotr...

Publish Year: 2010

[PDF] CASE REPORT Open Access Community acquired ...

<https://casesjournal.biomedcentral.com/track/pdf/10.1186/1757-1626-3-61>

It also is a rare reporting of rhabdomyolysis due to CA-MRSA. Introduction CA-MRSA commonly causes skin and soft tissue infections. In the current case report, we describe community acquired pneumonia due to MRSA which is until now infrequently seen. Further, this patient's clinical course was complicated by rhabdomyolysis which is even more uncommon.

Cited by: 1

Author: Poorani Nallam Goundan, Anurag Mehrotr...

Publish Year: 2010

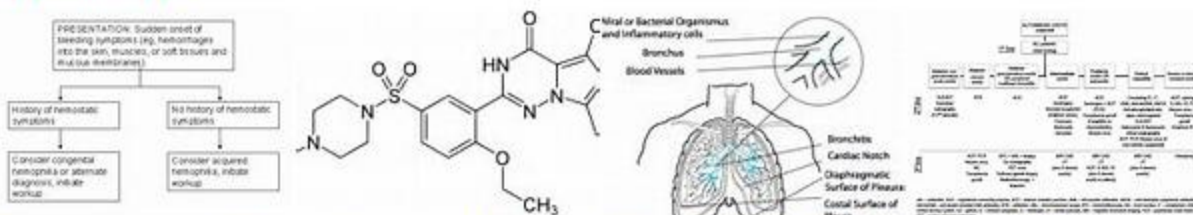
A documented case of Legionella infection presenting with ...

<https://www.itjem.org/2019/02/12/a-documented-case-of-legionella-infection-presenting...> ▾

Legionella infection is recognized as a frequent cause of both community-acquired pneumonia and nosocomial pneumonia, accounting for between 2 and 15% of pneumonias requiring hospitalization. A rare but demonstrated complication of Legionella infection is rhabdomyolysis.

Images of Community-acquired Pneumonia Complicated By ...

<bing.com/images>



See more images of Community-acquired Pneumonia Complicated By Rhabdomyolysis A Clinical