

World Journal of *Gastrointestinal Oncology*

World J Gastrointest Oncol 2020 June 15; 12(6): 604-704



**REVIEW**

- 604** Real-world evidence on adjuvant chemotherapy in older adults with stage II/III colon cancer
Batra A, Rigo R, Sheka D, Cheung WY

MINIREVIEWS

- 619** Structure and function of Septin 9 and its role in human malignant tumors
Sun J, Zheng MY, Li YW, Zhang SW

ORIGINAL ARTICLE**Retrospective Cohort Study**

- 632** Low ligation has a lower anastomotic leakage rate after rectal cancer surgery
Chen JN, Liu Z, Wang ZJ, Zhao FQ, Wei FZ, Mei SW, Shen HY, Li J, Pei W, Wang Z, Yu J, Liu Q

Retrospective Study

- 642** Clinical diagnosis and management of pancreatic mucinous cystadenoma and cystadenocarcinoma: Single-center experience with 82 patients
Zhao ZM, Jiang N, Gao YX, Yin ZZ, Zhao GD, Tan XL, Xu Y, Liu R

Clinical Trials Study

- 651** Fibrin sealant for esophageal anastomosis: A phase II study
Lin YB, Fu JH, Huang Y, Hu YH, Luo KJ, Wang KX, Bella AÉ, Situ DR, Chen JY, Lin T, D'Journo XB, Novoa NM, Brunelli A, Fernando HC, Cerfolio RJ, Ismail M, Yang H, the AME Thoracic Surgery Collaborative Group

Observational Study

- 663** Sorafenib combined with embolization plus hepatic arterial infusion chemotherapy for inoperable hepatocellular carcinoma
Liu BJ, Gao S, Zhu X, Guo JH, Zhang X, Chen H, Wang XD, Yang RJ
- 677** Clinical significance of expression of fibrous sheath interacting protein 1 in colon cancer
Wu HY, Yang B, Geng DH

META-ANALYSIS

- 687** Timing of surgery after neoadjuvant chemoradiotherapy affects oncologic outcomes in patients with esophageal cancer
Shang QX, Yang YS, Gu YM, Zeng XX, Zhang HL, Hu WP, Wang WP, Chen LQ, Yuan Y

CASE REPORT

- 699** Immune checkpoint inhibitors induced colitis, stay vigilant: A case report

Abu Khalaf S, Albarrak A, Yousef M, Tahan V

ABOUT COVER

Editorial Board Member of *World Journal of Gastrointestinal Oncology*, Nuri Faruk Aykan, MD, Professor, Department of Medical Oncology, Istinye University, Bahcesehir Liv Hospital, Istanbul 34510, Turkey

AIMS AND SCOPE

The primary aim of *World Journal of Gastrointestinal Oncology* (WJGO, *World J Gastrointest Oncol*) is to provide scholars and readers from various fields of gastrointestinal oncology with a platform to publish high-quality basic and clinical research articles and communicate their research findings online.

WJGO mainly publishes articles reporting research results and findings obtained in the field of gastrointestinal oncology and covering a wide range of topics including islet cell adenoma, liver cell adenoma, adenomatous polyposis coli, appendiceal neoplasms, bile duct neoplasms, biliary tract neoplasms, hepatocellular carcinoma, islet cell carcinoma, pancreatic ductal carcinoma, cecal neoplasms, colonic neoplasms, colorectal neoplasms, hereditary nonpolyposis colorectal neoplasms, common bile duct neoplasms, duodenal neoplasms, esophageal neoplasms, gallbladder neoplasms, etc.

INDEXING/ABSTRACTING

The WJGO is now indexed in Science Citation Index Expanded (also known as SciSearch®), PubMed, and PubMed Central. The 2019 edition of Journal Citation Reports® cites the 2018 impact factor for WJGO as 2.758 (5-year impact factor: 3.220), ranking WJGO as 52 among 84 journals in gastroenterology and hepatology (quartile in category Q3), and 131 among 229 journals in oncology (quartile in category Q3).

RESPONSIBLE EDITORS FOR THIS ISSUE

Responsible Electronic Editor: *Lu-Lu Qi*

Proofing Production Department Director: *Xiang Li*

Responsible Editorial Office Director: *Jin-Lai Wang*

NAME OF JOURNAL

World Journal of Gastrointestinal Oncology

ISSN

ISSN 1948-5204 (online)

LAUNCH DATE

February 15, 2009

FREQUENCY

Monthly

EDITORS-IN-CHIEF

Monjur Ahmed, Rosa M Jimenez Rodriguez, Pashtoon Kasi

EDITORIAL BOARD MEMBERS

<https://www.wjgnet.com/1948-5204/editorialboard.htm>

PUBLICATION DATE

June 15, 2020

COPYRIGHT

© 2020 Baishideng Publishing Group Inc

INSTRUCTIONS TO AUTHORS

<https://www.wjgnet.com/bpg/gerinfo/204>

GUIDELINES FOR ETHICS DOCUMENTS

<https://www.wjgnet.com/bpg/GerInfo/287>

GUIDELINES FOR NON-NATIVE SPEAKERS OF ENGLISH

<https://www.wjgnet.com/bpg/gerinfo/240>

PUBLICATION ETHICS

<https://www.wjgnet.com/bpg/GerInfo/288>

PUBLICATION MISCONDUCT

<https://www.wjgnet.com/bpg/gerinfo/208>

ARTICLE PROCESSING CHARGE

<https://www.wjgnet.com/bpg/gerinfo/242>

STEPS FOR SUBMITTING MANUSCRIPTS

<https://www.wjgnet.com/bpg/GerInfo/239>

ONLINE SUBMISSION

<https://www.f6publishing.com>



Immune checkpoint inhibitors induced colitis, stay vigilant: A case report

Suha Abu Khalaf, Abdulmajeed Albarrak, Mohamad Yousef, Veysel Tahan

ORCID number: Suha Abu khalaf (0000-0002-5392-507X); Abdulmajeed Albarrak (0000-0002-4078-8547); Mohamad Yousef (0000-0001-9573-5592); Veysel Tahan (0000-0001-6796-9359).

Author contributions: Abu Khalaf S reviewed the literature, performed the data collection, reviewed the patient chart, and wrote the original manuscript; Albarrak A edited the manuscript and performed the colonoscopy; Yousef M edited the manuscript; Tahan V reviewed the manuscript, edited, supervised the first author, got the patient's consent and performed the colonoscopy; all authors have read and agreed on the final version of the manuscript.

Informed consent statement:

Informed written consent wasn't obtained from the patient for publication of this report.

Conflict-of-interest statement: The authors declare that they have no conflict of interest.

CARE Checklist (2016) statement:

The authors have read the CARE Checklist (2016), and the manuscript was prepared and revised according to the CARE Checklist (2016).

Open-Access: This article is an open-access article that was selected by an in-house editor and fully peer-reviewed by external reviewers. It is distributed in accordance with the Creative Commons Attribution NonCommercial (CC BY-NC 4.0) license, which permits others to

Suha Abu Khalaf, Department of Internal Medicine, University of Missouri, Columbia, MO 65212, United States

Abdulmajeed Albarrak, Department of Internal Medicine, College of Medicine, Qassim University, Buraydah 81999, Saudi Arabia

Abdulmajeed Albarrak, Mohamad Yousef, Veysel Tahan, Division of Gastroenterology and Hepatology, University of Missouri, Columbia, MO 65212, United States

Corresponding author: Suha Abu Khalaf, MD, Doctor, Resident Physician, Department of Internal Medicine, University of Missouri, 1 Hospital Dr, Columbia, MO 65212, United States. abukhalafs@health.missouri.edu

Abstract

BACKGROUND

Colitis is one of the immune-related side effects of immunotherapy. Usually, such type of side effect was reported to develop within a few weeks of treatment initiation, our case started within a few days.

CASE SUMMARY

We present a case of a 37-year-old gentleman with bright red loose stools, abdominal pain, and tenesmus. A diagnosis of colitis was made based on endoscopic and histologic findings. Treatment was thereafter continued with oral steroids and discontinuation of the immunotherapy medications. Symptoms resolved after starting the treatment and the patient continued to be symptom-free on subsequent follow-up. The unique about this case report is that the patient developed bloody diarrhea within five days of the 1st immunotherapy cycle, and the patient was on combined ipilimumab and nivolumab.

CONCLUSION

Immunotherapy related complications might occur within days from being on immunotherapy; we need more research to open the way for future pathological and clinical research to further understand the pathophysiology behind it.

Key words: Immunotherapy; Colitis; Melanoma; Case report; Ipilimumab; Hepatitis

©The Author(s) 2020. Published by Baishideng Publishing Group Inc. All rights reserved.

Core tip: Immunotherapy is one of the novel treatments of this century, though it can

distribute, remix, adapt, build upon this work non-commercially, and license their derivative works on different terms, provided the original work is properly cited and the use is non-commercial. See: <http://creativecommons.org/licenses/by-nc/4.0/>

Manuscript source: Invited manuscript

Received: January 18, 2020

Peer-review started: January 18, 2020

First decision: April 16, 2020

Revised: May 7, 2020

Accepted: May 19, 2020

Article in press: May 19, 2020

Published online: June 15, 2020

P-Reviewer: Aykan NF, Cao ZF, Ebrahimifar M, Rassy EE

S-Editor: Dou Y

L-Editor: A

E-Editor: Qi LL



cause many predicted and unpredicted immune-related side effects. This is a rare case of immunotherapy induced colitis in an otherwise healthy male who was recently diagnosed with melanoma and was started on appropriate immunotherapy treatment. Clinicians should keep in mind the possible immune side effects of immune checkpoint inhibitors as they can develop at any stage, which will help physicians in stopping these medications earlier and avoiding further serious harm.

Citation: Abu Khalaf S, Albarrak A, Yousef M, Tahan V. Immune checkpoint inhibitors induced colitis, stay vigilant: A case report. *World J Gastrointest Oncol* 2020; 12(6): 699-704
URL: <https://www.wjgnet.com/1948-5204/full/v12/i6/699.htm>
DOI: <https://dx.doi.org/10.4251/wjgo.v12.i6.699>

INTRODUCTION

Immunotherapy are classes of medications that can affect the immune system at different levels to be able to fight cancer cells^[1], one of the Immunotherapy types is the immune checkpoint inhibitors (ICIs), their administration could be associated with various immune-related side effects; such as colitis^[2]. Our patient is a 37-year-old gentleman who complained of the passage of bright red loose stools, abdominal pain, and tenesmus. His symptoms started five days after the first immunotherapy cycle for melanoma treatment; he was on combined ipilimumab and nivolumab. A diagnosis of colitis was made based on endoscopic and histologic findings. The primary core stone for the treatment of high-grade immunotherapy induced-gastrointestinal (GI) adverse events is the cessation of the immunotherapy and/or the introduction of anti-inflammatory therapy^[3]. Our patient was treated with oral prednisone and discontinuation of immunotherapy.

CASE PRESENTATION

Chief complaints

A 37-year-old presented in August 2018 with chief complaints of bloody diarrhea of one-day duration which was accompanied by generalized abdominal pain, feeling of tenesmus, anorexia, and weight loss of 10 kg which were all noted along the previous few days prior to presentation. The temperature was maintained at 99-100 °F/37.2-37.8 °C.

History of present illness

He describes his recent bowel movements as irregular, loose, and bloody bowel movements, with a frequency of 10-15 times per day for one day.

History of past illness

He denied having chills, night sweats, arthralgia, eye pain, rash, ingestion of undercooked meat, sick contact, or recent travel history. patient denies any previous history of abdominal pain, bloody diarrhea, arthralgia, visual problems, or skin rash. Medical history was remarkable for a recent diagnosis of metastatic melanoma in left axillary lymph nodes with a positive BRAF marker with the staging of (T0, N3c, M0). No personal or family history of colitis. The symptoms started five days after starting nivolumab and ipilimumab treatment.

Physical examination

On medical exam, his vital signs were unremarkable. On general inspection of the abdomen, there was no distension, superficial palpation revealed generalized abdominal tenderness without rigidity. Otherwise, the physical examination was unremarkable.

Laboratory examinations

Laboratory tests were significant for leukocytosis, and isolated elevation in alanine transaminase, cholestasis labs with alkaline phosphatase, and bilirubin were within the normal range, liver synthetic function tests showed slightly reduced albumin, inflammatory markers including Erythrocyte sedimentation rate was within the normal range whereas C-reactive protein was mildly elevated. Initial significant

laboratory results values included a hemoglobin level of 14.0 g/dL, leukocytes of $12.39 \times 10^9/L$, and platelet count $475 \times 10^9/L$; other test results included a creatinine 1.19 mg/dL, blood urea nitrogen 16 mg/dL, alanine transaminase 124 U/L, aspartate aminotransferase 21 U/L, albumin 3.7 g/dL, C-reactive protein 2.13 mg/dL. Fecal pathogen panel and *Clostridioides difficile* test didn't show any detected positive results.

Imaging examinations

Abdominal computed tomography scan revealed inflammatory changes involving the mildly thickened walls of the transverse and descending colon.

MULTIDISCIPLINARY EXPERT CONSULTATION

Gastroenterology, Infectious disease, and Hematology/Oncology were consulted. a colonoscopy was performed. Colonoscopy revealed widespread inflammatory findings with erythematous mucosa and diffuse ulcerative lesions involving the large intestine and rectum (Figure 1) but sparing the terminal ileum. Colon biopsies revealed acute ulcerative inflammation with formation of granulation tissue (Figure 2). Infectious workup was unremarkable for diarrhea so Infectious disease recommended discontinuation of antibiotics.

FINAL DIAGNOSIS

Based on the history, endoscopic and histologic exams, the patient was diagnosed with grade IV colitis induced by immunotherapy.

TREATMENT

On admission, empiric antibiotic coverage with ciprofloxacin and metronidazole was started while waiting for cultures. In addition, a high dose prednisone of 80 mg daily was started empirically. Antibiotics were discontinued after one week. The dose of prednisone was increased to 120 mg daily after colonoscopy findings of grade IV colitis in the setting of persistent mildly improved diarrhea, continued on this dose for two weeks. He was transitioned to 80 mg daily with the tapering schedule for over one and a half months.

OUTCOME AND FOLLOW-UP

The patient was able to wean off the prednisone totally after two months, his symptoms have improved and currently denied any bloody diarrhea. The immunotherapy cycles were discontinued due to the colitis event. The patient received two months of prednisone treatment. His immunotherapy regimen was changed to dabrafenib and trametinib (BRAF/MEK inhibitors) for melanoma. The patient continued to report no complaints. He refused to undergo follow up colonoscopy.

DISCUSSION

Immunotherapies are very broad-spectrum medications that can be used in the treatment of different types of diseases including malignancies; one of the immunotherapy classes is the ICIs. To differentiate between normal and foreign cells, the immune system uses checkpoints, which function as regulators of the immune system; when stimulated, it slows down the immune response to the insult, and when inhibited/blocked the immune system is going to keep working, so the idea behind using the immunotherapy checkpoint inhibitors is to keep the cycle on without brakes. The drawback of this mechanism is the unspecific and unchecked activation of the immune system cells, which has resulted in overshooting immune response and autoimmune diseases. Scientists found that the cancer cells can protect themselves from immune attack by stimulating the checkpoints; Among these checkpoints are the cytotoxic T-lymphocyte antigen-4 (CTLA-4) and programmed cell death-1 which are receptors located on the T cells, their role is to inhibit T cells by various mechanisms^[1].

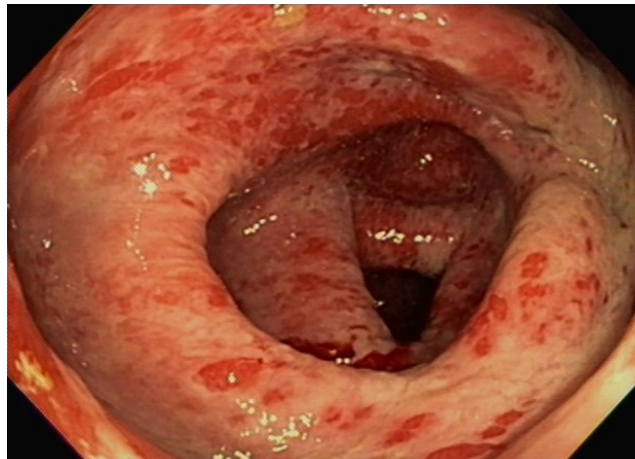


Figure 1 Endoscopic image of our patient who developed bloody diarrhea within five days of starting immunotherapy, the picture shows his transverse colon which was affected by grade IV severe pancolitis given diffuse erythema, inflammation, ulcers, and some patchy membrane at the proximal colon. Terminal ileum was examined, and it was unremarkable (no picture was included).

Checkpoints inhibitors have achieved remarkable outcomes with different types of cancers. Since the time of approval of the ICIs, Advanced metastatic melanoma's survival rate has improved significantly, which resulted in expanding their use in other malignancies at the expense of rising autoimmune-related side effects. Case reports have drawn attention towards various GI tract related autoimmune adverse effects, including but not limited to diarrhea, colitis, and hepatitis^[2-4].

Diarrhea, colitis, and hepatitis are clinically graded using the Common Terminology Criteria for Adverse Events V.4 which was developed by the National Cancer Institute of the National Institutes of Health^[5].

Parakh *et al*^[6] found in a study of 45 patients who received a combination of nivolumab (anti- programmed cell death-1), and ipilimumab (anti-CTLA-4) that adverse events due to the immunotherapy were reported in the majority of the patients, and in more than 50% of the patients, they were high-grade adverse events. Forty-four percent of the patients had the treatment discontinued^[6].

Of patients who have been treated with ipilimumab, high-grade adverse events related to the treatment have been reported in 27.3%, diarrhea was reported in 35%^[2,6], only 5% of those taking ipilimumab experienced grade 3 or 4 colitis^[2], it was reported that the average duration to develop diarrhea is 5-8 wk after starting ipilimumab^[3]. Of patients who have been treated with nivolumab, high-grade adverse events were reported in 16.3%, diarrhea was reported in 17%-20%^[6], notably nivolumab will take a longer time to cause diarrhea; in average 3-6 mo^[3].

In patients who have been treated with nivolumab and ipilimumab combination, development of high-grade adverse events connected to the treatment were reported in 55%, and diarrhea was reported in 44%^[6]. It is reported that a combination of therapy involving ipilimumab might cause diarrhea with a median onset of 5-8 wk after starting the treatment^[3]. The patient was receiving nivolumab and ipilimumab therapy, and his symptoms developed acutely in five days following the first therapy period.

The combination therapy has a higher incidence of adverse effects in comparison with the individualized treatment, immune checkpoints inhibitors work through different pathways, to boost the effector T cell response which will lead to a robust immune-inflammatory response required for tumor-fighting^[3,7].

No accurate statistics about the colitis as a side effect of immunotherapy, part of the reason is that the colonoscopy is not indicated for every case of colitis. Persistent diarrhea of grades two or more should be evaluated with colonoscopy. Macroscopic and microscopic findings of immunotherapy related-GI effects were reported, including exudates, granularity, erythema, loss of vascularity, and ulcerations. The main finding is pancolitis. However, normal findings were reported too. It is recommended to take biopsies even with normal-appearing mucosa, to rule out colitis^[3,8].

The primary cornerstone for treatment of high-grade immunotherapy induced-GI adverse events is the cessation of the immunotherapy and/or the introduction of anti-inflammatory therapy, route, and duration of anti-inflammatory therapy are based on the National Cancer Institute's Common Terminology Criteria for Adverse Events

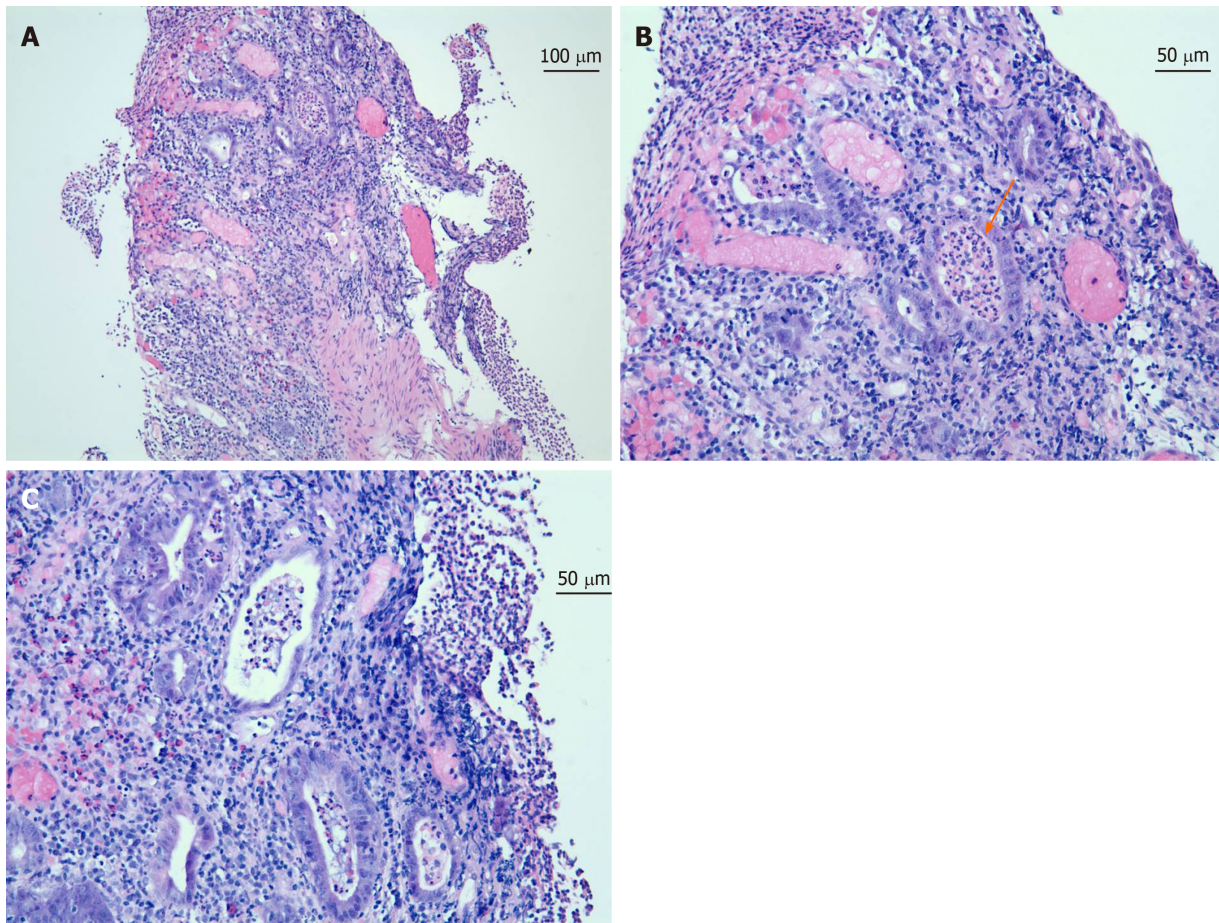


Figure 2 Colon mucosa biopsies stained with hematoxylin and eosin showing neutrophilic inflammation with cryptitis and crypt abscess as well as mucin depletion. A: Low power view 10 × highlighting distorted glands; B and C: Medium power view 20 ×, crypt abscess (orange arrow in B) and diffuse inflammation in the background.

grades of diarrhea and colitis^[8,9].

In refractory cases, a single dose of infliximab might be beneficial^[10]. Symptomatic improvement with mesalazine treatment was reported^[8]. A combination of mycophenolate mofetil and high-dose corticosteroids may speed up the recovery^[10]. Therapy with a vedolizumab was reported to be effective in a patient who was steroid-dependent^[11].

It is becoming more apparent that immunotherapy induced colitis has a lot in common with inflammatory bowel disease (IBD), including the clinical presentation, macroscopic, microscopic, and serological findings. However, what can be a difference is the acuity of the symptoms, patients with immunotherapy induced colitis tend to have an accelerated clinical course, unlike IBD, which has a chronic relapsing course usually. Moreover, immunotherapy induced colitis is reversible with the cessation of the immunotherapy and the introduction of the steroid or other anti-inflammatory medications. Another aspect of the relation between immunotherapy-induced colitis and IBD is anti-CTLA-4 colitis which is associated with the production of serologies specific to Ulcerative colitis and Crohn's diseases^[2,12].

CONCLUSION

We are reporting this adverse event to raise clinicians' awareness of this possible complication which might occur within days from being on immunotherapy and to open the way for future pathological and clinical research to further understand the pathophysiology behind it, and its possible relationship to IBD which might help in developing methods to avoid such severe complication and aid in shedding the light on some poorly understood concepts of IBD.

ACKNOWLEDGEMENTS

Thank you to Nitya Prabhakaran, the pathology chief resident for helping out in getting the pathology slides.

REFERENCES

- 1 **Herzberg B**, Fisher DE. Metastatic melanoma and immunotherapy. *Clin Immunol* 2016; **172**: 105-110 [PMID: 27430520 DOI: 10.1016/j.clim.2016.07.006]
- 2 **Bertha M**, Bellaguara E, Kuzel T, Hanauer S. Checkpoint Inhibitor-Induced Colitis: A New Type of Inflammatory Bowel Disease? *ACG Case Rep J* 2017; **4**: e112 [PMID: 29043290 DOI: 10.14309/crj.2017.112]
- 3 **Karamchandani DM**, Chetty R. Immune checkpoint inhibitor-induced gastrointestinal and hepatic injury: pathologists' perspective. *J Clin Pathol* 2018; **71**: 665-671 [PMID: 29703758 DOI: 10.1136/jclinpath-2018-205143]
- 4 **Wang Y**, Matthew C, Abraham S, Cotton I, Zuazua R. A Unique Case of Immunotherapy-Induced Colitis in a 50-year-old Female With Bladder Cancer. *Am J Gastroenterol* 2017; **112**: S798-S800
- 5 **US Department of Health and Human Services**, National Institutes of Health, National Cancer Institute. Common Terminology Criteria for Adverse Events (CTCAE) Version 4.0. [published 28 May 2009]. v4.03: June 14, 2010. Available from: https://evs.nci.nih.gov/ftp1/CTCAE/CTCAE_4.03/CTCAE_4.03_2010-06-14_QuickReference_8.5x11.pdf
- 6 **Parakh S**, Randhawa M, Nguyen B, Warburton L, Hussain MA, Cebon J, Millward M, Yip D, Ali S. Real-world efficacy and toxicity of combined nivolumab and ipilimumab in patients with metastatic melanoma. *Asia Pac J Clin Oncol* 2019; **15**: 26-30 [PMID: 30426665 DOI: 10.1111/ajco.13100]
- 7 **Wei W**, Luo Z. Risk of gastrointestinal toxicities with PD-1 inhibitors in cancer patients: A meta-analysis of randomized clinical trials. *Medicine (Baltimore)* 2017; **96**: e8931 [PMID: 29310385 DOI: 10.1097/MD.00000000000008931]
- 8 **Yamauchi R**, Araki T, Mitsuyama K, Tokito T, Ishii H, Yoshioka S, Kuwaki K, Mori A, Yoshimura T, Tsuruta O, Torimura T. The characteristics of nivolumab-induced colitis: an evaluation of three cases and a literature review. *BMC Gastroenterol* 2018; **18**: 135 [PMID: 30170560 DOI: 10.1186/s12876-018-0864-1]
- 9 **Gupta A**, Khanna S. Ipilimumab-associated colitis or refractory *Clostridium difficile* infection? *BMJ Case Rep* 2015; **2015** [PMID: 26153295 DOI: 10.1136/bcr-2015-211160]
- 10 **Mir R**, Shaw HM, Nathan PD. Mycophenolate mofetil alongside high-dose corticosteroids: optimizing the management of combination immune checkpoint inhibitor-induced colitis. *Melanoma Res* 2019; **29**: 102-106 [PMID: 30395075 DOI: 10.1097/CMR.0000000000000543]
- 11 **Hsieh AH**, Ferman M, Brown MP, Andrews JM. Vedolizumab: a novel treatment for ipilimumab-induced colitis. *BMJ Case Rep* 2016; **2016** [PMID: 27539137 DOI: 10.1136/bcr-2016-216641]
- 12 **Kohoutova D**, Drahosova M, Moravkova P, Rejchrt S, Bures J. Anti-Outer membrane protein C and anti-glycoprotein 2 antibodies in inflammatory bowel disease and their association with complicated forms of Crohn's disease. *BMC Gastroenterol* 2014; **14**: 190 [PMID: 25551469 DOI: 10.1186/s12876-014-0190-1]



Published by Baishideng Publishing Group Inc
7041 Koll Center Parkway, Suite 160, Pleasanton, CA 94566, USA
Telephone: +1-925-3991568
E-mail: bpgoffice@wjgnet.com
Help Desk: <https://www.f6publishing.com/helpdesk>
<https://www.wjgnet.com>

