

World Journal of *Clinical Cases*

World J Clin Cases 2020 July 6; 8(13): 2674-2892



OPINION REVIEW

- 2674 Minimizing the risk of community spread of COVID-19 *via* institutional quarantine of high-risk travelers with serial viral RNA testing: A successful experience from Macao SAR, China
Lio CF, Cheong HH, Lei CI, Lo IL, Lam C, Leong IH

REVIEW

- 2679 Balloon pulmonary angioplasty for chronic thromboembolic pulmonary hypertension: State of the art
Jin Q, Zhao ZH, Luo Q, Zhao Q, Yan L, Zhang Y, Li X, Yang T, Zeng QX, Xiong CM, Liu ZH
- 2703 Advances in para-aortic nodal dissection in gastric cancer surgery: A review of research progress over the last decade
Dong YP, Deng JY
- 2717 Relevance on the diagnosis of malignant lymphoma of the salivary gland
Zhang XY, Wang ZM

ORIGINAL ARTICLE

Clinical and Translational Research

- 2727 Role of peripheral eosinophilia in acute exacerbation of chronic obstructive pulmonary disease
Wu CW, Lan CC, Hsieh PC, Tzeng IS, Wu YK

Case Control Study

- 2738 Effects of prostaglandin E combined with continuous renal replacement therapy on septic acute kidney injury
Lei L, Wang MJ, Zhang S, Hu DJ

Retrospective Study

- 2749 Modified technique of advanced core decompression for treatment of femoral head osteonecrosis
Lin L, Jiao Y, Luo XG, Zhang JZ, Yin HL, Ma L, Chen BR, Kelly DM, Gu WK, Chen H
- 2758 Initial experience with stereotactic body radiotherapy for intrahepatic hepatocellular carcinoma recurrence after liver transplantation
Au KP, Chiang CL, Chan ACY, Cheung TT, Lo CM, Chok KSH
- 2769 Correlation between age of onset and gastrointestinal stenosis in hospitalized patients with Crohn's disease
Yang SB, Du SW, Wang JH
- 2778 Adjuvant nab-paclitaxel plus gemcitabine *vs* gemcitabine alone for resected pancreatic ductal adenocarcinoma: A single center experience in China
Yin ZZ, Zhao ZM, Tang WB, Jiang N, Zhang KD, Song YY, Wang Y, Li CG, Gao YX, Liu R

Observational Study

- 2787 Case studies in psychotherapy training using Austria as an example

Neidhart E, Löffler-Stastka H

Prospective Study

- 2802 Correlation between crowdedness in emergency departments and anxiety in Chinese patients

Wang S, Gao JY, Li X, Wu Y, Huo XX, Han CX, Kang MJ, Sun H, Ge BL, Liu Y, Liu YQ, Zhou JP, Wang Z

SCIENTOMETRICS

- 2817 Bibliometric analysis of subject trends and knowledge structures of gut microbiota

Yue YY, Fan XY, Zhang Q, Lu YP, Wu S, Wang S, Yu M, Cui CW, Sun ZR

CASE REPORT

- 2833 Acute myelomonocytic leukemia during pembrolizumab treatment for non-small cell lung cancer: A case report

Kim HB, Park SG, Hong R, Kang SH, Na YS

- 2841 Metallic ureteral stent in restoring kidney function: Nine case reports

Gao W, Ou TW, Cui X, Wu JT, Cui B

- 2849 Pheochromocytoma with delayed tumor thrombus detection in renal vein: A case report

Jia Z, Wang BJ, Li X, Zhang X

- 2855 Laparoscopic repair of uterine rupture following successful second vaginal birth after caesarean delivery: A case report

Cai YQ, Liu W, Zhang H, He XQ, Zhang J

- 2862 Missed diagnosis of femoral deep artery rupture after femoral shaft fracture: A case report

Ge J, Kong KY, Cheng XQ, Li P, Hu XX, Yang HL, Shen MJ

- 2870 Posterior reversible encephalopathy syndrome and heart failure tacrolimus-induced after liver transplantation: A case report

Liu JF, Shen T, Zhang YT

- 2876 Significant benefits of pembrolizumab in treating refractory advanced pulmonary sarcomatoid carcinoma: A case report

Chen P, Yu M, Zhang JL, Chen WY, Zhu L, Song Y, Jiang CY, Zhang S

- 2885 Two sequential surgeries in infant with multiple floor of the mouth dermoid cysts: A case report

Liu NN, Zhang XY, Tang YY, Wang ZM

ABOUT COVER

Editorial board member of *World Journal of Clinical Cases*, Dr. El Ghoch is a Full Professor in the Faculty of Health Sciences, Beirut Arab University, Lebanon. Having received his MD degree from University of Bologna, Italy in 2005, and undertook his postgraduate degree in Clinical Nutrition at the University of Modena and Reggio Emilia, Italy in 2009. In the following 10 year, he had a wide clinical and research activity in Italy in the field of obesity and eating disorders, and gained an international leadership in the study of the body composition in anorexia nervosa. In October 2018 he was appointed as Professor in the Clinical Nutrition, and Chairperson of the Department of Nutrition and Dietetics, Beirut Arab University, Lebanon. His ongoing research interests are body composition, physical activity, weight cycling, etc.

AIMS AND SCOPE

The primary aim of *World Journal of Clinical Cases* (*WJCC*, *World J Clin Cases*) is to provide scholars and readers from various fields of clinical medicine with a platform to publish high-quality clinical research articles and communicate their research findings online.

WJCC mainly publishes articles reporting research results and findings obtained in the field of clinical medicine and covering a wide range of topics, including case control studies, retrospective cohort studies, retrospective studies, clinical trials studies, observational studies, prospective studies, randomized controlled trials, randomized clinical trials, systematic reviews, meta-analysis, and case reports.

INDEXING/ABSTRACTING

The *WJCC* is now indexed in Science Citation Index Expanded (also known as SciSearch®), Journal Citation Reports/Science Edition, PubMed, and PubMed Central. The 2020 Edition of Journal Citation Reports® cites the 2019 impact factor for *WJCC* as 1.013 (5-year impact factor: N/A), ranking *WJCC* as 120 among 165 journals in medicine, general and internal (quartile in category Q3).

RESPONSIBLE EDITORS FOR THIS ISSUE

Electronic Editor: Yan-Xia Xing, Production Department Director: Yun-Xiaojian Wu, Editorial Office Director: Jin-Lai Wang.

NAME OF JOURNAL

World Journal of Clinical Cases

ISSN

ISSN 2307-8960 (online)

LAUNCH DATE

April 16, 2013

FREQUENCY

Semimonthly

EDITORS-IN-CHIEF

Dennis A Bloomfield, Sandro Vento, Bao-Gan Peng

EDITORIAL BOARD MEMBERS

<https://www.wjgnet.com/2307-8960/editorialboard.htm>

PUBLICATION DATE

July 6, 2020

COPYRIGHT

© 2020 Baishideng Publishing Group Inc

INSTRUCTIONS TO AUTHORS

<https://www.wjgnet.com/bpg/gerinfo/204>

GUIDELINES FOR ETHICS DOCUMENTS

<https://www.wjgnet.com/bpg/GerInfo/287>

GUIDELINES FOR NON-NATIVE SPEAKERS OF ENGLISH

<https://www.wjgnet.com/bpg/gerinfo/240>

PUBLICATION ETHICS

<https://www.wjgnet.com/bpg/GerInfo/288>

PUBLICATION MISCONDUCT

<https://www.wjgnet.com/bpg/gerinfo/208>

ARTICLE PROCESSING CHARGE

<https://www.wjgnet.com/bpg/gerinfo/242>

STEPS FOR SUBMITTING MANUSCRIPTS

<https://www.wjgnet.com/bpg/GerInfo/239>

ONLINE SUBMISSION

<https://www.f6publishing.com>

Retrospective Study

Modified technique of advanced core decompression for treatment of femoral head osteonecrosis

Lin Lin, Yan Jiao, Xian-Guo Luo, Jin-Zhu Zhang, He-Liang Yin, Li Ma, Bo-Ran Chen, Derek M Kelly, Wei-Kuan Gu, Hong Chen

ORCID number: Lin Lin 0000-0002-6158-9539; Yan Jiao 0000-0002-3913-8918; Xian-Guo Luo 0000-0003-2898-4411; Jin-Zhu Zhang 0000-0002-9457-2661; He-Liang Yin 0000-0002-9843-2201; Li Ma 0000-0001-8057-6170; Bo-Ran Chen 0000-0002-0246-2722; Derek M Kelly 0000-0002-9113-3858; Wei-Kuan Gu 0000-0003-1112-8088; Hong Chen 0000-0003-2556-4489.

Author contributions: Lin L and Gu WK carried out the studies, participated in collecting the data, and drafted the manuscript; Jiao Y and Kelly DM reviewed the language and helped to draft the manuscript; Luo XG and Zhang JZ participated in its design; Yin HL, Ma L, and Chen BR participated in collecting the data; Chen H acquired funding and project administration; all authors read and approved the final manuscript.

Supported by The First Hospital of Qiqihar, No. 2013-006; and Department of Veterans Affairs and the Veterans Administration Medical Center in Memphis, No. 101 BX000671.

Institutional review board statement: This study was reviewed and approved by the Ethics Committee of first hospital of Qiqihar city.

Lin Lin, Yan Jiao, He-Liang Yin, Li Ma, Derek M Kelly, Wei-Kuan Gu, Department of Orthopedic Surgery and BME-Campbell Clinic, University of Tennessee Health Science Center, Memphis, TN 38163, United States

Lin Lin, Xian-Guo Luo, Jin-Zhu Zhang, He-Liang Yin, Li Ma, Bo-Ran Chen, Hong Chen, Center of Integrative Research, The First Hospital of Qiqihar, Qiqihaer 161005, Heilongjiang Province, China

Lin Lin, Xian-Guo Luo, Jin-Zhu Zhang, He-Liang Yin, Li Ma, Bo-Ran Chen, Hong Chen, Affiliated Qiqihar Hospital, Southern Medical University, Qiqihaer 161005, Heilongjiang Province, China

Lin Lin, Xian-Guo Luo, Jin-Zhu Zhang, The Precision Treatment Institute of Jinzhu Osteoarthritis in Qiqihar, Qiqihaer 161005, Heilongjiang Province, China

Wei-Kuan Gu, Research Service 151, VA Medical Center, Memphis, TN 38112, United States

Corresponding author: Wei-Kuan Gu, PhD, Professor, Department of Orthopedic Surgery and BME-Campbell Clinic, University of Tennessee Health Science Center, 956 Court Ave, Memphis, TN 38163, United States. wgu@uthsc.edu

Abstract

BACKGROUND

Osteonecrosis of the femoral head (ONFH) is a destructive condition most commonly affecting young and middle-aged patients. The leading consequence of ONFH is often a significant articular disability. Effective joint-preserving surgical treatments are urgently needed for patients with early stage ONFH when outcomes of treatment are in general better than the advanced stage disease.

AIM

To introduce a new surgery procedure called percutaneous expanded core decompression and mixed bone graft technique, which is a new way of joint-preserving surgical treatments.

METHODS

The clinical data of 6 patients with ONFH diagnosed and treated with the procedure called percutaneous expanded core decompression and mixed bone

Informed consent statement: All participants provided written informed consent.

Conflict-of-interest statement: The authors declare that they have no conflicts of interest.

Data sharing statement: No additional data are available.

Open-Access: This article is an open-access article that was selected by an in-house editor and fully peer-reviewed by external reviewers. It is distributed in accordance with the Creative Commons Attribution NonCommercial (CC BY-NC 4.0) license, which permits others to distribute, remix, adapt, build upon this work non-commercially, and license their derivative works on different terms, provided the original work is properly cited and the use is non-commercial. See: <http://creativecommons.org/licenses/by-nc/4.0/>

Manuscript source: Unsolicited manuscript

Received: March 2, 2020

Peer-review started: March 2, 2020

First decision: April 22, 2020

Revised: May 14, 2020

Accepted: May 30, 2020

Article in press: May 30, 2020

Published online: July 6, 2020

P-Reviewer: Salvadori M

S-Editor: Liu M

L-Editor: Filipodia

E-Editor: Liu JH



graft technique at The First Hospital of Qiqihar from March 2013 to August 2019 were retrospectively analyzed; the follow-up ended in December 2019.

RESULTS

There were 6 male patients with an average age of 43 years in our study. Gratifying results have been obtained from the comparison of Harris hip score, visual analogue scale, and imaging examination before and after operation.

CONCLUSION

This new modified technique is simple, safe, and reliable. No serious perioperative complications were observed in our cases. Advantages of the single blade expandable reamer are obvious. The adjuvant substance is inexpensive and easy to obtain. Thus, this technique is an effective joint-preserving surgical treatment for patients with early stage of ONFH.

Key words: Osteonecrosis of the femoral head; Advanced core decompression; Mixed bone graft; Single blade expandable reamer; Autologous bone marrow aspirate; Joint-preserving surgical treatments

©The Author(s) 2020. Published by Baishideng Publishing Group Inc. All rights reserved.

Core tip: Percutaneous expanded core decompression and mixed bone graft technique is simple, safe, and reliable. In our cases no serious perioperative complications were observed. Advantages of the single blade expandable reamer are obvious. The adjuvant is inexpensive and easy to obtain. Thus, this technique is an effective joint-preserving surgical treatment for patients with early stage of osteonecrosis of the femoral head. It is easy to master as well as costs less. We present it here in the hope that colleagues in other institutions could try to use it and together to fully demonstrate its effectiveness.

Citation: Lin L, Jiao Y, Luo XG, Zhang JZ, Yin HL, Ma L, Chen BR, Kelly DM, Gu WK, Chen H. Modified technique of advanced core decompression for treatment of femoral head osteonecrosis. *World J Clin Cases* 2020; 8(13): 2749-2757

URL: <https://www.wjgnet.com/2307-8960/full/v8/i13/2749.htm>

DOI: <https://dx.doi.org/10.12998/wjcc.v8.i13.2749>

INTRODUCTION

Osteonecrosis of the femoral head (ONFH) is a destructive condition most commonly affecting young and middle-aged patients. ONFH often progresses to femoral head collapse, which in some cases can lead to total hip arthroplasty (THA)^[1-4]. The treatment of ONFH has been studied extensively, and there are many options available for ONFH, including both nonsurgical treatment and surgical treatment. However, there is little supporting data on nonsurgical treatment when the condition is identified in the early stages. Activity modification with restricted weight bearing is often used for symptom relief but does not seem to alter disease progression^[5,6]. Pharmacologic and biophysical treatments of ONFH consist of bisphosphonates, anticoagulants, vasodilators, statins, and biophysical modalities. The current state of nonsurgical treatment modalities for treatment of ONFH is still quite experimental in nature.

The most common surgical treatment is core decompression (with or without adjuvants) for early stage disease and THA. For patients with advanced stage of ONFH or failure of joint-preserving surgical treatments, THA is a better choice with excellent outcomes in terms of pain relief and survivorship^[1,4,7]. Despite the excellent survivorship of THA, most patients with ONFH are young when they receive their THA, leaving them most likely to experience loosening and revision in their lifetime^[8]. The ideal goal of early stage treatment is to postpone or stop the progression of the disease before femoral head collapse. Therefore, the most suitable time to intervene is the early stage of the disease before the mechanical failure of the subchondral bone and femoral head collapse, which belong to Association Research Circulation Osseous (ARCO) classification system stage I and II. A consensus has been reached on the

following treatment modalities against the ONFH: Joint-preserving surgery for early stage and arthroplasty for later stage^[9].

Core decompression is a joint-preserving surgical treatment that aims to improve blood flow and decrease intraosseous pressure for relieving pain. Its main goal is to promote early healing prior to collapse, thereby potentially postponing or avoiding THA^[4,10]. But studies have shown that the femoral head after simple decompression may not provide structural support; as a result, the risk of femoral head collapse increases^[11,12].

Bone grafting has been used to treat ONFH since the mid-twentieth century and is theorized to prevent femoral head collapse by providing structural support and establishing a stable environment for the growth of new bone^[13]. Kong *et al*^[14] studied the outcome of percutaneous core decompression with bone grafting on ONFH. They concluded that this method can be used to effectively treat the early stage of ONFH. This treatment modality can also significantly relieve symptoms, improve movement of hip, and postpone or stop femoral head collapse^[14]. Zalavras *et al*^[3] treated 17 hips in 15 patients with core decompression with autologous bone graft, and allogenic fibula perfused with human bone morphogenetic protein and noncollagenous proteins. Through a mean follow-up of 53 mo, 14 of 15 hips (93%) had relief of outcomes and no radiographic progression. Now the clinical outcome of core decompression with bone grafting on early stage of ONFH has been confirmed^[3].

Advanced core decompression (ACD) is a relatively new technique using a percutaneous expandable reamer that allows more efficient removal of necrotic tissue from the femoral head^[15-17]. Our new method is to use a single blade expandable reamer (Yierkang Technology Development Co., Ltd, Beijing, CHN) so that the lesion can be removed more precisely and thoroughly (Figure 1). Residual necrotic lesions are removed by cleaning with a sharp spoon. We use autologous bone from the ipsilateral ilium mixing allogeneic bone pieces with autologous bone marrow aspirate (BMA) and backfill the bone defects in the femoral head. We consider this is a good improvement of traditional surgical technique.

The aim of this article is to introduce a new modified surgical technique of ACD for early stage ONFH and demonstrate with one case from a group of patients treated with this method.

MATERIALS AND METHODS

Ideal patient selection

The patients for this treatment were chosen based on the 2012 Expert Consensus on the Diagnosis and Treatment Criteria for Adult Osteonecrosis of Femoral Head and belonged to the stage II of the ARCO classification system (Figure 2).

In addition, they needed to fulfill the following requirements: (1) The boundary of osteonecrosis in the femoral head was clear; (2) The patient's age was under 60-years-old; and (3) Good hip range of motion in order to maintain the requirements of intraoperative position.

The outcome was evaluated by the Harris hip score (HHS), visual analogue scale (VAS), radiography, and computed tomography changes preoperative and postoperative.

Surgical technique

Our new method is similar to the ACD procedure described by Landgraeber *et al*^[17]. Improvements were made in expandable reamer and adjuvant substances.

The surgery was performed with the patient lying flat on a trauma table and receiving continuous epidural anesthesia or general anesthesia (Figure 3A).

After the best entrance point for the drilling had been defined, a 2-3 cm skin incision at the distal end of the tuberculum innominatum was made. A 2.5 mm guide wire into the lesion area was introduced, then the introducer was placed (Figure 1C and D) along the guide wire and fixed on the lateral cortical bone of the femur. The design of this introducer made it easy and safe for the trephine to enter the bone. Then a 12 mm trephine into the lesion area under guidance of the introducer. To avoid deviation from the correct drilling, the trephine was guided by the introducer and the guide wire (Figure 3B). Then the introducer and the guide wire were removed, and a 10 mm trephine into the 12 mm trephine was drilled by turning the 10 mm trephine the cancellous bone in the femoral neck and a bone cylinder from the lateral cortical bone of femur. Afterwards, the drilling was completed with the 12 mm cannulated drill. These steps must be performed under C-arm fluoroscopy in both directions to make

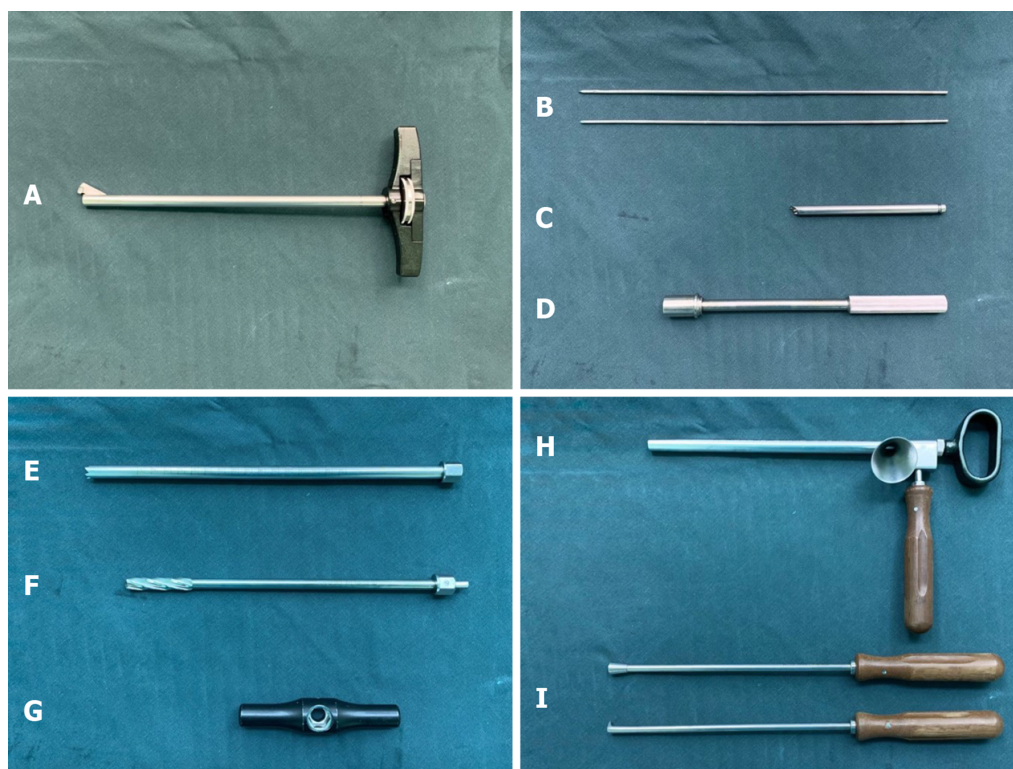


Figure 1 The tool for the surgery (Yierkang Technology Development Co., Ltd, Beijing, China). A: Single blade expandable reamer; B: 2.5 mm guide wire; C: The guiding device with a convex tip (introducer) for fixing it on the lateral cortical bone of femur; D: Retainer of the introducer; E: Trephine; F: Cannulated drill; G: Handle of the trephine and cannulated drill; H: Bone graft funnel; I: Pestles.


Stage	0	I	II	III	IV
Finding	All present techniques normal or nondiagnostic	X-ray and CT are normal, at least one of the blew mentioned is positive	No crescent sign, X-ray abnormal: Sclerosis, osteolysis, focal osteoporosis	Crescent sign or collapse on the X-ray and/or flattening of articular surface of femoral head	Osteoarthritis joint space narrowing, acetabular changes, joint destruction
Techniques	X-ray; CT; Scintigraph; MRI	Scintigraph; MRI; Quantitation on MRI	X-ray; CT; Scintigraph; MRI; Quantitation on MRI and X-ray	X-ray; CT; Quantitation on X-ray	X-ray
Sub-classification	NO	LOCATION medial central lateral 			NO
Quantitation	NO	Area involvement (%); minimal A: < 15%; moderate B: 15%-30%; extensive C: > 30%	Length of crescent (%); A: < 15%; B: 15%-30%; C: > 30%	Collapse and Dome depression; A: < 15% / < 2 mm; B: 15-30% / 2-4 mm; C: > 30% / > 4 mm	NO

Figure 2 Association Research Circulation Osseous classification system. CT: Computed tomography; MRI: Magnetic resonance imaging.

sure that the instruments were placed in the best possible position without damaging the cartilage or cortical bone.

The next step was different from the previous technique. A single blade expandable reamer into the drilling channel was introduced. By turning the handle and the blade control knob on it, the reamer can be rotated and the blades expanded under C-arm fluoroscopy to cut the necrotic lesion and dead bone as precisely as possible (Figure 3C). This instrument is different from the traditional expandable reamer in that its cutting plane is circular or fan-shaped by controlling the rotation angle. Therefore, its cutting range is more precise than traditional instruments, and the healthy bone can

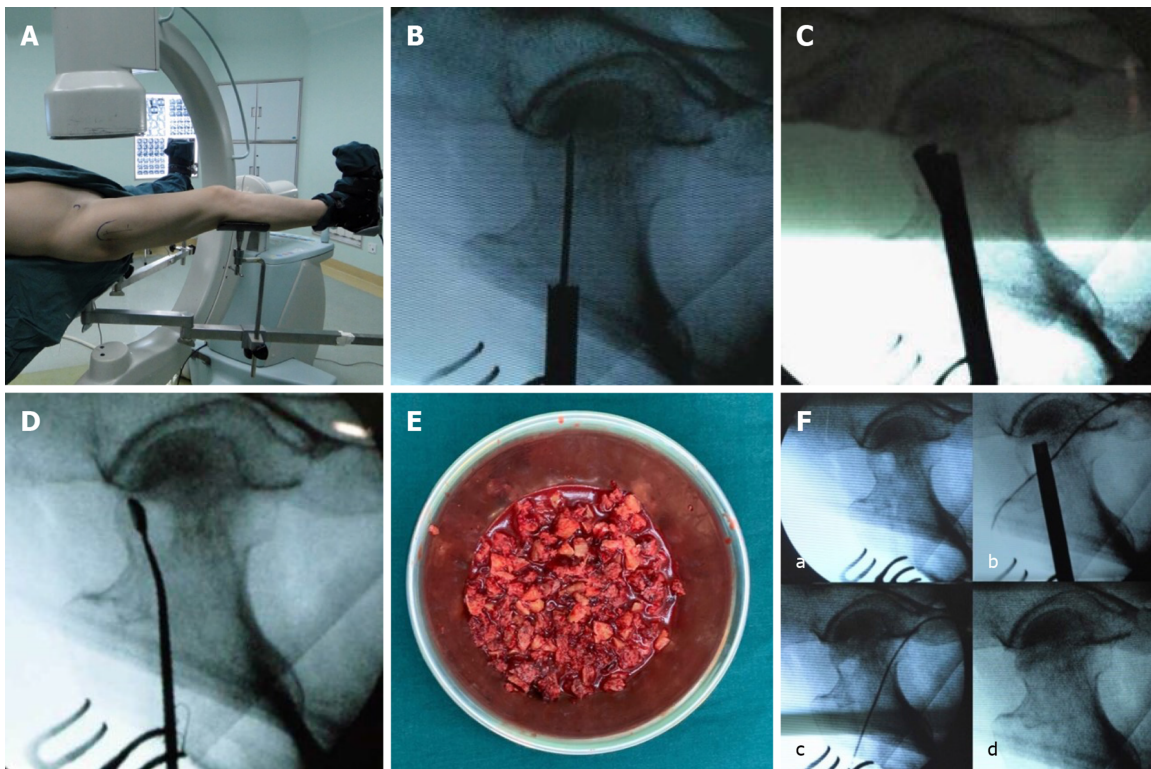


Figure 3 The main steps of the percutaneous expanded decompression and mixed bone graft technique under C-arm fluoroscopy. A: Intraoperative posture of the patient; B: A 12 mm trephine into the lesion area under guidance of the introducer; C: Turning the handle and the blade control knob on it. The reamer can be rotated and the blades expanded; D: The residual necrotic lesions are removed by cleaning with a sharp spoon; E: Autologous bone from the ipsilateral ilium mixing allogeneic bone pieces with bone marrow aspirate; F: a: Before bone grafting; b: Introduce the bone graft funnel into the drilling channel; c: Tamp the mixture with a pestle; d: Bone graft completed.

be retained to the maximum extent. After removal of the single blade expandable reamer, a sample of the necrotic lesion can be taken for pathological analysis to confirm the diagnosis. The residual lesions were removed by a sharp spoon (Figure 3D). Then the drilling channel and lesion area were flushed using a combination of irrigation and suction. These steps were important in order to remove the necrotic lesion and avoid postoperative infection. It should be repeated several times to achieve better results.

Finally, the lesion area and the surgical operation created bone defect were backfilled. This is another difference from the previous technique: We took the appropriate amount of cancellous bone and autologous BMA from the patient's ipsilateral ilium. Both autologous bone and allogeneic bone was divided into small pieces and mixed. After adding the BMA, the mixture (Figure 3E) was introduced through a bone graft funnel (Figure 1H) into the lesion area, and the mixture was tamped by a pestle. Lastly, bone cylinder was used to backfill the lateral of femur (Figure 3F).

The incision was closed by the standard steps. After operation, patients were routinely given infection prevention and venous thromboembolism prevention. They were asked to come to the hospital for reexamination regularly, and they were put on weight-bearing restriction for 4 wk or their doctor's recommendation.

RESULTS

Case example

A 49-year-old male patient was diagnosed with nontraumatic osteonecrosis of the right femoral head and had a history of hypertension and smoking. The pain of the right hip joint was accompanied by limited movement for 2 mo. Magnetic resonance imaging showed the evidence of osteonecrosis of the right femoral head in stage II b of the ARCO system. The preoperative HHS was 68, and VAS was 6. We operated on him by the method described in this article. The surgical time was 50 min, and intraoperative bleeding was 100 mL. After operation, the patient was routinely given

infection prevention and venous thromboembolism prevention. No complications occurred during the treatment. At 3 mo after surgery his HHS was 91, and VAS was 1. His right hip was almost free of discomfort. Radiography and computed tomography showed that the implanted bone was basically healed (Figure 4).

Since 2014, we have used this new modified technique in multiple patients, and gratifying results have been obtained from the comparison of HHS, VAS, and imaging examination before and after operation (Table 1).

DISCUSSION

ONFH is due to osteocyte ischemia and necrosis, trabecular fracture, and femoral head collapse induced by a local blood circulation disorder of the femoral head because of various factors^[3]. This disease is also a debilitating disease that leads to articular significant disability in young and middle-aged people. Without active and effective treatment, most of the patients need a THA after 2 years due to articular collapse^[11,18]. Current consensus is that THA is used just for advanced-stage ONFH in older patients or those who have failed joint-preserving treatment^[19]. Therefore, a definite and effective joint-preserving surgical treatment is urgently needed for young and middle-aged patients with early stage ONFH.

Core decompression combined with adjuvant substances as a joint-preserving surgical treatment has been widely recognized before^[3,10,20-22]. In recent years, studies also showed that patients with ARCO classification system stage II treated by ACD in combination with autologous bone and BMA had good outcomes^[23]. The usefulness of eliminating the necrotic bone and structural support by the adjuvant substances in the treatment of early ONFH has already been shown by other studies^[3,16,24].

The differences between us and previous technologies are application of the single blade expandable reamer and a new bone grafting method. The single blade expandable reamer structure is simpler, and the safety and reliability are higher when it is used in operation. The design of the single blade can also make the core decompression more precise and thorough. More healthy bone can be retained than the previous expandable reamer. It is known that autologous bone graft has better biomechanical and biological properties than artificial bone graft and has all the requirements for good bone remodeling in terms of osteoconduction, osteoinduction, osteogenesis as well as osteointegration^[25]. Autologous bone is precious and limited for every patient, so we mix allogeneic bone with it to increase the amount of bone graft. The biomechanical properties of allogeneic bone are similar to autologous bone. In China it is more cost effective than artificial bone. In addition, the mixture of autologous bone and allogeneic bone with BMA have better biological activity and are beneficial to the bone growth in the lesion area^[18,21,25,26].

However, this new technique needs to be confirmed in more cases along with more detailed data comparison and further research. In the future, the research will also include age factors, Kerboul angle, and the size and location of lesions on the outcomes.

In conclusion, this new modified technique is simple, safe, and reliable. No serious perioperative complications were observed in our cases. Advantages of the single blade expandable reamer are obvious. The adjuvant substance is inexpensive and easy to obtain. Thus, this technique is an effective joint-preserving surgical treatment for patients with early stage ONFH. Although it's too early to come to a definitive conclusion, in our opinion this technique is easy to master as well as costs less. We present it here in the hope that colleagues in other institutions will try to use it and fully demonstrate its effectiveness.

Table 1 Results of the preoperative and follow-up examinations

ID	Gender	Age	Diagnosis	Stage, ARCO	Date of surgery	Pre-op HHS/VAS	3-mo HHS/VAS	Arthroplasty, 5 yr
653075	M	48	Non-traumatic ONFH (R)	II c	3-12-2013	50/8	83/1	No
653711	M	50	Non-traumatic ONFH (L)	II a	3-13-2013	63/7	93/1	No
665314	M	27	Non-traumatic ONFH (R)	II b	3-24-2013	66/7	97/0	No
947454	M	46	Non-traumatic ONFH (B)	R: II b; L: II b	1-22-2016	R: 71/6; L: 73/5	R: 85/1; L: 86/1	—
1265962	M	49	Non-traumatic ONFH (R)	II b	8-8-2019	68/6	91/1	—
1270768	M	38	Non-traumatic ONFH (R)	II b	8-30-2019	63/7	83/1	—

ARCO: Association Research Circulation Osseous classification system; Pre-op: Preoperative; HHS: Harris hip score; VAS: Pain according to visual analogue scale; M: Male; ONFH: Osteonecrosis of the femoral head; R: Right; L: Left; B: Both.

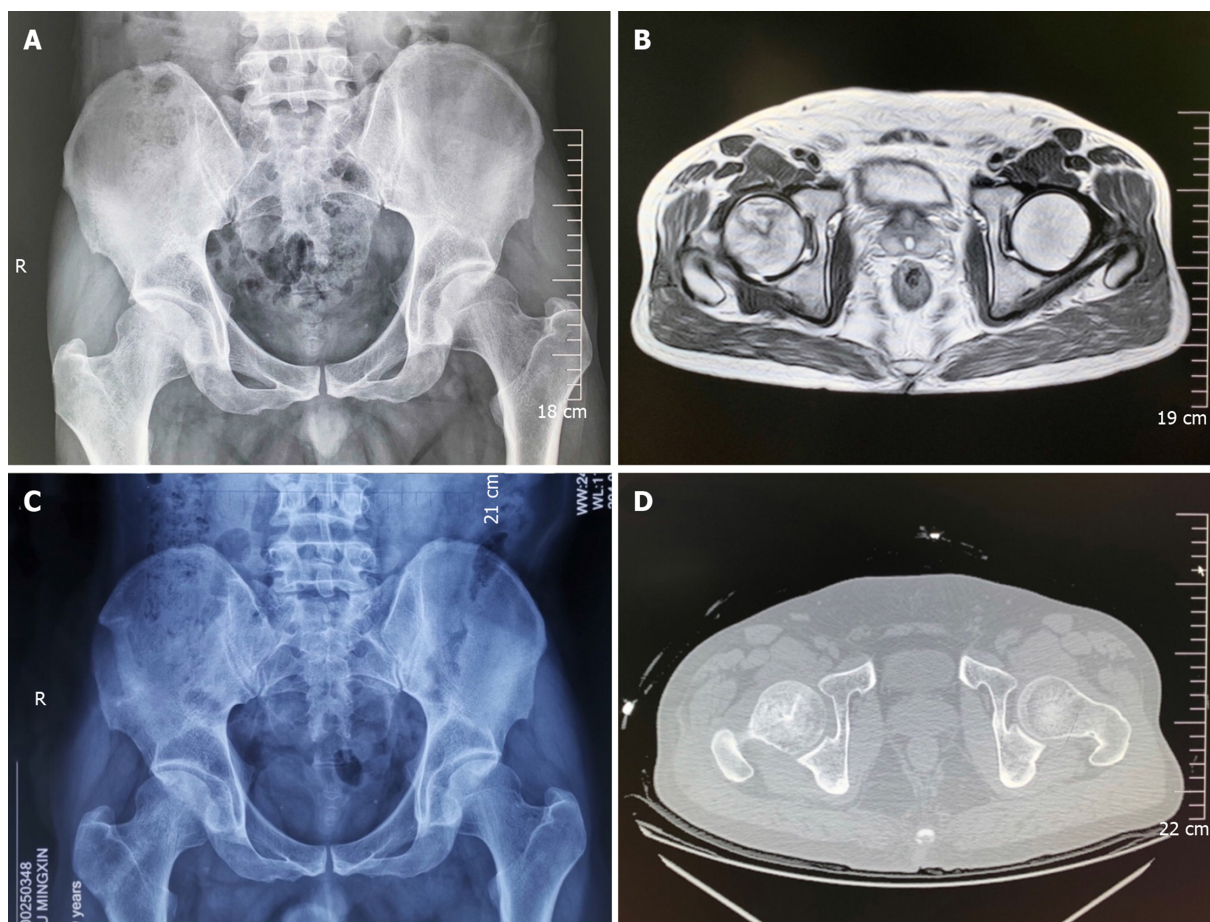


Figure 4 Radiography and computed tomography of the implanted bone. A: Preoperative radiograph; B: Preoperative magnetic resonance imaging; C: Postoperative radiograph; D: Postoperative computed tomography.

ARTICLE HIGHLIGHTS

Research background

Osteonecrosis of the femoral head (ONFH) is a terrible disease that usually affects young and middle-aged patients. The treatment of ONFH has been studied extensively. There are many options available for ONFH, including both nonsurgical treatment and surgical treatment. However, there is little supporting data on nonsurgical treatment when the condition is identified in the early stages. Most of the patients need a total hip arthroplasty after 2 years due to articular collapse. So effective joint-preserving surgical treatments are urgently needed for patients with early stage ONFH when outcomes of treatment are in general better than the advanced stage disease.

Research motivation

We would like to introduce a new technology that is safe, reliable, and effective in order for other doctors to adopt this new method for the joint-preserving treatment of ONFH.

Research objectives

Our study confirmed that percutaneous expanded core decompression and mixed bone graft technique is an effective joint-preserving surgical treatment for patients with early stage ONFH. It is easy to master and costs less than other methods. We want colleagues in other institutions to use it and also demonstrate its effectiveness.

Research methods

From 2013 to 2019, we used percutaneous expanded core decompression and mixed bone graft technique to operate on a group of patients with ONFH. After the operation, the patients were routinely given infection prevention and venous thromboembolism prevention and asked to come to hospital for reexamination regularly while restricting weight-bearing movement for 4 wk. Through the application of a single blade expandable reamer, the core decompression can be precise and thorough. Following the decompression, the mixed bone graft is added. It consists of autologous bone, allogeneic bone, and bone marrow aspirate for a combination of biological activity and structural supporting. An excellent result was obtained by comparing Harris hip score, visual analogue scale, and imaging examination before and after operation.

Research results

All of the patients have achieved satisfactory results in our study from 2013 to 2019. After surgery their Harris hip score and visual analogue scale were improved. Radiography and computed tomography showed that the implanted bone was healed. Clinical symptoms were also significantly relieved. None of the patients needed to accept the total hip arthroplasty in 5 years after surgery. No serious perioperative complications were observed in our cases.

Research conclusions

Percutaneous expanded core decompression and mixed bone graft technique is simple, safe, and reliable. Advantages of the single blade expandable reamer are obvious. The material of adjuvant substance is inexpensive and easy to obtain. Thus, this technique is an effective joint-preserving surgical treatment for patients with early stage ONFH. This new technique is easy to master as well as costs less than other methods. It is worth popularizing and verifying.

Research perspectives

For future research, the effect of age, Kerboul angle, and the size and location of lesions on outcomes should be demonstrated.

REFERENCES

- 1 Mont MA, Cherian JJ, Sierra RJ, Jones LC, Lieberman JR. Nontraumatic Osteonecrosis of the Femoral Head: Where Do We Stand Today? A Ten-Year Update. *J Bone Joint Surg Am* 2015; 97: 1604-1627 [PMID: 26446969 DOI: 10.2106/JBJS.O.00071]
- 2 Choi HR, Steinberg ME, Y Cheng E. Osteonecrosis of the femoral head: diagnosis and classification

- systems. *Curr Rev Musculoskelet Med* 2015; **8**: 210-220 [PMID: [26088795](#) DOI: [10.1007/s12178-015-9278-7](#)]
- 3 **Zalavras CG**, Lieberman JR. Osteonecrosis of the femoral head: evaluation and treatment. *J Am Acad Orthop Surg* 2014; **22**: 455-464 [PMID: [24966252](#) DOI: [10.5435/JAAOS-22-07-455](#)]
 - 4 **Banerjee S**, Issa K, Pivec R, Kapadia BH, Khanuja HS, Mont MA. Osteonecrosis of the hip: treatment options and outcomes. *Orthop Clin North Am* 2013; **44**: 463-476 [PMID: [24095063](#) DOI: [10.1016/j.ocl.2013.07.004](#)]
 - 5 **Mont MA**, Carbone JJ, Fairbank AC. Core decompression versus nonoperative management for osteonecrosis of the hip. *Clin Orthop Relat Res* 1996; **324**: 169-178 [PMID: [8595753](#) DOI: [10.1097/00003086-199603000-00020](#)]
 - 6 **Mont MA**, Zywiell MG, Marker DR, McGrath MS, Delanois RE. The natural history of untreated asymptomatic osteonecrosis of the femoral head: a systematic literature review. *J Bone Joint Surg Am* 2010; **92**: 2165-2170 [PMID: [20844158](#) DOI: [10.2106/JBJS.I.00575](#)]
 - 7 **Pierce TP**, Elmallah RK, Jauregui JJ, Verna DF, Mont MA. Outcomes of total hip arthroplasty in patients with osteonecrosis of the femoral head-a current review. *Curr Rev Musculoskelet Med* 2015; **8**: 246-251 [PMID: [26045086](#) DOI: [10.1007/s12178-015-9283-x](#)]
 - 8 **Kurtz S**, Ong K, Lau E, Mowat F, Halpern M. Projections of primary and revision hip and knee arthroplasty in the United States from 2005 to 2030. *J Bone Joint Surg Am* 2007; **89**: 780-785 [PMID: [17403800](#) DOI: [10.2106/JBJS.F.00222](#)]
 - 9 **Zhao DW**, Hu YC. Chinese experts' consensus on the diagnosis and treatment of osteonecrosis of the femoral head in adults. *Orthop Surg* 2012; **4**: 125-130 [PMID: [22927145](#) DOI: [10.1111/j.1757-7861.2012.00192.x](#)]
 - 10 **Pierce TP**, Jauregui JJ, Elmallah RK, Lavernia CJ, Mont MA, Nace J. A current review of core decompression in the treatment of osteonecrosis of the femoral head. *Curr Rev Musculoskelet Med* 2015; **8**: 228-232 [PMID: [26045085](#) DOI: [10.1007/s12178-015-9280-0](#)]
 - 11 **Musso ES**, Mitchell SN, Schink-Ascani M, Bassett CA. Results of conservative management of osteonecrosis of the femoral head. A retrospective review. *Clin Orthop Relat Res* 1986; 209-215 [PMID: [3720087](#)]
 - 12 **Kamath AF**, McGraw MH, Israelite CL. Surgical management of osteonecrosis of the femoral head in patients with sickle cell disease. *World J Orthop* 2015; **6**: 776-782 [PMID: [26601059](#) DOI: [10.5312/wjo.v6.i10.776](#)]
 - 13 **Millikan PD**, Karas V, Wellman SS. Treatment of osteonecrosis of the femoral head with vascularized bone grafting. *Curr Rev Musculoskelet Med* 2015; **8**: 252-259 [PMID: [26068178](#) DOI: [10.1007/s12178-015-9285-8](#)]
 - 14 **Kong FG**, Han SH, Liu FW, Li YJ. Percutaneous core decompression combined with percutaneous coronary intervention for the treatment of femoral head necrosis in adults. *Zhongguo Yiyao Zhinan* 2014; **35**: 32-34 [DOI: [10.15912/j.cnki.gocm.2014.35.016](#)]
 - 15 **Civinini R**, De Biase P, Carulli C, Matassi F, Nistri L, Capanna R, Innocenti M. The use of an injectable calcium sulphate/calcium phosphate bioceramic in the treatment of osteonecrosis of the femoral head. *Int Orthop* 2012; **36**: 1583-1588 [PMID: [22426934](#) DOI: [10.1007/s00264-012-1525-6](#)]
 - 16 **Classen T**, Warwas S, Jäger M, Landgraeber S. Two-year follow-up after advanced core decompression. *J Tissue Eng Regen Med* 2017; **11**: 1308-1314 [PMID: [26177805](#) DOI: [10.1002/term.2056](#)]
 - 17 **Landgraeber S**, Theysohn JM, Classen T, Jäger M, Warwas S, Hohn HP, Kowalczyk W. Advanced core decompression, a new treatment option of avascular necrosis of the femoral head--a first follow-up. *J Tissue Eng Regen Med* 2013; **7**: 893-900 [PMID: [22489064](#) DOI: [10.1002/term.1481](#)]
 - 18 **Ohzono K**, Saito M, Takaoka K, Ono K, Saito S, Nishina T, Kadowaki T. Natural history of nontraumatic avascular necrosis of the femoral head. *J Bone Joint Surg Br* 1991; **73**: 68-72 [PMID: [1991778](#)]
 - 19 **Cohen-Rosenblum A**, Cui Q. Osteonecrosis of the Femoral Head. *Orthop Clin North Am* 2019; **50**: 139-149 [PMID: [30850073](#) DOI: [10.1016/j.ocl.2018.10.001](#)]
 - 20 **Hernigou P**, Beaujean F. Treatment of osteonecrosis with autologous bone marrow grafting. *Clin Orthop Relat Res* 2002; **405**: 14-23 [PMID: [12461352](#) DOI: [10.1097/00003086-200212000-00003](#)]
 - 21 **Houdek MT**, Wyles CC, Martin JR, Sierra RJ. Stem cell treatment for avascular necrosis of the femoral head: current perspectives. *Stem Cells Cloning* 2014; **7**: 65-70 [PMID: [24744611](#) DOI: [10.2147/SCCAA.S36584](#)]
 - 22 **Larson E**, Jones LC, Goodman SB, Koo KH, Cui Q. Early-stage osteonecrosis of the femoral head: where are we and where are we going in year 2018? *Int Orthop* 2018; **42**: 1723-1728 [PMID: [29619500](#) DOI: [10.1007/s00264-018-3917-8](#)]
 - 23 **Landgraeber S**, Warwas S, Claßen T, Jäger M. Modifications to advanced Core decompression for treatment of Avascular necrosis of the femoral head. *BMC Musculoskelet Disord* 2017; **18**: 479 [PMID: [29162080](#) DOI: [10.1186/s12891-017-1811-y](#)]
 - 24 **Landgraeber S**, Tran TN, Claßen T, Warwas S, Theysohn J, Lazik A, Jäger M, Kowalczyk W. Geometric analysis of an expandable reamer for treatment of avascular necrosis of the femoral head. *Arch Orthop Trauma Surg* 2015; **135**: 1357-1362 [PMID: [26185054](#) DOI: [10.1007/s00402-015-2287-6](#)]
 - 25 **Hernigou P**, Flouzat-Lachaniette CH, Delambre J, Poignard A, Allain J, Chevallier N, Rouard H. Osteonecrosis repair with bone marrow cell therapies: state of the clinical art. *Bone* 2015; **70**: 102-109 [PMID: [25016964](#) DOI: [10.1016/j.bone.2014.04.034](#)]
 - 26 **Papakostidis C**, Tosounidis TH, Jones E, Giannoudis PV. The role of "cell therapy" in osteonecrosis of the femoral head. A systematic review of the literature and meta-analysis of 7 studies. *Acta Orthop* 2016; **87**: 72-78 [PMID: [26220203](#) DOI: [10.3109/17453674.2015.1077418](#)]



Published by **Baishideng Publishing Group Inc**
7041 Koll Center Parkway, Suite 160, Pleasanton, CA 94566, USA

Telephone: +1-925-3991568

E-mail: bpgoffice@wjgnet.com

Help Desk: <https://www.f6publishing.com/helpdesk>

<https://www.wjgnet.com>

