


World Journal of *Radiology*

World J Radiol 2020 July 28; 12(7): 130-141



MINIREVIEWS

- 130 Lung cancer screening, what has changed after the latest evidence?

Trujillo-Reyes JC, Seijo L, Martínez-Tellez E, Couñago F

CASE REPORT

- 137 Convalescent plasma therapy in a pregnant COVID-19 patient with a dramatic clinical and imaging response: A case report

Jafari R, Jonaidi-Jafari N, Dehghanpoor F, Saburi A

ABOUT COVER

Editorial board member of *World Journal of Radiology*, Dr. Gao is a distinguished Professor in Shijiazhuang First Hospital, Hebei Medical University. Currently, he is a special expert hired by the Hebei Provincial Government, a distinguished expert of "100 overseas talents plan" of Hebei Province, and an expert enjoying special allowance of Hebei Provincial Government. His ongoing research interests are mechanisms and endovascular treatment of cerebral aneurysms, intracranial atherosclerotic diseases, aortic aneurysms, cerebrovascular diseases, arterial stenosis, computational fluid dynamics of vascular diseases, neurointerventional radiology, animal experiments for vascular diseases, and animal models of all sorts of diseases. Dr. Gao has published over 120 SCI papers and serves as an expert reviewer for over 120 English journals including over 60 journals indexed by Web of Science.

AIMS AND SCOPE

The primary aim of *World Journal of Radiology* (*WJR*, *World J Radiol*) is to provide scholars and readers from various fields of radiology with a platform to publish high-quality basic and clinical research articles and communicate their research findings online.

WJR mainly publishes articles reporting research results and findings obtained in the field of radiology and covering a wide range of topics including state of the art information on cardiopulmonary imaging, gastrointestinal imaging, genitourinary imaging, musculoskeletal imaging, neuroradiology/head and neck imaging, nuclear medicine and molecular imaging, pediatric imaging, vascular and interventional radiology, and women's imaging.

INDEXING/ABSTRACTING

The *WJR* is now abstracted and indexed in Emerging Sources Citation Index (Web of Science), PubMed, PubMed Central, China National Knowledge Infrastructure (CNKI), China Science and Technology Journal Database (CSTJ), and Superstar Journals Database.

RESPONSIBLE EDITORS FOR THIS ISSUE

Electronic Editor: Ji-Hong Liu, Production Department Director: Yun-Xiaojuan Wu, Editorial Office Director: Jia-Ping Yan.

NAME OF JOURNAL

World Journal of Radiology

ISSN

ISSN 1949-8470 (online)

LAUNCH DATE

January 31, 2009

FREQUENCY

Monthly

EDITORS-IN-CHIEF

Venkatesh Mani

EDITORIAL BOARD MEMBERS

<https://www.wjgnet.com/1949-8470/editorialboard.htm>

PUBLICATION DATE

July 28, 2020

COPYRIGHT

© 2020 Baishideng Publishing Group Inc

INSTRUCTIONS TO AUTHORS

<https://www.wjgnet.com/bpg/gerinfo/204>

GUIDELINES FOR ETHICS DOCUMENTS

<https://www.wjgnet.com/bpg/GerInfo/287>

GUIDELINES FOR NON-NATIVE SPEAKERS OF ENGLISH

<https://www.wjgnet.com/bpg/gerinfo/240>

PUBLICATION ETHICS

<https://www.wjgnet.com/bpg/GerInfo/288>

PUBLICATION MISCONDUCT

<https://www.wjgnet.com/bpg/gerinfo/208>

ARTICLE PROCESSING CHARGE

<https://www.wjgnet.com/bpg/gerinfo/242>

STEPS FOR SUBMITTING MANUSCRIPTS

<https://www.wjgnet.com/bpg/GerInfo/239>

ONLINE SUBMISSION

<https://www.f6publishing.com>

Convalescent plasma therapy in a pregnant COVID-19 patient with a dramatic clinical and imaging response: A case report

Ramezan Jafari, Nematollah Jonaidi-Jafari, Fatemeh Dehghanpoor, Amin Saburi

ORCID number: Ramezan Jafari 0000-0003-1099-4259; Nematollah Jonaidi-Jafari 0000-0002-6006-7771; Fatemeh Dehghanpoor 0000-0003-1450-8748; Amin Saburi 0000-0001-7743-8244.

Author contributions: Jafari R took part in the data acquisition, supervision of the study, and writing, review and editing of the manuscript; Jonaidi-Jafari N was involved in project administration, and writing of the original draft; Dehghanpoor F was involved in data acquisition, and writing of the primary draft; Saburi A took part in data acquisition, supervision of the study, and writing, review and editing of the manuscript.

Informed consent statement: Informed consent from the patient in this case report was obtained.

Conflict-of-interest statement: The authors declare that they have no conflict of interest.

CARE Checklist (2016) statement: The authors have read the CARE Checklist (2016), and the manuscript was prepared and revised according to the CARE Checklist (2016).

Open-Access: This article is an open-access article that was selected by an in-house editor and fully peer-reviewed by external

Ramezan Jafari, Radiology Department, Faculty of Medicine and Chemical Injuries Research Center, Baqiyatallah University of Medical Sciences, Tehran 18151777, Iran

Nematollah Jonaidi-Jafari, Health Research Center and Faculty of Medicine, Baqiyatallah University of Medical Sciences, Tehran 18151777, Iran

Fatemeh Dehghanpoor, Radiology Department, Faculty of Medicine, Baqiyatallah University of Medical Sciences, Tehran 18151777, Iran

Amin Saburi, Chemical Injuries Research Center and Faculty of Medicine, Baqiyatallah University of Medical Sciences, Tehran 18151777, Iran

Corresponding author: Amin Saburi, MD, Academic Research, Doctor, Postdoc, Senior Researcher, Chemical Injuries Research Center and Faculty of Medicine, Baqiyatallah University of Medical Sciences, Mollasadra St, Vanak Sq, Tehran 18151777, Iran. aminsaburi@yahoo.com

Abstract

BACKGROUND

Coronavirus disease 2019 (COVID-19) is a novel very contagious infection which was designated a pandemic in all countries of the world in April 2020. Its presentation varies from mild to severe infection, but the majority of infected patients have mild manifestations. Many therapeutic choices have been suggested to treat the infection, but none are fully effective.

CASE SUMMARY

Herein we present a 26-year-old woman with a twin pregnancy at 36 wk and one day gestation with confirmed COVID-19 who responded dramatically to convalescent plasma therapy (CPT) and Favipiravir.

CONCLUSION

Although this case report shows the efficacy of CPT in addition to usual medications used for COVID-19, there are many questions that need to be answered regarding dosage, para-clinical efficacy, side effects and combination therapy.

Key words: Case report; Convalescent plasma therapy; Pregnancy; COVID-19; Favipiravir; Radiologic findings

reviewers. It is distributed in accordance with the Creative Commons Attribution NonCommercial (CC BY-NC 4.0) license, which permits others to distribute, remix, adapt, build upon this work non-commercially, and license their derivative works on different terms, provided the original work is properly cited and the use is non-commercial. See: <http://creativecommons.org/licenses/by-nc/4.0/>

Manuscript source: Invited manuscript

Received: April 27, 2020

Peer-review started: April 27, 2020

First decision: May 15, 2020

Revised: June 14, 2020

Accepted: June 17, 2020

Article in press: June 17, 2020

Published online: July 28, 2020

P-Reviewer: Liu YC, Rismanbaf A

S-Editor: Dou Y

L-Editor: Webster JR

E-Editor: Liu JH



©The Author(s) 2020. Published by Baishideng Publishing Group Inc. All rights reserved.

Core tip: This is one of the first reports on the efficacy of convalescent plasma therapy (CPT) in a pregnant patient with coronavirus disease 2019 (COVID-19) pneumonia. Chest computed tomography scan findings and clinical parameters showed a dramatic response to the combination of Favipiravir and CPT, which may be an important choice for pregnant patients with COVID-19 pneumonia.

Citation: Jafari R, Jonaidi-Jafari N, Dehghanpoor F, Saburi A. Convalescent plasma therapy in a pregnant COVID-19 patient with a dramatic clinical and imaging response: A case report.

World J Radiol 2020; 12(7): 137-141

URL: <https://www.wjgnet.com/1949-8470/full/v12/i7/137.htm>

DOI: <https://dx.doi.org/10.4329/wjr.v12.i7.137>

INTRODUCTION

Coronavirus disease 2019 (COVID-19) caused by a novel Coronavirus was first identified in Wuhan (China) in December 2019. The spread of COVID-19 was so rapid that within a few months it became a pandemic^[1,2]. The most common presentations of COVID-19 are cough, fever, dyspnea, and malaise, but some patients present severe manifestations such as respiratory failure, acute respiratory distress syndrome, septic shock, multi-organ failure, and disseminated intravascular coagulation (DIC)^[3]. Comorbidities such as diabetes, hypertension, chronic cardiovascular diseases, pulmonary disease, and malignancies exacerbate the disease, particularly in older patients and pregnant women, especially in the third trimester^[2,3]. Pregnant women are a sensitive group, therefore are susceptible to severe manifestations and complications of COVID-19. Thus, to avoid probable complications these patients should be treated appropriately and immediately.

CASE PRESENTATION

Chief complaints

A 26-year-old woman with a twin pregnancy at 36 wk and one day gestation (gravida 1, 0 abortions) was referred to our emergency unit.

History of present illness

The patient presented with malaise, fever, and a non-productive cough for 6 d prior to admission.

History of past illness

No remarkable past medical history.

Personal and family history

No remarkable personal and family medical history.

Physical examination

On physical examination, she was febrile, tachycardic, hypoxic with O₂ saturation of 92%, and diffuse rhonchi on auscultation.

Laboratory examinations

The most significant laboratory finding was an increased erythrocyte sedimentation rate. A non-stress-test was reactive for both fetuses and both biophysical profiles were 6/8 due to decreased fetal movement.

Imaging examinations

Chest computed tomography (CT) scan was performed for further evaluation and revealed multifocal sub-pleural patchy consolidative opacities on both lung fields highly suggestive of COVID-19 pneumonia (Figure 1A-C).

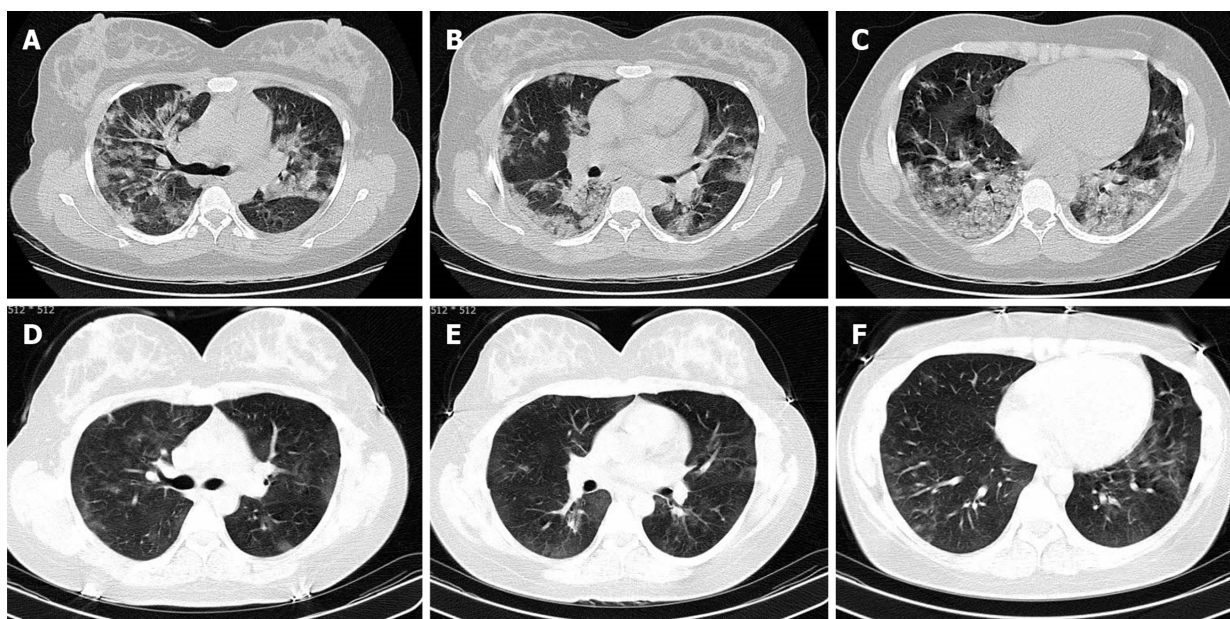


Figure 1 Chest computed tomography scan. A-C: Axial chest computed tomography scan without contrast shows multifocal sub-pleural patchy consolidative opacities in both lung fields compatible with coronavirus disease 2019 pneumonia; D-F: Twelve days later only very faint residual ground glass opacities were seen and the patient's dramatic response to treatment is notable.

After initial preparation and oxygen therapy, the patient was immediately transferred to the operating room for a cesarean section. Both infants were in a good condition with a first minute APGAR score of 9/10. They were isolated from their mother and transferred to the Neonatal Intensive Care Unit for close observation. COVID-19 infection was confirmed in the mother using the reverse transcription-polymerase chain reaction (RT-PCR), while nasopharynx specimens were negative in both infants and they were completely asymptomatic at the two-week follow-up. Meropenem, azithromycin, and hydroxychloroquine as well as supplemental oxygen were started after delivery. Due to the lack of a favorable response to treatment, on the sixth day after the admission, the patient received one plasma transfusion obtained from cured COVID-19 patients. Favipiravir was added to her medications. Her clinical course during hospitalization improved, particularly during the second week.

After twelve days, another CT scan was performed, and the results showed only very faint residual ground-glass opacities. Therefore, the dramatic response to this therapeutic regimen was notable (Figure 1E-G).

FINAL DIAGNOSIS

COVID-19 with pulmonary involvement.

TREATMENT

The patient was effectively treated with Favipiravir and convalescent plasma therapy (CPT).

OUTCOME AND FOLLOW-UP

The patient was discharged after 2 weeks with a dramatic response to therapy. Both newborns had no COVID-19 symptoms and negative PCR results.

DISCUSSION

Pregnant women, especially at the end of pregnancy, are more susceptible to severe manifestations of infections, including COVID-19, probably due to changes in the immune system and physical stature^[4]. However, few studies have investigated the influence of COVID-19 on pregnancy and its possible complications. However, evidence from similar viral infections from the Coronaviridae family such as Severe Acute Respiratory Syndrome and Middle East Respiratory Syndrome has indicated more maternal and fetal complications, such as spontaneous miscarriage, intrauterine growth retardation, preterm parturition, maternal renal failure, sepsis, DIC, and even death^[1-3,5]. Therefore, to reduce probable complications, pregnant women should be monitored for early diagnosis and given appropriate and immediate treatment^[6].

The course of COVID-19 in pregnant women is unpredictable. Chen *et al*^[7] reported nine pregnant women in the third trimester with an improved clinical course during hospitalization without complications. On the other hand, Liu *et al*^[8] investigated thirteen pregnant women with COVID-19, and reported that during the study period six of these patients were transferred to the intensive care unit. Karami *et al*^[3] reported a 27-year-old pregnant woman at 30 wk and 3 d gestation with COVID-19 and a deteriorating clinical course who subsequently died due to multi-organ failure. Fortunately, clinical and imaging findings in our patient indicated improved health status during hospitalization and she responded to treatment, especially during the second week and as mentioned, only very faint residual ground-glass opacities were visible in the second chest CT scan, in comparison with multifocal sub-pleural patchy consolidative opacities in her first chest CT.

Based on available published data, vertical transmission during pregnancy does not occur or occurs rarely^[9]. The presented cases by Chen *et al*^[7] and Liu *et al*^[8] confirmed this hypothesis; however, Yu *et al*^[10] reported one RT-PCR positive test for COVID-19 in seven neonates who were born by cesarean section, while all maternal tests were positive for COVID-19.

Many therapeutic opinions such as Chloroquine, Kaletra, Remdesivir, Azithromycin, Tocilizumab, and Favipiravir have been suggested for such cases, with no clear evidence of their effectiveness and their efficacy was confirmed by a few reports^[11-13]. Recently, the effectiveness of CPT for severe COVID-19 patients was confirmed and Iran (Islamic Rep. of) is a pioneer country in using this therapeutic strategy^[14]. Passive immunization using plasma obtained from recovered patients is the basis of this treatment, and the FDA has also approved this strategy, particularly for critically ill cases of COVID-19^[15]. Duan *et al*^[14] investigated the administration of a single dose of convalescent plasma in 10 adults with severe COVID-19. They reported a positive clinical outcome after 3 d and radiological outcome after 7 d. Huo *et al*^[16] reported that CPT can save as many as 6451 lives (ranging from 3074 to 26500 depending on the containment effectiveness) in the early period of the infection. However, as recently reported, "it seems that the convalescent plasma treatment discontinues the COVID-19 shedding, and cannot reduce mortality in critically end-stage COVID-19 patients"^[17]. Although this is not good news for critical cases, it helps early stage-cases to avoid intensive care units and slow progression of the disease^[18].

There is a query in the present case, and it is the simultaneous prescription of Favipiravir and CPT. This may confuse the efficacy of each medication, while the efficacy of Favipiravir has been previously confirmed^[19]. A randomized clinical trial is recommended to include three groups of patients, one group treated with Favipiravir and CPT, and the other two groups treated with Favipiravir and CPT alone.

Furthermore, in our case this novel therapy diminished the clinical and radiologic features of COVID-19. The effects of Oxytocine should also be considered, as it was previously stated that "oxytocin decreases the neuroendocrine and cytokine activation and might be a candidate for the therapy of inflammatory diseases and conditions associated with high cytokine and vascular endothelial growth factor levels"^[20].

CONCLUSION

Our knowledge on this novel coronavirus infection in pregnancy and its probable complications is insufficient, and more accurate investigations, particularly regarding biologic treatments, are necessary.

ACKNOWLEDGEMENTS

We would like to thank Professor Mostafa Ghanei for valuable comments.

REFERENCES

- 1 **Chen Y**, Peng H, Wang L, Zhao Y, Zeng L, Gao H, Liu Y. Infants Born to Mothers With a New Coronavirus (COVID-19). *Front Pediatr* 2020; **8**: 104 [PMID: 32266184 DOI: 10.3389/fped.2020.00104]
- 2 **Asadi L**, Tabatabaei RS, Nejad HS, Mohammadi M. New Corona Virus (COVID-19) Management in Pregnancy and Childbirth. *Arch Clin Infect Dis* 2020; In press: e102938 [DOI: 10.5812/archcid.102938]
- 3 **Karami P**, Naghavi M, Feyzi A, Aghamohammadi M, Novin MS, Mobaeni A, Qorbanisani M, Karami A, Norooznezhad AH. WITHDRAWN: Mortality of a pregnant patient diagnosed with COVID-19: A case report with clinical, radiological, and histopathological findings. *Travel Med Infect Dis* 2020; 101665 [PMID: 32283217 DOI: 10.1016/j.tmaid.2020.101665]
- 4 **Luo Y**, Yin K. Management of pregnant women infected with COVID-19. *Lancet Infect Dis* 2020; **20**: 513-514 [PMID: 32220285 DOI: 10.1016/S1473-3099(20)30191-2]
- 5 **Rasmussen SA**, Smulian JC, Lednický JA, Wen TS, Jamieson DJ. Coronavirus Disease 2019 (COVID-19) and pregnancy: what obstetricians need to know. *Am J Obstet Gynecol* 2020; **222**: 415-426 [PMID: 32105680 DOI: 10.1016/j.ajog.2020.02.017]
- 6 **Khan MA**, Khan A, Mustagir G, Rana J, Haque R, Rahman M. COVID-19 infection during pregnancy: A systematic review to summarize possible symptoms, treatments, and pregnancy outcomes. medRxiv preprint 2020 [DOI: 10.1101/2020.03.31.20049304]
- 7 **Chen H**, Guo J, Wang C, Luo F, Yu X, Zhang W, Li J, Zhao D, Xu D, Gong Q, Liao J, Yang H, Hou W, Zhang Y. Clinical characteristics and intrauterine vertical transmission potential of COVID-19 infection in nine pregnant women: a retrospective review of medical records. *Lancet* 2020; **395**: 809-815 [PMID: 32151335 DOI: 10.1016/S0140-6736(20)30360-3]
- 8 **Liu Y**, Chen H, Tang K, Guo Y. Clinical manifestations and outcome of SARS-CoV-2 infection during pregnancy. *J Infect* 2020 [PMID: 32145216 DOI: 10.1016/j.jinf.2020.02.028]
- 9 **Mimouni F**, Lakshminrusimha S, Pearlman SA, Raju T, Gallagher PG, Mendlovic J. Perinatal aspects on the covid-19 pandemic: a practical resource for perinatal-neonatal specialists. *J Perinatol* 2020; **40**: 820-826 [PMID: 32277162 DOI: 10.1038/s41372-020-0665-6]
- 10 **Yu N**, Li W, Kang Q, Xiong Z, Wang S, Lin X, Liu Y, Xiao J, Liu H, Deng D, Chen S, Zeng W, Feng L, Wu J. Clinical features and obstetric and neonatal outcomes of pregnant patients with COVID-19 in Wuhan, China: a retrospective, single-centre, descriptive study. *Lancet Infect Dis* 2020; **20**: 559-564 [PMID: 32220284 DOI: 10.1016/S1473-3099(20)30176-6]
- 11 **Chen L**, Xiong J, Bao L, Shi Y. Convalescent plasma as a potential therapy for COVID-19. *Lancet Infect Dis* 2020; **20**: 398-400 [PMID: 32113510 DOI: 10.1016/S1473-3099(20)30141-9]
- 12 **Mehta N**, Mazer-Amirshahi M, Alkindi N, Pourmand A. Pharmacotherapy in COVID-19; A narrative review for emergency providers. *Am J Emerg Med* 2020 [PMID: 32336586 DOI: 10.1016/j.ajem.2020.04.035]
- 13 **Al-Tawfiq JA**, Al-Homoud AH, Memish ZA. Remdesivir as a possible therapeutic option for the COVID-19. *Travel Med Infect Dis* 2020; **34**: 101615 [PMID: 32145386 DOI: 10.1016/j.tmaid.2020.101615]
- 14 **Duan K**, Liu B, Li C, Zhang H, Yu T, Qu J, Zhou M, Chen L, Meng S, Hu Y, Peng C, Yuan M, Huang J, Wang Z, Yu J, Gao X, Wang D, Yu X, Li L, Zhang J, Wu X, Li B, Xu Y, Chen W, Peng Y, Hu Y, Lin L, Liu X, Huang S, Zhou Z, Zhang L, Wang Y, Zhang Z, Deng K, Xia Z, Gong Q, Zhang W, Zheng X, Liu Y, Yang H, Zhou D, Yu D, Hou J, Shi Z, Chen S, Chen Z, Zhang X, Yang X. Effectiveness of convalescent plasma therapy in severe COVID-19 patients. *Proc Natl Acad Sci USA* 2020; **117**: 9490-9496 [PMID: 32253318 DOI: 10.1073/pnas.2004168117]
- 15 **Tanne JH**. Covid-19: FDA approves use of convalescent plasma to treat critically ill patients. *BMJ* 2020; **368**: m1256 [PMID: 32217555 DOI: 10.1136/bmj.m1256]
- 16 **Huo X**, Sun X, Bragazzi N, Wu J. Effectiveness and Feasibility of Convalescent Blood Transfusion to Reduce COVID-19 Fatality Ratio. *SSRN Electronic Journal* 2020 [DOI: 10.2139/ssrn.3573611]
- 17 **Zeng QL**, Yu ZJ, Gou JJ, Li GM, Ma SH, Zhang GF, Xu JH, Lin WB, Cui GL, Zhang MM, Li C, Wang ZS, Zhang ZH, Liu ZS. Effect of Convalescent Plasma Therapy on Viral Shedding and Survival in COVID-19 Patients. *J Infect Dis* 2020 [PMID: 32348485 DOI: 10.1093/infdis/jiaa228]
- 18 **Rubin R**. Testing an Old Therapy Against a New Disease: Convalescent Plasma for COVID-19. *JAMA* 2020 [PMID: 32352484 DOI: 10.1001/jama.2020.7456]
- 19 **Cai Q**, Yang M, Liu D, Chen J, Shu D, Xia J, Liao X, Gu Y, Cai Q, Yang Y, Shen C, Li X, Peng L, Huang D, Zhang J, Zhang S, Wang F, Liu J, Chen L, Chen S, Wang Z, Zhang Z, Cao R, Zhong W, Liu Y, Liu L. Experimental Treatment with Favipiravir for COVID-19: An Open-Label Control Study. *Engineering (Beijing)* 2020 [PMID: 32346491 DOI: 10.1016/j.eng.2020.03.007]
- 20 **Clodi M**, Vila G, Geyeregger R, Riedl M, Stulnig TM, Struck J, Luger TA, Luger A. Oxytocin alleviates the neuroendocrine and cytokine response to bacterial endotoxin in healthy men. *Am J Physiol Endocrinol Metab* 2008; **295**: E686-E691 [PMID: 18593851 DOI: 10.1152/ajpendo.90263.2008]



Published by **Baishideng Publishing Group Inc**
7041 Koll Center Parkway, Suite 160, Pleasanton, CA 94566, USA

Telephone: +1-925-3991568

E-mail: bpgoffice@wjgnet.com

Help Desk: <https://www.f6publishing.com/helpdesk>

<https://www.wjgnet.com>

