

World Journal of *Orthopedics*

World J Orthop 2020 August 18; 11(8): 345-363



REVIEW

- 345 Lumbar and cervical viscoelastic disc replacement: Concepts and current experience
Lazennec JY

CASE REPORT

- 357 Osteochondroma formation after avulsion fracture of anterior inferior iliac spine: A case report
Cho HG, Kwon HY, Lee YC, Lee YC, Kweon SH

ABOUT COVER

Editorial board member of *World Journal of Orthopedics*, Dr. Vahedi is an Assistant Professor of Neurosurgery at Tehran Medical Sciences Branch of Islamic Azad University of Medical Sciences (IAUMS), Tehran, Iran. Having received his MD degree from Mashad Medical University in 2001, Dr. Vahedi undertook his neurosurgery residency training at Tabriz University of Medical Sciences, attaining third rank in the Iranian National Board of Neurosurgery in 2010. His ongoing research interests are tumors of the spine and spinal cord, lumbopelvic fusions and sagittal balance of the spine, resulting in publication of over 40 peer-reviewed articles. He is the Deputy Editor-in-Chief of the *Iranian Journal of Neurosurgery* and a member of the editorial boards and a reviewer of several international journals. Currently, he serves as Chief of the Spine Division of Neurosurgery Department at Bou-Ali and Farhikhtegan teaching hospitals. (L-Editor: Filipodia)

AIMS AND SCOPE

The primary aim of *World Journal of Orthopedics* (*WJO*, *World J Orthop*) is to provide scholars and readers from various fields of orthopedics with a platform to publish high-quality basic and clinical research articles and communicate their research findings online.

WJO mainly publishes articles reporting research results and findings obtained in the field of orthopedics and covering a wide range of topics including arthroscopy, bone trauma, bone tumors, hand and foot surgery, joint surgery, orthopedic trauma, osteoarthritis, osteoporosis, pediatric orthopedics, spinal diseases, spine surgery, and sports medicine.

INDEXING/ABSTRACTING

The *WJO* is now abstracted and indexed in PubMed, PubMed Central, Emerging Sources Citation Index (Web of Science), Scopus, China National Knowledge Infrastructure (CNKI), China Science and Technology Journal Database (CSTJ), and Superstar Journals Database.

RESPONSIBLE EDITORS FOR THIS ISSUE

Production Editor: Yan-Xia Xing; Production Department Director: Xiang Li; Editorial Office Director: Jia-Ping Yan.

NAME OF JOURNAL

World Journal of Orthopedics

ISSN

ISSN 2218-5836 (online)

LAUNCH DATE

November 18, 2010

FREQUENCY

Monthly

EDITORS-IN-CHIEF

Massimiliano Leigheb

EDITORIAL BOARD MEMBERS

<http://www.wjgnet.com/2218-5836/editorialboard.htm>

PUBLICATION DATE

August 18, 2020

COPYRIGHT

© 2020 Baishideng Publishing Group Inc

INSTRUCTIONS TO AUTHORS

<https://www.wjgnet.com/bpg/gerinfo/204>

GUIDELINES FOR ETHICS DOCUMENTS

<https://www.wjgnet.com/bpg/GerInfo/287>

GUIDELINES FOR NON-NATIVE SPEAKERS OF ENGLISH

<https://www.wjgnet.com/bpg/gerinfo/240>

PUBLICATION ETHICS

<https://www.wjgnet.com/bpg/GerInfo/288>

PUBLICATION MISCONDUCT

<https://www.wjgnet.com/bpg/gerinfo/208>

ARTICLE PROCESSING CHARGE

<https://www.wjgnet.com/bpg/gerinfo/242>

STEPS FOR SUBMITTING MANUSCRIPTS

<https://www.wjgnet.com/bpg/GerInfo/239>

ONLINE SUBMISSION

<https://www.f6publishing.com>



Osteochondroma formation after avulsion fracture of anterior inferior iliac spine: A case report

Hyung Gyu Cho, Hoi Young Kwon, Yeong Chang Lee, Yong Chan Lee, Suc Hyun Kweon

ORCID number: Hyung Gyu Cho 0000-0003-0677-6734; Hoi Young Kwon 0000-0002-1097-658X; Yeong Chang Lee 0000-0002-7981-4300; Yong Chan Lee 0000-0001-9899-8718; Suc Hyun Kweon 0000-0003-1939-2676.

Author contributions: Cho HG designed the study and made the manuscript draft; Kwon HY reviewed the literature and contributed to manuscript drafting; Lee YC contributed to reviewing the images and literature; Lee YC contributed to critical role in revising the manuscript for revision; Kweon SH was the main surgeon of the patient and reviewed and revised the whole manuscript with final approval.

Informed consent statement: Informed written consent was obtained from the patient for publication of this report and any accompanying images.

Conflict-of-interest statement: The authors declare that they have no conflict of interest.

CARE Checklist (2016) statement: The authors have read the CARE Checklist (2016), and the manuscript was prepared and revised according to the CARE Checklist (2016).

Open-Access: This article is an

Hyung Gyu Cho, Hoi Young Kwon, Yeong Chang Lee, Yong Chan Lee, Suc Hyun Kweon, Department of Orthopaedic Surgery, Wonkwang University School of Medicine Hospital, Iksan 54538, South Korea

Corresponding author: Suc Hyun Kweon, MD, PhD, Full Professor, Department of Orthopaedic Surgery, Wonkwang University School of Medicine Hospital, No. 895 Mu-wang Road, Iksan 54538, South Korea. osksh@wku.ac.kr

Abstract

BACKGROUND

Hip avulsion fractures occur mostly during adolescence when actions such as kicking or running cause forceful contraction of attached muscle. Osteochondroma is benign tumor that mostly occurs at the metaphysis of a long bone, being usually asymptomatic.

CASE SUMMARY

A 15-year-old patient experienced feeling and sound of a break while kicking a ball in soccer game three years prior to his visit to our hospital. A simple X-ray revealed an avulsion fracture of the apophysis of the anterior inferior iliac spine (AIIS). Later in the follow-up X-ray, a palpable mass was found and demonstrated by magnetic resonance imaging to be a pedunculated osteochondroma in the superolateral aspect of the AIIS. For surgical treatment, we performed osteotomy for surgical excision and excisional biopsy. A mass with smooth surface and an unclear superolateral AIIS border was found intraoperatively. Pathologic exam showed definite diagnosis of osteochondroma. Postoperatively, discomfort during hip flexion was improved, and the hip joint range of motion during walking was recovered at the last follow-up, which was three weeks after the surgery.

CONCLUSION

This is a rare case to demonstrate relevant previous trauma history prior to the formation of osteochondroma.

Key words: Apophysis; Anterior inferior iliac spine; Avulsion fracture; Posttraumatic osteochondroma; Apophysis avulsion fracture; Apophysis osteochondroma; Case report

©The Author(s) 2020. Published by Baishideng Publishing Group Inc. All rights reserved.

open-access article that was selected by an in-house editor and fully peer-reviewed by external reviewers. It is distributed in accordance with the Creative Commons Attribution NonCommercial (CC BY-NC 4.0) license, which permits others to distribute, remix, adapt, build upon this work non-commercially, and license their derivative works on different terms, provided the original work is properly cited and the use is non-commercial. See: <http://creativecommons.org/licenses/by-nc/4.0/>

Manuscript source: Unsolicited manuscript

Received: April 30, 2020

Peer-review started: April 30, 2020

First decision: July 4, 2020

Revised: July 16, 2020

Accepted: August 1, 2020

Article in press: August 1, 2020

Published online: August 18, 2020

P-Reviewer: Rodriguez-Merchan EC, Yukata K

S-Editor: Zhang L

L-Editor: A

P-Editor: Xing YX



Core tip: The patient of this report showed change in the X-rays suggesting bone remodeling due to callus formation of anterior inferior iliac spine apophysis and osteochondroma being caused by anterior inferior iliac spine avulsion fracture. The patient complained of pain, and underwent osteotomy. This case can show the correlation between previous trauma and osteochondroma formation.

Citation: Cho HG, Kwon HY, Lee YC, Lee YC, Kweon SH. Osteochondroma formation after avulsion fracture of anterior inferior iliac spine: A case report. *World J Orthop* 2020; 11(8): 357-363

URL: <https://www.wjgnet.com/2218-5836/full/v11/i8/357.htm>

DOI: <https://dx.doi.org/10.5312/wjo.v11.i8.357>

INTRODUCTION

In adolescence, apophysis avulsion fractures mostly occur in the pelvis and proximal femur. The apophysis, a bony structure to which ligaments or tendons attach, has ossification center related to growth plate and its avulsion fractures are uncommon but can be induced by abrupt muscular contractions^[1]. Osteochondroma is benign tumor that mostly occurs at the metaphysis of a long bone, being usually asymptomatic. However, occasionally, it is symptomatic due to complications according to size and location. The precise mechanism is unknown, except for some cases reported of osteochondroma after trauma. We hereby report a case of osteochondroma found after inferior iliac spine (AIIS) apophysis avulsion fracture in a 15-year-old male with a literature review.

CASE PRESENTATION

Chief complaints

A 15-year-old male visited our hospital in August 2019, and a 3 cm × 3 cm mass-like lesion at right AIIS was identified. The area was tender, without limitation in the joint range of motion.

History of present illness

He experienced feeling and sound of a break while kicking a soccer ball in February 2016. He visited a local hospital because the active hip flexion became difficult. A simple X-ray revealed an AIIS apophysis avulsion fracture (Figure 1). He underwent conservative treatment in the hospital and physical therapy for six months. The follow-up X-ray after three months demonstrated callus formation of AIIS apophysis (Figure 2). Later, he felt a blocking sensation in the right hip joint while walking, and a palpable mass was found anterior to the joint.

History of past illness

The patient had no significant previous medical history.

Personal and family history

The patient himself and no others in the family suffered from this symptom before.

Physical examination

Tenderness and swelling were evident along the right hip joint. He showed limping gait and reported extensive pain from the right hip joint to thigh. He felt discomfort with full hip flexion in supine position (Figure 3).

Laboratory examinations

Laboratory tests showed no significant result.

Imaging examinations

Magnetic resonance imaging (MRI) of the superolateral portion of AIIS revealed an ossifying erosive mass with unclear border with the ilium. Lower signal was noted on

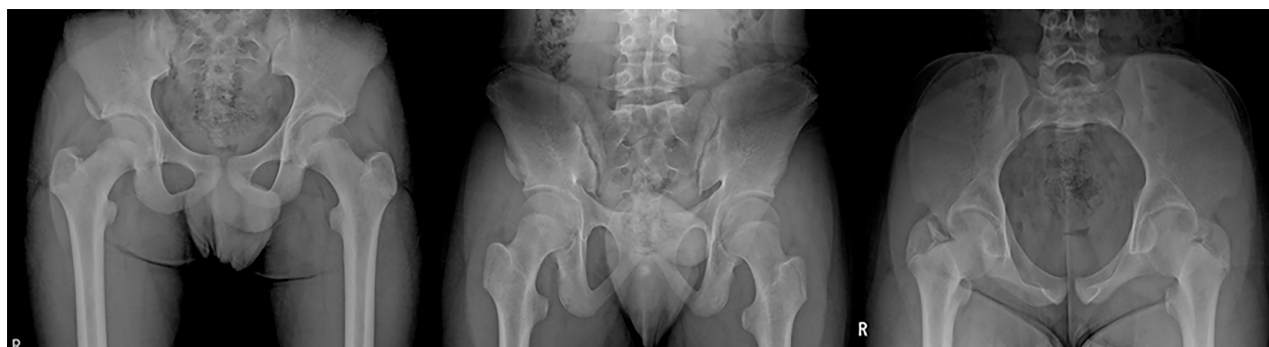

Figure 1 X-ray taken after the initial trauma showing a right avulsion fracture of the apophysis of the anterior inferior iliac spine.

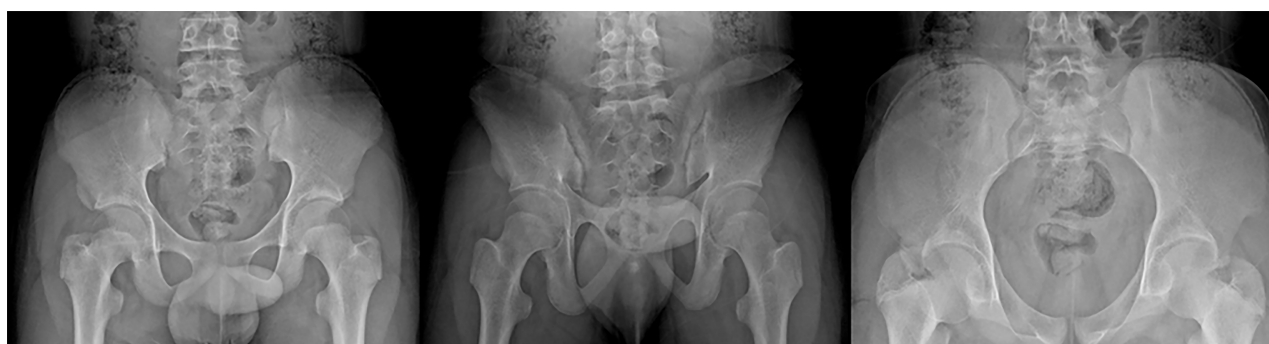

Figure 2 X-ray taken 3 mo after initial trauma showing callus formation in the anterior inferior iliac spine.

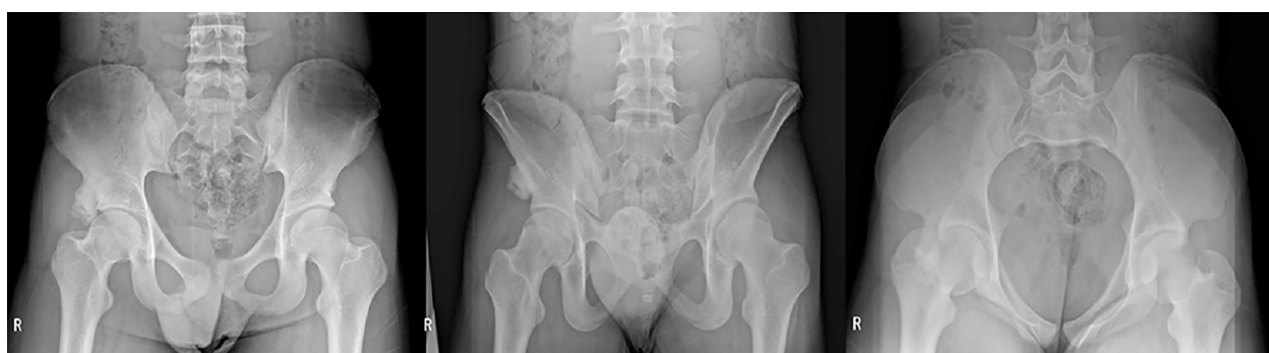

Figure 3 X-ray showing a round pedunculated bony protrusion on the superolateral aspect of the right anterior inferior iliac spine.

T1 stress view compared to the adjacent bone versus higher signal around the periphery of the mass on T2 stress view and gadolinium contrast-enhanced T1 view. Due to continuity between the superolateral portion of AIIS and cortical and medullary bone of the mass, which was surrounded by cartilaginous cap, we suspected it to be a pedunculated osteochondroma (Figure 4).

FINAL DIAGNOSIS

The surgical biopsy sample underwent hematoxylin and eosin staining to check malignancy, and revealed three layers consisting of a perichondrium cartilage cap and bone tissue; giving the patient definite diagnosis of osteochondroma (Figure 5).

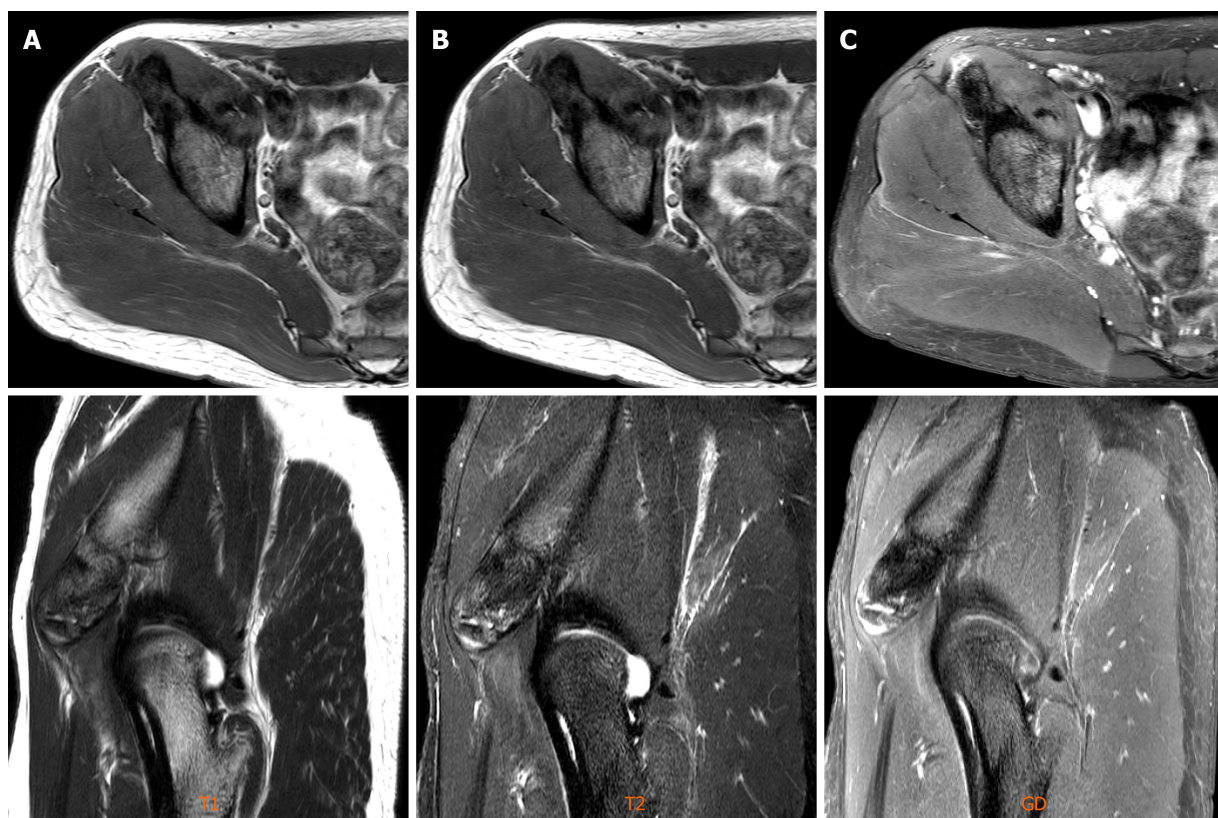


Figure 4 Imaging examinations. A: T1-weighted magnetic resonance images showed low signal intensity in the mass; B and C: T2 mDIXON water magnetic resonance images, gadolinium-enhanced T1 mDIXON water images showing high signal intensity around the mass.

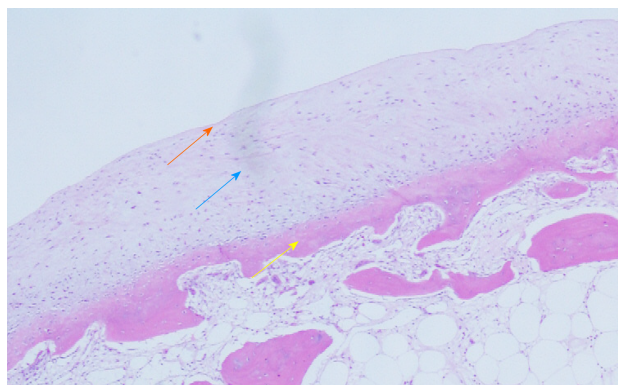


Figure 5 Histological section of an osteochondroma showing the three layers. Red arrow: Perichondrium; Green arrow: Cartilage cap; Yellow arrow: Underlying bone. Hematoxylin and eosin stain, $\times 100$.

TREATMENT

We planned to perform osteotomy for surgical excision and excisional biopsy. Intraoperatively, a mass with smooth surface and an unclear superolateral AIIS border was found (Figure 6). The mass was located anterior to the insertion site of the rectus femoris tendon, not involving it. We used a curved osteotome to expose the fresh bone following the border of ilium. Intraoperative fluoroscopic device showed the bony border being not the same as that of the unaffected side (Figure 7). We could confirm the removal with additional osteotomy by only the surface being peeled without the osteotome internally proceeding (Figure 8). Postoperatively, we found out that border of the bone was different from that of the unaffected side (Figure 9).

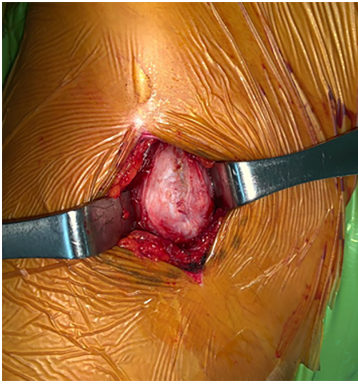


Figure 6 Intraoperatively, an osteochondroma with a smooth margin and cartilaginous cap was found.

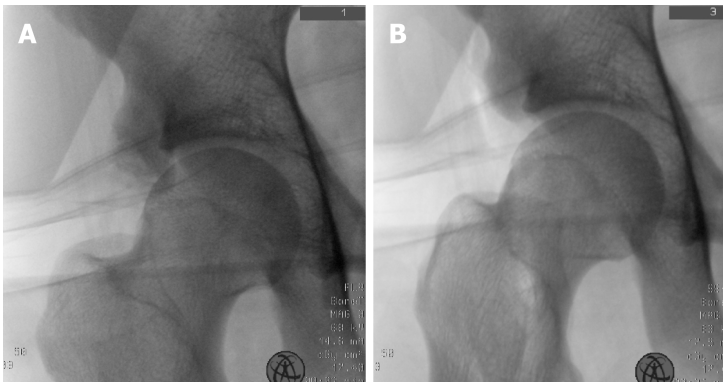


Figure 7 Intraoperative fluoroscopic device showed the bony border being not the same as that of the unaffected side. A: C-arm image before cutting; B: C-arm image after cutting.

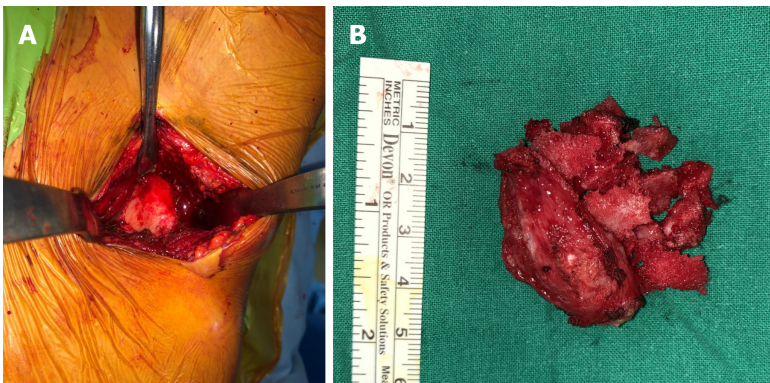


Figure 8 Confirm the removal with additional osteotomy by only the surface being peeled without the osteotome internally proceeding. A: After excision, the fresh bone was exposed; B: A 4 cm × 4 cm specimen was excised.

OUTCOME AND FOLLOW-UP

Postoperatively, the discomfort during hip flexion was improved, and the hip joint range of motion during walking was recovered at the last follow-up, three weeks after the surgery. He provided informed consent of his data being published.

DISCUSSION

Hip avulsion fractures occur mostly during adolescence when actions such as kicking or running cause forceful contraction of attached muscle. The fracture morphology

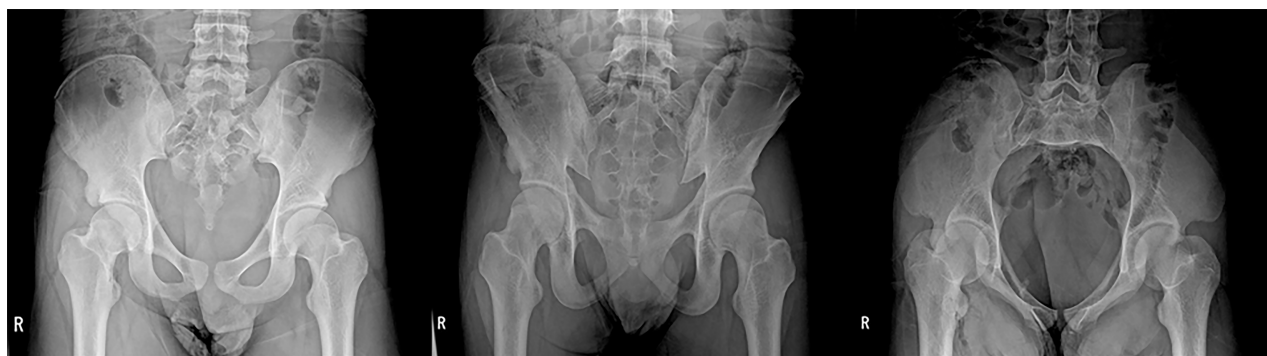

Figure 9 Postoperative X-ray that shows the border of the bone being different from that of the unaffected side.

varies. Ischial tuberosity fractures usually occur during gymnastics, while those of anterior superior iliac spine and AIIS occur during soccer^[2]. The symptoms tend to be mild, with localized tenderness and swelling in the fracture site. Primary ossification of the hip joint occurs from the age of 11 to 17 years. Fractures of this period can affect the secondary ossification center; therefore, the unaffected site must be the reference. In AIIS avulsion fractures, fracture displacement is rare, as other connected tendons bind it if proximal rectus femoris is intact. Most hip avulsion fractures can be satisfactorily treated conservatively. Partial weight bearing using crutches are allowed after two weeks, while stretching the muscles needs more care.

Osteochondroma is benign tumor that mostly occurs at the metaphysis of a long bone, being usually asymptomatic. However, occasionally, it is symptomatic due to complications according to size and location. Skeletal complications include deformity, defective function, fracture, and malignant change. Non-skeletal complications can occur because of vessel and nerve compression. Physical examination and simple X-ray are usually used for diagnosis, and computed tomography and MRI are helpful for confirming its exact size and location. MRI discerns surrounding soft tissue and the exact border between osteochondroma and normal bone using signal intensity difference. However, a definite diagnosis requires pathologic biopsy, which shows characteristic features of a well-divided cartilage cap over the bone's surface. Asymptomatic single osteochondroma does not require treatment, while X-rays are needed to monitor changes. Surgical excision must be considered when pain, limited range of motion, restricted blood supply, nerve symptoms, or malignant changes exist.

The origin of osteochondroma is unclear. In 1891, Virchow reported osteochondroma occurring in cartilage separated from growth plate. In 1920, Keith reported it occurring when a defect in the periosteal bone collar is, causing abnormal proliferation^[3]. Geshickter and Copeland mentioned that a cluster of embryonic connective tissue can transform into osteochondroma with repetitive external force at the tendon insertion site^[4]. Van Winkle and Mazur reported a case of osteochondroma at surgical drainage site of osteomyelitis in a ten-month-old infant, mentioning that surgical drainage may have damaged the growth plate and induced the osteochondroma, according to Keith's theory. Some authors have reported that a trauma history prior to osteochondroma formation is relevant^[5,6]. Mintzer *et al*^[7] reported a case of osteochondroma after a displaced Salter-Harris type II fracture in the distal femur^[7]. Miah *et al*^[8] reported a case of osteochondroma occurring ten years after trauma^[8].

The patient of this report underwent osteotomy until fresh bone was exposed. The border was different from that of the unaffected side. Compared to previous X-rays, this suggested bone remodeling due to callus formation of AIIS apophysis and that osteochondroma was caused by AIIS avulsion fracture.

CONCLUSION

This case can show the correlation between previous trauma and osteochondroma formation. Therefore, the authors found out the importance of history taking when we meet an osteochondroma patient. Previous traumatic history needs to be ruled out. Further case reports regarding this type of history and development of osteochondroma are needed for accumulation of data.

REFERENCES

- 1 **Calderazzi F**, Nosenzo A, Galavotti C, Menozzi M, Pogliacomì F, Ceccarelli F. Apophyseal avulsion fractures of the pelvis. A review. *Acta Biomed* 2018; **89**: 470-476 [PMID: [30657114](#) DOI: [10.23750/abm.v89i4.7632](#)]
- 2 **Rossi F**, Dragoni S. Acute avulsion fractures of the pelvis in adolescent competitive athletes: prevalence, location and sports distribution of 203 cases collected. *Skeletal Radiol* 2001; **30**: 127-131 [PMID: [11357449](#) DOI: [10.1007/s002560000319](#)]
- 3 **Brien EW**, Mirra JM, Luck JV Jr. Benign and malignant cartilage tumors of bone and joint: their anatomic and theoretical basis with an emphasis on radiology, pathology and clinical biology. II. Juxtacortical cartilage tumors. *Skeletal Radiol* 1999; **28**: 1-20 [PMID: [10068070](#) DOI: [10.1007/s002560050466](#)]
- 4 **Geschickter CF**, Copeland MM. Tumors of Bone. Philadelphia: JB Lippincott, 1949
- 5 **Bates DL**, Osborne WM. Post-traumatic osteochondroma of the calcaneus. *J Am Podiatr Med Assoc* 1990; **80**: 606-607 [PMID: [2231349](#) DOI: [10.7547/87507315-80-11-606](#)]
- 6 **Ogden JA**. Multiple hereditary osteochondromata. Report of an early case. *Clin Orthop Relat Res* 1976; 48-60 [PMID: [1084249](#)]
- 7 **Mintzer CM**, Klein JD, Kasser JR. Osteochondroma formation after a Salter II fracture. *J Orthop Trauma* 1994; **8**: 437-439 [PMID: [7996330](#) DOI: [10.1097/00005131-199410000-00013](#)]
- 8 **Miah A**, Chu JS, Yegorov A. Post-traumatic osteochondroma of the distal femur. *Radiol Case Rep* 2018; **13**: 208-211 [PMID: [29487657](#) DOI: [10.1016/j.racr.2017.08.009](#)]



Published by **Baishideng Publishing Group Inc**
7041 Koll Center Parkway, Suite 160, Pleasanton, CA 94566, USA

Telephone: +1-925-3991568

E-mail: bpgoffice@wjgnet.com

Help Desk: <https://www.f6publishing.com/helpdesk>

<https://www.wjgnet.com>

