


World Journal of *Gastroenterology*

World J Gastroenterol 2020 November 28; 26(44): 6909-7087



REVIEW

- 6909** Pituitary stalk interruption syndrome and liver changes: From clinical features to mechanisms
Wu ZY, Li YL, Chang B

MINIREVIEWS

- 6923** Emerging use of artificial intelligence in inflammatory bowel disease
Kohli A, Holzwanger EA, Levy AN

ORIGINAL ARTICLE

Basic Study

- 6929** Development and validation of a three-long noncoding RNA signature for predicting prognosis of patients with gastric cancer
Zhang J, Piao HY, Wang Y, Lou MY, Guo S, Zhao Y
- 6945** Artificial intelligence based real-time microcirculation analysis system for laparoscopic colorectal surgery
Park SH, Park HM, Baek KR, Ahn HM, Lee IY, Son GM
- 6963** Use of the alkaline phosphatase to prealbumin ratio as an independent predictive factor for the prognosis of gastric cancer
Li Y, Wang JS, Guo Y, Zhang T, Li LP

Case Control Study

- 6979** Fatty liver is an independent risk factor for gallbladder polyps
Ahn DW, Jeong JB, Kang J, Kim SH, Kim JW, Kim BG, Lee KL, Oh S, Yoon SH, Park SJ, Lee DH

Retrospective Cohort Study

- 6993** Active tuberculosis in inflammatory bowel disease patients under treatment from an endemic area in Latin America
Fortes FML, Boa Sorte N, Mariano VD, Andrade LD, Oliveira FA, Santos MCA, dos Santos CIN, Passos CA, Pacheco MP, Surlo VC, de Almeida NP, Fontes JAM, Pimentel AM, Rocha R, Santana GO

Retrospective Study

- 7005** Hepatocellular carcinoma with tumor thrombus in bile duct: A proposal of new classification according to resectability of primary lesion
Zhou D, Hu GF, Gao WC, Zhang XY, Guan WB, Wang JD, Ma F
- 7022** Prognostic value of changes in serum carcinoembryonic antigen levels for preoperative chemoradiotherapy response in locally advanced rectal cancer
Cheong C, Shin JS, Suh KW

- 7036** Endoscopic pancreaticobiliary drainage with overlength stents to prevent delayed perforation after endoscopic papillectomy: A pilot study

Wu L, Liu F, Zhang N, Wang XP, Li W

Observational Study

- 7046** Prevalence and predictors of nonalcoholic fatty liver disease in South Asian women with polycystic ovary syndrome

Shengir M, Krishnamurthy S, Ghali P, Deschenes M, Wong P, Chen T, Sebastiani G

Prospective Study

- 7061** Associations between serum uric acid and hepatobiliary-pancreatic cancer: A cohort study

Huang CF, Huang JJ, Mi NN, Lin YY, He QS, Lu YW, Yue P, Bai B, Zhang JD, Zhang C, Cai T, Fu WK, Gao L, Li X, Yuan JQ, Meng WB

CASE REPORT

- 7076** COVID-19 in a liver transplant recipient: Could iatrogenic immunosuppression have prevented severe pneumonia? A case report

Sessa A, Mazzola A, Lim C, Atif M, Pappatella J, Pourcher V, Scatton O, Conti F

LETTER TO THE EDITOR

- 7085** Letter to editor 'prognostic significance of hepatic encephalopathy in patients with cirrhosis treated with Rifaximin'

Elzubeir A, Alam SM

ABOUT COVER

Editorial Board Member of *World Journal of Gastroenterology*, Dr. Diego Garcia-Compeán is a Distinguished Professor of Internal Medicine and Gastroenterology at Faculty of Medicine, Autonomous University of Nuevo Leon Mexico, where he received his degree in Medicine (1979) and completed postgraduate training in Internal Medicine (1982). He studied gastroenterology at the University of Montpellier, France (1985) and received a Master's in Medical Sciences with *cum laude* honors from the National Autonomous University of Mexico (1988). He is currently a member of the National Research System, level II, the Mexican Association of Gastroenterology, the Société Nationale Française de Gastroentérologie, the AGA, and the LAASL. His ongoing research interests involve NAFLD, eosinophilic esophagitis, liver cirrhosis, and VCE. He has published more than 75 papers in international journals, edited 3 books, and obtained national and international awards. (L-Editor: Filipodia)

AIMS AND SCOPE

The primary aim of *World Journal of Gastroenterology* (WJG, *World J Gastroenterol*) is to provide scholars and readers from various fields of gastroenterology and hepatology with a platform to publish high-quality basic and clinical research articles and communicate their research findings online. WJG mainly publishes articles reporting research results and findings obtained in the field of gastroenterology and hepatology and covering a wide range of topics including gastroenterology, hepatology, gastrointestinal endoscopy, gastrointestinal surgery, gastrointestinal oncology, and pediatric gastroenterology.

INDEXING/ABSTRACTING

The WJG is now indexed in Current Contents®/Clinical Medicine, Science Citation Index Expanded (also known as SciSearch®), Journal Citation Reports®, Index Medicus, MEDLINE, PubMed, PubMed Central, and Scopus. The 2020 edition of Journal Citation Report® cites the 2019 impact factor (IF) for WJG as 3.665; IF without journal self cites: 3.534; 5-year IF: 4.048; Ranking: 35 among 88 journals in gastroenterology and hepatology; and Quartile category: Q2.

RESPONSIBLE EDITORS FOR THIS ISSUE

Production Editor: Ji-Hong Liu; Production Department Director: Yun-Xiaojuan Wu; Editorial Office Director: Ze-Mao Gong.

NAME OF JOURNAL

World Journal of Gastroenterology

ISSN

ISSN 1007-9327 (print) ISSN 2219-2840 (online)

LAUNCH DATE

October 1, 1995

FREQUENCY

Weekly

EDITORS-IN-CHIEF

Andrzej S Tarnawski, Subrata Ghosh

EDITORIAL BOARD MEMBERS

<http://www.wjgnet.com/1007-9327/editorialboard.htm>

PUBLICATION DATE

November 28, 2020

COPYRIGHT

© 2020 Baishideng Publishing Group Inc

INSTRUCTIONS TO AUTHORS

<https://www.wjgnet.com/bpg/gerinfo/204>

GUIDELINES FOR ETHICS DOCUMENTS

<https://www.wjgnet.com/bpg/GerInfo/287>

GUIDELINES FOR NON-NATIVE SPEAKERS OF ENGLISH

<https://www.wjgnet.com/bpg/gerinfo/240>

PUBLICATION ETHICS

<https://www.wjgnet.com/bpg/GerInfo/288>

PUBLICATION MISCONDUCT

<https://www.wjgnet.com/bpg/gerinfo/208>

ARTICLE PROCESSING CHARGE

<https://www.wjgnet.com/bpg/gerinfo/242>

STEPS FOR SUBMITTING MANUSCRIPTS

<https://www.wjgnet.com/bpg/GerInfo/239>

ONLINE SUBMISSION

<https://www.f6publishing.com>



COVID-19 in a liver transplant recipient: Could iatrogenic immunosuppression have prevented severe pneumonia? A case report

Anna Sessa, Alessandra Mazzola, Chetana Lim, Mohammed Atif, Juliana Pappatella, Valerie Pourcher, Olivier Scatton, Filomena Conti

ORCID number: Anna Sessa 0000-0001-5168-6135; Alessandra Mazzola 0000-0003-4661-9629; Chetana Lim 0000-0001-9644-2572; Mohammed Atif 0000-0001-8673-8134; Juliana Pappatella 0000-0001-5550-7325; Valerie Pourcher 0000-0003-0617-8136; Olivier Scatton 0000-0001-8313-3500; Filomena Conti 0000-0001-6914-8204.

Author contributions: Sessa A and Mazzola A were the patient's doctors, reviewed the literature and contributed to manuscript drafting; Pourcher V performed the infectious diseases consultation, and drafted the manuscript; Lim C performed the surgery consultation; Pappatella J contributed to manuscript drafting; Scatton O, Conti F and Atif M were responsible for the revision of the manuscript for important intellectual content; and all authors issued final approval for the version to be submitted.

Informed consent statement:

Informed written consent was obtained from the patient for publication of this report and any accompanying images.

Conflict-of-interest statement: The authors declare that they have no conflict of interest.

Anna Sessa, Department of Hepatology and Gastroenterology, University of Naples Federico II, Napoli 80131, Italy

Anna Sessa, Alessandra Mazzola, Juliana Pappatella, Filomena Conti, APHP, Unité Médicale de Transplantation Hépatique Hôpital Pitié Salpêtrière, Paris 75013, France

Alessandra Mazzola, Olivier Scatton, Filomena Conti, Sorbonne Université, INSERM, Centre de Recherche Saint-Antoine (CRSA), Paris 75013, France

Chetana Lim, Olivier Scatton, APHP, Unité de Chirurgie Hépatobiliaire et Transplantation Hépatique, Hôpital Pitié Salpêtrière, Paris 75013, France

Mohammed Atif, APHP, Centre d'immunologie et des Maladies Infectieuses, Inserm U1135, Hôpital Pitié-Salpêtrière, Paris 75013, France

Juliana Pappatella, Hospital Felicio Rocho, Barro Preto 9530, Brazil

Valerie Pourcher, APHP, Service des Maladies Infectieuses, Hôpital Pitié Salpêtrière, Paris 75013, France

Filomena Conti, Sorbonne Université, INSERM, Institute of Cardiometabolism and Nutrition (ICAN), Paris 75013, France

Corresponding author: Alessandra Mazzola, MD, PhD, Doctor, APHP, Unité Médicale de Transplantation Hépatique Hôpital Pitié Salpêtrière, Boulevard de l'Hôpital 47-83, Paris 75013, France. alessandra.mazzola3@gmail.com

Abstract

BACKGROUND

Coronavirus disease (COVID) is a new and highly contagious infectious disease caused by the coronavirus (COVID-19 or severe acute respiratory syndrome coronavirus 2). There is limited data regarding the incidence and management of COVID-19 in immunocompromised patients' post-transplantation. In the pre-COVID-19 era, these patients were already at an increased risk of developing opportunistic infections. These often manifested with atypical symptoms.

CASE SUMMARY

CARE Checklist (2016) statement:

The authors have read the CARE Checklist (2016), and the manuscript was prepared and revised according to the CARE Checklist (2016).

Open-Access: This article is an open-access article that was selected by an in-house editor and fully peer-reviewed by external reviewers. It is distributed in accordance with the Creative Commons Attribution NonCommercial (CC BY-NC 4.0) license, which permits others to distribute, remix, adapt, build upon this work non-commercially, and license their derivative works on different terms, provided the original work is properly cited and the use is non-commercial. See: <http://creativecommons.org/licenses/by-nc/4.0/>

Manuscript source: Unsolicited manuscript

Specialty type: Gastroenterology and hepatology

Country/Territory of origin: France

Peer-review report's scientific quality classification

Grade A (Excellent): A
Grade B (Very good): B
Grade C (Good): C
Grade D (Fair): D
Grade E (Poor): E

Received: May 5, 2020

Peer-review started: May 5, 2020

First decision: May 15, 2020

Revised: May 22, 2020

Accepted: October 26, 2020

Article in press: October 26, 2020

Published online: November 28, 2020

P-Reviewer: Vetrugno L, Zhang HW

S-Editor: Huang P

L-Editor: A

P-Editor: Liu JH



We report another case of uneventful COVID-19 pneumonia in a 58-year old male who was 18 mo' post liver transplantation. He received tacrolimus monotherapy since July 2019. The clinical manifestations included only epigastric pain radiating to the right hypochondrium, nausea and vomiting. He had no fevers, cough, shortness of breath, anosmia or dysgeusia even if the chest computed tomography scan revealed an extension of the multiple patchy ground-glass density shadows to the upper lobe of the left lung too. He was hospitalised and received a course of oral chloroquine (200 mg × 3 per day) for a period of 10 d. Interestingly, the COVID 19 infection was uneventful though there were no modifications to his tacrolimus dosing. He was successfully discharged. We performed subsequent follow-up *via* telemedicine.

CONCLUSION

In light of the current pandemic, it is even more important to identify how the liver recipient's patients present and are managed, especially for immunosuppression treatment.

Key Words: Liver transplantation; COVID-19; Immunosuppression; Gastrointestinal symptom; Infection; Case report

©The Author(s) 2020. Published by Baishideng Publishing Group Inc. All rights reserved.

Core Tip: Coronavirus disease (COVID) is a novel and unknown infectious disease that involves all the world due to a novel coronavirus (named severe acute respiratory syndrome coronavirus 2 latter). Immunocompromised patients often present atypical presentations of viral diseases. We report a case of a COVID-19 infection in a liver transplant recipient, in which the first clinical symptoms were abdominal pain without fever or respiratory symptoms. The immunosuppression seems to be doesn't worsen the prognostic of COVID-19 pneumonia for this patient but future studies including more patients are needed to explore the impact of COVID-19 infections in this special setting.

Citation: Sessa A, Mazzola A, Lim C, Atif M, Pappatella J, Pourcher V, Scatton O, Conti F. COVID-19 in a liver transplant recipient: Could iatrogenic immunosuppression have prevented severe pneumonia? A case report. *World J Gastroenterol* 2020; 26(44): 7076-7084

URL: <https://www.wjgnet.com/1007-9327/full/v26/i44/7076.htm>

DOI: <https://dx.doi.org/10.3748/wjg.v26.i44.7076>

INTRODUCTION

Coronavirus disease 2019 (COVID-19) is a highly infectious viral disease with over 3 million confirmed cases globally and over 200000 deaths. On the 30th of January 2020, the World Health Organization declared the Chinese outbreak of COVID-19 as a "Public Health Emergency of International Concern". To contain COVID-19, their Emergency Committee recommended the need for early detection, isolation, contact tracing as well as prompt treatment. However, despite rigorous efforts by governments globally to contain this virus, its incidence continues to rise^[1].

Solid organ transplant (SOT) recipients are under chronic immunosuppression and thus, at an increased risk of developing opportunistic infectious diseases. Amongst SOT patients, the early clinical reports of COVID-19 have been limited to heart and kidney transplant recipients only. In this report, we describe the management of COVID-19 infection in a liver transplantation (LT) recipient^[2].

CASE PRESENTATION**Chief complaints**

A 58-year old black male who was 18 mo' post LT presented to our Emergency

Department with abdominal pain.

History of present illness

On the 9th of March, he developed epigastric pain radiating to the right hypochondrium as well as nausea and vomiting. He had no fevers, cough, shortness of breath, anosmia or dysgeusia.

History of past illness

The liver transplant had been performed in July 2018 for hepatocellular carcinoma and end-stage liver disease secondary to hepatitis B (HBV). He was on tacrolimus-based immunosuppression in mono-therapy since July 2019 and took a nucleoside analogue for HBV graft reinfection prophylaxis. He had stopped mycophenolate mofetil because of repetitive urinary infections.

Unfortunately, this gentleman's early and late post-transplant course was complicated by the need for further surgical and endoscopic interventions. In November 2018, he underwent emergency laparotomy for adhesional bowel obstruction during which a colostomy was formed. In January 2019, he presented with repetitive cholangitis and iatrogenic acute pancreatitis. This was related to issues with biliary drainage and thus, was resolved after undergoing an endoscopic retrograde cholangio-pancreatography.

In terms of other relevant medical history, he took aspirin as thromboprophylaxis for prevention of hepatic artery thrombosis and was on amlodipine for arterial hypertension. He denied any history of recent foreign travel or exposure to others infected/suspected of COVID-19.

Personal and family history

The patient did not smoke or consume alcohol. There was no noteworthy family medical history.

Physical examination

His physical examination was unremarkable.

Laboratory examinations

On the 10th of March, his laboratory results revealed; low lymphocyte count, percentage of lymphocytes and a slightly increased C-reactive protein (CRP) at (12.4 mg/L). There were no other abnormalities identified (Table 1).

Imaging examinations

His abdominal computed tomography (CT) scan with contrast was unremarkable from the abdominal perspective however, the lower chest slices identified multiple bilateral patchy ground-glass density shadows. For this reason, the 12th of March, he underwent a formal chest CT scan, which revealed an extension of the multiple patchy ground-glass density shadows to the upper lobe of the left lung too (Figure 1). All of this was suggestive of COVID-19 pneumonia and the patient was hospitalised in infectious disease department of our hospital the same day.

Further diagnosis work-up

At admission, he remained afebrile and his clinical observations such as blood pressure, pulse, blood oxygen saturation (98%) were all within normal ranges. The body mass index was 22 kg/m². He thus did not require intensive support neither oxygen therapy. On examination of his chest, there were no positive cardiac- or pulmonary-related findings. However, upon abdominal examination, he continued to have epigastric pain radiating to the right hypochondrium.

His laboratory results revealed an exacerbation of the lymphocyte counts and percentages as well as an increase in his CRP (112.28 mg/L) (Table 1). There were no abnormalities in his liver and kidney biochemical markers. In terms of confirming COVID-19, his nasopharyngeal and oropharyngeal swab specimens came back as positive using the real-time polymerase chain reaction.

FINAL DIAGNOSIS

The radiological and virological characteristics were strongly suggestive for COVID-19 pneumonia with gastrointestinal involvement in a LT patient.

Table 1 Laboratory tests of patients

	No symptoms	Start symptoms	Start treatment	After treatment
Laboratory parameters	February 22	March 10	March 16	March 24
AST, UI/L	24	22	32	26
ALT, UI/L	19	28	16	24
Total bilirubin (μmol/L)	6.5	3.5	8	8
Albumin (g/L)	33	35	33	31
Creatinine (μmol/L)	118.6	119	135	134.5
Hemoglobin (g/L)	12.1	12.5	12.5	11.7
Platelet	159000	122000	136000	296000
Lymphocytes	1020	1050	390	996
PT (%)	100	86	27	88
INR	1	1.05	1.5	1.1
Tacrolimus (ng/mL)	3.5	3.5	3.2	3.8
CRP (mg/L)	3.05	12.4	112.28	6.6

AST: Aspartate transaminase; ALT: Alanine transaminase; PT: Prothrombin time; INR: International normalized ratio; CRP: C reactive protein.

TREATMENT

On the 16th March, he received a course of oral chloroquine (200 mg × 3 per day) for a period of 10 d. No antibiotic treatment was administered. We made no modifications to his tacrolimus dosing (serum level was 3.8 ng/mL).

OUTCOME AND FOLLOW-UP

He was successfully discharged to advice to finish his course of chloroquine at home and self-isolate. We performed subsequent follow-up *via* telemedicine. At the end of his treatment, his abdominal pain had resolved and his laboratory results were normal too (Table 1). After two months of COVID infection, no clinical and biological abnormalities have been found during our medical consultation.

DISCUSSION

There remains limited knowledge of the impact of COVID-19 in SOT patients. It is all the more challenging for LT as recent case reports have been limited to kidney and heart recipients only^[3-5]. In a previous manuscript, Qin *et al*^[6] described the diagnose of COVID-19 in a LT-recipient during the peri-operative period. This was put down to an unrecognized infection caught pre-transplantation. Also, few cases are recently reported in Lombardia transplant centre, in a Spanish series of SOT and in a Chinese report for a total number of 7 patients^[7-9]. The clinical characteristics and outcomes of COVID-19 LT patients are summarized in Table 2. To our knowledge, our report is another case of COVID-19 infection in a patient after 2 years of LT.

Symptoms

Infections might be considered in the differential diagnosis in the case of changes in clinical status of SOT even in the absence of common signs or symptoms of infection. Data showed that, fever and physical signs of all types of infection in SOT patients, especially pulmonary and gastrointestinal infections, are diminished with subtle laboratory or radiological signs^[10].

For symptoms of COVID-19 infection, it seems that SOT patients consistently have atypical presentations.

Our patient had epigastric pain, nausea and vomiting without any symptoms

Table 2 Clinical and biological characteristics of patients with coronavirus disease 2019 pneumonia after liver transplants

Ref.	Study type	Patients (n)	Age (yr)	Time from transplantation	Clinical manifestations	Immunosuppression treatment	Immuno-suppression, modification	Metabolic comorbidities	Death
Fernández-Ruiz <i>et al</i> ^[8]	Case series	6	63	7.9 yr	Fever, shortness of breath, cough	EVE	Yes	Hypertension, diabetes	No
			72	5.5 yr	Fever, shortness of breath, cough	MMF, EVE	Yes	Hypertension, diabetes, obesity	Yes
			79	15.3 yr	Shortness of breath, cough, malaise, diarrhea	Prednisone AZA, EVE	Yes	Diabetes, chronic renal failure	Yes
			73	16.4 yr	Fever, shortness of breath, cough, malaise	MMF	Yes	Diabetes	Yes
			76	26.5 yr	Fever, thoracic, pain	Tacrolimus	No	Hypertension	No
			46	6.4 yr	Diarrhea	Tacrolimus	No		No
Bhoori <i>et al</i> ^[7]	Correspondence	6	> 65	> 10 yr			Yes		Yes
			> 65	> 10 yr			Yes	Diabetes, overweight, hyperlipidemia	Yes
			> 65	> 10 yr			Yes	Diabetes, overweight, hyperlipidemia	Yes
				< 2 yr		Calcineurin inhibitors	Yes	Diabetes, overweight, hyperlipidemia	No
				< 2 yr		Calcineurin inhibitors	Yes		No
				< 2 yr		Calcineurin inhibitors	Yes		No
Huang <i>et al</i> ^[9]	Case report	1	59	3 yr	Fever, cough, chills, fatigue, icterus and diarrhea	MMF et tacrolimus			Yes
Qin <i>et al</i> ^[6]	Case report	1	37	53 d	Persistent fever	Tacrolimus and glucocorticoids			No

EVE: Everolimus; MMF: Mycophenolate mofetil; AZA: Azathioprine.

classically associated with COVID-19. A recent manuscript regarding COVID-19 infection in a heart transplant recipient reported that their patient presented with fever, diarrhoea, fatigue but no respiratory symptoms^[3]. Also, in the Spanish case series, the authors reported 6 cases in liver transplant recipients: Five of them presented with respiratory symptoms, one presented with only diarrhoea^[8].

Interestingly, a different report in a patient post-kidney transplantation described that their patient presented with conjunctivitis. Although this could be because the virus is present in conjunctival secretions, < 1% of other COVID-19 patients present in this manner^[5].

In terms of explaining the modality of our patients' gastrointestinal symptoms, these could be due to the presence of the angiotensin-converting enzyme II (ACE2) receptors in the upper oesophagus (stratified squamous epithelium) and intestinal enterocytes. The ACE2 receptor is the entry mechanism for the severe acute respiratory syndrome coronavirus (SARS-CoV) virus into human cells. This receptor is also highly expressed in alveolar type II pneumocytes, which may the development of respiratory symptoms classically associated with COVID-19 infection. Upon intracellular entry, the host transmembrane serine protease enzyme (TMPRSS) helps to release the viral proteins into the cell. It is plausible that the presence of the ACE2 receptors on the gastrointestinal cells may explain the occurrence of abdominal pain and diarrhoea^[11]. The SARS-CoV-2 virus has been found in faeces and stool samples

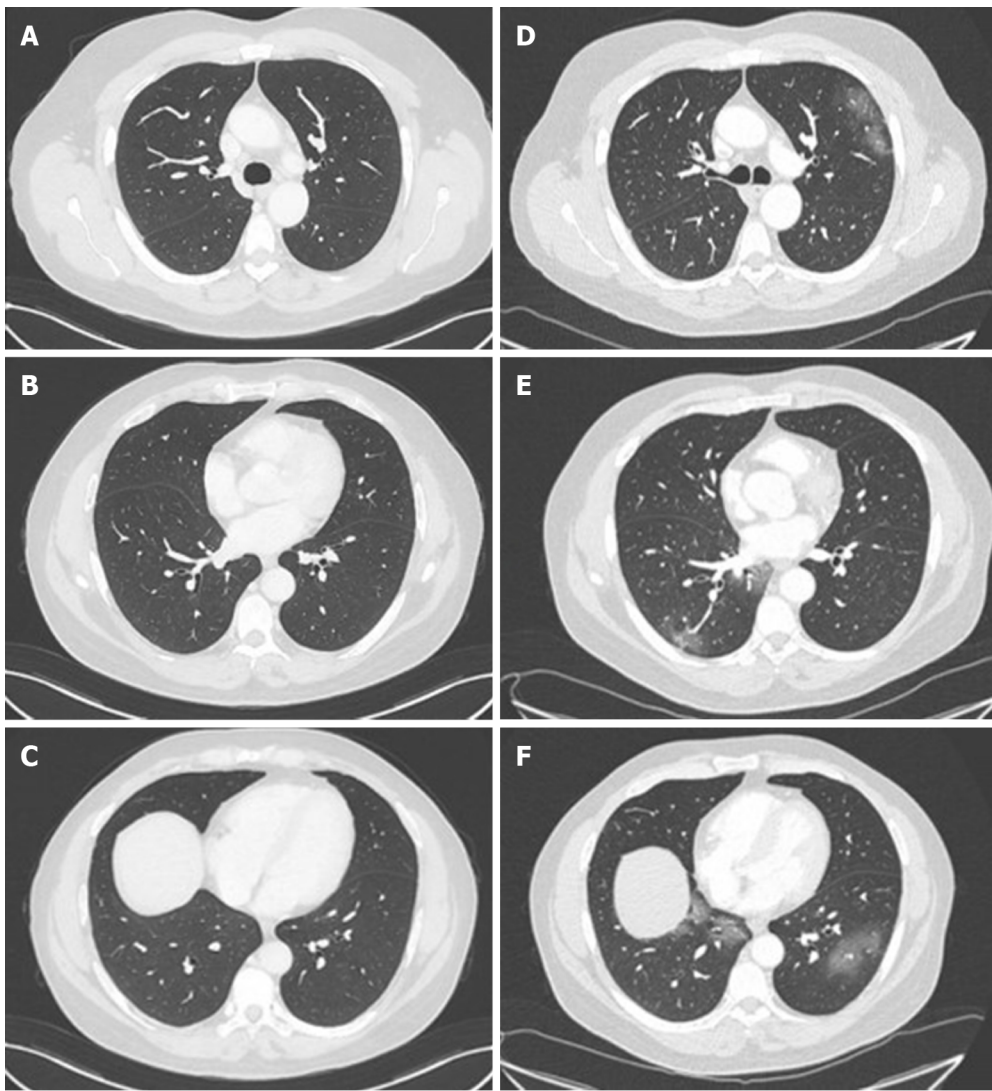


Figure 1 Chest computed tomography of a 58-year-old man who underwent liver transplantation in 2018. A-C: Normal chest computed tomography (CT) of the patient in November 2019; D and E: Chest CT on admission in March 2020 showing ground-glass opacities with a peripheral distribution.

even when it is no longer detectable in the respiratory tract. This suggests the possibility of a faecal–oral route of viral transmission^[12].

Immunosuppression management

The risk of serious infections in SOT is determined by interactions between the patient's epidemiological exposures and the state of immune suppression. In case of infection, the reduction in immunosuppression may be a useful component of antimicrobial therapy but with an increased risk of graft rejection or immune reconstitution syndromes. Reduction in specific immunosuppressive regimen should be roughly linked to the host responses desired for the pathogens encountered (*e.g.*, steroids for bacteria and fungi, calcineurin inhibitors for viruses, cell cycle agents in neutropenia) recognizing that each agent has multiple effects on the immune system^[10].

In our case, instead, our decision to continue tacrolimus at the same dose was based upon recommendations from The French Society of Transplantation as well as the recent joint position paper by The European Society for Study of Liver (EASL) and European Society of Clinical Microbiology and Infectious Diseases (ESCMID)^[13,14]. The French guidelines recommended that LT recipients who were more than a year post-transplant to make the following modifications to their immunosuppression regimens^[13]: (1) Patients on dual therapy of tacrolimus/mycophenolate plus mammalian transporter of rapamycin (mTOR) inhibitor: Maintain the tacrolimus/mycophenolate, however discontinue the mTOR inhibitor; and (2) Patients on monotherapy with mycophenolate acid or mTOR inhibitor: Maintain the same treatment at the same dose.

In parallel, the EASL-ESCMID recommendation was to only reduce immuno-

suppression dosage under special circumstances (*e.g.*, drug-induced lymphopenia, or bacterial/fungal superinfection in the case of severe COVID-19)^[14]. Furthermore, the safety of immunosuppression therapy was confirmed in a recent case series from Italy, in which immunosuppression seemed not to increased risk of severe pulmonary disease in children who had received liver transplants, compared with the general population^[15]. In comparison with Lombardia experience, and in line with Spanish experience, no change in immunosuppression therapy was done^[7,8]. Although our patient neither stopped nor reduced immunosuppression, they had a favourable outcome using an experimental treatment. In conclusion, it seems reasonable that all these decisions were to be made in close consultation with the patients' local transplant hepatologist^[14].

Overall, there is limited data regarding immunosuppression management in COVID-19-positive transplant patients. In these patients, it is critical to get the right balance between protecting the allograft as well as aiding the immune system in mounting an effective anti-COVID-19 response. Moreover, it is most concerning that a subgroup of non-transplant patients with severe COVID-19 have been shown to develop a cytokine storm-like syndrome involving haemophagocytic lymphohistiocytosis and multi-organ failure^[16]. The authors who identified this suggested that all patients with severe COVID-19 should be screened for hyperinflammation to identify the subgroup for whom immunosuppression could prevent mortality^[16]. This is amongst one of the primary reasons for which clinical trials are underway to test a broad range of anti-inflammatory agents (*e.g.*, steroids, intravenous immunoglobulins, anti-IL-1, anti-IL-6, and JAK inhibition)^[17,18]. In the case of our patient, we would speculate that the continued use of tacrolimus in our patient could have in parallel, also protected against the cytokine storm syndrome.

Treatment of COVID-19 pneumonia and outcomes

When infections occur in SOT were associated with an increased risk of morbidity and mortality especially in the first three months after transplantation^[10]. A rapid diagnosis and the beginning of a specific therapy consent an improvement in a clinical outcome.

Our patient received a 10-d course of chloroquine rapidly after diagnosis with no reported side effects. However, it is important to consider that there is currently no global consensus on the ideal treatment for COVID-19 infection in transplant and non-transplant patients. It is all the most challenging in transplantation as we generally have a lower threshold to treat other opportunistic infections.

An early clinical trial from China conducted in COVID-19-positive non-transplant patients demonstrated that chloroquine had a significant effect, both in terms of clinical outcome and viral clearance. Indeed, the Chinese guidance recommends the use of chloroquine as a treatment for COVID-19 pneumonia regardless of severity^[19,20]. Furthermore, a recent French trial conducted reported the efficacy of hydroxychloroquine treatment in reduction and suppression of viral load for COVID-19 patients^[21]. In our case, it is theoretically plausible that, although chloroquine could have reduced viral load, the concomitant tacrolimus inhibited the inflammatory cascade involved in the propagation of severe respiratory symptoms^[22].

Moreover, few data are available regarding the outcomes on COVID-19 liver transplant patients. As reported in Table 2, three of among 111 patients liver transplant survivors (transplanted more than 10 years ago) died following severe COVID-19 disease^[7], 3 patients died in a Spanish series and, a fatal case of COVID pneumonia after 3 years of LT in a 59 old man with probably overlap chronic rejection was reported by Huang *et al*^[9]. Although the favourable outcome of our patient find another explanation also in scarce presence of metabolic-related comorbidities (only arterial hypertension), normally increased with time since transplant^[2,23], that might be associated with an increased risk of severe COVID-19 disease.

CONCLUSION

To our knowledge, this is one of few uneventful reports about COVID-19 infection in a patient post-LT. He had atypical symptoms which successfully resolved with chloroquine treatment and continued tacrolimus. We would recommend that screening for underlying COVID-19 infection be performed in all immunocompromised patients presenting with atypical symptoms. The recommendations from the national guidance should be modified with the evolution of our understanding of this disease and its treatment.

REFERENCES

- World Health Organization.** Coronavirus disease 2019 (COVID-19) Situation Report – 44. 2020 Available from: https://www.who.int/docs/default-source/coronaviruse/situation-reports/20200304-sitrep-44-covid-19.pdf?sfvrsn=93937f92_6
- Huang C,** Wang Y, Li X, Ren L, Zhao J, Hu Y, Zhang L, Fan G, Xu J, Gu X, Cheng Z, Yu T, Xia J, Wei Y, Wu W, Xie X, Yin W, Li H, Liu M, Xiao Y, Gao H, Guo L, Xie J, Wang G, Jiang R, Gao Z, Jin Q, Wang J, Cao B. Clinical features of patients infected with 2019 novel coronavirus in Wuhan, China. *Lancet* 2020; **395**: 497-506 [PMID: 31986264 DOI: 10.1016/S0140-6736(20)30183-5]
- Li F,** Cai J, Dong N. First cases of COVID-19 in heart transplantation from China. *J Heart Lung Transplant* 2020; **39**: 496-497 [PMID: 32362394 DOI: 10.1016/j.healun.2020.03.006]
- Zhu L,** Xu X, Ma K, Yang J, Guan H, Chen S, Chen Z, Chen G. Successful recovery of COVID-19 pneumonia in a renal transplant recipient with long-term immunosuppression. *Am J Transplant* 2020; **20**: 1859-1863 [PMID: 32181990 DOI: 10.1111/ajt.15869]
- Guillen E,** Pineiro GJ, Revuelta I, Rodriguez D, Bodro M, Moreno A, Campistol JM, Diekmann F, Ventura-Aguir P. Case report of COVID-19 in a kidney transplant recipient: Does immunosuppression alter the clinical presentation? *Am J Transplant* 2020; **20**: 1875-1878 [PMID: 32198834 DOI: 10.1111/ajt.15874]
- Qin J,** Wang H, Qin X, Zhang P, Zhu L, Cai J, Yuan Y, Li H. Perioperative Presentation of COVID-19 Disease in a Liver Transplant Recipient. *Hepatology* 2020; Online ahead of print [PMID: 32220017 DOI: 10.1002/hep.31257]
- Bhoori S,** Rossi RE, Citterio D, Mazzaferro V. COVID-19 in long-term liver transplant patients: preliminary experience from an Italian transplant centre in Lombardy. *Lancet Gastroenterol Hepatol* 2020; **5**: 532-533 [PMID: 32278366 DOI: 10.1016/S2468-1253(20)30116-3]
- Fernández-Ruiz M,** Andrés A, Loinaz C, Delgado JF, López-Medrano F, San Juan R, González E, Polanco N, Folgueira MD, Lalueza A, Lumberras C, Aguado JM. COVID-19 in solid organ transplant recipients: A single-center case series from Spain. *Am J Transplant* 2020; **20**: 1849-1858 [PMID: 32301155 DOI: 10.1111/ajt.15929]
- Huang JF,** Zheng KI, George J, Gao HN, Wei RN, Yan HD, Zheng MH. Fatal outcome in a liver transplant recipient with COVID-19. *Am J Transplant* 2020; **20**: 1907-1910 [PMID: 32277591 DOI: 10.1111/ajt.15909]
- Fishman JA.** Infection in Organ Transplantation. *Am J Transplant* 2017; **17**: 856-879 [PMID: 28117944 DOI: 10.1111/ajt.14208]
- Gu J,** Han B, Wang J. COVID-19: Gastrointestinal Manifestations and Potential Fecal-Oral Transmission. *Gastroenterology* 2020; **158**: 1518-1519 [PMID: 32142785 DOI: 10.1053/j.gastro.2020.02.054]
- Ianiro G,** Mullah BH, Kelly CR, Sokol H, Kassam Z, Ng SC, Fischer M, Allegretti JR, Masucci L, Zhang F, Keller J, Sanguinetti M, Costello SP, Tilg H, Gasbarrini A, Cammarota G. Screening of faecal microbiota transplant donors during the COVID-19 outbreak: suggestions for urgent updates from an international expert panel. *Lancet Gastroenterol Hepatol* 2020; **5**: 430-432 [PMID: 32192627 DOI: 10.1016/S2468-1253(20)30082-0]
- Société Francophone de Transplantation (SFT);** Société Francophone de Néphrologie; Dialyse et Transplantation (SFNDT); Groupe Infection et Immunodépression; Société de pathologie infectieuse de langue française (SPILF). Prise en charge de l'infection due au SARS-CoV-2 chez les patients adultes transplantés d'organe solide. Available from: https://content.tts.org/content/covid19/COVID19_et_transplant_ees_d_organes_solides_Guide_pratiquev1_SFT_SFNDT_SP.pdf
- Boettler T,** Newsome PN, Mondelli MU, Maticic M, Cordero E, Cornberg M, Berg T. Care of patients with liver disease during the COVID-19 pandemic: EASL-ESCMID position paper. *JHEP Rep* 2020; **2**: 100113 [PMID: 32289115 DOI: 10.1016/j.jhepr.2020.100113]
- D'Antiga L.** Coronaviruses and Immunosuppressed Patients: The Facts During the Third Epidemic. *Liver Transpl* 2020; **26**: 832-834 [PMID: 32196933 DOI: 10.1002/lt.25756]
- Mehta P,** McAuley DF, Brown M, Sanchez E, Tattersall RS, Manson JJ; HLH Across Speciality Collaboration; UK. COVID-19: consider cytokine storm syndromes and immunosuppression. *Lancet* 2020; **395**: 1033-1034 [PMID: 32192578 DOI: 10.1016/S0140-6736(20)30628-0]
- Shakoory B,** Carcillo JA, Chatham WW, Amdur RL, Zhao H, Dinarello CA, Cron RQ, Opal SM. Interleukin-1 Receptor Blockade Is Associated With Reduced Mortality in Sepsis Patients With Features of Macrophage Activation Syndrome: Reanalysis of a Prior Phase III Trial. *Crit Care Med* 2016; **44**: 275-281 [PMID: 26584195 DOI: 10.1097/CCM.0000000000001402]
- Wang DS,** Xu XL. A multicenter, randomized controlled trial for the efficacy and safety of tocilizumab in the treatment of new coronavirus pneumonia (COVID-19). [accessed March 6, 2020]. In: Chinese Clinical Trial Registry [Internet]. Available from: <http://www.chictr.org.cn/showprojen.aspx?proj=49409> Registration number: ChiCTR2000029765
- Gao J,** Tian Z, Yang X. Breakthrough: Chloroquine phosphate has shown apparent efficacy in treatment of COVID-19 associated pneumonia in clinical studies. *Biosci Trends* 2020; **14**: 72-73 [PMID: 32074550 DOI: 10.5582/bst.2020.01047]
- Chinese Clinical Trial Registry. Available from: <http://www.chictr.org.cn/searchproj.aspx?title=&officialname=&E6%B0%AF%E5%96%B9&subjectid=&secondaryid=&applier=&studyleader=ðicalcommitteesaction=&sponsor=&studyaiment=&studyaimentcode=&studytype=&studystage=&studydesign=&minstudyexecutetime=&maxstudyexecutetime=&recruitmentstatus=&gender=&agreetosign=&secsponsor=®no=®status=&country=&province=&city=&institution=&institutionlevel=&measure=&intercode=&sourceofspends=&createyear=&isuploadrf=&whetherpublic=&btngo=btn&verifycode=&page=1>
- Gautret P,** Lagier JC, Parola P, Hoang VT, Meddeb L, Mailhe M, Doudier B, Courjon J, Giordanengo V, Vieira VE, Tissot Dupont H, Honoré S, Colson P, Chabrière E, La Scola B, Rolain JM, Brouqui P, Raoult D. Hydroxychloroquine and azithromycin as a treatment of COVID-19: results of an open-label non-randomized clinical trial. *Int J Antimicrob Agents* 2020; **56**: 105949 [PMID: 32205204 DOI: 10.1016/j.ijantimicag.2020.105949]

- 22 **Wang M**, Cao R, Zhang L, Yang X, Liu J, Xu M, Shi Z, Hu Z, Zhong W, Xiao G. Remdesivir and chloroquine effectively inhibit the recently emerged novel coronavirus (2019-nCoV) in vitro. *Cell Res* 2020; **30**: 269-271 [PMID: [32020029](#) DOI: [10.1038/s41422-020-0282-0](#)]
- 23 **Grasselli G**, Zangrillo A, Zanella A, Antonelli M, Cabrini L, Castelli A, Cereda D, Coluccello A, Foti G, Fumagalli R, Iotti G, Latronico N, Lorini L, Merler S, Natalini G, Piatti A, Ranieri MV, Scandroglio AM, Storti E, Cecconi M, Pesenti A; COVID-19 Lombardy ICU Network. Baseline Characteristics and Outcomes of 1591 Patients Infected With SARS-CoV-2 Admitted to ICUs of the Lombardy Region, Italy. *JAMA* 2020; **323**: 1574-1581 [PMID: [32250385](#) DOI: [10.1001/jama.2020.5394](#)]



Published by **Baishideng Publishing Group Inc**
7041 Koll Center Parkway, Suite 160, Pleasanton, CA 94566, USA

Telephone: +1-925-3991568

E-mail: bpgoffice@wjgnet.com

Help Desk: <https://www.f6publishing.com/helpdesk>

<https://www.wjgnet.com>

