

Match Overview

| | | |
|---|--|----|
| 1 | Internet 26 words crawled on 15-Feb-2020 f6publishing.blob.core.windows.net | 2% |
| 2 | Internet 16 words crawled on 07-Aug-2018 academic.oup.com | 1% |

¹
Name of Journal: *World Journal of Gastrointestinal Surgery*

Manuscript NO: 57479

Manuscript Type: CASE REPORT

Gastric splenosis mimicking **a** gastrointestinal stromal tumor: A case report

Isopi C *et al.* An intragastric nodule mimicking GIST

Claudio Isopi, Giulia Vitali, Federica Pieri, Leonardo Solaini, Giorgio Ercolani

Abstract

BACKGROUND

Mass lesions located in the wall of the stomach (and also of the bowel) are referred to as “intramural”. The differential diagnosis of such lesions can be challenging in some



国内版

国际版



Chat with Bing



An intragastric nodule mimicking a gastrointestinal stromal tumor



Sign in



ALL

IMAGES

VIDEOS

45,600 Results

Any time ▾

Intra-abdominal desmoid tumors mimicking gastrointestinal ...

<https://www.ncbi.nlm.nih.gov/pmc/articles/PMC6487383>

Apr 28, 2019 · **Intra-abdominal desmoid tumors (DTs)** can mimic recurrence or progression of gastrointestinal stromal tumors (GISTs). Differential diagnosis is important to avoid unnecessary or inappropriate treatment.


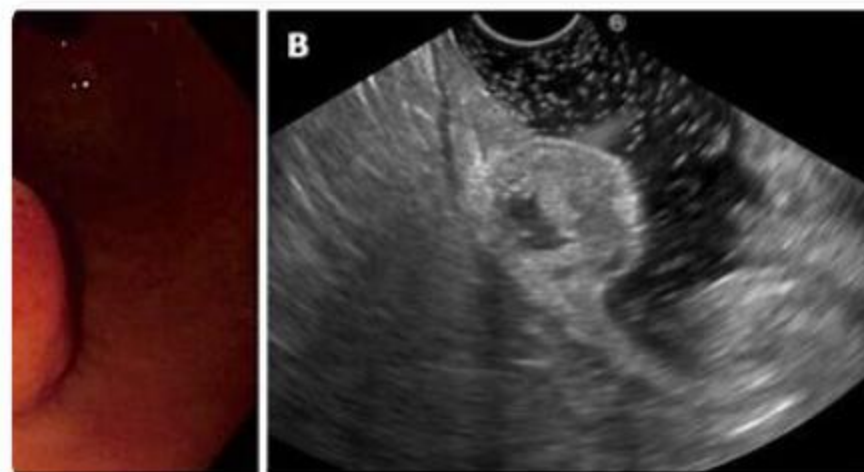
Author: Jwa Hoon Kim, Min-Hee Ryu, Young ... **Publish Year:** 2019

Search Tools

Turn off Hover Translation (关闭取词)

Images of an Intragastric Nodule mimicking a Gastrointestina...

[bing.com/images](https://www.bing.com/images)





ALL

IMAGES

VIDEOS

77,800 Results

Any time ▾

that was initially suspected for **gastric stromal tumor** by upper **gastrointestinal endoscopy** and **endoscopic ultrasonography (EUS)**, and **splenosis** was finally diagnosed after **computed tomography (CT) scan** and a **Tc-99m labeled heat-denatured red blood cell scintigraphy**. To our knowledge, there are no reported cases of splenosis mimicking a gastric GIST. CASE REPORT A 74-year-old male patient was admitted for

SPLENOSIS MIMICKING GASTRIC GIST: CASE REPORT AND ...

www.scielo.br/pdf/abcd/v24n2/en_a19v24n2.pdf

Was this helpful?



[PDF] **SPLENOSIS MIMICKING GASTRIC GIST: CASE REPORT ...**

https://www.scielo.br/pdf/abcd/v24n2/en_a19v24n2.pdf

that was initially suspected for gastric stromal tumor by upper gastrointestinal endoscopy and endoscopic ultrasonography (EUS), and splenosis was finally diagnosed after computed tomography (CT) scan and a Tc-99m labeled heat-denatured red blood cell scintigraphy. To our knowledge, there are no reported cases of splenosis mimicking a gastric GIST. CASE REPORT A 74-year-old male ...

A Case of Gastric Splenosis Mimicking a Stromal Tumor

<https://pubmed.ncbi.nlm.nih.gov/26505815>

A Case of Gastric Splenosis Mimicking a Stromal Tumor. A Case of Gastric Splenosis Mimicking a Stromal Tumor Clin Gastroenterol Hepatol. 2016 May;14(5):e50-1. doi: 10.1016/j.cgh.2015.10.017. Epub 2015 Oct 23. Authors ... Gastrointestinal Stromal Tumors / pathology*

Author: Silvia Carrara, Daoud Rahal, Alessand... Publish Year: 2016

Splenosis in gastric fundus mimicking gastrointestinal ...

<https://www.ncbi.nlm.nih.gov/pubmed/26261537>

Jun 01, 2015 · Splenosis in gastric fundus is rare and difficult to diagnose, since splenosis has similar manifestation with gastrointestinal stromal tumor (GIST) under routine endoscopy examination. In this report, we present two quite rare case of splenosis. Both of their pre-operative diagnose under endoscopic ultrasonography was considered as GIST.

Cited by: 5

Author: Bin Li, Ya Huang, Baoting Chao, Qi Zhao,...



Gastric splenosis mimicking a gastrointestinal stromal tumor: A case



ALL

IMAGES

VIDEOS

MAPS

NEWS

SHOPPING

77,900 Results

Any time ▾

that was initially suspected for **gastric stromal tumor** by upper **gastrointestinal endoscopy** and **endoscopic ultrasonography (EUS)**, and **splenosis** was finally diagnosed after **computed tomography (CT) scan** and a **Tc-99m labeled heat-denatured red blood cell scintigraphy**. To our knowledge, there are no reported cases of splenosis mimicking a gastric **GIST**. CASE REPORT A 74-year-old male patient was admitted for

[SPLENOSIS MIMICKING GASTRIC GIST: CASE REPORT AND ...](#)

www.scielo.br/pdf/abcd/v24n2/en_a19v24n2.pdf

Was this helpful?

[PDF] [SPLENOSIS MIMICKING GASTRIC GIST: CASE REPORT AND ...](#)

https://www.scielo.br/pdf/abcd/v24n2/en_a19v24n2.pdf

that was initially suspected for **gastric stromal tumor** by upper **gastrointestinal endoscopy** and **endoscopic ultrasonography (EUS)**, and **splenosis** was finally diagnosed after **computed tomography (CT) scan** and a **Tc-99m labeled heat-denatured red blood cell scintigraphy**. To our knowledge, there are no reported cases of splenosis mimicking a gastric **GIST**. CASE REPORT A 74-year-old male ...

[A Case of Gastric Splenosis Mimicking a Stromal Tumor](#)

<https://pubmed.ncbi.nlm.nih.gov/26505815>

A Case of Gastric Splenosis Mimicking a Stromal Tumor. A Case of Gastric Splenosis Mimicking a Stromal Tumor Clin Gastroenterol Hepatol. 2016 May;14(5):e50-1. doi: 10.1016/j.cgh.2015.10.017. Epub 2015 Oct 23. Authors ... **Gastrointestinal Stromal Tumors** / pathology*

Author: Silvia Carrara, Daoud Rahal, Alessan... **Publish Year:** 2016

[Splenosis in gastric fundus mimicking gastrointestinal ...](#)

<https://www.ncbi.nlm.nih.gov/pubmed/26261537>

Jun 01, 2015 - **Splenosis** in **gastric fundus** is rare and difficult to diagnose, since **splenosis** has similar manifestation with **gastrointestinal stromal tumor (GIST)** under routine endoscopy examination. In this **report**, we present two quite rare **case** of **splenosis**.

Cited by: 5

Author: Bin Li, Ya Huang, Baoting Chao, Qi Zhao,

http://www.scielo.br/pdf/abcd/v24n2/en_a19v24n2.pdf **Abstract:** This was initially suspected for gastric stromal tumor, REPORT A 74-year-old male