


World Journal of *Clinical Cases*

World J Clin Cases 2021 April 16; 9(11): 2419-2695



MINIREVIEWS

- 2419 Current status of radical laparoscopy for treating hepatocellular carcinoma with portal hypertension
Shen ZF, Liang X

ORIGINAL ARTICLE**Retrospective Cohort Study**

- 2433 Impact of type 2 diabetes on adenoma detection in screening colonoscopies performed in disparate populations
Joseph DF, Li E, Stanley III SL, Zhu YC, Li XN, Yang J, Ottaviano LF, Bucobo JC, Buscaglia JM, Miller JD, Veluvolu R, Follen M, Grossman EB

- 2446 Early colonoscopy and urgent contrast enhanced computed tomography for colonic diverticular bleeding reduces risk of rebleeding
Ochi M, Kamoshida T, Hamano Y, Ohkawara A, Ohkawara H, Kakinoki N, Yamaguchi Y, Hirai S, Yanaka A

Retrospective Study

- 2458 Relationship between mismatch repair protein, *RAS*, *BRAF*, *PIK3CA* gene expression and clinicopathological characteristics in elderly colorectal cancer patients
Fan JZ, Wang GF, Cheng XB, Dong ZH, Chen X, Deng YJ, Song X

Clinical Trials Study

- 2469 Possible effect of blonanserin on gambling disorder: A clinical study protocol and a case report
Shiina A, Hasegawa T, Iyo M

Observational Study

- 2478 Parents' experience of caring for children with type 1 diabetes in mainland China: A qualitative study
Tong HJ, Qiu F, Fan L
- 2487 Differences in dietary habits of people with vs without irritable bowel syndrome and their association with symptom and psychological status: A pilot study
Meng Q, Qin G, Yao SK, Fan GH, Dong F, Tan C

SCIENTOMETRICS

- 2503 Prognostic nomograms for predicting overall survival and cause-specific survival of signet ring cell carcinoma in colorectal cancer patients
Kou FR, Zhang YZ, Xu WR

CASE REPORT

- 2519** Cerebellar artery infarction with sudden hearing loss and vertigo as initial symptoms: A case report
Wang XL, Sun M, Wang XP
- 2524** Three-dimensional-printed custom-made patellar endoprosthesis for recurrent giant cell tumor of the patella: A case report and review of the literature
Wang J, Zhou Y, Wang YT, Min L, Zhang YQ, Lu MX, Tang F, Luo Y, Zhang YH, Zhang XL, Tu CQ
- 2533** Gastrointestinal-type chemotherapy prolongs survival in an atypical primary ovarian mucinous carcinoma: A case report
Wang Q, Niu XY, Feng H, Wu J, Gao W, Zhang ZX, Zou YW, Zhang BY, Wang HJ
- 2542** Neoadjuvant chemoradiotherapy followed by laparoscopic distal gastrectomy in advanced gastric cancer: A case report and review of literature
Liu ZN, Wang YK, Li ZY
- 2555** Extraosseous spinal epidural plasmocytoma associated with multiple myeloma: Two case reports
Cui JF, Sun LL, Liu H, Gao CP
- 2562** Endoscopic diagnosis of early-stage primary esophageal small cell carcinoma: Report of two cases
Er LM, Ding Y, Sun XF, Ma WQ, Yuan L, Zheng XL, An NN, Wu ML
- 2569** Nemaline myopathy with dilated cardiomyopathy and severe heart failure: A case report
Wang Q, Hu F
- 2576** Immunoglobulin D- λ/λ biclonal multiple myeloma: A case report
He QL, Meng SS, Yang JN, Wang HC, Li YM, Li YX, Lin XH
- 2584** Point-of-care ultrasound for the early diagnosis of emphysematous pyelonephritis: A case report and literature review
Xing ZX, Yang H, Zhang W, Wang Y, Wang CS, Chen T, Chen HJ
- 2595** Minimally invasive treatment of forearm double fracture in adult using Acumed forearm intramedullary nail: A case report
Liu JC, Huang BZ, Ding J, Mu XJ, Li YL, Piao CD
- 2602** *Klebsiella pneumoniae* infection secondary to spontaneous renal rupture that presents only as fever: A case report
Zhang CG, Duan M, Zhang XY, Wang Y, Wu S, Feng LL, Song LL, Chen XY
- 2611** Eltrombopag-related renal vein thromboembolism in a patient with immune thrombocytopenia: A case report
Wu C, Zhou XM, Liu XD
- 2619** *Cryptococcus* infection with asymptomatic diffuse pulmonary disease in an immunocompetent patient: A case report
Li Y, Fang L, Chang FQ, Xu FZ, Zhang YB

- 2627** Triple administration of osimertinib followed by chemotherapy for advanced lung adenocarcinoma: A case report
Hu XY, Fei YC, Zhou WC, Zhu JM, Lv DL
- 2634** Anesthetic management of a child with double outlet right ventricle and severe polycythemia: A case report
Tan LC, Zhang WY, Zuo YD, Chen HY, Jiang CL
- 2641** Combined immune checkpoint inhibitors of CTLA4 and PD-1 for hepatic melanoma of unknown primary origin: A case report
Cheng AC, Lin YJ, Chiu SH, Shih YL
- 2649** Cholangiojejunostomy for multiple biliary ducts in living donor liver transplantation: A case report
Xiao F, Sun LY, Wei L, Zeng ZG, Qu W, Liu Y, Zhang HM, Zhu ZJ
- 2655** Surgical therapy for hemangioma of the azygos vein arch under thoracoscopy: A case report
Wang ZX, Yang LL, Xu ZN, Lv PY, Wang Y
- 2662** Calcium pyrophosphate deposition disease of the temporomandibular joint invading the middle cranial fossa: Two case reports
Tang T, Han FG
- 2671** Rare histological subtype of invasive micropapillary carcinoma in the ampulla of Vater: A case report
Noguchi H, Higashi M, Idichi T, Kurahara H, Mataka Y, Tasaki T, Kitazono I, Ohtsuka T, Tanimoto A
- 2679** Contrast-enhanced ultrasound using SonoVue mixed with oral gastrointestinal contrast agent to evaluate esophageal hiatal hernia: Report of three cases and a literature review
Wang JY, Luo Y, Wang WY, Zheng SC, He L, Xie CY, Peng L
- 2688** Melatonin for an obese child with MC4R gene variant showing epilepsy and disordered sleep: A case report
Ge WR, Wan L, Yang G

ABOUT COVER

Editorial Board Member of *World Journal of Clinical Cases*, Hong-Tao Xu, MD, PhD, Chief Physician, Professor, Department of Pathology, The First Affiliated Hospital and College of Basic Medical Sciences of China Medical University, Shenyang 110001, Liaoning Province, China. xuht@cmu.edu.cn

AIMS AND SCOPE

The primary aim of *World Journal of Clinical Cases* (WJCC, *World J Clin Cases*) is to provide scholars and readers from various fields of clinical medicine with a platform to publish high-quality clinical research articles and communicate their research findings online.

WJCC mainly publishes articles reporting research results and findings obtained in the field of clinical medicine and covering a wide range of topics, including case control studies, retrospective cohort studies, retrospective studies, clinical trials studies, observational studies, prospective studies, randomized controlled trials, randomized clinical trials, systematic reviews, meta-analysis, and case reports.

INDEXING/ABSTRACTING

The WJCC is now indexed in Science Citation Index Expanded (also known as SciSearch®), Journal Citation Reports/Science Edition, Scopus, PubMed, and PubMed Central. The 2020 Edition of Journal Citation Reports® cites the 2019 impact factor (IF) for WJCC as 1.013; IF without journal self cites: 0.991; Ranking: 120 among 165 journals in medicine, general and internal; and Quartile category: Q3. The WJCC's CiteScore for 2019 is 0.3 and Scopus CiteScore rank 2019: General Medicine is 394/529.

RESPONSIBLE EDITORS FOR THIS ISSUE

Production Editor: Jia-Hui Li; Production Department Director: Yun-Jie Ma; Editorial Office Director: Jin-Li Wang.

NAME OF JOURNAL

World Journal of Clinical Cases

ISSN

ISSN 2307-8960 (online)

LAUNCH DATE

April 16, 2013

FREQUENCY

Thrice Monthly

EDITORS-IN-CHIEF

Dennis A Bloomfield, Sandro Vento, Bao-Gan Peng

EDITORIAL BOARD MEMBERS

<https://www.wjnet.com/2307-8960/editorialboard.htm>

PUBLICATION DATE

April 16, 2021

COPYRIGHT

© 2021 Baishideng Publishing Group Inc

INSTRUCTIONS TO AUTHORS

<https://www.wjnet.com/bpg/gerinfo/204>

GUIDELINES FOR ETHICS DOCUMENTS

<https://www.wjnet.com/bpg/GerInfo/287>

GUIDELINES FOR NON-NATIVE SPEAKERS OF ENGLISH

<https://www.wjnet.com/bpg/gerinfo/240>

PUBLICATION ETHICS

<https://www.wjnet.com/bpg/GerInfo/288>

PUBLICATION MISCONDUCT

<https://www.wjnet.com/bpg/gerinfo/208>

ARTICLE PROCESSING CHARGE

<https://www.wjnet.com/bpg/gerinfo/242>

STEPS FOR SUBMITTING MANUSCRIPTS

<https://www.wjnet.com/bpg/GerInfo/239>

ONLINE SUBMISSION

<https://www.f6publishing.com>

Gastrointestinal-type chemotherapy prolongs survival in an atypical primary ovarian mucinous carcinoma: A case report

Qi Wang, Xiao-Yan Niu, Hui Feng, Jie Wu, Wen Gao, Zai-Xian Zhang, Yu-Wei Zou, Bi-Yuan Zhang, Hai-Ji Wang

ORCID number: Qi Wang 0000-0001-7155-8878; Xiao-Yan Niu 0000-0003-1332-4103; Hui Feng 0000-0002-7457-4686; Jie Wu 0000-0001-6079-3741; Wen Gao 0000-0001-5137-617X; Zai-Xian Zhang 0000-0003-0308-7802; Yu-Wei Zou 0000-0002-1600-0609; Bi-Yuan Zhang 0000-0003-1738-3856; Hai-Ji Wang 0000-0001-7023-8872.

Author contributions: Wang Q wrote the paper; Wu J, Zou YW, and Gao W performed the pathological tests; Zhang ZX, Niu XY, Feng H, and Zhang BY interpreted the imaging examinations; Wang Q and Wang HJ provided this case.

Supported by Natural Science Foundation of Shandong Province, No. ZR2018BH019.

Informed consent statement: The present study was approved by the Affiliated Hospital of Qingdao University. The specimens of this study were obtained from pathology department of the Affiliated Hospital of Qingdao University. Informed written consent was obtained from the patient for publication of this report and any accompanying images.

Conflict-of-interest statement: The authors declare no conflicts of

Qi Wang, Hui Feng, Wen Gao, Bi-Yuan Zhang, Hai-Ji Wang, Department of Radiation Oncology, The Affiliated Hospital of Qingdao University, Qingdao 266000, Shandong Province, China

Xiao-Yan Niu, Department of Ultrasound, The Affiliated Hospital of Qingdao University, Qingdao 266000, Shandong Province, China

Jie Wu, Yu-Wei Zou, Department of Pathology, The Affiliated Hospital of Qingdao University, Qingdao 266000, Shandong Province, China

Zai-Xian Zhang, Department of Radiology, The Affiliated Hospital of Qingdao University, Qingdao 266000, Shandong Province, China

Corresponding author: Hai-Ji Wang, MD, Doctor, Department of Radiation Oncology, The Affiliated Hospital of Qingdao University, No. 16 Jiangsu Road, Qingdao 266000, Shandong Province, China. whj_qdfy@163.com

Abstract

BACKGROUND

Primary ovarian mucinous carcinoma is a rare histologic subtype of epithelial ovarian carcinoma and exhibits considerable morphologic overlap with secondary tumour. It is hard to differentiate primary from metastatic ovarian mucinous carcinoma by morphological and immunohistochemical features. Because of the histologic similarity between primary ovarian mucinous carcinoma and metastatic gastrointestinal carcinoma, it has been hypothesized that ovarian mucinous carcinomas might respond better to non-gynecologic regimens. However, the standard treatment of advanced ovarian mucinous carcinoma has not reached a consensus.

CASE SUMMARY

A 56-year-old postmenopausal woman presented with repeated pain attacks in the right lower quadrant abdomen, accompanied by diarrhoea, anorexia, and weight loss for about 3 mo. The patient initially misdiagnosed as having gastrointestinal carcinoma because of similar pathological features. Based on the physical examination, tumour markers, imaging tests, and genetic tests, the patient was clinically diagnosed with ovary mucinous adenocarcinoma. Whether gastrointestinal-type chemotherapy or gynecologic chemotherapy was a favourable choice for patients with advanced ovarian mucinous cancer had not been determined. The patient received a chemotherapy regimen based on the

interest.

CARE Checklist (2016) statement:

The authors have read the CARE Checklist (2016), and the manuscript was prepared and revised according to the CARE Checklist (2016).

Open-Access: This article is an open-access article that was selected by an in-house editor and fully peer-reviewed by external reviewers. It is distributed in accordance with the Creative Commons Attribution NonCommercial (CC BY-NC 4.0) license, which permits others to distribute, remix, adapt, build upon this work non-commercially, and license their derivative works on different terms, provided the original work is properly cited and the use is non-commercial. See: <http://creativecommons.org/licenses/by-nc/4.0/>

Manuscript source: Unsolicited manuscript

Specialty type: Medicine, research and experimental

Country/Territory of origin: China

Peer-review report's scientific quality classification

Grade A (Excellent): A
Grade B (Very good): 0
Grade C (Good): C
Grade D (Fair): 0
Grade E (Poor): 0

Received: September 8, 2020

Peer-review started: September 8, 2020

First decision: December 8, 2020

Revised: December 16, 2020

Accepted: February 11, 2021

Article in press: February 11, 2021

Published online: April 16, 2021

P-Reviewer: Cihan YB, Neri V

S-Editor: Gao CC

L-Editor: Wang TQ

P-Editor: Wang LL



histologic characteristics rather than the tumour origin. The patient received nine cycles of FOLFOX and bevacizumab. This was followed by seven cycles of bevacizumab maintenance therapy for 9 mo. Satisfactory therapeutic efficacy was achieved.

CONCLUSION

The genetic analysis might be used in the differential diagnosis of primary ovarian mucinous carcinoma and non-gynecologic mucinous carcinoma. Moreover, primary ovarian mucinous carcinoma patients could benefit from gastrointestinal-type chemotherapy.

Key Words: Ovarian mucinous cancer; Chemotherapy; Pathology; Next-generation sequencing; Case report

©The Author(s) 2021. Published by Baishideng Publishing Group Inc. All rights reserved.

Core Tip: Primary ovarian mucinous carcinoma is a rare histologic subtype of epithelial ovarian carcinoma and exhibits considerable morphologic overlap with secondary tumour. Because of the histologic similarity between primary ovarian mucinous carcinoma and metastatic gastrointestinal carcinoma, it has been hypothesized that ovarian mucinous carcinomas might respond better to non-gynecologic regimens. Here, we report an initially misdiagnosed case of primary ovarian mucinous carcinoma by considering clinical characteristics, imaging, and genetic tests. The patient received a chemotherapy regimen based on the histologic characteristics rather than the tumour origin. This achieved satisfactory therapeutic efficacy.

Citation: Wang Q, Niu XY, Feng H, Wu J, Gao W, Zhang ZX, Zou YW, Zhang BY, Wang HJ. Gastrointestinal-type chemotherapy prolongs survival in an atypical primary ovarian mucinous carcinoma: A case report. *World J Clin Cases* 2021; 9(11): 2533-2541

URL: <https://www.wjgnet.com/2307-8960/full/v9/i11/2533.htm>

DOI: <https://dx.doi.org/10.12998/wjcc.v9.i11.2533>

INTRODUCTION

Primary ovarian mucinous carcinoma is a rare histologic subtype of epithelial ovarian cancer (EOC), only accounting for 2% of new EOC cases^[1]. Unlike other histologic types, it is presented with a low histologic grade and usually diagnosed at an early stage. Nevertheless, advanced stage cases are often associated with a poor prognosis and chemotherapy resistance^[2-5]. Because the morphological features of primary ovarian mucinous carcinoma can be mimicked by gastrointestinal metastases, pathologic diagnosis can particularly be challenging^[6,7]. Histopathologic evaluation of hematoxylin-eosin (HE) staining and immunohistochemical analysis offers few markers with limited value in the differential diagnosis. Because of the histologic similarity between primary ovarian mucinous carcinoma and metastatic gastrointestinal carcinoma, it has been hypothesized that ovarian mucinous carcinomas might respond better to non-gynecologic regimens^[8]. However, the standard chemotherapy regimen for the treatment of advanced ovarian mucinous carcinoma remains unestablished. Herein, we report an initially misdiagnosed case of primary ovarian mucinous carcinoma by considering clinical characteristics, imaging, and genetic tests. The patient received a chemotherapy regimen based on the histologic characteristics rather than the tumour origin. This achieved satisfactory therapeutic efficacy.

CASE PRESENTATION

Chief complaints

A 56-year-old postmenopausal woman visited our hospital with lower abdominal

pain.

History of present illness

The patient presented with repeated pain attacks in the right lower quadrant of the abdomen, accompanied by diarrhea, anorexia, and weight loss for approximately 3 mo. She took diclofenac sodium mucilage 1-2 times daily to relieve the pain, with a pain score ranging from 3 to 4 points.

History of past illness

The patient had hypertension for 3 years. The blood pressure ranged from 120-140/80-100 mmHg after taking nifedipine controlled-release tablets and enalapril. She received laparoscopic cholecystectomy, resection of lateral lobe of the left liver, and choledocholithotomy with exploration because of cholelithiasis. Histologically, there was a large range of related inflammatory epithelial changes including fibrosis, mononuclear infiltrate, and thickening of the muscular layer.

Personal and family history

Menarche occurred at 13 years of age, and menstrual cycles were regular, with bleeding typically occurring every 30 d and lasting for 5-6 d. She married at the age of 25 years and had a son and two daughters. The patient had an occasional drink but did not smoke tobacco or use illicit drugs. Her father had died of liver cancer associated with hepatitis B virus, her mother had died of cerebral hemorrhage, one brother had died of cholangiocarcinoma, and another had died of gastric cancer. Her sister and younger brother were healthy.

Physical examination

On examination, there were several hard and painless masses at the left-sided cervical and supraclavicular regions. The largest mass (measuring 2 cm × 3 cm) was located at the lower neck (level IV). There was tenderness in the right lower quadrant. The liver and spleen were impalpable.

Laboratory examinations

The baseline results of laboratory tests and tumor markers are shown in Tables 1 and 2.

Imaging examinations

The total abdominal and pelvic contrast-enhanced computed tomography (CT) scan at a local hospital indicated enlarged retroperitoneal lymph nodes measuring 1 cm in diameter and a small amount of pelvic free fluid. There were no obvious occupying lesions in the uterus, bilateral adnexa, or iliac blood vessel area.

Further diagnostic work-up

The aspiration biopsy of the cervical lymph nodes under ultrasound guidance showed lowly differentiated mucinous adenocarcinoma. The tumour cells were mainly arranged in an irregular adenoid, cribriform, or strip-shaped pattern with moderate to severe atypia. The nucleus was round or ovoid-shaped and centrally located in the cells. A moderate amount of extracellular mucus was found. The tumour cells were embedded in the collagenized desmoplastic stroma with focal necrosis. Tumour cells expressed CK7, p53, and p16 but not CK20, TTF-1, GATA3, CDX-2, Pax-8, ER, SATB2, NapsinA, and WT-1 (Figure 1). The pathologists suspected metastases from the digestive and biliary tract. They reviewed the patient's pathological specimen from the hepatobiliary operation and found no precancerous lesions or invasive carcinoma. Gastroscopy and colonoscopy also showed no abnormal mass.

The patient refused further medical examination and resorted to traditional Chinese medicine at her discretion for 2 mo. After aggravated symptoms, she visited our hospital again for further evaluation and a general checkup was performed. Gynaecological examination revealed a smooth cervix and a neoplasm of about 0.5 cm in size. The rest of the examination was as previously reported.

Positron emission tomography-computed tomography (PET-CT) showed multiple hypermetabolic foci of the neck, supraclavicular fossa, axilla, pectoralis major deep surface, retroperitoneal area, right adnexal mass, and osteolytic bone destruction of the right 8th rib.

The patient refused the diagnostic operation and CT-guided percutaneous biopsy of the right adnexal occupying lesions. Therefore, the pathological diagnosis was not obtained. However, the biopsy of the cervical neoplasm indicated poorly differentiated

Table 1 Laboratory data

Variable	On presentation	Reference range
Blood routine examination		
White blood cell count	$6.69 \times 10^9/L$	$3.5-9.5 \times 10^9/L$
Neutrophils	$5.33 \times 10^9/L$	$1.8-6.3 \times 10^9/L$
Lymphocytes	$1.02 \times 10^9/L$	$1.1-3.2 \times 10^9/L$
Monocytes	$0.31 \times 10^9/L$	$0.1-0.6 \times 10^9/L$
Eosinophils	$0.01 \times 10^9/L$	$0.02-0.52 \times 10^9/L$
Basophils	$0.02 \times 10^9/L$	$0-0.06 \times 10^9/L$
Hemoglobin	124 g/L	115-150 g/L
Platelet	$161 \times 10^9/L$	$125-350 \times 10^9/L$
Sodium	147 mmol/L	137-147 mmol/L
Potassium	2.9 mmol/L	3.5-5.3 mmol/L
Chloride	105 mmol/L	99-110 mmol/L
Calcium	2.62 mmol/L	2.11-2.52 mmol/L
Albumin	44.9 g/L	20-55 g/L
Aspartate aminotransferase	23 U/L	13-35 U/L
Alanine aminotransferase	17 U/L	7-40 U/L
Bilirubin	18.91 $\mu\text{mol/L}$	3-22 $\mu\text{mol/L}$
Creatinine	81 $\mu\text{mol/L}$	31-132 $\mu\text{mol/L}$
Urea nitrogen	3.12 mmol/L	2.6-7.5 mmol/L
Cystatin c	0.88 mg/L	0.10-0.45 mg/L

Table 2 Tumor markers

Variable	Reference range	First visit	Second hospitalisation	Third hospitalisation	Forth hospitalisation	Last dose of chemotherapy
CEA (ng/mL)	0-3.4	44.04	28.69	17.18	5.67	3.21
CA242 (IU/mL)	0-15	18.08	14.45	10.81	7.85	8.52
CA19-9 (U/mL)	0-39	100.8	60.81	33.83	18.39	16.70
AFP (ng/mL)	0-7.02	9.03	8.09	7.16	6.15	6.75
CA15-3 (U/mL)	0-25	30.37	22.58	20.13	15.84	14.70
CA125 (U/mL)	0-35	137.4	40.68	21.11	11.66	12.10
HE4 (pmol/L)	< 140	105.7	72.3	70.1	64.4	50.7

CEA: Carcinoembryonic antigen; CA: Carbohydrate antigen; HE4: Human epididymis protein 4.

adenocarcinoma. The pathologists compared the morphological characteristics between the tumour cells of the cervical lymph nodes and cervical neoplasm and concluded that the two metastases were from the same origin. The morphology of the tumour cells in cervical biopsy was similar to some extent to that of the lymph node in the neck but it was much richer in the papillary arrangement, especially the extracellular mucus, and was diagnosed as mucinous adenocarcinoma. The intracellular mucus was more visible and the columnar mucinous epithelium was more abundant than those in the neck lesion were. After combining the medical history and immunohistochemical results, the biliary tract and the ovary were the two

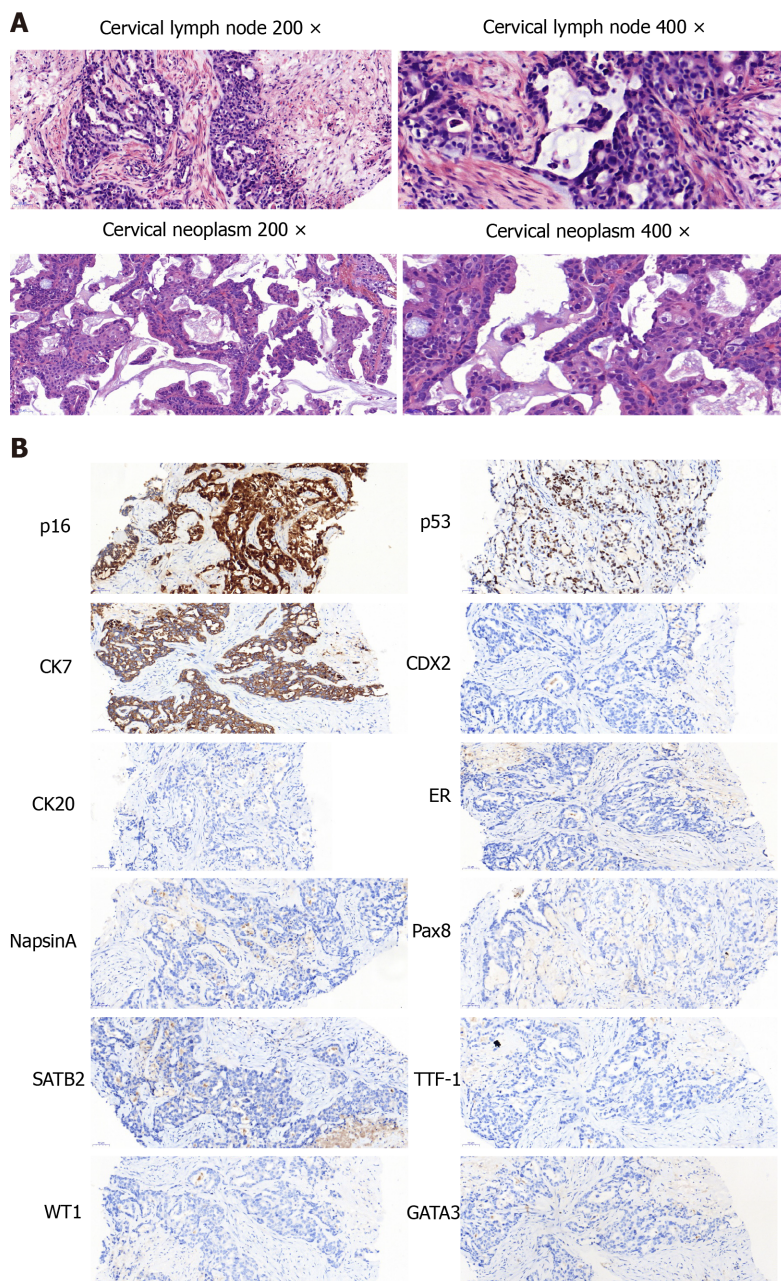


Figure 1 Pathological examination. A and B: Cervical lymph node (A) and cervical neoplasm (B).

most likely sources.

The genetic tests of the metastatic lymph node, cervical neoplasm, and blood revealed a *BRCA2* exon 20 truncating mutation and epithelial cell adhesion molecule (*EPCAM*) exon 7 frameshift mutation (Table 3). Based on the physical examination, tumour markers, imaging tests, and genetic tests, the patient was clinically diagnosed with ovary mucinous adenocarcinoma.

FINAL DIAGNOSIS

Based on the physical examination, tumor markers, imaging tests, and genetic tests, the patient was clinically diagnosed with ovarian mucinous adenocarcinoma.

TREATMENT

The patient received nine cycles of FOLFOX and bevacizumab (oxaliplatin: 100

Table 3 Mutation profiling by next-generation sequencing

Gene	Variation	Mutation	Cervical lymph node	Cervical neoplasm	Peripheral Blood
Tumor-specific mutation					
<i>CCNE1</i>	Gene amplification		-	3.1-fold	-
<i>DLL3</i>	Gene amplification		-	3.2-fold	-
<i>KRAS</i>	Gene amplification		5.2-fold	9.8-fold	-
<i>PTK2</i>	Gene amplification		-	2.2-fold	-
<i>RB1</i>	Splice site mutation	c.1421+29_1498+69del	8.5%	52.0%	0.4%
<i>STK11</i>	Single copy deletion		-	Single copy deletion	-
<i>VHL</i>	Single copy deletion		-	Single copy deletion	-
<i>DDR2</i>	Truncation mutation	c.1646C>G(p.S549 [*])	10.4%	20.8%	0.8%
<i>EPHA3</i>	Missense mutation	c.2515G>A(p.E839K)	-	1.1%	-
<i>ETV6</i>	Missense mutation	c.369G>C(p.Q123H)	14.0%	23.5%	0.9%
<i>GNAS</i>	Missense mutation	c.1984G>A(p.E662K)	13.4%	-	0.6%
<i>TAP1</i>	Missense mutation	c.149C>T(p.P50L)	2.0%	-	-
<i>TP53</i>	Splice site mutation	c.376-1G>A	18.2%	69.9%	0.8%
<i>TP53</i>	Single copy deletion	-	-	Single copy deletion	-
Germline mutation		Mutation			
<i>BRCA2</i>	Truncation mutation	c.8629G>T(p.E2877 [*])			
<i>EPCAM</i>	Frameshift mutation	c.843delT(p.G282Efs [*] 21)			

mg/m², calcium levofofinate, 5-fluorouracil bolus 400 mg/m², 5-fluorouracil 46h, 2400-3000 mg/m², bevacizumab 5 mg/kg, q2w). This was followed by seven cycles of bevacizumab maintenance therapy for 9 mo.

OUTCOME AND FOLLOW-UP

Imaging tests were performed after every three cycles of chemotherapy to evaluate the therapeutic effect. CT indicated continuous shrinkage of the lymphatic metastases without evidence of new metastatic disease (Figure 2). Before the treatment, evaluation of the tumor markers showed noticeable levels of carcinoembryonic antigen (CEA), carbohydrate antigen 19-9 (CA19-9), CA125, and CA242 (Table 2). After four cycles of chemotherapy, all the tumor markers decreased to normal ranges.

DISCUSSION

Primary ovarian mucinous carcinoma accounts for 1%-2% of all primary ovarian carcinomas^[1]. Unlike other histologic types, mucinous carcinomas usually have a low histologic grade, present at an early stage, and are associated with a favourable outcome. However, primary ovarian mucinous carcinoma should be distinguished from metastatic tumours to the ovary. Gastrointestinal, breast, and endometrial origins are the most common, and all exhibit considerable morphologic overlap. Histopathologic evaluation of the HE staining and immunohistochemical analysis is usually problematic in identifying and distinguishing primary ovarian mucinous carcinoma and metastatic carcinoma^[7].

In the present case, it was difficult to achieve a precise diagnosis. First, both the gastrointestinal and ovarian tumour markers were elevated. Serum CEA, CA19-9, and CA242 levels are most frequently elevated in patients with pancreatic and gastrointestinal tract tumours. Serum CA125 is a tumour marker derived from tethered mucin, MUC16, and is usually associated with serous and endometrioid tumours.

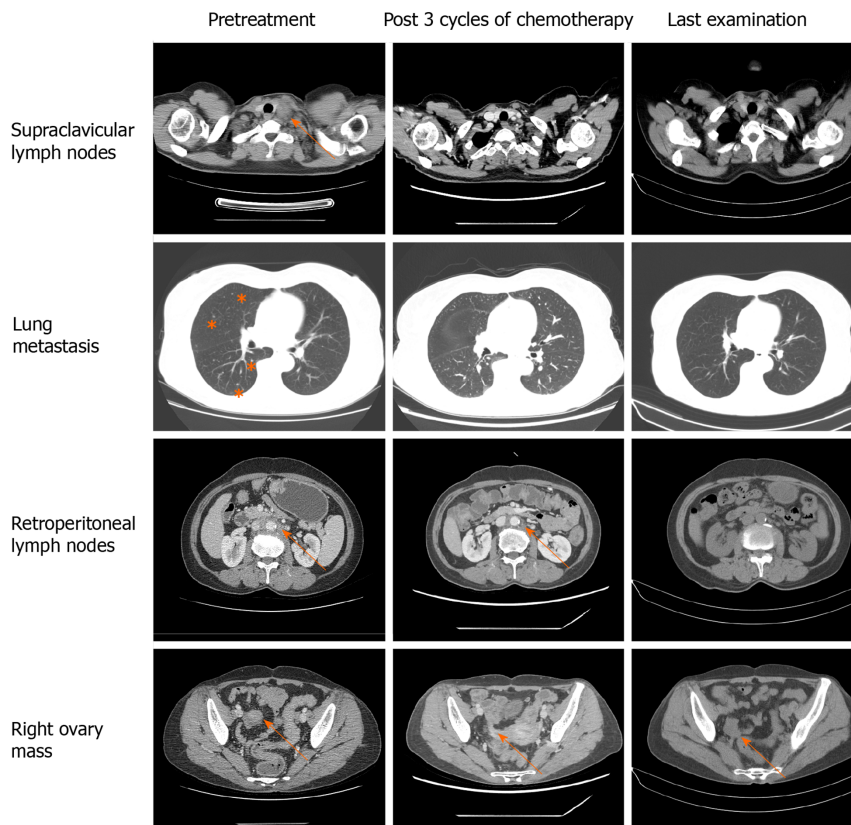


Figure 2 Computed tomography, axial view. Arrows indicate metastatic lesions and the right ovary mass. Computed tomography indicated continuous shrinkage of the tumour.

Second, the right adnexal occupying lesion was relatively small. Unilateral ovarian tumours of more than 10 cm in the greatest dimension are most likely to be ovarian in origin, whereas bilateral, smaller ovarian masses are more likely to be metastatic^[9]. The characteristics of metastases are also inconsistent with primary ovarian cancer. The metastatic spread of ovarian cancer is characterized by ascites and widespread peritoneal implantation. However, our case mainly showed multiple salutatory lymph node metastases.

Finally, although the immunohistochemical profile was consistent with a typical profile of ovarian mucinous carcinoma^[10], it was hard to differentiate metastatic carcinoma and ovarian cancer by the morphological features. After combining the medical history and immunohistochemical results, the biliary tract and the ovary were the two most likely sources. Because CK7, p16, and p53 may be positive in both potential sources, immunohistochemical indicators are not reliable. Ovarian mucinous adenocarcinoma is rare and often gastrointestinal-epithelium like. In our case, the morphologies in both lesions lacked the typical characteristics of gastrointestinal epithelium features such as nuclear spindling or goblet-shaped like epithelial cells. Stromal sclerosis is one of the characteristics of biliary epithelial carcinoma. The lesion in the neck lymph node was very similar to stromal sclerosis not only in cellular morphology but also in heavy stroma fibrosis.

The most expedient way to establish the diagnosis would be to perform diagnostic laparotomy with an intraoperative frozen section examination. However, the patient refused the diagnostic operation and CT-guided percutaneous biopsy of the right adnexal occupying lesions. The patient was diagnosed with ovarian mucinous carcinoma based on the following reasons. Although the tumour-marker profile favored the diagnosis of biliary and gastrointestinal carcinoma, the PET-CT and gastroendoscopy showed no abnormal mass. Next, genetic tests revealed *BRCA2* exon 20 truncating mutation (p.E2877), which has been identified as the mutation for hereditary breast, ovarian, and other related cancers in the ClinVar website (<https://www.ncbi.nlm.nih.gov/clinvar/>). The relationship between *EPCAM* mutation and carcinogenesis has not been previously reported in the literature. Based on the Cancer Genome Atlas, mutations of this gene are common in melanoma, ovarian cancer, leiomyosarcoma, and cholangiocarcinoma.

Because of the histologic similarity between primary ovarian mucinous carcinoma and metastatic gastrointestinal carcinoma, it has been hypothesized that ovarian mucinous carcinomas might respond better to non-gynecologic regimens. GOG-241, a randomized controlled trial, was designed to compare the gastrointestinal regimen to standard gynecologic regimen among ovarian mucinous carcinoma patients^[11]. However, the trial was closed prematurely because of low recruitment rates. Nonetheless, more than half of the enrolled patients so far were diagnosed with non-gynecologic mucinous carcinoma after the central review by pathologists. Kurnit *et al.*^[12] conducted a retrospective study to estimate whether gastrointestinal-type chemotherapy was associated with improved survival compared with standard gynecologic regimens for ovarian mucinous carcinoma patients. They found that gastrointestinal-type chemotherapy with or without bevacizumab improved survival in patients with ovarian mucinous carcinoma requiring adjuvant therapy. However, the vast majority of patients were at an early stage and receiving surgery. Whether gastrointestinal-type chemotherapy or gynecologic chemotherapy is a favourable choice for patients with advanced ovarian mucinous cancer has not been determined. Our patient received FOLFOX + bevacizumab as the first-line chemotherapy regimen. Interestingly, partial remission was achieved after three cycles of chemotherapy, which was maintained for approximately 1 year.

We report an initially misdiagnosed case of primary ovarian mucinous carcinoma by considering clinical characteristics, imaging, and genetic tests. The patient received chemotherapy regimen based on the histologic characteristics rather than the tumour origin, achieving satisfactory therapeutic efficacy. However, further studies should focus on genetic analysis in the differential diagnosis of primary ovarian mucinous carcinoma and non-gynecologic mucinous carcinoma. Because of the rarity of this tumour, there are no standard criteria for the guidelines for treatment. In the future, standard treatments should be explored through randomized controlled trial or retrospective studies.

CONCLUSION

Genetic analysis might be used in the differential diagnosis of primary ovarian mucinous carcinoma and non-gynecologic mucinous carcinoma. Moreover, primary ovarian mucinous carcinoma patients could benefit from gastrointestinal-type chemotherapy.

REFERENCES

- 1 **Zaino RJ**, Brady MF, Lele SM, Michael H, Greer B, Bookman MA. Advanced stage mucinous adenocarcinoma of the ovary is both rare and highly lethal: a Gynecologic Oncology Group study. *Cancer* 2011; **117**: 554-562 [PMID: 20862744 DOI: 10.1002/cnecr.25460]
- 2 **Karabuk E**, Kose MF, Hizli D, Taşkin S, Karadağ B, Turan T, Boran N, Ozfuttu A, Ortaç UF. Comparison of advanced stage mucinous epithelial ovarian cancer and serous epithelial ovarian cancer with regard to chemosensitivity and survival outcome: a matched case-control study. *J Gynecol Oncol* 2013; **24**: 160-166 [PMID: 23653834 DOI: 10.3802/jgo.2013.24.2.160]
- 3 **Chung YS**, Park SY, Lee JY, Park JY, Lee JW, Kim HS, Suh DS, Kim YH, Lee JM, Kim M, Choi MC, Shim SH, Lee KH, Song T, Hong JH, Lee WM, Lee B, Lee IH. Outcomes of non-high grade serous carcinoma after neoadjuvant chemotherapy for advanced-stage ovarian cancer: a Korean gynecologic oncology group study (OV 1708). *BMC Cancer* 2019; **19**: 341 [PMID: 30971221 DOI: 10.1186/s12885-019-5514-7]
- 4 **Simons M**, Ezendam N, Bulten J, Nagtegaal I, Massuger L. Survival of Patients With Mucinous Ovarian Carcinoma and Ovarian Metastases: A Population-Based Cancer Registry Study. *Int J Gynecol Cancer* 2015; **25**: 1208-1215 [PMID: 25978291 DOI: 10.1097/IGC.0000000000000473]
- 5 **Firat Cuyulan Z**, Karabuk E, Oz M, Turan AT, Meydanli MM, Taskin S, Sari ME, Sahin H, Ulukent SC, Akbayir O, Gungorduk K, Gungor T, Kose MF, Ayhan A. Comparison of stage III mucinous and serous ovarian cancer: a case-control study. *J Ovarian Res* 2018; **11**: 91 [PMID: 30376858 DOI: 10.1186/s13048-018-0464-2]
- 6 **Rioped MA**, Ronnett BM, Kurman RJ. Evaluation of diagnostic criteria and behavior of ovarian intestinal-type mucinous tumors: atypical proliferative (borderline) tumors and intraepithelial, microinvasive, invasive, and metastatic carcinomas. *Am J Surg Pathol* 1999; **23**: 617-635 [PMID: 10366144 DOI: 10.1097/00000478-199906000-00001]
- 7 **Köbel M**, Rahimi K, Rambau PF, Naugler C, Le Page C, Meunier L, de Ladurantaye M, Lee S, Leung S, Goode EL, Ramus SJ, Carlson JW, Li X, Ewanowich CA, Kelemen LE, Vanderhyden B, Provencher D, Huntsman D, Lee CH, Gilks CB, Mes Masson AM. An Immunohistochemical

- Algorithm for Ovarian Carcinoma Typing. *Int J Gynecol Pathol* 2016; **35**: 430-441 [PMID: 26974996 DOI: 10.1097/PGP.0000000000000274]
- 8 **Frumovitz M**, Schmeler KM, Malpica A, Sood AK, Gershenson DM. Unmasking the complexities of mucinous ovarian carcinoma. *Gynecol Oncol* 2010; **117**: 491-496 [PMID: 20332054 DOI: 10.1016/j.ygyno.2010.02.010]
 - 9 **Khunamornpong S**, Suprasert P, Pojchamarnwiputh S, Na Chiangmai W, Settakorn J, Siriaunkgul S. Primary and metastatic mucinous adenocarcinomas of the ovary: Evaluation of the diagnostic approach using tumor size and laterality. *Gynecol Oncol* 2006; **101**: 152-157 [PMID: 16300822 DOI: 10.1016/j.ygyno.2005.10.008]
 - 10 **Bassiouny D**, Ismiil N, Dubé V, Han G, Cesari M, Lu FI, Slodkowska E, Parra-Herran C, Chiu HF, Naeim M, Li N, Khalifa M, Nofech-Mozes S. Comprehensive Clinicopathologic and Updated Immunohistochemical Characterization of Primary Ovarian Mucinous Carcinoma. *Int J Surg Pathol* 2018; **26**: 306-317 [PMID: 29338553 DOI: 10.1177/1066896917752861]
 - 11 **Gore M**, Hackshaw A, Brady WE, Penson RT, Zaino R, McCluggage WG, Ganesan R, Wilkinson N, Perren T, Montes A, Summers J, Lord R, Dark G, Rustin G, Mackean M, Reed N, Kehoe S, Frumovitz M, Christensen H, Feeney A, Ledermann J, Gershenson DM. An international, phase III randomized trial in patients with mucinous epithelial ovarian cancer (mEOC/GOG 0241) with long-term follow-up: and experience of conducting a clinical trial in a rare gynecological tumor. *Gynecol Oncol* 2019; **153**: 541-548 [PMID: 31005287 DOI: 10.1016/j.ygyno.2019.03.256]
 - 12 **Kurnit KC**, Sinno AK, Fellman BM, Varghese A, Stone R, Sood AK, Gershenson DM, Schmeler KM, Malpica A, Fader AN, Frumovitz M. Effects of Gastrointestinal-Type Chemotherapy in Women With Ovarian Mucinous Carcinoma. *Obstet Gynecol* 2019; **134**: 1253-1259 [PMID: 31764736 DOI: 10.1097/AOG.0000000000003579]



Published by **Baishideng Publishing Group Inc**
7041 Koll Center Parkway, Suite 160, Pleasanton, CA 94566, USA

Telephone: +1-925-3991568

E-mail: bpgoffice@wjgnet.com

Help Desk: <https://www.f6publishing.com/helpdesk>

<https://www.wjgnet.com>

