

国内版 国际版

Radiological and Clinical Spectrum of Novel Coronavirus (COVID-19



ALL IMAGES VIDEOS

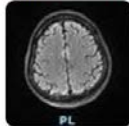
69,700 Results

Any time ▾

Open links in new tab ☒

Cureus | Clinical, Radiological, and Molecular Findings of ...

<https://www.cureus.com/articles/42276-clinical...>



We report a case of **encephalitis** in a young male patient with severe coronavirus disease 2019 (COVID-19) who initially presented with typical symptoms of **fever**, **dry cough**, and **shortness of breath** but later on developed **acute respiratory...**

Cited by: 1

Author: Saud Bin Abdul Sattar, Muha...

Publish Year: 2020

Coronavirus Disease 2019 (COVID-19): A Perspective from ...

<https://pubs.rsna.org/doi/full/10.1148/radiol.2020200490>

< Introduction Etiology Epidemiology Clinical Symptom Spectrum >

An ongoing outbreak of pneumonia associated with a **novel coronavirus**, called severe acute **respiratory syndrome coronavirus 2** (SARS-CoV-2), was reported in Wuhan, Hubei province, China (1-3) in December 2019. In the following weeks, infections spread across China and other countries around the world (4-6). The Chinese public health, clinical, and scientific communities took prompt response to allow for timely recognition of the new virus and shared the viral gene s...

[See more on pubs.rsna.org](#)

Cited by: 690

Author: Zi Yue Zu, Meng Di Jiang, Peng Peng...

Publish Year: 2020

COVID-19-A Novel Zoonotic Disease: A Review of the ...

<https://pubmed.ncbi.nlm.nih.gov/32475144>

The virus was named SARS-CoV-2 by the International Committee for the Taxonomy of Viruses,

Name of Journal: *World Journal of Radiology*

Manuscript NO: 60547

Manuscript Type: MINIREVIEWS

Radiological and clinical spectrum of COVID-19: A major concern for public health

Radiological Spectrum of Novel Coronavirus 2019

Abstract

The pandemic of novel coronavirus disease 2019 (COVID-19) is an infectious disease caused by +ve strand RNA virus (SARS-CoV-2) that belongs to the corona viridae family. In March, the WHO declared the outbreak of novel coronavirus for the public health emergency. Although SARS-CoV-2 infection presents with respiratory symptoms, it affects other organs such as the kidneys, liver, heart and brain. Early-stage laboratory disease testing shows many false positive or negative outcomes such as less white blood cell (WBC) count and a low number

Match Overview

1	Crossref 35 words Rachel J Gravell, Mark D Theodoreson, Danilo Buonsens o, John Curtis. "Radiological manifestations of COVID-19 ...	1%
2	Crossref 30 words N. Stoganinos, D. Fotopoulos, N. Woznitza, C. Malamateni ou. "Coronavirus disease 2019 (COVID-19) in the radiologic ...	1%
3	Crossref 21 words Marina Carotti, Fausto Salaffi, Piercarlo Sarzi-Puttini, Andr ea Agostini et al. "Chest CT features of coronavirus disea ...	1%
4	Internet 20 words crawled on 22-Dec-2020 export.arxiv.org	1%
5	Internet 18 words crawled on 06-Jan-2021 www.fda.gov	1%
6	Crossref 18 words Paolo Simoni, Alberto Bazzocchi, Grammatina Boitsios, Ale ssandro De Leucio, Marco Preziosi, Maria Pilar Aparisi Gó	1%
7	Crossref 18 words Yashwant Kumar Ratre, Niamrata Kahar, L. V. K. S. Bhaska r, Antanipa Bhattacharya, Henu Kumar Verma. "Molecular	1%
8	Internet 15 words crawled on 29-Oct-2020 stemcells.journals.onlinelibrary.wiley.com	<1%

国内版 国际版

Radiological and clinical spectrum of COVID-19: A major concern fo



ALL IMAGES VIDEOS

2,530,000 Results Any time ▾

Coronavirus Disease 2019 (COVID-19): A Perspective from ...
<https://pubs.rsna.org/doi/full/10.1148/radiol.2020200490>

Se
Tur

< y Epidemiology **Clinical Symptom Spectrum** Diagnosis of Covid-19 | >

Understanding the clinical symptoms of COVID-19 is important, although the clinical symptoms are indicated nonspecific. Common symptoms include fever, cough and myalgia or fatigue. Patients may initially present with diarrhea and nausea a few days prior to fever, suggesting fever is dominant but not the premier symptom of infection. A small number of patients can have headache or hemoptysis (26,32) and even relatively asymptomatic (12). Affected older men with comorbidities are more likely to have re...

[See more on pubs.rsna.org](#)

Cited by: 728 Author: Zi Yue Zu, Meng Di Jiang, Peng Peng Xu,...
Publish Year: 2020

Clinical presentations, laboratory and radiological ...
<https://www.nature.com/articles/s41598-020-74988-9>

Nov 13, 2020 · More global reports are crucially needed to give a better picture of the spectrum of presentations among all COVID-19 infected persons. Also, public health ...

[PDF] Coronavirus Disease 2019 (COVID-19): A Perspective ...
<https://pubs.rsna.org/doi/pdf/10.1148/radiol.2020200490>

navirus disease 2019 (COVID-19) will help detect the infection early and assess the disease course. Essentials n Coronavirus disease 2019 (COVID-19) has nonspecific clinical manifestations at presentation, so diagnosis depends on epidemiologic factors including exposure related to Wuhan, China, or close contact with a patient with confirmed COVID-19.

COVID-19-A Novel Zoonotic Disease: A Review of the ...
<https://pubmed.ncbi.nlm.nih.gov/32475144>

The virus was named SARS-CoV-2 by the International Committee for the Taxonomy of Viruses, and the disease it causes was named COVID-19 by the World Health Organization. This article described the evolution of the outbreak, and the known properties of the novel virus, SARS-CoV-2 and the clinical disease it causes, and the major public health ...

Cited by: 2 Author: John S. Mackenzie, John S. Mackenzie, ...
Publish Year: 2020