

World Journal of *Clinical Cases*

World J Clin Cases 2021 August 6; 9(22): 6178-6581



Contents

Thrice Monthly Volume 9 Number 22 August 6, 2021

REVIEW

- 6178** COVID-19 infection and liver injury: Clinical features, biomarkers, potential mechanisms, treatment, and management challenges

Sivandzadeh GR, Askari H, Safarpour AR, Ejtehad F, Raeis-Abdollahi E, Vaez Lari A, Abazari MF, Tarkesh F, Bagheri Lankarani K

- 6201** Gastrointestinal manifestations of systemic sclerosis: An updated review

Luquez-Mindiola A, Atuesta AJ, Gómez-Aldana AJ

MINIREVIEWS

- 6218** Mesenchymal stem cell-derived exosomes: An emerging therapeutic strategy for normal and chronic wound healing

Zeng QL, Liu DW

- 6234** Role of autophagy in cholangiocarcinoma: Pathophysiology and implications for therapy

Ninfolle E, Pinto C, Benedetti A, Marziani M, Maroni L

ORIGINAL ARTICLE

Case Control Study

- 6244** Risk factors for intussusception in children with Henoch-Schönlein purpura: A case-control study

Zhao Q, Yang Y, He SW, Wang XT, Liu C

Retrospective Study

- 6254** Sequential therapy with combined trans-papillary endoscopic naso-pancreatic and endoscopic retrograde pancreatic drainage for pancreatic pseudocysts

He YG, Li J, Peng XH, Wu J, Xie MX, Tang YC, Zheng L, Huang XB

- 6268** Retrospective study of effect of whole-body vibration training on balance and walking function in stroke patients

Xie L, Yi SX, Peng QF, Liu P, Jiang H

- 6278** Risk factors for preoperative carcinogenesis of bile duct cysts in adults

Wu X, Li BL, Zheng CJ, He XD

- 6287** Diagnostic and prognostic value of secreted protein acidic and rich in cysteine in the diffuse large B-cell lymphoma

Pan PJ, Liu JX

- 6300** Jumbo cup in hip joint renovation may cause the center of rotation to increase

Peng YW, Shen JM, Zhang YC, Sun JY, Du YQ, Zhou YG

Clinical Trials Study

- 6308** Effect of exercise training on left ventricular remodeling in patients with myocardial infarction and possible mechanisms
Cai M, Wang L, Ren YL

Observational Study

- 6319** Analysis of sleep characteristics and clinical outcomes of 139 adult patients with infective endocarditis after surgery
Hu XM, Lin CD, Huang DY, Li XM, Lu F, Wei WT, Yu ZH, Liao HS, Huang F, Huang XZ, Jia FJ
- 6329** Health-related risky behaviors and their risk factors in adolescents with high-functioning autism
Sun YJ, Xu LZ, Ma ZH, Yang YL, Yin TN, Gong XY, Gao ZL, Liu YL, Liu J
- 6343** Selection of internal fixation method for femoral intertrochanteric fractures using a finite element method
Mu JX, Xiang SY, Ma QY, Gu HL

META-ANALYSIS

- 6357** Neoadjuvant chemotherapy for patients with resectable colorectal cancer liver metastases: A systematic review and meta-analysis
Zhang Y, Ge L, Weng J, Tuo WY, Liu B, Ma SX, Yang KH, Cai H

CASE REPORT

- 6380** Ruptured intracranial aneurysm presenting as cerebral circulation insufficiency: A case report
Zhao L, Zhao SQ, Tang XP
- 6388** Prostatic carcinosarcoma seven years after radical prostatectomy and hormonal therapy for prostatic adenocarcinoma: A case report
Huang X, Cai SL, Xie LP
- 6393** Pyogenic arthritis, pyoderma gangrenosum, and acne syndrome in a Chinese family: A case report and review of literature
Lu LY, Tang XY, Luo GJ, Tang MJ, Liu Y, Yu XJ
- 6403** Malaria-associated secondary hemophagocytic lympho-histiocytosis: A case report
Zhou X, Duan ML
- 6410** Ileal hemorrhagic infarction after carotid artery stenting: A case report and review of the literature
Xu XY, Shen W, Li G, Wang XF, Xu Y
- 6418** Inflammatory myofibroblastic tumor of the pancreatic neck: A case report and review of literature
Chen ZT, Lin YX, Li MX, Zhang T, Wan DL, Lin SZ
- 6428** Management of heterotopic cesarean scar pregnancy with preservation of intrauterine pregnancy: A case report
Chen ZY, Zhou Y, Qian Y, Luo JM, Huang XF, Zhang XM

- 6435** Manifestation of severe pneumonia in anti-PL-7 antisynthetase syndrome and B cell lymphoma: A case report
Xu XL, Zhang RH, Wang YH, Zhou JY
- 6443** Disseminated infection by *Fusarium solani* in acute lymphocytic leukemia: A case report
Yao YF, Feng J, Liu J, Chen CF, Yu B, Hu XP
- 6450** Primary hepatic neuroendocrine tumor – ¹⁸F-fluorodeoxyglucose positron emission tomography/computed tomography findings: A case report
Rao YY, Zhang HJ, Wang XJ, Li MF
- 6457** Malignant peripheral nerve sheath tumor in an elderly patient with superficial spreading melanoma: A case report
Yang CM, Li JM, Wang R, Lu LG
- 6464** False positive anti-hepatitis A virus immunoglobulin M in autoimmune hepatitis/primary biliary cholangitis overlap syndrome: A case report
Yan J, He YS, Song Y, Chen XY, Liu HB, Rao CY
- 6469** Successful totally laparoscopic right trihepatectomy following conversion therapy for hepatocellular carcinoma: A case report
Zhang JJ, Wang ZX, Niu JX, Zhang M, An N, Li PF, Zheng WH
- 6478** Primary small cell esophageal carcinoma, chemotherapy sequential immunotherapy: A case report
Wu YH, Zhang K, Chen HG, Wu WB, Li XJ, Zhang J
- 6485** Subdural fluid collection rather than meningitis contributes to hydrocephalus after cervical laminoplasty: A case report
Huang HH, Cheng ZH, Ding BZ, Zhao J, Zhao CQ
- 6493** Phlegmonous gastritis developed during chemotherapy for acute lymphocytic leukemia: A case report
Saito M, Morioka M, Izumiyama K, Mori A, Ogasawara R, Kondo T, Miyajima T, Yokoyama E, Tanikawa S
- 6501** Spinal epidural hematoma after spinal manipulation therapy: Report of three cases and a literature review
Liu H, Zhang T, Qu T, Yang CW, Li SK
- 6510** Abdominal hemorrhage after peritoneal dialysis catheter insertion: A rare cause of luteal rupture: A case report
Gan LW, Li QC, Yu ZL, Zhang LL, Liu Q, Li Y, Ou ST
- 6515** Concealed mesenteric ischemia after total knee arthroplasty: A case report
Zhang SY, He BJ, Xu HH, Xiao MM, Zhang JJ, Tong PJ, Mao Q
- 6522** Chylothorax following posterior low lumbar fusion surgery: A case report
Huang XM, Luo M, Ran LY, You XH, Wu DW, Huang SS, Gong Q
- 6531** Non-immune hydrops fetalis: Two case reports
Maranto M, Cigna V, Orlandi E, Cucinella G, Lo Verso C, Duca V, Picciotto F

- 6538** Bystander effect and abscopal effect in recurrent thymic carcinoma treated with carbon-ion radiation therapy: A case report
Zhang YS, Zhang YH, Li XJ, Hu TC, Chen WZ, Pan X, Chai HY, Ye YC
- 6544** Management of an intracranial hypotension patient with diplopia as the primary symptom: A case report
Wei TT, Huang H, Chen G, He FF
- 6552** Spontaneous rupture of adrenal myelolipoma as a cause of acute flank pain: A case report
Kim DS, Lee JW, Lee SH
- 6557** Neonatal necrotizing enterocolitis caused by umbilical arterial catheter-associated abdominal aortic embolism: A case report
Huang X, Hu YL, Zhao Y, Chen Q, Li YX
- 6566** Primary mucosa-associated lymphoid tissue lymphoma in the midbrain: A case report
Zhao YR, Hu RH, Wu R, Xu JK
- 6575** Extensive cutaneous metastasis of recurrent gastric cancer: A case report
Chen JW, Zheng LZ, Xu DH, Lin W

ABOUT COVER

Editorial Board Member of *World Journal of Clinical Cases*, Salma Ahi, MD, Assistant Professor, Research Center for Noncommunicable Diseases, Jahrom University of Medical Sciences, Jahrom 193, Iran. salmaahi.61@gmail.com

AIMS AND SCOPE

The primary aim of *World Journal of Clinical Cases* (WJCC, *World J Clin Cases*) is to provide scholars and readers from various fields of clinical medicine with a platform to publish high-quality clinical research articles and communicate their research findings online.

WJCC mainly publishes articles reporting research results and findings obtained in the field of clinical medicine and covering a wide range of topics, including case control studies, retrospective cohort studies, retrospective studies, clinical trials studies, observational studies, prospective studies, randomized controlled trials, randomized clinical trials, systematic reviews, meta-analysis, and case reports.

INDEXING/ABSTRACTING

The WJCC is now indexed in Science Citation Index Expanded (also known as SciSearch®), Journal Citation Reports/Science Edition, Scopus, PubMed, and PubMed Central. The 2021 Edition of Journal Citation Reports® cites the 2020 impact factor (IF) for WJCC as 1.337; IF without journal self cites: 1.301; 5-year IF: 1.742; Journal Citation Indicator: 0.33; Ranking: 119 among 169 journals in medicine, general and internal; and Quartile category: Q3. The WJCC's CiteScore for 2020 is 0.8 and Scopus CiteScore rank 2020: General Medicine is 493/793.

RESPONSIBLE EDITORS FOR THIS ISSUE

Production Editor: Yan-Xia Xing; **Production Department Director:** Yun-Jie Ma; **Editorial Office Director:** Jin-Lei Wang.

NAME OF JOURNAL

World Journal of Clinical Cases

ISSN

ISSN 2307-8960 (online)

LAUNCH DATE

April 16, 2013

FREQUENCY

Thrice Monthly

EDITORS-IN-CHIEF

Dennis A Bloomfield, Sandro Vento, Bao-Gan Peng

EDITORIAL BOARD MEMBERS

<https://www.wjgnet.com/2307-8960/editorialboard.htm>

PUBLICATION DATE

August 6, 2021

COPYRIGHT

© 2021 Baishideng Publishing Group Inc

INSTRUCTIONS TO AUTHORS

<https://www.wjgnet.com/bpg/gerinfo/204>

GUIDELINES FOR ETHICS DOCUMENTS

<https://www.wjgnet.com/bpg/GerInfo/287>

GUIDELINES FOR NON-NATIVE SPEAKERS OF ENGLISH

<https://www.wjgnet.com/bpg/gerinfo/240>

PUBLICATION ETHICS

<https://www.wjgnet.com/bpg/GerInfo/288>

PUBLICATION MISCONDUCT

<https://www.wjgnet.com/bpg/gerinfo/208>

ARTICLE PROCESSING CHARGE

<https://www.wjgnet.com/bpg/gerinfo/242>

STEPS FOR SUBMITTING MANUSCRIPTS

<https://www.wjgnet.com/bpg/GerInfo/239>

ONLINE SUBMISSION

<https://www.f6publishing.com>

Pyogenic arthritis, pyoderma gangrenosum, and acne syndrome in a Chinese family: A case report and review of literature

Ling-Yun Lu, Xue-Yang Tang, Guo-Jing Luo, Meng-Jia Tang, Yi Liu, Xi-Jie Yu

ORCID number: Ling-Yun Lu 0000-0003-3629-1420; Xue-Yang Tang 0000-0002-3465-4534; Guo-Jing Luo 0000-0002-9298-2544; Meng-Jia Tang 0000-0002-6437-8112; Yi Liu 0000-0003-3511-3841; Xi-Jie Yu 0000-0002-3504-7664.

Author contributions: Lu LY, Tang XY and Luo GJ reviewed the literature and analyzed the examinations; Lu LY and Tang XY contributed to manuscript drafting; Tang MJ was responsible for the patient follow-up; Yu XJ and Liu Y were responsible for the revision of the manuscript; all authors issued final approval for the version to be submitted.

Supported by the National Natural Science Foundation of China, No. 81770875; the Post-Doctor Research Project, West China Hospital, Sichuan University, No. 19HXBH053; the Health and Family Planning Commission of Sichuan Province, No. 19PJ096; and the 1.3.5 Project for Disciplines of Excellence, West China Hospital, Sichuan University, No. 2020HFXH008 and No. ZYJC18003.

Informed consent statement:

Informed written consent was obtained from the patient for publication of this report and any accompanying images.

Conflict-of-interest statement:

The

Ling-Yun Lu, Meng-Jia Tang, Xi-Jie Yu, Department of Endocrinology, Laboratory of Endocrinology and Metabolism, West China Hospital, Sichuan University, Chengdu 610041, Sichuan Province, China

Ling-Yun Lu, Department of Integrated Traditional Chinese and Western Medicine, West China Hospital, Sichuan University, Chengdu 610041, Sichuan Province, China

Xue-Yang Tang, Department of Pediatric Surgery, West China Hospital, Sichuan University, Chengdu 610041, Sichuan Province, China

Guo-Jing Luo, Department of Endocrinology, Zhuhai People's Hospital, Zhuhai Hospital Affiliated with Jinan University, Zhuhai 519000, Guangdong Province, China

Yi Liu, Department of Rheumatology and Immunology, Rare Disease Center, West China Hospital, Sichuan University, Chengdu 610041, Sichuan Province, China

Corresponding author: Xi-Jie Yu, MD, PhD, Professor, Department of Endocrinology, Laboratory of Endocrinology and Metabolism, West China Hospital, Sichuan University, No. 37 Guoxue Xiang, Chengdu 610041, Sichuan Province, China. xijieyu@hotmail.com

Abstract

BACKGROUND

Pyogenic arthritis, pyoderma gangrenosum, and acne (PAPA) syndrome is a rare autosomal dominant genetic disease characterized by severe autoimmune inflammation, caused by mutations in the *PSTPIP1* gene. Due to PAPA heterogeneous clinical manifestation, misdiagnosis or delayed diagnoses are difficult to avoid. With the use of whole-exome sequencing, we identified a missense mutation in the *PSTPIP1* gene in a Chinese family. To the best of our knowledge, this is the first case of PAPA reported in China.

CASE SUMMARY

A 9-year-old boy suffered from recurrent aseptic pyogenic arthritis triggered by minor trauma or few obvious predisposing causes for more than 3 years. Pyogenic arthritis occurred every 3-5 mo, affecting his knees, elbows, and ankle joints. Treatments, such as glucocorticoids, antibiotics, even surgeries could alleviate joints pain and swelling to some extent but could not inhibit the recurrence of arthritis. Similar symptoms were present in his younger brother but not in his parents. According to the whole-exome sequencing, a missense mutation in exon 11 of the *PSTPIP1* gene (c.748G>C; p.E250Q) was detected in the boy, his young-er

authors declare that they have no conflicts of interest.

CARE Checklist (2016) statement:

The authors have read the CARE Checklist (2016), and the manuscript was prepared and revised according to the CARE Checklist (2016).

Open-Access: This article is an open-access article that was selected by an in-house editor and fully peer-reviewed by external reviewers. It is distributed in accordance with the Creative Commons Attribution NonCommercial (CC BY-NC 4.0) license, which permits others to distribute, remix, adapt, build upon this work non-commercially, and license their derivative works on different terms, provided the original work is properly cited and the use is non-commercial. See: <http://creativecommons.org/licenses/by-nc/4.0/>

Manuscript source: Unsolicited manuscript

Specialty type: Immunology

Country/Territory of origin: China

Peer-review report's scientific quality classification

Grade A (Excellent): A
Grade B (Very good): B
Grade C (Good): 0
Grade D (Fair): 0
Grade E (Poor): 0

Received: January 20, 2021

Peer-review started: January 20, 2021

First decision: March 25, 2021

Revised: April 7, 2021

Accepted: May 8, 2021

Article in press: May 8, 2021

Published online: August 6, 2021

P-Reviewer: Lambrecht NW

S-Editor: Zhang H

L-Editor: Filipodia

P-Editor: Liu JH



brother and his father. Taking into account the similar phenotypic features with PAPA syndrome reported previously, we confirmed a diagnosis of PAPA syndrome for the family.

CONCLUSION

In this case, a missense mutation (c.748G>C; p.E250Q) in *PSTPIP1* gene was identified in a Chinese family with PAPA syndrome. Previous studies emphasize the fact that PAPA syndrome is hard to diagnose just through the clinical manifestations owing to its heterogeneous expression. Genetic testing is an effectual auxiliary diagnostic method, especially in the early stages of pyogenic arthritis. Only if we have a deep understanding and rich experience of this rare disease can we make a prompt diagnosis, develop the best clinical treatment plan, and give good fertility guidance.

Key Words: Pyogenic arthritis, pyoderma gangrenosum, and acne syndrome; *PSTPIP1*; Autoinflammatory disease; Rare disease; Case report

©The Author(s) 2021. Published by Baishideng Publishing Group Inc. All rights reserved.

Core Tip: Pyogenic arthritis, pyoderma gangrenosum, and acne (PAPA) syndrome (OMIM 604416) is a rare autosomal dominant genetic disease characterized by severe autoimmune inflammation. Herein, we reported a case of a Chinese boy diagnosed with PAPA syndrome due to an E250Q mutation in the *PSTPIP1* gene and summarized the clinical characteristics, potential mechanisms, and relatively effective treatments from previous literature in order to provide some useful information for a comprehensive understanding of this rare disease.

Citation: Lu LY, Tang XY, Luo GJ, Tang MJ, Liu Y, Yu XJ. Pyogenic arthritis, pyoderma gangrenosum, and acne syndrome in a Chinese family: A case report and review of literature. *World J Clin Cases* 2021; 9(22): 6393-6402

URL: <https://www.wjgnet.com/2307-8960/full/v9/i22/6393.htm>

DOI: <https://dx.doi.org/10.12998/wjcc.v9.i22.6393>

INTRODUCTION

Pyogenic arthritis, pyoderma gangrenosum, and acne (PAPA) syndrome (OMIM 604416) is a rare autosomal dominant genetic disease characterized by severe autoimmune inflammation and was named in 1997[1]. The main symptoms of PAPA are recurrent episodes of aseptic pyogenic arthritis before puberty and skin lesions, such as severe cystic acne and refractory aseptic ulcers or even pyoderma gangrenosum during or after puberty[2]. So far, 14 familial and 18 sporadic cases with the disease have been reported worldwide, and none of them were from China. Herein, we report a case of Chinese brothers with PAPA and review previous case reports to gain a further understanding of the disease.

CASE PRESENTATION

Chief complaints

A 9-year-old boy who suffered from recurrent aseptic pyogenic arthritis triggered by minor trauma or few obvious predisposing causes for more than 3 years.

History of present illness

At the age of six, the patient developed pain in his right knee joint after a fall, which lasted for 5 d without remission. He was admitted to our hospital for further treatment. His right knee was markedly swollen with movement limitation. A large number of neutrophils and red blood cells were found through joint cavity paracentesis. However, repeated bacterial cultures of synovial fluid were negative.

Inflammatory indices, such as serum C-reactive protein, erythrocyte sedimentation rate, and procalcitonin, increased significantly. Immune-related examinations, such as antistreptolysin O, anti-neutrophil cytoplasmic antibodies, human leukocyte antigen-B27, and anticardiolipin antibodies, were normal. The incision and drainage of the abscess was performed. With a 20-d treatment of anti-infection and joint cavity irrigation after the surgery, the symptoms were relieved. However, the arthritis flared up again about 6 mo later. Over the next 2 years, pyogenic arthritis occurred every 3-5 mo, affecting his knees, elbows, and ankle joints.

History of past illness

The patient had a nonspecific previous medical history.

Personal and family history

Similar symptoms were present in his younger brother but not his parents. As his father recalled, his grandfather might also have similar symptoms (Figure 1A).

Physical examination

On physical examination, body temperature was 36.2 °C; pulse rate was 112 beats per min; respiration rate was 22 breaths per min; and blood pressure was 107/75 mmHg (1 mmHg = 0.133 kPa). Vital signs were stable. The right knee joint was swollen and deformed, and two 10 cm incision scars were visible. The skin temperature of the right side was higher than that of the left, with marked tenderness and without obvious fluctuation feeling. The knee movement was limited; the flexion was limited to 40°, and the intorsion and extorsion were slightly limited. The floating patellar test was negative.

Laboratory examinations

Routine test results for complete blood count, liver and kidney function, and electrolytes were normal. Serum C-reactive protein, erythrocyte sedimentation rate, and procalcitonin were increased significantly. Serum interleukin (IL)-1, IL-6, or tumor necrosis factor (TNF)- α levels were elevated. Serum inflammatory factors of the recent examination are shown in Table 1.

Whole-exome sequencing

Whole-exome sequencing of the proband was performed and the mutations were further analyzed in DNA samples from his relatives (Joy Orient Translational Medicine Research Center Co., Ltd. Beijing, China). This revealed that heterozygosity for a glutamic acid-to-glutamine substitution at amino acid position 748 (p.Glu250Gln or E250Q) encoded by exon 11 of the *PSTPIP1* gene (Figure 1B). Both brothers and their father showed a missense mutation of the *PSTPIP1* gene, which was autosomal-dominant, but their father did not show clinical symptoms.

FINAL DIAGNOSIS

PAPA syndrome.

TREATMENT

The patient received tocilizumab (12 mg/kg intravenously) every 4 wk for about 6 mo. After that, adalimumab was given (20 mg subcutaneously) every 2 wk successively.

OUTCOME AND FOLLOW-UP

Considering the significant increase in serum IL-6, tocilizumab, the humanized anti-IL-6 receptor monoclonal antibody, was given in August 2018. The symptoms were quickly relieved within 1 wk but recurred after 6 mo, and the drug did not work well from then on. In November 2019, tocilizumab, the humanized anti-TNF- α monoclonal antibody, was applied, and the symptoms were controlled for 6 mo before relapse. In the recent episode, the rapid relief was achieved by intra-articular triamcinolone hexacetone. Cutaneous symptoms have not yet appeared. Due to the limited afford-

Table 1 Levels of serum inflammatory factors in the recent episode of the two brothers

Laboratory indexes	III-1	III-2
IL-1 β (0-5.00 pg/mL)	444	344
IL-6 (0-5.90 pg/mL)	> 1000	774
IL-8 (0-62.00 pg/mL)	> 7500	4072
IL-10 (0-9.10 pg/mL)	< 5.00	< 5.00
TNF- α (0-8.10 pg/mL)	54.50	42.20

IL: Interleukin; TNF: Tumor necrosis factor.

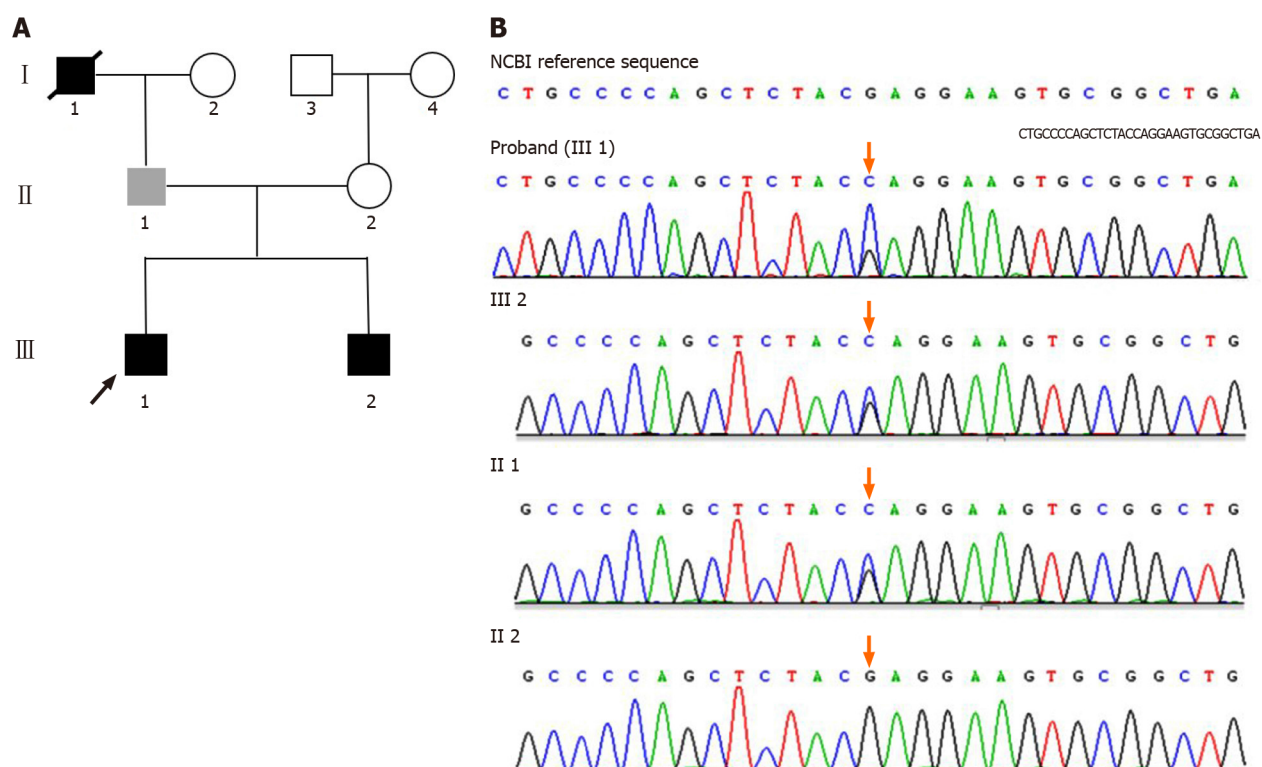


Figure 1 Pedigree of the PAPA family and genetic analysis. A: Family tree of an autosomal dominant hyponatremia pedigree. Square represents male and circle represents female. Arrow denotes the proband (III-1), black symbols represent the affected individuals (III-1 and III-2). The grey symbol refers to the individual that has the gene mutation without symptoms (II-1). The symbol with diagonal slashes denotes the deceased individual who had the similar symptoms (I-1); B: A missense mutation p.748 G>C (p.E250Q) in *PSTPIP1* was found in proband (III-1), III-2, and II-1.

ability of the family, cost-effective therapies will be tried in the future.

DISCUSSION

Clinical characteristics

PAPA is a rare immunoinflammatory rather than immunodeficiency disease. The main symptoms are pyogenic arthritis, acne, and gangrenous pyoderma. To our knowledge, there have been 30 case reports worldwide, including 14 familial and 18 sporadic cases, since the first case was reported in 1997[1]. The clinical symptoms of PAPA vary from person to person, probably due to the different mutation sites of *PSTPIP1* and the unknown interaction between *PSTPIP1* and other immune-related proteins[3,4]. The triad manifestations are rarely synchronized. Only 19 patients suffered from three typical symptoms simultaneously in our summary (Figure 2A).

Acute recurrent sterile pyogenic arthritis is usually the earliest manifestation, which appears before puberty generally, even in infancy[1,5-9] (Figure 2B). Each flare up affects one to three joints and mainly occurs in knee joints, elbow joints, ankle joints,

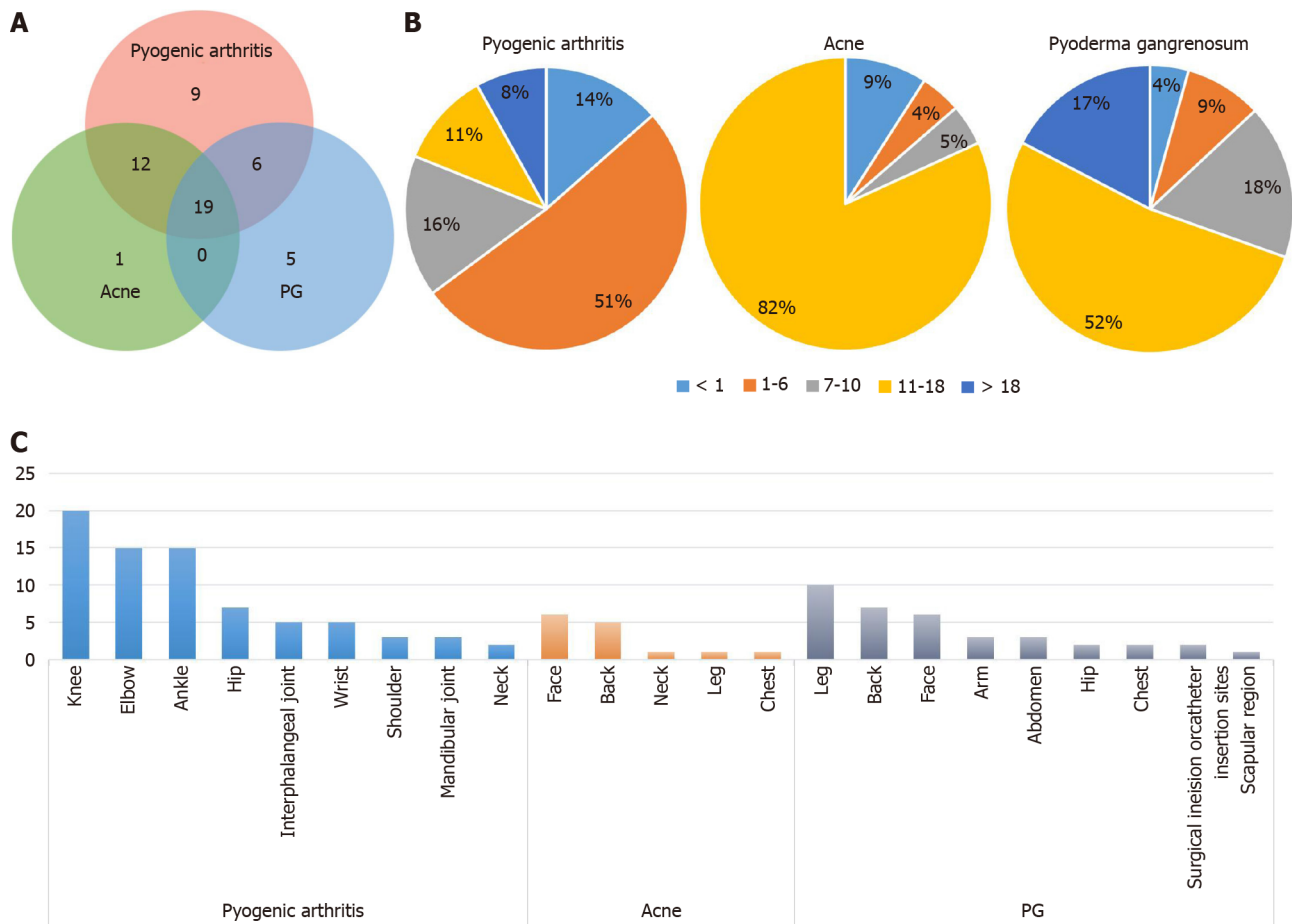


Figure 2 Characteristics of clinical manifestations in pyogenic arthritis, pyoderma gangrenosum, and acne syndrome (data were collected from 52 cases who had detailed description of symptoms). A: The Venn diagram for the three typical symptoms. Each circle represents a symptom, the area of coincidence represents cases with two or three symptoms; B: The sector diagram for the age of each symptom onset. Pyogenic arthritis always appears in childhood. Skin lesions are more likely to appear from adolescence to adulthood; C: The histogram for the affecting areas of each symptom. Arthritis mainly affects occurs in knee joints, elbow joints, ankle joints, hip joints, and other large joints. Acne always appears on the face and back. Pyogenic granuloma often occurs on the extremities and the back.

hip joints, and other large joints (Figure 2C). The recurrent inflammatory joint episodes lead to an accumulation of neutrophil-rich purulence in the articular cavities and result in the destruction of the synovial membrane, cartilage, and even bone[10]. Diffuse joint space narrowing and osteophyte formation in conjunction with subchondral sclerosis, cyst formation, and bone destruction can be demonstrated from imaging[1,7,11].

The main skin manifestations in PAPA include severe cystic acne and recurrent pyogenic granuloma. Most patients suffer from nodulocystic acne, which commonly occurs in the head, chest, and back[12-15] (Figure 2C). Pyogenic granuloma is a sterile neutrophilic disorder with painful skin lesions, erythematous pustules, bullae, or nodules, enlarging from the center to the periphery[8,12,13,15-21]. It mainly occurs in the limbs, face, abdomen, and back (Figure 2C). Skin manifestations frequently appear from puberty to adulthood, while joint symptoms are likely to be alleviated (Figure 2B). Although our patients only suffer from pyogenic arthritis at present, the possibility that cutaneous symptoms develop gradually with age cannot be ruled out.

PAPA patients often have a state of high inflammatory response. Laboratory tests usually show systemic inflammation with elevated serum IL-1, IL-6, or TNF- α levels. Our cases show similar changes (Table 1).

Mechanism

The exact mechanisms of PAPA syndrome remain to be elucidated. In 2000, Yeon *et al* [22] initiated a genetic linkage analysis in the original family and mapped the loci between D15S1023 and D15S979 in chromosome 15q according to highly polymorphic loci. Wise *et al*[23] reported another family with PAPA-like clinical manifestations, which were initially named familial recurrent arthritis. The symptoms of the family

members were early onset, including episodic inflammation in joints with an accumulation of sterile pyogenic joint fluid and skin lesions[23]. According to the comparison of clinical expressions and the results of a genome-wide linkage scan, Wise *et al*[23] concluded that familial recurrent arthritis and PAPA syndrome were likely the same disorder.

Yeast two-hybrid interaction trap assays revealed that two dominantly inherited missense mutations, A230T and E250Q, in the proline-serine-threonine phosphatase-interacting protein 1 [*PSTPIP1*, or CD2-binding protein 1 (*CD2BP1*)] gene were the pathogenesis[24]. *PSTPIP1* encodes an adaptor protein in coupling membrane deformation to cytoskeletal reorganization and participates in modulating T cell and phagocyte activation as well as proinflammatory cytokine release[24-27]. It was confirmed that pyrin binds to *PSTPIP1* through both immunoprecipitation and fluorescence microscopy[2]. The PAPA syndrome-associated A230T and E250Q mutations interfere with the binding of PEST-type protein tyrosine phosphatase (PTP-PTP) to *PSTPIP1*, leading to the hyperphosphorylation of *PSTPIP1*, which have a higher affinity for pyrin than non-mutated forms[2]. A high level of pyrin-*PSTPIP1* binding can raise the pyrin domain of apoptosis associated speck-like protein containing a caspase-recruitment domain (ASC) pyroptosome assembly, leading to procaspase-1 recruitment[2,28,29]. Pyrin, ASC, and procaspase-1 assemble an inflammasome, resulting in ASC oligomerization and caspase-1 activation[28]. Caspase-1 cracks the inactive pro-IL-1 β molecular kinase into the active subtype IL-1 β . Excess IL-1 β promotes the production and release of chemokines, tissue damage effector molecules, and classical pro-inflammatory cytokines, triggering neutrophil-mediated inflammatory responses[30,31]. IL-1 β and its downstream cytokines, IL-6 and IL-12 p70, were increased in the mice with *PSTPIP1* gene mutations and patients with PAPA episodes, and probably amplified the inflammatory cascade[2]. Therefore, the mutations predispose one to an IL-1 β -dependent inflammatory reaction dominated by granulocytes and monocytes. As a result, patients develop recurrent episodes of neutrophilic infiltrative inflammatory disease[24,32]. It is also known that *PSTPIP1* may have complex interactions with immune proteins (WASP, FASL, and CD3) and regulate a pivotal effect on podosome formation and extracellular matrix degradation [4,33]. This might be the reason for the heterogeneous phenotype and diverse treatment response of PAPA syndrome. Over the last 20 years, ten mutations in *PSTPIP1* have been demonstrated in PAPA (Figure 3A). A230T, E250Q, and E250K are the three most common missense mutations.

Treatment

A standard treatment strategy has not been established for PAPA syndrome owing to its rarity, variable gene mutations, and heterogeneous manifestations. The therapeutic approach remains challenging and individualized due to unclear mechanisms, poor responses to systemic glucocorticosteroid[8,18,19], the high risks of opportunistic infections with immunosuppressive therapy[5,13,18], the high cost, and the limited access to biologics[21]. Fifteen drugs showed a good efficacy, including corticosteroids, azathioprine, sulfasalazine, leflunomide, TNF- α inhibitors, and IL-1 β antagonist (Figure 3). The effective drugs are summarized based on their different gene mutation sites (Figure 3B). No matter what the mutation site is, intra-articular glucocorticoid is an effective alternative for acute arthritis episode[7,12]. As PAPA syndrome is closely related to the inflammasome and the production of IL-1 β , anakinra and the monoclonal antibody (canakinumab) are proven to be effective in controlling flare ups in many cases[3,5,11,19,20,34,35]. TNF- α is a downstream target of the IL-1 β signaling pathway. Therefore, the treatment of PAPA with TNF- α monoclonal antibodies (infliximab and adalimumab) has shown promising efficacy[5,6,18,36]. Our patients were treated with adalimumab for 6 mo, and their joint symptoms were alleviated quickly. However, the relief only lasted for several months, and the arthritis recurred. Responses to adalimumab are associated with many factors, such as genetic factors, inflammatory states, and medical histories. TNF- α gene polymorphisms were proven as a genetic factor of response to adalimumab in patients with rheumatoid arthritis in a pharmacogenetic study[37]. Patients with the TNF- α locus haplotype (-238G/-308G/-857C) in a homozygous form had lower responses to adalimumab[37]. In adalimumab treatment for psoriatic arthritis, men with lower joint function damage and no systemic glucocorticoid therapy were more likely to achieve therapeutic effects[38]. Additionally, it was found that there was a relationship between the inflammatory factor levels and the efficacy of infliximab, another anti-tumor necrosis factor agent. A lower serum IL-6 level might predict a better early response to anti-TNF therapy[39]. The unsustainable clinical remission provided by adalimumab is probably due to our patients' long-term states of high inflammation blunting the drug effects. TNF- α gene

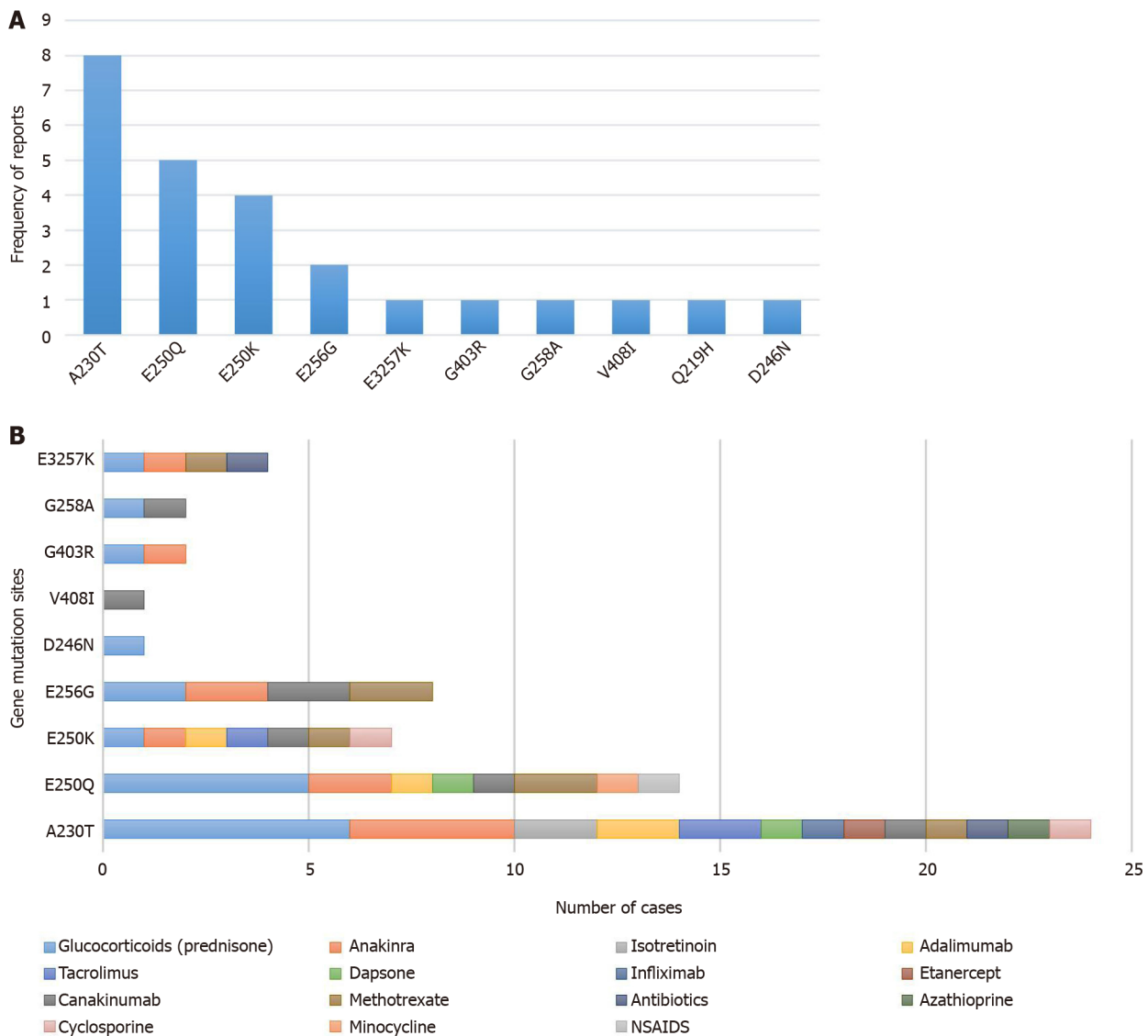


Figure 3 Type of gene mutation and relationship between gene mutation sites and effective drugs. A: Types of gene mutation. Ten gene mutations of pyogenic arthritis, pyoderma gangrenosum, and acne have been reported worldwide. A230T, E250Q, and E250K are the most common mutations; B: Fifteen drugs with a good efficacy were found, including corticosteroids, azathioprine, sulfasalazine, leflunomide, tumor necrosis factor- α inhibitors, interleukin-1 β antagonist, etc. This figure summarizes effective drugs based on their gene mutation sites.

polymorphisms might be another factor in the poor response to adalimumab, but further tests are required.

For chronic diseases, cost-effectiveness is an important factor. Biological agents with a high cost are not the optimal choice for personal affordability, while an inexpensive and effective drug may be more suitable. Sardana *et al*[21] applied a combination of minocycline, dapsone, deflazacort, and methotrexate for a classic case of PAPA syndrome along with arthritis and a worsening painful ulceration of the face, back, and legs. The sustained disease remission was observed with the complete healing of ulcers, the amelioration of arthritis, and the clearance of acne without any obvious side events during a 2-year follow-up. The treatment seemed to be safe and have a cost-effective advantage.

CONCLUSION

As far as we know, this is the first report of PAPA syndrome in China. This and previous studies emphasize the fact that PAPA syndrome is not easily diagnosed through its clinical manifestations owing to its heterogeneous expressions. Genetic testing is an effectual auxiliary diagnostic method, especially in the early stages of pyogenic arthritis. Just like our patients, they are probably diagnosed as having

juvenile idiopathic arthritis rather than PAPA without genetic testing. We speculate that there may be a lot of patients with PAPA in China who are ignored and misdiagnosed due to our insufficient understanding of the disease. Only if we have a deep understanding and rich experience of this rare disease can we make a prompt diagnosis, develop the best clinical treatment plan, and give good fertility guidance.

REFERENCES

- 1 **Lindor NM**, Arsenault TM, Solomon H, Seidman CE, McEvoy MT. A new autosomal dominant disorder of pyogenic sterile arthritis, pyoderma gangrenosum, and acne: PAPA syndrome. *Mayo Clin Proc* 1997; **72**: 611-615 [PMID: [9212761](#) DOI: [10.1016/S0025-6196\(11\)63565-9](#)]
- 2 **Shoham NG**, Centola M, Mansfield E, Hull KM, Wood G, Wise CA, Kastner DL. Pyrin binds the PSTPIP1/CD2BP1 protein, defining familial Mediterranean fever and PAPA syndrome as disorders in the same pathway. *Proc Natl Acad Sci USA* 2003; **100**: 13501-13506 [PMID: [14595024](#) DOI: [10.1073/pnas.2135380100](#)]
- 3 **Schellevis MA**, Stoffels M, Hoppenreijns EP, Bodar E, Simon A, van der Meer JW. Variable expression and treatment of PAPA syndrome. *Ann Rheum Dis* 2011; **70**: 1168-1170 [PMID: [21325428](#) DOI: [10.1136/ard.2009.126185](#)]
- 4 **Starnes TW**, Bennin DA, Bing X, Eickhoff JC, Grahf DC, Bellak JM, Seroogy CM, Ferguson PJ, Huttenlocher A. The F-BAR protein PSTPIP1 controls extracellular matrix degradation and filopodia formation in macrophages. *Blood* 2014; **123**: 2703-2714 [PMID: [24421327](#) DOI: [10.1182/blood-2013-07-516948](#)]
- 5 **Demidowich AP**, Freeman AF, Kuhns DB, Aksentijevich I, Gallin JI, Turner ML, Kastner DL, Holland SM. Brief report: genotype, phenotype, and clinical course in five patients with PAPA syndrome (pyogenic sterile arthritis, pyoderma gangrenosum, and acne). *Arthritis Rheum* 2012; **64**: 2022-2027 [PMID: [22161697](#) DOI: [10.1002/art.34332](#)]
- 6 **Lee H**, Park SH, Kim SK, Choe JY, Park JS. Pyogenic arthritis, pyoderma gangrenosum, and acne syndrome (PAPA syndrome) with E250K mutation in CD2BP1 gene treated with the tumor necrosis factor inhibitor adalimumab. *Clin Exp Rheumatol* 2012; **30**: 452 [PMID: [22513199](#)]
- 7 **Tallon B**, Corkill M. Peculiarities of PAPA syndrome. *Rheumatology (Oxford)* 2006; **45**: 1140-1143 [PMID: [16527883](#) DOI: [10.1093/rheumatology/kei178](#)]
- 8 **Tofteland ND**, Shaver TS. Clinical efficacy of etanercept for treatment of PAPA syndrome. *J Clin Rheumatol* 2010; **16**: 244-245 [PMID: [20661073](#) DOI: [10.1097/RHU.0b013e3181e969b9](#)]
- 9 **Fathalla BM**, Al-Wahadneh AM, Al-Mutawa M, Kambouris M, El-Shanti H. A novel de novo PSTPIP1 mutation in a boy with pyogenic arthritis, pyoderma gangrenosum, acne (PAPA) syndrome. *Clin Exp Rheumatol* 2014; **32**: 956-958 [PMID: [24960411](#)]
- 10 **Martinez-Rios C**, Jariwala MP, Highmore K, Duffy KW, Spiegel L, Laxer RM, Stimec J. Imaging findings of sterile pyogenic arthritis, pyoderma gangrenosum and acne (PAPA) syndrome: differential diagnosis and review of the literature. *Pediatr Radiol* 2019; **49**: 23-36 [PMID: [30225645](#) DOI: [10.1007/s00247-018-4246-1](#)]
- 11 **Caorsi R**, Picco P, Buoncompagni A, Martini A, Gattorno M. Osteolytic lesion in PAPA syndrome responding to anti-interleukin 1 treatment. *J Rheumatol* 2014; **41**: 2333-2334 [PMID: [25362725](#) DOI: [10.3899/jrheum.140060](#)]
- 12 **Hong JB**, Su YN, Chiu HC. Pyogenic arthritis, pyoderma gangrenosum, and acne syndrome (PAPA syndrome): report of a sporadic case without an identifiable mutation in the CD2BP1 gene. *J Am Acad Dermatol* 2009; **61**: 533-535 [PMID: [19700023](#) DOI: [10.1016/j.jaad.2008.11.017](#)]
- 13 **Geusau A**, Mothes-Luksch N, Nahavandi H, Pickl WF, Wise CA, Pourpak Z, Ponweiser E, Eckhart L, Sunder-Plassmann R. Identification of a homozygous PSTPIP1 mutation in a patient with a PAPA-like syndrome responding to canakinumab treatment. *JAMA Dermatol* 2013; **149**: 209-215 [PMID: [23426477](#) DOI: [10.1001/2013.jamadermatol.717](#)]
- 14 **Park BM**, Yun SJ, Lee SC, Lee JB. A sporadic case of pyogenic arthritis, pyoderma gangrenosum and acne syndrome without an identifiable mutation. *Clin Exp Dermatol* 2014; **39**: 73-75 [PMID: [23692517](#) DOI: [10.1111/ced.12154](#)]
- 15 **Zeeli T**, Padalon-Brauch G, Ellenbogen E, Gat A, Sarig O, Sprecher E. Pyoderma gangrenosum, acne and ulcerative colitis in a patient with a novel mutation in the PSTPIP1 gene. *Clin Exp Dermatol* 2015; **40**: 367-372 [PMID: [25683018](#) DOI: [10.1111/ced.12585](#)]
- 16 **Kechichian E**, Haber R, Mourad N, El Khoury R, Jabbour S, Tomb R. Pediatric pyoderma gangrenosum: a systematic review and update. *Int J Dermatol* 2017; **56**: 486-495 [PMID: [28233293](#) DOI: [10.1111/ijd.13584](#)]
- 17 **Edrees AF**, Kaplan DL, Abdou NI. Pyogenic arthritis, pyoderma gangrenosum, and acne syndrome (PAPA syndrome) associated with hypogammaglobulinemia and elevated serum tumor necrosis factor-alpha levels. *J Clin Rheumatol* 2002; **8**: 273-275 [PMID: [17041385](#) DOI: [10.1097/00124743-200210000-00009](#)]
- 18 **Stichweh DS**, Punaro M, Pascual V. Dramatic improvement of pyoderma gangrenosum with infliximab in a patient with PAPA syndrome. *Pediatr Dermatol* 2005; **22**: 262-265 [PMID: [15916580](#) DOI: [10.1111/j.1525-1470.2005.22320.x](#)]
- 19 **Brenner M**, Ruzicka T, Plewig G, Thomas P, Herzer P. Targeted treatment of pyoderma

- gangrenosum in PAPA (pyogenic arthritis, pyoderma gangrenosum and acne) syndrome with the recombinant human interleukin-1 receptor antagonist anakinra. *Br J Dermatol* 2009; **161**: 1199-1201 [PMID: 19673875 DOI: 10.1111/j.1365-2133.2009.09404.x]
- 20 **Omenetti A**, Carta S, Caorsi R, Finetti M, Marotto D, Lattanzi B, Jorini M, Delfino L, Penco F, Picco P, Buoncompagni A, Martini A, Rubartelli A, Gattorno M. Disease activity accounts for long-term efficacy of IL-1 blockers in pyogenic sterile arthritis pyoderma gangrenosum and severe acne syndrome. *Rheumatology (Oxford)* 2016; **55**: 1325-1335 [PMID: 26989109 DOI: 10.1093/rheumatology/kew031]
 - 21 **Sardana K**, Bajaj S, Bose SK. Successful treatment of PAPA syndrome with minocycline, dapsone, deflazacort and methotrexate: a cost-effective therapy with a 2-year follow-up. *Clin Exp Dermatol* 2019; **44**: 577-579 [PMID: 30259545 DOI: 10.1111/ced.13792]
 - 22 **Yeon HB**, Lindor NM, Seidman JG, Seidman CE. Pyogenic arthritis, pyoderma gangrenosum, and acne syndrome maps to chromosome 15q. *Am J Hum Genet* 2000; **66**: 1443-1448 [PMID: 10729114 DOI: 10.1086/302866]
 - 23 **Wise CA**, Bennett LB, Pascual V, Gillum JD, Bowcock AM. Localization of a gene for familial recurrent arthritis. *Arthritis Rheum* 2000; **43**: 2041-2045 [PMID: 11014354 DOI: 10.1002/1529-0131(200009)43:9<2041::AID-ANR15>3.0.CO;2-G]
 - 24 **Wise CA**, Gillum JD, Seidman CE, Lindor NM, Veile R, Bashardes S, Lovett M. Mutations in CD2BP1 disrupt binding to PTP PEST and are responsible for PAPA syndrome, an autoinflammatory disorder. *Hum Mol Genet* 2002; **11**: 961-969 [PMID: 11971877 DOI: 10.1093/hmg/11.8.961]
 - 25 **Wang D**, Höing S, Patterson HC, Ahmad UM, Rathinam VA, Rajewsky K, Fitzgerald KA, Golenbock DT. Inflammation in mice ectopically expressing human Pyogenic Arthritis, Pyoderma Gangrenosum, and Acne (PAPA) Syndrome-associated PSTPIP1 A230T mutant proteins. *J Biol Chem* 2013; **288**: 4594-4601 [PMID: 23293022 DOI: 10.1074/jbc.M112.443077]
 - 26 **Yang H**, Reinherz EL. CD2BP1 modulates CD2-dependent T cell activation via linkage to protein tyrosine phosphatase (PTP)-PEST. *J Immunol* 2006; **176**: 5898-5907 [PMID: 16670297 DOI: 10.4049/jimmunol.176.10.5898]
 - 27 **Yu JW**, Wu J, Zhang Z, Datta P, Ibrahim I, Taniguchi S, Sagara J, Fernandes-Alnemri T, Alnemri ES. Cryopyrin and pyrin activate caspase-1, but not NF-kappaB, via ASC oligomerization. *Cell Death Differ* 2006; **13**: 236-249 [PMID: 16037825 DOI: 10.1038/sj.cdd.4401734]
 - 28 **Yu JW**, Fernandes-Alnemri T, Datta P, Wu J, Juliana C, Solorzano L, McCormick M, Zhang Z, Alnemri ES. Pyrin activates the ASC pyroptosome in response to engagement by autoinflammatory PSTPIP1 mutants. *Mol Cell* 2007; **28**: 214-227 [PMID: 17964261 DOI: 10.1016/j.molcel.2007.08.029]
 - 29 **Campbell L**, Raheem I, Malesud CJ, Askari AD. The Relationship between NALP3 and Autoinflammatory Syndromes. *Int J Mol Sci* 2016; **17** [PMID: 27187378 DOI: 10.3390/ijms17050725]
 - 30 **Mankan AK**, Dau T, Jenne D, Hornung V. The NLRP3/ASC/Caspase-1 axis regulates IL-1 β processing in neutrophils. *Eur J Immunol* 2012; **42**: 710-715 [PMID: 22213227 DOI: 10.1002/eji.201141921]
 - 31 **Marzano AV**, Borghi A, Meroni PL, Cugno M. Pyoderma gangrenosum and its syndromic forms: evidence for a link with autoinflammation. *Br J Dermatol* 2016; **175**: 882-891 [PMID: 27106250 DOI: 10.1111/bjd.14691]
 - 32 **Smith EJ**, Allantaz F, Bennett L, Zhang D, Gao X, Wood G, Kastner DL, Punaro M, Aksentijevich I, Pascual V, Wise CA. Clinical, Molecular, and Genetic Characteristics of PAPA Syndrome: A Review. *Curr Genomics* 2010; **11**: 519-527 [PMID: 21532836 DOI: 10.2174/138920210793175921]
 - 33 **Cortesio CL**, Wernimont SA, Kastner DL, Cooper KM, Huttenlocher A. Impaired podosome formation and invasive migration of macrophages from patients with a PSTPIP1 mutation and PAPA syndrome. *Arthritis Rheum* 2010; **62**: 2556-2558 [PMID: 20506269 DOI: 10.1002/art.27521]
 - 34 **Dierselhuis MP**, Frenkel J, Wulffraat NM, Boelens JJ. Anakinra for flares of pyogenic arthritis in PAPA syndrome. *Rheumatology (Oxford)* 2005; **44**: 406-408 [PMID: 15637033 DOI: 10.1093/rheumatology/keh479]
 - 35 **Löffler W**, Lohse P, Weihmayr T, Widenmayer W. Pyogenic arthritis, pyoderma gangrenosum, and acne (PAPA) syndrome: differential diagnosis of septic arthritis by regular detection of exceedingly high synovial cell counts. *Infection* 2017; **45**: 395-402 [PMID: 28251506 DOI: 10.1007/s15010-017-0996-1]
 - 36 **Sood AK**, McShane DB, Googe PB, Wu EY. Successful Treatment of PAPA Syndrome with Dual Adalimumab and Tacrolimus Therapy. *J Clin Immunol* 2019; **39**: 832-835 [PMID: 31471736 DOI: 10.1007/s10875-019-00685-6]
 - 37 **Miceli-Richard C**, Comets E, Verstuyft C, Tamouza R, Loiseau P, Ravaud P, Kupper H, Becquemont L, Charron D, Mariette X. A single tumour necrosis factor haplotype influences the response to adalimumab in rheumatoid arthritis. *Ann Rheum Dis* 2008; **67**: 478-484 [PMID: 17673491 DOI: 10.1136/ard.2007.074104]
 - 38 **Van den Bosch F**, Manger B, Goupille P, McHugh N, Rødevand E, Holck P, van Vollenhoven RF, Leirisalo-Repo M, Fitzgerald O, Kron M, Frank M, Kary S, Kupper H. Effectiveness of adalimumab in treating patients with active psoriatic arthritis and predictors of good clinical responses for arthritis, skin and nail lesions. *Ann Rheum Dis* 2010; **69**: 394-399 [PMID: 19815494 DOI: 10.1136/ard.2009.111856]
 - 39 **Braun-Moscovici Y**, Markovits D, Zinder O, Schapira D, Rozin A, Ehrenburg M, Dain L, Hoffer E,

Nahir AM, Balbir-Gurman A. Anti-cyclic citrullinated protein antibodies as a predictor of response to anti-tumor necrosis factor-alpha therapy in patients with rheumatoid arthritis. *J Rheumatol* 2006; **33**: 497-500 [PMID: [16511906](#)]



Published by **Baishideng Publishing Group Inc**
7041 Koll Center Parkway, Suite 160, Pleasanton, CA 94566, USA

Telephone: +1-925-3991568

E-mail: bpgoffice@wjgnet.com

Help Desk: <https://www.f6publishing.com/helpdesk>

<https://www.wjgnet.com>

