

# World Journal of *Methodology*

*World J Methodol* 2022 January 20; 12(1): 1-63



**MINIREVIEWS**

- 1 Ophthalmological instruments of Al-Halabi fill in a gap in the biomedical engineering history  
*Saad MN*
- 20 Severe acute respiratory syndrome coronavirus 2 pandemic related morbidity and mortality in patients with pediatric surgical diseases: A concerning challenge  
*Vaos G, Zavras N*
- 32 Liver transplant allocation policies and outcomes in United States: A comprehensive review  
*Latt NL, Niazi M, Pyrsopoulos NT*
- 43 Interrogating the interplay of angiogenesis and immunity in metastatic colorectal cancer  
*Kampoli K, Foukas PG, Ntavatzikos A, Arkadopoulos N, Koumarianou A*

**ORIGINAL ARTICLE****Retrospective Study**

- 54 Phenomenology of obsessive-compulsive disorder in children and adolescents: Sample from a tertiary care center in Istanbul, Turkey  
*Cifter A, Erdogan AB*

**ABOUT COVER**

Peer Reviewer of *World Journal of Methodology*, Angela Domínguez Camacho, DDS, MEd, Professor, Department of Orthodontics, Unico-Cali, Colombia. [angela.dominguezc@gmail.com](mailto:angela.dominguezc@gmail.com)

**AIMS AND SCOPE**

The primary aim of *World Journal of Methodology* (WJM, *World J Methodol*) is to provide scholars and readers from various fields of methodology with a platform to publish high-quality basic and clinical research articles and communicate their research findings online.

WJM mainly publishes articles reporting research results obtained in the field of methodology and covering a wide range of topics including breath tests, cardiac imaging techniques, clinical laboratory techniques, diagnostic self-evaluation, cardiovascular diagnostic techniques, digestive system diagnostic techniques, endocrine diagnostic techniques, neurological diagnostic techniques, obstetrical and gynecological diagnostic techniques, ophthalmological diagnostic techniques, otological diagnostic techniques, radioisotope diagnostic techniques, respiratory system diagnostic techniques, surgical diagnostic techniques, *etc.*

**INDEXING/ABSTRACTING**

The WJM is now abstracted and indexed in PubMed, PubMed Central, China National Knowledge Infrastructure (CNKI), China Science and Technology Journal Database (CSTJ), and Superstar Journals Database.

**RESPONSIBLE EDITORS FOR THIS ISSUE**

Production Editor: Rui-Rui Wu, Production Department Director: Xu Guo, Editorial Office Director: Ji-Hong Lin.

**NAME OF JOURNAL**

*World Journal of Methodology*

**ISSN**

ISSN 2222-0682 (online)

**LAUNCH DATE**

September 26, 2011

**FREQUENCY**

Bimonthly

**EDITORS-IN-CHIEF**

Bruno Megarbane

**EDITORIAL BOARD MEMBERS**

<https://www.wjnet.com/2222-0682/editorialboard.htm>

**PUBLICATION DATE**

January 20, 2022

**COPYRIGHT**

© 2022 Baishideng Publishing Group Inc

**INSTRUCTIONS TO AUTHORS**

<https://www.wjnet.com/bpg/gerinfo/204>

**GUIDELINES FOR ETHICS DOCUMENTS**

<https://www.wjnet.com/bpg/gerinfo/287>

**GUIDELINES FOR NON-NATIVE SPEAKERS OF ENGLISH**

<https://www.wjnet.com/bpg/gerinfo/240>

**PUBLICATION ETHICS**

<https://www.wjnet.com/bpg/gerinfo/288>

**PUBLICATION MISCONDUCT**

<https://www.wjnet.com/bpg/gerinfo/208>

**ARTICLE PROCESSING CHARGE**

<https://www.wjnet.com/bpg/gerinfo/242>

**STEPS FOR SUBMITTING MANUSCRIPTS**

<https://www.wjnet.com/bpg/gerinfo/239>

**ONLINE SUBMISSION**

<https://www.f6publishing.com>



## Ophthalmological instruments of Al-Halabi fill in a gap in the biomedical engineering history

Mohamed N Saad

**ORCID number:** Mohamed N Saad  
0000-0001-8229-0280.

**Author contributions:** Saad MN designed the study, drafted the article, prepared the figures and tables, granted permission for figures reproduction, designed the outline, and read and approved the final version of the article to be published.

**Conflict-of-interest statement:**  
There is no conflict of interest associated with the single author contributed his efforts in this manuscript.

**Country/Territory of origin:** Egypt

**Specialty type:** Medical laboratory technology

**Provenance and peer review:**  
Invited article; Externally peer reviewed.

**Peer-review model:** Single blind

**Peer-review report's scientific quality classification**

Grade A (Excellent): 0  
Grade B (Very good): 0  
Grade C (Good): C  
Grade D (Fair): 0  
Grade E (Poor): 0

**Open-Access:** This article is an open-access article that was selected by an in-house editor and

**Mohamed N Saad**, Biomedical Engineering Department, Faculty of Engineering, Minia University, Minia 61111, Egypt

**Corresponding author:** Mohamed N Saad, PhD, Assistant Professor, Biomedical Engineering Department, Faculty of Engineering, Minia University, Misr Aswan Agricultural Road, Minia 61111, Egypt. [m.n.saad@mu.edu.eg](mailto:m.n.saad@mu.edu.eg)

### Abstract

Al-Halabi is an intriguing ophthalmologist who invented numerous surgical instruments for treating various eye diseases. The illustrations of such instruments in his invaluable book "*Kitab Al-Kafi fi Al-Kuhl*" reflect his willingness to teach. Moreover, he included in his book a magnificent illustration of the anatomical structure of the eye. The book reflects Al-Halabi's medical practice and teaching and shows several advanced medical techniques and tools. His invaluable comments reflect his deep experimental observations in the field of ophthalmology. The current article provides proof that Al-Halabi is one of our early biomedical engineers from more than 800 years ago. Al-Halabi represents a ring in the chain of biomedical engineering history. His surgical instruments represent the biomechanics field. Al-Halabi should be acknowledged among the biomedical engineering students for his various contributions in the field of surgical instruments.

**Key Words:** Al-Halabi; Biomedical engineering education; Biomedical engineering history; Ophthalmological instruments

©The Author(s) 2022. Published by Baishideng Publishing Group Inc. All rights reserved.

**Core Tip:** Medieval Islamic ophthalmological instruments are a rich, complex, and understudied subject. This topic is interesting and deserves more attention than it has had. The book of Al-Halabi is indeed one of the interesting books on ophthalmology written in Arabic. The ophthalmological instruments included in Al-Halabi's table represent an untold story about the contributions of Muslim and Arab scholars in the field of ophthalmology. The aim of the present article is to fill in one of the gaps to some extent in biomedical engineering history. The ophthalmological instruments represent the biomechanics field.



fully peer-reviewed by external reviewers. It is distributed in accordance with the Creative Commons Attribution NonCommercial (CC BY-NC 4.0) license, which permits others to distribute, remix, adapt, build upon this work non-commercially, and license their derivative works on different terms, provided the original work is properly cited and the use is non-commercial. See: <https://creativecommons.org/licenses/by-nc/4.0/>

**Received:** January 13, 2021

**Peer-review started:** January 15, 2021

**First decision:** October 17, 2021

**Revised:** October 25, 2021

**Accepted:** December 11, 2021

**Article in press:** December 11, 2021

**Published online:** January 20, 2022

**P-Reviewer:** Au SCL

**S-Editor:** Wang JJ

**L-Editor:** A

**P-Editor:** Wang JJ



**Citation:** Saad MN. Ophthalmological instruments of Al-Halabi fill in a gap in the biomedical engineering history. *World J Methodol* 2022; 12(1): 1-19

**URL:** <https://www.wjgnet.com/2222-0682/full/v12/i1/1.htm>

**DOI:** <https://dx.doi.org/10.5662/wjm.v12.i1.1>

## INTRODUCTION

Studying the biomedical engineering history has greatly influenced the creative and inventive sense of biomedical engineering students[1]. Biomedical technologies have a very long history, among which are the ancient surgical instruments[2]. Bronze age epilation forceps were found in Ur, Iraq. The forceps, used in the treatment of trachoma, date back to ca. 2600 BC[3]. Other epilation forceps were discovered in tombs of the New Kingdom of Egypt (1570-1070 BC). Moreover, pots containing copper, zinc oxide, lead, and antimony sulphates were uncovered at the same tombs. These pigments were utilized for treating conjunctivitis[4]. It is argued that the first “book” on medicine in the world which is a medical papyrus (1553-1550 BC) was discovered in Luxor (Thebes), Egypt, in 1872 by the German archeologist Georg Ebers (1837-1898). In the eye treatment section, the only surgical procedure mentioned in the papyrus that has survived was applying to the eyelid onions, myrrh, gazelle excrement, and blood from lizards or bats after epilation through the use of feathers of a vulture[3].

Furthermore, in Egypt, several surgical needles could be seen carved in stone from the relief on the internal facade of the second wall in Kom Ombo Temple, constructed during the Ptolemaic dynasty (180-47 BC). Moreover, W.M. Flinders Petrie (1853-1942) (English Egyptologist) has discovered a series of ancient cooper needles with no hooks or apertures in King Khasekhemwy’s tomb (ca. 2690 BC) in the Royal Necropolis at Abydos, Upper Egypt, in 1900. These needles represent the earliest known ancient surgical instruments for dislodging the cataract away from the pupil[5]. These needles could be found in the National Museums in Liverpool, England[6].

Hippocrates (Greek physician d. 370 BC) recommended using wool rounded around a wooden rod soaked in a caustic solution for scraping the eyelids when treating trachoma. Celsus (Roman encyclopaedist d. 50 AD) included in the medical work of his encyclopedia the recommendation of using a hook, a threaded needle, and a scalpel in the treatment of pterygium. Galen (Greek physician d. 210 AD) utilized a cuttlefish bone for roughness in treating trachoma and as an agent to dissolve pterygium. Aëtius of Amida (Byzantine Greek physician, mid-5<sup>th</sup> century to mid-6<sup>th</sup> century) applied a blunt hook, a tiny hook, a horse-hair and linen thread through a needle, and a knife in the treatment of pterygium[7]. Numerous gaps exist in the biomedical engineering history, one of which the present article aims to fill in through providing an overview of Al-Halabi’s contributions.

## AL-HALABI’S BIOGRAPHY

Al-Halabi (middle of the 13<sup>th</sup> century)[8,9] - whose full name was Khalifah ibn Abi Al-Mahasin Al-Halabi[10] and who was known as Khalifa Ben Abi Al-Mahassin[11], Khalifa ibn Abi Al-Mahasin Al-Halabi[12], Halifa B Abi L-Mahasin[13], and Halifa[14] for short - was named after Aleppo (Arabic: Halab), a city in the northern part of Syria, known for its thriving trades and wealth in the middle ages before the Mongol onslaught (in 1260 AD)[11]. It was mostly where he was born and died[15,16]. He mentioned two incidents that happened to him in Aleppo in 1252 and 1254 AD (650 and 652 AH)[11,15]. Aleppo was, as it has been for centuries, an important city and the capital of a principality[17]. It appears that Al-Halabi must have had a wide spectrum of knowledge about medical sciences as can be derived from the list of references that he cited. He was considered the first ophthalmologist to use a magnet in order to remove metallic foreign body from the eye by Wafai and Kalaji as well as Hirschberg, as he extracted a couching needle that was broken in a patient’s eye during the surgery [14-16,18]. He realized that an instrument may be substituted by another because of unavailability[15].

## AL-HALABI'S BOOK

*The Sufficient Knowledge in Ophthalmology* (Arabic: Kitab Al-Kafi fi Al-Kuhl), expected to be written within the period from 1256 to 1275 AD, is the only known book by Al-Halabi[11,13,14]. It is one of the masterpieces of Islamic ophthalmological medicine and surgery. The book's scientific value is incomparable to European manuscripts till the beginning of the nineteenth century[14]. The book describes in a separate chapter the measurements, weights, and sizes used at that time by physicians. It quotes 73 authors and 41 books before its time[9,18]. He referenced famous Arabian or Muslim authors such as Al-Razi, Ibn Sina (Avicenna), Al-Tabari, Hunayn ibn Ishaq, Al-Ghafiqi, Ibn Zuhri (Avenzoar), and Al-Zahrawi; Greeks such as Galen, Hippocrates, and Oribasius; and Indians[15,16].

The two copies of the book are to be found in the Bibliothèque Nationale in Paris, France (under the number 1043d. Arabe), and the Süleymaniye Kütüphanesi in Istanbul, Turkey (under the number Yeni Jami 924). The Paris manuscript was written by the Christian copyist Abd Al-Aziz ibn Abi Saeed Al-Masihi Al-Mawsili Al-Mutatabbeeb in 1277 AD, meaning that it is very close to the time of the author. The Istanbul manuscript was written by the Muslim copyist Ahmad Al-Wali in 1560 AD, meaning that the manuscript was written around 300 years after the death of the author[15].

The book was disappointingly ignored until the French medical historian Lucien Leclerc (1816-1893) had described it briefly for the first time in 1876 in his book “*Histoire de la Médecine Arabe*”[19]. In 1905, the German ophthalmologist and historian Julius Hirschberg (1843-1925) with the orientalist J. Lippert (1839-1909) and E. Mittwoch (1876-1942) wrote a book entitled “*Arabian Ophthalmologists*” in which they studied the book with great detail[15,16,20].

The present article depends basically on the reproduction of Al-Halabi's book edited by M. Z. Wafai and M. R. Kalaji. They produced Al-Halabi's book within the combined series “*The Islamic Heritage in Ophthalmology*” in which they unearthed the Islamic glorious heritage and its valuable knowledge that served humanity for over thirteen centuries. They compared the two copies of the book (in Paris and Istanbul) and put in the text the most accurate words. They explained in the footnotes some words that could contain more than one meaning. They gave the modern names of the diseases that Al-Halabi described. The book was published by the Islamic Educational, Scientific and Cultural Organization, Rabat, Morocco in 1990[15].

## THE INSTRUMENTS TABLE

Al-Halabi's book is the first book to place thirty-six surgical instruments in a very elegant table[9,21]. This table is considered to be well organized as each surgical instrument was placed in a special frame with the name of the instrument on the top and the way to use it underneath it, as shown in Figure 1[16,22]. This was the first time that an author put a table for the surgical instruments, unlike his predecessors who used to put the drawing of the instrument within the text[15].


Some of these instruments were known and used by earlier Arabic ophthalmologists, and a few authors also included illustrations of the instruments, but none was as comprehensively or as systematically as Al-Halabi[18]. For example, Al-Razi (d. 925 AD) recommended the rose leaf needle (No. 7 in Figure 1) for scraping off the chronic trachoma. Moreover, Al-Razi used hooks (No. 6 in Figure 1) to lift thick pannus, which was then excised with scissors[23]. Al-Zahrawi (d. 1013 AD) used spear (No. 9 in Figure 1) to treat symblepharon[24]. Al-Ghafiqi (d. 1165 AD) used drill (No. 12 in Figure 1) and small drill (No. 34 in Figure 1) in dacryocystorhinostomy[25]. Ammar ibn Ali Al-Mawsili (d. 1010 AD) invented a hollowed aspirating needle (No. 22 in Figure 1) for cataract surgery[26]. Ibn Al-Nafis (d. 1288 AD)[27] used the scalpel (No. 4 in Figure 1) or the rose leaf needle for scraping the eyelid in trachoma surgery. Besides, Ibn Al-Nafis used speculums (No. 3 in Figure 1), scissors (No. 2 in Figure 1), and hooks in the treatment of pannus. Furthermore, Ibn Al-Nafis applied the rounded couching needle (No. 16 in Figure 1) to penetrate pterygium and strip it away from the conjunctiva and cornea[28].

It is worth mentioning that Al-Halabi used the instruments with other diseases other than what he mentioned in the instruments table. So, for all the instruments discussed in the current article, the statements of use on the table itself were given first and then supplemented with other uses given elsewhere in his treatise (with page numbers given for those), as could be seen in Table 1. These instruments were as

**Table 1 The descriptions of the uses of the instruments[15]**

<b>Instrument name</b>	<b>No. in Figure 1</b>	<b>Uses in his table</b>	<b>Other uses in his book with page numbers in reference[15] given</b>
Scissors	1	Distichiasis	
Scissors	2	Pannus	Concretions (p.121, p.276); Ectropion (p.278); Styne (p.279); Distichiasis (p.282); Hordeolum (p.287); Hemangioma at the eyelid (p.287); Wart (p.289); Lacrimal caruncle swelling (p.291); Pterygium (p.293); Hemangioma at the conjunctiva (p.297); Iris prolapse (p.299); Superficial temporal artery (p.300)
Speculums	3	Only description	Pannus (p.295)
Scissors	5	Pannus, pterygium (a note with the myrtle leaf needle)	Granuloma at the conjunctiva (p.297)
Hooks	6	Pannus, pterygium, distichiasis	Symblepharon (p.277); Ectropion (p.278); Distichiasis (p.281); Hemangioma at the eyelid (p.287); Sebaceous cyst (p.290); Lacrimal caruncle swelling (p.291); Hemangioma at the conjunctiva (p.297); Granuloma at the conjunctiva (p.297); Superficial temporal artery (p.300)
Rose leaf needle	7	Hemangioma at the eyelid, sebaceous cyst, hemangioma at the conjunctiva (a note with the half rose leaf needle)	Trachoma (p.275); Symblepharon (p.277); Lagophthalmos (p.123, p.278); Ectropion (p.278); Wart (p.289)
Half rose leaf needle	8	Hemangioma at the conjunctiva, (Trachoma, concretions) (a note with the scraper)	Adhesions between the two eyelids (p.277)
Spear	9	Sebaceous cyst	Symblepharon (p.277); Ectropion (p.278)
Myrtle leaf needle	10	Pterygium, symblepharon, sebaceous cyst (a note with the spear)	
Axe	11	Bloodletting the supraorbital vein	
Drill	12	Dacryocystitis	
Raven's beak	13	Removing whatever sticks to the eye or the inner side of the eyelid	Conjunctival wound (p.213)
Lancet	14	Cataract	
Rounded couching needle	16	Could be substituted by the triangular needle	Pannus (p.295); Hemangioma at the conjunctiva (p.297); Cataract (p.305)
Scalpel	18	Hypopyon, chemosis	Adhesions between the two eyelids (p.277); Allergic dermatitis (p.288)
Scraper	19	Trachoma, concretions	
Lancet	20	Lipoma, chalazion	Concretions (p.276); Chemosis (p.285); Blepharitis (p.289); Hypopyon (p.298); Superficial temporal artery (p.300); Cataract (p.307)
Sickle	21	Adhesions between the two eyelids, ectropion	
Hollowed aspirating needle	22	Cataract	
Gooseneck speculum and tailor's needle	24	Distichiasis	
Gatherer	27	Wart	'Foreign body' fallen into the eye (p.215), Styne (p.279), Hordeolum (p.287),
Gatherer	28	Distichiasis, 'foreign body' fallen into the eye	
Cautery	29	Supraorbital vein, superficial temporal veins	Superficial temporal artery (pp.300-301)
Cautery	30	Dacryocystitis	
Cautery	31	Distichiasis	
Small drill	34	Dacryocystitis	
Awn-tongs	35	'Foreign body' fallen into the eye	

functional as the seventy-six instruments invented by the Austrian ophthalmic surgeon Wilhelm Czermak (1856-1906) as considered by Hirschberg[14].



**Figure 1** Ophthalmological instruments from Al-Halabi's book, the Istanbul manuscript of the Süleymaniye Kütüphanesi, Yeni Cami 924. Citation: Sezgin F, Neubauer E. Volume IV: Catalogue of the collection of instruments of the institute for the history of Arabic and Islamic sciences. In: Sezgin F. Science and technology in Islam. Frankfurt am Main, Germany: Institute for the History of Arabic-Islamic Science, 2010: 6. Copyright ©The Author(s) 2010. Published by Institute for the History of Arabic-Islamic Science (Institut für Geschichte der Arabisch-Islamischen Wissenschaften). The author has obtained the permission for figure using from the Institute for the History of Arabic-Islamic Science (Institut für Geschichte der Arabisch-Islamischen Wissenschaften) (Supplementary Material).

## CONTRIBUTIONS IN EYELID DISEASES

Al-Halabi utilized a needle in the treatment of trachoma (called granular conjunctivitis or Egyptian ophthalmia, which is a contagious, chronic inflammation of the mucous membranes of the eyes, caused by *Chlamydia trachomatis*; it is characterized by swelling of the eyelids, sensitivity to light, and eventual scarring of the conjunctivae and corneas of the eyes). The patient was lied down and Al-Halabi stayed beside the diseased eye. A nurse stayed beside Al-Halabi for handing him the required surgical instrument. The shape of the tip of the needle resembled the rose leaf with a small, short, pointed end, as illustrated in Figure 2[22]. He started stripping the scabies by the needle from the medial canthus to the lateral canthus. He noted that the ophthalmologist should preserve mildness and tranquility to prevent eye damage. As an alternative to the needle, a scraper can be used. It looks like a right-angled bolt extractor, as seen in Figure 3[22]. It is utilized for scratching scabies[15].

Moreover, Al-Halabi used the rose leaf needle when treating lagophthalmos (a condition in which a complete closure of the eyelids over the eyeball is difficult or impossible). If lagophthalmos was a result of a healed ulcer or a strained suture of a wound leading to eyelid attraction, the rose leaf needle was used to incise the place of the healed ulcer or the strained suture. Then, a piece of cotton was inserted at the place of the incision[15].

He used a lancet in order to remove chalazion (a cyst that appears on the eyelid because of a blocked meibomian gland)[8]. If medications did not heal chalazion, an incision should be applied to it. If the chalazion was at the upper eyelid, it should be extended downwards. If the chalazion was at the lower eyelid, it should be extended upwards. At this point, a horizontal incision was applied to the chalazion through the





**Figure 2 Rose leaf needle (instrument number 7 in Figure 1) used in treatment of trachoma, lagophthalmos, symblepharon, hemangioma at the eyelid, and sebaceous cyst.** Citation: Sezgin F, Neubauer E. Volume IV: Catalogue of the collection of instruments of the institute for the history of Arabic and Islamic sciences. In: Sezgin F. Science and technology in Islam. Frankfurt am Main, Germany: Institute for the History of Arabic-Islamic Science, 2010: 45. Copyright ©The Author(s) 2010. Published by Institute for the History of Arabic-Islamic Science (Institut für Geschichte der Arabisch-Islamischen Wissenschaften). The author has obtained the permission for figure using from the Institute for the History of Arabic-Islamic Science (Institut für Geschichte der Arabisch-Islamischen Wissenschaften) ([Supplementary Material](#)).



**Figure 3 Scraper (instrument number 19 in Figure 1) for scratching scabies and for digging out concretions.** Citation: Sezgin F, Neubauer E. Volume IV: Catalogue of the collection of instruments of the institute for the history of Arabic and Islamic sciences. In: Sezgin F. Science and technology in Islam. Frankfurt am Main, Germany: Institute for the History of Arabic-Islamic Science, 2010: 49. Copyright ©The Author(s) 2010. Published by Institute for the History of Arabic-Islamic Science (Institut für Geschichte der Arabisch-Islamischen Wissenschaften). The author has obtained the permission for figure using from the Institute for the History of Arabic-Islamic Science (Institut für Geschichte der Arabisch-Islamischen Wissenschaften) ([Supplementary Material](#)).

use of a lancet with a rounded tip ([Figure 4](#)) in order to cleave the chalazion[22]. If the chalazion was inclined to the outer side of the eyelid, the incision should be applied on the outer side of the eyelid, and vice versa. Finally, the chalazion should be removed using a spoon[15,29].

The lancet as well could be used in the treatment of chemosis (abnormal edematous swelling of the mucous membrane covering the eyeball and lining the eyelids) and lipoma (benign fatty tumor occurring at the inner side of the upper eyelid between its layers). In case of lipoma, Al-Halabi warned the ophthalmologists that they should be cautious of the penetration of the eyelid leading to the puncture of the tarsal cartilage of the eyelid, and a perforated cornea and iris. Furthermore, the lancet could be used in the incision of blepharitis (inflammation of the eye glands and eyelash follicles along the margin of the eyelids).

The same lancet was applied for removing the concretions (small, separated tumors at the inner side of the eyelid). A horizontal deep incision was conducted through the use of the lancet for digging out the stone formations. Besides, the scraper could be used as a substitution for the lancet. Al-Halabi mentioned that the ophthalmologist should be careful while using either the lancet or the scraper to prevent the penetration of the eyelid. Scissors may be used after the eradication of the concretions to cut off the incision slits. This procedure slows the healing of the incision in order to prevent the reappearance of the concretions. The scissors (Arabic: Miqrada) have a flattened, sharp, and straight shape, with the pivot tempered, as shown in [Figure 5](#)[15, 22].

Al-Halabi used a tool that resembles to some extent an extremely small sickle (see [Figure 6](#)) in the treatment of the adhesions between the two eyelids[22]. If the two eyelids were closely adhered, a small incision should be performed using a fine scalpel (instrument number 18 in [Figure 1](#)) or a needle at the origins of the eyelashes to let the tip of the sickle be introduced between the two eyelids. The shape of the tip of the needle resembles half the rose leaf (instrument number 8 in [Figure 1](#)). He started opening the incision from the direction of the medial canthus towards the lateral canthus[15].





**Figure 4 Lancet with rounded tip (instrument number 20 in Figure 1) used in treatment of chalazion, chemosis, lipoma, blepharitis, concretions, hypopyon, headache, and cataract.** Citation: Sezgin F, Neubauer E. Volume IV: Catalogue of the collection of instruments of the institute for the history of Arabic and Islamic sciences. In: Sezgin F. Science and technology in Islam. Frankfurt am Main, Germany: Institute for the History of Arabic-Islamic Science, 2010: 49. Copyright ©The Author(s) 2010. Published by Institute for the History of Arabic-Islamic Science (Institut für Geschichte der Arabisch-Islamischen Wissenschaften). The author has obtained the permission for figure using from the Institute for the History of Arabic-Islamic Science (Institut für Geschichte der Arabisch-Islamischen Wissenschaften) ([Supplementary Material](#)).



**Figure 5 Scissors (Miqrad) (instrument number 2 in Figure 1) used in treatment of concretions, ectropion, sty, hordeolum, lacrimal caruncle swelling, pannus, pterygium, hemangioma, iris prolapse, and headache.** Citation: Sezgin F, Neubauer E. Volume IV: Catalogue of the collection of instruments of the institute for the history of Arabic and Islamic sciences. In: Sezgin F. Science and technology in Islam. Frankfurt am Main, Germany: Institute for the History of Arabic-Islamic Science, 2010: 48. Copyright ©The Author(s) 2010. Published by Institute for the History of Arabic-Islamic Science (Institut für Geschichte der Arabisch-Islamischen Wissenschaften). The author has obtained the permission for figure using from the Institute for the History of Arabic-Islamic Science (Institut für Geschichte der Arabisch-Islamischen Wissenschaften) ([Supplementary Material](#)).

If the adhesions were between the eyelid and the conjunctiva or the cornea (symblepharon), two hooks were utilized for holding up the eyelid. If the adhesions were at the upper eyelid, it should be extended upwards. If the adhesions were at the lower eyelid, it should be extended downwards. Al-Halabi used the rose leaf needle to separate the adhesions. He stated that the ophthalmologist should use delicacy when the adhesions were between the eyelid and the conjunctiva. A tremendous delicacy should be applied when the adhesions were between the eyelid and the cornea in order to prevent making punctures in the corneal layers. These punctures could cause iris prolapse (protrusion of the iris or part of the iris through an injury in the cornea).

When the adhesions are closer to the bones of the eyebrow, it is harder to separate them, and a longer tool should be used like the needle or the spear. The shape of the tip of the needle resembles the myrtle leaf with a small, long pointed end appropriate for cleaving the adhesions, as presented in [Figure 7](#)[22]. The spear has a big long pointed end, as shown in [Figure 8](#), and could replace the myrtle leaf needle[15,22].

Al-Halabi used hooks (instrument number 6 in [Figure 1](#)), the spear, and the scissors (Miqrad) in the treatment of ectropion (eversion or turning outward of the margin of the eyelid). If the ectropion was due to the growth of a superfluous fleshy tissue on the inner side of the eyelid, two or three hooks were inserted in the fleshy tissue for holding up the eyelid. Then, the tip of the spear was inserted under the fleshy tissue to



**Figure 6 Sickle (instrument number 21 in Figure 1) for splitting adhesions between the two eyelids.** Citation: Sezgin F, Neubauer E. Volume IV: Catalogue of the collection of instruments of the institute for the history of Arabic and Islamic sciences. In: Sezgin F. Science and technology in Islam. Frankfurt am Main, Germany: Institute for the History of Arabic-Islamic Science, 2010: 52. Copyright ©The Author(s) 2010. Published by Institute for the History of Arabic-Islamic Science (Institut für Geschichte der Arabisch-Islamischen Wissenschaften). The author has obtained the permission for figure using from the Institute for the History of Arabic-Islamic Science (Institut für Geschichte der Arabisch-Islamischen Wissenschaften) ([Supplementary Material](#)).



**Figure 7 Myrtle leaf needle (instrument number 10 in Figure 1) used in treatment of symblepharon, and pterygium.** Citation: Sezgin F, Neubauer E. Volume IV: Catalogue of the collection of instruments of the institute for the history of Arabic and Islamic sciences. In: Sezgin F. Science and technology in Islam. Frankfurt am Main, Germany: Institute for the History of Arabic-Islamic Science, 2010: 47. Copyright ©The Author(s) 2010. Published by Institute for the History of Arabic-Islamic Science (Institut für Geschichte der Arabisch-Islamischen Wissenschaften). The author has obtained the permission for figure using from the Institute for the History of Arabic-Islamic Science (Institut für Geschichte der Arabisch-Islamischen Wissenschaften) ([Supplementary Material](#)).



**Figure 8 Spear (instrument number 9 in Figure 1) used in treatment of symblepharon, ectropion, and sebaceous cyst.** Citation: Sezgin F, Neubauer E. Volume IV: Catalogue of the collection of instruments of the institute for the history of Arabic and Islamic sciences. In: Sezgin F. Science and technology in Islam. Frankfurt am Main, Germany: Institute for the History of Arabic-Islamic Science, 2010: 45. Copyright ©The Author(s) 2010. Published by Institute for the History of Arabic-Islamic Science (Institut für Geschichte der Arabisch-Islamischen Wissenschaften). The author has obtained the permission for figure using from the Institute for the History of Arabic-Islamic Science (Institut für Geschichte der Arabisch-Islamischen Wissenschaften) ([Supplementary Material](#)).

warn it off the eyelid skin. Finally, the scissors were utilized for dissecting the fleshy tissue. Al-Halabi pointed out that the ophthalmologist should use tremendous delicacy in order to prevent the laceration of the eyelid skin and its dissection with the fleshy tissue[15].

He used the scissors (Miqrada) and a gatherer for treating sty (inflammation of the sebaceous gland of an eyelash) or wart (small, benign growth caused by a viral infection of the skin). The gatherer which has two broad heads (instrument number 27 in Figure 1) was utilized for holding sty or wart from its middle and extending it away from the eyelid. Then, the scissors were used for cutting it out of its roots. In the case of the wart, the scissors could be replaced by a horse-tail hair. In order to saw off the wart, the horse-tail hair was placed under the gatherer[16]. Actually, a recent study indicated that the horse-tail hair is about 0.2 mm thick, and it recommended using it in ophthalmic surgeries[30].

In addition, the scissors and gatherer were utilized for eradicating hordeolum (suppurative inflammation of a gland of the eyelid). Furthermore, the scissors were used for uprooting the hemangioma at the eyelid (benign tumor found on the eyelid, composed of dilated blood vessels, and often encapsulated within a fibrous shell) with the aid of a hook. The rose leaf needle could substitute the scissors.

The rose leaf needle was used in sebaceous cyst removal. The function of the needle was to make a horizontal incision at the liquefied tissue. Then, a hook and the rose leaf needle were utilized for removing the pus. The spear was applied for a deeper, T-shaped incision when the inflamed area was bigger and deeper. The myrtle leaf needle could substitute the spear. Al-Halabi elucidated that the liquefied tissue should be completely removed in order to avoid the reappearance of the sebaceous cyst[15].

## CONTRIBUTIONS IN DISTICHIASIS TREATMENT

Al-Halabi used annexation technique in the treatment of distichiasis (congenital, abnormal, accessory row of eyelashes, often causing severe discomfort from contact with the eye). If the eyelashes number was from one to five, a very thin tailor's needle could be used. A thread was twisted through the needle hole and around itself to make a buttonhole. Another thread was entered in the buttonhole to make it ready for annexation. The needle was applied at the margin of the eyelid from its inner side to the center of the distichiasis. The abnormal eyelashes were entered in the buttonhole with the aid of a tip of a gooseneck speculum (instrument number 24 in Figure 1). Then, the needle was pulled slowly and carefully to tighten the buttonhole on the eyelashes. Finally, the needle was extended quickly away of the eyelid, and the eyelashes were epilated at the middle of the buttonhole[15].

Another technique for treating distichiasis was the use of glue. If the abnormal eyelashes were long enough and their number was from one to five, they were pasted to the nearest normal eyelashes. The components of the glue are listed in Table 2[31, 32]. First, the glue was placed on a plate made of bronze. Second, the glue was melted on a soft flame. He noted that the flame should be near the ophthalmologist and ready to be used in order to prevent the glue from cooling down while being used. Third, an eye stick or a tip of a hook was utilized for applying the glue on the misdirected eyelashes. Finally, these eyelashes were extended to allow them to paste to the normal eyelashes for preventing the irritation of the eyeball. If the glue reached undesired normal eyelashes, it was removed by rubbing[15].

Moreover, distichiasis could be treated by cauterization. If the aberrant eyelashes number was from one to five despite being long or short, they should be plucked out first through the use of the gatherer. It could also be used in pulling out any "foreign body" that has fallen into the eye, as shown in Figure 9[22]. Then, a cautery was applied to the position of the pulled-out eyelashes. The cautery was pointed to be appropriate for the narrow places, as seen in Figure 10[22]. Al-Halabi preferred gold as a material of the cautery as the disease was cleared quickly and blisters did not appear at the cauterized position. When the eyelash was plucked out, the cautery was heated till its color turned red. Then, it was directed to the position of the pulled-out eyelashes. It should be slightly deeper to destroy the lash follicle[15].

In case of abnormal eyelashes number being more than five, their place on the eyelid should be cut using scissors. First, the eyelid was rolled up and incised at the location of the abnormal eyelashes from the medial canthus to the lateral canthus. A tailor's needle and a thread were used to sew the incision. Then, Al-Halabi placed the amount of the eyelid's skin between the two blades of the scissors. The scissors (Arabic: Miqass) (see Figure 11) should have two broad blades with their length equal to or more than the amount of the eyelid's skin that should be removed[22]. He distinguished the Miqass scissors from the Miqrad scissors that the first type has thicker and longer blades than the second being appropriate for removing the amount of the eyelid's skin in one cut[15].

## CONTRIBUTIONS IN MEDIAL CANTHUS DISEASES

Al-Halabi used a hook and scissors (Miqrad) in treating lacrimal caruncle swelling. The hook was utilized for hanging up the swelling. Then, the swelling was excised by the scissors. Finally, he warned the ophthalmologists that they should be cautious of the excision of a normal part of the lacrimal caruncle causing epiphora[15].

In case of dacryocystitis (congenital displacement of lacrimal tissue results in subconjunctival cysts), he placed a cautery that looks like a right-angled screwdriver, as shown in Figure 12[22]. Its shape is appropriate for the target with a smooth rounded tip contact. This cautery was used to cauterize the lacrimal gland fistula after its rupture until the vessels stop bleeding. He preferred gold as a material of the cautery. The cautery was heated till its color turns red. Then, it was directed to the

**Table 2 Medicinal natural products used in distichiasis treatment[15,31,32]**

Common name	Scientific name	Arabic name	Effects
Mastic	<i>Pistacia lentiscus</i>	Mustaqy	Antiseptic, anti-inflammatory, analgesic, sedative
Sarcocolla	<i>Astragalus Sarcocolla L</i>	Aanzarout	Anthelmintic, emollient
Aloe	<i>Aloe vera</i>	Sabr	Wound healing, antimicrobial



**Figure 9 Gatherer (instrument number 28 in Figure 1) used in treatment of distichiasis.** Citation: Sezgin F, Neubauer E. Volume IV: Catalogue of the collection of instruments of the institute for the history of Arabic and Islamic sciences. In: Sezgin F. Science and technology in Islam. Frankfurt am Main, Germany: Institute for the History of Arabic-Islamic Science, 2010: 53. Copyright ©The Author(s) 2010. Published by Institute for the History of Arabic-Islamic Science (Institut für Geschichte der Arabisch-Islamischen Wissenschaften). The author has obtained the permission for figure using from the Institute for the History of Arabic-Islamic Science (Institut für Geschichte der Arabisch-Islamischen Wissenschaften) ([Supplementary Material](#)).



**Figure 10 Pointed cautery (instrument number 31 in Figure 1) for cauterizing the places of superfluous eyelashes after they have been pulled out.** Citation: Sezgin F, Neubauer E. Volume IV: Catalogue of the collection of instruments of the institute for the history of Arabic and Islamic sciences. In: Sezgin F. Science and technology in Islam. Frankfurt am Main, Germany: Institute for the History of Arabic-Islamic Science, 2010: 51. Copyright ©The Author(s) 2010. Published by Institute for the History of Arabic-Islamic Science (Institut für Geschichte der Arabisch-Islamischen Wissenschaften). The author has obtained the permission for figure using from the Institute for the History of Arabic-Islamic Science (Institut für Geschichte der Arabisch-Islamischen Wissenschaften) ([Supplementary Material](#)).

position of the fistula till boiling. The cauterized position was wiped with a rag. Next, cauterization was repeated several times till the crust on the lacrimal bone was peeled. Finally, the cauterized position was cleaned from rot[15].

A drill was utilized in case the patient refused the cauterization solution. It consists of a handle and a long shaft with a small sharp pointed end, as seen in [Figure 13](#)[22]. It was used to clean the entire corner of the eye. In addition, a perforation was made at the tear-producing gland fistula in the nasal direction. A high strength should be applied until the blood flows from the nose and the mouth. Al-Halabi discussed that the perforation should not be directed upward as this would be the incorrect direction. Moreover, he noted that the ophthalmologist's working hand should be inclined to the nose (not to the eye) in order to avoid damage to the eye layers. Through this, a smaller drill (instrument number 34 in [Figure 1](#)) was wrapped in cotton which should be dry or soaked in ox fat or in verdigris ointment (corrosive, anti-inflammatory effects). He pointed that the verdigris became less effective if used after a year of its manufacture date. This would then be exchanged every day until the cotton was extracted clean in order to reach the bone pureness. With some details, the opening of



**Figure 11 Scissors (Miqass) (instrument number 1 in Figure 1) used in treatment of distichiasis.** Citation: Sezgin F, Neubauer E. Volume IV: Catalogue of the collection of instruments of the institute for the history of Arabic and Islamic sciences. In: Sezgin F. Science and technology in Islam. Frankfurt am Main, Germany: Institute for the History of Arabic-Islamic Science, 2010: 46. Copyright ©The Author(s) 2010. Published by Institute for the History of Arabic-Islamic Science (Institut für Geschichte der Arabisch-Islamischen Wissenschaften). The author has obtained the permission for figure using from the Institute for the History of Arabic-Islamic Science (Institut für Geschichte der Arabisch-Islamischen Wissenschaften) ([Supplementary Material](#)).



**Figure 12 Cautery (instrument number 30 in Figure 1) used in treatment of dacryocystitis.** Citation: Sezgin F, Neubauer E. Volume IV: Catalogue of the collection of instruments of the institute for the history of Arabic and Islamic sciences. In: Sezgin F. Science and technology in Islam. Frankfurt am Main, Germany: Institute for the History of Arabic-Islamic Science, 2010: 43. Copyright ©The Author(s) 2010. Published by Institute for the History of Arabic-Islamic Science (Institut für Geschichte der Arabisch-Islamischen Wissenschaften). The author has obtained the permission for figure using from the Institute for the History of Arabic-Islamic Science (Institut für Geschichte der Arabisch-Islamischen Wissenschaften) ([Supplementary Material](#)).



**Figure 13 Drill (instrument number 12 in Figure 1) for cleaning the entire corner of the eye.** Citation: Sezgin F, Neubauer E. Volume IV: Catalogue of the collection of instruments of the institute for the history of Arabic and Islamic sciences. In: Sezgin F. Science and technology in Islam. Frankfurt am Main, Germany: Institute for the History of Arabic-Islamic Science, 2010: 43. Copyright ©The Author(s) 2010. Published by Institute for the History of Arabic-Islamic Science (Institut für Geschichte der Arabisch-Islamischen Wissenschaften). The author has obtained the permission for figure using from the Institute for the History of Arabic-Islamic Science (Institut für Geschichte der Arabisch-Islamischen Wissenschaften) ([Supplementary Material](#)).

the wound should be widened through the use of the smaller drill, and the cotton should be exchanged as it is expected that the cotton would be extracted from the wound with small dirty fractures of the bone[15].



## CONTRIBUTIONS IN PANNUS TREATMENT

Al-Halabi used eye speculums, hooks, scissors (Miqrad), couching needle with a rounded tip, dove's feather, and eye stick in the treatment of pannus (membrane of fine blood vessels and fibrous tissue that spreads down over the peripheral cornea in trachoma and other inflammatory corneal disorders causing loss of vision)[34]. The patient was lied down, and he stayed behind the patient. A sessile pillow was put under the patient's head to make it slightly declined[15].

A tool, which looks somewhat like the eye speculum nowadays (instrument number 3 in Figure 1), was used to keep the patient's diseased eye open. Al-Halabi expressed his preference of using two thumbs of a skilled nurse instead of two eye speculums. The disadvantage of using the eye speculums from Al-Halabi's viewpoint was the obstruction of the eye speculums to the movement of the scissors (Miqrad) while cutting off the pannus. Three hooks were applied to hang up the pannus, one from the medial canthus, one from the center of the conjunctiva, and one from the lateral canthus. The hooks were applied near the upper eyelid[15].

A tip of the scissors (Miqrad) was utilized for cutting off a part of the membrane from the lateral canthus. Then, the couching needle was introduced to saw off the pannus. Al-Halabi recommended that the couching needle should be made of red bronze (instrument number 16 in Figure 1). A dove's feather might substitute the couching needle. The Miqrad scissors were used again to pick out the membrane until reaching the medial canthus. At this part, the three hooks were applied near the lower eyelid, and the same procedure was repeated till the pannus was completely removed. He noted that the ophthalmologist should watch out the cornea while performing this procedure[15].

A tiny eye stick was wrapped in cotton which should be soaked in egg yolk and rose oil (calms painful sores and constricts and cools wounds). He recommended that the rose oil should not be used after two years of its manufacture date as it got expired. The eye stick should be applied at the middle of the eye and extended in the directions of the two eyelids in order to prevent any adhesions that might occur[15].

Al-Halabi described another way to get rid of the pannus. One hook was applied to hang up the pannus. The scissors (Arabic: Kaz) were used to make a cut in the membrane. The Kaz scissors were thinner than the Miqass scissors and thicker than the Miqrad scissors, as shown in Figure 14[23]. Consequently, the hook was raised up while connected to the membrane, another hook was inserted, and the Kaz scissors were applied again. This procedure was repeated many times until the membrane was gathered by the Kaz scissors as one piece[15].

A third technique was elucidated by Al-Halabi for removing the pannus. Several hooks were used to hang up the pannus. The number of hooks ranged from six to twelve depending on the size of the eye. The insertion of the hooks started from the medial canthus near the upper eyelid and ended near the lower eyelid in a circular shape. A tip of the Miqrad scissors was used for cutting off a part of the membrane from the lateral canthus near the upper eyelid, and then near the lower eyelid. Then, the couching needle was introduced to saw off the pannus. At this point, the Kaz scissors were applied to make a circular incision in the membrane. The pannus would be extracted in a shape that looks like a signet ring[15].

## CONTRIBUTIONS IN CONJUNCTIVA DISEASES

Al-Halabi used a hook, a smooth dove's feather, myrtle leaf needle, Miqrad scissors, and Kaz scissors in treating pterygium (a pink, fleshy tissue that grows on the conjunctiva)[33]. The hook was utilized for raising the pterygium from its center. If the pterygium loosely adhered to the conjunctiva, a smooth dove's feather was inserted under the hook to saw off the pterygium. If the pterygium hardly adhered to the conjunctiva, two or three hooks could be added to the sides of the pterygium. Then, the myrtle leaf needle was used for sawing off the tissue. Finally, the Miqrad scissors or the Kaz scissors were used for cutting off the pterygium[15].

Al-Zahrawi used a horse-tail hair to saw off the pterygium. The dove's feather and the horse-tail hair were utilized due to the inability of the technology of that era to manufacture a man-made instrument with the required thickness and sharpness[24]. Al-Halabi stated that the ophthalmologist should use extreme delicacy in order to avoid penetrating the cornea or the medial canthus. He asked the ophthalmologist to beware of the total removal of the pterygium to avoid its reappearance. Furthermore, he asked the ophthalmologist to take care of the adhesiveness of the pterygium with



**Figure 14 Scissors (Kaz) (instrument number 5 in Figure 1) used in treatment of pannus, pterygium, and granuloma at the conjunctiva.**

Citation: Sezgin F, Neubauer E. Volume IV: Catalogue of the collection of instruments of the institute for the history of Arabic and Islamic sciences. In: Sezgin F. Science and technology in Islam. Frankfurt am Main, Germany: Institute for the History of Arabic-Islamic Science, 2010: 48. Copyright ©The Author(s) 2010. Published by Institute for the History of Arabic-Islamic Science (Institut für Geschichte der Arabisch-Islamischen Wissenschaften). The author has obtained the permission for figure using from the Institute for the History of Arabic-Islamic Science (Institut für Geschichte der Arabisch-Islamischen Wissenschaften) (Supplementary Material).

the conjunctiva. If the pterygium extremely adhered to the conjunctiva, the surgical instruments should not be applied at all in order to avoid eye damage[15].

Al-Halabi used a hook, a couching needle, the half of the rose leaf needle, and the Miqrada scissors in treating hemangioma at the conjunctiva. The hook was applied to raise up the hemangioma. He stated that the ophthalmologist should use tremendous delicacy while raising up the hemangioma because it has a spongy consistency, and the hook might turn up during the treatment. The couching needle was inserted under the blood vessels, and he started sawing off the hemangioma. The half of the rose leaf needle could replace the couching needle in sawing off the hemangioma. Finally, the scissors were utilized for uprooting the hemangioma[15].

Al-Halabi used a hook and the scissors (Kaz) in the treatment of granuloma at the conjunctiva (growth appearing like a nodule, consisting essentially of granulation tissue, and occurring as a result of localized inflammation). The hook was utilized for holding up the granuloma. If the size of the granuloma was large, two or three hooks should be applied. The Kaz scissors were applied to eradicate the granuloma[15].

He used a Raven's beak in the treatment of conjunctival wound (presence of wound or laceration of the conjunctiva with swelling and edema of the wound edges). The Raven's beak is a slim gatherer with two heads, as displayed in Figure 15[22]. The Raven's beak was used to extract an extremely small piece of wood that penetrated the eyeball and was fallen between the sclera and the eye bones. In addition, the Raven's beak could be used for removing whatever sticks to the eye or the inner side of the eyelid. The awn-tongs (see Figure 16) were utilized when an awn (either a hair- or bristle-like appendage) or a similar object fell down into the eye[15,22].

## CONTRIBUTIONS IN CORNEA AND IRIS DISEASES

Al-Halabi used a scalpel and a lancet in treating hypopyon (inflammatory cells in the anterior chamber of the eye). The scalpel was applied between the cornea and the conjunctiva to make an incision. He noted that the ophthalmologist should be cautious of the penetration of the iris. The lancet was applied at the position of the incision for the expulsion of the inflammatory cells. He used a needle, a thread, and scissors (Miqrada) in the treatment of the iris prolapse. A needle with a thread was inserted beneath the protrusion from the medial canthus and extracted from the lateral canthus. The two ends of the thread were drawn out of the eye. Then, the scissors were used to cleave the protrusion[15].



**Figure 15 Raven's beak (instrument number 13 in Figure 1) for removing whatever sticks to the eye or the inner side of the eyelid.** Citation: Sezgin F, Neubauer E. Volume IV: Catalogue of the collection of instruments of the institute for the history of Arabic and Islamic sciences. In: Sezgin F. Science and technology in Islam. Frankfurt am Main, Germany: Institute for the History of Arabic-Islamic Science, 2010: 52. Copyright ©The Author(s) 2010. Published by Institute for the History of Arabic-Islamic Science (Institut für Geschichte der Arabisch-Islamischen Wissenschaften). The author has obtained the permission for figure using from the Institute for the History of Arabic-Islamic Science (Institut für Geschichte der Arabisch-Islamischen Wissenschaften) (Supplementary Material).



**Figure 16 Awn tongs (instrument number 35 in Figure 1) used when an awn or something of that kind falls into the eye.** Citation: Sezgin F, Neubauer E. Volume IV: Catalogue of the collection of instruments of the institute for the history of Arabic and Islamic sciences. In: Sezgin F. Science and technology in Islam. Frankfurt am Main, Germany: Institute for the History of Arabic-Islamic Science, 2010: 53. Copyright ©The Author(s) 2010. Published by Institute for the History of Arabic-Islamic Science (Institut für Geschichte der Arabisch-Islamischen Wissenschaften). The author has obtained the permission for figure using from the Institute for the History of Arabic-Islamic Science (Institut für Geschichte der Arabisch-Islamischen Wissenschaften) (Supplementary Material).

## CONTRIBUTIONS IN HEADACHE AND MIGRAINE TREATMENT

In case of pain in the temporal muscles, headache, and migraine due to eye diseases, Al-Halabi used scissors (Miqrad), a hook, a lancet, and a cautery in the bloodletting and cutting the superficial temporal arteries and the posterior auricular veins[13]. A cord was tightened around the patient's throat with great mildness. Then, the patient was asked to throttle himself/herself with leniency. This procedure was conducted to make the arteries and the veins of the head visible and to target them. In case of the superficial temporal artery, he suggested shaving the temple, and spotting the artery with ink – this made the artery visible. After targeting the artery, the patient was asked to stop throttling himself/herself, and the cord was released to reduce the amount of the seepage blood while working[15].

Then, he attracted the skin over the artery using two fingers of his left hand. At this point, an incision was performed in the skin through the use of scissors (Miqrad). Consequently, the artery was extracted from its position and eradicated through the

use of a hook's tip. In case the artery was slim, a lancet was inserted under it to cut it off. Equally, the artery might be cut off using the scissors (Miqrad) instead of the lancet. In case the artery was thick, Al-Halabi used a needle and a thread made of silk or linen so that the artery would be tied in two places. Then, the lancet was utilized for opening an aperture between the two ligatures so that the desired amount of blood would flow out. After bloodletting, the artery was ligated and the blood flow was controlled[15].

Al-Halabi provided the cauterization by a flathead cautery instead of the eradication of the artery through the use of the lancet or the scissors. The same procedures were conducted for the posterior auricular vein except that the cautery was smaller than that for the superficial temporal artery. His usage of smaller cautery for the posterior auricular vein is in line with modern knowledge, as the thickness of the outer walls and the layers of muscle and elastic fibers of the veins is less than that of the arteries. As a disinfection procedure, he recommended the use of medical packs made of cotton after cauterization[15].

In case the previous procedures were unfruitful in treating migraine and headache, the supraorbital vein and the superficial temporal veins should be cauterized. First, the head was shaved from the middle of the scalp towards the forehead. Al-Halabi described how to know the position of the supraorbital vein in the forehead. The patient was asked to put the nail of his/her thumb of the right hand on the apex of the nose. Then, his/her forefinger was extended on the nasal septum towards the forehead. The maximum point the forefinger could reach was the position of the supraorbital vein. Next, this position was massaged using rough linen pack until it became red. At this point, a cautery was applied on the position longitudinally and horizontally in order to make a cross-shaped cauterization. The cautery looks like a fleshy olive and was made of iron, as shown in Figure 17[22]. The same procedures were performed on the superficial temporal veins. A knife that resembles to some extent an extremely small axe (see Figure 18) might replace the cautery for the supraorbital vein[22]. The knife was utilized for bloodletting the supraorbital vein. It was placed lengthwise on the vein, and the severing was conducted with the middle finger of the right hand[15].

## THE ANATOMICAL STRUCTURE OF THE EYE

Al-Halabi's book was the first book to give a remarkable illustration of the anatomy of the brain, the eyes, and the visual pathway among them, as displayed in Figure 19[9, 22]. The illustration presented the eyes, the optic chiasm, the cerebral ventricles, the pericranium, the dura mater, the pia mater, the olfactory nerves, and the petrosal bone [34]. The illustration showed that the left eye is controlled by the right part of the brain, and vice versa. All the ocular coats (cornea, sclera, choroid, zonules, and the retina) and the three humidities (vitreous, crystalline lens, and aqueous) are clearly illustrated and labelled. In this drawing, the conjunctiva seemed to originate from the pericranium and the sclera from the dura mater[16].


He drew the optic nerves as hollow, parallel lines, stemming from the back of the sclera to meet the optic chiasm and continue their course posteriorly through the brain tissue until finally reaching the occipital lobe[35]. Two parallel lines extended from the back of the lens to the sclera and optic nerve, almost nearing the description of Cloquet's canal. Although Al-Halabi drew a small circle in the middle of the triangle behind the chiasm, he did not mention or give the pituitary gland a name.

The American neuroanatomist and neurologist Stephen Lucian Polyak (1889-1955) considered all the European diagrams of the eye until the end of the 16<sup>th</sup> century, including those by Leonardo da Vinci (1452-1519)[36], to be dependent on Arabic models[37]. Al-Halabi's drawing is more detailed and informative than Leonardo da Vinci's one (Codex Atlanticus: Biblioteca Ambrosiana, Milan, vol. 3, fol. 628). Al-Halabi's drawing remained a reference to all the books dealing with the anatomy of the eye until the German physician D. W. Soemmerring (1793-1871) drew a cross section of the eye in 1827. The American Academy of Ophthalmology used a modified version of Al-Halabi's drawing as the emblem for the 1987 annual meeting without giving credit to him[11,15,16].

J. Hirschberg stated that *"First of all one must appreciate that the Arab ophthalmologists since Hunain had made real efforts to exploit the anatomy, the physiology and the pathology of the brain for their patients. Therefore we do not wish to criticize them for having dragged the optic nerve crossing unnaturally to the front in this imaginary stylized representation of the brain in order to be able to illustrate it at all; we also do that in our diagrams"* and *"In any*



**Figure 17 Olivary-shaped cautery (instrument number 29 in Figure 1) used for headache, and migraine.** Citation: Sezgin F, Neubauer E. Volume IV: Catalogue of the collection of instruments of the institute for the history of Arabic and Islamic sciences. In: Sezgin F. Science and technology in Islam. Frankfurt am Main, Germany: Institute for the History of Arabic-Islamic Science, 2010: 50. Copyright ©The Author(s) 2010. Published by Institute for the History of Arabic-Islamic Science (Institut für Geschichte der Arabisch-Islamischen Wissenschaften). The author has obtained the permission for figure using from the Institute for the History of Arabic-Islamic Science (Institut für Geschichte der Arabisch-Islamischen Wissenschaften) ([Supplementary Material](#)).



**Figure 18 Axe (instrument number 11 in Figure 1) for bloodletting the supraorbital vein.** Citation: Sezgin F, Neubauer E. Volume IV: Catalogue of the collection of instruments of the institute for the history of Arabic and Islamic sciences. In: Sezgin F. Science and technology in Islam. Frankfurt am Main, Germany: Institute for the History of Arabic-Islamic Science, 2010: 50. Copyright ©The Author(s) 2010. Published by Institute for the History of Arabic-Islamic Science (Institut für Geschichte der Arabisch-Islamischen Wissenschaften). The author has obtained the permission for figure using from the Institute for the History of Arabic-Islamic Science (Institut für Geschichte der Arabisch-Islamischen Wissenschaften) ([Supplementary Material](#)).

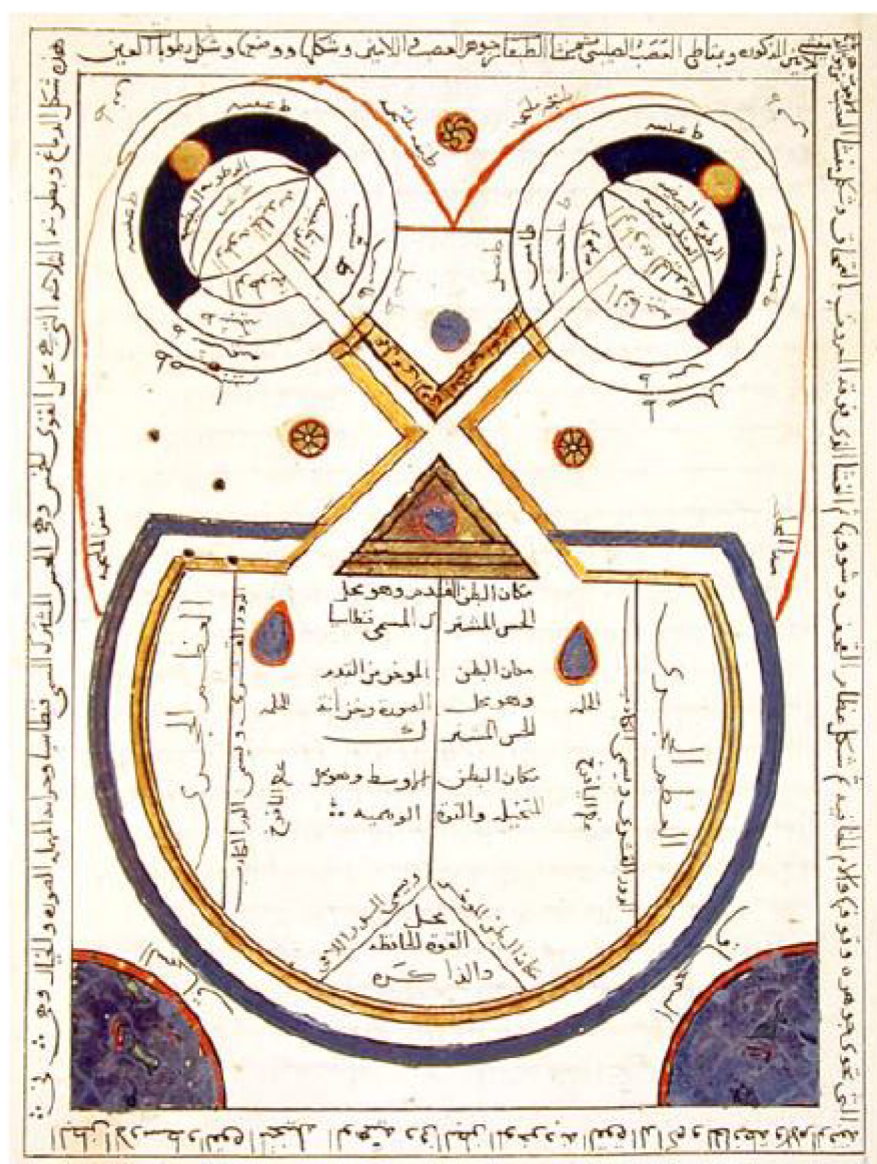
*case we see in this venerable picture, which probably goes back to models at least from the time around 1000 A.D., a cautious attempt to represent what D. W. Soemmerring insightfully arranged in his classic illustration in 1827” commenting on Al-Halabi’s illustration[22].*

## CONTRIBUTIONS IN CATARACT SURGERY

Al-Halabi detailed cataract operation representing twelve sorts of cataract in a table [14]. He dedicated a chapter of his book to the surgeries for removing the cataract. He described cataract operations, the required instruments, and the steps to be taken after the operation. He included his own experience which was described in good detail. He is so confident in his own talents that he had the courage to operate the cataract surgery on a one-eyed man for forty days[11,13]. Moreover, he surprisingly reported that he performed a successful cataract surgery for a predatory bird that was owned by his servant. However, the bird’s head movement after the surgery allowed the reappearance of the cataract[15].

He preferred the use of the hollowed cataract needle for aspiration[33], on the solid three-edged couching needle or the rounded couching needle for its safety in the operation. First, a lancet with a rounded tip (instrument number 14 in [Figure 1](#)) was utilized for puncturing the outer coats. Then, the hollowed needle (instrument number 22 in [Figure 1](#)) was applied to the iris without perforating the cornea. Extracting the lens by suction, using the hollowed needle that resembles to some extent the aspirating syringe nowadays as what could be understood from Al-Halabi’s description has the benefit of excluding the possibility of the lens falling back into the eye[8,15].





**Figure 19 Optic nerve crossing together with that of the eye and the brain from Al-Halabi's book, the Istanbul manuscript of the Süleymaniye Kütüphanesi, Yeni Cami 924.** Citation: Sezgin F, Neubauer E. Volume IV: Catalogue of the collection of instruments of the institute for the history of Arabic and Islamic sciences. In: Sezgin F. Science and technology in Islam. Frankfurt am Main, Germany: Institute for the History of Arabic-Islamic Science, 2010: 27. Copyright ©The Author(s) 2010. Published by Institute for the History of Arabic-Islamic Science (Institut für Geschichte der Arabisch-Islamischen Wissenschaften). The author has obtained the permission for figure using from the Institute for the History of Arabic-Islamic Science (Institut für Geschichte der Arabisch-Islamischen Wissenschaften) (Supplementary Material).

## CONCLUSION

Al-Halabi is an early biomedical engineer who invented various ophthalmological instruments. He is the first ophthalmologist to use a magnet for removing metallic foreign body from the eye. He utilized his instruments in the treatment of different eye diseases such as trachoma, lagophthalmos, chalazion, chemosis, symblepharon, ectropion, hordeolum, distichiasis, pannus, pterygium, and cataract. Al-Halabi's book was the first to give a remarkable illustration of the anatomy of the brain, the eyes, and the visual pathway among them. Al-Halabi detailed cataract operation representing twelve sorts of cataract in a table.

## ACKNOWLEDGEMENTS

The current research article could not come to light without the reproduction of Al-Halabi's book edited by Wafai MZ (MD, FACS, FICS, and FRCOphth) and Kalaji MR (PhD). Dr. Wafai is a chief of Vitreo-Retina Division, King Khalid Eye Specialist

Hospital, Riyadh, Saudi Arabia, and a former instructor in ophthalmology, Harvard Medical School, Boston, Massachusetts, United States. Dr. Kalaji is a professor of Islamic Studies, King Saud University, Riyadh, Saudi Arabia, and a former professor of Islamic Studies, Damascus University, Syria.

Finally, recognition must be given to the Frankfurt and Istanbul Museums for the History of Science and Technology in Islam. The Istanbul Museum has copies of the instruments that are in the Frankfurt Museum, and both museums are founded by the same person, Professor Dr. Fuat Sezgin. Institute for the History of Arab-Islamic Sciences, which runs the Frankfurt Museum, kindly and generously authorized the reproduction of the photos in this article.

## REFERENCES

- 1 **Gooday G**, Lynch JM, Wilson KG, Barsky CK. Does science education need the history of science? *Isis* 2008; **99**: 322-330 [PMID: [18702401](#) DOI: [10.1086/588690](#)]
- 2 **Valentinuzzi ME**. Why study the history of BME, science, and technology? *IEEE Pulse* 2011; **2**: 45-47 [DOI: [10.1109/MPUL.2010.939610](#)]
- 3 **Taylor HR**. Trachoma is an ancient disease and a weapon of mass destruction. In: Taylor HR. Trachoma: A blinding scourge from the bronze age to the twenty-first century. Victoria, Australia: Centre for Eye Research Australia, 2008: 1-16
- 4 **Maccallan AF**. THE BIRTH OF OPHTHALMOLOGY AND ITS DEVELOPMENT IN EARLY ARABIC LITERATURE. *Br J Ophthalmol* 1927; **11**: 63-67 [PMID: [18168595](#) DOI: [10.1136/bjo.11.2.63](#)]
- 5 **Griffith FLI**. The inscriptions. In: Petrie WMF, Griffith FLI. The royal tombs of the first dynasty. London, UK: Cambridge University Press, 1900-1901: 48-55
- 6 **Ascaso FJ**, Huerva V. The history of cataract surgery. In: Zaidi F. Cataract surgery. Rijeka, Croatia: IntechOpen, 2013: 75-90 [DOI: [10.5772/19243](#)]
- 7 **Savage-Smith E**. Hellenistic and Byzantine ophthalmology: Trachoma and sequelae. *Dumbarton Oaks Papers* 1984; **38**: 169-186
- 8 **FEIGENBAUM A**. Early history of cataract and the ancient operation for cataract. *Am J Ophthalmol* 1960; **49**: 305-326 [PMID: [13821917](#)]
- 9 **Kaadan AN**, Hamati S. The Ophthalmic Medicine in Aleppo in 100 Years 1850-1950 AD. The International Society for the History of Islamic Medicine. 2001. [cited 5 January 2021]. Available from: <http://www.ishim.net/2009/The%20Ophthalmic%20Medicine%20in%20Aleppo%20in%20100%20Years.doc>
- 10 **Abdalla M**. The fate of Islamic science between the eleventh and sixteenth-centuries: a critical study of scholarship from Ibn Khaldun to the present. Griffith University. 2004 [DOI: [10.25904/1912/2281](#)]
- 11 **Zaimeche S**. Aleppo. The Foundation for Science, Technology and Civilisation (FSTC). 2008. [cited 5 January 2021]. Available from: <http://www.muslimheritage.com/uploads/Aleppo.pdf>
- 12 **Kaadan AN**, Alherek M. Subconjunctival hemorrhage in the most famous eye Islamic medical books. *J Int Soc Hist Islam Med* 2011; **10**: 42-45
- 13 **POLLOCK WB**. Arabian ophthalmology. *Br J Ophthalmol* 1946; **30**: 445-456 [PMID: [20994655](#) DOI: [10.1136/bjo.30.8.445](#)]
- 14 **Hirschberg J**. Arabian ophthalmology. *J Am Med Assoc* 1905; **XLV**: 1127-1131 [DOI: [10.1001/jama.1905.52510160001001](#)]
- 15 **Wafai MZ**, Kalaji MR. Al-Kafi Fi Al-Kuhl by Khalifah ibn Abi Al-Mahasin Al-Halabi (died around 656AH = 1256AD). Rabat, Morocco: Islamic Educational, Scientific and Cultural Organization (ISESCO) Publications, 1990: 1-794
- 16 **Wafai MZ**. Ophthalmologists of the Medieval Islamic world. The Foundation for Science, Technology and Civilisation (FSTC). 2016. [cited 5 January 2021]. Available from: [http://www.muslimheritage.com/uploads/ophthalmologists\\_sy\\_v6\\_08\\_04.pdf](http://www.muslimheritage.com/uploads/ophthalmologists_sy_v6_08_04.pdf)
- 17 **Langermann YT**. Ibn Kammūna at Aleppo. *J R Asiat Soc* 2007; **17**: 1-19 [DOI: [10.1017/s1356186306006766](#)]
- 18 **Savage-Smith E**. Medicine in Medieval Islam. In: Lindberg DC, Shank, MH. The Cambridge history of science: Volume 2: Medieval science. Cambridge: Cambridge University Press, 2013: 139-167 [DOI: [10.1017/cho9780511974007.007](#)]
- 19 **Leclerc L**. Histoire de la Médecine Arabe (History of the Arabian Medicine). Paris, France: Ernest Laroux, 1876: 157-213
- 20 **Hirschberg J**, Lippert J, Mittwoch E. Ammar B. Ali Al-Mausili, Halifa Al-Halabi, Salah Ad-Din. In: Hirschberg J, Lippert J, Mittwoch E. Die Arabischen augenärzte (Arabian ophthalmologists). Leipzig, Germany: Verlag Von Veit & Comp, 1905: 150-153
- 21 **Haq I**, Khatib HA. Light through the dark ages: The Arabist contribution to Western ophthalmology. *Oman J Ophthalmol* 2012; **5**: 75-78 [PMID: [22993459](#) DOI: [10.4103/0974-620X.99367](#)]
- 22 **Sezgin F**, Neubauer E. Volume IV: Catalogue of the collection of instruments of the institute for the history of Arabic and Islamic sciences. In: Sezgin F. Science and technology in Islam. Frankfurt am Main, Germany: Institute for the History of Arabic-Islamic Science, 2010: 1-94

- 23 **Alvarez-Millan C.** Practice vs theory: tenth-century case histories from the Islamic Middle East. *Soc Hist Med* 2000; **13**: 293-306 [PMID: 14535258 DOI: 10.1093/shm/13.2.293]
- 24 **Saad MN.** Could Al-Zahrawi Be Considered a Biomedical Engineer? *IEEE Pulse* 2016; **7**: 56-67 [PMID: 26978854 DOI: 10.1109/MPUL.2016.2516180]
- 25 **Giasin O, Yeo DC, Aguirre A.** Just how old is the modern dacryocystorhinostomy? *Br J Ophthalmol* 2014; **98**: 1134-1135 [PMID: 24825840 DOI: 10.1136/bjophthalmol-2014-305151]
- 26 **Laios K, Moschos MM, George A.** Ammar ibn Ali al-Mawsili and His Innovating Suction Method for the Treatment of Cataract. *Surg Innov* 2016; **23**: 433 [PMID: 26603693 DOI: 10.1177/1553350615618289]
- 27 **Masic I.** On occasion of 800th anniversary of birth of Ibn al-Nafis--discoverer of cardiac and pulmonary circulation. *Med Arh* 2010; **64**: 309-313 [PMID: 21287961 DOI: 10.5455/medarh.2010.64.309-313]
- 28 **Savage-Smith E.** Ibn al-Nafis's Perfected book on ophthalmology and his treatment of trachoma and its sequelae. *J Hist Arabic Sci* 1980; **4**: 147-204 [PMID: 11611349]
- 29 **Kaadan AN, Alherek M.** Chalazion and its Treatment in Arabic and Islamic Medicine. The International Society for the History of Islamic Medicine. 2001. [cited 1 January 2021]. Available from: <http://www.ishim.net/islam/baradah.htm#2> [DOI: 10.1163/ej.97890004157224.i-272.45]
- 30 **Yedke SR, Raut SY, Jangde CR.** Experimental evaluation of horse hair as a nonabsorbable monofilament suture. *J Ayurveda Integr Med* 2013; **4**: 206-210 [PMID: 24459386 DOI: 10.4103/0975-9476.123691]
- 31 **Kaadan AN, Kakhshan, A.** Ophthalmic drops in the book of Kitab Al-Umdah Al-Kuhliyah fi Al-Amrad Al-Basariyah. *J Int Soc Hist Islam Med* **14-15**: 31-34
- 32 **Alraghran A, khatib C.** The new informations about aromatherapy and scents edited by Albucasis. *J Int Soc Hist Islam Med* **14-15**: 64-83
- 33 **Savage-Smith E.** The practice of surgery in Islamic lands: myth and reality. *Soc Hist Med* 2000; **13**: 307-321 [PMID: 14535259 DOI: 10.1093/shm/13.2.307]
- 34 **Savage-Smith E.** Anatomical illustration in arabic manuscripts. In: Contadini, A. Arab painting: Text and image in illustrated Arabic manuscripts. Leiden, Netherlands: Brill, 2010: 145-159
- 35 **Tamraz JC, Comair YG.** Optic pathway and striate cortex. In: Tamraz JC, Comair YG. Atlas of regional anatomy of the brain using MRI: With functional correlations. Berlin, Heidelberg, Germany: Springer Berlin Heidelberg, 2000: 257-298 [DOI: 10.1007/3-540-30672-2]
- 36 **Valentinuzzi ME, Pallotti G.** Leonardo: the bioengineer. *IEEE Pulse* 2013; **4**: 58, 60, 62 [PMID: 24180027 DOI: 10.1109/mpul.2013.2271417]
- 37 **Polyak SL.** The retina: the anatomy and the histology of the retina in man, ape, and monkey, including the consideration of visual functions, the history of physiological optics, and the histological laboratory technique. Chicago: The University of Chicago Press, 1941:128



Published by **Baishideng Publishing Group Inc**  
7041 Koll Center Parkway, Suite 160, Pleasanton, CA 94566, USA

**Telephone:** +1-925-3991568

**E-mail:** [bpgoffice@wjgnet.com](mailto:bpgoffice@wjgnet.com)

**Help Desk:** <https://www.f6publishing.com/helpdesk>

<https://www.wjgnet.com>

