

# World Journal of *Orthopedics*

*World J Orthop* 2021 August 18; 12(8): 515-619



## Contents

Monthly Volume 12 Number 8 August 18, 2021

## REVIEW

- 515 International recognition of the Ilizarov bone reconstruction techniques: Current practice and research (dedicated to 100<sup>th</sup> birthday of G. A. Ilizarov)

*Malkova TA, Borzunov DY*

## MINIREVIEWS

- 534 Calcar-guided short-stem total hip arthroplasty: Will it be the future standard? Review and perspectives

*Kutzner KP*

## ORIGINAL ARTICLE

## Basic Study

- 548 Fibula pro-tibia vs standard locking plate fixation in an ankle fracture saw bone model

*Okoro T, Teoh KH, Tanaka H*

## Observational Study

- 555 Thromboelastography in elective total hip arthroplasty

*Lloyd-Donald P, Lee WS, Liu GM, Bellomo R, McNicol L, Weinberg L*

## Prospective Study

- 565 Performance of alpha-defensin lateral flow test after synovial fluid centrifugation for diagnosis of periprosthetic knee infection

*Abdo RCT, Gobbi RG, Leite CBG, Pasoto SG, Leon EP, Lima ALLM, Bonfa E, Pécora JR, Demange MK*

## SYSTEMATIC REVIEWS

- 575 Limb lengthening with PRECICE magnetic nail in pediatric patients: A systematic review

*Masci G, Palmacci O, Vitiello R, Bonfiglio N, Bocchi MB, Cipolloni V, Maccauro G, Pola E*

- 584 Complications in growth-friendly spinal surgeries for early-onset scoliosis: Literature review

*Latalski M, Fatyga M, Sowa I, Wojciak M, Starobrat G, Danielewicz A*

- 604 Safety and efficacy of surgical hip dislocation in managing femoral head fractures: A systematic review and meta-analysis

*Khalifa AA, Haridy MA, Fergany A*

**ABOUT COVER**

Editorial Board Member of *World Journal of Orthopedics*, Richard Lass, MD, Assistant Professor, Department of Orthopedics, Medical University of Vienna, Vienna 1090, Austria. richard.lass@meduniwien.ac.at

**AIMS AND SCOPE**

The primary aim of *World Journal of Orthopedics* (WJO, *World J Orthop*) is to provide scholars and readers from various fields of orthopedics with a platform to publish high-quality basic and clinical research articles and communicate their research findings online.

WJO mainly publishes articles reporting research results and findings obtained in the field of orthopedics and covering a wide range of topics including arthroscopy, bone trauma, bone tumors, hand and foot surgery, joint surgery, orthopedic trauma, osteoarthropathy, osteoporosis, pediatric orthopedics, spinal diseases, spine surgery, and sports medicine.

**INDEXING/ABSTRACTING**

The WJO is now abstracted and indexed in PubMed, PubMed Central, Emerging Sources Citation Index (Web of Science), Scopus, China National Knowledge Infrastructure (CNKI), China Science and Technology Journal Database (CSTJ), and Superstar Journals Database. The 2021 edition of Journal Citation Reports® cites the 2020 Journal Citation Indicator (JCI) for WJO as 0.66. The WJO's CiteScore for 2020 is 3.2 and Scopus CiteScore rank 2020: Orthopedics and Sports Medicine is 87/262.

**RESPONSIBLE EDITORS FOR THIS ISSUE**

**Production Editor:** Yan-Xia Xing; **Production Department Director:** Xiang Li; **Editorial Office Director:** Jin-Lai Wang.

**NAME OF JOURNAL**

*World Journal of Orthopedics*

**ISSN**

ISSN 2218-5836 (online)

**LAUNCH DATE**

November 18, 2010

**FREQUENCY**

Monthly

**EDITORS-IN-CHIEF**

Massimiliano Leigheb

**EDITORIAL BOARD MEMBERS**

<http://www.wjgnet.com/2218-5836/editorialboard.htm>

**PUBLICATION DATE**

August 18, 2021

**COPYRIGHT**

© 2021 Baishideng Publishing Group Inc

**INSTRUCTIONS TO AUTHORS**

<https://www.wjgnet.com/bpg/gerinfo/204>

**GUIDELINES FOR ETHICS DOCUMENTS**

<https://www.wjgnet.com/bpg/GerInfo/287>

**GUIDELINES FOR NON-NATIVE SPEAKERS OF ENGLISH**

<https://www.wjgnet.com/bpg/gerinfo/240>

**PUBLICATION ETHICS**

<https://www.wjgnet.com/bpg/GerInfo/288>

**PUBLICATION MISCONDUCT**

<https://www.wjgnet.com/bpg/gerinfo/208>

**ARTICLE PROCESSING CHARGE**

<https://www.wjgnet.com/bpg/gerinfo/242>

**STEPS FOR SUBMITTING MANUSCRIPTS**

<https://www.wjgnet.com/bpg/GerInfo/239>

**ONLINE SUBMISSION**

<https://www.f6publishing.com>



## Limb lengthening with PRECICE magnetic nail in pediatric patients: A systematic review

Giulia Masci, Osvaldo Palmacci, Raffaele Vitiello, Nadia Bonfiglio, Maria Beatrice Bocchi, Valerio Cipolloni, Giulio Maccauro, Enrico Pola

**ORCID number:** Giulia Masci 0000-0002-2137-0145; Osvaldo Palmacci 0000-0002-1575-4003; Raffaele Vitiello 0000-0003-2321-9665; Nadia Bonfiglio 0000-0001-9973-1003; Maria Beatrice Bocchi 0000-0002-0363-4514; Valerio Cipolloni 0000-0001-8778-3105; Giulio Maccauro 0000-0002-7359-268X; Enrico Pola 0000-0001-5350-3910.

**Author contributions:** Palmacci O and Masci G designed the study; Cipolloni V and Vitiello R contributed to the data collection and data analyses; Masci G and Bonfiglio N contributed to the manuscript preparation; Bocchi MB and Pola E contributed to revising the manuscript content.

**Conflict-of-interest statement:** The authors declare that there are no conflict of interest.

**PRISMA 2009 Checklist statement:** The authors have read the PRISMA 2009 Checklist, and the manuscript was prepared and revised according to the PRISMA 2009 Checklist.

**Open-Access:** This article is an open-access article that was selected by an in-house editor and fully peer-reviewed by external reviewers. It is distributed in accordance with the Creative Commons Attribution

Giulia Masci, Osvaldo Palmacci, Raffaele Vitiello, Nadia Bonfiglio, Maria Beatrice Bocchi, Valerio Cipolloni, Giulio Maccauro, Enrico Pola, Department of Orthopaedics and Traumatology, Fondazione Policlinico Universitario A. Gemelli IRCCS, Rome 00168, Italy

Enrico Pola, Policlinico di Napoli University Hospital, Università della Campania Luigi Vanvitelli School of Medicine, Napoli 80100, Italy

**Corresponding author:** Raffaele Vitiello, MD, Doctor, Department of Orthopaedics and Traumatology, Fondazione Policlinico Universitario A. Gemelli IRCCS, Università Cattolica del Sacro Cuore, Rome 00168, Italy. [lele.vitiello@gmail.com](mailto:lele.vitiello@gmail.com)

### Abstract

#### BACKGROUND

Limb lengthening techniques play an increasingly important role in the pediatric orthopedic field. The principles of the osteogenesis distraction bonded traditionally with external fixators; however, the recent deployment of fully implantable systems has been able to overcome severities related to external fixators. The PRECICE® is an implantable limb lengthening intramedullary nail system that is remotely controlled and magnetically driven.

#### AIM

To review the current literature available on this matter in order to assess the PRECICE clinical and radiological outcomes and its possible complications in a population of pediatric patients undergoing limb lengthening.

#### METHODS

Only five studies met the inclusion criteria and were consequently included in the review for a total of 131 patients and 135 femurs. The clinical and radiological outcomes of interest were: the main lengthening obtained, the distraction rate, the period of time to full weight bearing, the consolidation index, and the Association for the Study and Application of Methods of Ilizarov score.

#### RESULTS

In conclusion, data collected from the articles under investigation were comparable with the exception of the consolidation index. Unfortunately, the study population was too small and the patients' follow-up was too short to make definitive conclusions.



NonCommercial (CC BY-NC 4.0) license, which permits others to distribute, remix, adapt, build upon this work non-commercially, and license their derivative works on different terms, provided the original work is properly cited and the use is non-commercial. See: <http://creativecommons.org/licenses/by-nc/4.0/>

**Manuscript source:** Invited manuscript

**Specialty type:** Orthopedics

**Country/Territory of origin:** Italy

**Peer-review report's scientific quality classification**

Grade A (Excellent): 0  
Grade B (Very good): 0  
Grade C (Good): 0  
Grade D (Fair): 0  
Grade E (Poor): 0

**Received:** January 29, 2021

**Peer-review started:** January 29, 2021

**First decision:** May 3, 2021

**Revised:** May 12, 2021

**Accepted:** June 22, 2021

**Article in press:** June 22, 2021

**Published online:** August 18, 2021

**P-Reviewer:** Wang XQ

**S-Editor:** Ma YJ

**L-Editor:** Filipodia

**P-Editor:** Li X



## CONCLUSION

This review shows that the PRECICE Nail System is still a therapeutic challenge in limb lengthening for pediatric orthopedic surgeons; however, careful pre-operative planning and an accurate surgical technique could allow the correction of more complex deformities with a low rate of complications.

**Key Words:** Limbs lengthening; PRECICE; Nail; Pediatric; Dysmetria; Deformities

©The Author(s) 2021. Published by Baishideng Publishing Group Inc. All rights reserved.

**Core Tip:** Limb lengthening techniques play an increasingly important role in the pediatric orthopedic field. The PRECICE® is an implantable limb lengthening intramedullary nail system that is remotely controlled and magnetically driven. The aim of our study was to review the current literature in order to assess the clinical and radiological outcomes and possible complications in a population of pediatric patients undergoing limb lengthening. This review shows that the PRECICE allows correction of the more complex deformities with a low rate of complications.

**Citation:** Maschi G, Palmacci O, Vitiello R, Bonfiglio N, Bocchi MB, Cipolloni V, Maccauro G, Pola E. Limb lengthening with PRECICE magnetic nail in pediatric patients: A systematic review. *World J Orthop* 2021; 12(8): 575-583

**URL:** <https://www.wjgnet.com/2218-5836/full/v12/i8/575.htm>

**DOI:** <https://dx.doi.org/10.5312/wjo.v12.i8.575>

## INTRODUCTION

Limb lengthening techniques play an increasingly important role in the field of pediatric orthopedics with regard to length discrepancy, angular deformities (referable either to fractures sequelae or congenital malformations), and short stature correction[1-4]. The osteogenesis distraction is a reparative process involving not only the bone but also the soft tissues including the muscles, nerves, and skin. Therefore, accurate distraction control is required since too rapid correction could lead to nonunion, nerve damage, and joint contractures, while on the other hand a process that is too slow could result in premature consolidation[5].

The principles of the osteogenesis distraction bonded traditionally with the external fixators, considering both monolateral and circular fixators[6,7]. More recently, the deployment of fully implantable systems for limb lengthening has allowed overcoming external fixator-related severities such as pin-site infections, soft tissue tethering, and patient device intolerance during treatment, to name a few[8-10]. Intramedullary nails were initially used in conjunction with external fixation in hybrid techniques such as lengthening over nail or lengthening and then nailing[11,12], in order to reduce fixator time and prevent secondary deformities. However, these techniques are not free from external fixator-related complications. Over the past couple of decades, internal bone lengthening devices have been developed to obviate the need for external fixators. They seem to decrease patients' pain and discomfort and facilitate a more rapid and effective rehabilitation compared with external fixation[13].

At present, three types of telescopic nails are mainly used: mechanically activated nails, motorized nails, and magnetically driven nails[14-16]. The PRECICE® Intramedullary Limb Lengthening System (NuVasive Specialized Orthopedics, San Diego, CA, United States) is a remotely controlled, magnetically driven, implantable limb lengthening intramedullary nail system first used in Europe in 2012[17-19]. The PRECICE nail is a magnet-operated telescopic internal lengthening device with an ERC that contains two rotating magnets[20]. When placed by the patient on the skin, above the magnet which is within the nail, it causes this internal magnet to rotate, which translates to the thinner nail element telescoping out of the thicker surrounding nail; the nail can be both extended and retracted by altering the settings on the ERC as well as accurately setting the rate of distraction. A distance of 1 mm requires the ERC to be placed over the magnet within the nail for 7 min[21].

The PRECICE represents a safe and accurate technique able to correct both deformity and limb-length discrepancy, lengthening but also shortening (unlike other lengthening nails[22]) with reduced side effects. Among the advantages of opting for this implant, there is the ability to maintain the knee range of motion during the lengthening process and also the rapid bone healing allows a relatively early return to weight bearing[23,24].

The aim of our study was to review the current literature available on this matter in order to assess the PRECICE clinical and radiological outcomes and its possible complications in a population of pediatric patients undergoing limb lengthening.

## MATERIALS AND METHODS

A systematic review of the literature indexed in PubMed MEDLINE and Cochrane Library databases using the search key word "PRECICE" was carried out. To minimize the number of missed studies, no filters were applied to the search strategy. The bibliography of the selected studies was accurately searched by hand, in order to identify further studies not found during our electronic search. No restrictions on the date of publication or language were applied. The title of the journal, name of authors, or supporting institutions were not masked at any stage. No attempt to contact authors in order to obtain individual patient data was made. The Preferred Reporting Items for Systematically Reviews and Meta-Analyses (PRISMA) was followed as reported in Figure 1. In order to be considered for this review, the articles needed to comply with the following inclusion criteria: use of the PRECICE® Intramedullary Limb Lengthening System (NuVasive Specialized Orthopedics) for femur lengthening and patient age under 18 years. No restrictions for surgical approach to nailing were applied. Abstracts and full texts were independently screened by two authors (Vitiello R and Maccauro G), and any discordance was solved by consensus with a third author (Palmacci O). The methodological quality of the studies was assessed using the modified Coleman Methodology Score (mCMS)[25]. Each article was evaluated by two independent investigators (Vitiello R and Bocchi MB); in cases with more than a five-point difference between their rating, the discrepancy was solved by consensus with a third author (Palmacci O). The mCMS ranges from 0 to 100 points, representing a well-designed study with no bias or confounding factors.

## RESULTS

The electronic search resulted in 60 hits. Following the PRISMA flow chart[26], only five studies met the inclusion criteria and were taken into consideration in the review [27-31]. Eight papers partially followed the inclusion criteria; these studies included a non-specific pediatric population. An extra analysis was performed for these latter papers. All of the selected studies were retrospectively analyzed. The target population consisted of 131 patients for a total of 135 femurs. According to the mCMS evaluation, the mean score of the studies reached was 47 points (25-57 points) showing a poor-mediocre result. The papers we took into consideration had several methodological issues, particularly when considering the procedure in assessing the outcomes. Moreover, the study population was too small and the patient's follow-up was too short. However, all of the papers accurately reported the indications for surgical intervention and the surgical technique (respectively 5 points each). Studies by Szymczuk *et al*[30] and Hammouda *et al*[32] compared the PRECICE intramedullary nailing with external fixation, but in our analysis, we only took into account the PRECICE nailing results. In studies by Nasto *et al*[27] and Iliadis *et al*[29], both retrograde and antegrade approaches were used, and some tibia nailing was included. Other studies preferred the antegrade approach to the femur.

## DISCUSSION

### *Demographic data and etiology*

We reached a population of 131 male and female patients for a total of 135 femurs. Males and females numbered 69 and 62, respectively. The mean age was 14.8 years old, ranged between 7 and 18 years old[31]. All of the studies reported pre-operative discrepancy except one[31], with a mean value of 5.2 cm (range, 4.9 to 6.3). The mean

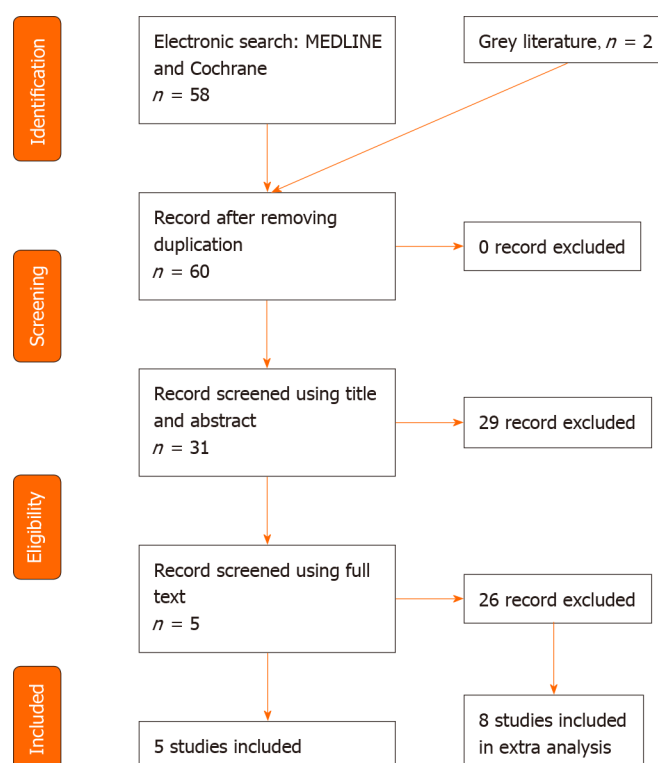


Figure 1 PRISMA flowchart.

follow-up was 1.7 years when reported (Table 1). Concerning surgical indications, one study only focused on a single pathology; in particular, Szymczuk *et al*[30] focused on congenital femoral deficiency treatment for a total of 30 femurs (Table 2). Among other papers, the principal surgical indication was congenital femoral deficiency (19 femurs), and yet post-traumatic malformations (18 femurs), achondroplasia (8 femurs), hemihypertrophy (8 femurs) and Ollier disease (6 femurs). Nevertheless, the main indication remained “miscellaneous” (46 femurs).

### Clinical and radiological outcomes

Regarding the PRECICE system results, the studies examined focused on the following issues: The main lengthening obtained with particular reference to accuracy and reliability, the distraction rate, the period to reach full weight bearing, the consolidation index, and the Association for the Study and Application of Method of Ilizarov (ASAMI) score (Table 3 and Table 4). Nail accuracy is defined as the ratio between the lengthening obtained and the planned length, while nail reliability is the ratio between the number of implanted lengthening devices and the number of successfully ended lengthening treatments. Analyzing the main lengthening obtained, the results were similar across all studies. In particular, Hammouda *et al*[31] reported a mean lengthening of 5.6 (3-6.7), with no reference to accuracy and reliability. It is relevant to notice that the authors performed intramedullary nailing using the trochanteric entry. During the follow-up time no patients showed radiographic nor clinical signs of femoral head necrosis. The average lengthening achieved reported by Nasto *et al*[27] was  $4.4 \pm 1.2$ , with a nail accuracy and reliability of 91% and 88% respectively. Iliadis *et al*[29] reported a nail accuracy of 96% and a nail reliability of 98%, due to a single case where a nail was implanted without lengthening because of the patient’s mental health issues.

The distraction index (DI), defined as the ratio between the number of days of distraction and the achieved length (days/cm), was reported in all of the studies analyzed, except for Hammouda *et al*[31]. Among the articles, the results were almost comparable. Szymczuk *et al*[30] described a DI of  $0.7 \pm 0.18$ , while Iliadis *et al*[29] reported a DI of 0.92 (0.67-1). Furthermore, this latter retrospective review was the only one considering the days to full weight bearing from lengthening accomplishment with a mean of 45 days. All patients in fact gradually obtained full weight bearing over a 4-wk period after the planned length achievement. The consolidation index (CI) is defined as the ratio between the total duration required to achieve bone healing and the achieved length (day/cm). The data collected in the articles under

Table 1 Demographic data

Ref.	Number of patients	Gender	Tibia nailing	Age (yr)	Discrepancy (cm)	Follow-up (yr)	mCMS
Hammouda <i>et al</i> [32]	28 patients; 31 femurs	17 males; 11 females	-	12.9	-	1.9	49
Szymczuk <i>et al</i> [30]	30	14 males; 16 females	-	15.4	4.9	1.9	51
Iliadis <i>et al</i> [29]	42 patients; 43 femurs	20 males; 22 females	7	15	4.9	-	54
Nasto <i>et al</i> [27]	26	15 males; 11 females	5	14.7	4.9	1.4	57
Tomaszewski <i>et al</i> [28]	5	3 males; 2 females	-	16.3	6.3	-	27

In brackets measurement unit; Data are reported as absolute value. mCMS: Modified Coleman Methodology Score.

Table 2 Etiology

Ref.	Congenital femoral deficiency	Achondroplasia	Post-traumatic	Hemihypertrophy	Ollier disease	Miscellaneous
Hammouda <i>et al</i> [32]	10	6	5	3	2	5
Szymczuk <i>et al</i> [30]	30	-	-	-	-	-
Iliadis <i>et al</i> [29]	5	2	7	5	1	23
Nasto <i>et al</i> [27]	4	-	4	-	3	15
Tomaszewski <i>et al</i> [28]	-	-	2	-	-	3

In brackets measurement unit; Data are reported as absolute values.

Table 3 Result

Ref.	Mean lengthening (cm)	Accuracy	Reliability	Distraction rate (mm/d)	Day to full weight bearing	Consolidation index (d/cm)	ASAMI functional score	ASAMI bone score
Hammouda <i>et al</i> [32]	5.6 (3-6.7)	-	-	-	-	-	-	-
Szymczuk <i>et al</i> [30]	4.75 ± 1.43	95%	-	0.7 ± 0.18	-	34.7 ± 11.2	-	-
Iliadis <i>et al</i> [29]	-	96%	98%	0.92 (0.67-1)	45 (21-132)	28 (18-43)	35 excellent; 11 good; 3 fairs; 1 poor	41 excellent; 8 good; 1 fair
Nasto <i>et al</i> [27]	4.4 ± 1.2	91%	88%	0.9 ± 0.1	-	11.9 ± 2.1	22 excellent; 3 good; 1 fair	24 excellent; 1 fair; 1 poor
Tomaszewski <i>et al</i> [28]	4.9 (4-5.8)	-	-	0.8 (0.8-1)	-	29.3 (21-33)	-	-

In brackets measurement unit; Data are reported as absolute values.

investigation were different. Nasto *et al*[27] in particular obtained a CI of 11.9 ± 2.1, while Szymczuk *et al*[30] obtained a CI of 34.7 ± 11.2. Nasto *et al*[27] and Iliadis *et al*[29] reported the modified ASAMI score, which is a scoring system that classifies clinical results into excellent, good, fair, and poor based on four different parameters. The data we collected were similar and encouraging, supporting the efficacy of this device. In the paper by Iliadis *et al*[29], patients reported a low pain score throughout the lengthening and consolidation period. No significant impact on daily living activities was reported by 66% of patients, to the extent that 92% of patients were satisfied with the surgical treatment results and felt that they had achieved their goals.

### Complications

Adverse events were divided into problems, obstacles, and complications in accordance with the data previously described by Paley[17]. Problems were defined as



Table 4 Complication

Ref.	Number of patients	Problem	Obstacle	Complication
Hammouda <i>et al</i> [32]	28 patients; 31 femurs	-	-	2
Szymczuk <i>et al</i> [30]	30	8	19	4
Iliadis <i>et al</i> [29]	42 patients; 43 femurs	7	4	4
Nasto <i>et al</i> [27]	26	5	1	3
Tomaszewski <i>et al</i> [28]	5	1	-	-

In brackets measurement unit; Data are reported as absolute values. Problems are post-operative difficulties that resolved completely with non-operative intervention; obstacles were difficulties that needed an operative intervention, resolved completely after surgery; complications consisted of all intra- and post-operative complications that remained unresolved even after treatment was completed.

difficulties after the surgical procedure resolved with conservative treatment, obstacles were difficulties that required surgical treatment, and complications were true intra or post-operative complications that persisted after the treatment. Hammouda *et al*[31] reported no problems or obstacles in 28 patients and two complications. Among them, 1 patient developed hip subluxation and delayed union of the regenerate, which was treated surgically. In addition, the nail was exchanged 6 mo after surgery. Iliadis *et al* [29] reported instead seven problems, four obstacles, and four complications. In 7 cases, they reported joint stiffness during the lengthening period, which was resolved with physiotherapy and by slowing down the distraction. Two femoral nails required the locking bolts removal as they were causing discomfort after consolidation. One patient with fibrous dysplasia, who previously underwent proximal femoral osteotomy with locking plate fixation, had a periprosthetic fracture so the PRECICE was exchanged with a trauma nail, but with loss of about 30 mm of lengthening.

Tomaszewski *et al*[28] reported no inflammatory complications, but in 1 case, after a lengthening of more than 45 mm, they noted a knee flexion contracture of about 10° despite the physiotherapy. Moreover, they had to stop the lengthening treatment in 1 case due to the pain and femoral nerve paresthesia. In the retrospective multi-center study conducted by Nasto *et al*[27], a total of five problems (joint contractures), one obstacle (femur fracture), and three complications (hip subluxation, 1 deep infection and 1 nail running back) were encountered. No bone healing complications were reported. Considering the patient who developed deep infection, the treatment was suspended and the nail removed. Regarding the case of hip subluxation, we would like to note that the patient had a developmental hip dysplasia history treated with proximal femur varus derotation osteotomy (VDRO) and Dega osteotomy. This complication was surgically treated with periacetabular osteotomy and VDRO; at the latest follow-up, the patient was asymptomatic and pain free during walking.

### Non-specific pediatric population

Analyzing the entire population, a great heterogeneity has emerged in terms of age (7-72), male/female ratio, surgical access and surgical site[18,19,21,32-36]. The rise in the average population age has led to an increase of post-traumatic etiology[32], although the congenital and syndromic causes are still well represented[18,32,36]. All of the reviewed articles analyzed both femoral and tibial lengthening nails outcomes, except one[32]. In a retrospective review by Wagner *et al*[18], both PRECICE nail accuracy and precision reached 97.3% and 92.4%, respectively, with a total of nine complications (28%), all of which were successfully resolved without any long-term sequelae. In his 24-nail series, Kirane *et al*[21] revealed an accuracy of 96% and a precision of 86% with only one (4%) implant-related failure caused by a non-functional distractor mechanism and 6 (24%) non-implant-related obstacles; the minimum follow-up was 3 wk (mean 14 wk). In a different 9 case series by Wiebking *et al*[34], there were significant differences regarding the lengthening goal achievement and thus also the full weight bearing among patients. Consequently, the accuracy and the precision rate were 78% *vs* 61%, respectively. Despite the complications, patient satisfaction was generally positive.

A slight improvement in the quality of life was shown in preoperative and 12-mo postoperative Enneking scores; no differences were revealed in the physical and mental SF-12 score[18].

Concerning complications, a low complication rate was demonstrated in a series of 17 post-traumatic femoral lengthening nails with 2.2-year follow-up[32]. Hammouda *et al*[32] reported 3 patients (18%) with non-implant related complications that all resolved without permanent sequelae. Similar outcomes were reported by Horn *et al* [35] who described 8 of 50 complications, which were treated by surgery without sequelae and therefore were graded as obstacles. However, in this study, 16 nails were not PRECICE[35].

## CONCLUSION

This review shows that the PRECICE Nail System is still a therapeutic challenge in limb lengthening for pediatric orthopedic surgeons. In the literature, only few studies have been published; nevertheless, the outcome demonstrates excellent clinical results and patient satisfaction. Careful pre-operative planning and an accurate surgical technique could allow correction of the more complex deformities with a low rate of complications.

## ARTICLE HIGHLIGHTS

### Research background

Limb lengthening devices have evolved in the last century to correct limb length discrepancies, congenital short statures, and limb deformities. The unilateral external fixator has been the standard method of fixation for a long time; however, the method of fixation has rapidly evolved from unilateral external fixator to the ring fixator, to the computer-assisted fixator, and finally to the lengthening of intramedullary nails.

### Research motivation

The large number of complications related to the use of external fixation has led to the development of alternatives. The PRECICE represents an innovative and less invasive option to external fixation with regard to limb lengthening, allowing a controlled lengthening phase with the ability to shorten and regulate the device if necessary.

### Research objectives

To review the current literature available on the specific matter in order to assess the PRECICE clinical and radiological outcomes and its possible complications in a population of pediatric patients undergoing femur lengthening.

### Research methods

The current study is the result of a systematic review of the available literature using a single search term "PRECICE". The articles were sorted according to both pre-determined inclusion and exclusion criteria. PRISMA was followed.

### Research results

Five studies met the inclusion criteria for a total of 131 patients. The studies examined focused on the following issues: the main lengthening obtained, the distraction rate, the number of days necessary to reach full weight bearing, the consolidation index and the ASAMI score. Among the articles all the results were almost comparable with the only exception of the consolidation index. Adverse events that emerged in a low percentage were divided into problems, obstacles, and complications.

### Research conclusions

Although the PRECICE nail system is still a therapeutic challenge, the results have shown excellent clinical results and patient satisfaction with a low rate of complications. Therefore this approach could represent a valid alternative to the traditional limb lengthening systems.

### Research perspectives

Future studies on larger and more homogeneous samples are needed to validate the use of PRECICE.

# REFERENCES

- 1 **Popkov A**, Dučić S, Lazović M, Lascombes P, Popkov D. Limb lengthening and deformity correction in children with abnormal bone. *Injury* 2019; **50** Suppl 1: S79-S86 [PMID: [30987742](#) DOI: [10.1016/j.injury.2019.03.045](#)]
- 2 **Chilbule SK**, Dutt V, Madhuri V. Limb lengthening in achondroplasia. *Indian J Orthop* 2016; **50**: 397-405 [PMID: [27512222](#) DOI: [10.4103/0019-5413.185604](#)]
- 3 **Alrabai HM**, Gesheff MG, Conway JD. Use of internal lengthening nails in post-traumatic sequelae. *Int Orthop* 2017; **41**: 1915-1923 [PMID: [28389837](#) DOI: [10.1007/s00264-017-3466-6](#)]
- 4 **Vitiello R**, Lillo M, Donati F, Maschi G, Noia G, De Santis V, Maccauro G. Locking plate fixation in pediatric femur fracture: evaluation of the outcomes in our experience. *Acta Biomed* 2019; **90**: 110-115 [PMID: [30715008](#) DOI: [10.23750/abm.v90i1-S.8109](#)]
- 5 **Ippolito E**, Peretti G, Bellocchi M, Farsetti P, Tudisco C, Caterini R, De Martino C. Histology and ultrastructure of arteries, veins, and peripheral nerves during limb lengthening. *Clin Orthop Relat Res* 1994; **54**: 54-62 [PMID: [7955701](#)]
- 6 **Calder PR**, Faimali M, Goodier WD. The role of external fixation in paediatric limb lengthening and deformity correction. *Injury* 2019; **50** Suppl 1: S18-S23 [PMID: [30987743](#) DOI: [10.1016/j.injury.2019.03.049](#)]
- 7 **Ilizarov GA**. Clinical application of the tension-stress effect for limb lengthening. *Clin Orthop Relat Res* 1990; **8**: 26 [PMID: [2403497](#)]
- 8 **Hosny GA**. Limb lengthening history, evolution, complications and current concepts. *J Orthop Traumatol* 2020; **21**: 3 [PMID: [32140790](#) DOI: [10.1186/s10195-019-0541-3](#)]
- 9 **Green SA**. Complications of external skeletal fixation. *Clin Orthop Relat Res* 1983; **109**: 109-116 [PMID: [6627782](#)]
- 10 **Farsetti P**, De Maio F, Potenza V, Efremov K, Marsiolo M, Caterini A, Ippolito E. Lower limb lengthening over an intramedullary nail: a long-term follow-up study of 28 cases. *J Orthop Traumatol* 2019; **20**: 30 [PMID: [31506759](#) DOI: [10.1186/s10195-019-0538-y](#)]
- 11 **Axelrod D**, Rubinger L, Shah A, Guy P, Johal H. How should we lengthen post-traumatic limb defects? *Eur J Orthop Surg Traumatol* 2020 [PMID: [33222112](#) DOI: [10.1007/s00590-020-02831-y](#).]
- 12 **Paley D**, Herzenberg JE, Paremian G, Bhav A. Femoral lengthening over an intramedullary nail. A matched-case comparison with Ilizarov femoral lengthening. *J Bone Joint Surg Am* 1997; **79**: 1464-1480 [PMID: [9378732](#) DOI: [10.2106/00004623-199710000-00003](#)]
- 13 **Socci AR**, Horn D, Fornari ED, Lakra A, Schulz JF, Sharkey MS. What's New in Pediatric Limb Lengthening and Deformity Correction? *J Pediatr Orthop* 2020; **40**: e598-e602 [PMID: [31688516](#) DOI: [10.1097/BPO.0000000000001456](#)]
- 14 **Thonse R**, Herzenberg JE, Standard SC, Paley D. Limb Lengthening with a Fully Implantable, Telescopic, Intramedullary Nail. *Oper Tech Orthop* 2005; **15**: 355-362 [DOI: [10.1053/j.oto.2005.08.007](#)]
- 15 **Cole JD**, Justin D, Kasparis T, DeVlugt D, Knobloch C. The intramedullary skeletal kinetic distractor (ISKD): first clinical results of a new intramedullary nail for lengthening of the femur and tibia. *Injury* 2001; **32** Suppl 4: S129-S139 [PMID: [11812486](#) DOI: [10.1016/s0020-1383\(01\)00116-4](#)]
- 16 **Baumgart R**, Betz A, Schweiberer L. A fully implantable motorized intramedullary nail for limb lengthening and bone transport. *Clin Orthop Relat Res* 1997; **135**: 135-143 [PMID: [9345218](#)]
- 17 **Paley D**. PRECICE intramedullary limb lengthening system. *Expert Rev Med Devices* 2015; **12**: 231-249 [PMID: [25692375](#) DOI: [10.1586/17434440.2015.1005604](#)]
- 18 **Wagner P**, Burghardt RD, Green SA, Specht SC, Standard SC, Herzenberg JE. PRECICE® magnetically-driven, telescopic, intramedullary lengthening nail: pre-clinical testing and first 30 patients. *SICOT J* 2017; **3**: 19 [PMID: [29785927](#) DOI: [10.1051/sicotj/2016048](#)]
- 19 **Schiedel FM**, Vogt B, Tretow HL, Schuhknecht B, Gosheger G, Horter MJ, Rödl R. How precise is the PRECICE compared to the ISKD in intramedullary limb lengthening? *Acta Orthop* 2014; **85**: 293-298 [PMID: [24758320](#) DOI: [10.3109/17453674.2014.913955](#)]
- 20 **Calder PR**, Laubscher M, Goodier WD. The role of the intramedullary implant in limb lengthening. *Injury* 2017; **48** Suppl 1: S52-S58 [PMID: [28449859](#) DOI: [10.1016/j.injury.2017.04.028](#)]
- 21 **Kirane YM**, Fragomen AT, Rozbruch SR. Precision of the PRECICE internal bone lengthening nail. *Clin Orthop Relat Res* 2014; **472**: 3869-3878 [PMID: [24682741](#) DOI: [10.1007/s11999-014-3575-0](#)]
- 22 **Kariksiz M**, Karakoyun O. Limb lengthening with one Precice nail over its capacity. *Saudi Med J* 2019; **40**: 1058-1062 [PMID: [31588487](#) DOI: [10.15537/mj.2019.10.24019](#)]
- 23 **Couto A**, Freitas J, Alegrate N, Coutinho J, Costa G. Two consecutive limb lengthenings with the same PRECICE nail: a technical note. *Strategies Trauma Limb Reconstr* 2018; **13**: 199-204 [PMID: [30232655](#) DOI: [10.1007/s11751-018-0317-y](#)]
- 24 **Chaudhary M**. Limb lengthening over a nail can safely reduce the duration of external fixation. *Indian J Orthop* 2008; **42**: 323-329 [PMID: [19753160](#) DOI: [10.4103/0019-5413.41857](#)]
- 25 **Coleman BD**, Khan KM, Maffulli N, Cook JL, Wark JD. Studies of surgical outcome after patellar tendinopathy: clinical significance of methodological deficiencies and guidelines for future studies. Victorian Institute of Sport Tendon Study Group. *Scand J Med Sci Sports* 2000; **10**: 2-11 [PMID: [10693606](#) DOI: [10.1034/j.1600-0838.2000.010001002.x](#)]
- 26 **Liberati A**, Altman DG, Tetzlaff J, Mulrow C, Gøtzsche PC, Ioannidis JP, Clarke M, Devereaux PJ, Kleijnen J, Moher D. The PRISMA statement for reporting systematic reviews and meta-analyses of

- studies that evaluate healthcare interventions: explanation and elaboration. *BMJ* 2009; **339**: b2700 [PMID: 19622552 DOI: 10.1136/bmj.b2700]
- 27 **Nasto LA**, Coppa V, Riganti S, Ruzzini L, Manfrini M, Campanacci L, Palmacci O, Boero S. Clinical results and complication rates of lower limb lengthening in paediatric patients using the PRECICE 2 intramedullary magnetic nail: a multicentre study. *J Pediatr Orthop B* 2020; **29**: 611-617 [PMID: 31904740 DOI: 10.1097/BPB.0000000000000651]
- 28 **Tomaszewski R**, Wiktor Ł, Kler J, Pethe K, Gap A. Results of Femoral Elongation Treatment Using Electromagnetic Intramedullary Nail. Preliminary Report. *Ortop Traumatol Rehabil* 2020; **22**: 173-179 [PMID: 32732445 DOI: 10.5604/01.3001.0014.3233]
- 29 **Iliadis AD**, Palloni V, Wright J, Goodier D, Calder P. Pediatric Lower Limb Lengthening Using the PRECICE Nail: Our Experience With 50 Cases. *J Pediatr Orthop* 2021; **41**: e44-e49 [PMID: 32947442 DOI: 10.1097/BPO.0000000000001672]
- 30 **Szymczuk VL**, Hammouda AI, Gesheff MG, Standard SC, Herzenberg JE. Lengthening With Monolateral External Fixation Versus Magnetically Motorized Intramedullary Nail in Congenital Femoral Deficiency. *J Pediatr Orthop* 2019; **39**: 458-465 [PMID: 31503231 DOI: 10.1097/BPO.0000000000001047]
- 31 **Hammouda AI**, Jauregui JJ, Gesheff MG, Standard SC, Herzenberg JE. Trochanteric Entry for Femoral Lengthening Nails in Children: Is It Safe? *J Pediatr Orthop* 2017; **37**: 258-264 [PMID: 28481811 DOI: 10.1097/BPO.0000000000000636]
- 32 **Hammouda AI**, Jauregui JJ, Gesheff MG, Standard SC, Conway JD, Herzenberg JE. Treatment of Post-Traumatic Femoral Discrepancy With PRECICE Magnetic-Powered Intramedullary Lengthening Nails. *J Orthop Trauma* 2017; **31**: 369-374 [PMID: 28379937 DOI: 10.1097/BOT.0000000000000828]
- 33 **Karakoyun O**, Sokucu S, Erol MF, Kucukkaya M, Kabukçuoğlu YS. Use of a magnetic bone nail for lengthening of the femur and tibia. *J Orthop Surg (Hong Kong)* 2016; **24**: 374-378 [PMID: 28031510 DOI: 10.1177/1602400321]
- 34 **Wiebking U**, Liodakis E, Kenawey M, Krettek C. Limb Lengthening Using the PRECICE™ Nail System: Complications and Results. *Arch Trauma Res* 2016; **5**: e36273 [PMID: 28144605 DOI: 10.5812/atr.36273]
- 35 **Horn J**, Hvid I, Huhnstock S, Breen AB, Steen H. Limb lengthening and deformity correction with externally controlled motorized intramedullary nails: evaluation of 50 consecutive lengthenings. *Acta Orthop* 2019; **90**: 81-87 [PMID: 30371122 DOI: 10.1080/17453674.2018.1534321]
- 36 **Shabtai L**, Specht SC, Standard SC, Herzenberg JE. Internal lengthening device for congenital femoral deficiency and fibular hemimelia. *Clin Orthop Relat Res* 2014; **472**: 3860-3868 [PMID: 24664194 DOI: 10.1007/s11999-014-3572-3]



Published by **Baishideng Publishing Group Inc**  
7041 Koll Center Parkway, Suite 160, Pleasanton, CA 94566, USA

**Telephone:** +1-925-3991568

**E-mail:** [bpgoffice@wjgnet.com](mailto:bpgoffice@wjgnet.com)

**Help Desk:** <https://www.f6publishing.com/helpdesk>

<https://www.wjgnet.com>

