

# World Journal of *Gastroenterology*

*World J Gastroenterol* 2021 September 28; 27(36): 5989-6160



## FRONTIER

- 5989 Fluorescent cholangiography: An up-to-date overview twelve years after the first clinical application  
*Pesce A, Piccolo G, Lecchi F, Fabbri N, Diana M, Feo CV*

## REVIEW

- 6004 Histone methylation in pancreatic cancer and its clinical implications  
*Liu XY, Guo CH, Xi ZY, Xu XQ, Zhao QY, Li LS, Wang Y*
- 6025 Hepatitis B virus infection and hepatocellular carcinoma in sub-Saharan Africa: Implications for elimination of viral hepatitis by 2030?  
*Amponsah-Dacosta E*

## MINIREVIEWS

- 6039 Liver disease in the era of COVID-19: Is the worst yet to come?  
*Mikolasevic I, Bozic D, Pavić T, Ruzic A, Hauser G, Radic M, Radic-Kristo D, Razov-Radas M, Puljiz Z, Milic S*
- 6053 Treatment of hepatitis B virus infection in children and adolescents  
*Stinco M, Rubino C, Trapani S, Indolfi G*

## ORIGINAL ARTICLE

## Basic Study

- 6064 CircRNA\_0084927 promotes colorectal cancer progression by regulating miRNA-20b-3p/glutathione S-transferase mu 5 axis  
*Liu F, Xiao XL, Liu YJ, Xu RH, Zhou WJ, Xu HC, Zhao AG, Xu YX, Dang YQ, Ji G*
- 6079 Exosomal microRNA-588 from M2 polarized macrophages contributes to cisplatin resistance of gastric cancer cells  
*Cui HY, Rong JS, Chen J, Guo J, Zhu JQ, Ruan M, Zuo RR, Zhang SS, Qi JM, Zhang BH*

## Case Control Study

- 6093 Evaluation of biomarkers, genetic mutations, and epigenetic modifications in early diagnosis of pancreatic cancer  
*Rah B, Bandy MA, Bhat GR, Shah OJ, Jeelani H, Kawoosa F, Yousuf T, Afroze D*

## Retrospective Study

- 6110 Impact of radiogenomics in esophageal cancer on clinical outcomes: A pilot study  
*Brancato V, Garbino N, Mannelli L, Aiello M, Salvatore M, Franzese M, Cavaliere C*

- 6128** Clinicopathological characteristics and longterm survival of patients with synchronous multiple primary gastrointestinal stromal tumors: A propensity score matching analysis

*Wu H, Li C, Li H, Shang L, Jing HY, Liu J, Fang Z, Du FY, Liu Y, Fu MD, Jiang KW, Li LP*

#### Observational Study

- 6142** Urotensin II levels in patients with inflammatory bowel disease

*Alicic D, Martinovic D, Rusic D, Zivkovic PM, Tadin Hadjina I, Vilovic M, Kumric M, Tokic D, Supe-Domic D, Lupi-Ferandin S, Bozic J*

#### CASE REPORT

- 6154** Inverted Meckel's diverticulum diagnosed using capsule endoscopy: A case report

*El Hajra Martínez I, Calvo M, Martínez-Porras JL, Gomez-Pimpollo Garcia L, Rodriguez JL, Leon C, Calleja Panero JL*



**ABOUT COVER**

Editorial Board Member of *World Journal of Gastroenterology*, Mark D Gorrell, BSc, PhD, Professor of Liver Science, Head, Liver Enzymes in Metabolism and Inflammation Program, Centenary Institute, Faculty of Medicine and Health, The University of Sydney, New South Wales 2006, Australia. m.gorrell@centenary.org.au

**AIMS AND SCOPE**

The primary aim of *World Journal of Gastroenterology* (WJG, *World J Gastroenterol*) is to provide scholars and readers from various fields of gastroenterology and hepatology with a platform to publish high-quality basic and clinical research articles and communicate their research findings online. WJG mainly publishes articles reporting research results and findings obtained in the field of gastroenterology and hepatology and covering a wide range of topics including gastroenterology, hepatology, gastrointestinal endoscopy, gastrointestinal surgery, gastrointestinal oncology, and pediatric gastroenterology.

**INDEXING/ABSTRACTING**

The WJG is now indexed in Current Contents®/Clinical Medicine, Science Citation Index Expanded (also known as SciSearch®), Journal Citation Reports®, Index Medicus, MEDLINE, PubMed, PubMed Central, and Scopus. The 2021 edition of Journal Citation Report® cites the 2020 impact factor (IF) for WJG as 5.742; Journal Citation Indicator: 0.79; IF without journal self cites: 5.590; 5-year IF: 5.044; Ranking: 28 among 92 journals in gastroenterology and hepatology; and Quartile category: Q2. The WJG's CiteScore for 2020 is 6.9 and Scopus CiteScore rank 2020: Gastroenterology is 19/136.

**RESPONSIBLE EDITORS FOR THIS ISSUE**

Production Editor: Jia-Hui Li; Production Department Director: Yu-Jie Ma; Editorial Office Director: Ze-Mao Gong.

**NAME OF JOURNAL**

*World Journal of Gastroenterology*

**ISSN**

ISSN 1007-9327 (print) ISSN 2219-2840 (online)

**LAUNCH DATE**

October 1, 1995

**FREQUENCY**

Weekly

**EDITORS-IN-CHIEF**

Andrzej S Tarnawski, Subrata Ghosh

**EDITORIAL BOARD MEMBERS**

<http://www.wjgnet.com/1007-9327/editorialboard.htm>

**PUBLICATION DATE**

September 28, 2021

**COPYRIGHT**

© 2021 Baishideng Publishing Group Inc

**INSTRUCTIONS TO AUTHORS**

<https://www.wjgnet.com/bpg/gerinfo/204>

**GUIDELINES FOR ETHICS DOCUMENTS**

<https://www.wjgnet.com/bpg/GerInfo/287>

**GUIDELINES FOR NON-NATIVE SPEAKERS OF ENGLISH**

<https://www.wjgnet.com/bpg/gerinfo/240>

**PUBLICATION ETHICS**

<https://www.wjgnet.com/bpg/GerInfo/288>

**PUBLICATION MISCONDUCT**

<https://www.wjgnet.com/bpg/gerinfo/208>

**ARTICLE PROCESSING CHARGE**

<https://www.wjgnet.com/bpg/gerinfo/242>

**STEPS FOR SUBMITTING MANUSCRIPTS**

<https://www.wjgnet.com/bpg/GerInfo/239>

**ONLINE SUBMISSION**

<https://www.f6publishing.com>

## Inverted Meckel's diverticulum diagnosed using capsule endoscopy: A case report

Ismael El Hajra Martínez, Marta Calvo, José Luis Martínez-Porras, Lucia Gomez-Pimpollo Garcia, Jose L Rodriguez, Carmen Leon, José Luis Calleja Panero

**ORCID number:** Ismael El Hajra Martínez [0000-0002-7802-0920](https://orcid.org/0000-0002-7802-0920); Marta Calvo [0000-0003-0744-8636](https://orcid.org/0000-0003-0744-8636); José Luis Martínez-Porras [0000-0003-0560-9213](https://orcid.org/0000-0003-0560-9213); Lucia Gomez-Pimpollo Garcia [0000-0001-8914-8500](https://orcid.org/0000-0001-8914-8500); Jose L Rodriguez [0000-0003-0513-1707](https://orcid.org/0000-0003-0513-1707); Carmen Leon [0000-0003-1971-9253](https://orcid.org/0000-0003-1971-9253); José Luis Calleja Panero [0000-0002-2265-6591](https://orcid.org/0000-0002-2265-6591).

**Author contributions:** El Hajra Martínez I and Calvo M contributed to the manuscript design and drafting, and reviewed the literature; Martínez-Porras JL performed capsule endoscopy, and interpretation and revision of the manuscript; Gomez-Pimpollo Garcia L contributed to analysis and interpretation of the imaging findings, and revision of the manuscript; Rodriguez JL contributed to pathological examination and revision of the manuscript; Leon C performed laparoscopic surgery and manuscript drafting; Calleja Panero JL and Calvo M were responsible for revision of the manuscript for important intellectual content; All authors issued final approval for the version to be submitted.

**Informed consent statement:** The patient provided informed written consent prior to treatment.

**Ismael El Hajra Martínez, Marta Calvo, José Luis Martínez-Porras,** Department of Gastroenterology, Hospital Universitario Puerta de Hierro, Madrid 28222, Spain

**Lucia Gomez-Pimpollo Garcia,** Department of Radiology, Hospital Universitario Puerta de Hierro, Madrid 28222, Spain

**Jose L Rodriguez,** Department of Diagnostic Pathology, Hospital Universitario Puerta de Hierro, Madrid 28222, Spain

**Carmen Leon,** Department of Surgery, Hospital Universitario Puerta de Hierro, Madrid 28222, Spain

**José Luis Calleja Panero,** Department of Gastroenterology, Hospital Universitario Puerta de Hierro, Madrid 28222, Spain

**Corresponding author:** Marta Calvo, PhD, Doctor, Department of Gastroenterology, Hospital Universitario Puerta de Hierro, Calle Joaquín Rodrigo, 1, Majadahonda, Madrid 28222, Spain. [calvo.marta@gmail.com](mailto:calvo.marta@gmail.com)

### Abstract

#### BACKGROUND

Meckel's diverticulum is a common asymptomatic congenital gastrointestinal anomaly. However, its presentation as an inverted Meckel's diverticulum is a rare complication, of which few cases have been reported in the literature.

#### CASE SUMMARY

Here, we report the case of a 33-year-old man with iron deficiency anemia without manifestation of gastrointestinal bleeding. An upper gastrointestinal endoscopy and total colonoscopy were performed, but no abnormalities were found within the observed area. Finally, a capsule endoscopy was performed and offered us a clue to subsequently confirm the diagnosis of inverted Meckel's diverticulum *via* computed tomography scan. Laparoscopic intestinal resection surgery was performed. The final pathology report described a Meckel's diverticulum.

#### CONCLUSION

Since inverted Meckel's diverticulum is an uncommon disease and its clinical presentation is not specific, it may go undetected by capsule endoscopy.

**Conflict-of-interest statement:** The authors declare having no conflicts of interest.

**CARE Checklist (2016) statement:**

The authors have read the CARE Checklist (2016), and the manuscript was prepared and revised according to the CARE Checklist (2016).

**Open-Access:** This article is an open-access article that was selected by an in-house editor and fully peer-reviewed by external reviewers. It is distributed in accordance with the Creative Commons Attribution NonCommercial (CC BY-NC 4.0) license, which permits others to distribute, remix, adapt, build upon this work non-commercially, and license their derivative works on different terms, provided the original work is properly cited and the use is non-commercial. See: <http://creativecommons.org/licenses/by-nc/4.0/>

**Manuscript source:** Unsolicited manuscript

**Specialty type:** Gastroenterology and hepatology

**Country/Territory of origin:** Spain

**Peer-review report's scientific quality classification**

Grade A (Excellent): 0  
Grade B (Very good): B, B, B  
Grade C (Good): 0  
Grade D (Fair): 0  
Grade E (Poor): 0

**Received:** February 25, 2021

**Peer-review started:** February 25, 2021

**First decision:** April 29, 2021

**Revised:** May 13, 2021

**Accepted:** August 16, 2021

**Article in press:** August 16, 2021

**Published online:** September 28, 2021

**P-Reviewer:** Cami MM, Raczy I, Sulbaran MN

**S-Editor:** Wang JL

**L-Editor:** Filipodia

**P-Editor:** Li JH

Successful diagnosis and treatment of this disease requires a high index of clinical suspicion.

**Key Words:** Inverted Meckel's diverticulum; Capsule endoscopy; Anemia study; Small bowel tumor; Case report

©The Author(s) 2021. Published by Baishideng Publishing Group Inc. All rights reserved.

**Core Tip:** Inverted Meckel's diverticulum is an uncommon disease with a wide spectrum of accompanying nonspecific symptoms. We present, here, a case of iron deficiency anemia with negative endoscopic study, in which capsule endoscopy played a key role in confirming the diagnosis. Since inverted Meckel's diverticulum is an uncommon disease with few cases described in the literature, this report aims to contribute more information concerning the clinical characteristics as well as radiological and capsule endoscopy findings of inverted Meckel's diverticulum that can help clinicians make the correct diagnosis.

**Citation:** El Hajra Martínez I, Calvo M, Martínez-Porras JL, Gomez-Pimpollo Garcia L, Rodriguez JL, Leon C, Calleja Panero JL. Inverted Meckel's diverticulum diagnosed using capsule endoscopy: A case report. *World J Gastroenterol* 2021; 27(36): 6154-6160

**URL:** <https://www.wjgnet.com/1007-9327/full/v27/i36/6154.htm>

**DOI:** <https://dx.doi.org/10.3748/wjg.v27.i36.6154>

## INTRODUCTION

Meckel's diverticulum is a common congenital gastrointestinal anomaly which is a remnant of the omphalomesenteric duct[1]. It is often within 100 cm of the ileocecal valve and located in the antimesenteric surface of the ileum[2]. According to autopsy studies, this condition is found in 0.3%-2% of the general population[3,4].

Patients with Meckel's diverticulum are usually asymptomatic. However, up to 6.4% develop complications that require surgery[5]. The most common complications are gastrointestinal bleeding in association with ectopic gastric and/or pancreatic mucosa, intestinal obstruction, intussusceptions, diverticulitis or volvulus. The inversion of Meckel's diverticulum is a rare complication with a pathophysiology not clearly understood, that can be a clinical challenge given its diagnostic difficulty. Moreover, the clinical presentation is nonspecific, the most frequent mode of presentation being intussusception, abdominal pain, anemia or gastrointestinal bleeding[6].

Although Meckel's diverticulum is the most common congenital anomaly of the small bowel, inversion or invagination of the diverticulum is a rare occurrence. To date, there are only around 100 cases in the literature that demonstrate the presence of inverted Meckel's diverticulum.

Herein, we present the case of iron deficiency anemia without manifestation of gastrointestinal bleeding, in which capsule endoscopy played a key role in the final diagnosis of inverted Meckel's diverticulum.

## CASE PRESENTATION

### Chief complaints

A 33-year-old male with no significant medical history presented to the emergency room with progressive weakness, easy fatigability and headache. He had no evidence of lower or upper gastrointestinal bleeding and he reported no abdominal pain, nausea, vomiting, anorexia, fever or weight loss.

### History of present illness

The patient's symptoms started 3 wk prior and had worsened over the last 4 d.



### History of past illness

There was no significant medical history.

### Personal and family history

There was no significant medical history.

### Physical examination

In the emergency room, the patient was clinically stable, with a normal temperature (36.7 °C). The patient exhibited an oxygen saturation level of 97% while he was breathing ambient air. His blood pressure was 102/61 mmHg and his heart rate was 91 beats per minute. The patient was awake, alert, and fully oriented. Physical examination revealed signs of pallor and an absence of lymphadenopathy, hepatosplenomegaly, bone tenderness or jaundice. Examination of the rectum revealed a few external hemorrhoids, but there was no blood or melena in the rectal vault; there were no skin tags, fissures or palpable masses.

### Laboratory examinations

The initial laboratory findings showed low hemoglobin levels (7 g/dL), a white blood cell count of 11250 per mm<sup>3</sup>, a platelet count of 221000 per mm<sup>3</sup> and a C-reactive protein of 1.31 mg/dL. Two pints of packed red blood cells were therefore transfused and the patient was admitted to the gastroenterology department. Electrocardiography (ECG) showed sinus rhythm at 93 beats per minute and the results of the patient's chest radiography were normal.

The patient's next blood test, showed a mean corpuscular volume of 72.5 fl, a mean corpuscular hemoglobin of 25.6 pg, and a reticulocyte count of 1%. The patient's iron level was 38 µg/dL, his ferritin level was 17 ng/mL, and his transferrin saturation was 9%. The hemolysis study was negative. Hence, the patient's anemia was classified as iron deficiency anemia.

### Imaging examinations

During this period, an upper gastrointestinal endoscopy and a colonoscopy were performed to study the patient's anemia. The colonoscopy revealed internal hemorrhoids without any other relevant findings while the upper gastrointestinal endoscopy showed no abnormalities. The patient remained stable and was discharged and the study was completed on an outpatient basis with oral iron treatment.

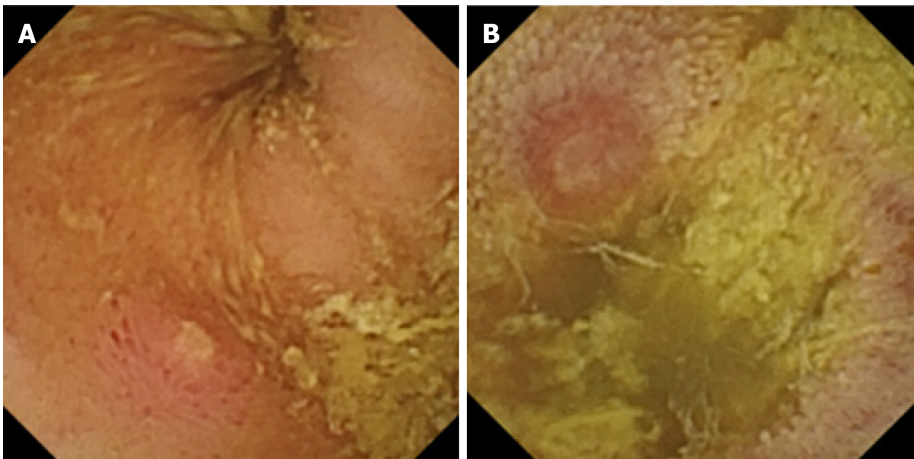
During his visit to the outpatient clinic 3 wk later, the patient remained anemic, with a hemoglobin level of 8.8 g/dL. The anemia study was completed with a capsule endoscopy, which revealed a lifted erosion and mild bulge in the ileum of approximately 8-9 mm in size (Figure 1). These findings of appearance of a subepithelial bulge in the ileum suggested an inverted Meckel diverticulum. Normal intestinal mucosa was seen on the surface of the tumor with a longer small intestine transit time suggestive of Meckel's diverticulum. A technetium-99m pertechnetate radioisotope scintigraphy (Meckel's scan) was performed and was negative. The patient subsequently underwent an ultrasound examination, which revealed no pathological findings. Finally, an abdominal computed tomography (CT) was performed and showed a central area of fat attenuation surrounded by a thick collar of soft tissue attenuation (Figure 2) suggestive of inverted Meckel's diverticulum.

## FINAL DIAGNOSIS

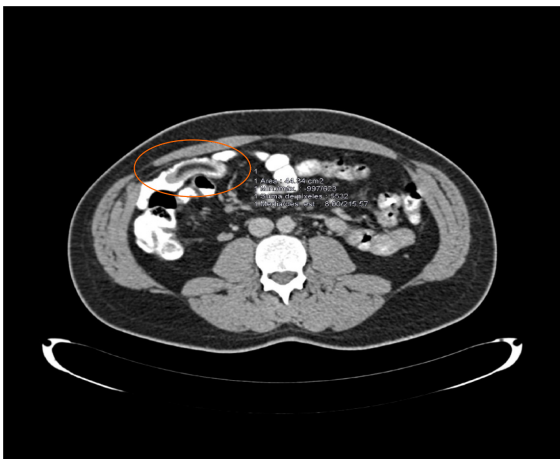The patient was diagnosed with an inverted Meckel's diverticulum and underwent a laparoscopic surgery. A large intraluminal polyp-like mass in the mid-ileum was observed. The remainder of the small bowel was normal to the level of the ligament of Treitz. A segmentary resection of the small bowel with adequate margin was performed and side-to-side anastomosis was carried out using a stapling device.

On gross examination, the specimen consisted of a segmental resection of the small bowel of 8 cm × 4 cm × 2.6 cm with a sausage-shaped polypoid lesion.

Histological examination (Figure 3) showed a polypoid lesion, with a central fatty and collagenous core lined with an intestinal type mucosa. A central area of ulceration was seen, with no presence of gastric or pancreatic heterotopia. The final pathology report described a Meckel's diverticulum.



**Figure 1 Capsule endoscopy with protruding lesion.** A: Capsule endoscopy with protruding lesion, with a depressed erosion at the tip suggestive of Meckel's diverticulum; B: Capsule endoscopy with protruding lesion suggestive of Meckel's diverticulum.



**Figure 2 Abdominal computed tomography scan revealed a central area of fat attenuation surrounded by a thick collar of soft tissue attenuation suggestive of Meckel's diverticulum.**

## TREATMENT

The patient was diagnosed with an inverted Meckel's diverticulum and underwent a laparoscopic surgery. A large intraluminal polyp-like mass in the mid-ileum was observed. The remainder of the small bowel was normal to the level of the ligament of Treitz. A segmentary resection of the small bowel with adequate margin was performed and side-to-side anastomosis was carried out using a stapling device.

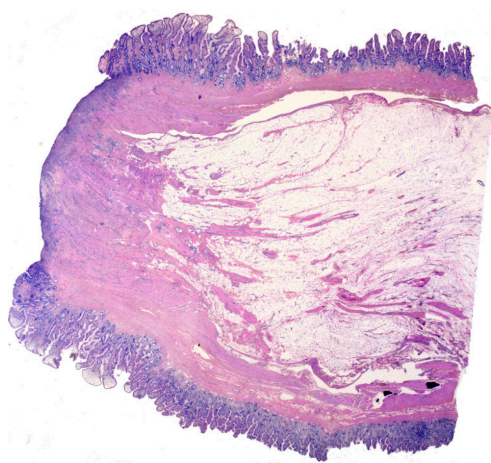
## OUTCOME AND FOLLOW-UP

The patient had an uneventful postoperative course and was discharged 4 d after surgery.

## DISCUSSION

Meckel's diverticulum is the most common congenital anomaly in the gastrointestinal tract[1] and is often incidentally discovered during evaluations performed for other reasons, as it is usually an asymptomatic condition. However, complications can occur in up to 6.4% of patients[7]. These are more frequent in the pediatric population and mainly involve bowel obstruction with or without intussusception, gastrointestinal hemorrhage, diverticulitis and inflammation, and Littre hernia (hernia involving the





**Figure 3** Low power histologic examination of a polypoid lesion lined by an intestinal type mucosa with a central ulcerated area. No gastric or pancreatic heterotopic tissue can be found.

bowel segment bearing Meckel's)[4,7].

Inverted Meckel's diverticulum is an unusual condition that is not yet clearly understood and there are no more than 100 cases reported in literature.

It has been proposed that the mechanism that could produce the inversion is an abnormal peristaltic movement around an ulceration or ectopic tissue. Nevertheless, no ectopic tissue was found in 41% of patients with inverted Meckel's diverticulum[6]. In this regard, tc-99m pertechnetate scintigraphy can help detect ectopic gastric mucosa and has been used for years as a diagnostic method for Meckel's diverticulum, especially in children, with a sensitivity of 92.1% and a specificity of 95.4%[8]. In adults, the sensitivity of this method is significantly less (54%)[9]. No cases of diagnosis of inverted Meckel's diverticulum by scintigraphy have been described, while there is only 1 case with gastric and pancreatic mucosa in the histopathological sample where the scintigraphy was negative[10]. Our patient's scintigraphy was negative. Therefore, this suggests that a negative scan does not preclude the presence of ectopic mucosa and the diagnosis of possible inverted Meckel's diverticulum.

This inversion of the Meckel's diverticulum can lead to a complete intussusception of the bowel or compromise blood flow to that bowel, ulceration and then gastrointestinal bleeding. The bleeding can also be explained by repetitive mechanical trauma to the mucosa from the reversible intussusception.

As in our patient, anemia or gastrointestinal bleeding are the most frequent clinical manifestations, found in up to 80% of patients[6]. This usually leads to an upper and lower gastrointestinal endoscopy, where the cause of the bleeding cannot be found.

Other clinical manifestations which can occur are abdominal pain (68%) and intussusception (39%). The median age of presentation is 27.7 years, younger than that reported for Meckel's diverticulum, which has been 33, with a male to female ratio of approximately 2.33:1[6].

Regarding the diagnostic tools, abdominal ultrasonography can contribute to the diagnosis, but often shows nonspecific findings such as thickened intestinal wall, fluid filled target or distended loops of bowel[11,12]. In our case, abdominal ultrasonography revealed no pathological findings.

One of the most useful tools is a CT scan. It usually shows a thickened small intestinal wall, with an elongated, intraluminal, fat-attenuating lesion[13], as in our case. In the case of intussusceptions, a CT scan is especially useful as it can reveal the characteristic "target sign". Inverted Meckel's diverticulum is sometimes confused with a lipoma on CT scans because it also consists of macroscopic fatty tissue. However, in most cases, abdominal CT scans provide useful information for the diagnosis and treatment of inverted Meckel's diverticulum[6].

Capsule endoscopy has recently been considered a useful diagnostic tool for diagnosing Meckel's diverticulum[9,14,15]. However, the role of capsule endoscopy in the identification of Meckel's diverticulum is not yet clear, with only a few case reports and case series available. Furthermore, in the case of inverted Meckel's diverticulum, the information is very limited, represented by only 2 case reports[16,17]. The capsule findings compatible with inverted Meckel's diverticulum were described as an elevated lesion with normal mucosa[16] or as pedunculated polyp[17].

In our case, the capsule endoscopy images were similar (a subepithelial protruding lesion in the ileum with the presence of blood, hematin, ulcer or erosion) and offered us a clue to subsequently confirm the diagnosis of inverted Meckel's diverticulum. In addition, the clinical suspicion due to the clinical characteristics (such as the fact that the patient was a young man with anemia) and a negative endoscopic study was of great importance for the diagnosis of inverted Meckel's diverticulum.

Regarding the risk of possible intestinal obstruction of the endoscopic capsule due to Meckel's diverticulum, no events have been described.

Surgery is the treatment of choice for symptomatic Meckel's diverticulum. The general consensus is that it should be treated with resection. In the case of asymptomatic Meckel's diverticulum, there is some debate. Resection is generally recommended for patients younger than 40-years-old, with diverticulum longer than 2 cm, diverticula with narrow necks, fibrous bands, and/or ectopic gastric tissue, and/or when the diverticulum appears thickened and inflamed[4,6,18].

It is important to note that in cases of anemia without abdominal pain, like that of our patient, it may take a long time for the patient to be diagnosed with inverted Meckel's diverticulum, given that it is an unusual condition with a nonspecific clinical presentation. Capsule endoscopy is usually performed in those patients with anemia with a normal upper and lower gastrointestinal endoscopy. However, if clinicians are unaware of the characteristics of this lesion, it may go undetected since it is an uncommon disease. Therefore, this report aims to contribute more information concerning the clinical characteristics, radiological findings and especially, the capsule endoscopy findings of inverted Meckel's diverticulum that can help clinicians suspect that this disease is present and enable them to establish a definitive diagnosis.

## CONCLUSION

To date, inverted Meckel's diverticulum is a pathology that is still not completely well known, with few cases described in the literature. Its clinical presentation is not specific, its most frequent symptoms being anemia or lower gastrointestinal bleeding. Patients are often given an upper and lower gastrointestinal endoscopy which reveals no abnormalities and a subsequent capsule endoscopy. Therefore, increased awareness of the disease and a greater understanding of the features of this lesion in capsule endoscopy findings could ultimately help clinicians make the correct diagnosis.

## REFERENCES

- 1 Sagar J, Kumar V, Shah DK. Meckel's diverticulum: a systematic review. *J R Soc Med* 2006; **99**: 501-505 [PMID: 17021300 DOI: 10.1258/jrsm.99.10.501]
- 2 Karadeniz Cakmak G, Emre AU, Tascilar O, Bektaş S, Uçan BH, Irkorucu O, Karakaya K, Ustundag Y, Comert M. Lipoma within inverted Meckel's diverticulum as a cause of recurrent partial intestinal obstruction and hemorrhage: a case report and review of literature. *World J Gastroenterol* 2007; **13**: 1141-1143 [PMID: 17373755 DOI: 10.3748/wjg.v13.i7.1141]
- 3 WEINSTEIN EC, CAIN JC, REMINE WH. Meckel's diverticulum: 55 years of clinical and surgical experience. *JAMA* 1962; **182**: 251-253 [PMID: 13999637 DOI: 10.1001/jama.1962.03050420027007]
- 4 Park JJ, Wolff BG, Tollefson MK, Walsh EE, Larson DR. Meckel diverticulum: the Mayo Clinic experience with 1476 patients (1950-2002). *Ann Surg* 2005; **241**: 529-533 [PMID: 15729078 DOI: 10.1097/01.sla.0000154270.14308.5f]
- 5 Cullen JJ, Kelly KA, Moir CR, Hodge DO, Zinsmeister AR, Melton LJ 3rd. Surgical management of Meckel's diverticulum. An epidemiologic, population-based study. *Ann Surg* 1994; **220**: 564-8; discussion 568 [PMID: 7944666 DOI: 10.1097/00000658-199410000-00014]
- 6 Rashid OM, Ku JK, Nagahashi M, Yamada A, Takabe K. Inverted Meckel's diverticulum as a cause of occult lower gastrointestinal hemorrhage. *World J Gastroenterol* 2012; **18**: 6155-6159 [PMID: 23155346 DOI: 10.3748/wjg.v18.i42.6155]
- 7 Hansen CC, Søreide K. Systematic review of epidemiology, presentation, and management of Meckel's diverticulum in the 21st century. *Medicine (Baltimore)* 2018; **97**: e12154 [PMID: 30170459 DOI: 10.1097/MD.00000000000012154]
- 8 Hosseinnazhad T, Shariati F, Treglia G, Kakhki VR, Sadri K, Kianifar HR, Sadeghi R. 99mTc-Pertechnetate imaging for detection of ectopic gastric mucosa: a systematic review and meta-analysis of the pertinent literature. *Acta Gastroenterol Belg* 2014; **77**: 318-327 [PMID: 25509203]
- 9 Krstic SN, Martinov JB, Sokic-Milutinovic AD, Milosavljevic TN, Krstic MN. Capsule endoscopy is useful diagnostic tool for diagnosing Meckel's diverticulum. *Eur J Gastroenterol Hepatol* 2016; **28**: 702-707 [PMID: 26854797 DOI: 10.1097/MEG.0000000000000603]
- 10 Dujardin M, de Beeck BO, Osteaux M. Inverted Meckel's diverticulum as a leading point for

- ileoileal intussusception in an adult: case report. *Abdom Imaging* 2002; **27**: 563-565 [PMID: 12172999 DOI: 10.1007/s00261-001-0070-3]
- 11 **El-Dhuwaib Y**, O'Shea S, Ammori BJ. Laparoscopic reduction of an ileoileal intussusception and resection of an inverted Meckel's diverticulum in an adult. *Surg Endosc* 2003; **17**: 1157 [PMID: 12728389 DOI: 10.1007/s00464-002-4284-4]
- 12 **Karahasanoglu T**, Memisoglu K, Korman U, Tunckale A, Curgunlu A, Karter Y. Adult intussusception due to inverted Meckel's diverticulum: laparoscopic approach. *Surg Laparosc Endosc Percutan Tech* 2003; **13**: 39-41 [PMID: 12598757 DOI: 10.1097/00129689-200302000-00009]
- 13 **Takagaki K**, Osawa S, Ito T, Iwaizumi M, Hamaya Y, Tsukui H, Furuta T, Wada H, Baba S, Sugimoto K. Inverted Meckel's diverticulum preoperatively diagnosed using double-balloon enteroscopy. *World J Gastroenterol* 2016; **22**: 4416-4420 [PMID: 27158212 DOI: 10.3748/wjg.v22.i17.4416]
- 14 **Wu J**, Huang Z, Wang Y, Tang Z, Lai L, Xue A, Huang Y. Clinical features of capsule endoscopy in 825 children: A single-center, retrospective cohort study. *Medicine (Baltimore)* 2020; **99**: e22864 [PMID: 33120825 DOI: 10.1097/MD.00000000000022864]
- 15 **Lin L**, Liu K, Liu H, Wu J, Zhang Y. Capsule endoscopy as a diagnostic test for Meckel's diverticulum. *Scand J Gastroenterol* 2019; **54**: 122-127 [PMID: 30638099 DOI: 10.1080/00365521.2018.1553353]
- 16 **Ibuka T**, Araki H, Sugiyama T, Takada J, Kubota M, Shirakami Y, Shiraki M, Shimizu M, Suzui N, Miyazaki T. [A case of an elderly patient with inverted Meckel's diverticulum with small intestinal bleeding detected using capsule and double-balloon endoscopies]. *Nihon Shokakibyo Gakkai Zasshi* 2017; **114**: 2005-2011 [PMID: 29109349 DOI: 10.11405/nisshoshi.114.2005]
- 17 **Payeras Capó MA**, Ambrona Zafra D, Garrido Durán C. Inverted Meckel's diverticulum in an adult patient diagnosed via capsule endoscopy. *Rev Esp Enferm Dig* 2018; **110**: 210-211 [PMID: 29368940 DOI: 10.17235/reed.2018.5347/2017]
- 18 **Lequet J**, Menahem B, Alves A, Fohlen A, Mulliri A. Meckel's diverticulum in the adult. *J Visc Surg* 2017; **154**: 253-259 [PMID: 28698005 DOI: 10.1016/j.jviscsurg.2017.06.006]



Published by **Baishideng Publishing Group Inc**  
7041 Koll Center Parkway, Suite 160, Pleasanton, CA 94566, USA

**Telephone:** +1-925-3991568

**E-mail:** [bpgoffice@wjgnet.com](mailto:bpgoffice@wjgnet.com)

**Help Desk:** <https://www.f6publishing.com/helpdesk>

<https://www.wjgnet.com>

