

World Journal of *Orthopedics*

World J Orthop 2021 October 18; 12(10): 727-810



EDITORIAL

- 727 Mixed reality for visualization of orthopedic surgical anatomy
Chytas D, Nikolaou VS

MINIREVIEWS

- 732 Bicruciate-retaining total knee arthroplasty: What's new?
Sabatini L, Barberis L, Camazzola D, Centola M, Capella M, Bistolfi A, Schiraldi M, Massè A
- 743 Surgical treatment of metastatic bone disease of the distal extremities
Sebghati J, Khalili P, Tsagkosis P

ORIGINAL ARTICLE

Case Control Study

- 751 SARS-CoV-2 outbreak impact on a trauma unit
Mills S, Ibarzábal-Gil A, Martínez-Diez JM, Pallarés-Sanmartín J, Kalbakdj-Sánchez C, Rubio-Suárez JC, Losantos-García I, Rodríguez-Merchán EC

Retrospective Cohort Study

- 760 Clinical outcome after surgery on schwannomas in the extremities
Granlund AS, Sørensen MS, Jensen CL, Bech BH, Petersen MM

Retrospective Study

- 768 Osteolysis in total hip arthroplasty in relation to metal ion release: Comparison between monolithic prostheses and different modularities
Manfreda F, Bufi E, Florio EF, Ceccarini P, Rinonapoli G, Caraffa A, Antinolfi P

Clinical Trials Study

- 781 Short-term effectiveness of high- and low-intensity percutaneous electrolysis in patients with patellofemoral pain syndrome: A pilot study
Valera-Calero JA, Sánchez-Mayoral-Martín A, Varol U

SYSTEMATIC REVIEWS

- 791 Alignment of the hindfoot following total knee arthroplasty: A systematic review
Butler JJ, Mercer NP, Hurley ET, Azam MT, Kennedy JG

CASE REPORT

- 802 Simultaneous repair of bilateral pectoralis major tendons: A case report
Abbas MJ, Buckley P, Shah S, Okoroha KR

ABOUT COVER

Editorial Board Member of *World Journal of Orthopedics*, Dariusz Czaprowski, PhD, Associate Professor, Department of Health Sciences, Physiotherapy Unit, Olsztyn University, Olsztyn 10-243, Poland. dariusz.czaprowski@interia.pl

AIMS AND SCOPE

The primary aim of *World Journal of Orthopedics* (WJO, *World J Orthop*) is to provide scholars and readers from various fields of orthopedics with a platform to publish high-quality basic and clinical research articles and communicate their research findings online.

WJO mainly publishes articles reporting research results and findings obtained in the field of orthopedics and covering a wide range of topics including arthroscopy, bone trauma, bone tumors, hand and foot surgery, joint surgery, orthopedic trauma, osteoarthropathy, osteoporosis, pediatric orthopedics, spinal diseases, spine surgery, and sports medicine.

INDEXING/ABSTRACTING

The WJO is now abstracted and indexed in PubMed, PubMed Central, Emerging Sources Citation Index (Web of Science), Scopus, China National Knowledge Infrastructure (CNKI), China Science and Technology Journal Database (CSTJ), and Superstar Journals Database. The 2021 edition of Journal Citation Reports® cites the 2020 Journal Citation Indicator (JCI) for WJO as 0.66. The WJO's CiteScore for 2020 is 3.2 and Scopus CiteScore rank 2020: Orthopedics and Sports Medicine is 87/262.

RESPONSIBLE EDITORS FOR THIS ISSUE

Production Editor: *Lin-YuTong Wang*; Production Department Director: *Xiang Li*; Editorial Office Director: *Jim-Lai Wang*.

NAME OF JOURNAL

World Journal of Orthopedics

ISSN

ISSN 2218-5836 (online)

LAUNCH DATE

November 18, 2010

FREQUENCY

Monthly

EDITORS-IN-CHIEF

Massimiliano Leigheb

EDITORIAL BOARD MEMBERS

<http://www.wjgnet.com/2218-5836/editorialboard.htm>

PUBLICATION DATE

October 18, 2021

COPYRIGHT

© 2021 Baishideng Publishing Group Inc

INSTRUCTIONS TO AUTHORS

<https://www.wjgnet.com/bpg/gerinfo/204>

GUIDELINES FOR ETHICS DOCUMENTS

<https://www.wjgnet.com/bpg/gerinfo/287>

GUIDELINES FOR NON-NATIVE SPEAKERS OF ENGLISH

<https://www.wjgnet.com/bpg/gerinfo/240>

PUBLICATION ETHICS

<https://www.wjgnet.com/bpg/gerinfo/288>

PUBLICATION MISCONDUCT

<https://www.wjgnet.com/bpg/gerinfo/208>

ARTICLE PROCESSING CHARGE

<https://www.wjgnet.com/bpg/gerinfo/242>

STEPS FOR SUBMITTING MANUSCRIPTS

<https://www.wjgnet.com/bpg/gerinfo/239>

ONLINE SUBMISSION

<https://www.f6publishing.com>



Simultaneous repair of bilateral pectoralis major tendons: A case report

Muhammad J Abbas, Patrick Buckley, Sabin Shah, Kelechi R Okoroha

ORCID number: Muhammad J Abbas 0000-0002-2191-1757; Patrick Buckley 0000-0003-0650-929X; Sabin Shah 0000-0002-9796-9023; Kelechi R Okoroha 0000-0002-2780-3159.

Author contributions: Okoroha KR, Shah S, Buckley P, and Abbas MJ were members of the patients care team and reviewed the literature and contributed to manuscript writing; Okoroha KR and Shah S were the orthopaedic surgeons who managed the patient operatively; Buckley P and Abbas MJ recorded the operative technique and captured images of the patients in the perioperative setting; all authors contributed to revisions of the manuscript and issued approval on the draft submitted.

Informed consent statement:

Consent was obtained from the patient prior to the writing of this manuscript.

Conflict-of-interest statement:

Authors have no disclosures. No outside funding contributed towards the completion of this case report.

CARE Checklist (2016) statement:

CARE guidelines were followed during the completion of this case report.

Open-Access: This article is an

Muhammad J Abbas, Patrick Buckley, Sabin Shah, Department of Orthopedic Surgery, Henry Ford Health System, Dearborn, MI 48124, United States

Kelechi R Okoroha, Department of Orthopaedic Surgery, Mayo Clinic, Minneapolis, MN 55403, United States

Corresponding author: Muhammad J Abbas, BSc, Research Fellow, Department of Orthopedic Surgery, Henry Ford Health System, 2799 W Grand Blvd, Dearborn, MI 48124, United States. fh1408@wayne.edu

Abstract

BACKGROUND

Injuries to the pectoralis major are infrequent, with only a few hundred cases currently recorded in the literature.

CASE SUMMARY

We report a case of a patient who sustained bilateral pectoralis major tendon ruptures. While other cases of bilateral pectoralis major tears have been reported in the literature, the operative management in this report differs. Due to delayed presentation of the patient right and left pectoralis major repairs were performed simultaneously.

CONCLUSION

Patients with delayed presentation of bilateral pectoralis major tendon ruptures can undergo simultaneous repair of both tendon with a good postoperative outcome and high patient satisfaction.

Key Words: Bilateral repair; Pectoralis major; Tendon rupture; Simultaneous repair; Case report

©The Author(s) 2021. Published by Baishideng Publishing Group Inc. All rights reserved.

Core Tip: Patients with delayed presentation of bilateral pectoralis major tendon ruptures can undergo simultaneous repair of both tendon with a good postoperative outcome and high patient satisfaction.

open-access article that was selected by an in-house editor and fully peer-reviewed by external reviewers. It is distributed in accordance with the Creative Commons Attribution NonCommercial (CC BY-NC 4.0) license, which permits others to distribute, remix, adapt, build upon this work non-commercially, and license their derivative works on different terms, provided the original work is properly cited and the use is non-commercial. See: <http://creativecommons.org/licenses/by-nc/4.0/>

Manuscript source: Unsolicited manuscript

Specialty type: Orthopedics

Country/Territory of origin: United States

Peer-review report's scientific quality classification

Grade A (Excellent): 0
Grade B (Very good): 0
Grade C (Good): C
Grade D (Fair): 0
Grade E (Poor): 0

Received: March 18, 2021

Peer-review started: March 18, 2021

First decision: June 7, 2021

Revised: June 20, 2021

Accepted: August 20, 2021

Article in press: August 20, 2021

Published online: October 18, 2021

P-Reviewer: Nishikawa DRC

S-Editor: Wang JL

L-Editor: A

P-Editor: Ma YJ



Citation: Abbas MJ, Buckley P, Shah S, Okoroha KR. Simultaneous repair of bilateral pectoralis major tendons: A case report. *World J Orthop* 2021; 12(10): 802-810

URL: <https://www.wjgnet.com/2218-5836/full/v12/i10/802.htm>

DOI: <https://dx.doi.org/10.5312/wjo.v12.i10.802>

INTRODUCTION

Injuries to the pectoralis major are infrequent, with only a few hundred cases currently recorded in the literature[1,2]. Yet, pectoralis major tears are occurring at an increasing rate over the past few decades, including over half all reported cases occurring in the past decade[1,3-6]. Over 80% of pectoralis major injuries result from indirect trauma and up to half occur during weight training, especially during the eccentric part of a bench press[1-3,7,8]. We report a case of a patient who sustained bilateral pectoralis major tendon ruptures. While other cases of bilateral pectoralis major tears have been reported in the literature, the operative management in this report differs by providing clinical outcomes for simultaneous repair of both tendons[9-12].

CASE PRESENTATION

Chief complaints

A thirty-nine-year-old man presented to our ambulatory sports medicine clinic with complaints of painful range motion in the upper extremities, as well as localized swelling and ecchymosis over bilateral pectoralis major and arms.

History of present illness

Four weeks ago, the patient was performing a flat bench pressing with 405 Lbs. On the sixth repetition of his second set, the patient described feeling a tearing sensation and hearing loud pop emanating from both axillae before re-racking the weight (Video 1). Patient reports the immediate onset of a dull and aching pain and swelling following the incident, as well as reduced strength in internal rotation and adduction of the bilateral upper extremities. In the subsequent morning the patient described significant ecchymosis and swelling in the axillae and anterior surface of the arms bilaterally. Upon assessment of medications, patient denied the use of anabolic steroids and fluoroquinolones. Due to issues with insurance, the patient delayed seeking care. The patient provided informed consent for all imaging, reports, and publications regarding his injury.

History of past illness

The patient has no known surgical history and a past medical history of a transient ischemic attack, myalgia and Wilson's disease.

Physical examination

During a focused physical exam, our patient presented with a loss of the anterior axillary contour bilaterally (Figure 1), as well as retraction of the pectoralis major muscles medially when performing an isometric contraction in the prayer position (Figure 2). On clinical strength testing, the patient's internal rotation was 4- of 5 bilaterally and adduction was of 4- of 5 bilaterally.

Imaging examinations

Magnetic resonance imaging (MRI) confirmed the diagnosis of bilateral pectoralis major tendon ruptures and demonstrated tears with approximately 7 cm of retraction on the right and 5cm of retraction on the left (Figure 3).

FINAL DIAGNOSIS

The final diagnosis of was bilateral pectoralis major tendon ruptures.

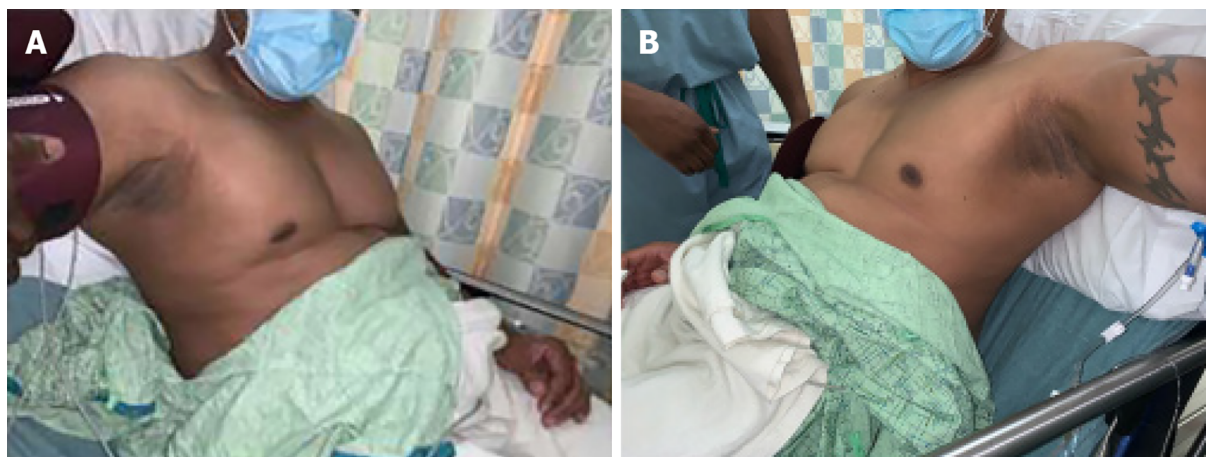

Figure 1 Photographs of patient four weeks since initial injury, demonstrating loss of axillary fold on the right side and on the left side. A: Right side; B: Left side.

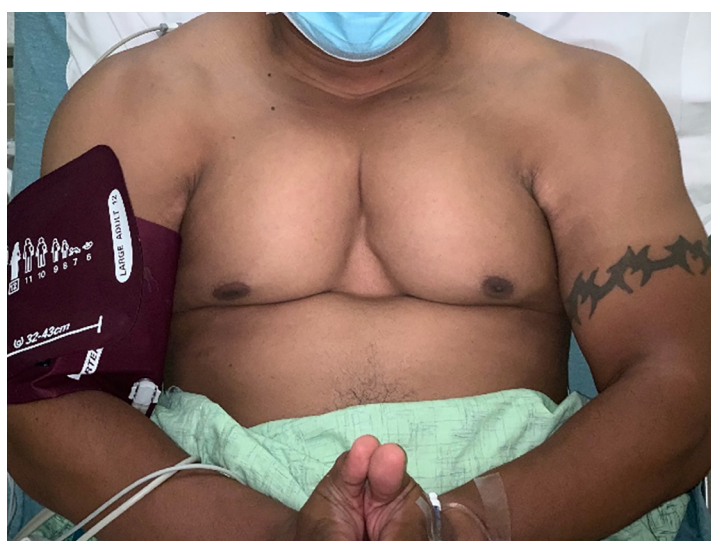

Figure 2 Photograph of patient four weeks since initial injury, demonstrating medial retraction of pectoralis major muscle while isometrically contracting in the prayer position.

TREATMENT

Due to delayed presentation of the patient and his desire to return to maximal strength, right and left pectoralis major repairs were performed simultaneously using all suture anchors. The patient was placed in beach chair position and both upper extremities were draped simultaneously (Figure 4). The bed was placed in a slight Trendelenburg and a deltopectoral approach was used (Figure 5). Fascia distal to the clavicular head of the pectoralis major was opened and hematoma was evacuated before identifying the retracted ruptured pectoralis major tendon. A tag stitch was then placed through the tendon to facilitate mobilization (Figure 6). The pectoralis major insertion site was then identified lateral to the long head of the biceps tendon and a burr was used to create a bleeding bony bed (Figure 7). Following the preparation of the insertion site three 2.8 Q fix all suture anchors (Smith & Nephew, Waterford, England, UK) were placed with one proximally, one in the middle, and one distally (Figure 8). One set of sutures from each anchor pair was passed through the tendon in a horizontal mattress fashion and the second suture set was passed medially to act as a rip stop (Figure 9). All sutures were sequentially tied from proximal to distal. Range of motion was then examined, and wound was closed and dressed in standard fashion. Postoperatively both shoulders were immobilized for 6 wks. in adduction and internal rotation with a Shoulder Immobilizer.

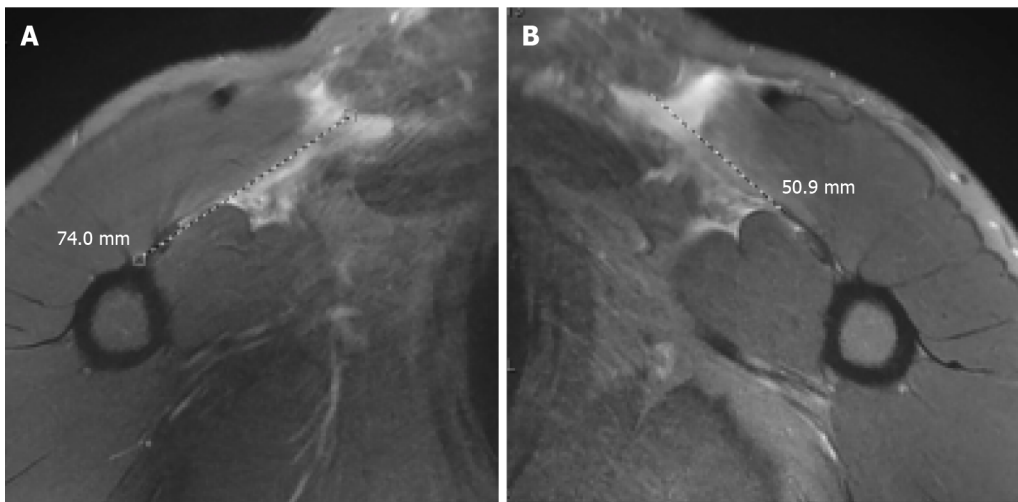


Figure 3 Magnetic resonance imaging of pectoralis major tear. A: 7 cm of retraction on the right pectoralis major tendon; B: 5 cm of retraction on the left pectoralis major tendon.

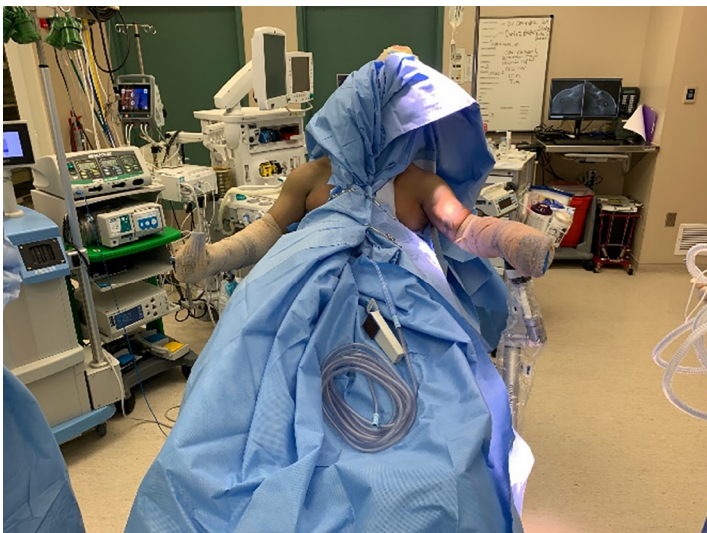

Figure 4 Photograph demonstrating patient in the beach chair position with both upper extremities draped.

OUTCOME AND FOLLOW-UP

During the first post-operative visit at 10 d following surgery the patient reported PROMIS interference scores for upper extremity, physical function, pain, and depression of 21.2, 26.1, 68.1, and 34.2 respectively. Patient visual analog pain score (VAS) was 7. Rehabilitation started at 2 wks. post-operatively with Cuff isometrics and passive shoulder ROM. After 6 wks. postoperatively the sling was discontinued, and the patient began active shoulder motion, rotator cuff and scapular stabilizer strengthening, and restoration of full passive shoulder range of motion (ROM).

At three-months postoperatively the patient presented with strength of 5- of 5 on clinical evaluation of internal rotation and adduction of the arms bilaterally. The patient had full ROM in forward flexion, abduction, internal rotation and external rotation bilaterally. PROMIS interference scores for upper extremity, physical function, pain, and depression were recorded as 54.2, 56.1, 58.1, and 54.2 respectively. VAS score was reported as 2. In physical therapy the patient continued to progress with strengthening and was permitted to start performing a light bench press. The patient has reported no discomfort with resistance training.

During the patients most recent follow-up, six-months postoperatively, the patient reported PROMIS interference scores for upper extremity, physical function, pain, and depression of 51.4, 56.1, 38.7, and 34.2 respectively. The patient reported a VAS score of 1 and demonstrated full range of motion in forward flexion, abduction, internal

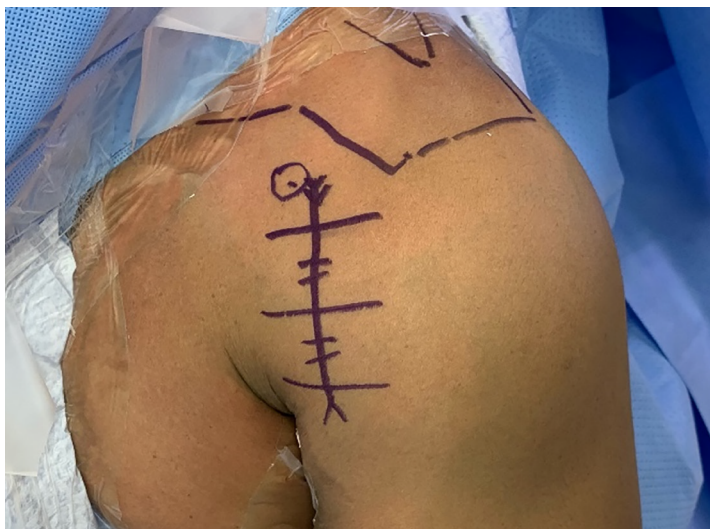

Figure 5 Photograph of anatomical landmarks used to perform a deltopectoral approach

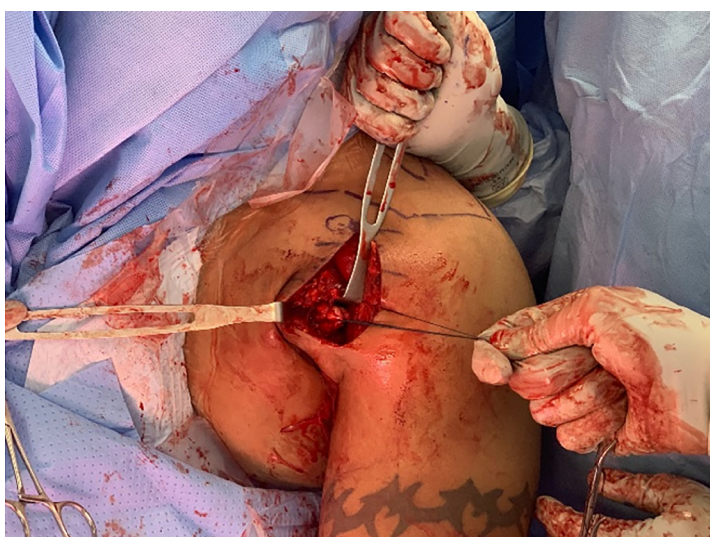

Figure 6 Photograph of a tag stitch that was placed through the pectoralis major tendon.

rotation and external rotation bilaterally (Figure 10). Patient has completed physical therapy and was cleared to resume full strengthening activities.

DISCUSSION

Complete tear of the pectoralis major is increasing in frequency over the past few decades. Between the first case recorded in 1822[13] and 1990, fewer than 90 cases were documented in the literature. As of 2010 there have been 365 recorded cases in the literature[1]. According to a recent meta-analysis performed by Bodendorfer *et al* [3], there are currently 693 cases reported in the literature. The authors described that 63.2% of pectoralis major tears occur due to weight training, including 39.5% of all documented tears resulting from a bench press. Eighty-seven percent ($n = 603$) of all tears underwent surgical management either acutely or chronically. Bodendorfer *et al* [3]'s results were consistent with previous studies which concluded operative treatment is superior to non-operative treatment in both the acute and chronic setting [1,14,15]. When compared to patients managed non-operatively, surgical intervention yielded greater functional improvement according to Bak criteria[2] (scored 1-4; $P = 0.027$), increased likelihood to regain full isometric strength ($P < 0.001$), better isokinetic strength as measured against the contralateral side ($P < 0.001$), decreased chance of a resting deformity ($P = 0.037$), and increased cosmetic satisfaction ($P <$

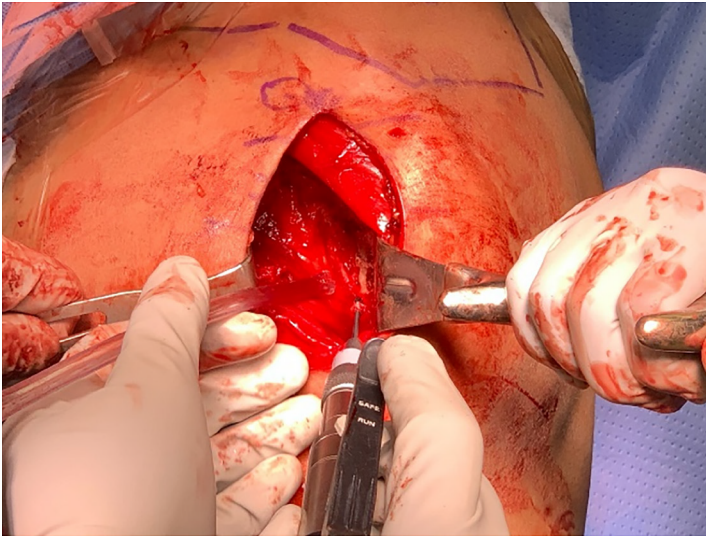


Figure 7 Photograph of the pectoralis major insertion was site with the burr that was used to debride the site and create a bleeding bony bed.

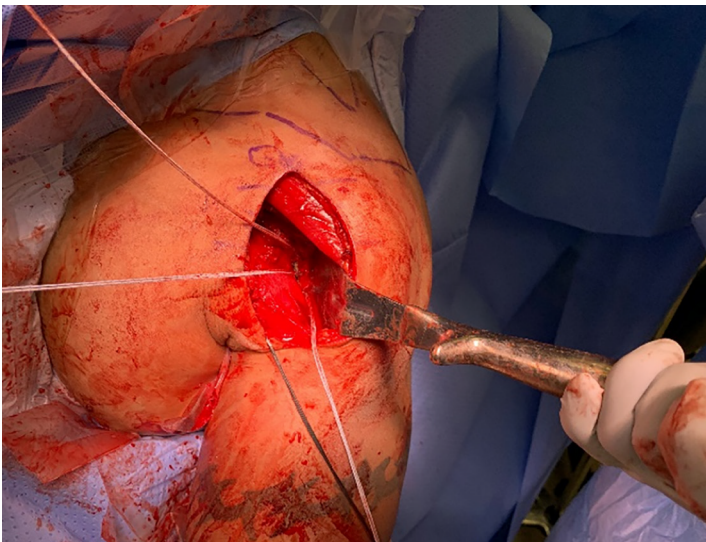


Figure 8 Photograph of the three 2.8 Q fix all suture anchors that were place with one proximally, one in the middle, and one distally.

0.001).

Our patient's bilateral tears occurred during a bench press, the most common mechanism by which pectoralis major tears occur[1-3,7,8]. Additionally, as a thirty-nine year old male, our patient matches the demographic most often affected by pectoralis major tears: males in their third or fourth decade[1-3,5]. MRI was performed (Figure 3) to confirm the diagnosis, determine the severity and location of the tear, and better create a preoperative plan as described by Kadu *et al*[16].

Our patient presented to our clinic 29 d out from injury; if the patient had appeared closer to the date of injury, staggering the surgeries between sides would have been contemplated. This would have allowed for use of the contralateral arm while the surgical arm was placed in a sling. It has been demonstrated that patients who underwent surgery within 6 wks. of injury have better outcomes compared to those who delay surgery beyond 6 wks.[14,15]. Furthermore, the findings from Ritsch's[17] prospective study of 25 patients with chronic pectoralis major tears demonstrated even when post-operative clinical outcomes are adequate, as defined by the Bak criteria, there is a higher risk of complications (24%). Considering all factors along with confirmation from our patient there was someone to help with activities of daily living when both arms would be in a sling post-operatively, we decided to proceed with simultaneous, bilateral pectoralis major repairs. Extra considerations must be made

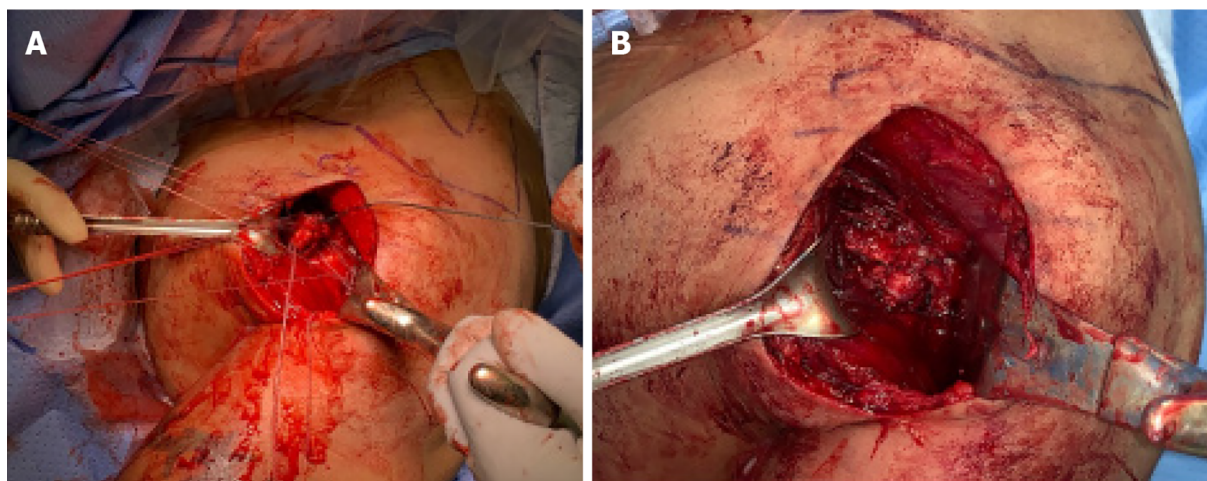


Figure 9 Photograph of sutures being passed through the tendon and all sutures being tied from proximal to distal. A: Sutures being passed through the tendon; B: All sutures being tied from proximal to distal.

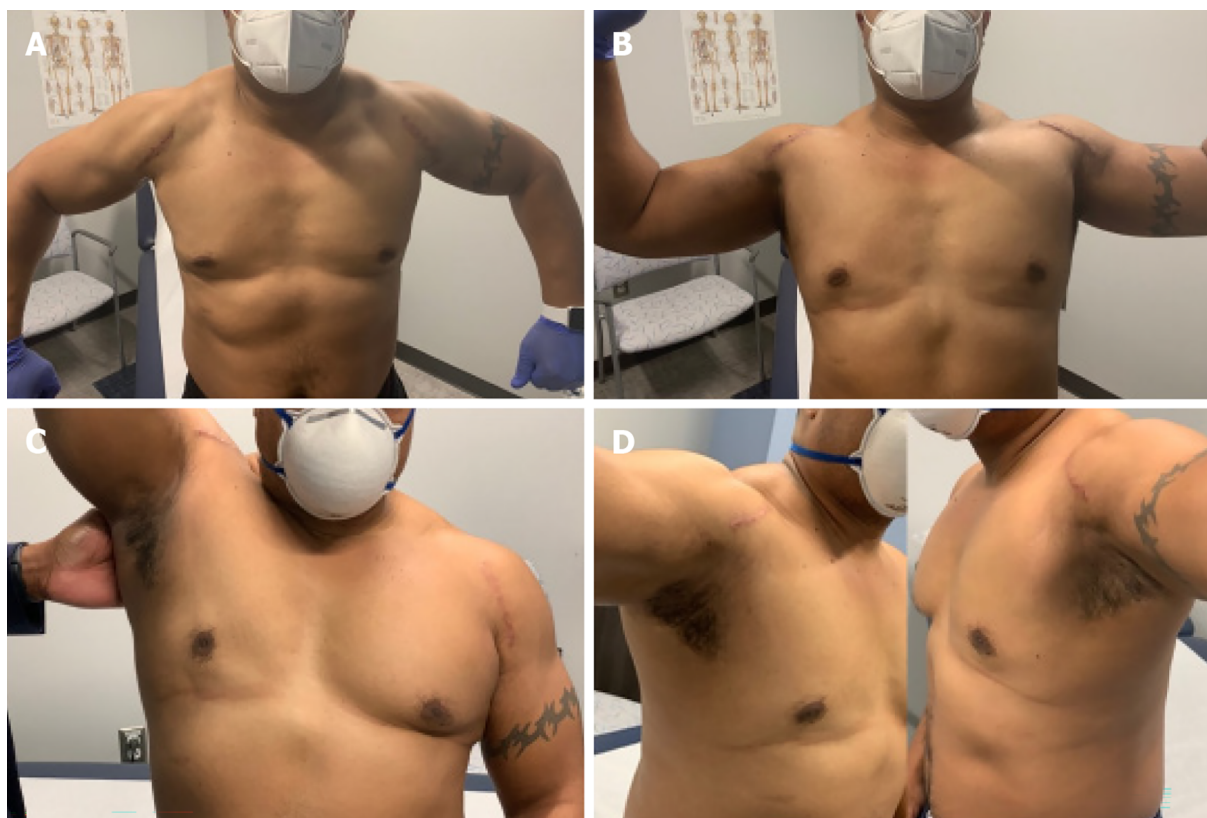

Figure 10 Photograph of patient at 6 months post-operatively in abduction internal rotation of shoulder, abduction external rotation of the shoulder, forward flexion of the shoulder, and abduction of the shoulder. A: Abduction internal rotation of shoulder; B: Abduction external rotation of the shoulder; C: Forward flexion of the shoulder; D: Abduction of the shoulder.

when opting to perform simultaneous bilateral surgical repairs. Patient selection is critical particularly in patients with significant comorbidities as there could be potential for increased perioperative complications. Additionally, it is essential that patients understand their limited function in the immediate postoperative period and have a dependable support system to aid in the recovery process. Operative time is also a consideration as performing bilateral simultaneous repairs will lead to increased anesthesia, higher risk for clotting, and increased blood loss than a one sided procedure.

According to the systematic review performed by Gupton *et al*[18], there are currently three main surgical techniques used to repair a pectoralis major tear:

Transosseus suture *via* drill holes, suture anchor, and unicortical or bicortical button. Compared to the button technique, both the transosseus suture (OR = 6.28, 95%CI: 1.37-28.75; $P = 0.02$) and suture anchor (OR = 3.40; 95%CI: 1.06-10.85; $P = 0.04$) techniques demonstrated better clinical outcomes according to the Bak criteria. There was no significant difference between the suture anchor and transosseus techniques (OR = 1.85; 95%CI: 0.33-10.45; $P = 0.49$). The benefits to the suture anchor technique include decreased operative time, less operative insult to the cortical humerus, excellent approximation of the tendon to its anatomic insertion, and reliable fixation [14,18-21]. All-suture anchors confer the benefit of decreased bone loss and smaller anchor footprint has been demonstrated compared to traditional anchors [22-24]. Only a handful of cases regarding bilateral rupture of the pectoralis major tendon have been recorded in the literature demonstrating staggered repair of each tendon [9-12]; however, this case represents a simultaneous repair for bilateral rupture of the pectoralis major tendons.

CONCLUSION

Patients with delayed presentation of bilateral pectoralis major tendon ruptures can undergo simultaneous repair of both tendon with a good postoperative outcome and high patient satisfaction.

REFERENCES

- 1 **ElMaraghy AW**, Devereaux MW. A systematic review and comprehensive classification of pectoralis major tears. *J Shoulder Elbow Surg* 2012; **21**: 412-422 [PMID: 21831661 DOI: 10.1016/j.jse.2011.04.035]
- 2 **Bak K**, Cameron EA, Henderson IJ. Rupture of the pectoralis major: a meta-analysis of 112 cases. *Knee Surg Sports Traumatol Arthrosc* 2000; **8**: 113-119 [PMID: 10795675 DOI: 10.1007/s001670050197]
- 3 **Bodendorfer BM**, McCormick BP, Wang DX, Looney AM, Conroy CM, Fryar CM, Kotler JA, Ferris WJ, Postma WF, Chang ES. Treatment of Pectoralis Major Tendon Tears: A Systematic Review and Meta-analysis of Operative and Nonoperative Treatment. *Orthop J Sports Med* 2020; **8**: 2325967119900813 [PMID: 32083144 DOI: 10.1177/2325967119900813]
- 4 **Long M**, Enders T, Trasolini R, Schneider W, Cappellino A, Ruotolo C. Pectoralis major tendon reconstruction using semitendinosus allograft following rupture at the musculotendinous junction. *JSES Open Access* 2019; **3**: 328-332 [PMID: 31891034 DOI: 10.1016/j.jse.2019.08.007]
- 5 **Schepesis AA**, Grafe MW, Jones HP, Lemos MJ. Rupture of the pectoralis major muscle. Outcome after repair of acute and chronic injuries. *Am J Sports Med* 2000; **28**: 9-15 [PMID: 10653537 DOI: 10.1177/03635465000280012701]
- 6 **Potter BK**, Lehman RA Jr, Doukas WC. Pectoralis major ruptures. *Am J Orthop (Belle Mead NJ)* 2006; **35**: 189-195 [PMID: 16689519]
- 7 **Wurm M**, Imhoff AB, Siebenlist S. Surgical repair of acute pectoralis major muscle ruptures. *Oper Orthop Traumatol* 2018; **30**: 390-397 [PMID: 29980801 DOI: 10.1007/s00064-018-0557-5]
- 8 **Garrigues GE**, Kraeutler MJ, Gillespie RJ, O'Brien DF, Lazarus MD. Repair of pectoralis major ruptures: single-surgeon case series. *Orthopedics* 2012; **35**: e1184-e1190 [PMID: 22868603 DOI: 10.3928/01477447-20120725-17]
- 9 **Potter BK**, Lehman RA Jr, Doukas WC. Simultaneous bilateral rupture of the pectoralis major tendon. A case report. *J Bone Joint Surg Am* 2004; **86**: 1519-1521 [PMID: 15252102 DOI: 10.2106/00004623-200407000-00023]
- 10 **Kusler JE**, Chong ACM, Piatt BE. Bilateral Pectoralis Major Tendon Rupture While Performing Intermediate Level Bench Press. *Kans J Med* 2019; **12**: 94-96 [PMID: 31489108]
- 11 **Valeriote J**, Purchase RJ, Kelly JD. Simultaneous bilateral pectoralis major muscle rupture. *Am J Orthop (Belle Mead NJ)* 2005; **34**: 301-302 [PMID: 16060560]
- 12 **Zvijac JE GB**, Kiebzak GM. Simultaneous bilateral rupture of the pectoralis major tendons while exercising on the rings. *Curr Orthop Pract* 2011; **22**: 376-378 [DOI: 10.1097/BCO.0b013e31821e5c75]
- 13 **Patissier P**. Maladies des bouchers. Traite des maladies des artisans. *Chez J-B Baillière Libaire* 1882; 162-165
- 14 **Aärmaa V**, Rantanen J, Heikkilä J, Helttula I, Orava S. Rupture of the pectoralis major muscle. *Am J Sports Med* 2004; **32**: 1256-1262 [PMID: 15262651 DOI: 10.1177/0363546503261137]
- 15 **Thompson K**, Kwon Y, Flatow E, Jazrawi L, Strauss E, Alaia M. Everything pectoralis major: from repair to transfer. *Phys Sportsmed* 2020; **48**: 33-45 [PMID: 31246519 DOI: 10.1080/00913847.2019.1637301]
- 16 **Kadu VV**, Saindane KA, Godghate N. Pectoralis Major Tear: An Unusual and Rare Presentation. *J Orthop Case Rep* 2016; **6**: 17-19 [PMID: 28443250]

- 17 **Ritsch M.** [Surgical treatment of chronic pectoralis major rupture]. *Oper Orthop Traumatol* 2018; **30**: 398-409 [PMID: [30483825](#) DOI: [10.1007/s00064-018-0577-1](#)]
- 18 **Gupton M**, Johnson JE. Surgical Treatment of Pectoralis Major Muscle Ruptures: A Systematic Review and Meta-analysis. *Orthop J Sports Med* 2019; **7**: 2325967118824551 [PMID: [30800687](#) DOI: [10.1177/2325967118824551](#)]
- 19 **Merolla G**, Campi F, Paladini P, Porcellini G. Surgical approach to acute pectoralis major tendon rupture. *G Chir* 2009; **30**: 53-57 [PMID: [19272235](#)]
- 20 **Petillon J**, Carr DR, Sekiya JK, Unger DV. Pectoralis major muscle injuries: evaluation and management. *J Am Acad Orthop Surg* 2005; **13**: 59-68 [PMID: [15712983](#) DOI: [10.5435/00124635-200501000-00008](#)]
- 21 **Hart ND**, Lindsey DP, McAdams TR. Pectoralis major tendon rupture: a biomechanical analysis of repair techniques. *J Orthop Res* 2011; **29**: 1783-1787 [PMID: [21538507](#) DOI: [10.1002/jor.21438](#)]
- 22 **Dhawan A**, Ghodadra N, Karas V, Salata MJ, Cole BJ. Complications of bioabsorbable suture anchors in the shoulder. *Am J Sports Med* 2012; **40**: 1424-1430 [PMID: [21856927](#) DOI: [10.1177/0363546511417573](#)]
- 23 **Mazzocca AD**, Chowanec D, Cote MP, Fierro J, Apostolakis J, Nowak M, Arciero RA, Beitzel K. Biomechanical evaluation of classic solid and novel all-soft suture anchors for glenoid labral repair. *Arthroscopy* 2012; **28**: 642-648 [PMID: [22301360](#) DOI: [10.1016/j.arthro.2011.10.024](#)]
- 24 **Erickson J**, Chiarappa F, Haskel J, Rice J, Hyatt A, Monica J, Dhawan A. Biomechanical Comparison of a First- and a Second-Generation All-Soft Suture Glenoid Anchor. *Orthop J Sports Med* 2017; **5**: 2325967117717010 [PMID: [28795073](#) DOI: [10.1177/2325967117717010](#)]



Published by **Baishideng Publishing Group Inc**
7041 Koll Center Parkway, Suite 160, Pleasanton, CA 94566, USA

Telephone: +1-925-3991568

E-mail: bpgoffice@wjgnet.com

Help Desk: <https://www.f6publishing.com/helpdesk>

<https://www.wjgnet.com>

