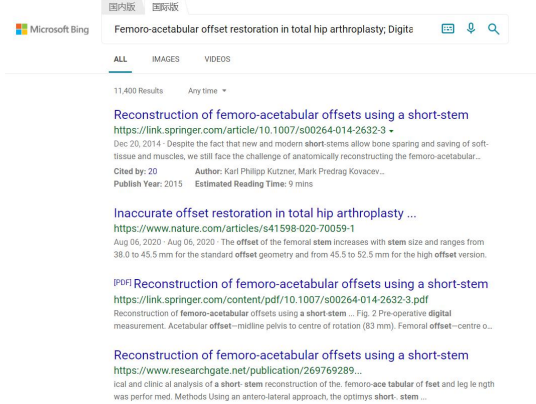


	Author Response	Revised Manuscript Line Number and Text Change (in highlights)
Reviewer: 1		
Were these two study groups representative for the type of the femoral canal according to the Dorr classification, as each of these stems has indications for a particular type of the femoral canal.	 <p>The X-rays were chosen from two prospective study cohorts, where we didn't look specifically at the Dorr classification.</p> <p>But we do feel that the reviewer is making an important comment, as the type of femur canal can pose difficulty in offset restoration or stem fixation. We have described this as a limitation in our study in the discussion part.</p>	Line 255-258: added “second, other characteristics of the....inadequate fixation of a short stem.
Please, add please examples of x-ray pictures after THA of both groups with measurements in digital templating.	We definitely understand the reason for wanting an example of the postoperative X-rays in both groups. However, we think that putting the X-ray in the article can lead to confusion, as we don't have any postoperative measurements of both groups. The reason for not putting the postoperative measurements in this article is because that would lead to too much data in one article.	No revision necessary