

# World Journal of *Clinical Cases*

*World J Clin Cases* 2022 January 14; 10(2): 397-752



## Contents

Thrice Monthly Volume 10 Number 2 January 14, 2022

## EDITORIAL

- 397 New trends in treatment of muscle fatigue throughout rehabilitation of elderlies with motor neuron diseases  
*Mohamed A*

## MINIREVIEWS

- 401 What emotion dimensions can affect working memory performance in healthy adults? A review  
*Hou TY, Cai WP*
- 412 Quadrilateral plate fractures of the acetabulum: Classification, approach, implant therapy and related research progress  
*Zhou XF, Gu SC, Zhu WB, Yang JZ, Xu L, Fang SY*

## ORIGINAL ARTICLE

## Case Control Study

- 426 Methylprednisolone accelerate chest computed tomography absorption in COVID-19: A three-centered retrospective case control study from China  
*Lin L, Xue D, Chen JH, Wei QY, Huang ZH*

## Retrospective Study

- 437 Analysis of photostimulable phosphor image plate artifacts and their prevalence  
*Elkhateeb SM, Aloyouny AY, Omer MMS, Mansour SM*
- 448 N6-methyladenine-modified DNA was decreased in Alzheimer's disease patients  
*Lv S, Zhou X, Li YM, Yang T, Zhang SJ, Wang Y, Jia SH, Peng DT*
- 458 Inflammation-related indicators to distinguish between gastric stromal tumors and leiomyomas: A retrospective study  
*Zhai YH, Zheng Z, Deng W, Yin J, Bai ZG, Liu XY, Zhang J, Zhang ZT*
- 469 Relationship between Ki-67 and CD44 expression and microvascular formation in gastric stromal tumor tissues  
*Ma B, Huang XT, Zou GJ, Hou WY, Du XH*
- 477 Modified surgical method of supra- and infratentorial epidural hematoma and the related anatomical study of the squamous part of the occipital bone  
*Li RC, Guo SW, Liang C*
- 485 Combined molybdenum target X-ray and magnetic resonance imaging examinations improve breast cancer diagnostic efficacy  
*Gu WQ, Cai SM, Liu WD, Zhang Q, Shi Y, Du LJ*

- 492 Value of thyroglobulin combined with ultrasound-guided fine-needle aspiration cytology for diagnosis of lymph node metastasis of thyroid carcinoma

*Zhang LY, Chen Y, Ao YZ*

- 502 Locking compression plate + T-type steel plate for postoperative weight bearing and functional recovery in complex tibial plateau fractures

*Li HF, Yu T, Zhu XF, Wang H, Zhang YQ*

- 511 Effect of Mirena placement on reproductive hormone levels at different time intervals after artificial abortion

*Jin XX, Sun L, Lai XL, Li J, Liang ML, Ma X*

- 518 Diagnostic value of artificial intelligence automatic detection systems for breast BI-RADS 4 nodules

*Lyu SY, Zhang Y, Zhang MW, Zhang BS, Gao LB, Bai LT, Wang J*

### Clinical Trials Study

- 528 Analysis of 20 patients with laparoscopic extended right colectomy

*Zheng HD, Xu JH, Liu YR, Sun YF*

### Observational Study

- 538 Knowledge, attitude, practice and factors that influence the awareness of college students with regards to breast cancer

*Zhang QN, Lu HX*

- 547 Diagnosing early scar pregnancy in the lower uterine segment after cesarean section by intracavitary ultrasound

*Cheng XL, Cao XY, Wang XQ, Lin HL, Fang JC, Wang L*

- 554 Impact of failure mode and effects analysis-based emergency management on the effectiveness of craniocerebral injury treatment

*Shao XL, Wang YZ, Chen XH, Ding WJ*

- 563 Predictive value of alarm symptoms in Rome IV irritable bowel syndrome: A multicenter cross-sectional study

*Yang Q, Wei ZC, Liu N, Pan YL, Jiang XS, Tantai XX, Yang Q, Yang J, Wang JJ, Shang L, Lin Q, Xiao CL, Wang JH*

### Prospective Study

- 576 5-min mindfulness audio induction alleviates psychological distress and sleep disorders in patients with COVID-19

*Li J, Zhang YY, Cong XY, Ren SR, Tu XM, Wu JF*

### META-ANALYSIS

- 585 Efficacy and safety of argatroban in treatment of acute ischemic stroke: A meta-analysis

*Ly B, Guo FF, Lin JC, Jing F*

## SCIENTOMETRICS

- 594 Biologic therapy for Crohn's disease over the last 3 decades  
*Shen JL, Zhou Z, Cao JS, Zhang B, Hu JH, Li JY, Liu XM, Juengpanich S, Li MS, Feng X*

## CASE REPORT

- 607 Novel compound heterozygous GPR56 gene mutation in a twin with lissencephaly: A case report  
*Lin WX, Chai YY, Huang TT, Zhang X, Zheng G, Zhang G, Peng F, Huang YJ*
- 618 Patients with SERPINC1 rs2227589 polymorphism found to have multiple cerebral venous sinus thromboses despite a normal antithrombin level: A case report  
*Liao F, Zeng JL, Pan JG, Ma J, Zhang ZJ, Lin ZJ, Lin LF, Chen YS, Ma XT*
- 625 Successful management of delirium with dexmedetomidine in a patient with haloperidol-induced neuroleptic malignant syndrome: A case report  
*Yang CJ, Chiu CT, Yeh YC, Chao A*
- 631 Malignant solitary fibrous tumor in the central nervous system treated with surgery, radiotherapy and anlotinib: A case report  
*Zhang DY, Su L, Wang YW*
- 643 Anesthesia and perioperative management for giant adrenal Ewing's sarcoma with inferior vena cava and right atrium tumor thrombus: A case report  
*Wang JL, Xu CY, Geng CJ, Liu L, Zhang MZ, Wang H, Xiao RT, Liu L, Zhang G, Ni C, Guo XY*
- 656 Full-endoscopic spine surgery treatment of lumbar foraminal stenosis after osteoporotic vertebral compression fractures: A case report  
*Zhao QL, Hou KP, Wu ZX, Xiao L, Xu HG*
- 663 Ethambutol-induced optic neuropathy with rare bilateral asymmetry onset: A case report  
*Sheng WY, Wu SQ, Su LY, Zhu LW*
- 671 Vitrectomy with residual internal limiting membrane covering and autologous blood for a secondary macular hole: A case report  
*Ying HF, Wu SQ, Hu WP, Ni LY, Zhang ZL, Xu YG*
- 677 Intervertebral bridging ossification after kyphoplasty in a Parkinson's patient with Kummell's disease: A case report  
*Li J, Liu Y, Peng L, Liu J, Cao ZD, He M*
- 685 Synovial chondromatosis of the hip joint in a 6 year-old child: A case report  
*Yi RB, Gong HL, Arthur DT, Wen J, Xiao S, Tang ZW, Xiang F, Wang KJ, Song ZQ*
- 691 Orthodontic retreatment of an adult woman with mandibular backward positioning and temporomandibular joint disorder: A case report  
*Yu LY, Xia K, Sun WT, Huang XQ, Chi JY, Wang LJ, Zhao ZH, Liu J*

- 703** Autosomal recessive spinocerebellar ataxia type 4 with a *VPS13D* mutation: A case report  
*Huang X, Fan DS*
- 709** Primary adrenal diffuse large B-cell lymphoma with normal adrenal cortex function: A case report  
*Fan ZN, Shi HJ, Xiong BB, Zhang JS, Wang HF, Wang JS*
- 717** Varicella-zoster virus-associated meningitis, encephalitis, and myelitis with sporadic skin blisters: A case report  
*Takami K, Kenzaka T, Kumabe A, Fukuzawa M, Eto Y, Nakata S, Shinohara K, Endo K*
- 725** Tension pneumocephalus following endoscopic resection of a mediastinal thoracic spinal tumor: A case report  
*Chang CY, Hung CC, Liu JM, Chiu CD*
- 733** Accelerated Infliximab Induction for Severe Lower Gastrointestinal Bleeding in a Young Patient with Crohn's Disease: A Case Report  
*Zeng J, Shen F, Fan JG, Ge WS*
- 741** Occupational fibrotic hypersensitivity pneumonia in a halogen dishes manufacturer: A case report  
*Wang M, Fang HH, Jiang ZF, Ye W, Liu RY*
- 747** Using a fretsaw in treating chronic penial incarceration: A case report  
*Zhao Y, Xue XQ, Huang HF, Xie Y, Ji ZG, Fan XR*



**ABOUT COVER**

Associate Editor of *World Journal of Clinical Cases*, Bruno Ramos Chrcanovic, DDS, MSc, PhD, Associate Professor, Department of Prosthodontics, Malmö University, Malmö 241 21, Sweden. [bruno.chrcanovic@mau.se](mailto:bruno.chrcanovic@mau.se)

**AIMS AND SCOPE**

The primary aim of *World Journal of Clinical Cases* (WJCC, *World J Clin Cases*) is to provide scholars and readers from various fields of clinical medicine with a platform to publish high-quality clinical research articles and communicate their research findings online.

WJCC mainly publishes articles reporting research results and findings obtained in the field of clinical medicine and covering a wide range of topics, including case control studies, retrospective cohort studies, retrospective studies, clinical trials studies, observational studies, prospective studies, randomized controlled trials, randomized clinical trials, systematic reviews, meta-analysis, and case reports.

**INDEXING/ABSTRACTING**

The WJCC is now indexed in Science Citation Index Expanded (also known as SciSearch®), Journal Citation Reports/Science Edition, Scopus, PubMed, and PubMed Central. The 2021 Edition of Journal Citation Reports® cites the 2020 impact factor (IF) for WJCC as 1.337; IF without journal self cites: 1.301; 5-year IF: 1.742; Journal Citation Indicator: 0.33; Ranking: 119 among 169 journals in medicine, general and internal; and Quartile category: Q3. The WJCC's CiteScore for 2020 is 0.8 and Scopus CiteScore rank 2020: General Medicine is 493/793.

**RESPONSIBLE EDITORS FOR THIS ISSUE**

Production Editor: *Jia-Hui Li*; Production Department Director: *Xu Guo*; Editorial Office Director: *Jim-Lai Wang*.

**NAME OF JOURNAL**

*World Journal of Clinical Cases*

**ISSN**

ISSN 2307-8960 (online)

**LAUNCH DATE**

April 16, 2013

**FREQUENCY**

Thrice Monthly

**EDITORS-IN-CHIEF**

Bao-Gan Peng, Jerzy Tadeusz Chudek, George Kontogeorgos, Maurizio Serati, Ja Hyeon Ku

**EDITORIAL BOARD MEMBERS**

<https://www.wjgnet.com/2307-8960/editorialboard.htm>

**PUBLICATION DATE**

January 14, 2022

**COPYRIGHT**

© 2022 Baishideng Publishing Group Inc

**INSTRUCTIONS TO AUTHORS**

<https://www.wjgnet.com/bpg/gerinfo/204>

**GUIDELINES FOR ETHICS DOCUMENTS**

<https://www.wjgnet.com/bpg/GerInfo/287>

**GUIDELINES FOR NON-NATIVE SPEAKERS OF ENGLISH**

<https://www.wjgnet.com/bpg/gerinfo/240>

**PUBLICATION ETHICS**

<https://www.wjgnet.com/bpg/GerInfo/288>

**PUBLICATION MISCONDUCT**

<https://www.wjgnet.com/bpg/gerinfo/208>

**ARTICLE PROCESSING CHARGE**

<https://www.wjgnet.com/bpg/gerinfo/242>

**STEPS FOR SUBMITTING MANUSCRIPTS**

<https://www.wjgnet.com/bpg/GerInfo/239>

**ONLINE SUBMISSION**

<https://www.f6publishing.com>

## Retrospective Study

## Analysis of photostimulable phosphor image plate artifacts and their prevalence

Sara Mohamed Elkhateeb, Ashwag Yagoub Aloyouny, Mohamed Mohamed Saeed Omer, Soad Mahmoud Mansour

**ORCID number:** Sara Mohamed Elkhateeb 0000-0002-1570-4524; Ashwag Yagoub Aloyouny 0000-0001-6759-2846; Mohamed Mohamed Saeed Omer 0000-0001-9808-3390; Soad Mahmoud Mansour 0000-0002-7250-5791.

**Author contributions:** Elkhateeb S designed and performed the research, reviewed the literature, contributed to the analysis, wrote and revised the manuscript; Mansour S performed the research, wrote and revised the manuscript; Aloyouny A provided clinical advice and revised the manuscript; Omer M contributed to data collection.

**Institutional review board statement:** This study was reviewed and approved by the Ethics Committee of Princess Nourah Bint Abdulrahman University.

**Informed consent statement:** Clinical data were collected anonymously. Moreover, participants were not required to obtain informed consent to this study because all patients agreed to treatment, sharing clinical data, and participation in research by written consent at the very first visit at College of Dentistry,

Sara Mohamed Elkhateeb, Ashwag Yagoub Aloyouny, Soad Mahmoud Mansour, Department of Basic Dental Science, College of Dentistry, Princess Nourah bint Abdulrahman University, Riyadh 11671, Saudi Arabia

Mohamed Mohamed Saeed Omer, College of Dentistry, Princess Nourah bint Abdulrahman University, Riyadh 11671, Saudi Arabia

**Corresponding author:** Ashwag Yagoub Aloyouny, DDS, Doctor, Department of Basic Dental Science, Princess Nourah bint Abdulrahman University, King Khalid International Airport Road, Riyadh 11671, Saudi Arabia. [ayaloyouny@pnu.edu.sa](mailto:ayaloyouny@pnu.edu.sa)

## Abstract

## BACKGROUND

Digital radiography has recently been used in dentistry as a substitute for conventional film radiography worldwide. Digital imaging has many advantages and provides new possibilities for recording and interpreting radiographic data. This system uses different types of digital receptors.

## AIM

To detect the frequency, type, and reasons behind the appearance of intraoral image artifacts acquired by photostimulable phosphor plates (PSP).

## METHODS

This retrospective descriptive study was conducted in the oral and maxillofacial radiology unit of the dental clinics of the College of Dentistry, Princess Nourah University (PNU). All intraoral digital radiographs were acquired using (Gendex Expert DC., United States) an intraoral X-ray machine with 7 -mA, 65-kVP using a PSP system (Soredex DIGORA Optime imaging plate) and laser scanners (Soredex DIGORA Optime), which can house all sizes of reusable intraoral PSP sensor plates with image acquisition software (MIPACS Dental Enterprise viewer 3.2.2). A total of 50000 intraoral radiographs were retrieved from the clinical database from April 2018 to April 2020 to evaluate the reason, type, and solutions to these image artifacts.

## RESULTS

Overall, 50000 intraoral digital radiographs were acquired in a two-year-period; that is, from April 2018 to April 2020. Of these, 3550 (7.1%) retakes were per-

Princess Nourah Bint  
Abdulrahman university.

**Conflict-of-interest statement:** The authors declare that there no conflict of interest.

**Data sharing statement:** Dataset is available from the corresponding author at [ayaloyouny@pnu.edu.sa](mailto:ayaloyouny@pnu.edu.sa). Participants gave informed consent for data sharing.

**Supported by** the Deanship of Scientific Research, Princess Nourah bint Abdulrahman University, through the Program of Research Project Funding After publication, No. 41-PRFA-P-16.

**Country/Territory of origin:** Saudi Arabia

**Specialty type:** Medicine, research and experimental

**Provenance and peer review:** Unsolicited article; Externally peer reviewed.

**Peer-review model:** Single blind

**Peer-review report's scientific quality classification**

Grade A (Excellent): 0

Grade B (Very good): B

Grade C (Good): 0

Grade D (Fair): 0

Grade E (Poor): 0

**Open-Access:** This article is an open-access article that was selected by an in-house editor and fully peer-reviewed by external reviewers. It is distributed in accordance with the Creative Commons Attribution NonCommercial (CC BY-NC 4.0) license, which permits others to distribute, remix, adapt, build upon this work non-commercially, and license their derivative works on different terms, provided the original work is properly cited and the use is non-commercial. See: <http://creativecommons.org/licenses/by-nc/4.0/>

**Received:** June 14, 2021

**Peer-review started:** June 14, 2021

**First decision:** October 18, 2021

**Revised:** October 25, 2021

**Accepted:** December 10, 2021

formed due to the presence of image artifacts. Periapical radiographs were the most common image type of intraoral retakes (80.8%). Imaging artifacts were divided into three categories: operator, plate and scanning errors. Out of 3550 retakes, 5%, 1.37%, and 0.73% were related to operator, plate, and scanning errors, respectively. The cone cut was the most common operator error (988 images), Bite marks were the most common plate error (276 images), and delayed scanning artifacts were the most common scanning errors (145 images). The calculated kappa value for interobserver reliability was 0.99, indicating almost perfect interobserver agreement.

## CONCLUSION

Our study discussed intraoral image artifacts that were characteristic of PSP, where the most common artifacts were bitemarks, image size reduction, scratches, and delayed scanning.

**Key Words:** Photostimulable phosphor image; Artifacts; Intraoral radiographs; Errors; Prevalence and types

©The Author(s) 2022. Published by Baishideng Publishing Group Inc. All rights reserved.

**Core Tip:** Digital radiography has been used widely in dentistry as a substitute to conventional film radiography. Digital radiography holds many advantages and provides a wide range of possibilities to interpret and archive radiographic images. The latter system uses different types of digital receptors, and as any recent technology, different types of image pitfalls are expected. Therefore, these pitfalls render improper diagnosis for the radiographic images. The appearance of intraoral radiographic image artifacts can be produced by using the reusable intraoral photostimulable phosphor sensor plates. Thus, recognizing these errors and defining the causes and their troubleshooting are crucial factors in making images possess great clinical impacts.

**Citation:** Elkhateeb SM, Aloyouny AY, Omer MMS, Mansour SM. Analysis of photostimulable phosphor image plate artifacts and their prevalence. *World J Clin Cases* 2022; 10(2): 437-447

**URL:** <https://www.wjgnet.com/2307-8960/full/v10/i2/437.htm>

**DOI:** <https://dx.doi.org/10.12998/wjcc.v10.i2.437>

## INTRODUCTION

Digital radiography has recently been used in dentistry as a substitute for conventional film radiography worldwide. Digital imaging provides new possibilities for recording and interpreting radiographic data in a user-friendly digital way for archiving and teleradiography[1]. Digital imaging has many advantages over film-based radiography, such as real-time imaging, not needing the use of darkroom chemicals, having image manipulation tools, better archiving, and decreased patient and operator radiation exposure[2-6].

Dental radiography is provided by two main types of radiography: Conventional and digital radiography. Conventional radiography uses dental films that require chemical solutions for processing, more human resources, is time consuming, and with a higher radiation dose. This traditional type of radiography provides a permanent record of imaging without any possibility for archiving, and any error requires the retake of the radiograph, which exposes the patient to unnecessary additional radiation exposure. This is in contrast to digital radiography, which allows image manipulation to correct the visual characteristics of the image, such as contrast, brightness, and density, thus enhancing image quality without the need to retake the image. Digital radiography permits easy archiving of images and their electronic transfer between different specialties in the dental field. Digital radiographic technology uses electronic image receptors (digital sensors or plates), which are based on two main techniques in acquiring the image: A direct method using a charge-coupled device (CCD) or complementary metal oxide semiconductor (CMOS) sensors [7] that transmit the signal of the exposed plate directly over a wire with a real-time



Article in press: December 10, 2021

Published online: January 14, 2022

P-Reviewer: Aoun G

S-Editor: Wang LL

L-Editor: A

P-Editor: Wang LL



image on the monitor or indirect method using a photostimulable phosphor storage plate (PSP), which forms a latent image when exposed to radiation. The stored energy is then transported to a computer for display using a laser scanner[8-10].

The scanning times of PSP plates vary from a few seconds to several minutes, depending on the type of laser scanner used and the spatial and contrast resolutions of the image[5]. PSP plates are available in a variety of sizes in a way similar to conventional films, so they are vulnerable to bending and scratching during handling[2,11].

Moreover, PSP plates must be handled more carefully than films because they are reusable after erasing the image[12]. PSP plates are selected by most dental practitioners because of their easy intraoral placement with little patient discomfort, as well as them being cordless and resembling conventional films. This is in comparison to the more difficult intraoral placement of CCD plates, with more patient discomfort caused by the stiffness of these plates with a cord linking them to the computer even though an image can be obtained promptly by the practitioner after exposure of the plate in this system[11,12].

Digital radiography, like any evolving technology, produces a new type of image pitfall that remains a problem for clinicians in that it can be overwhelming. To the best of our knowledge, a systematic review of dental digital radiography artifacts in clinical usage has not yet been reported[13]. In addition, few studies have assessed PSP image errors using illustrative figures[14].

## MATERIALS AND METHODS

This retrospective descriptive study was conducted in the oral and maxillofacial radiology unit of the dental clinics of the College of Dentistry, Princess Nourah University (PNU), where conventional film-based radiography was gradually replaced by digital radiography starting in 2018. All the intraoral digital radiographs were acquired using (Gendex Expert DC., United States) an intraoral X-ray machine with 7 - mA 65-kVP using a PSP system (Soredex DIGORA Optime imaging plate) and laser scanners (Soredex DIGORA Optime), which can house all sizes of reusable intraoral PSP sensor plates with image acquisition software (MIPACS Dental Enterprise viewer 3.2.2).

The investigators retrieved all the digital intraoral periapical and bitewing radiographs that were taken and approved by the clinicians from all dental specialties in our college and with the consent of the patients from April 2018 to April 2020. We used the Medicor Imaging/MIPACS Toolkit software, which regularly detects and records all deleted radiographs due to retakes performed by all oral radiology technicians in the radiology unit with clarification of the image type. All the retakes were screened by two well-experienced oral and maxillofacial radiologists for evaluation of the present artifact type and cause, while the remaining images without errors were excluded from the study. Artifacts were classified into three categories: plate errors, scanning errors, and operator errors. First, two observers sat together in a collaboration session to determine the criteria and subtypes for each category of digital artifacts to unify the interpretation process.

The observers independently evaluated and agreed on image artifacts. When disagreement existed among them, consensus was reached through discussion. Out of the selected cases, 1000 images with errors were reevaluated by both investigators after 2 wk for the calculation of interobserver reliability. Our retrospective study was approved by the institutional review board (IRB) of PNU.

### Statistical analysis

Statistical analysis was performed using SPSS Statistics version 23 (IBM Corp., New York, NY; formerly SPSS Inc., Chicago, IL, United States), and the frequencies and percentages of PSP artifacts were calculated. Interobserver reliability was analyzed with kappa analyses, which was interpreted as follows: *P* value < 0 denoted less than chance agreement, 0.01-0.20 denoted slight agreement, 0.21-0.40 denoted fair agreement, 0.41-0.60 denoted moderate agreement, 0.61-0.80 indicated substantial agreement, and 0.81-0.99 was considered almost perfect agreement[13].

## RESULTS

A total of 50000 intraoral digital radiographs were acquired in the 2 year-period from

April 2018 to April 2020. Of these, 3550 (7.1%) retakes were performed due to the presence of image artifacts. Of these retakes, 5% was related to operator errors and 2.1% was related to plate and scanning errors. The calculated kappa value for interobserver reliability was 0.99, indicating almost perfect interobserver agreement.

Intraoral radiographs requiring retakes due to image artifacts included 2869 (80.8%) periapical (PA) images, 518 (14.6%) bite wing images, and 163 blank images (4.6%).

Imaging artifacts were divided into three categories. Of the 3550 retakes, operator errors were the most common and were observed in 2500 images (70.4%), while plate errors were detected in 685 images (19.3%) and scanning errors in 365 images (10.3%).

### Operator errors

In this study, the operator error category consisted of eight subtypes that were closely similar to the same error categories in conventional film radiography, as this type of artifact does not depend on the type of image receptor except for the reversed or mirror image, movement of the plate inside the packet, and double exposure in the plate either due to partial erasing of the previous image or failure of the image scanning.

The cone cut was the most common error observed in 988 images (39.5%) out of 3550 images (Figure 1A), followed by the artifacts of improper PSP placement in the mouth (30.4%), projection geometry (22.4%), unexposed plate (4.5%), movement of phosphor plate in the disposable pocket (1.6%) (Figure 1A and B), reversed image (0.8%) (Figure 1c and d), overexposed (0.6%), and plate bending (0.3%).

### Plate errors

Bite marks were the most common error observed in 276 images (40.3%), while image size reduction was detected in 174 images (25.4%). In addition, plate scratches were detected in 19.6% of cases, with other errors being contamination of PSP (6.5%), peeling of the coat (5.7%), plate damage (2.3%), and fingerprints (0.1%) (Figures 2, 3 and 4).

### Scanning errors

Delayed scanning artifacts (non-uniform density or bright image) were the most common errors observed in 145 images (39.9%). White (radiopaque) lines (37.2%), blank images (13.4%), black (radiolucent) lines (5.5%), and double images (incomplete or partial erasing) (4.1%) were also seen. (Table 1, Figures 5 and 6).

## DISCUSSION

Digital intraoral imaging systems have gradually replaced film-based imaging in recent years, as this technology has many advantages over conventional imaging. Two types of receptors are used for digital intraoral radiography: solid-state sensors of either CCD or CMOS, which are used with a wire and PSP plates that are cordless. Solid-state sensors have been used for more than two decades, while systems that use PSP plates have only recently been used in clinical practice. Each receptor type has its own advantages and disadvantages[2].

PSP and CCD digital systems are preferred over traditional films because of the lower radiation dose for both patients and operators, less time needed, ability to perform image manipulation as well as enhancement without the need for retake, better archiving, and environmental friendliness.

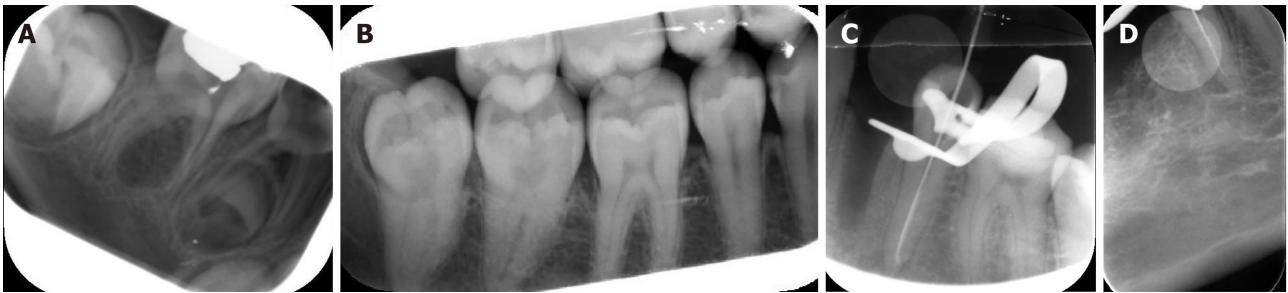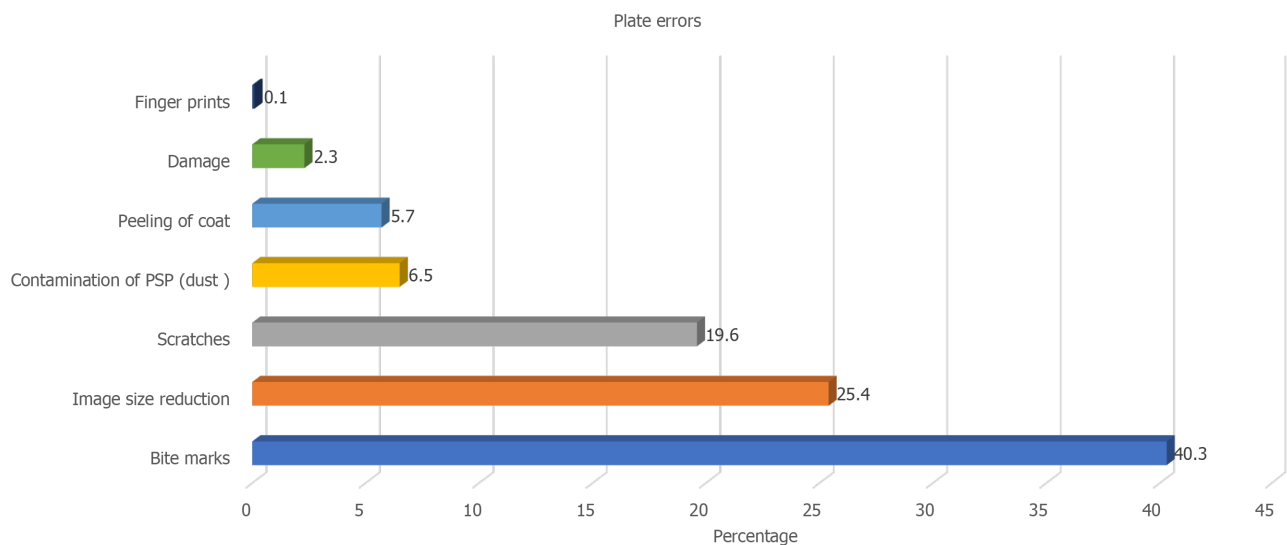
PSP plates are more comfortable to the patient than CCD because they are cordless, more flexible, and thin, which resembles standard films. However, despite their superiority, PSP plates are more susceptible to bending and scratches, require more time for scanning, and subsequently develop more image artifacts, which consequently affects image quality[15]. In previous studies, it has been stated that 95% of PSP plates used for 10 wk (used approximately 50 times) became non-diagnostic and needed to be substituted[16,17].

Radiographic artifacts that occur with plain film radiography are well-identified and documented. However, to the best of our knowledge, few studies have reported and categorized the artifacts of PSP plates[17-21]. Most of these studies investigated them in medical radiology; however, very few studies were correlated to the dental field[14,15,20,22].

Moreover, to reduce the radiation exposure of the patient, it is clinically important to avoid the occurrence of image artifacts in order to minimize repeated radiographs, which could happen through proper understanding of the reasons and solutions for

**Table 1** Frequency and percentage of scanning errors

Subtype	Frequency	Percent
Delayed scanning	145	39.9
White lines	136	37.2
Blank	49	13.4
Black lines	20	5.5
Double image	15	4.1
Total	365	100

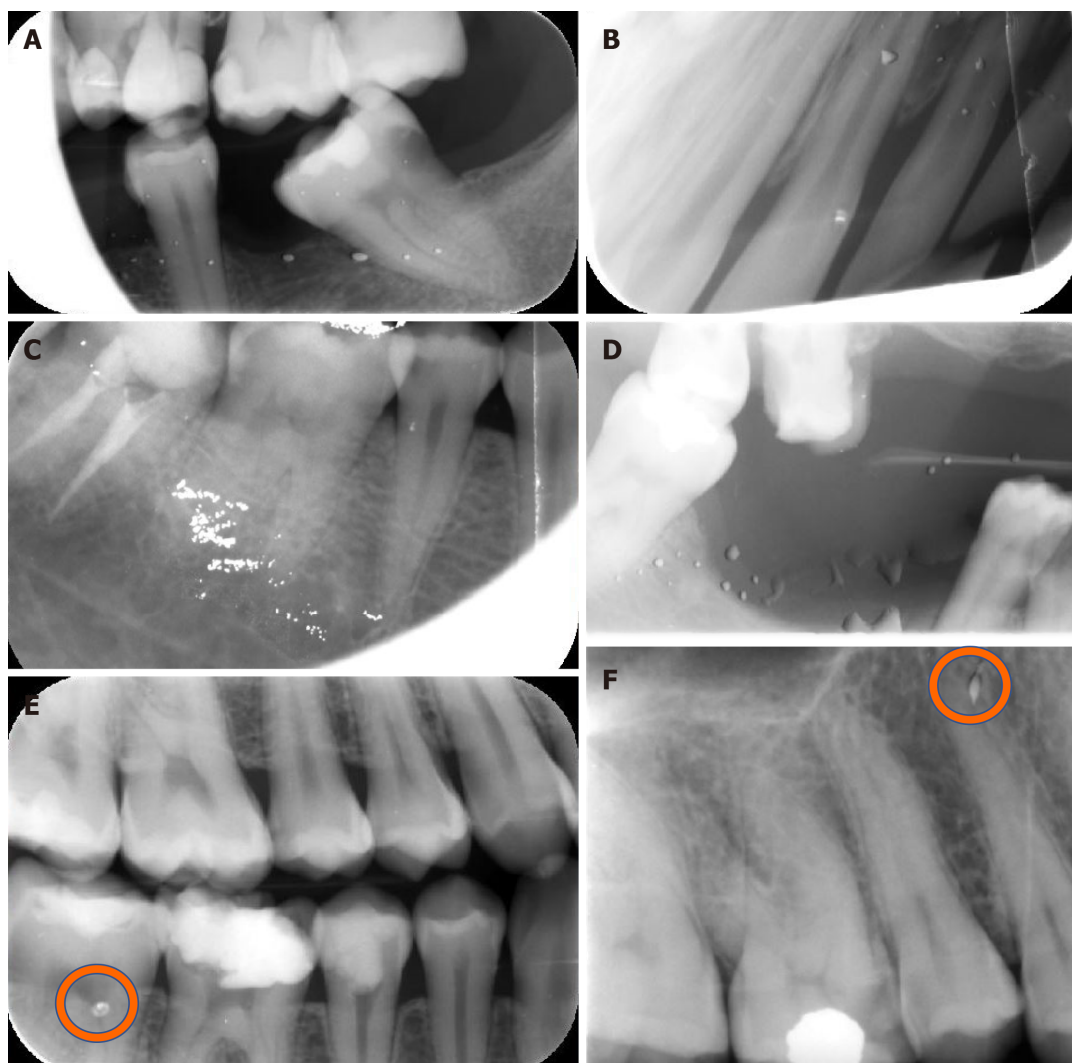
**Figure 1** Periapical and bitewing radiographs show some operator errors. A: Movement of phosphor plate inside the disposable packet; B: Movement of phosphor plate in the disposable packet and plate scratch; C: Reversed image, cone cut and white line; D: Reversed image and improper plate placement.**Figure 2** Bar chart illustrating frequency and percentage of plate errors.

incidence of image artifacts and thus lessen its frequency, especially in the recent commonly used dental digital imaging technology[14].

Therefore, the aim of this study was to detect the type, frequency, and reasons for the occurrence of intraoral image artifacts acquired by PSP plates in our dental clinics, and to propose probable methods to avoid these image artifacts.

In the present study, the examined intraoral radiographic errors were categorized into three main categories: operator, plate, and scanning errors. Operator errors were the most common and were observed in 2500 out of 50000 intraoral images (5%) and in 70% of 3550 retakes, which is in accordance with the findings of Hui-Lin Chiu *et al*[23] 2008. regarding the increased incidence of operator errors as seen in the current study. In addition, this reflects the need for broader training of radiology technicians.

In the present study, only 0.07% of 50000 intraoral images reported in the existing study presented with movement artifacts of the PSP plate inside the disposable packet. However, in Gulsahi and Secgin study in 2016, it was recorded frequently, whereas



**Figure 3 Bitewing and periapical radiographs show some plate errors.** A: Plate contamination and cone cut; B: Plate contamination, plate movement inside packet, white line, black line, and image distortion; C: Plate contamination, white line and cone cut; D: Plate contamination and non-uniform image; E: Bitemarks; F: Plate scratch.

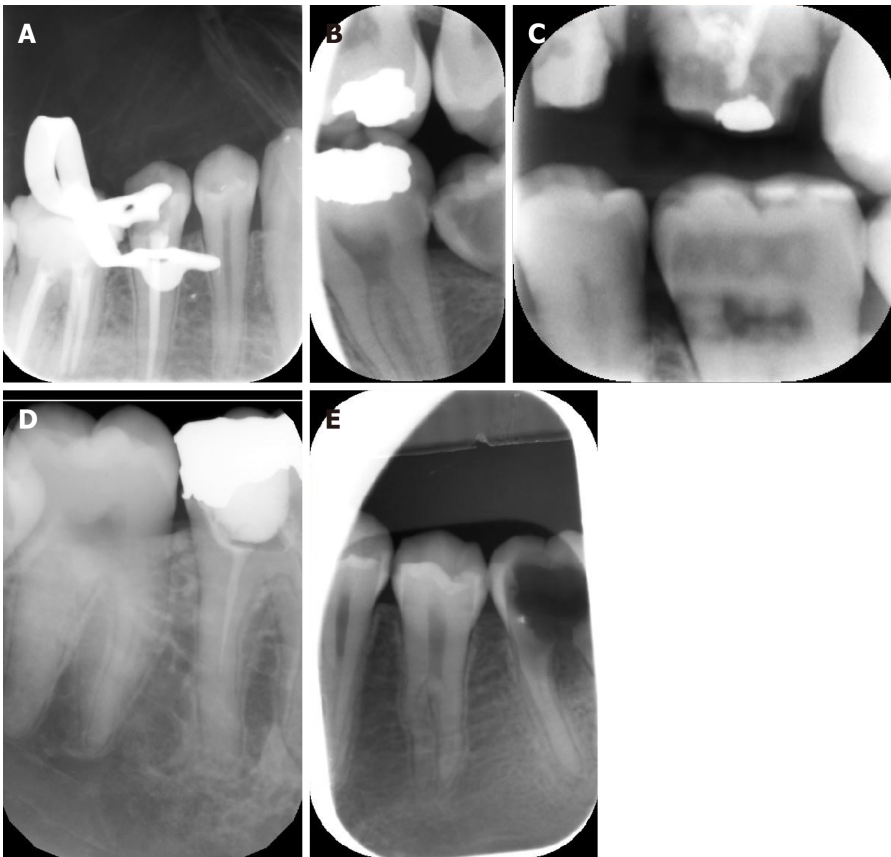
other studies did not report this type of artifact. It has been stated that this artifact is detected only with the Digora system, where both cardboard cover and disposable plastic envelopes should be used. While the cardboard cover is used to protect the PSP plates, they may unfortunately cause motion of the plates, resulting in these artifacts [24].

The second most common errors in the current study were plate errors that were detected in 685 intraoral images (1.37% of total images and 19.3% of retakes), followed by scanning errors seen in 365 intraoral images (0.73% of total images and 10.3% of retakes). Chiu *et al* [23] 2008 reported that scanning errors were the second most common error, followed by plate errors.

In the current study, bite marks were the most common plate error subtypes observed in 276 images (40.3%).

The most probable cause of the increased incidence of bitemarks in our study is the disposable plastic packet. It is used for infection control and acts as a light barrier, but it does not provide proper safety against plate damage from bite marks, bending, or pressure. Another possible reason for plate bitemarks would be the patient unintentionally biting on the plate. Thus, the patient must be comprehensively instructed to avoid doing so before the exposure.

It was reported that pediatric periapical radiographs of primary incisors that were taken by a modified technique by making the child bite on a size 2 PSP plate to keep it in place during exposure simulating occlusal radiograph could be one of the reasons for PSP bite marks. Snap-A ray film holding devices with teeth-like edges were used. Roberts, Mol, 2004 reported that the risk of teeth biting in pediatric primary incisors can be reduced by placing “adhesive backed sponge-like pads” on each side of the



**Figure 4** Periapical and bitewing radiographs show some plate errors. A: Plate scratches; B-D: image size reduction; E: Image size reduction and movement of plate inside packet.

disposable sleeve that holds the reusable size 2 plate[2].

Image size reduction artifact after scanning was reported in 174 images (25.4% of retakes) and 0.3% of all intraoral images, which can be related to scanning errors. This was also reported by various studies[20].

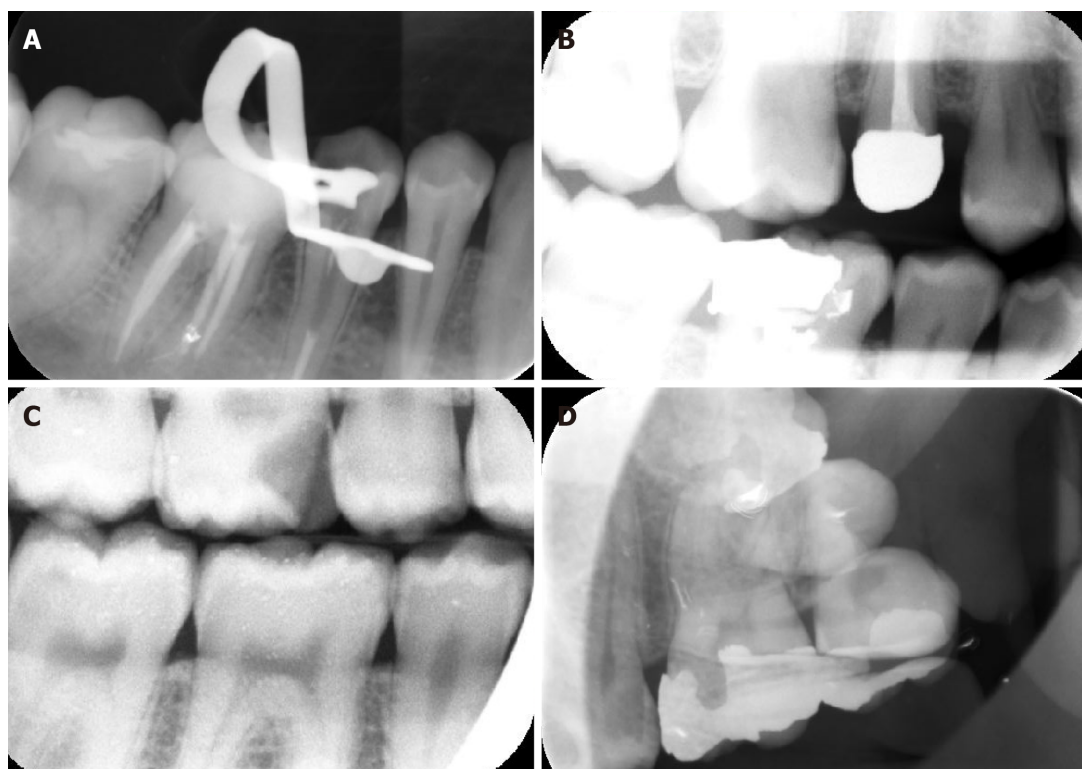
In the present study, PSP plate scratches were detected in 19.6% of patients, while surface contamination of PSP was seen in 6.5%. To the best of our knowledge, the actual reasons for plate surface contamination and scratches have not been completely recognized and investigated. Kalathingall *et al*[17] 2010 stated that the possible cause of plate surface contamination could be the adhesive utilized in the barrier sheath, which could have affected the plate before scanning. The same study found that the plates that were used in dental colleges, as in our study, were more susceptible to scratches because of the increased number of people handling the plate, especially when they were discovered after scanning and before packaging the plate with a new protective sheath. Also, Kalathingall *et al*[17] 2010 reported that the hard rubbing of PSP plates with alcohol could be a cause for more scratches, and recommended that only the plates with visible surface contamination should be lightly wiped to remove any contaminants[17].

In the current study, peeling of the coat was found in 5.7%, plate damage was recorded in 2.3%, and fingerprints were found in 0.1% of plates. These findings were in the line with those reported by Gulsahi and Secgin in 2016, wherein they found damaged plates to occur in only a few images[20]. The most probable causes of plate damage are tough handling of PSP plates during their placement in the mouth, extensive bending, forceful placement of the plate into the scanner, or mechanical stresses exerted by the scanner roller during scanning[15].

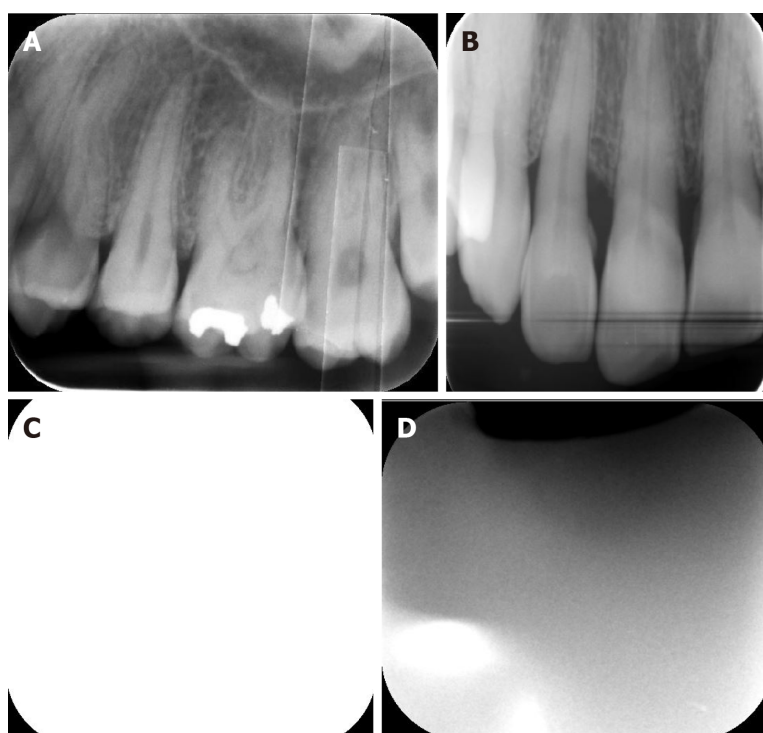
Scanning errors were detected in 365 images (0.73% of all intraoral images), where delayed scanning was the most common error in this type and was seen in 145 images (0.29%). Despite Gulsahi and Secgin[24] reporting 12.6% of all images exhibited non-uniform brightness in their 2016 study, Chiu *et al*[23] recorded 0.4% delayed scanning errors in their 2008 study.

Although PSP plates can be exposed to regular light while being uncovered and imported into the scanner, it is recommended that exposure to regular light should not exceed 10 minutes, and that the scanning procedure should not be delayed more than





**Figure 5** Periapical and bitewing radiographs show some scanning errors. A and B: Non-uniformity of the image; C: bright noisy image; D: Double image due to incomplete erasing.



**Figure 6** Periapical radiographs show some scanning errors. A: Multiple white lines; B: Black line; C: Blank image; D: Inhomogeneous image.

that. Otherwise, the information in the plate will fade away[24], which will lead to increased signal loss and a reduction in the signal-to-noise ratio[25,26]. It could appear as total image fading with too bright an image or non-uniform image density caused by partial exposure of PSP to excessive ambient light before scanning. In addition, fluctuating signal loss leads to a noisy image[24].

In the current study, the most common subtype of scanning error was delayed scanning (39.9% of retakes), which was comparable to the results of Çalışkan and Sumer in their study in 2017, who affirmed that the probable cause for this artifact is the elimination of the plate from its cover after radiation exposure to inhibit infection before scanning[24].

It has been reported that the higher the light intensity and the longer the exposure time, the greater the loss of plate information[27]. This was supported by the study of Ang DB in 2006, which reported that plates were not exposed to any light before scanning presented no change in image quality even after many days of storage[25,28].

The second scanning error was the presence of white lines in 136 images (37.2%), which were reported to be due to dust or dirt particles on the slim scanning opening of the scanner. This caused them to remain fixed during the scanning process or dirt on the rollers, which acted as a blockage to the laser light. Thus, resulting in production of areas devoid of signals. Therefore, the mechanical scanner transport system should be checked and cleaned regularly, with additional replacement of the belt, if necessary [15].

The black or radiolucent lines that were detected in 20 images (5.5%) were hypothesized by a previous study to have resulted from electromagnetic interfering artifacts that were caused by anything that interfered, interrupted, decreased, or limited efficient scanner performance[15,29].

Moreover, Çalışkan A and Sumer AP[26] denoted this artifact as a ridging artifact, and advocated that these black lines occurred due to fast variations in the intensity of the light of the stimulating lasers as well as the loss of harmonization between rapid scan cycles and image plate movement. It is recommended to add proper electromagnetic shielding, appropriate voltage supply, uninterrupted power supply, and regular maintenance of scanner performance to avoid the occurrence of artifacts in radiolucent lines[15].

The previously mentioned errors observed in our study could be limited by proper regular orientation and enforcement by all operators, technicians, and students of the appropriate procedures of gentle handling of the PSP plates during exposure, scanning, and after scanning. This also includes focusing on the correct light rubbing of the PSP plates only with visible surface contamination to increase their longevity and usability. Moreover, regular checkups of PSP plates should be regularly performed to check the integrity of the plates. In addition, periodic maintenance, cleaning, and calibration of scanning devices would significantly reduce the number of scanning errors. Furthermore, additional comprehensive training of radiology technicians regarding application of proper radiographic techniques using the PSP system would be very beneficial in reducing operator errors.

## CONCLUSION

The use of digital imaging in dental practice has recently made a revolution in image recording and analysis. Our institution made a significant modification by digitizing all dental images recently acquired using mainly the PSP system. Our study investigated the prevalence of intraoral image artifacts in our clinics, which were characteristic of PSP plates wherein the most common artifacts were bitemarks, image size reduction, scratches, and delayed scanning. Defining the causes of these artifacts and identifying methods for preventing them are of great clinical significance. Further research on PSP artifacts for further error identification and proper handling is needed and is a process that is essential to produce superior diagnostic images needed for instituting proper dental care.

## ARTICLE HIGHLIGHTS

### Research background

Nowadays, digital imaging outweighs conventional imaging and has been used widely in dentistry. Digital radiography allows image manipulation to adjust the visual characteristics of the image, such as contrast, brightness, and density, thus enhancing image quality without the need to retake the image.

### Research motivation

Digital imaging provides an easier, comfortable, and user-friendly way for recording

and interpreting radiographic data for archiving and teleradiography.

### Research objectives

To detect the frequency, type, and reasons behind the appearance of intraoral image artifacts acquired by photostimulable phosphor plates (PSP).

### Research methods

This retrospective descriptive study. A total of 50000 intraoral radiographs were retrieved from the clinical database from April 2018 to April 2020 to evaluate the reason, type, and solutions to these image artifacts. All intraoral digital radiographs were acquired using an intraoral X-ray machine with 7 -mA, 65-kVP using a PSP system and laser scanners, which can house all sizes of reusable intraoral PSP sensor plates with image acquisition software.

### Research results

Imaging artifacts were divided into three categories; operator, plate, and scanning errors. Out of 3550 retakes, 5%, 1.37%, and 0.73% were related to the operator, plate, and scanning errors, respectively. The cone cut was the most common operator error (988 images), Bite marks were the most common plate error (276 images), and delayed scanning artifacts were the most common scanning errors (145 images).

### Research conclusions

Our study discussed intraoral image artifacts that were characteristic of PSP, where the most common artifacts were bitemarks, image size reduction, scratches, and delayed scanning.

### Research perspectives

Thus, recognizing intraoral radiographic image errors and defining the causes and their trouble-shooting are crucial factors in making images possess great clinical impacts.

## REFERENCES

- 1 White SC, Pharoah MJ. White and pharoah's oral radiology: principles and interpretation. 8th edition. St. Louis: Elsevier Health Sciences, 2019: 40-60
- 2 Roberts MW, Mol A. Clinical techniques to reduce sensor plate damage in PSP digital radiography. *J Dent Child (Chic)* 2004; **71**: 169-170 [PMID: 15587103]
- 3 Malleshi SN, V G M, Raina A, Patil K. A Subjective Assessment of Perceived Clarity of Indirect Digital Images and Processed Digital Images with Conventional Intra-oral Periapical Radiographs. *J Clin Diagn Res* 2013; **7**: 1793-1796 [PMID: 24086916 DOI: 10.7860/JCDR/2013/5545.3278]
- 4 Ludlow JB MA. Digital imaging. In: White SC, Pharoah MJ, editors. Oral Radiology: Principles and Interpretation. St. Louis, Missouri: Mosby, Elsevier, 2014: 41-62
- 5 Berkhout WE, Sanderink GC, Van der Stelt PF. A comparison of digital and film radiography in Dutch dental practices assessed by questionnaire. *Dentomaxillofac Radiol* 2002; **31**: 93-99 [PMID: 12076062 DOI: 10.1038/sj.dmf.4600669]
- 6 Wenzel A, Møystad A. Work flow with digital intraoral radiography: a systematic review. *Acta Odontol Scand* 2010; **68**: 106-114 [PMID: 20141365 DOI: 10.3109/00016350903514426]
- 7 Ajmal M, Elshinawy MI. Subjective image quality comparison between two digital dental radiographic systems and conventional dental film. *Saudi Dent J* 2014; **26**: 145-150 [PMID: 25382946 DOI: 10.1016/j.sdentj.2014.05.007]
- 8 van der Stelt PF. Better imaging: the advantages of digital radiography. *J Am Dent Assoc* 2008; **139** Suppl: 7S-13S [PMID: 18539866 DOI: 10.14219/jada.archive.2008.0357]
- 9 Parks ET, Williamson GF. Digital radiography: an overview. *J Contemp Dent Pract* 2002; **3**: 23-39 [PMID: 12444400]
- 10 Chiu HL, Wei YW, Wang WC, Chen YK. Simple and effective methods to protect the photostimulable phosphor storage plate sensor. *J Dent Sci* 2018; **13**: 85-86 [PMID: 30895101 DOI: 10.1016/j.jds.2017.08.004]
- 11 Macdonald R. Digital imaging for dentists. *Aust Dent J* 2001; **46**: 301-305 [DOI: 10.1111/j.1834-7819.]
- 12 Kitagawa H, Farman AG, Scheetz JP, Brown WP, Lewis J, Benefiel M. Comparison of three intra-oral storage phosphor systems using subjective image quality. *Dentomaxillofac Radiol* 2000; **29**: 272-276 [DOI: 10.1038/sj.dmf.4600532]
- 13 Borg E. Some characteristics of solid-state and photo-stimulable phosphor detectors for intra-oral radiography. *Swed Dent J Suppl* 1999; **139**: i-viii, 1 [PMID: 10635104]
- 14 Hildebolt CF, Couture RA, Whiting BR. Dental photostimulable phosphor radiography. *Dent Clin*

- North Am* 2000; **44**: 273-297, vi [PMID: [10740769](#)]
- 15 **Viera AJ**, Garrett JM. Understanding interobserver agreement: the kappa statistic. *Fam Med* 2005; **37**: 360-363 [PMID: [15883903](#)]
  - 16 **Deniz Y**, Kaya S. Determination and classification of intraoral phosphor storage plate artifacts and errors. *Imaging Sci Dent* 2019; **49**: 219-228 [PMID: [31583205](#) DOI: [10.5624/isd.2019.49.3.219](#)]
  - 17 **Kalathingal SM**, Shrout MK, Comer C, Brady C. Rating the extent of surface scratches on photostimulable storage phosphor plates in a dental school environment. *Dentomaxillofac Radiol* 2010; **39**: 179-183 [PMID: [20203281](#) DOI: [10.1259/dmfr/28972644](#)]
  - 18 **Shetty CM**, Barthur A, Kambadakone A, Narayanan N, Kv R. Computed radiography image artifacts revisited. *AJR Am J Roentgenol* 2011; **196**: W37-W47 [PMID: [21178029](#) DOI: [10.2214/AJR.10.5563](#)]
  - 19 **Oestmann JW**, Prokop M, Schaefer CM, Galanski M. Hardware and software artifacts in storage phosphor radiography. *Radiographics* 1991; **11**: 795-805 [PMID: [1947316](#) DOI: [10.1148/radiographics.11.5.1947316](#)]
  - 20 **Willis CE**, Thompson SK SS. Artifacts and misadventures in digital radiography. *Appl Radiol* 2004; **33**: 11-21
  - 21 **Cesar LJ**, Schueler BA, Zink FE, Daly TR, Taubel JP, Jorgenson LL. Artefacts found in computed radiography. *Br J Radiol* 2001; **74**: 195-202 [PMID: [11718396](#) DOI: [10.1259/bjr.74.878.740195](#)]
  - 22 **Bedard A**, Davis TD, Angelopoulos C. Storage phosphor plates: how durable are they as a digital dental radiographic system? *J Contemp Dent Pract* 2004; **5**: 57-69 [PMID: [15150634](#)]
  - 23 **Chiu HL**, Lin SH, Chen CH, Wang WC, Chen JY, Chen YK, Lin LM. Analysis of photostimulable phosphor plate image artifacts in an oral and maxillofacial radiology department. *Oral Surg Oral Med Oral Pathol Oral Radiol Endod* 2008; **106**: 749-756 [PMID: [18547836](#) DOI: [10.1016/j.tripleo.2008.01.003](#)]
  - 24 **Gulsahi A**, Secgin CK. Assessment of intraoral image artifacts related to photostimulable phosphor plates in a dentomaxillofacial radiology department. *Niger J Clin Pract* 2016; **19**: 248-253 [PMID: [26856290](#) DOI: [10.4103/1119-3077.164338](#)]
  - 25 **Akdeniz BG**, Gröndahl HG, Kose T. Effect of delayed scanning of storage phosphor plates. *Oral Surg Oral Med Oral Pathol Oral Radiol Endod* 2005; **99**: 603-607 [PMID: [15829885](#) DOI: [10.1016/j.tripleo.2004.10.021](#)]
  - 26 **Çalışkan A**, Sumer AP. Definition, classification and retrospective analysis of photostimulable phosphor image artefacts and errors in intraoral dental radiography. *Dentomaxillofac Radiol* 2017; **46**: 20160188 [PMID: [27883287](#) DOI: [10.1259/dmfr.20160188](#)]
  - 27 **Ramamurthy R**, Canning CF, Scheetz JP, Farman AG. Impact of ambient lighting intensity and duration on the signal-to-noise ratio of images from photostimulable phosphor plates processed using DenOptix and ScanX systems. *Dentomaxillofac Radiol* 2004; **33**: 307-311 [PMID: [15585807](#) DOI: [10.1259/dmfr/91373164](#)]
  - 28 **Ang DB**, Angelopoulos C, Katz JO. How does signal fade on photo-stimulable storage phosphor imaging plates when scanned with a delay and what is the effect on image quality? *Oral Surg Oral Med Oral Pathol Oral Radiol Endod* 2006; **102**: 673-679 [PMID: [17052646](#) DOI: [10.1016/j.tripleo.2005.11.002](#)]
  - 29 **Seeram E**. Computed radiography: physics and technology. In: Digital radiography. Singapore: Springer, 2019: 41-63



Published by **Baishideng Publishing Group Inc**  
7041 Koll Center Parkway, Suite 160, Pleasanton, CA 94566, USA

**Telephone:** +1-925-3991568

**E-mail:** [bpgoffice@wjgnet.com](mailto:bpgoffice@wjgnet.com)

**Help Desk:** <https://www.f6publishing.com/helpdesk>

<https://www.wjgnet.com>

