

World Journal of *Clinical Cases*

World J Clin Cases 2021 November 26; 9(33): 10052-10391



Contents

Thrice Monthly Volume 9 Number 33 November 26, 2021

REVIEW

- 10052** Effects of alcohol consumption on viral hepatitis B and C

Xu HQ, Wang CG, Zhou Q, Gao YH

MINIREVIEWS

- 10064** Effects of anti-diabetic drugs on sarcopenia: Best treatment options for elderly patients with type 2 diabetes mellitus and sarcopenia

Ma XY, Chen FQ

ORIGINAL ARTICLE

Retrospective Cohort Study

- 10075** Utility of cooling patches to prevent hand-foot syndrome caused by pegylated liposomal doxorubicin in breast cancer patients

Zheng YF, Fu X, Wang XX, Sun XJ, He XD

Retrospective Study

- 10088** Clinicopathological features of small T1 colorectal cancers

Takashina Y, Kudo SE, Ichimasa K, Kouyama Y, Mochizuki K, Akimoto Y, Maeda Y, Mori Y, Misawa M, Ogata N, Kudo T, Hisayuki T, Hayashi T, Wakamura K, Sawada N, Baba T, Ishida F, Yokoyama K, Daita M, Nemoto T, Miyachi H

- 10098** Comparison of dental pulp periodontal therapy and conventional simple periodontal therapy as treatment modalities for severe periodontitis

Li L, Chen HJ, Lian Y, Wang T

- 10106** Tripartite intensive intervention for prevention of rebleeding in elderly patients with hypertensive cerebral hemorrhage

Li CX, Li L, Zhang JF, Zhang QH, Jin XH, Cai GJ

- 10116** Clinical and electroencephalogram characteristics and treatment outcomes in children with benign epilepsy and centrotemporal spikes

Chen RH, Li BF, Wen JH, Zhong CL, Ji MM

- 10126** Endoscopic ultrasonography diagnosis of gastric glomus tumors

Bai B, Mao CS, Li Z, Kuang SL

- 10134** Learning curves of robot-assisted pedicle screw fixations based on the cumulative sum test

Yu J, Zhang Q, Fan MX, Han XG, Liu B, Tian W

- 10143** Value of GRACE and SYNTAX scores for predicting the prognosis of patients with non-ST elevation acute coronary syndrome

Wang XF, Zhao M, Liu F, Sun GR

- 10151** Effectiveness of enhanced recovery after surgery in the perioperative management of patients with bone surgery in China

Zhao LY, Liu XT, Zhao ZL, Gu R, Ni XM, Deng R, Li XY, Gao MJ, Zhu WN

Clinical Trials Study

- 10161** Association between plasma dipeptidyl peptidase-4 levels and cognitive function in perinatal pregnant women with gestational diabetes mellitus

Sana SRGL, Li EY, Deng XJ, Guo L

- 10172** Paricalcitol in hemodialysis patients with secondary hyperparathyroidism and its potential benefits

Chen X, Zhao F, Pan WJ, Di JM, Xie WN, Yuan L, Liu Z

Observational Study

- 10180** Did the severe acute respiratory syndrome-coronavirus 2 pandemic cause an endemic *Clostridium difficile* infection?

Cojocariu C, Girleanu I, Trifan A, Olteanu A, Muzica CM, Huiban L, Chiriac S, Singeap AM, Cuciureanu T, Sfarti C, Stanciu C

- 10189** Effect of nursing intervention based on Maslow's hierarchy of needs in patients with coronary heart disease interventional surgery

Xu JX, Wu LX, Jiang W, Fan GH

- 10198** Impacts of statin and metformin on neuropathy in patients with type 2 diabetes mellitus: Korean Health Insurance data

Min HK, Kim SH, Choi JH, Choi K, Kim HR, Lee SH

META-ANALYSIS

- 10208** Is endoscopic retrograde appendicitis therapy a better modality for acute uncomplicated appendicitis? A systematic review and meta-analysis

Wang Y, Sun CY, Liu J, Chen Y, Bhan C, Tuason JPW, Misra S, Huang YT, Ma SD, Cheng XY, Zhou Q, Gu WC, Wu DD, Chen X

- 10222** Prognostic value of ground glass opacity on computed tomography in pathological stage I pulmonary adenocarcinoma: A meta-analysis

Pan XL, Liao ZL, Yao H, Yan WJ, Wen DY, Wang Y, Li ZL

CASE REPORT

- 10233** Atrial fibrillation and concomitant left subclavian, axillary and brachial artery embolism after fiberoptic bronchoscopy: A case report

Yang CL, Zhou R, Jin ZX, Chen M, Zi BL, Li P, Zhou KH

- 10238** Streptococcal toxic shock syndrome after hemorrhoidectomy: A case report

Lee CY, Lee YJ, Chen CC, Kuo LJ

- 10244** Subsequent placenta accreta after previous mifepristone-induced abortion: A case report

Zhao P, Zhao Y, He J, Bai XX, Chen J

- 10249** Autosomal dominant tubulointerstitial kidney disease with a novel heterozygous missense mutation in the uromodulin gene: A case report
Zhang LL, Lin JR, Zhu TT, Liu Q, Zhang DM, Gan LW, Li Y, Ou ST
- 10257** Novel KDM6A mutation in a Chinese infant with Kabuki syndrome: A case report
Guo HX, Li BW, Hu M, Si SY, Feng K
- 10265** Pancreatic cancer with synchronous liver and colon metastases: A case report
Dong YM, Sun HN, Sun DC, Deng MH, Peng YG, Zhu YY
- 10273** Veno-venous-extracorporeal membrane oxygenation treatment for severe capillary leakage syndrome: A case report
Nong WX, Lv QJ, Lu YS
- 10279** Anticoagulant treatment for pulmonary embolism in patient with cerebral hemorrhage secondary to mechanical thrombectomy: A case report
Chen XT, Zhang Q, Zhou CQ, Han YF, Cao QQ
- 10286** Complete restoration of congenital conductive hearing loss by staged surgery: A case report
Yoo JS, Lee CM, Yang YN, Lee EJ
- 10293** Blastic plasmacytoid dendritic cell neoplasm with skin and bone marrow involvement: Report of three cases
Guo JH, Zhang HW, Wang L, Bai W, Wang JF
- 10300** Extracranial multiorgan metastasis from primary glioblastoma: A case report
Luan XZ, Wang HR, Xiang W, Li SJ, He H, Chen LG, Wang JM, Zhou J
- 10308** Transverse myelitis after infection with varicella zoster virus in patient with normal immunity: A case report
Yun D, Cho SY, Ju W, Seo EH
- 10315** Duodenal ulcer caused by coil wiggle after digital subtraction angiography-guided embolization: A case report
Xu S, Yang SX, Xue ZX, Xu CL, Cai ZZ, Xu CZ
- 10323** Crab lice infestation in unilateral eyelashes and adjacent eyelids: A case report
Tang W, Li QQ
- 10328** Local random flaps for cervical circumferential defect or tracheoesophageal fistula reconstruction after failed gastric pull-up: Two case reports
Zhang Y, Liu Y, Sun Y, Xu M, Wang XL
- 10337** Incurable and refractory spinal cystic echinococcosis: A case report
Zhang T, Ma LH, Liu H, Li SK
- 10345** Individualized treatment of breast cancer with chronic renal failure: A case report and review of literature
Cai JH, Zheng JH, Lin XQ, Lin WX, Zou J, Chen YK, Li ZY, Chen YX

- 10355** Persistent fibrinogen deficiency after snake bite: A case report
Xu MH, Li J, Han L, Chen C
- 10362** Successful prolonged cardiopulmonary resuscitation after intraoperative cardiac arrest due to povidone-iodine allergy: A case report
Xiang BB, Yao YT, Jiao SL
- 10369** Clinical algorithm for preventing missed diagnoses of occult cervical spine instability after acute trauma: A case report
Zhu C, Yang HL, Im GH, Liu LM, Zhou CG, Song YM
- 10374** Carbon ion radiotherapy for synchronous choroidal melanoma and lung cancer: A case report
Zhang YS, Hu TC, Ye YC, Han JH, Li XJ, Zhang YH, Chen WZ, Chai HY, Pan X, Wang X, Yang YL
- 10382** Heart failure as an adverse effect of infliximab for Crohn's disease: A case report and review of the literature
Grillo TG, Almeida LR, Beraldo RF, Marcondes MB, Queiróz DAR, da Silva DL, Quera R, Baima JP, Saad-Hossne R, Sasaki LY

ABOUT COVER

Editorial Board Member of *World Journal of Clinical Cases*, Jian-Wu Zhao, PhD, Chief Physician, Professor, Department of Orthopedics, Jilin University Second Hospital, Changchun 130000, Jilin Province, China. jianwu@jlu.edu.cn

AIMS AND SCOPE

The primary aim of *World Journal of Clinical Cases* (WJCC, *World J Clin Cases*) is to provide scholars and readers from various fields of clinical medicine with a platform to publish high-quality clinical research articles and communicate their research findings online.

WJCC mainly publishes articles reporting research results and findings obtained in the field of clinical medicine and covering a wide range of topics, including case control studies, retrospective cohort studies, retrospective studies, clinical trials studies, observational studies, prospective studies, randomized controlled trials, randomized clinical trials, systematic reviews, meta-analysis, and case reports.

INDEXING/ABSTRACTING

The WJCC is now indexed in Science Citation Index Expanded (also known as SciSearch®), Journal Citation Reports/Science Edition, Scopus, PubMed, and PubMed Central. The 2021 Edition of Journal Citation Reports® cites the 2020 impact factor (IF) for WJCC as 1.337; IF without journal self cites: 1.301; 5-year IF: 1.742; Journal Citation Indicator: 0.33; Ranking: 119 among 169 journals in medicine, general and internal; and Quartile category: Q3. The WJCC's CiteScore for 2020 is 0.8 and Scopus CiteScore rank 2020: General Medicine is 493/793.

RESPONSIBLE EDITORS FOR THIS ISSUE

Production Editor: Ji-Hong Lin; Production Department Director: Xiang Li; Editorial Office Director: Jin-Lai Wang.

NAME OF JOURNAL

World Journal of Clinical Cases

ISSN

ISSN 2307-8960 (online)

LAUNCH DATE

April 16, 2013

FREQUENCY

Thrice Monthly

EDITORS-IN-CHIEF

Dennis A Bloomfield, Sandro Vento, Bao-Gan Peng

EDITORIAL BOARD MEMBERS

<https://www.wjnet.com/2307-8960/editorialboard.htm>

PUBLICATION DATE

November 26, 2021

COPYRIGHT

© 2021 Baishideng Publishing Group Inc

INSTRUCTIONS TO AUTHORS

<https://www.wjnet.com/bpg/gerinfo/204>

GUIDELINES FOR ETHICS DOCUMENTS

<https://www.wjnet.com/bpg/GerInfo/287>

GUIDELINES FOR NON-NATIVE SPEAKERS OF ENGLISH

<https://www.wjnet.com/bpg/gerinfo/240>

PUBLICATION ETHICS

<https://www.wjnet.com/bpg/GerInfo/288>

PUBLICATION MISCONDUCT

<https://www.wjnet.com/bpg/gerinfo/208>

ARTICLE PROCESSING CHARGE

<https://www.wjnet.com/bpg/gerinfo/242>

STEPS FOR SUBMITTING MANUSCRIPTS

<https://www.wjnet.com/bpg/GerInfo/239>

ONLINE SUBMISSION

<https://www.f6publishing.com>

Transverse myelitis after infection with varicella zoster virus in patient with normal immunity: A case report

Daehun Yun, Soo Young Cho, Wan Ju, Eun Hyoung Seo

ORCID number: Daehun Yun 0000-0003-4564-1461; Soo Young Cho 0000-0002-1709-7537; Wan Ju 0000-0002-6700-2436; Eun Hyoung Seo 0000-0002-2934-4953.

Author contributions: Yun DH and Seo EH cared for the patient, conceived and designed the case report, and wrote the manuscript; Yun DH, Cho SY and Ju W edited the manuscript; Cho SY and Ju W supervised the work; all authors read and approved the final manuscript.

Informed consent statement:

Informed written consent was obtained from the patient for publication of this report and any accompanying images.

Conflict-of-interest statement: The authors declare that they have no conflicts of interest.

CARE Checklist (2016) statement:

The authors have read the CARE Checklist (2016), and the manuscript was prepared and revised according to the CARE Checklist (2016).

Country/Territory of origin: South Korea

Specialty type: Medicine, research and experimental

Provenance and peer review:

Daehun Yun, Soo Young Cho, Wan Ju, Eun Hyoung Seo, Department of Anesthesiology and Pain Medicine, Kwangju Christian Hospital, Gwangju 61661, South Korea

Corresponding author: Daehun Yun, MD, Doctor, Department of Anesthesiology and Pain Medicine, Kwangju Christian Hospital, No. 37 Yangnim-ro, Nam-gu, Gwangju 61661, South Korea. squall12@naver.com

Abstract

BACKGROUND

Varicella zoster virus (VZV) is a human neurotropic and double-stranded DNA alpha-herpes virus. Primary infection with VZV usually occurs during childhood, manifesting as chickenpox. Reactivation of latent VZV can lead to various neurological complications, including transverse myelitis (TM); although cases of the latter are very rare, particularly in newly active VZV infection.

CASE SUMMARY

We report here an unusual case of TM in a middle-aged adult immunocompetent patient that developed concomitant to an active VZV infection. The 46-year-old male presented with painful vesicular eruption on his left chest that had steadily progressed to involvement of his back over a 3-d period. Cerebrospinal fluid testing was denied, but findings from magnetic resonance imaging and collective symptomatology indicated TM. He was administered antiviral drugs and corticosteroids immediately but his symptom improvement waxed and waned, necessitating multiple hospital admissions. After about a month of repeated treatments, he was deemed sufficiently improved for hospital discharge to home.

CONCLUSION

VZV myelitis should be suspected when a patient visits the outpatient pain clinic with herpes zoster showing neurological symptoms.

Key Words: Herpes zoster; Postherpetic neuralgia; Transverse myelitis; Varicella zoster virus; Motor weakness; Vesicular; Pain; Case report

©The Author(s) 2021. Published by Baishideng Publishing Group Inc. All rights reserved.

Unsolicited article; Externally peer reviewed.

Peer-review report's scientific quality classification

Grade A (Excellent): 0
Grade B (Very good): 0
Grade C (Good): C
Grade D (Fair): 0
Grade E (Poor): 0

Open-Access: This article is an open-access article that was selected by an in-house editor and fully peer-reviewed by external reviewers. It is distributed in accordance with the Creative Commons Attribution NonCommercial (CC BY-NC 4.0) license, which permits others to distribute, remix, adapt, build upon this work non-commercially, and license their derivative works on different terms, provided the original work is properly cited and the use is non-commercial. See: <http://creativecommons.org/licenses/by-nc/4.0/>

Received: July 6, 2021

Peer-review started: July 6, 2021

First decision: August 18, 2021

Revised: August 21, 2021

Accepted: September 22, 2021

Article in press: September 22, 2021

Published online: November 26, 2021

P-Reviewer: Kim YH

S-Editor: Fan JR

L-Editor: A

P-Editor: Guo X



Core Tip: The occurrence of transverse myelitis (TM) secondary to varicella zoster virus (VZV) in immunocompetent patients is very rare. VZV-TM should be suspected when a patient visits an outpatient pain clinic with herpes zoster and presents neurological symptom(s). VZV-TM must be diagnosed early, by magnetic resonance imaging and/or cerebrospinal fluid analysis, since delayed intervention may allow for serious complications to develop. Also, early administration of a combination of antiviral drugs and corticosteroids may help resolve the condition and relieve the associated pain experienced by patients with TM secondary to VZV.

Citation: Yun D, Cho SY, Ju W, Seo EH. Transverse myelitis after infection with varicella zoster virus in patient with normal immunity: A case report. *World J Clin Cases* 2021; 9(33): 10308-10314

URL: <https://www.wjgnet.com/2307-8960/full/v9/i33/10308.htm>

DOI: <https://dx.doi.org/10.12998/wjcc.v9.i33.10308>

INTRODUCTION

Among the outpatient population of the pain clinic, a significant number of patient visits are prompted by pain caused by herpes zoster (HZ). Rarely, that pain is accompanied by neurological symptoms; however, in such cases, concomitant transverse myelitis (TM) should be suspected. We describe herein an unusual case of TM shortly following infection by the varicella zoster virus (VZV) and in conjunction with the usual symptomatology in immunocompetent patient.

VZV infection is very common and causes chickenpox and HZ[1]. The VZV infection itself is often complicated by postherpetic neuralgia (the most common neurologic complication), VZV vasculopathy, cerebellitis, meningoradiculitis, meningoencephalitis, myelitis, and ocular disease[2]. However, very few cases of VZV-TM have been reported, particularly in an immunocompetent patient. In order to accurately determine VZV as the cause of TM, cerebrospinal fluid (CSF) analysis is required, despite it being technically difficult to isolate VZV from CSF in VZV patients who have developed myelitis[3]. Additional evaluation of the neurological symptoms by magnetic resonance imaging (MRI) is important for accurate diagnosis, which allows for the timely initiation of treatment and improves prognosis.

CASE PRESENTATION

Chief complaints

A 46-year-old male presented to our hospital with complaint of painful vesicular eruption that had begun 3 d prior on his left chest and steadily progressed to involvement of his back.

History of present illness

The patient characterized the pain as 'stinging' and reported that it had begun after he participated in strenuous outdoor activities. He noted that the pain was accompanied by the vesicle eruption. He denied any history of trauma.

History of past illness

The patient denied VZV infection (*i.e.* chickenpox or any form of HZ) in his medical history.

Personal and family history

The patient's other personal and family medical history was unremarkable for this case.

Physical examination

Vesicular eruption was present on the left chest to the axillary side, being limited within the T5-T8 dermatome (Figure 1). Using the visual analogue scale (VAS), the

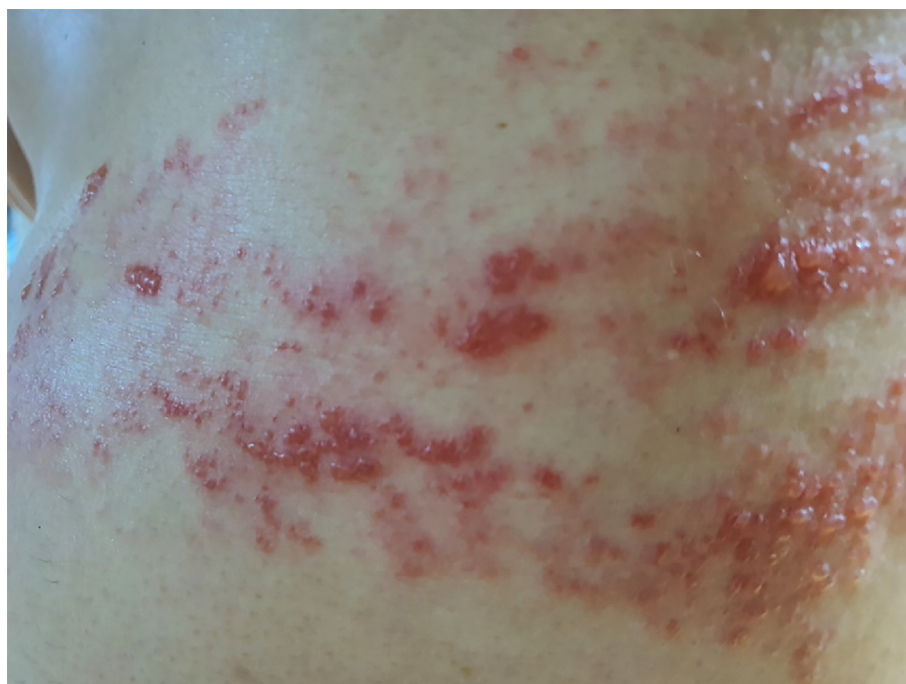

Figure 1 Multiple vesicles on the axillary side of the left chest.

patient classified the stinging pain intensity of the vesicle eruption as 7.

Laboratory examinations

Blood tests for serum VZV immunoglobulin (Ig) M and VZV IgG were positive.

Imaging examinations

Chest computed tomography (CT) findings were nonspecific.

First diagnosis and treatment

The patient was diagnosed with HZ and ordered treatment with an antiviral drug (Clovir tablet, famciclovir at 250 mg bid; Dong Wha Pharm, Seoul, Korea), steroid (dexamethasone at 5 mg bid; Daewon Pharm, Busan, Korea), and nonsteroidal anti-inflammatory drugs (Naxozole tablet, esomeprazole strontium 24.6 mg/naproxen 500 mg bid (Hanmi Pharm, Seoul, Korea); Valentac, declofenac sodium at 75 mg/mL intramuscular injection (WhanIn Pharm, Seoul, Korea). After 1 wk, the patient showed improvement (Figure 2), with pain score reducing to VAS 2, and was discharged to home.

However, 10 d after discharge, the patient returned to the hospital with complaint of pain recurrence (VAS 7-8) and was referred to our pain clinic. The same dermatome region showed re-eruption of the vesicles. Upon readmission, we administered ultrasound-guided erector spina plane block (commonly referred to as ESPB) and prescribed Lyrica Capsules (pregabalin at 75 mg bid; Pfizer, New York, NY, United States) and Targin prolonged-release (oxycodone at 5 mg/naloxone at 2.5 mg bid; Mundipharma, Seoul, Korea) for pain control. After the ESPB, the patient reported his pain reduced to VAS 2 and he was again discharged. At 2 d later, however, his pain worsened (VAS 6-7), and he returned to hospital and was again readmitted for pain control. This time, we inserted a patient-controlled epidural analgesia (PCEA) port. First, with the patient in prone position, an 18-G Tuohy needle was advanced using the paramedian approach at the thoracic spine level 9-10 under C-arm guidance. The epidural space was identified using loss-of-resistance technique and the contrast medium was injected. After confirming loss-of-resistance using C-arm, a flexible epidural catheter was passed cranially for about 2-3 cm and secured with the skin. Initially, the port was used to administer 300 mL of 0.1% ropivacaine at a continuous infusion rate of 4 mL/h *via* a disposable silicone balloon infuser (AutoFuser; ACE Medical, Beverly Hills, CA, United States). During the maintenance of PCEA, the patient reported his pain to be reduced to VAS 3. However, that night, the patient began to experience difficulty urinating as well as mild motor weakness (motor grade 4) and paresthesia in the bilateral distal lower extremities. The epidural catheter was

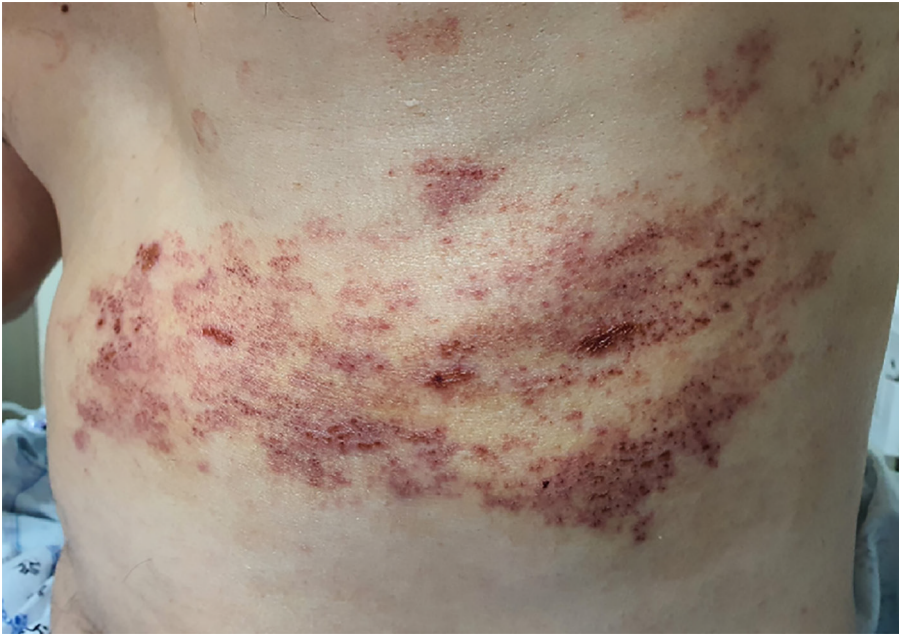

Figure 2 After 1 wk of hospitalization with antiviral and corticosteroid treatment, the vesicular eruption showed improvement.

removed immediately.

Further diagnostic work-up

A catheter tip culture was ordered but revealed no microorganism. To rule-out central nervous system infection, a T-spine MRI was performed. The T2-weighted images showed high signal intensity within the left spinal cord level T2-8 (Figure 3). The neurologic examination revealed mild paresthesia and normal motor strength at the bilateral distal lower-half extremities and hyperactive deep tendon reflex on the left side. The need for a CSF study was explained, but the patient's guardian refused consent.

FINAL DIAGNOSIS

Based on the patient's overall clinical presentation profile and imaging findings, he was diagnosed with VZV and myelitis.

TREATMENT

A 1-wk course of Clovir (acyclovir 250 mg tid; Myung-In Pharm), Maxipime (cefepime at 1 g bid; Boryung, Seoul, Korea) and Solondo tablet (prednisolone at 5 mg tid; Yuhan, Seoul, Korea) was initiated; in addition, the patient was administered Targin prolonged-release (oxycodone at 5 mg/naloxone at 2.5 mg bid; Mundipharma) and Lyrica Capsules (pregabalin at 75 mg bid; Pfizer) for pain control. The patient reported his pain to remain at about VAS 3 with these medications. The acyclovir was discontinued after the 1-wk course. A follow-up MRI was performed 3 wk later, and did not show any significant changes (Figure 4). At this time, the patient reported his pain to be well controlled (VAS 2) and findings from neurological examination were normal, allowing for discharge to home.

OUTCOME AND FOLLOW-UP

At the outpatient follow-up visit, conducted 1 mo after discharge, the patient had no neurologic symptoms but residual pain (VAS 2) that involved the area from the chest to the axillary side of the T5-T8 dermatome.

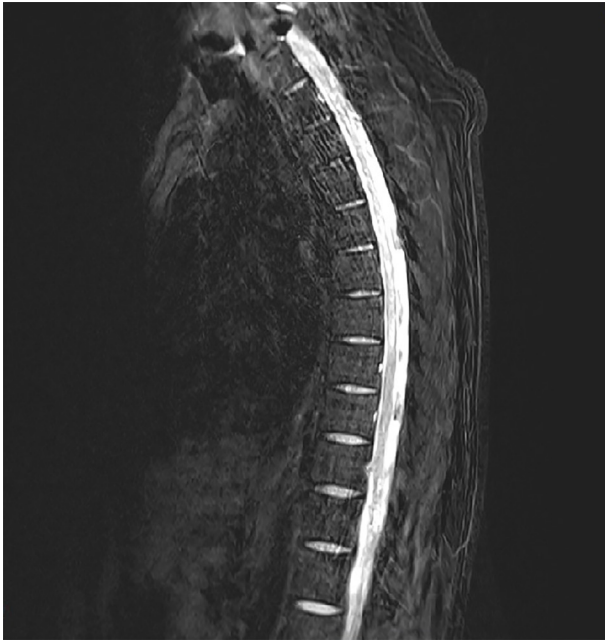

Figure 3 Spine magnetic resonance imaging made on admission. High signal intensity was apparent within the left spinal cord at level T2-8 on a T2-weighted image.

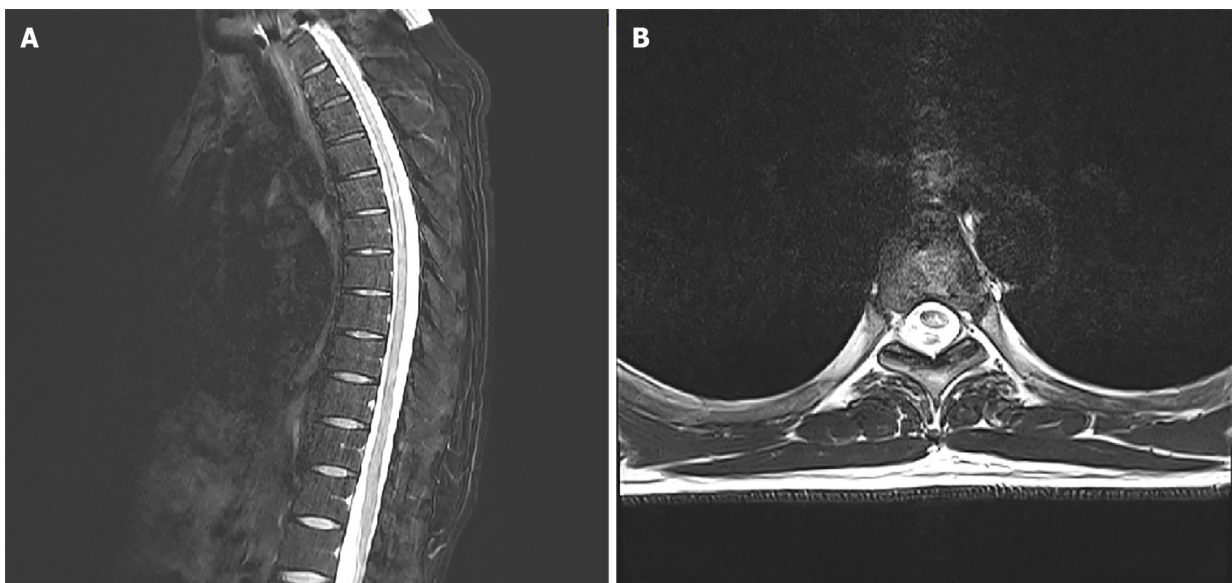


Figure 4 After 3 wk of antiviral and corticosteroid treatment, the high signal intensity had decreased slightly but had not resolved. A: Remaining high signal intensity at level T2-8 on a sagittal T2-weighted image; B: Level T5 on a coronal view.

DISCUSSION

VZV is a human neurotropic and double-stranded DNA alpha-herpesvirus – the primary infection of which usually occurs during childhood and manifests as chickenpox[1]. After the primary infection, VZV becomes latent in the cranial root ganglia or dorsal root ganglia and can remain so for several decades; however, in elderly or immunocompromised individuals, it can become reactivated and recur as HZ[3,4].

HZ itself is associated with a variety of complications, such as HZ vasculitis and ophthalmic, neurologic or visceral disease. The most common neurological complication is postherpetic neuralgia, a chronic neuropathic pain that persists after resolution of the HZ skin rash. Other complications include cranial nerve or peripheral nerve palsy, myelitis, meningoencephalitis, and stroke[2].

Only 0.3% of patients reported with HZ manifestation experience TM[5]. In general, about 25%-50% of TM cases are caused by viral infections, including herpes virus or poliovirus. Though HZ infection is common, even in immunocompetent patients, it rarely progresses to TM. In Korea, in particular, only a few cases of TM secondary to VZV have been reported. Thus, TM secondary to VZV is an abnormal inflammatory finding; yet, the literature indicates that it can involve all parts of the spinal cord and that the pathogenesis may be related directly to the viral invasion and consequent axonal degeneration[6].

Symptoms of TM usually develop over a period of hours to days and sometimes progress gradually over weeks. Mostly, it involves both sides of the body below the affected area of the spinal cord, but there are cases wherein it appears to affect only one side. Common signs and symptoms include pain (back, abdomen, chest), abnormal sensation, weakness in arms or legs, and bladder and bowel problems[7].

TM is diagnosed based on the patient's signs and symptoms, medical history, and clinical assessment of nerve function. If several diagnostic workups, including MRI, CSF analysis and complete blood count, provide evidence of inflammation, TM can be diagnosed after ruling out of other causes. MRI is one of the most effective diagnostic tools for TM secondary to VZV. In MRI, VZV myelitis is shown as hyperintensity in the spinal cord on T2-weighted images[8]. CSF analysis can then be done as a confirmatory test. Unfortunately, however, the procedure of CSF analysis is actually quite complicated; the VZV must first be separated from the CSF sample (invasively acquired) and must then demonstrate presence of VZV antigen *via* immunofluorescence assay. Indeed, in some cases reported in the literature, the VZV antibody was not found in the CSF sample and patient was diagnosed by MRI findings alone[3,9]. Likewise, no CSF study was conducted for our patient and the diagnosis was made according to the collective profile of clinical symptoms and MRI findings.

In TM, early therapeutic intervention is essential to minimize complications and pain extent and duration suffered by the patient. The intervention must be tailored to the patient's symptoms, since there is yet no standardized treatment regimen for TM secondary to VZV. Currently, the accepted treatment regimen should include an antibiotic, antiviral, high-dose corticosteroid, and intravenous Ig[3,6]. However, the efficacy of no specific treatment regimen has not been systematically demonstrated [10]. Of note, however, a study found that the combination of acyclovir and corticosteroids effectively reduced acute neuritis in VZV myelitis patients, and the most important prognostic factor was determined to be early medical intervention[5]. Another study showed that after administration of antivirals and steroids, the interval prior to symptom improvement ranged from 3 d to 9 d, with complete recovery seen in 10 d, but some patients were left with permanent neurological deficits, such as weakness or numbness, or had even progressed to encephalitis[11]. In our case, the early application of a combination treatment involving antivirals and corticosteroids significantly relieved the patient's symptoms.

CONCLUSION

The occurrence of TM secondary to VZV in immunocompetent patients is very rare. VZV myelitis should be suspected when a patient visits the outpatient pain clinic with HZ showing neurological symptoms. VZV myelitis must be diagnosed early, using MRI and CSF study, since delayed intervention may allow for serious complications to develop. Also, early application of a combination treatment approach using antivirals and corticosteroids may benefit patients with TM secondary to VZV.

REFERENCES

- 1 **Gilden D**, Nagel MA, Cohrs RJ, Mahalingam R. The variegated neurological manifestations of varicella zoster virus infection. *Curr Neurol Neurosci Rep* 2013; **13**: 374 [PMID: 23884722 DOI: 10.1007/s11910-013-0374-z]
- 2 **Kovac M**, Lal H, Cunningham AL, Levin MJ, Johnson RW, Campora L, Volpi A, Heineman TC; ZOE-50/70 Study Group. Complications of herpes zoster in immunocompetent older adults: Incidence in vaccine and placebo groups in two large phase 3 trials. *Vaccine* 2018; **36**: 1537-1541 [PMID: 29463421 DOI: 10.1016/j.vaccine.2018.02.029]
- 3 **Yılmaz S**, Köseolu HK, Yücel E. Transverse myelitis caused by varicella zoster: case reports. *Braz J Infect Dis* 2007; **11**: 179-181 [PMID: 17625754 DOI: 10.1590/s1413-86702007000100040]
- 4 **Nagel MA**, Gilden D. Neurological complications of varicella zoster virus reactivation. *Curr Opin*

- Neurol* 2014; **27**: 356-360 [PMID: [24792344](#) DOI: [10.1097/WCO.0000000000000092](#)]
- 5 **Lee CC**, Wu JC, Huang WC, Shih YH, Cheng H. Herpes zoster cervical myelitis in a young adult. *J Chin Med Assoc* 2010; **73**: 605-610 [PMID: [21093831](#) DOI: [10.1016/S1726-4901\(10\)70132-5](#)]
- 6 **Ari BC**, Karaci R, Domac FM, Ulker M, Bolluk B, Ofluoglu D, Ozgen Kenangil G. Transverse Myelitis Caused by Varicella Zoster Virus: A Case Report. *Infect Dis Clin Pract* 2019; **27**: 231-233 [DOI: [10.1097/ipc.0000000000000747](#)]
- 7 **Frohman EM**, Wingerchuk DM. Clinical practice. Transverse myelitis. *N Engl J Med* 2010; **363**: 564-572 [PMID: [20818891](#) DOI: [10.1056/NEJMcpl001112](#)]
- 8 **Lee JE**, Lee S, Kim KH, Jang HR, Park YJ, Kang JS, Han SY, Lee SH. A Case of Transverse Myelitis Caused by Varicella Zoster Virus in an Immunocompetent Older Patient. *Infect Chemother* 2016; **48**: 334-337 [PMID: [27883372](#) DOI: [10.3947/ic.2016.48.4.334](#)]
- 9 **Ong OL**, Churchyard AC, New PW. The importance of early diagnosis of herpes zoster myelitis. *Med J Aust* 2010; **193**: 546-547 [PMID: [21034391](#) DOI: [10.5694/j.1326-5377.2010.tb04043.x](#)]
- 10 **Dworkin RH**, Johnson RW, Breuer J, Gnann JW, Levin MJ, Backonja M, Betts RF, Gershon AA, Haanpaa ML, McKendrick MW, Nurmikko TJ, Oaklander AL, Oxman MN, Pavan-Langston D, Petersen KL, Rowbotham MC, Schmader KE, Stacey BR, Tying SK, van Wijck AJ, Wallace MS, Wassilew SW, Whitley RJ. Recommendations for the management of herpes zoster. *Clin Infect Dis* 2007; **44** Suppl 1: S1-26 [PMID: [17143845](#) DOI: [10.1086/510206](#)]
- 11 **de Silva SM**, Mark AS, Gilden DH, Mahalingam R, Balish M, Sandbrink F, Houff S. Zoster myelitis: improvement with antiviral therapy in two cases. *Neurology* 1996; **47**: 929-931 [PMID: [8857721](#) DOI: [10.1212/wnl.47.4.929](#)]



Published by **Baishideng Publishing Group Inc**
7041 Koll Center Parkway, Suite 160, Pleasanton, CA 94566, USA

Telephone: +1-925-3991568

E-mail: bpgoffice@wjgnet.com

Help Desk: <https://www.f6publishing.com/helpdesk>

<https://www.wjgnet.com>

