

World Journal of *Clinical Cases*

World J Clin Cases 2022 January 21; 10(3): 753-1139



Contents

Thrice Monthly Volume 10 Number 3 January 21, 2022

OPINION REVIEW

- 753 Lung injury after cardiopulmonary bypass: Alternative treatment prospects
Zheng XM, Yang Z, Yang GL, Huang Y, Peng JR, Wu MJ

REVIEW

- 762 Acute myocardial injury in patients with COVID-19: Possible mechanisms and clinical implications
Rusu I, Turlacu M, Micheu MM

MINIREVIEWS

- 777 Anemia in cirrhosis: An underestimated entity
Manrai M, Dawra S, Kapoor R, Srivastava S, Singh A

ORIGINAL ARTICLE

Retrospective Cohort Study

- 790 High tumor mutation burden indicates a poor prognosis in patients with intrahepatic cholangiocarcinoma
Song JP, Liu XZ, Chen Q, Liu YF

Retrospective Study

- 802 Does delaying ureteral stent placement lead to higher rates of preoperative acute pyelonephritis during pregnancy?
He MM, Lin XT, Lei M, Xu XL, He ZH
- 811 Management of retroperitoneal sarcoma involving the iliac artery: Single-center surgical experience
Li WX, Tong HX, Lv CT, Yang H, Zhao G, Lu WQ, Zhang Y
- 820 COVID-19 pandemic changed the management and outcomes of acute appendicitis in northern Beijing: A single-center study
Zhang P, Zhang Q, Zhao HW
- 830 Laparoscopic approach for managing intussusception in children: Analysis of 65 cases
Li SM, Wu XY, Luo CF, Yu LJ
- 840 Clinical features and risk factors of severely and critically ill patients with COVID-19
Chu X, Zhang GF, Zheng YK, Zhong YG, Wen L, Zeng P, Fu CY, Tong XL, Long YF, Li J, Liu YL, Chang ZG, Xi H
- 856 Evaluating tumor-infiltrating lymphocytes in hepatocellular carcinoma using hematoxylin and eosin-stained tumor sections
Du M, Cai YM, Yin YL, Xiao L, Ji Y

Clinical Trials Study

- 870 Role of carbon nanotracers in lymph node dissection of advanced gastric cancer and the selection of preoperative labeling time
Zhao K, Shan BQ, Gao YP, Xu JY

Observational Study

- 882 Craving variations in patients with substance use disorder and gambling during COVID-19 lockdown: The Italian experience
Alessi MC, Martinotti G, De Berardis D, Sociali A, Di Natale C, Sepede G, Cheffo DPR, Monti L, Casella P, Pettorruso M, Sensi S, Di Giannantonio M
- 891 Mesh safety in pelvic surgery: Our experience and outcome of biological mesh used in laparoscopic ventral mesh rectopexy
Tsiaousidou A, MacDonald L, Shalli K
- 899 Dynamic monitoring of carcinoembryonic antigen, CA19-9 and inflammation-based indices in patients with advanced colorectal cancer undergoing chemotherapy
Manojlovic N, Savic G, Nikolic B, Rancic N
- 919 Prevalence of depression and anxiety and associated factors among geriatric orthopedic trauma inpatients: A cross-sectional study
Chen JL, Luo R, Liu M

Randomized Controlled Trial

- 929 Efficacy of acupuncture at ghost points combined with fluoxetine in treating depression: A randomized study
Wang Y, Huang YW, Ablikim D, Lu Q, Zhang AJ, Dong YQ, Zeng FC, Xu JH, Wang W, Hu ZH

SYSTEMATIC REVIEWS

- 939 Atrial fibrillation burden and the risk of stroke: A systematic review and dose-response meta-analysis
Yang SY, Huang M, Wang AL, Ge G, Ma M, Zhi H, Wang LN

META-ANALYSIS

- 954 Effectiveness of Maitland and Mulligan mobilization methods for adults with knee osteoarthritis: A systematic review and meta-analysis
Li LL, Hu XJ, Di YH, Jiao W
- 966 Patients with inflammatory bowel disease and post-inflammatory polyps have an increased risk of colorectal neoplasia: A meta-analysis
Shi JL, Lv YH, Huang J, Huang X, Liu Y

CASE REPORT

- 985 Intravascular fasciitis involving the external jugular vein and subclavian vein: A case report
Meng XH, Liu YC, Xie LS, Huang CP, Xie XP, Fang X

- 992** Occurrence of human leukocyte antigen B51-related ankylosing spondylitis in a family: Two case reports
Lim MJ, Noh E, Lee RW, Jung KH, Park W
- 1000** Multicentric recurrence of intraductal papillary neoplasm of bile duct after spontaneous detachment of primary tumor: A case report
Fukuya H, Kuwano A, Nagasawa S, Morita Y, Tanaka K, Yada M, Masumoto A, Motomura K
- 1008** Case of primary extracranial meningioma of the maxillary sinus presenting as buccal swelling associated with headache: A case report
Sigdel K, Ding ZF, Xie HX
- 1016** Pulmonary amyloidosis and multiple myeloma mimicking lymphoma in a patient with Sjogren's syndrome: A case report
Kim J, Kim YS, Lee HJ, Park SG
- 1024** Concomitant Othello syndrome and impulse control disorders in a patient with Parkinson's disease: A case report
Xu T, Li ZS, Fang W, Cao LX, Zhao GH
- 1032** Multiple endocrine neoplasia type 1 combined with thyroid neoplasm: A case report and review of literatures
Xu JL, Dong S, Sun LL, Zhu JX, Liu J
- 1041** Full recovery from chronic headache and hypopituitarism caused by lymphocytic hypophysitis: A case report
Yang MG, Cai HQ, Wang SS, Liu L, Wang CM
- 1050** Novel method of primary endoscopic realignment for high-grade posterior urethral injuries: A case report
Ho CJ, Yang MH
- 1056** Congenital muscular dystrophy caused by *beta1,3-N-acetylgalactosaminyltransferase 2* gene mutation: Two case reports
Wu WJ, Sun SZ, Li BG
- 1067** Novel α -galactosidase A gene mutation in a Chinese Fabry disease family: A case report
Fu AY, Jin QZ, Sun YX
- 1077** Cervical spondylotic myelopathy with syringomyelia presenting as hip Charcot neuroarthropathy: A case report and review of literature
Lu Y, Xiang JY, Shi CY, Li JB, Gu HC, Liu C, Ye GY
- 1086** Bullectomy used to treat a patient with pulmonary vesicles related to COVID-19: A case report
Tang HX, Zhang L, Wei YH, Li CS, Hu B, Zhao JP, Mokadam NA, Zhu H, Lin J, Tian SF, Zhou XF
- 1093** Epibulbar osseous choristoma: Two case reports
Wang YC, Wang ZZ, You DB, Wang W
- 1099** Gastric submucosal lesion caused by an embedded fish bone: A case report
Li J, Wang QQ, Xue S, Zhang YY, Xu QY, Zhang XH, Feng L

- 1106** Metastasis to the thyroid gland from primary breast cancer presenting as diffuse goiter: A case report and review of literature
Wen W, Jiang H, Wen HY, Peng YL
- 1116** New method to remove tibial intramedullary nail through original suprapatellar incision: A case report
He M, Li J
- 1122** Recurrence of sigmoid colon cancer-derived anal metastasis: A case report and review of literature
Meng LK, Zhu D, Zhang Y, Fang Y, Liu WZ, Zhang XQ, Zhu Y
- 1131** *Mycoplasma hominis* meningitis after operative neurosurgery: A case report and review of literature
Yang NL, Cai X, Que Q, Zhao H, Zhang KL, Lv S

ABOUT COVER

Editorial Board Member of *World Journal of Clinical Cases*, M Anwar Iqbal, PhD, Professor, Department of Pathology and Laboratory Medicine, University of Rochester Medical Center, Rochester, NY 14642, United States. anwar_iqbal@urmc.rochester.edu

AIMS AND SCOPE

The primary aim of *World Journal of Clinical Cases* (WJCC, *World J Clin Cases*) is to provide scholars and readers from various fields of clinical medicine with a platform to publish high-quality clinical research articles and communicate their research findings online.

WJCC mainly publishes articles reporting research results and findings obtained in the field of clinical medicine and covering a wide range of topics, including case control studies, retrospective cohort studies, retrospective studies, clinical trials studies, observational studies, prospective studies, randomized controlled trials, randomized clinical trials, systematic reviews, meta-analysis, and case reports.

INDEXING/ABSTRACTING

The WJCC is now indexed in Science Citation Index Expanded (also known as SciSearch®), Journal Citation Reports/Science Edition, Scopus, PubMed, and PubMed Central. The 2021 Edition of Journal Citation Reports® cites the 2020 impact factor (IF) for WJCC as 1.337; IF without journal self cites: 1.301; 5-year IF: 1.742; Journal Citation Indicator: 0.33; Ranking: 119 among 169 journals in medicine, general and internal; and Quartile category: Q3. The WJCC's CiteScore for 2020 is 0.8 and Scopus CiteScore rank 2020: General Medicine is 493/793.

RESPONSIBLE EDITORS FOR THIS ISSUE

Production Editor: *Ying-Yi Yuan*, Production Department Director: *Xiang Li*, Editorial Office Director: *Jin-Lei Wang*.

NAME OF JOURNAL

World Journal of Clinical Cases

ISSN

ISSN 2307-8960 (online)

LAUNCH DATE

April 16, 2013

FREQUENCY

Thrice Monthly

EDITORS-IN-CHIEF

Bao-Gan Peng, Jerzy Tadeusz Chudek, George Kontogeorgos, Maurizio Serati, Ja Hyeon Ku

EDITORIAL BOARD MEMBERS

<https://www.wjgnet.com/2307-8960/editorialboard.htm>

PUBLICATION DATE

January 21, 2022

COPYRIGHT

© 2022 Baishideng Publishing Group Inc

INSTRUCTIONS TO AUTHORS

<https://www.wjgnet.com/bpg/gerinfo/204>

GUIDELINES FOR ETHICS DOCUMENTS

<https://www.wjgnet.com/bpg/GerInfo/287>

GUIDELINES FOR NON-NATIVE SPEAKERS OF ENGLISH

<https://www.wjgnet.com/bpg/gerinfo/240>

PUBLICATION ETHICS

<https://www.wjgnet.com/bpg/GerInfo/288>

PUBLICATION MISCONDUCT

<https://www.wjgnet.com/bpg/gerinfo/208>

ARTICLE PROCESSING CHARGE

<https://www.wjgnet.com/bpg/gerinfo/242>

STEPS FOR SUBMITTING MANUSCRIPTS

<https://www.wjgnet.com/bpg/GerInfo/239>

ONLINE SUBMISSION

<https://www.f6publishing.com>



Retrospective Study

Laparoscopic approach for managing intussusception in children: Analysis of 65 cases

Sheng-Miao Li, Xiao-Ying Wu, Chun-Fen Luo, Lin-Jun Yu

ORCID number: Sheng-Miao Li 0000-0001-5884-1433; Xiao-Ying Wu 0000-0001-8707-2557; Chun-Fen Luo 0000-0002-8643-4138; Lin-Jun Yu 0000-0002-3829-4767.

Author contributions: Li SM conceived and coordinated the study, designed, performed and analyzed the experiments, wrote the paper; Wu XY, Luo CF and Yu LJ carried out the data collection, data analysis, and revised the paper; all authors reviewed the results and approved the final version of the manuscript.

Institutional review board statement: The study was approved by the ethics committee of Taizhou Hospital.

Informed consent statement: The requirement for informed consent was waived by the committee because of the retrospective nature of the study.

Conflict-of-interest statement: We have no financial relationships to disclose.

Data sharing statement: No additional data are available.

Country/Territory of origin: China

Specialty type: Surgery

Provenance and peer review:

Sheng-Miao Li, Xiao-Ying Wu, Chun-Fen Luo, Lin-Jun Yu, Department Pediatric Surgery, Taizhou Hospital of Zhejiang Province Affiliated to Wenzhou Medical University, Taizhou 317000, Zhejiang Province, China

Corresponding author: Lin-Jun Yu, MS, Doctor, Department Pediatric Surgery, Taizhou Hospital of Zhejiang Province Affiliated to Wenzhou Medical University, No. 150 Ximen Street, Taizhou 317000, Zhejiang Province, China. wannanyixue@163.com

Abstract

BACKGROUND

Intussusception can be managed by pneumatic reduction, ultrasound-guided hydrostatic reduction, open or laparoscopic surgery, but laparoscopy in such cases remains controversial.

AIM

To explore the clinical characteristics, effectiveness, and complications of surgical reduction for intussusception using laparoscopy in children.

METHODS

This study was a retrospective case series of pediatric patients with intussusception who underwent surgical reduction by laparoscopy from May 2011 to April 2016 at Taizhou Hospital of Zhejiang Province. Clinical characteristics (operation time, intraoperative blood loss, conversion rate of laparotomy, reasons for conversion, postoperative hospital stay, and adverse events) were described.

RESULTS

The 65 patients included 45 boys and 20 girls. The average age was 2.3 years (27.5 ± 24.5 mo). Of the 65 patients, 61 underwent surgical reduction by laparoscopy after a failed enema reduction of intussusception, and four underwent the procedure directly. All patients were treated successfully and 57 (87.7%) patients underwent successful laparoscopic surgery, two of which had a spontaneous reduction. Among the remaining cases, one was converted to open surgery *via* right upper quadrant incision, and seven required enlarged umbilical incisions. Intestinal resection was performed in 5 patients because of abnormal bowel lesions. There were no complications (intestinal perforations, wound infections, or intestinal adhesions) during the follow-up of 3 years to 8 years. Two patients experienced a recurrence of intussusception; one was resolved with pneumatic reduction, and the other underwent a second laparoscopic surgery.

Unsolicited article; Externally peer reviewed.

Peer-review model: Single blind

Peer-review report's scientific quality classification

Grade A (Excellent): A
Grade B (Very good): B
Grade C (Good): C
Grade D (Fair): 0
Grade E (Poor): 0

Open-Access: This article is an open-access article that was selected by an in-house editor and fully peer-reviewed by external reviewers. It is distributed in accordance with the Creative Commons Attribution NonCommercial (CC BY-NC 4.0) license, which permits others to distribute, remix, adapt, build upon this work non-commercially, and license their derivative works on different terms, provided the original work is properly cited and the use is non-commercial. See: <http://creativecommons.org/licenses/by-nc/4.0/>

Peer-review started: August 2, 2021

First decision: November 6, 2021

Revised: November 19, 2021

Accepted: December 25, 2021

Article in press: December 25, 2021

Published online: January 21, 2022

P-Reviewer: Abraha M, Gupta R, Osorno JF

S-Editor: Wu YXJ

L-Editor: A

P-Editor: Wu YXJ



CONCLUSION

Laparoscopic approach for pediatric intussusception is feasible and safe. Bowel resection if required can be performed by extending umbilical incision without the conventional laparotomy.

Key Words: Laparoscopy; Intussusception; Air reduction; Benefits; Complications

©The Author(s) 2022. Published by Baishideng Publishing Group Inc. All rights reserved.

Core Tip: This study aimed to explore the clinical characteristics, effectiveness, and complications of surgical reduction for intussusception using laparoscopy in children. Laparoscopic intussusception reduction can be beneficial and without significant complications if well indicated, and if an extension of the umbilical incision is used if needed. Laparoscopic assistance can also yield good treatment outcomes in some complicated cases requiring intestinal resection.

Citation: Li SM, Wu XY, Luo CF, Yu LJ. Laparoscopic approach for managing intussusception in children: Analysis of 65 cases. *World J Clin Cases* 2022; 10(3): 830-839

URL: <https://www.wjgnet.com/2307-8960/full/v10/i3/830.htm>

DOI: <https://dx.doi.org/10.12998/wjcc.v10.i3.830>

INTRODUCTION

For intussusception, the laparoscopic approach is a feasible alternative when pneumatic reduction or ultrasound-guided hydrostatic reduction failure. Laparoscopic intussusception reduction can be beneficial and without significant complications if well indicated, and an extension of the umbilical incision is used if needed. Laparoscopic assistance can also yield good treatment outcomes in some complicated cases requiring intestinal resection. Next, we can take the results of this study as a starting point for further prospective multicenter cohort studies.

MATERIALS AND METHODS

Intussusception can be managed by laparoscopic surgery, but it remains controversial. The results of this study strongly suggest that intussusception reduction using the laparoscopic approach is effective and without complications in patients with complex conditions or those requiring bowel resection.

Laparoscopy has been reported to be effective and without major complications for the management of intussusception[1,2], supporting the present study. In the present study, the success rate of laparoscopy was 88%, which is within the 79%-90% range reported by many case series[1-3]. Nevertheless, the use of laparoscopy remains controversial because laparoscopic intussusception reduction has a high rate of conversion to laparotomy, as high as 70% in some reports[4]. Nevertheless, with the improvement of laparoscopic techniques in recent years, the conversion rate of laparoscopic intussusception reduction to laparotomy has decreased from 14.3% to 5.4%[5, 6]. In this study, the overall conversion rate to open laparotomy was 12%, including seven patients with extension of the umbilical incision. Considering that the small transverse umbilical incision is concealed, it is more aesthetically appealing than traditional open surgery. Besides, laparoscopically-assisted surgery can be considered a form of minimally invasive surgery with laparoscopic assistance; thus, there was only one case of true conversion to open surgery, resulting in a rate of conversion to open surgery of only 1.5%.

It has been reported that patients over 3 years of age have a higher probability of intestinal resection[7,8]; for these patients, laparoscopic intussusception reduction surgery is not recommended[9]. In this study, two patients were > 3 years of age, in whom intussusception was diagnosed using preoperative B-mode ultrasound. Considering the patients' age, there was a possibility of intestinal lesions, and laparoscopic surgery was performed directly. After reduction was completed, erosion was

found in the terminal ileum in one patient, and the tissue was frozen and rapidly sent for pathological examination, revealing lymphoma. The umbilical incision was extended to remove the diseased tissue and the ileocecal segment. The patient recovered after chemotherapy, and the incision site maintained a good aesthetic appearance. It was also reported that laparoscopic reduction is not recommended for patients aged < 3 mo[7,8]. In this study, one 1-month-old patient underwent difficult laparoscopic reduction, and the umbilical incision had to be extended. It was found that the terminal ileum had duplication malformations that were managed with intestinal resection and anastomosis. With the improvement of laparoscopic techniques and instrumentation, we believe that laparoscopic surgery will not be contraindicated by age or intestinal resection because minimally invasive surgery through a small umbilical incision can be achieved even for intestinal resection[1-3].

Another major controversy involves the fact that laparoscopic intussusception reduction is associated with a higher recurrence rate than is conventional open surgery. Nevertheless, it was recently reported that the recurrence rate after laparoscopic intussusception was 3.4%[6]. In this study, there were two recurrences (3.1%), nearly the same as traditional open surgery[10]. The ileum's seromuscular layers and the ascending colon were repaired with two sutures, and the terminal ileum and the ascending colon were juxtaposed. If the ileocecal segment was relatively isolated, it was fixed to the lower right abdominal wall with two sutures to prevent relapse. The recurrence rate in our cohort of only 3.1% suggests good effectiveness. One patient experienced recurrence and required re-operation. The original fixation suture was found to be loose and was re-fixed, without subsequent recurrence. In our opinion, intestine fixation to the abdominal wall may be an effective method for intussusception. Although this method of intestine fixation to the abdominal wall has not occurred intestinal torsion in this study, but we do not know whether it is a risk factor for intestinal torsion. Therefore, we need longer follow-up time and more cases.

It has been reported that the appendix is also a site susceptible to intussusception [4]. The appendix is prone to becoming a lead point for intussusception because of viral or bacterial infection or abnormal anatomical position. Therefore, when intussusception is found in the appendix during operation, the appendix exhibiting congestion and swelling is resected. There were no recurrences after appendicular resection in this study. Besides, there were no complications in our cohort, such as intestinal adhesions, wound infections, and intestinal perforations, as supported by the low rates of complications observed in previous studies[2,4].

The short operative time and hospital stay reflect the advantages of laparoscopic techniques[5,6]. Besides, laparoscopic techniques have obvious advantages for intussusception reduction. First, owing to muscle relaxation after anesthesia, some of the intussuscepted intestines might resolve spontaneously. Second, laparoscopic surgery can more intuitively locate organic lesions such as lymphomas of the terminal ileum and intestinal polyps. With open surgery, only the intussusception at the diverticulum's distal end might have been discovered, and the intussusception of the diverticulum itself might have been missed. Nevertheless, laparoscopy might also have some disadvantages, mainly related to the small abdominal cavity in children and the significant amount of edema in intussusception. First, if the intra-abdominal pressure is too high, the cardiopulmonary function of the patient will be affected. If it is too low, the operating field will be too small. Second, given the abdominal cavity's limited space, a gastric tube could be placed before surgery. Third, intussusception masses are often found in the upper right abdomen because the appendix is sometimes involved. Therefore, searching along the terminal ileum and the appendix is more difficult. Fourth, during reduction, the right-hand grasping forceps pulls the neck of the intussuscepted ileum along the fan-shaped curvature of the mesentery, while the left-hand grasping forceps pulls the neck of the intussuscepted sheath to the opposite direction; in this way, the two forces are maintained in the fan-shaped curvature of the mesentery. If the directions of the two forces are along a straight line, the traction on the mesentery tends to be insufficient. In addition, in the reduced intestine, it is important to change the two forceps' positions at an appropriate time to maintain some tension between the two forces. Finally, if it is found that the intussusception is challenging to reduce by laparoscopy, the umbilical incision should be extended, and the reduction should be performed through the umbilical incision. If necessary, bowel resection should be performed. Although laparoscopic intussusception reduction has many advantages, there are specific contraindications. First, laparoscopic surgery should not be performed in cases with longer times of onset (especially > 48 h), instability of the respiratory or circulatory systems, intestinal perforation, peritonitis, severe abdominal distension, or other manifestations. Second, the intussusceptum ideally should not extend past the middle segment of the transverse colon. Those

advantages and disadvantages have been highlighted in previous studies[2,4-6], but this study innovates by indicating that the umbilical excision can be enlarged when laparoscopy is difficult, without the need to convert the surgery to a true open surgery.

This study has limitations. The sample size was relatively small and from a single center. A treatment bias might be observed due to local practices. The retrospective nature of the study prevented the observation of some variables. Prospective multicenter cohort studies should be performed in the future.

RESULTS

Characteristics of the patients

During the study period, laparoscopic intussusception reduction was performed in 65 patients (Table 1). There were 45 (69.2%) boys and 20 (30.8%) girls, of whom the youngest was 1 mo old, and the oldest was 13 years old, and the average age was 2.3 years (27.5 ± 24.5 mo). The clinical presentations included paroxysmal crying or abdominal pain in 60 cases. There was an abdominal mass in 45 patients, and jam-colored bowel movements in 48 patients. The time of onset was 26.3 ± 7.8 h and was within 48 h in 64 cases and up to 52 h in one patient. Sixty (92.3%) had primary intussusception. Among all patients, three (4.6%), 40 (61.5%), and 22 (33.9%) had ileum, ascending colon, and transverse colon involvement, respectively. Nine (13.8%) patients had acute gastroenteritis, seven (10.8%) had respiratory infection, and one (1.5%) had urinary tract infection. Six (9.2%) were taking probiotics, eight (12.3%) proton pump inhibitors, 13 (20.0%) antibiotics, and four (6.2%) gastrointestinal motility drugs.

Surgical outcomes

Of the 65 patients, laparoscopic reduction surgery was completed in 57 (87.7%) (Table 2). For two (3.1%) patients, laparoscopy revealed that the intussusception had spontaneously resolved. Among the other 8 patients, one patient's intussusceptum was found to have extended past the middle segment of the transverse colon. The mass was large and challenging to reduce under laparoscopy, and the procedure was directly converted to a transverse incision in the right upper abdomen to complete the operation; the operation of the other seven patients was completed with an extension of the umbilical incision. Among them, five (7.7%) patients had abnormal bowel lesions, one (1.5%) had intestinal necrosis, and one (1.5%) had severe bowel nesting. Postoperative pathological findings indicated two patients with lymphoma of the terminal ileum, one patient with Meckel's diverticulum, one patient with small intestinal duplication, and one patient with small intestine polyps. There were 15 with appendicular intussusception among all patients, in which the appendixes exhibited congestion and swelling and were resected. The average operative time was 42.2 ± 12.2 min. All patients were discharged uneventfully, and the hospital stays were 3-12 d, with an average of 4.5 d (4.5 ± 1.3). The intraoperative blood loss was 2.2 ± 1.6 mL.

Complications

The follow-up period ranged from 3 years to 8 years. There were no complications, such as intestinal adhesions, wound infections, or intestinal perforations. There were two cases of recurrent intussusception, one of which was resolved with pneumatic reduction, and one underwent a second laparoscopic surgery.

DISCUSSION

Study design and patients

This study was a retrospective case series of pediatric patients with intussusception who underwent surgical reduction by laparoscopy from May 2011 to April 2016 at the Department of Pediatric Surgery of Taizhou Hospital of Zhejiang Province. The cases in this study were consecutive cases and were operated by the same surgical team. The study was approved by the ethics committee of Taizhou Hospital. The committee waived the requirement for informed consent because of the study's retrospective nature. The indications for laparoscopic surgery: (1) Diagnosed with intussusception by B-mode ultrasound[11]; (2) Unsuccessful gaseous enema reduction; (3) Organic lesions are highly suspected; and (4) Repeated intussusception times were more than three times within 1 wk.

Table 1 Characteristics of the patients

Characteristic	Total (n = 65)
Age, means \pm SD (range)	27.5 \pm 24.5 mo (1 mo-13 yr)
Sex, n (%)	
Male	45 (69.2)
Female	20 (30.8)
Time of onset, h, means \pm SD	26.3 \pm 7.8
Clinical presentations, n (%)	
Paroxysmal crying or abdominal pain	60 (92.3)
Abdominal mass	45 (69.2)
Jam-colored bowel movements	48 (73.8)
Type of intussusception, n (%)	
Primary	60 (92.3)
Secondary	5 (7.7)
Level of intussusceptum, n (%)	
Ileum	3 (4.6)
Ascending colon	40 (61.5)
Transverse colon	22 (33.9)
Descending colon	0
Comorbidities, n (%)	
Acute gastroenteritis	9 (13.8)
Respiratory infection	7 (10.8)
Urinary tract infection	1 (1.5)
Medication, n (%)	
Probiotics	6 (9.2)
Proton pump inhibitor	8 (12.3)
Antibiotics	13 (20.0)
Gastrointestinal motility	4 (6.2)

SD: Standard deviation.

The contra-indications for laparoscopic surgery: (1) Children with high abdominal distension and pneumoperitoneum could not be established; (2) Patients with abnormal cardiopulmonary functions and unable to tolerate pneumoperitoneum; or (3) The intussusception was large, and its head exceeded the middle section of the transverse colon. The cases in this study were consecutive cases and were operated by the same surgical team.

Surgical method

Routine blood tests, electrolyte tests, and blood gas analyses were performed before surgery. Before the operation, a gastric tube and an indwelling catheter were placed when it was considered necessary. General anesthesia by tracheal intubation was used in all cases. The patient was positioned with the head downward and tilted to the left to expose the ileocecal segment of the intestine fully. The operator was positioned on the left side of the patient. An incision of 0.5-1.0-cm in length was made at the lower margin of the umbilicus. A trocar was placed under direct vision. CO₂ was slowly injected, and the pressure was maintained at 8-12 mmHg. A 0° laparoscope was placed, 5-mm trocars were inserted in the lower right abdomen and the lower left abdomen under laparoscopic monitoring, and minimally invasive grasping forceps were placed. First, we find the hepatic segment of the transverse colon below the liver,

Table 2 Clinical characteristics and prognosis related to surgery

Characteristic	Total (n = 65)
Operation time, min, means \pm SD	42.2 \pm 12.2
Intraoperative blood loss, mL, means \pm SD	2.2 \pm 1.6
Conversion rate of laparotomy, n (%)	8 (12.3)
With a transverse incision in the right upper abdomen	1 (1.5)
With an extension of the umbilical incision	7 (10.8)
Reasons for conversion, n (%)	
Abnormal bowel lesions	5 (7.7)
Intestinal necrosis	1 (1.5)
Severe bowel nesting	1 (1.5)
Postoperative pathology, n (%)	
Lymphoma of the terminal ileum	2 (3.0)
Meckel's diverticulum	1 (1.5)
Small intestinal duplication	1 (1.5)
Small intestine polyps	1 (1.5)
Intraoperative appendectomy	15 (23.1)
Postoperative hospital stay, d, means \pm SD	4.5 \pm 1.3
Postoperative complications, n (%)	
Intestinal adhesion, intestinal obstruction	0
Infection of incision	0
Intussusception recurred	2 (3.0)

SD: Standard deviation.

and then find the intussusception along its proximal direction. With the right hand, the ileum's neck was grasped with the grasping forceps and pulled outward, paying attention to pull along the fan-shaped curvature of the mesentery. With the left hand, the intussuscepted sheath's neck was pulled in the opposite direction (Figure 1). Based on the length of the reduced intestine, the positions of the two grasping forceps were changed appropriately so that the two forces maintained some tension and were in the mesentery's curvature. The neck of the intussuscepted mass was frequently tight, and the left-hand forceps were used to open the neck of the outer sheath, while the right-hand forceps were used to pull the neck of the intussuscepted ileum so that some of the fluid in the neck could be drained. Simultaneously, part of the mesenteric tissue was pulled outward so that the neck was relatively loose and easy to reduce. After reduction, the intestines were examined for necrosis and other organic lesions. If none were found, the ileum's seromuscular layer and the ascending colon were repaired with two sutures. If the ileocecal segment was relatively isolated, it was fixed to the lower right abdominal wall with two sutures. Appendectomy was performed depending on the condition of the appendicular blood supply and swelling. When there was a reduction with a single laparoscope were found to be complicated or organic lesions were present, the neck of the intussusception mass or the intestine with organic lesions was fixed with grasping forceps under laparoscopic monitoring, and then the umbilical incision was extended transversely. The intussusception mass was then pulled out of the umbilical incision for manual reduction or intestinal resection (Figure 2). After anesthesia and return to consciousness, the patients were transferred to the general pediatric surgical ward. They received conventional second-generation cephalosporin antibiotics (50-100 mg/kg/d), omeprazole injection (0.7 mg/kg/d), and intravenous fluids for 3-7 d. The patients began to eat and gradually returned to normal diet 1-5 d after the operation according to their condition.

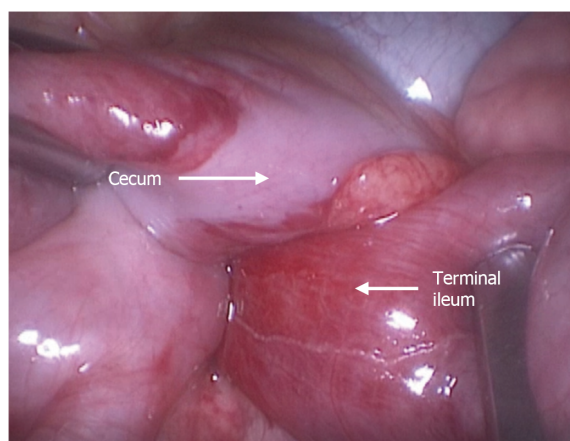


Figure 1 Laparoscopic approach for managing intussusception. The neck of the ileum was grasped with grasping forceps and pulled outward. Other grasping forceps were used to pull the neck of the intussusceptum sheath to the opposite direction.

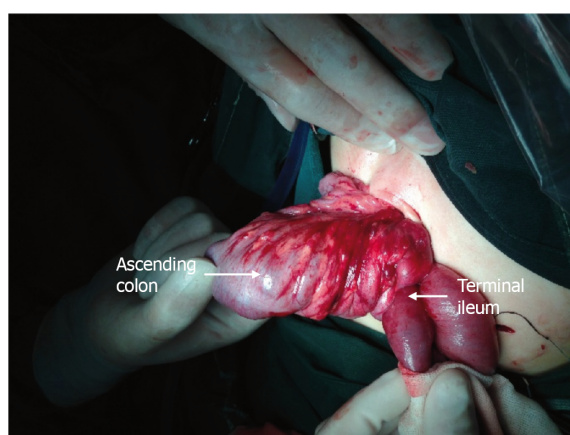


Figure 2 Conversion because of complicated or organic lesions. The umbilical incision was extended, and grasping forceps were used to grasp the intussusception mass out of the incision for manual reduction.

Data collection and follow-up

The data of all patients were collected from the paper medical records of the Department of Pediatric Surgery of Taizhou Hospital of Zhejiang Province, including basic characteristics (age, sex, time of onset, type of intussusception, level of intussusceptum, comorbidities, and medication) and clinical characteristics (operation time, intraoperative blood loss, conversion rate of laparotomy, reasons for conversion, postoperative hospital stay, and adverse events).

The family members of all patients were followed until June 2019 by outpatient reexamination, telephone or Wechat contact at 1 wk, 1 mo, half a year and 1 year, respectively, to collect data including wound healing, diet, bowel movements, abdominal pain and vomiting, sleep, growth and development, *etc.* Follow-up was conducted by 3 practicing physicians with more than 5 years of clinical experience in pediatric surgery.

Statistics

All data were analyzed using SPSS 19.0 for Windows (IBM, Armonk, NY, United States). The continuous data were tested for normal distribution using the Kolmogorov-Smirnov test; those meeting the normal distribution are presented as means \pm SD; otherwise, they are presented as medians (ranges). The categorical data are presented as *n* (%). Descriptive statistics were used.

CONCLUSION

Intussusception is an invagination of a proximal segment of the intestine into a distal part of the intestine that may result in bowel obstruction, venous congestion, and bowel wall edema[12-15]. It is a common cause of acute abdominal emergency in infants and children. It is most common in infants and children aged 3 mo to 3 years, with a peak incidence between 5 and 9 mo of age[12,13,16]. The vast majority of cases are ileocolic, but small bowel to small bowel and colocolonic intussusceptions may also occur[12,13]. The incidence is 3-40 cases per 10000 live births in the United States of America, Europe, and Australia[7,14,17,18]. Typical clinical presentation of intussusception includes paroxysmal crying, vomiting, an abdominal sausage-like mass, and jam-like, bloody stool[8,12,13]. It is primarily diagnosed through medical history taking, physical examination, ultrasound, and computed tomography[8,12,13]. Pneumatic reduction and ultrasound-guided hydrostatic reduction are the most widely used methods for treating intussusception in children[12,13,16,19-21]. They have a success rate as high as 95%, but pneumatic reduction and ultrasound-guided hydrostatic reduction still fails in some intussusception cases[7,8], and such children will require surgical treatment.

In the past, conventional open surgery was the mainstream surgical treatment for intussusception[12,13,20,21]. However, conventional surgery is associated with significant trauma in children[12,13]. With the development of laparoscopic techniques, there have been increasingly more reports of successful laparoscopic treatment of intussusception, limiting the surgical trauma and allowing faster recovery [1,21]. Nevertheless, laparoscopic treatment for intussusception remains controversial because the port setting is challenging because of the small working space in infants and small children and because the affected segment may vary among children. Besides, the reported series are small.

Therefore, this retrospective study aimed to explore the clinical characteristics, effectiveness, and complications of surgical reduction for intussusception using laparoscopy in children. The results could provide additional data for the management of this condition.

ARTICLE HIGHLIGHTS

Research background

Intussusception can be managed by pneumatic reduction, ultrasound-guided hydrostatic reduction, open or laparoscopic surgery. On the other hand, the use of laparoscopy in such cases remains controversial.

Research motivation

The use of laparoscopy in infants with intussusception could be less morbid for the patients.

Research objectives

To explore the clinical characteristics, effectiveness, and complications of surgical reduction for intussusception using laparoscopy in children.

Research methods

This retrospective case series included pediatric patients with intussusception who underwent surgical reduction by laparoscopy from May 2011 to April 2016 at Taizhou Hospital of Zhejiang Province. The clinical characteristics (operation time, intraoperative blood loss, conversion rate of laparotomy, reasons for conversion, postoperative hospital stay, and adverse events) of the patients were described.

Research results

The study could include 65 patients (45 boys and 20 girls). They were 2.3 years (27.5 ± 24.5 mo). Of the 65 patients, 61 underwent surgical reduction by laparoscopy after a failed enema reduction of intussusception, and four underwent the procedure directly. All patients were treated successfully. Fifty-seven (87.7%) patients underwent successful laparoscopic surgery, two of which had a spontaneous reduction. Among the remaining cases, one was converted to open surgery *via* right upper quadrant incision, and seven required enlarged umbilical incisions. Intestinal resection was performed in five patients because of abnormal bowel lesions. There were no complications (intesti-

nal perforations, wound infections, or intestinal adhesions) during the follow-up of 3 years to 8 years. Two patients experienced a recurrence of intussusception; one was resolved with pneumatic reduction, and the other underwent a second laparoscopic surgery.

Research conclusions

Laparoscopic approach for pediatric intussusception is feasible and safe. Bowel resection if required can be performed by extending umbilical incision without the conventional laparotomy.

Research perspectives

This study provides useful data for the management of infants with intussusception.

REFERENCES

- 1 **Chang PC**, Duh YC, Fu YW, Hsu YJ, Wei CH. Single-incision laparoscopic surgery for idiopathic intussusception in children: Comparison with conventional laparoscopy. *J Pediatr Surg* 2019; **54**: 1604-1608 [PMID: [30121127](#) DOI: [10.1016/j.jpedsurg.2018.07.010](#)]
- 2 **Vilallonga R**, Himpens J, Vandercruysse F. Laparoscopic treatment of intussusception. *Int J Surg Case Rep* 2015; **7C**: 32-34 [PMID: [25574769](#) DOI: [10.1016/j.ijscr.2014.10.085](#)]
- 3 **Song EJ**, Nam SH. Feasibility of Laparoscopic Surgery for Intussusception in Pediatric Patients and Risk of Bowel Resection. *J Minim Invas Surg* 2018; **21**: 154-159 [DOI: [10.7602/jmis.2018.21.4.154](#)]
- 4 **Kao C**, Tseng SH, Chen Y. Laparoscopic reduction of intussusception in children by a single surgeon in comparison with open surgery. *Minim Invasive Ther Allied Technol* 2011; **20**: 141-145 [PMID: [20925588](#) DOI: [10.3109/13645706.2010.518801](#)]
- 5 **Almaramhy HH**. Laparoscopic reduction of intussusception in children: role in primary and revisional reduction after failed non-surgical therapies. *Int J Health Sci (Qassim)* 2011; **5**: 71-78 [PMID: [22489232](#)]
- 6 **Wei CH**, Fu YW, Wang NL, Du YC, Sheu JC. Laparoscopy vs open surgery for idiopathic intussusception in children. *Surg Endosc* 2015; **29**: 668-672 [PMID: [25037726](#) DOI: [10.1007/s00464-014-3717-1](#)]
- 7 **Ko HS**, Schenk JP, Tröger J, Rohrschneider WK. Current radiological management of intussusception in children. *Eur Radiol* 2007; **17**: 2411-2421 [PMID: [17308922](#) DOI: [10.1007/s00330-007-0589-y](#)]
- 8 **Waseem M**, Rosenberg HK. Intussusception. *Pediatr Emerg Care* 2008; **24**: 793-800 [PMID: [19018227](#) DOI: [10.1097/PEC.0b013e31818c2a3e](#)]
- 9 **van der Laan M**, Bax NM, van der Zee DC, Ure BM. The role of laparoscopy in the management of childhood intussusception. *Surg Endosc* 2001; **15**: 373-376 [PMID: [11395818](#) DOI: [10.1007/s004640090044](#)]
- 10 **Kaiser AD**, Applegate KE, Ladd AP. Current success in the treatment of intussusception in children. *Surgery* 2007; **142**: 469-75; discussion 475 [PMID: [17950338](#) DOI: [10.1016/j.surg.2007.07.015](#)]
- 11 **Endoscopic Surgery Group**, Pediatric Surgery Society, Zhonghua Yixuehui [DOI: [10.1007/s42804-019-00035-8](#)]
- 12 **Loukas M**, Pellerin M, Kimball Z, de la Garza-Jordan J, Tubbs RS, Jordan R. Intussusception: an anatomical perspective with review of the literature. *Clin Anat* 2011; **24**: 552-561 [PMID: [21268121](#) DOI: [10.1002/ca.21099](#)]
- 13 **Edwards EA**, Pigg N, Courtier J, Zapala MA, MacKenzie JD, Phelps AS. Intussusception: past, present and future. *Pediatr Radiol* 2017; **47**: 1101-1108 [PMID: [28779197](#) DOI: [10.1007/s00247-017-3878-x](#)]
- 14 **Jiang J**, Jiang B, Parashar U, Nguyen T, Bines J, Patel MM. Childhood intussusception: a literature review. *PLoS One* 2013; **8**: e68482 [PMID: [23894308](#) DOI: [10.1371/journal.pone.0068482](#)]
- 15 **Jain S**, Haydel MJ. Child Intussusception. StatPearls. Treasure Island (FL) 2020 [DOI: [10.5040/9780571352654.000000004](#)]
- 16 **Applegate KE**. Intussusception in children: evidence-based diagnosis and treatment. *Pediatr Radiol* 2009; **39** Suppl 2: S140-S143 [PMID: [19308373](#) DOI: [10.1007/s00247-009-1178-9](#)]
- 17 **Tate JE**, Simonsen L, Viboud C, Steiner C, Patel MM, Curns AT, Parashar UD. Trends in intussusception hospitalizations among US infants, 1993-2004: implications for monitoring the safety of the new rotavirus vaccination program. *Pediatrics* 2008; **121**: e1125-e1132 [PMID: [18450856](#) DOI: [10.1542/peds.2007-1590](#)]
- 18 **Buettcher M**, Baer G, Bonhoeffer J, Schaad UB, Heininger U. Three-year surveillance of intussusception in children in Switzerland. *Pediatrics* 2007; **120**: 473-480 [PMID: [17766518](#) DOI: [10.1542/peds.2007-0035](#)]
- 19 **Gluckman S**, Karpelowsky J, Webster AC, McGee RG. Management for intussusception in children. *Cochrane Database Syst Rev* 2017; **6**: CD006476 [PMID: [28567798](#) DOI: [10.1002/14651858.CD006476.pub3](#)]
- 20 **Charles T**, Penninga L, Reurings JC, Berry MC. Intussusception in Children: A Clinical Review.

- Acta Chir Belg* 2015; **115**: 327-333 [PMID: 26559998 DOI: 10.1080/00015458.2015.11681124]
- 21 **Kelley-Quon LI**, Arthur LG, Williams RF, Goldin AB, St Peter SD, Beres AL, Hu YY, Renaud EJ, Ricca R, Slidell MB, Taylor A, Smith CA, Miniati D, Sola JE, Valusek P, Berman L, Raval MV, Gosain A, Dellinger MB, Somme S, Downard CD, McAteer JP, Kawaguchi A. Management of intussusception in children: A systematic review. *J Pediatr Surg* 2021 [PMID: 33158508 DOI: 10.1016/j.jpedsurg.2020.09.055]



Published by **Baishideng Publishing Group Inc**
7041 Koll Center Parkway, Suite 160, Pleasanton, CA 94566, USA

Telephone: +1-925-3991568

E-mail: bpgoffice@wjgnet.com

Help Desk: <https://www.f6publishing.com/helpdesk>

<https://www.wjgnet.com>

