

World Journal of *Radiology*

World J Radiol 2022 June 28; 14(6): 114-179



REVIEW

- 114 Tuberculosis conundrum - current and future scenarios: A proposed comprehensive approach combining laboratory, imaging, and computing advances
Merchant SA, Shaikh MJS, Nadkarni P

MINIREVIEWS

- 137 Recent advances in imaging techniques of renal masses
Aggarwal A, Das CJ, Sharma S
- 151 Artificial intelligence technologies in nuclear medicine
Tamam MO, Tamam MC

ORIGINAL ARTICLE**Prospective Study**

- 155 Evaluation of the dual vascular supply patterns in ground-glass nodules with a dynamic volume computed tomography
Wang C, Wu N, Zhang Z, Zhang LX, Yuan XD
- 165 Do preoperative pancreatic computed tomography attenuation index and enhancement ratio predict pancreatic fistula after pancreaticoduodenectomy?
Gnanasekaran S, Durgesh S, Gurram R, Kalayarasan R, Pottakkat B, Rajeswari M, Srinivas BH, Ramesh A, Sahoo J

LETTER TO THE EDITOR

- 177 Comments on "Neonatal infratentorial subdural hematoma contributing to obstructive hydrocephalus in the setting of therapeutic cooling: A case report"
Siasios I, Fotiadou A, Rud Y

ABOUT COVER

Editorial Board Member of *World Journal of Radiology*, Jaber S Alqahtani, MSc, PhD, Academic Research, Assistant Professor, Research Scientist, Department of Respiratory Care, Prince Sultan Military College of Health Sciences, Dammam 34313, Saudi Arabia. Alqahtani-Jaber@hotmail.com

AIMS AND SCOPE

The primary aim of *World Journal of Radiology* (*WJR*, *World J Radiol*) is to provide scholars and readers from various fields of radiology with a platform to publish high-quality basic and clinical research articles and communicate their research findings online.

WJR mainly publishes articles reporting research results and findings obtained in the field of radiology and covering a wide range of topics including state of the art information on cardiopulmonary imaging, gastrointestinal imaging, genitourinary imaging, musculoskeletal imaging, neuroradiology/head and neck imaging, nuclear medicine and molecular imaging, pediatric imaging, vascular and interventional radiology, and women's imaging.

INDEXING/ABSTRACTING

The *WJR* is now abstracted and indexed in Emerging Sources Citation Index (Web of Science), PubMed, PubMed Central, Reference Citation Analysis, China National Knowledge Infrastructure, China Science and Technology Journal Database, and Superstar Journals Database. The 2021 edition of Journal Citation Reports® cites the 2020 Journal Citation Indicator (JCI) for *WJR* as 0.51.

RESPONSIBLE EDITORS FOR THIS ISSUE

Production Editor: Wen-Wen Qi; Production Department Director: Xu Guo; Editorial Office Director: Jia-Ping Yan.

NAME OF JOURNAL

World Journal of Radiology

ISSN

ISSN 1949-8470 (online)

LAUNCH DATE

January 31, 2009

FREQUENCY

Monthly

EDITORS-IN-CHIEF

Thomas J Vogl

EDITORIAL BOARD MEMBERS

<https://www.wjgnet.com/1949-8470/editorialboard.htm>

PUBLICATION DATE

June 28, 2022

COPYRIGHT

© 2022 Baishideng Publishing Group Inc

INSTRUCTIONS TO AUTHORS

<https://www.wjgnet.com/bpg/gerinfo/204>

GUIDELINES FOR ETHICS DOCUMENTS

<https://www.wjgnet.com/bpg/gerinfo/287>

GUIDELINES FOR NON-NATIVE SPEAKERS OF ENGLISH

<https://www.wjgnet.com/bpg/gerinfo/240>

PUBLICATION ETHICS

<https://www.wjgnet.com/bpg/gerinfo/288>

PUBLICATION MISCONDUCT

<https://www.wjgnet.com/bpg/gerinfo/208>

ARTICLE PROCESSING CHARGE

<https://www.wjgnet.com/bpg/gerinfo/242>

STEPS FOR SUBMITTING MANUSCRIPTS

<https://www.wjgnet.com/bpg/gerinfo/239>

ONLINE SUBMISSION

<https://www.f6publishing.com>

Tuberculosis conundrum - current and future scenarios: A proposed comprehensive approach combining laboratory, imaging, and computing advances

Suleman Adam Merchant, Mohd Javed Saifullah Shaikh, Prakash Nadkarni

Specialty type: Radiology, nuclear medicine and medical imaging

Provenance and peer review: Invited article; Externally peer reviewed.

Peer-review model: Single blind

Peer-review report's scientific quality classification

Grade A (Excellent): A

Grade B (Very good): B

Grade C (Good): C, C

Grade D (Fair): 0

Grade E (Poor): 0

P-Reviewer: Barbosa OA, Brazil; Phan LMT, South Korea; Primadhi RA, Indonesia

A-Editor: Zhu JQ, United States

Received: January 17, 2022

Peer-review started: January 17, 2022

First decision: March 16, 2022

Revised: April 17, 2022

Accepted: May 27, 2022

Article in press: May 27, 2022

Published online: June 28, 2022



Suleman Adam Merchant, Lokmanya Tilak Municipal Medical College and General Hospital, Mumbai 400022, Maharashtra, India

Mohd Javed Saifullah Shaikh, Department of Radiology, North Bengal Neuro Centre, Jupiter magnetic resonance imaging, Diagnostic Centre, Siliguri 734003, West Bengal, India

Prakash Nadkarni, College of Nursing, University of Iowa, Iowa 52242, IA, United States

Corresponding author: Suleman Adam Merchant, MBBS, MD, Former Dean, Professor & Head (Radiology), Lokmanya Tilak Municipal Medical College and General Hospital, Sion Hospital, Mumbai 400022, Maharashtra, India. suleman.a.merchant@gmail.com

Abstract

Tuberculosis (TB) remains a global threat, with the rise of multiple and extensively drug resistant TB posing additional challenges. The International health community has set various 5-yearly targets for TB elimination: mathematical modelling suggests that a 2050 target is feasible with a strategy combining better diagnostics, drugs, and vaccines to detect and treat both latent and active infection. The availability of rapid and highly sensitive diagnostic tools (Gene-Xpert, TB-Quick) will vastly facilitate population-level identification of TB (including rifampicin resistance and through it, multi-drug-resistant TB). Basic-research advances have illuminated molecular mechanisms in TB, including the protective role of Vitamin D. Also, Mycobacterium tuberculosis impairs the host immune response through epigenetic mechanisms (histone-binding modulation). Imaging will continue to be key, both for initial diagnosis and follow-up. We discuss advances in multiple imaging modalities to evaluate TB tissue changes, such as molecular imaging techniques (including pathogen-specific positron emission tomography imaging agents), non-invasive temporal monitoring, and computing enhancements to improve data acquisition and reduce scan times. Big data analysis and Artificial Intelligence (AI) algorithms, notably in the AI sub-field called "Deep Learning", can potentially increase the speed and accuracy of diagnosis. Additionally, Federated learning makes multi-institutional/multi-city AI-based collaborations possible without sharing identifiable patient data. More powerful hardware designs - e.g., Edge and Quantum Computing- will facilitate the role of computing applications in TB. However, "Artificial Intelligence needs real Intelligence to guide it!" To have maximal impact, AI must use a holistic

approach that incorporates time tested human wisdom gained over decades from the full gamut of TB, *i.e.*, key imaging and clinical parameters, including prognostic indicators, plus bacterial and epidemiologic data. We propose a similar holistic approach at the level of national/international policy formulation and implementation, to enable effective culmination of TB's endgame, summarizing it with the acronym "TB - REVISITED".

Key Words: Tuberculosis; Radiology; GenXpert; Artificial intelligence; Molecular imaging; Quantum computing

©The Author(s) 2022. Published by Baishideng Publishing Group Inc. All rights reserved.

Core Tip: A Holistic (comprehensive) approach is suggested to achieve tuberculosis (TB) elimination goals. Early diagnosis especially for Multi-Drug Resistant TB. Utility of Modern Rapid Diagnostic Tools. The role of Imaging in TB and key radiological signs. Comprehensive Artificial Intelligence(AI) algorithms incorporating key Imaging and clinical signs. The role of Vitamin D supplementation in complementing the TB drug regimen. Molecular Imaging. Quantum Computing and other perspectives in TB strategies to help achieve the various targets set for elimination of TB. A unified Global approach with edge computing/ dashboards and other technological innovations.

Citation: Merchant SA, Shaikh MJS, Nadkarni P. Tuberculosis conundrum - current and future scenarios: A proposed comprehensive approach combining laboratory, imaging, and computing advances. *World J Radiol* 2022; 14(6): 114-136

URL: <https://www.wjgnet.com/1949-8470/full/v14/i6/114.htm>

DOI: <https://dx.doi.org/10.4329/wjr.v14.i6.114>

INTRODUCTION

Nearly 1.5 centuries after Robert Koch discovered *Mycobacterium tuberculosis* (MTB) in 1882, tuberculosis (TB) remains a global threat and a deadly human pathogen, ubiquitous enough to comprise an occupational hazard for medical personnel in many locales. Its high prevalence in both immunocompetent and immunocompromised individuals historically made TB a top-10 cause of death worldwide and the leading cause of death from a single infectious agent, though it fell to 13th after being overtaken by COVID-19 in 2021[1]. 95% of cases and deaths occur in developing countries. About one-quarter of the world's population has a TB infection, though most are not (yet) symptomatic and contagious[2]. Because people with active TB can infect 5-15 other people through close contact over a single year, the consequence of delayed/missed diagnosis cascade[2]. However, TB is curable and preventable[2].

The incessant rise of Multidrug-resistant TB (MDR-TB) and extensively drug-resistant (XDR) TB, either primary or acquired, pose an additional challenge[3,4]. Incidence of either varies in different studies: More concerning, only 1/3rd of such individuals accessed treatment in 2020[2].

The three countries with the largest share of the global burden in 2019 were India (27%, 2.8 million cases annually, 150,000 MDR-TB cases every year), China (14%), and the Russian Federation (8%)[5,6]. In 2020, an estimated 10 million people fell ill with TB worldwide. The largest number of new TB cases occurred in the WHO South-East Asian Region (43%), African Region (25%), and Western Pacific (18%)[2]. In descending case-count order, eight countries account for two thirds of the total: India, China, Indonesia, the Philippines, Pakistan, Nigeria, Bangladesh, and South Africa[2].

Ending the TB epidemic by 2030 is among the health targets of the United Nations Sustainable Development Goals[2]. The End TB Strategy defines five-yearly milestones/targets for reducing TB cases and deaths. The targets for 2030 are a 90% reduction in TB deaths and an 80% reduction in new cases per year, compared with levels in 2015, with a reduction in new cases to < 1 per million population annually by 2050[7,8].

DIAGNOSIS OF TB

MDR-TB: Advances in laboratory diagnosis

MDR-TB is defined as an infection with MTB strains non-responsive to isoniazid (INH) and rifampicin (RIF), the 2 most effective first-line anti-TB drugs. Mutations in the INH and RIF resistance gene confers high competitive fitness, favoring their spread: >90% of RIF-resistant strains are also INH-resistant[9-11]. Most people develop MDR-TB because of delayed or incomplete treatment, increasing subsequent

healthcare costs dramatically[12]. MDR-TB is curable with second-line drugs: In 2018, the treatment success rate of MDR-TB patients was 59% worldwide. The earlier treatment regimens for up to 2 years have been superseded by WHO's updated (2021) recommendation for shorter (9-11 mo) and fully oral regimens, which increase compliance greatly[2,13,14]. Previously laboratory confirmation of TB by culture required 6-8 wk: Diagnosing MDR-TB, which used to be exclusively clinical, involved delays of up to 4 mo to identify therapeutic response failure; coupled with persistently positive sputum smears after 4 mo of regular treatment with a first-line DOTS (Directly Observed Treatment, Short-course Regimen)[15-17]. Such therapeutic setbacks especially impacted impoverished or illiterate patients psychologically: after expecting a treatment duration of 7-9 mo only, to be informed halfway through that a new regimen was necessary, they often stopped treatment and were lost to follow-up, eventually spreading MDR-TB to others, exponentially. The spread of MDR-TB was also worsened by policies of using the much cheaper 'regular TB' drug regimen empirically: Treating MDR-TB is 5-200 times more expensive than treating nondrug resistant TB[18].

However, PCR based technologies such as cartridge based nucleic acid amplification techniques [CBNAAT] (GeneXpert®, Cepheid United States, introduced in 2010), can now rapidly detect both MTB genetic material from sputum samples and RIF resistance within 2 h using the current generation of technology, without requiring special technicians/rooms and barely occupying the space of a computer printer, at a cost of \$5/test[19,12]. This has been called the most exciting innovation in TB diagnostics in over a century[12]. It is recommended by WHO, which developed policies/guidelines and monitoring frameworks for its use to support developing countries' Ministries of Health (MOHs) in their implementation[12,20]. The latest GeneXpert technology (MTB/RIF Ultra) has a ten-fold improvement in the lower limit of TB detection, and improves differentiation of certain silent mutations, RIF resistance detection in mixed infections (in 3-7 d), increased specificity in detecting RIF resistance in paucibacillary specimens, and better sensitivity in both pulmonary samples and extrapulmonary samples such as pleural/ascitic fluid and biopsied material such as lymph nodes[12,19,21-23]. Our group were amongst the first to successfully use it for lymph nodes and also to recommend the same being used to detect MDR TB upfront.

TB-QUICK is a recent ultrasensitive MTB detection platform which combines loop-mediated isothermal amplification and clustered regularly interspaced short palindromic repeats (CRISPR)-Cas12b reaction for M TB detection. It is highly sensitive (with a near single-copy sensitivity), requires less sample input and offers even a shorter turnaround time than Gene-Xpert for RIF resistance[24].

In South Africa, national screening of high-risk groups [e.g., human immunodeficiency virus (HIV)-infected individuals], deployment of Gene-Xpert machines, treating latent TB, and using quality MTB drugs with shorter regimens led to a decline in TB[25]. We suggest that an identical approach be deployed elsewhere to control the spread of this dreaded scourge.

Overall, TB, either incident or prevalent, is found in 4.1% of the MDR-TB contacts, which is higher than the corresponding prevalence rates of 1.9% and 1.7% reported among household contacts of drug-susceptible TB in the same locality[26,27]. In a study it was shown that RFLP analysis confirmed the transmission of MDR-TB among household contacts while regression analysis showed XDR-TB had an even higher risk of household transmission among all MDR-TB cases[28]. We have successfully used CBNAAT to diagnose extrapulmonary TB, and feel this has tremendous potential to revolutionize TB, especially MDR-TB early diagnosis, treatment, and further management. Piatek *et al*[12] and Mechali *et al* [23] have independently reported the same.

National TB control programs are working to eliminate TB mainly by intensifying efforts to find and cure patients with active disease. Mathematical models developed by Dye and Williams[29] suggest that, while most TB patients can be cured with present drug regimens, the 2050 target is far more likely to be achieved with a synergistic combination of diagnostics, drugs, and vaccines to detect and treat both latent infection and active disease.

IMAGING METHODS IN TUBERCULOSIS

Note: While interventional radiology plays a major role in TB treatment, we deliberately limit this review's scope to diagnostic/prognostic imaging.

TB has a known propensity for dissemination from its primary site and can affect virtually any organ system in the body. It therefore demonstrates a variety of clinical and radiologic findings and can mimic numerous other diseases[30]. Hence, the role of imaging in TB has grown exponentially. The possibility of TB is often first suggested on an imaging study, particularly in relatively inaccessible sites.

In a known case of TB, imaging is often requested to assess the extent of disease, evaluate response to therapy, or detect residual infection after completion of anti-TB therapy. Imaging is also vital in guiding aspiration biopsies, therapeutic drainage of collections of pathological fluid *etc*[31]. Hence, Radiologists will continue to play a vital role in eliminating TB.

Imaging findings in TB depend upon the extent of the disease process. Familiarity with various imaging features permits early diagnosis and prompt management, thereby reducing patient morbidity [30].

In this section, we will also refer to various techniques that fall into the category of “Molecular Imaging Technology” (MIT). MIT visualizes molecules of relevance to a disease at both microscopic levels and in living subjects. For the latter, it provides 3D spatial characterization (often using existing imaging modalities) and non-invasive, temporal monitoring within the same subject[32]. MIT may augment TB research by advancing fundamental knowledge and accelerating the development of novel diagnostics, biomarkers, and therapeutics[32].

Conventional Chest radiography

While radiology training has moved away from conventional radiology, most of the developing world's population cannot access tomographic (cross sectional) imaging readily for logistic or financial reasons. Therefore, the time-tested signs/patterns of TB in conventional chest X-ray (CXR) cannot be forgotten. There is no excuse for missing a Ghon's focus/complex or lamellar effusion of childhood TB in a CXR taken for a different purpose (Figure 1). CXR has high sensitivity but limited specificity for detecting pulmonary TB. As recommended by WHO's guidelines, it is very suitable for TB screening and triaging, to stratify for risk, assess asymptomatic active disease, and for follow-up[33]. Stability of radiographic findings for 6 mo distinguishes inactive from active disease. Where CT is unavailable, lordotic view and penetrated (high kV) views improve depiction of the lung apices and mediastinal/carinal nodes, respectively[34]. Dual-energy radiography with bone subtraction, has also been used to improve depiction of the lung apices[34].

Ultrasonography

Ultrasonography (US) is one of the commonest recommended examinations for TB, including in the evaluation of suspected/affected lymph nodes and for guiding biopsies for the same. Basic details are well known and beyond the scope of this manuscript. It is a very useful non-invasive examination method in children including those with cervical lymphadenitis (across age groups). The US signs of hilar absence, short to long axis (S/L) ratio ≥ 0.5 , an unclear edge, necrosis, an echogenic thin layer, strong echoes and capsular or peripheral vascularity; may aid in the diagnosis of cervical tuberculous lymphadenitis[35]. Endobronchial US-guided fine-needle aspiration biopsy for intrathoracic TB lymphadenopathy is valuable when bronchoalveolar lavage and sputum culture are ambiguous[36].

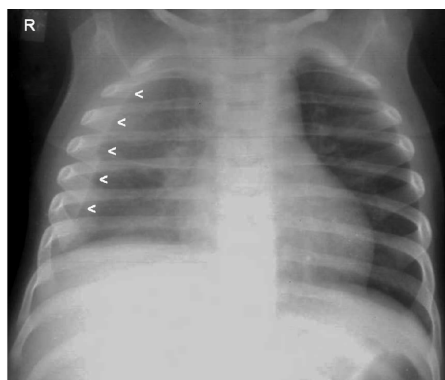
US elastography: [Strain/shear wave] is useful for further evaluation of lymph nodes and the detection of complications such as fibrosis[37,38]. US elastography (USE) techniques are classified by the type of excitation applied: (1) Strain elastography; and (2) Shear wave elastography. Strain elastography includes constant force-induced displacement (static/quasi-static imaging) or acoustic energy-induced physiologic motion. Shear wave elastography is sub-classified as: Transient elastography, point shear wave elastography (pSWE), two-dimensional SWE (2D-SWE), and three-dimensional SWE. Shear wave USE has clear advantages over strain USE by virtue of being quantitative and user independent. However, shear wave measurements are effective only till 3 cm depth from the skin surface, as the shear wave signal tends to attenuate rapidly beyond this depth. This though is an ideal depth for evaluating most cervical TB lymph nodes. On the color elastogram, red represents the softest and blue represents the hardest areas, while intermediate stiffness is indicated by green. These colors represent the relative hardness of tissues on the elastogram (Figure 2A-C). The units of measurement are kilopascal (kPa) or Velocity (V) in meters/sec (m/s) - $[1 \text{ KPa} = 3 \times V^2 (\text{m/s})]$ [39].

Cervical, axillary, and inguinal lymph nodes are easily evaluated by standard USE; and USE has the potential to non-invasively differentiate tuberculous from metastatic lymph nodes because of the latter's greater stiffness[40,41]. On strain USE a cut-off value of 3.0 (strain ratio) has been suggested for determining if a mass/tissue is benign or malignant[42-44]. Shehata *et al*[43] stated that the best shear wave elasticity ratio cut-off value that allows significant differentiation between benign and malignant mass groups was > 4.9 . USE also has great potential for marking biopsy sites in a lymph node for collecting samples for confirmation of the disease, as well as for drug sensitivity purposes, especially in drug resistant TB (Figure 2D). The samples collected should also be run through CBNAAT techniques such as GenXpert. This will enable MDR TB to be detected upfront (refer 'diagnosis of TB section').

These non-invasive techniques will be useful both for initial diagnosis and follow-up, including treatment - response assessment and monitoring of sequelae; *e.g.*, post TB medication Liver fibrosis (Figure 3); where avoiding a liver biopsy would be a great boon[38]. Shear wave Elastography features while assessing liver tissue stiffness are as follows: (1) Normal: 1.37 m/s, Metavir F0-F1; (2) Mild Fibrosis: 1.37 - 1.55 m/s, Metavir F2; (3) Advanced Fibrosis: 1.55 - 1.8 m/s, Metavir F3; and (4) Cirrhosis: > 1.8 m/sec, F4[39]. Metavir is an acronym for "meta-analysis of histological data in viral hepatitis".

EUS: EUS elastography has proven to be useful for the evaluation of mediastinal and abdominal lymph nodes and can provide additional information about the structure and pathology of mediastinal and abdominal lymph nodes. It is an excellent method for targeting different areas of the lymph node to avoid unnecessary needle passes in EUS guided biopsies[40].

Multimodal ultrasound imaging: Multimodal ultrasound imaging combines several US modalities simultaneously: Color Doppler US, US elastography, and contrast-enhanced ultrasound (discussed



DOI: 10.4329/wjrv.14.i6.114 Copyright © The Author(s) 2022.

Figure 1 Lamellar pleural effusion. Frontal chest radiograph of an 18-mo-old child with Pulmonary tuberculosis (primary complex) reveals a lamellar pleural effusion- (homogeneous increased radio-opacity along lateral aspect of right lung field with blunting of the right costophrenic angle- mimicking the appearance of pleural thickening) - [arrowheads]. Image courtesy – Department of Radiology, KEM Hospital, Mumbai.

shortly). It differentiates tuberculous from non-tuberculous superficial tuberculous lymphadenitis with 100.00% sensitivity and a 94.12% positive predictive value[45].

Micro-Bubbles in diagnosis and theragnostics: “Theragnostics” combines disease diagnosis with therapy[46,47]. Micrometer-sized gas bubbles “micro-bubbles (MB)” allow for intravenous contrast-enhanced US: MBs oscillate resonantly when subjected to high-frequency US, which they reflect intensely[48].

The utility of the same in diagnostic radiology, especially for the urinary tract, is well established[49]. They can readily be utilized for US assessment of vesico-ureteric reflux in patulous golf-hole ureterovesical junctions seen in TB, circumventing the use of ionizing radiation. Kiessling *et al*[50] discuss conjugation of antibodies to the MB surface and incorporation of various molecules inside or onto the MB shell.

MBs have potential for targeted therapies. High-intensity US (HIUS) temporarily disrupts the blood-brain barrier, allowing medications contained in MBs, which HIUS also disrupts, to treat CNS cancers and intracranial TB[50]. Additionally, MBs can deliver medications to TB lymph nodes, as well as gene therapy to tissues exhibiting congenital disease phenotypes[51].

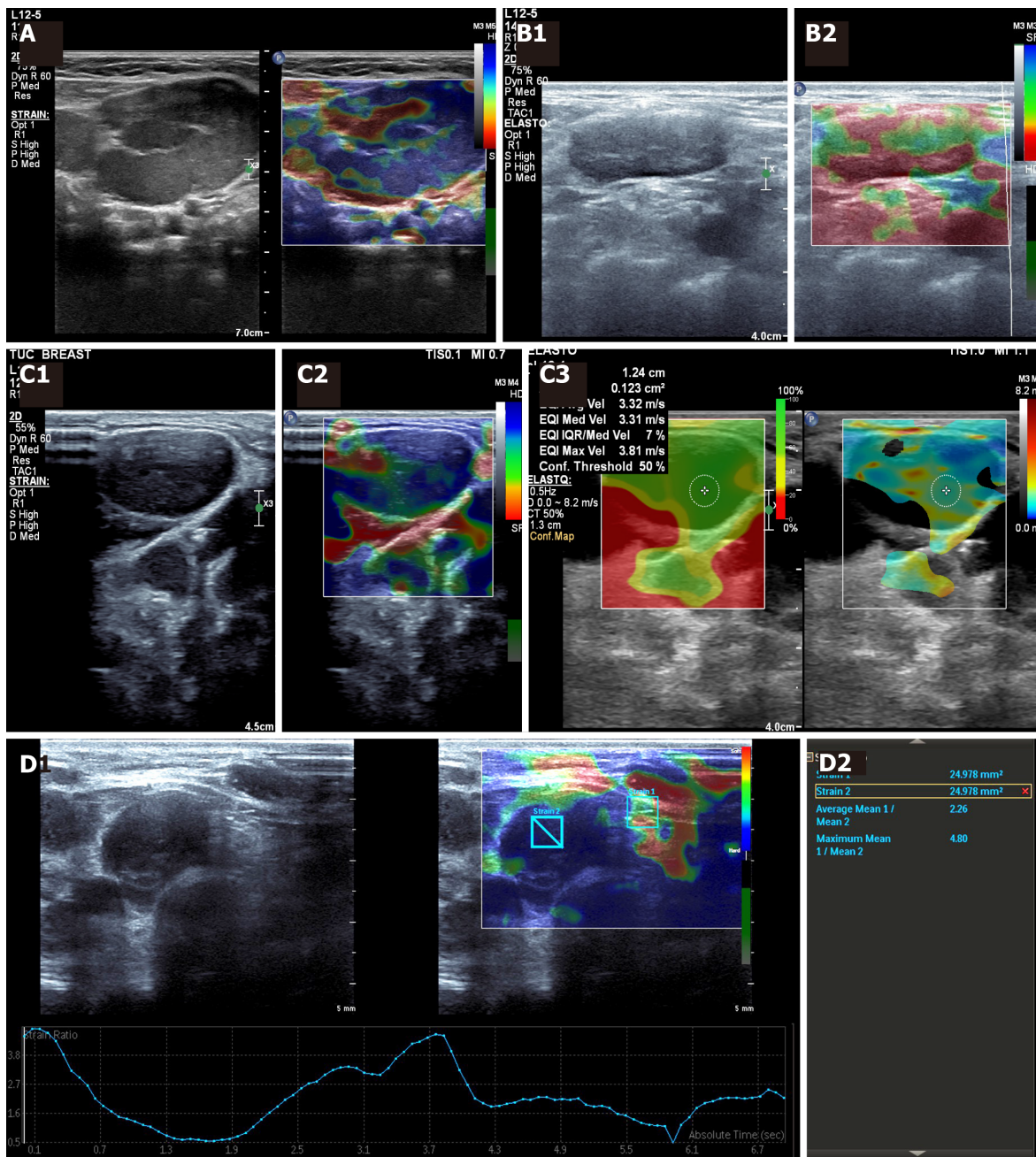
Ultra-high-frequency US and Ultrasound biomicroscopy: Ultrasound biomicroscopy (UBM) is a superb tool to assess superficial TB lesions such as skin TB (lupus vulgaris), both in their diagnosis, as well as during follow up (Figure 4). This is safe and easily repeatable and avoids the use of repeated biopsies. Ma *et al*[48] have designed a small-aperture (0.6 mm × 3 mm) IVUS probe optimized for high-frequency contrast imaging. Their design utilizes a dual-frequency (6.5 MHz/30 MHz) transducer for exciting microbubbles at low frequencies (near their resonance) and detecting their broadband harmonics at high frequencies. Fei *et al*[52] have developed broadband lithium niobate single element ultrasonic transducers in the range of 100-300 MHz for high resolution imaging. They claim a performance comparable to optical resolution and state that availability of ultrahigh frequency transducers will make Ultrasound Biomicroscopy (UBM) a promising tool to study fine biological structures. Future applications of CEUS and UBM could be expected in TB too.

Dark Field Radiography

X-ray dark-field radiography relies on ultra-small-angle scattering (diffraction) of X-rays at the material interfaces within the tissue under investigation[53]. “Dark field”, when applied to visible light, refers to the bright appearance of scattering objects on a dark background. Healthy lung tissue, with numerous air/parenchyma interfaces in the alveoli, produces a relatively high signal[54,55]. Introduced experimentally in 2008, Dark field radiography may increase sensitivity for early detection of varied lung pathologies involving the alveoli, including tuberculosis.

Computed Tomography

Computed tomography (CT) enables non-invasive diagnosis of TB in patients with negative sputum examination or no sputum production (as occurs in the follow-up of patients on anti-tuberculosis therapy (ATT) or at presentation) non-invasively: it permits empirical ATT initiation until culture results are obtained[56]. Contrast-enhanced CT is the investigation of choice for evaluating mediastinal LNs and identifying pleural enhancement in empyema (Figure 5). High-resolution CT (HRCT) reconstructions are especially useful to detect miliary and centrilobular nodules, ground-glass opacities,



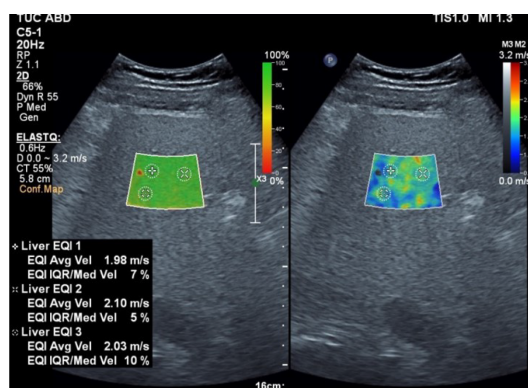
DOI: 10.4329/wjr.v14.i6.114 Copyright © The Author(s) 2022.

Figure 2 Cervical tuberculosis lymph node. A: Cervical tuberculosis lymph node: Ultrasonography (US) elastography - central necrotic area appears soft (red); B: Tuberculous lymphadenopathy: A 16-year-old female with fever and neck swelling; B1: Grey scale B-mode image: shows an enlarged lymph node with diffusely hypoechoic echotexture and loss of fatty hilum; B2: Strain US Elastography: Showing a mixed pattern, predominantly soft (red); C: Tuberculous lymphadenopathy: 35-year-old male with neck swelling and history of weight loss; C1: Grey scale image: shows an enlarged lymph node with diffusely hypoechoic echotexture and loss of fatty hilum; C2: Strain US elastography: Showing soft areas within (red areas) s/o necrosis / liquefaction; C3: Shear wave US elastography: Shows relatively low shear wave values; D: Tuberculous lymphadenopathy: Neck US of a 14-year-old female (known case of drug resistant tuberculosis); D1: Grey scale B-mode image: enlarged lymph nodes with diffusely hypoechoic echotexture and loss of fatty hilum; D2: Strain US Elastography: The strain elastography reveals a low strain ratio (2.26). Elastography details are noted on the elastography graph too. Trucut biopsy was done - results awaited. Images courtesy Dr. Chaubal N, Thane Ultrasound Centre, India.

and air-trapping (Figure 6).

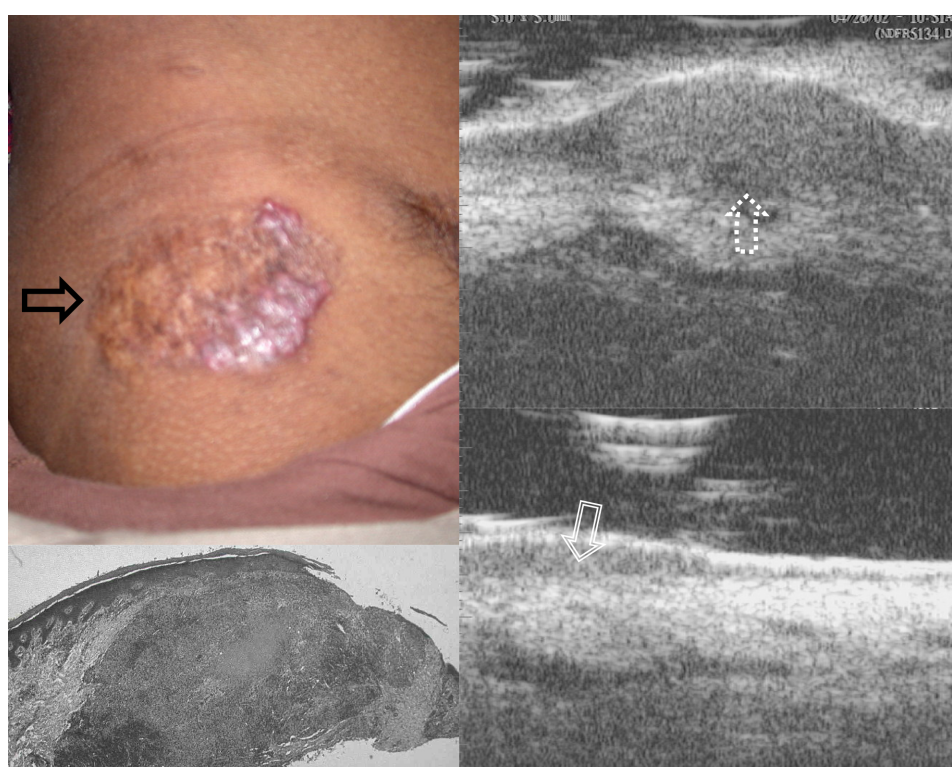
Multi-detector CT and its volumetric capability enables earlier and more accurate diagnosis of pulmonary lesions: detection of radiographically occult disease; assessment of disease activity, parenchymal lesions (including miliary TB), mediastinal lymph nodes (LNs), and visualized bones. It also helps evaluate complications like bronchiectasis, cavitation, associated fungal balls, LN necrosis, and pleural/airway/diaphragmatic pathology (Figure 7).

Spectral imaging on CT (dual-/tri-/quad-energy), when it becomes widely available, should further enhance radiologists' diagnostic armamentarium[38]. Khan *et al*[57] concluded that dual energy CT is superior to high-resolution CT for assessing pulmonary TB. Recent CT iterative reconstructions allow



DOI: 10.4329/wjrv.14.i6.114 Copyright © The Author(s) 2022.

Figure 3 Shear wave ultrasonography elastography of Liver: 28-year male, on tuberculosis medications for 8 mo, with altered liver functions. Stiffness median - 1.76 metres/sec -- Metavir F3: indicative of Enhanced liver fibrosis. Images courtesy Dr. Chaubal N, Thane Ultrasound Centre, India.



DOI: 10.4329/wjrv.14.i6.114 Copyright © The Author(s) 2022.

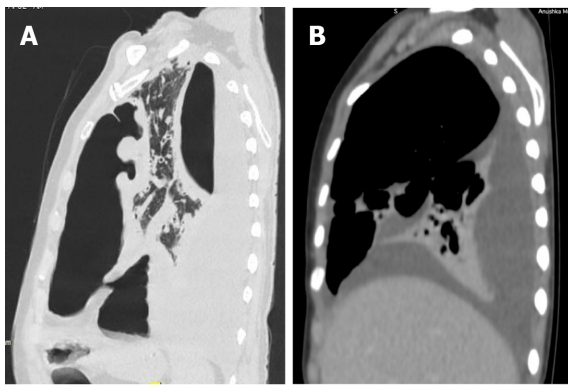
Figure 4 Ultrasound Biomicroscopy scanned at 50 MHz - Skin tuberculosis - lupus vulgaris. A well-defined reddish-brown plaque with papulo-nodular borders is seen on the skin (black arrow), Ultrasound biomicroscopy (UBM) shows a well-defined heterogenous mass lesion in the dermis (up arrow-dotted), Histopathology shows a well-defined tuberculous granuloma in the dermis (white filled arrow), Follow up UBM after 6 mo of AKT shows marked decrease in the size of granuloma in the dermis (down arrow- dashed). Images Courtesy Dr. Bhatt K, UBM Institute & Sonography Centre, Mumbai.

significant X-ray dose reduction and improved image quality over conventional filtered back-projection reconstruction methods[58]. These advantages would enable greater use of CT in Molecular Imaging.

Magnetic Resonance Imaging

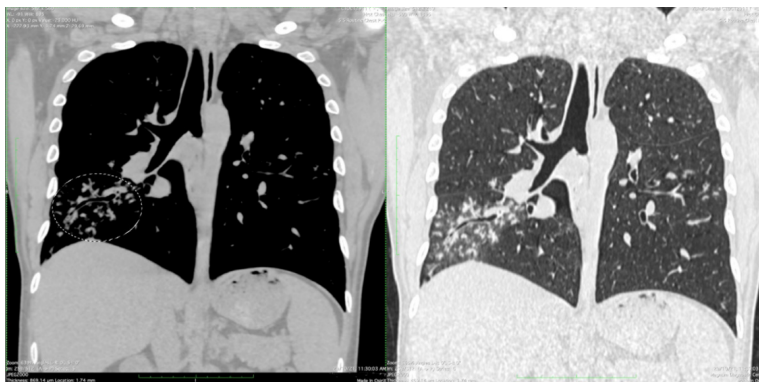
Magnetic resonance imaging (MRI) yields high soft tissue contrast and resolution with high sensitivity for detection of tissue necrosis, as occurs in TB[59]. While MRI lacks the ionizing-radiation hazard, it usually requires longer acquisition times. However, more recently, short-sequence lung MRI (such as HASTE T2, BLADE T2, TRUFI T2 and VIBE T1) have been used for pulmonary imaging in TB patients [60]. Cardiac MRI has made rapid progress too and is the ideal modality for diagnosing Cardiac TB.

Cardiac TB can take the form of Pericarditis, Peri-Myocarditis or a Pancarditis. Pericardial TB is the commonest manifestation of Cardiac TB (Figure 8A and B). In its early form it is seen as pericardial thickening. In advanced cases, pericardial effusion and septations are seen. Accompanying para-spinal



DOI: 10.4329/wjr.v14.i6.114 Copyright © The Author(s) 2022.

Figure 5 Tuberculous pyo-pneumothorax. A: Sagittal high-resolution computed tomography image in lung window showing a thick-walled cavity communicating with the left pleural space. A large loculated collection in the left pleural space showing air-fluid level; B: Sagittal image in a mediastinal window showing a Right pleural effusion with partial collapse of Right lower lobe. Images courtesy Dr. Thakkar H, Prof & Head (Radiology), KEM Hospital, Mumbai.



DOI: 10.4329/wjr.v14.i6.114 Copyright © The Author(s) 2022.

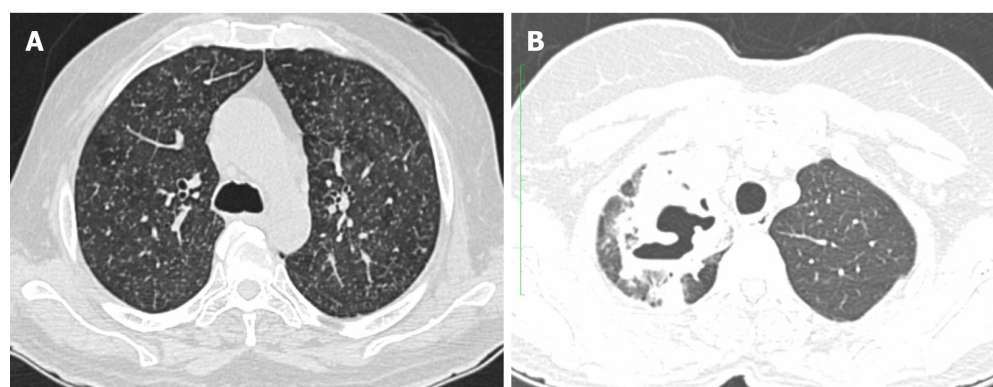
Figure 6 Endobronchial spread of tuberculosis. Coronal computed tomography images in mediastinal and lung windows; demonstrative of multiple discrete and confluent centrilobular nodules in the lateral basal segment of right lower lobe, some of which show V-Y branching pattern ("tree in bud appearance"- circled area). Enlarged mediastinal lymph nodes are also observed in the subcarinal region. Images courtesy Dr. Joshi A, Prof & Head (Department of Radiology), LTMMC & LTMGH, Mumbai.

abscesses and pleural effusions can easily be seen (Figure 8C). This may resolve on therapy or can undergo calcification. Myocardial TB is rare and in the presence of a myocardial mass lesion, can frequently be misdiagnosed as a neoplasm. The presence of associated diffuse or non-contiguous pericarditis in the presence of myocardial masses is a good pointer to TB etiology of the cardiac masses: The 'Myocarditis - Pericarditis Complex' sign[61] (Figure 9). In a case series of 11 Cardiac TB cases imaged on a 3 Tesla MRI scanner, myocardial lesions were seen in 6 cases (55%) and all of them had concomitant (either diffuse or non-contiguous) pericardial involvement[61]. This is in keeping with the etiopathogenesis of myopericarditis in Cardiac TB. Greater awareness about the "Myopericarditis-Pericarditis Complex" sign/when added to Cardiac AI diagnostic protocols/algorithms, can save the patient from unnecessary invasive tests / cardiac biopsies.

Additionally, novel modalities, such as MR spectroscopy (MRS), chemical exchange saturation transfer (CEST) contrast, Amide Proton transfer imaging and dynamic contrast-enhanced imaging can detect physiological or metabolic changes without the need of exogenous agents. In animal models, these novel MRI capabilities differentiated bacterial infections from sterile inflammation or oncological processes[62,63].

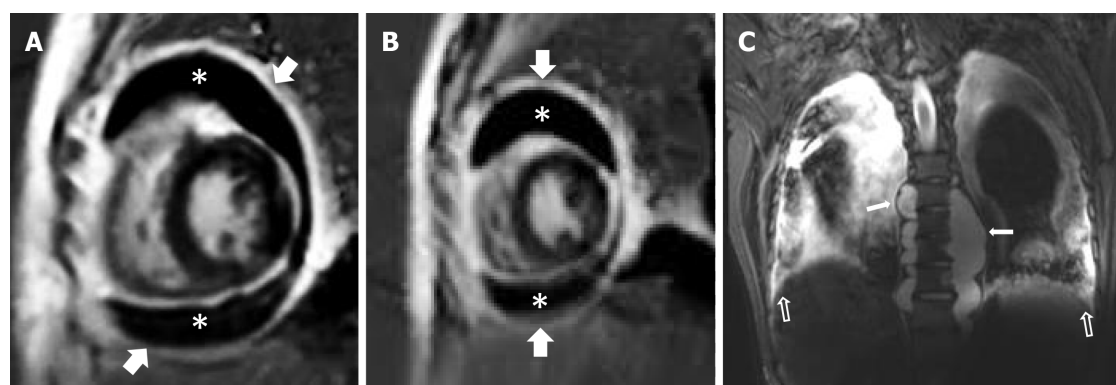
Low-field MRI: Though currently still under development, low-field-strength (and lower-cost) MRI (0.5 T vs 1.5 or 3 T for typical scanners), coupled with state-of-the-art hardware, is being evaluated for high-quality imaging lungs and heart[64].

MR spectroscopy: MR spectroscopy (MRS) allows imaging of biochemical processes using endogenous metabolites (*e.g.*, choline, creatine, lactate) or substances labelled with exogenous nuclei such as ^{19}F and ^{13}C . MRS can be performed with most clinical MRI scanners, but multi-voxel MRS scanners are preferred for their greater coverage and resolution. Morales *et al*[65] reported that a singlet peak at ~3.8 parts-per-million (ppm) is present in most tuberculomas and absent in most malignant tumors, allowing



DOI: 10.4329/wjr.v14.i6.114 Copyright © The Author(s) 2022.

Figure 7 Tuberculosis sagittal computed tomography. A: Miliary tuberculosis: Axial high-resolution computed tomography (HRCT) image in lung window demonstrates miliary nodules scattered in both lungs; B: Tuberculous cavity: Axial HRCT image in lung window showing a thick-walled cavity in the apical segment of the right upper lobe. Images courtesy Dr. Joshi A, Prof & Head (Department of Radiology), LTMMC & LTMGH, Mumbai.



DOI: 10.4329/wjr.v14.i6.114 Copyright © The Author(s) 2022.

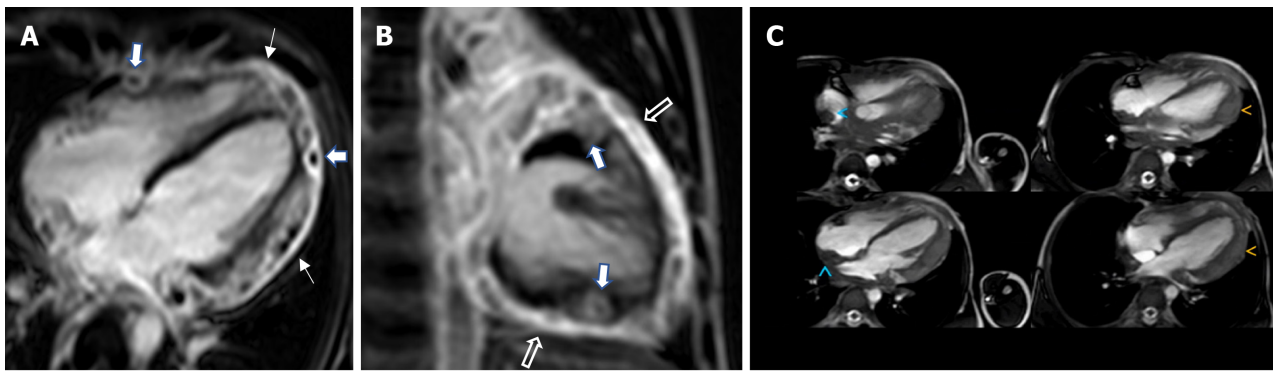
Figure 8 Tuberculous pericarditis and pericardial effusion: 3 Tesla Cardiac magnetic resonance imaging. A and B: PSIR (short axis view) images shows enhancing pericardial thickening (arrow) and moderate distension of pericardial space with hypointense fluid (asterisk); C: Coronal STIR dorsal spine: Paraspinal abscesses (white arrow -filled) with concomitant pleural effusions (white arrow- unfilled).

differentiation between these lesions.

CEST contrast MRI: CEST contrast MRI uses compounds containing exchangeable protons or molecules in concentrations too low to be visualized using standard MR imaging, with gadolinium substituted by alternative metals, such as manganese, lanthanides, or iron-based agents[66,67]. CEST agents can be diamagnetic or paramagnetic[68]. *Diamagnetic* agents create relatively small chemical shift differences (within 5 ppm of the water signal) that limit the observed effect per injected agent dose. *Paramagnetic* (PARACEST) ions induce much larger shifts, up to a few hundred ppm, thus allowing much shorter proton lifetimes. PARACEST can be single metal-containing chelates (*e.g.*, lanthanides), dendrimers, supramolecules, and liposomes.

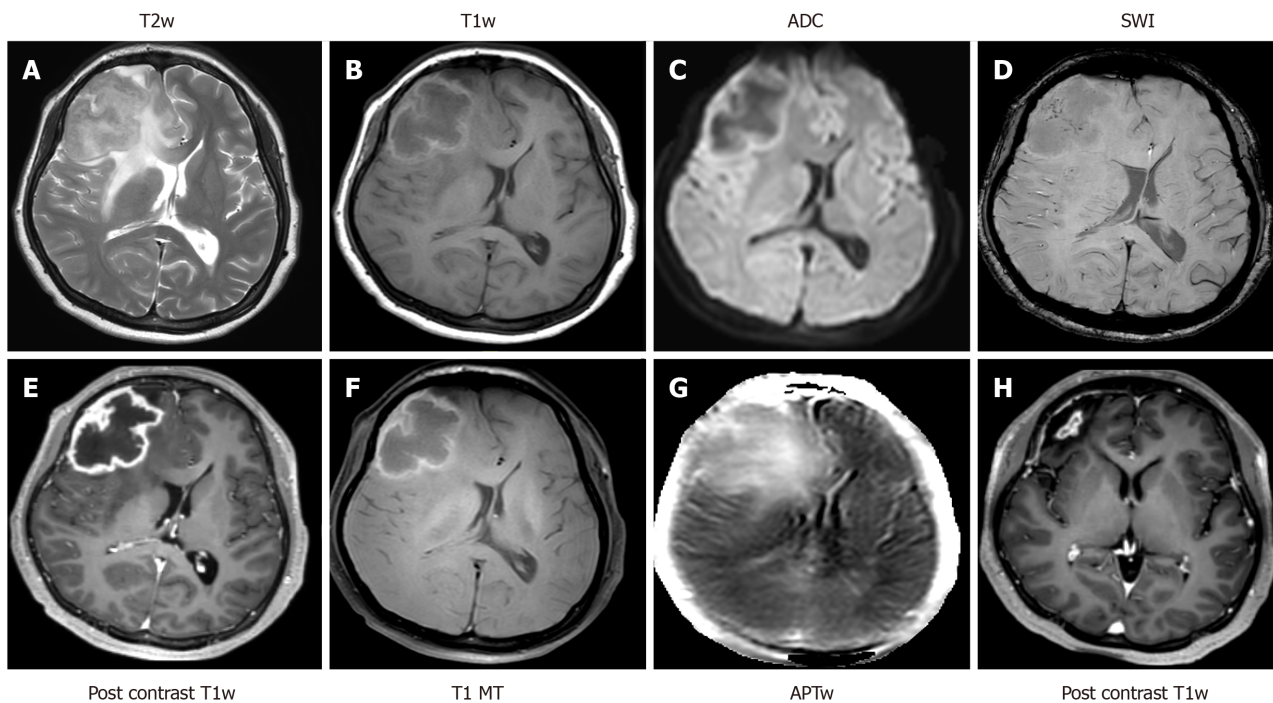
Amide proton transfer: Building on the principles of CEST and Magnetization Transfer (MT), amide proton transfer (APT) imaging generates tissue contrast as a function of the mobile amide protons in the tissue's native peptides and intracellular proteins (Figure 10). Tuberculomas demonstrate lower MT ratios (MTR_{asym}) compared to High Grade Gliomas, reflective of a relative paucity of mobile amide protons in the ambient microenvironment. Elevated MTR_{asym} values in the perilesional parenchyma of tuberculomas are a unique observation that may be a clue to the inflammatory milieu[69].

MR elastography: Rapid progress has been noted in the utilisation of MR elastography (MRE), which includes the evaluation of alternatives to the expensive and invasive 'liver biopsy option' for assessing liver fibrosis in patients. Hepatic fibrosis is a known complication of TB medications (ATT) (Figure 11) [70]. Imajo *et al*[71] reported that MRE and US shear wave elastography (2D-SWE) demonstrated excellent diagnostic accuracy in detecting liver fibrosis in patients. They reported that MRE demonstrated the highest diagnostic accuracy for stage 4 fibrosis detection and intra - and inter-observer reproducibility[71]. MRE has the potential to be applied to detection of TB fibrosis in other



DOI: 10.4329/wjrv.14.i6.114 Copyright © The Author(s) 2022.

Figure 9 Cardiac tuberculous myo-pericarditis - 'the myocarditis-pericarditis complex - a sign of cardiac tuberculosis': 3 tesla cardiac magnetic resonance imaging. A: PSIR (4 chamber view -4CH) images shows enhancing pericardial thickening (thin arrow) and peripherally enhancing nodules in the subepicardial myocardium (thick arrow); B: PSIR (VLA view) - Thickened enhancing pericardium (unfilled arrow) with multiple nodular lesions (filled arrow) involving the myo-pericardium; C: Cine 4CH view: Diffuse pericardial thickening (<). In addition, nodular wall thickening (<) of the atria, and the interatrial septum is noted. (The patient was 10-year-old boy with a 2-mo h/o fever and chest pain and responded to anti-tuberculosis medications- regression of the lesions noted).

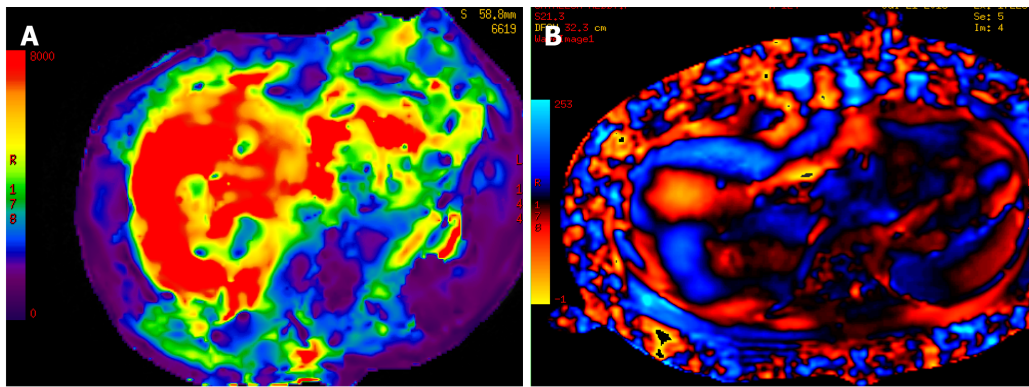


DOI: 10.4329/wjrv.14.i6.114 Copyright © The Author(s) 2022.

Figure 10 Magnetic resonance imaging - tuberculoma. A: Axial T2-weighted imaging shows a variable T2 hypointense circumscribed mass lesion in the right anterior frontal region, with surrounding perilesional edema; B: T1 weighted imaging shows a peripheral T1 hyperintense rim; C: Apparent diffusion co-efficient map shows restriction of diffusion; D: Susceptibility weighted imaging demonstrates fine punctate intralesional foci of blooming; E: Post contrast T1 weighted imaging showing slightly irregular peripheral rim enhancement; F: T1 magnetization transfer images; G: Amide proton transfer weighted images show elevated magnetization transfer asymmetry in the periphery of the lesion; H: T1 post contrast imaging after completion of anti-tuberculosis treatment reveals significant reduction in the size of the previously seen ring enhancing lesion. APT: Amide proton transfer. Images courtesy Dr. Saini J, Professor, Neuroimaging & IVR, NIMHANS, Bangalore.

organs too, *e.g.* kidney: Including for treatment-response assessment and monitoring of sequelae, as fibrosis is a common manifestation in TB, including during healing[38]. This could be extremely vital in TB ureteric strictures which need to be stented, as they will heal by fibrosis (with treatment); and could result in serious damage/function loss of the affected kidney, if left unstented.

Advances in MR hardware and software: The development of sequences, arrays of coils, k-space strategies, stochastic imaging, and machine learning (ML)-based image analysis procedures will provide numerous opportunities to improve image contrast in MRI[72,73]. MRI sequences and post-processing techniques may replace or decrease the use of contrast agents (for example 4D MRI instead of MRA and CEST imaging); hybrid technologies such as positron emission tomography (PET)/MR may rely on



DOI: 10.4329/wjrr.v14.i6.114 Copyright © The Author(s) 2022.

Figure 11 Post tuberculosis medication liver fibrosis on magnetic resonance elastography. A: Color elastogram of liver with a 0-8kPa scale shows the stiffness distribution in organs for qualitative evaluation. Red or orange regions have higher stiffness values, whereas blue and purple regions are depictive of lower stiffness values. Severe Liver fibrosis is noted - 8.1kPa; B: Wave image of liver shows excellent wave propagation anteriorly and laterally. Low amplitude waves with wave distortion observed in segment VII and II of liver. Images courtesy Dr. Bhaskar N, Vista Imaging Centre, Bangalore.

radiotracers in lieu of MR contrast agents[74].

Nuclear imaging, fusion imaging and miscellaneous

Nuclear imaging detects gamma-radiation produced by radioactive molecules administered non-invasively in micromolar quantities. If such molecules also have biological functions, one visualizes biological processes *in vivo* through functional **images** (at the cost of poorer anatomical resolution compared to CT/MRI/High-res US). Well-established for cancer management, molecular imaging may soon have potential for infectious disease[75].

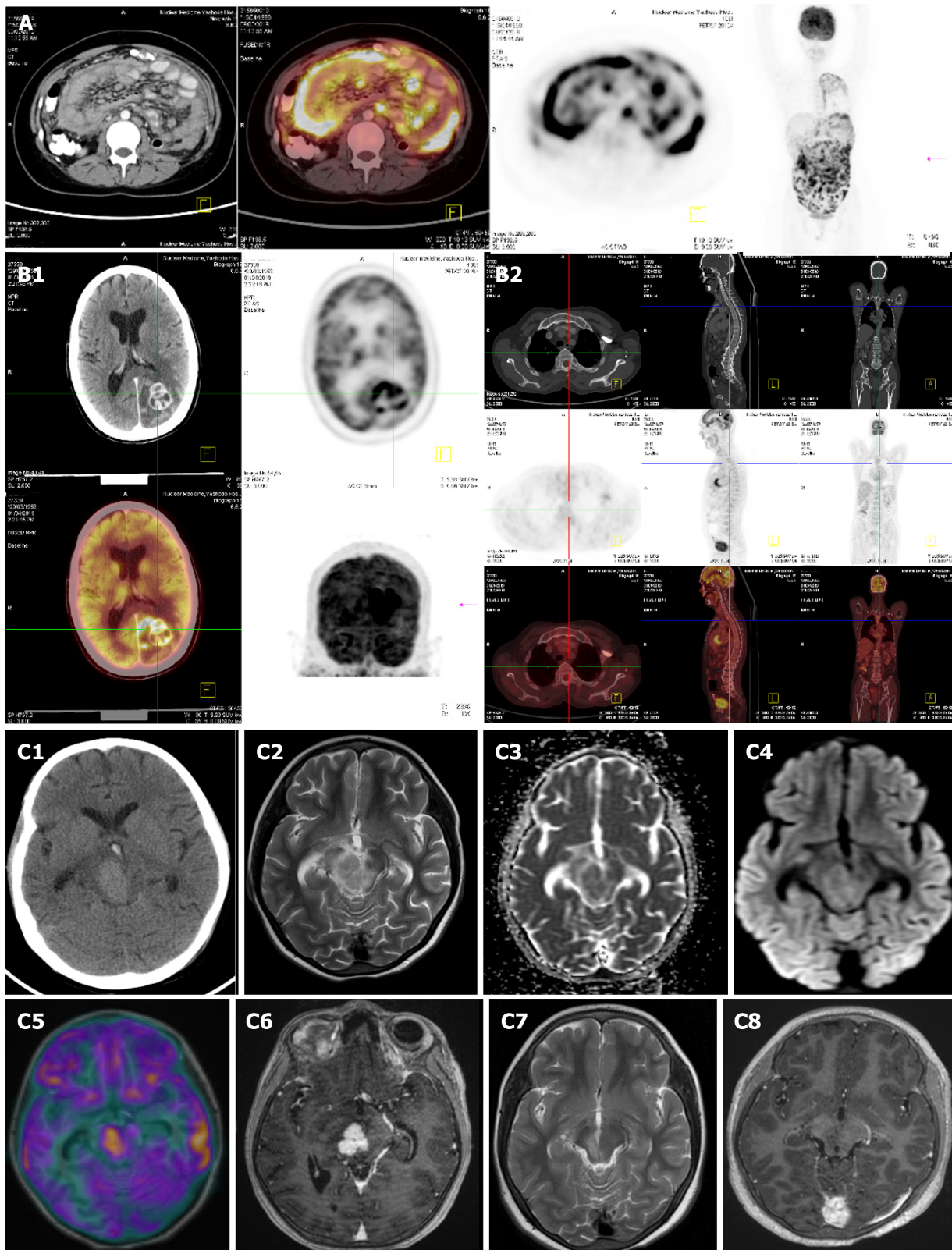
PET: PET uses radionuclides that decay *via* positron emission relatively quickly (*e.g.*, 18-Fluorine and 11-Carbon have half-lives of 110 and 20 min) and require an on-site cyclotron to make the radionuclides on demand before they decay. Single-photon emission computed tomography (SPECT) uses longer-lived radionuclides (99-metastable-Technetium and 123-Iodine have half-lives of 6 and 13.2 h). In either case, gamma radiation is converted by semiconductor detectors into electrical signals which are then reconstructed as 3D tomographic images.

Pathogen-specific PET imaging agents: Pathogen-specific PET imaging agents currently in development, could provide more accurate data on bacterial burden and other longitudinal information on infection dynamics and treatment responses[76,77].

Fusion imaging: PET CT (Figure 12A and B) and PET MR (Figure 12C) combines functional imaging (PET, SPECT) for pharmacokinetic/ metabolic information with anatomic imaging (CT, MRI) for structural detail. This permits repeated studies in the same subject over time, a fundamental advantage over traditional techniques. Data thus obtained can be supplied to mathematical models of disease progression, which represents a major advance for the field that has primarily relied on snapshots to understand TB[75]. A small study in adults with MDR-TB, 18F-Fluoro-deoxyglucose (18-FDG) PET plus CT showed quantitative changes in computed abnormal volumes at 2 mo into the treatment that predicted long-term treatment success more sensitively than conventional sputum microbiology, suggesting the potential of imaging scans as possible surrogate endpoints in clinical trials of new TB drug regimens[78]. TB reactivation risk in animal models and human subjects has been accurately identified through 18F-FDG PET/CT[79-81].

Explorer total-body PET: This device's increased sensitivity ($\times 40$) allows PET scans at extremely low radiation doses while improving the scan speed (potentially in less than a minute) and can track radiopharmaceuticals for longer periods after injection[82]. Although MDR-TB poses mortality risks comparable to those of many common cancers, radiopharmaceutical imaging, while accepted for cancer workup, is oddly avoided for infectious diseases[83]. Explorer total-body PET could allow increased PET use in both pediatric and adult patients with infectious diseases and would be very useful for assessing the extent of TB, especially when involving multiple sites, including the response to treatment [84-86].

SPECT: A rotating gamma camera captures energies from labelled molecules, which decay *via* the emission of single gamma rays. Most cameras produce 2D images, although some can perform tomographic 3D reconstructions. Foss *et al*[87] have designed a monoclonal antibody mAb 3d29 that can be used to detect and localize areas of infection with *M. tuberculosis* non-invasively, on SPECT, 24 h



DOI: 10.4329/wjr.v14.i6.114 Copyright © The Author(s) 2022.

Figure 12 Fusion imaging. A: Fluoro-deoxyglucose (FDG) positron emission tomography (PET)/computed tomography (CT) Abdominal tuberculosis: 55-year F - h/o loss of weight with mild abdominal pain on and off gradually increasing (for 4 mo). Low grade evening rise of fever. Whole body PET CT showing irregular peritoneal thickening with nodularities and cocoon formation. PET and fused PET-CT images showing significant amount of uptake with SUV max of 12.3; B: Whole body FDG-PET/CT - Brain Tuberculomas: 45 years male - h/o seizures for 5 mo, gradually increasing in frequency. PET-CT advised for the possibility of metastases; B1: Whole body FDG-PET/CT done showing irregular ring enhancing lesions in the brain with peri-lesional edema. PET and fused PET-CT images showing significant amount of uptake with SUV max of 14.8; B2: There is no other abnormal uptake in the entire body. (Normal myocardial uptake and left axillary vessel uptake is noted); C: Fusion imaging (MR-PET): Tuberculoma with Rubral tremor. 12-year-old girl presented with right 3rd and 4th cranial nerve palsy along with rhythmic to and fro left 'shoulder joint tremor' which worsened with movement; C1: Axial non-contrast CT image demonstrates a well circumscribed hyperdense mass

lesion within the right half of the midbrain; C2: T2-weighted imaging shows variable T2 hypo intensity within the lesion; C3 and C4: Diffusion weighted imaging and apparent diffusion co-efficient maps reveal restricted diffusion within the lesion; C5: Fusion imaging (T1W and PET) demonstrates avid glucose uptake within the lesion; C6: Post contrast T1 weighted imaging with fat saturation, reveals intense nodular enhancement. Stereotactic biopsy of the lesion revealed granulomatous inflammatory pathology; C7 and C8: After completion of anti-tuberculosis treatment, resolution of the granulomatous lesion with residual gliosis was observed on T2 weighted and Post contrast fat saturated T1w images. Images (A & B) courtesy Dr. Sikander Shaikh, Consultant radiologist, Yashodha Hospital, Hyderabad & Image (C) courtesy Dr. Saini J, Professor, Neuroimaging & IVR, NIMHANS, Bangalore.

after radiotracer injection.

Optical imaging: Optical Imaging provides high-resolution (*e.g.*, single-cell resolution) live imaging in small animal models and has provided very valuable insights into various biological processes (*e.g.*, TB granuloma formation)[32,88]. It is performed with highly sensitive fluorescent or bioluminescent agents. However, the use of low-energy photons means that the depth of penetration is limited to only a few centimetres. These could be used for superficial pathologies *e.g.*, cervical lymph nodes, including their complications (TB lymphadenitis, including collar-stud abscess *etc.*).

Advances in ex vivo molecular imaging and microscopy

Including autoradiography, fluorescence microscopy, fluorescence life-time imaging microscopy (FLIM), matrix assisted laser desorption/ ionization mass spectroscopy imaging (MALDI/MSI): Visualization of molecules based on mass detection. MALDI/MSI can simultaneously detect multiple compounds and provides high spatial resolution. Quantum Microscopy (improving the speed and sensitivity of Raman Scatter Microscopy (SRS); visualizing structures that would otherwise be impossible to see.

The molecular imaging techniques discussed below offer potential for cutting-edge research into the cellular mechanisms of TB. While autoradiography and Fluorescence Microscopy are long-established molecular imaging methods, the newer techniques use different modalities and/or extended study in living tissue.

FLIM: Performed *in vivo* with highly sensitive fluorescent or bioluminescent agents provides high-resolution (*e.g.*, single-cell resolution) in small animal models, allowing visualization of various biological processes (*e.g.*, TB granuloma formation)[32,88,89]. However, the use of low-energy photons limits the depth of penetration to a few centimeters. These could be used for superficial pathologies *e.g.*, cervical lymph nodes, including their complications (TB lymphadenitis, including collar-stud abscess, *etc.*).

Multiphoton intravital microscopy: Multiphoton intravital microscopy (MP-IVM) is based on the simultaneous absorption of two or more (near-) infrared photons. It allows visualization at single-cell resolution within a depth of a few millimeters. Murooka *et al*[90] used MP-IVM to monitor lymphocyte motility in lymph nodes of mice.

Matrix assisted laser desorption/ ionization mass spectroscopy imaging: This visualizes molecules based on mass detection. MALDI/MSI can simultaneously detect multiple compounds with high spatial resolution. It has been used to localize mycobacterial biomarkers and TB drugs in infected tissue[89]. MALDI-MSI can localize multiple molecules (*e.g.*, drugs, metabolites, lipids, proteins) simultaneously, overlaying them onto histologically stained sections to reveal the spatial distribution of each molecule with subcellular resolution[89,90]. MALDI-MSI can also be applied to archived tissue blocks dating back decades[91]. This would be a great boon for research, including retrospective studies.

The transition from anatomical imaging to functional/molecular imaging now allows integration of imaging data with various levels of “omics” data (genomics, metabolomics, proteomics, and pharmacogenomics). This may open new avenues for predictive, preventive, and personalized medicines[58].

Quantum microscopy: Quantum Microscopy has been utilized for improving the speed and sensitivity of SRS microscopy; visualizing structures that would otherwise be impossible to see. Casacio applied squeezed states of light in SRS, developing a quantum-enhanced-microscope[92]. This enhancement allowed for resolution of the cell membrane which could not be seen on a conventional microscope and sub-micron spatial resolution and the improved image contrast and reduced imaging time surpassed the current state-of-the-art Raman microscopes, while avoiding photodamage in the sample.

MOLECULAR MECHANISMS IN TB

Role of vitamin D

Another addition worth considering is the humble Vitamin D, which was used to treat TB in the pre-

antibiotic era[93]. Serum levels of 25-hydroxy-cholecalciferol (25-OH-D3) in TB patients have been shown to be lower than in healthy controls[94]. The vitamin D-cathelicidin pathway regulates the autophagy machinery, protective immune defenses, and inflammation; and contributes to immune cooperation between innate and adaptive immunity[95]. Vitamin D activates macrophages and restricts MTB's intracellular growth[96]. In monocytes and macrophages, MTB lipoprotein binds to the TLR2/TLR1 heterodimer (TLR = Toll-like receptor): this increases vitamin D receptor expression and processing of the pro-vitamin D precursor, which in turn increases production of a mycobactericidal peptide[94]. Vitamin D supplementation during TB treatment accelerates sputum smear conversion and hastens resolution of inflammatory responses[97].

A systematic review (Sutaria *et al*[98]) evaluated 21 randomized, controlled trials and concluded that: (1) TB patients had lower vitamin D status (lower serum levels of 25-OH-D3 than healthy, age-matched, and sex-matched controls) [99]; (2) People with certain Vitamin D receptor polymorphisms (BsmI and FokI) had increased susceptibility to TB; and (3) TB patients receiving vitamin D supplementation had improved outcomes in most studies, including shortening treatment duration[98,100]. Vitamin D deficiency may adversely influence TB re-activation/ re-infection: lowered 25-OH-D3 Level leads to a fall in cell-mediated immune defenses, which can activate latent tuberculosis[101]. Hence, it would be worth checking and restoring 25-OH-D3 Levels in malnourished TB patients[102].

Epigenetics perspective

Epigenetics refers to heritable changes in DNA function caused by environmental factors, without altering the DNA sequence, through mechanisms such as DNA (de)methylation (methylation typically deactivates genes) and histone modification (DNA is inactive when tightly bound to histone proteins.) MTB is known to cause histone changes in immune cells that inactivate the defensive IL-2V gene (IL=interleukin), improving MTB's survival chances[103]. Gauba *et al*[104] review various MTB-induced epigenetic mechanisms. In their review, they have unravelled the numerous ways by which MTB reshapes the host epigenetic landscape as a strategy to overpower the host immune system, for its survival and persistence.

The degree of methylation of key genes in the vitamin D metabolic pathway influence risk and prognosis of tuberculosis[105]. Here's where Vit D supplementation can play a vital role in protecting against TB and in complimenting Anti TB therapies. Understanding the inter-talk between MTB and epigenetic mechanisms will also play a vital role in controlling/ eliminating the scourge of TB[106]. Analysing epigenetic changes offers great potential in the diagnosis, prevention, and treatment strategies for a wide range of diseases, including TB. CRISPR interference (CRISPRi) has been utilized in mycobacteria to identify novel drug targets by the demonstration of gene essentiality. Faulkner *et al*[107] used CRISPRi to study genes involved in mycobacterial antibiotic resistance, restoring Rifampicin sensitivity in *M. smegmatis* with CRISPR. This offers hope for the future - for the creation of epigenetically modified Anti -TB drugs to treat MDR and XDR TB.

ADVANCES IN COMPUTING

We discuss these advances under two broad categories, software (*e.g.*, Artificial Intelligence, Augmented and Virtual Reality) as well as Hardware Innovations.

Artificial intelligence applications in TB

Increasing Internet bandwidth, coupled with transparent data security, has advanced telemedicine, so that remote diagnosis is now routine. Diagnosis can be assisted by Artificial Intelligence (AI). An important AI sub-field, ML, uses statistical techniques, rather than explicitly encoded insight from human experts, to detect patterns in (often considerable) volumes of data. ML allows classification (*e.g.*, diagnosis) or making predictions. A rapidly progressing branch of ML, called multilayer neural networks or "Deep Learning" (DL), can increase speed and accuracy of onsite and remote diagnosis. DL algorithms have already been used to detect features consistent with pulmonary TB in CXR and CT scans[108].

However, "Artificial Intelligence needs Real Intelligence to guide it!" To maximize AI applications' accuracy and utility in medical diagnosis and treatment modalities, AI must incorporate experiential wisdom accumulated over decades of clinical and radiological experience time, namely time-tested key medical 'teaching' and/or key 'clinical' parameters, including prognostic indicators.

TB is no exception. Take childhood (< 15 years) pulmonary TB, which represents 12% of new cases, but 16% of the estimated 1.4 million deaths[109]. This higher mortality highlights the urgent need to improve case detection, and to identify children without TB disease eligible for preventive treatment. One strategy is systematic screening for tuberculosis in high-risk groups[109]. Early diagnosis and prompt treatment will prevent spread to other children at school or in community settings, especially in resource-limited settings[109]. Imaging algorithms can thus play an important role in screening strategies.

The TB Primary Complex (Ghon's focus, draining lymphatics and hilar node/s) is very common in developing countries. However, inexperienced radiologists find it challenging to identify it in children on CXR, partly because the relatively prominent pulmonary arteries obscure the hila. However, co-occurrence of pleural effusion simplifies identification, because "classical" pleural effusions, especially of the lamellar type (tracking along the pleura, mimicking pleural thickening) (Figure 1) are relatively uncommon in children due to non-TB causes. A Childhood TB diagnosis algorithm using this information would gain in specificity. Similar considerations apply to Adult TB. Patients with "Open Kochs" (lung cavities or smear positive) (Figure 7B) are far more contagious and require isolation: including these factors in analysis/algorithms enables more effective screening/control/management [27].

While DL excels at recognizing individual patterns (most artificial-vision applications use it), higher-level knowledge of key imaging and clinical signs allows integrating the individual patterns into a diagnosis. Such "Holistic" algorithms that integrate all the available information-not just on a single patient, but also molecular and epidemiologic knowledge-can significantly improve not only early detection of TB, including MDR-TB, but more effective management and significant improvement in healthcare outcomes.

Augmented reality and Virtual reality

Virtual reality creates entirely synthesized 3-D environments, while augmented reality (which is technically simpler to create and often more practical) superimposes synthesized content on existing environments, typically under user control. Both are potentially valuable for teaching/simulation and in clinical practice/patient education, by providing novel visualizations. Clinicians/radiologists could walk the patient through their own body to explain the disease, intended intervention, and anticipated post-intervention changes. Such immersive experiences could likely ensure greater compliance with the treatment regimen.

Distributed computing

We introduce distributed computing (DC) because many AI problems, such as would address TB, require computing power that single computing units cannot provide; including data housed in computers at diverse geographical locations. In DC, a computational problem is tackled by multiple, communicating, computing units. It has the following characteristics: (1) The units may lie within a single organization (connected by a local area network) or be distributed geographically (connected by the Internet); (2) Typically, a subset of units (often, just one "central" unit) may operate as either "coordinators" that control/direct other "peripheral" units, or provide resources (e.g., data, computing services) to them; (3) The central units typically have far more CPU power and storage capacity than the peripheral units. In the extreme case, the peripherals may be devices like smartphones, or even single-purpose sensors (e.g., for continuous glucose or EKG monitoring); (4) The central units' upkeep requires skilled/expensive personnel. In Cloud Computing, the units' housing/maintenance are outsourced to a "cloud vendor" (Amazon, Microsoft, Google, etc.). The available services can be scaled up or down in each billing cycle based on the customer's requirements. The term "cloud" indicates that the central unit is "out there", its physical location transparent to customers: location may even change; and (5) A single central unit can pose a bottleneck if thousands of small devices connect to it, especially over a sluggish Internet. Edge Computing enhances cloud computing by interposing intermediary units between the peripherals and central units[110]. The Edge units are physically close to the peripherals at a given geographic location (*i.e.*, at the "Edge" of a network diagram). They prevent overwhelming of the central unit, reduce overall network traffic by aggregating inputs from the peripherals and also provide some computing resources.

Federated ML: ML in general, and DL specifically, need lots of data (as well as diverse data from multiple geographic locales) to achieve the desired accuracy. "Big-data" solutions naturally suggest themselves. However, the obvious solution, physical pooling of data, faces the following barriers: (1) Data privacy - which is less of an issue with all forms of digital imaging, where DICOM metadata containing identifiable information can be removed; and (2) Mistrust - a formidable hurdle when academic or commercial consortia bring rivals together.

The technique of *Federated Learning* (FL), originally pioneered by Google as an application of their well-known MapReduce algorithm allows iteratively training an ML model across geographically separated hardware: the ML algorithm is distributed, while data remains local[111,112]. It can be employed for both statistical and deep learning.

Typically, a central server coordinates computations across multiple distributed clients. At start-up, the server sends the clients initialization information. The clients commence computation. When each client is done, it sends only aggregate results back to the server, not detailed or identifiable data elements. The server collates all clients' results and sends updates to each client, which then computes again. The process continues until the ML training completes convergence.

Ng *et al*[113] provide a detailed technology overview. Sheller *et al*[114] use FL to replicate prior analysis of a 10-institution brain-tumor-image-dataset derived from The Cancer Genome Atlas (TCGA). Navia-Vasquez *et al*[115] describe an approach for Federated Logistic Regression.

Most important, many AI algorithms can run in FL mode, making them more accurate because they are based on more voluminous and diverse data. This increases the scope for Multi- Institutional/Multi-city collaborations. Dashboards augmented with these algorithms' can aid key organizational decision-makers to identify trends (including epidemiological), communicate vital information and monitor performance against strategic goals. Better information through technology-assisted developments would aid WHO, UNICEF and other such organizations counter/eliminate the scourge of TB worldwide. While FL works around institutional barriers, one pays a cost in computational speed, which is limited by Internet bandwidth. In almost all cases, this tradeoff is worthwhile.

Quantum technology

"Quantum" technology refers to a highly diverse set of technologies that leverage "quantum mechanics", the physics of sub-atomic particles. Some of these are established, such as scanning tunneling microscopy and photoionization, while others are still largely theoretical, or in the prototype stage[116]. Quantum Computers and Quantum microscopes, new quantum repeaters enabling a scalable super secure Quantum Internet (distance will no longer be a hindrance, not just IOT but 'Intelligent Edge' devices commonplace); will give a quantum boost to Medical Imaging/other health-care Algorithms/strategies, including in other related fields, improving healthcare in ways beyond the realm of dreams[117].

Quantum entanglement microscopy: Quantum entanglement (QE) occurs when a group of particles are generated and interact with each other so that each particle's sub-atomic (*i.e.*, quantum) state cannot be described independently of the others' state. Originally postulated in 1935 by Einstein, Podolsky, and Rosen, it led to seemingly bizarre predictions if true. For example, if one particle encountered an object (*e.g.*, a bacterium), the other particles would reflect this interaction instantaneously - even if the particles were at opposite ends of the universe, violating General Relativity's prediction that faster-than-light interactions are impossible. Such predictions led Einstein to believe that Quantum Theory was erroneous: However, QE was demonstrated experimentally almost eight decades later.

With QE using confocal "differential interference contrast," standard microscopy wavelengths, *e.g.*, visible light or ultraviolet (UV), provides much higher resolution than without QE, demonstrated by Ono *et al*[118]. QE achieves such detail using much less light (useful for light-sensitive micro-organisms or living tissues when UV is employed). A quantum optical counterpart has been developed to the classical Fourier-transform infrared spectrometer[119]. "Quantum ghost imaging" produced the world's first 2D image captured and reconstructed using asynchronous detection. Ghost imaging is well suited to biological and medical applications, in which light-sensitive cell samples can be observed over a long period because the new processes use less light[120]. QE microscopy may thus impact TB research and diagnosis.

Quantum computing: Quantum computing (QC) relies on the possibility of keeping a collection of "qubits" (quantum bits) stable long enough to perform computations with. While a bit (the smallest unit of information in a traditional computer, 1 Byte = 8 bits) can be either 1 or 0, a qubit can be both 1 and 0 simultaneously: thus, 32 qubits can represent 2^{32} approximately equal to 4 billion possibilities. Conceived by Nobelist Richard Feynman, QC's theoretical foundations were strengthened after Peter Shor's work ("Shor's[121] Algorithm) showed that QC could achieve exponential speedup for extremely compute-intensive problems like factorizing the product of two large prime numbers, the basis of RSA (= Rivest, Shamir, Adelman) encryption. Building a practical Quantum Computer, however, is challenging. Qubits are most stable at very low temperatures (*e.g.*, 0.025 Kelvin), and most Qubits in a computer perform error correction rather than computation. However, QC is showing remarkable progress - entangling qubits that could improve error correction in quantum computing, creation of a third state to qubits, to create 'qutrits' that allow more information to be encoded in a single element and decrease readout errors significantly, development of a high-performance source of "squeezed light" used to transmit information in optical quantum computing; all signify a quantum leap in the technology; with the last being a paradigm shift[122-124]. Optical Quantum computers can now be expected to run at room temperature, without the expensive cooling equipment needed for other quantum computers that use superconductors.

A recent simulated quantum algorithm by Case Western Reserve University and Microsoft scientists (it would have required a quantum computer with 1 million computing qubits) addressed Magnetic Resonance Fingerprinting (MRF)[125]. MRF goes beyond MRI in identifying signatures from individual tissues simultaneously.

If QC's hardware challenges are solved (there is no clear-cut timeline for this) the impact on general computing, including AI-deep learning, under the hood, performing mathematical optimization-could be extraordinary. Almost all aspects of healthcare would benefit: TB diagnosis and disease modeling would definitely be a part of it. As quantum computers are also ideally suited for solving complex optimization tasks and performing fast searches of unsorted data, this could be relevant for many applications in healthcare related to TB; medical imaging, epidemiological simulations, dashboard creation, holistic algorithm creation, targeted policy making, to a host of other applications; including the realm of Quantum Artificial Intelligence, which offers unlimited possibilities, including many

presently undreamable/unthinkable ones. Researchers have now suggested that neuromorphic or brain like computers built using memristors (these resemble neuronal synapses) would perform well at running neural networks[126]. Scientists in Austria and Italy have already developed a quantum version of the memristor that they suggest could lead to 'quantum neuromorphic computers', which in turn could lead to an exponential growth in performance, in an ML approach known as 'reservoir computing' that excels at learning quickly; and may have a quantum advantage over classical reservoir computing, due to the fact that the memristor, unlike any other quantum component has memory[127].

Thus, the Future looks great for QC (including QC based AI) contributing phenomenally to Medical Imaging and overall Healthcare as well. We can merely speculate at the potential applications of this yet 'Work in Progress' technology. The spectacular jump in overall computing power will enable hitherto unimaginable tasks to be done in a 'jiffy' and thus enable more complex tasks to be thought of. Quantum Artificial Intelligence Algorithms and the like will be something to look forward to. As and when QC evolves the Metaverse will give a more immersive experience both for teaching/simulation and during actual interactions; by giving visualizations/viewpoints that would otherwise not have been possible; with Augmented Reality/Virtual reality (especially for teaching/simulations *etc.*) offering tremendous potential for Medical Imaging in TB, community involvement, amongst other applications; to enable better compliance of TB guidelines and norms (refer the Augmented Reality &/Virtual Reality section above).

CONCLUSION

While we have discussed numerous technologies, which operate at scales ranging from the subatomic to human populations, the primary challenge for employing these to eliminate the scourge of TB is integrating them into a holistic approach. For example, AI cannot operate in a vacuum; it needs large volumes of data at the patient and population level: incorporating data also from novel imaging modalities, or from translational applications of bench-science research (*e.g.*, detection of resistance mutations through PCR, augmented optionally by CRISPR), will make it much more useful. The integration must be guided by policies developed by the coordinated actions of international consortia (including bodies like WHO, Big Pharma, national health ministries, philanthropists, *etc.*) that make use of diverse expertise around the globe, including those available through leading-edge technologies.

Below, we provide an outline for the implementation of such policies.

Prevention: In addition to current standard practices (besides the usual methods, nutrition, social norms *etc.*

Screening of vulnerable contacts/populations.

Screening for, and correction of nutritional deficiencies, including vitamin D.

Early diagnosis utilizing newer techniques/technological developments: *e.g.*, Gene-Xpert, TB QUICK *etc.*, for both 'regular TB' and MDR/XDR TB, including extrapulmonary samples.

Effective treatment, especially for MDR/XDR TB [including addition of recent drugs, shorter duration regimen (for better compliance)] + vitamin D for better healing as well as complimenting the action of various anti-TB drugs.

Effective monitoring including long term follow up coupled with development of large epidemiological data banks and dashboards that summarize the data therein to facilitate timely decision-making.

Enhanced Computing Infrastructure to facilitate all the above, from optimized data gathering, to more sophisticated algorithms, to more powerful hardware architectures.

The following is a useful acronym for the strategies we believe are vital to help us achieve the various targets set by the international health community for elimination of TB.

TB - REVISITED: Regular Screening / Remote patient monitoring; Early Diagnosis; Vitamin D levels/supplementation; Imaging and Investigations; Set up a Holistic Approach (Clinical/Imaging/Bacteriological); Intelligent comprehensive Holistic AI algorithms (+ wisdom *vs* knowledge); Technology - CBNAAT (GenXpert *etc.*)/National - Global Dashboards; Ensure a Global approach/Edge Computing; Do not delay the diagnosis of MDR-TB.

We believe that effective strategy implementation can help alleviate the suffering of millions of underprivileged citizens of the world.

ACKNOWLEDGEMENTS

We wish to thank Merchant N, MD, Diagnostic Radiologist, The Joint Department of Medical Imaging - Lecturer, Faculty of Medicine, University of Toronto, for assistance in preparing this manuscript.

FOOTNOTES

Author contributions: Merchant SA conceptualized the article; all authors wrote, read and approved the final manuscript.

Conflict-of-interest statement: All authors declare no conflict of interests for this article.

Open-Access: This article is an open-access article that was selected by an in-house editor and fully peer-reviewed by external reviewers. It is distributed in accordance with the Creative Commons Attribution NonCommercial (CC BY-NC 4.0) license, which permits others to distribute, remix, adapt, build upon this work non-commercially, and license their derivative works on different terms, provided the original work is properly cited and the use is non-commercial. See: <https://creativecommons.org/licenses/by-nc/4.0/>

Country/Territory of origin: India

ORCID number: Suleman Adam Merchant 0000-0001-6513-450X; Mohd Javed Saifullah Shaikh 0000-0002-5615-4813; Prakash Nadkarni 0000-0002-9628-4700.

S-Editor: Wang LL

L-Editor: A

P-Editor: Wang LL

REFERENCES

- 1 **WHO.** Global tuberculosis report 2020. [cited 20 January 2022]. Available from: <https://www.who.int/publications/i/item/9789240013131>
- 2 **WHO.** Global Tuberculosis Report 2021. [cited 20 January 2022]. Available from: <https://www.who.int/publications/i/item/9789240037021>
- 3 **Centers for Disease C and Prevention.** Emergence of Mycobacterium tuberculosis with extensive resistance to second-line drugs-worldwide, 2000-2004. *MMWR Morb Mortal Wkly Rep* 2006; **55**: 301-305 [PMID: 16557213]
- 4 **Salazar-Austin N,** Ordonez AA, Hsu AJ. Extensively drug-resistant tuberculosis in a young child after travel to India. *Lancet Infect Dis* 2015; **15**: 1485-1491 [PMID: 26607130 DOI: 10.1016/S1473-3099(15)00356-4]
- 5 **Kanabus A.** TB Statistics - 2020 - deaths, case notifications. [cited 20 January 2022]. Available from: [https://tbfacts.org/tb-statistics/\(2021\)](https://tbfacts.org/tb-statistics/(2021))
- 6 **United States AID.** [cited 20 January 2022]. Available from: <https://blog.usaid.gov/2017/>
- 7 **WHO.** Global strategy and targets for tuberculosis prevention, care and control after 2015. Sixty seventh World health Assembly: WORLD HEALTH ORGANISATION. [cited 20 January 2022]. Available from: https://apps.who.int/gb/ebwha/pdf_files/WHA67/A67_R1-en.pdf
- 8 **Dye C,** Glaziou P, Floyd K. Prospects for tuberculosis elimination. *Annu Rev Public Health* 2013; **34**: 271-286 [PMID: 23244049 DOI: 10.1146/annurev-publhealth-031912-114431]
- 9 **Lee JH,** Ammerman NC, Nolan S. Prospects for tuberculosis elimination. *Nat Commun* 2012; **3**: 753-753 [PMID: 22434196 DOI: 10.1038/ncomms1724]
- 10 **Comas I,** Borrell S, Roetzer A. Whole-genome sequencing of rifampicin-resistant Mycobacterium tuberculosis strains identifies compensatory mutations in RNA polymerase genes. *Nat Genet* 2011; **44**: 106-110 [PMID: 22179134 DOI: 10.1038/ng.1038]
- 11 **Jaleta KN,** Gizachew M, Gelaw B. Rifampicin-resistant Mycobacterium tuberculosis among tuberculosis-presumptive cases at University of Gondar Hospital, northwest Ethiopia. *Infect Drug Resist* 2017; **10**: 185-192 [PMID: 28652786 DOI: 10.2147/IDR.S135935]
- 12 **Piatek AS,** Van Cleeff M, Alexander H. GeneXpert for TB diagnosis: planned and purposeful implementation. *Glob Health Sci Pract* 2013; **1**: 18-23 [PMID: 25276513 DOI: 10.9745/GHSP-D-12-00004]
- 13 **WHO.** The shorter mdr-tb regimen. [cited 20 January 2022]. Available from: <https://apps.who.int/iris/bitstream/handle/10665/250125/9789241549639-eng.pdf>
- 14 **Mirzayev F,** Viney K, Linh NN, Gonzalez-Angulo L, Gegia M, Jaramillo E, Zignol M, Kasaeva T. World Health Organization recommendations on the treatment of drug-resistant tuberculosis, 2020 update. *Eur Respir J* 2021; **57** [PMID: 33243847 DOI: 10.1183/13993003.03300-2020]
- 15 **Ogwang S,** Mubiri P, Bark CM, Joloba ML, Boom WH, Johnson JL. Incubation time of Mycobacterium tuberculosis complex sputum cultures in BACTEC MGIT 960: 4weeks of negative culture is enough for physicians to consider alternative diagnoses. *Diagn Microbiol Infect Dis* 2015; **83**: 162-164 [PMID: 26239846 DOI: 10.1016/j.diagmicrobio.2015.07.002]
- 16 **Chavez Pachas AM,** Blank R, Smith Fawzi MC, Bayona J, Becerra MC, Mitnick CD. Identifying early treatment failure on category I therapy for pulmonary tuberculosis in Lima Ciudad, Peru. *Int J Tuberc Lung Dis* 2004; **8**: 52-58 [PMID: 14974746]
- 17 **Satti H,** McLaughlin MM, Seung KJ, Becerra MC, Keshavjee S. High risk of drug-resistant tuberculosis when first-line therapy fails in a high HIV prevalence setting. *Int J Tuberc Lung Dis* 2013; **17**: 100-106 [PMID: 23232009 DOI: 10.5588/ijtld.12.0344]
- 18 **WHO.** Multidrug and extensively drug-resistant TB (M/XDR-TB). 2010. [cited 20 January 2022]. Available from:

- http://apps.who.int/iris/bitstream/handle/10665/44286/9789241599191_eng.pdf?sequence=1
- 19 **Osei Sekyere J**, Maphalala N, Malinga LA, Mbelle NM, Maningi NE. A Comparative Evaluation of the New Genexpert MTB/RIF Ultra and other Rapid Diagnostic Assays for Detecting Tuberculosis in Pulmonary and Extra Pulmonary Specimens. *Sci Rep* 2019; **9**: 16587 [PMID: [31719625](#) DOI: [10.1038/s41598-019-53086-5](#)]
 - 20 **Helb D**, Jones M, Story E, Boehme C, Wallace E, Ho K, Kop J, Owens MR, Rodgers R, Banada P, Safi H, Blakemore R, Lan NT, Jones-López EC, Levi M, Burday M, Ayakaka I, Mugerwa RD, McMillan B, Winn-Deen E, Christel L, Dailey P, Perkins MD, Persing DH, Alland D. Rapid detection of Mycobacterium tuberculosis and rifampin resistance by use of on-demand, near-patient technology. *J Clin Microbiol* 2010; **48**: 229-237 [PMID: [19864480](#) DOI: [10.1128/JCM.01463-09](#)]
 - 21 **Perez-Risco D**, Rodriguez-Temporal D, Valledor-Sanchez I, Alcaide F. Evaluation of the Xpert MTB/RIF Ultra Assay for Direct Detection of Mycobacterium tuberculosis Complex in Smear-Negative Extrapulmonary Samples. *J Clin Microbiol* 2018; **56** [PMID: [29950333](#) DOI: [10.1128/JCM.00659-18](#)]
 - 22 **Dorman SE**, Schumacher SG, Alland D, Nabeta P, Armstrong DT, King B, Hall SL, Chakravorty S, Cirillo DM, Tukvadze N, Bablishvili N, Stevens W, Scott L, Rodrigues C, Kazi MI, Joloba M, Nakiyingi L, Nicol MP, Ghebrekristos Y, Anyango I, Murithi W, Dietze R, Lyrio Peres R, Skrahina A, Auchynka V, Chopra KK, Hanif M, Liu X, Yuan X, Boehme CC, Ellner JJ, Denking CM; study team. Xpert MTB/RIF Ultra for detection of Mycobacterium tuberculosis and rifampicin resistance: a prospective multicentre diagnostic accuracy study. *Lancet Infect Dis* 2018; **18**: 76-84 [PMID: [29198911](#) DOI: [10.1016/S1473-3099\(17\)30691-6](#)]
 - 23 **Mechal Y**, Benaissa E, El Mrimar N, Benlahlou Y, Bssaibis F, Zegmout A, Chadli M, Malik YS, Touil N, Abid A, Maleb A, Elouennass M. Evaluation of GeneXpert MTB/RIF system performances in the diagnosis of extrapulmonary tuberculosis. *BMC Infect Dis* 2019; **19**: 1069 [PMID: [31856744](#) DOI: [10.1186/s12879-019-4687-7](#)]
 - 24 **Sam IK**, Chen YY, Ma J, Li SY, Ying RY, Li LX, Ji P, Wang SJ, Xu J, Bao YJ, Zhao GP, Zheng HJ, Wang J, Sha W, Wang Y. TB-QUICK: CRISPR-Cas12b-assisted rapid and sensitive detection of Mycobacterium tuberculosis. *J Infect* 2021; **83**: 54-60 [PMID: [33951419](#) DOI: [10.1016/j.jinf.2021.04.032](#)]
 - 25 **Churchyard GJ**, Mametja LD, Mvusi L, Ndjeka N, Hesselting AC, Reid A, Babatunde S, Pillay Y. Tuberculosis control in South Africa: successes, challenges and recommendations. *S Afr Med J* 2014; **104**: 244-248 [PMID: [24893501](#) DOI: [10.7196/samj.7689](#)]
 - 26 **Noertjojo K**, Tam CM, Chan SL, Tan J, Chan-Yeung M. Contact examination for tuberculosis in Hong Kong is useful. *Int J Tuberc Lung Dis* 2002; **6**: 19-24 [PMID: [11931396](#)]
 - 27 **Lee MS**, Leung CC, Kam KM, Wong MY, Leung MC, Tam CM, Leung EC. Early and late tuberculosis risks among close contacts in Hong Kong. *Int J Tuberc Lung Dis* 2008; **12**: 281-287 [PMID: [18284833](#)]
 - 28 **Leung EC**, Leung CC, Kam KM, Yew WW, Chang KC, Leung WM, Tam CM. Transmission of multidrug-resistant and extensively drug-resistant tuberculosis in a metropolitan city. *Eur Respir J* 2013; **41**: 901-908 [PMID: [22878878](#) DOI: [10.1183/09031936.00071212](#)]
 - 29 **Dye C**, Williams BG. Eliminating human tuberculosis in the twenty-first century. *J R Soc Interface* 2008; **5**: 653-662 [PMID: [17690054](#) DOI: [10.1098/rsif.2007.1138](#)]
 - 30 **Harisinghani MG**, McLoud TC, Shepard JA, Ko JP, Shroff MM, Mueller PR. Tuberculosis from head to toe. *Radiographics* 2000; **20**: 449-70; quiz 528 [PMID: [10715343](#) DOI: [10.1148/radiographics.20.2.g00mc12449](#)]
 - 31 **Bomanji JB**, Gupta N, Gulati P, Das CJ. Imaging in tuberculosis. *Cold Spring Harb Perspect Med* 2015; **5** [PMID: [25605754](#) DOI: [10.1101/cshperspect.a017814](#)]
 - 32 **Ordóñez AA**, Tucker EW, Anderson CJ, Carter CL, Ganatra S, Kaushal D, Kramnik I, Lin PL, Madigan CA, Mendez S, Rao J, Savic RM, Tobin DM, Walz G, Wilkinson RJ, Lacourciere KA, Via LE, Jain SK. Visualizing the dynamics of tuberculosis pathology using molecular imaging. *J Clin Invest* 2021; **131** [PMID: [33645551](#) DOI: [10.1172/JCI145107](#)]
 - 33 **WHO**. Chest radiography in tuberculosis detection. [cited 20 January 2022]. Available from: <https://apps.who.int/iris/handle/10665/252424>
 - 34 **Sharma M**, Sandhu MS, Gorski U, Gupta D, Khandelwal N. Role of digital tomosynthesis and dual energy subtraction digital radiography in detection of parenchymal lesions in active pulmonary tuberculosis. *Eur J Radiol* 2015; **84**: 1820-1827 [PMID: [26071244](#) DOI: [10.1016/j.ejrad.2015.05.031](#)]
 - 35 **Yu TZ**, Zhang Y, Zhang WZ, Yang GY. Role of ultrasound in the diagnosis of cervical tuberculous lymphadenitis in children. *World J Pediatr* 2021; **17**: 544-550 [PMID: [34472036](#) DOI: [10.1007/s12519-021-00453-w](#)]
 - 36 **Navani N**, Molyneaux PL, Breen RA, Connell DW, Jepson A, Nankivell M, Brown JM, Morris-Jones S, Ng B, Wickremasinghe M, Lalvani A, Rintoul RC, Santis G, Kon OM, Janes SM. Utility of endobronchial ultrasound-guided transbronchial needle aspiration in patients with tuberculous intrathoracic lymphadenopathy: a multicentre study. *Thorax* 2011; **66**: 889-893 [PMID: [21813622](#) DOI: [10.1136/thoraxjnl-2011-200063](#)]
 - 37 **Wang B**, Guo Q, Wang JY, Yu Y, Yi AJ, Cui XW, Dietrich CF. Ultrasound Elastography for the Evaluation of Lymph Nodes. *Front Oncol* 2021; **11**: 714660 [PMID: [34485150](#) DOI: [10.3389/fonc.2021.714660](#)]
 - 38 **Merchant S**, Bharati A, Merchant N. Tuberculosis of the genitourinary system-Urinary tract tuberculosis: Renal tuberculosis-Part II. *Indian J Radiol Imaging* 2013; **23**: 64-77 [PMID: [23986619](#) DOI: [10.4103/0971-3026.113617](#)]
 - 39 **Chaubal N**, Bam A & Khatdare K. Elastography of Lymph Nodes. In: Richard. G Barr (Ed) *Elastography - A Practical Approach*. First ed. New York - Stuttgart: Thieme, 2017: 100-114
 - 40 **Dietrich CF**, Jenssen C, Arcidiacono PG, Cui XW, Giovannini M, Hocke M, Iglesias-Garcia J, Saftoiu A, Sun S, Chiorean L. Endoscopic ultrasound: Elastographic lymph node evaluation. *Endosc Ultrasound* 2015; **4**: 176-190 [PMID: [26374575](#) DOI: [10.4103/2303-9027.162995](#)]
 - 41 **Kanagaraju V**, Rakshith AVB, Devanand B, Rajakumar R. Utility of Ultrasound Elastography to Differentiate Benign from Malignant Cervical Lymph Nodes. *J Med Ultrasound* 2020; **28**: 92-98 [PMID: [32874867](#) DOI: [10.4103/JMU.JMU_72_19](#)]
 - 42 **Özel D**, Özel BD. Evaluating the role of strain ratio elastography in determining malignancy potential and calculating objective BIRADS US scores using ultrasonography and elastography features. *Pol J Radiol* 2018; **83**: e268-e274 [PMID: [30627246](#) DOI: [10.5114/pjr.2018.76790](#)]

- 43 **Shehata RMA**, El-Sharkawy MAM, Mahmoud OM. Qualitative and quantitative strain and shear wave elastography paradigm in differentiation of breast lesions. [cited 20 January 2022]. Available from: <https://ejrm.springeropen.com/articles/10.1186/s43055-022-00697-0>
- 44 **Wang Z**, Yang T, Wu Z, Tang S, Liang X, Qin A, Ouyang T, Liu P, Liu J. Correlation between elastography score and strain rate ratio in breast small tumor. *Zhongnan Daxue Xuebao Yixueban* 2010; **35**: 928-932 [PMID: [20871156](#) DOI: [10.3969/j.issn.1672-7347.2010.09.005](#)]
- 45 **Chu J**, Zhang Y, Zhang W, Zhao D, Xu J, Yu T, Yang G. The value of multimodal ultrasonography in differential diagnosis of tuberculous and non-tuberculous superficial lymphadenitis. *BMC Surg* 2021; **21**: 416 [PMID: [34906107](#) DOI: [10.1186/s12893-021-01418-6](#)]
- 46 **Lammers T**, Aime S, Hennink WE, Storm G, Kiessling F. Theranostic nanomedicine. *Acc Chem Res* 2011; **44**: 1029-1038 [PMID: [21545096](#) DOI: [10.1021/ar200019c](#)]
- 47 **Martin KH**, Dayton PA. Current status and prospects for microbubbles in ultrasound theranostics. *Wiley Interdiscip Rev Nanomed Nanobiotechnol* 2013; **5**: 329-345 [PMID: [23504911](#) DOI: [10.1002/wnan.1219](#)]
- 48 **Ma J**, Martin K, Dayton PA, Jiang X. A preliminary engineering design of intravascular dual-frequency transducers for contrast-enhanced acoustic angiography and molecular imaging. *IEEE Trans Ultrason Ferroelectr Freq Control* 2014; **61**: 870-880 [PMID: [24801226](#) DOI: [10.1109/TUFFC.2014.6805699](#)]
- 49 **Duran C**, Beltrán VP, González A, Gómez C, Riego JD. Contrast-enhanced Voiding Urosonography for Vesicoureteral Reflux Diagnosis in Children. *Radiographics* 2017; **37**: 1854-1869 [PMID: [29019761](#) DOI: [10.1148/rg.2017170024](#)]
- 50 **Kiessling F**, Fokong S, Bzyl J, Lederle W, Palmowski M, Lammers T. Recent advances in molecular, multimodal and theranostic ultrasound imaging. *Adv Drug Deliv Rev* 2014; **72**: 15-27 [PMID: [24316070](#) DOI: [10.1016/j.addr.2013.11.013](#)]
- 51 **Palmowski M**, Morgenstern B, Hauff P, Reinhardt M, Huppert J, Maurer M, Woenne EC, Doerk S, Ladewig G, Jenne JW, Delorme S, Grenacher L, Hallscheidt P, Kauffmann GW, Semmler W, Kiessling F. Pharmacodynamics of streptavidin-coated cyanoacrylate microbubbles designed for molecular ultrasound imaging. *Invest Radiol* 2008; **43**: 162-169 [PMID: [18301312](#) DOI: [10.1097/RLI.0b013e31815a251b](#)]
- 52 **Fei C**, Chiu CT, Chen X, Chen Z, Ma J, Zhu B, Shung KK, Zhou Q. Ultrahigh Frequency (100 MHz-300 MHz) Ultrasonic Transducers for Optical Resolution Medical Imaging. *Sci Rep* 2016; **6**: 28360 [PMID: [27329379](#) DOI: [10.1038/srep28360](#)]
- 53 **Willer K**, Fingerle AA, Gromann LB, De Marco F, Herzen J, Achterhold K, Gleich B, Muenzel D, Scherer K, Renz M, Renger B, Kopp F, Kriner F, Fischer F, Braun C, Auweter S, Hellbach K, Reiser MF, Schroeter T, Mohr J, Yaroshenko A, Maack HJ, Pralow T, van der Heijden H, Proksa R, Koehler T, Wieberneit N, Rindt K, Rummeny EJ, Pfeiffer F, Noël PB. X-ray dark-field imaging of the human lung-A feasibility study on a deceased body. *PLoS One* 2018; **13**: e0204565 [PMID: [30261038](#) DOI: [10.1371/journal.pone.0204565](#)]
- 54 **Bech M**, Tapfer A, Velroyen A, Yaroshenko A, Pauwels B, Hostens J, Bruyndonckx P, Sasov A, Pfeiffer F. In-vivo dark-field and phase-contrast x-ray imaging. *Sci Rep* 2013; **3**: 3209 [PMID: [24220606](#) DOI: [10.1038/srep03209](#)]
- 55 **Schleede S**, Meinel FG, Bech M, Herzen J, Achterhold K, Potdevin G, Malecki A, Adam-Neumair S, Thieme SF, Bamberg F, Nikolaou K, Bohla A, Yildirim AÖ, Loewen R, Gifford M, Ruth R, Eickelberg O, Reiser M, Pfeiffer F. Emphysema diagnosis using X-ray dark-field imaging at a laser-driven compact synchrotron light source. *Proc Natl Acad Sci U S A* 2012; **109**: 17880-17885 [PMID: [23074250](#) DOI: [10.1073/pnas.1206684109](#)]
- 56 **Bhalla AS**, Goyal A, Guleria R, Gupta AK. Chest tuberculosis: Radiological review and imaging recommendations. *Indian J Radiol Imaging* 2015; **25**: 213-225 [PMID: [26288514](#)]
- 57 **Khan AU**, Khanduri S, Tarin Z, Abbas SZ, Husain M, Singh A, Yadav P, Jain S. Dual-Energy Computed Tomography Lung in patients of Pulmonary Tuberculosis. *J Clin Imaging Sci* 2020; **10**: 39 [PMID: [32754374](#) DOI: [10.25259/JCIS_78_2020](#)]
- 58 **Huang HM**, Shih YY. Pushing CT and MR imaging to the molecular level for studying the "omics": current challenges and advancements. *Biomed Res Int* 2014; **2014**: 365812 [PMID: [24738056](#) DOI: [10.1155/2014/365812](#)]
- 59 **Peprah KO**, Andronikou S, Goussard P. Characteristic magnetic resonance imaging low T2 signal intensity of necrotic lung parenchyma in children with pulmonary tuberculosis. *J Thorac Imaging* 2012; **27**: 171-174 [PMID: [21516045](#) DOI: [10.1097/RTI.0b013e3181211abfb](#)]
- 60 **Sodhi KS**, Khandelwal N, Saxena AK, Singh M, Agarwal R, Bhatia A, Lee EY. Rapid lung MRI in children with pulmonary infections: Time to change our diagnostic algorithms. *J Magn Reson Imaging* 2016; **43**: 1196-1206 [PMID: [26546472](#) DOI: [10.1002/jmri.25082](#)]
- 61 **Bharati A**, Merchant S, Nagesh C. The 'Myocarditis-Pericarditis' Complex - A CMR Sign of Cardiac Tuberculosis and The Spectrum of imaging findings of Cardiac Tuberculosis on CMR. RSNA Annual Conference. Chicago: Radiological Society of North America, 2013. [cited 20 January 2022]. Available from: <https://archive.rsna.org/2013/13012394.html>
- 62 **Liu J**, Bai R, Li Y, Staedtke V, Zhang S, van Zijl PCM, Liu G. MRI detection of bacterial brain abscesses and monitoring of antibiotic treatment using bacCEST. *Magn Reson Med* 2018; **80**: 662-671 [PMID: [29577382](#) DOI: [10.1002/mrm.27180](#)]
- 63 **Goldenberg JM**, Berthussen AJ, Cárdenas-Rodríguez J, Pagel MD. Differentiation of Myositis-Induced Models of Bacterial Infection and Inflammation with T₂-Weighted, CEST, and DCE-MRI. *Tomography* 2019; **5**: 283-291 [PMID: [31572789](#) DOI: [10.18383/j.tom.2019.00009](#)]
- 64 **Campbell-Washburn AE**, Ramasawmy R, Restivo MC, Bhattacharya I, Basar B, Herzka DA, Hansen MS, Rogers T, Bandettini WP, McGuirt DR, Mancini C, Grodzki D, Schneider R, Majeed W, Bhat H, Xue H, Moss J, Malayeri AA, Jones EC, Koretsky AP, Kellman P, Chen MY, Lederman RJ, Balaban RS. Opportunities in Interventional and Diagnostic Imaging by Using High-Performance Low-Field-Strength MRI. *Radiology* 2019; **293**: 384-393 [PMID: [31573398](#) DOI: [10.1148/radiol.2019190452](#)]
- 65 **Morales H**, Alfaro D, Martinot C, Fayed N, Gaskill-Shipley M. MR spectroscopy of intracranial tuberculomas: A singlet peak at 3.8 ppm as potential marker to differentiate them from malignant tumors. *Neuroradiol J* 2015; **28**: 294-302 [PMID: [26246099](#) DOI: [10.1177/1971400915592077](#)]
- 66 **van Zijl PC**, Yadav NN. Chemical exchange saturation transfer (CEST): what is in a name and what isn't? *Magn Reson*

- Med* 2011; **65**: 927-948 [PMID: [21337419](#) DOI: [10.1002/mrm.22761](#)]
- 67 **Minton LE**, Pandit R, Willoughby WR, Porter KK. The Future of Magnetic Resonance Imaging Contrast Agents. *Appl Radiol* 2022; **51**: 7-11 [cited 20 January 2022]. Available from: <https://appliedradiology.com/articles/the-future-of-magnetic-resonance-imaging-contrast-agents>
- 68 **Hancu I**, Dixon WT, Woods M, Vinogradov E, Sherry AD, Lenkinski RE. CEST and PARACEST MR contrast agents. *Acta Radiol* 2010; **51**: 910-923 [PMID: [20828299](#) DOI: [10.3109/02841851.2010.502126](#)]
- 69 **Kulanthaivelu K**, Jabeen S, Saini J, Raju S, Nalini A, Sadashiva N, Hegde S, Rolla NK, Saha I, M N, Vengalil S, Swaroop S, Rao S. Amide proton transfer imaging for differentiation of tuberculomas from high-grade gliomas: Preliminary experience. *Neuroradiol J* 2021; **34**: 440-448 [PMID: [33823712](#) DOI: [10.1177/19714009211002766](#)]
- 70 **Biswas A**, Santra S, Bishnu D, Dhali GK, Chowdhury A, Santra A. Isoniazid and Rifampicin Produce Hepatic Fibrosis through an Oxidative Stress-Dependent Mechanism. *Int J Hepatol* 2020; **2020**: 6987295 [PMID: [32373368](#) DOI: [10.1155/2020/6987295](#)]
- 71 **Imajo K**, Honda Y, Kobayashi T, Nagai K, Ozaki A, Iwaki M, Kessoku T, Ogawa Y, Takahashi H, Saigusa Y, Yoneda M, Kirikoshi H, Utsunomiya D, Aishima S, Saito S, Nakajima A. Direct Comparison of US and MR Elastography for Staging Liver Fibrosis in Patients With Nonalcoholic Fatty Liver Disease. *Clin Gastroenterol Hepatol* 2022; **20**: 908-917.e11 [PMID: [33340780](#)]
- 72 **Xu C**, Howey J, Ohorodnyk P, Roth M, Zhang H, Li S. Segmentation and quantification of infarction without contrast agents via spatiotemporal generative adversarial learning. *Med Image Anal* 2020; **59**: 101568 [PMID: [31622838](#) DOI: [10.1016/j.media.2019.101568](#)]
- 73 **de Figueiredo EH**, Borgonovi AF, Doring TM. Basic concepts of MR imaging, diffusion MR imaging, and diffusion tensor imaging. *Magn Reson Imaging Clin N Am* 2011; **19**: 1-22 [PMID: [21129633](#) DOI: [10.1016/j.mric.2010.10.005](#)]
- 74 **Jadvar H**, Colletti PM. Competitive advantage of PET/MRI. *Eur J Radiol* 2014; **83**: 84-94 [PMID: [23791129](#) DOI: [10.1016/j.ejrad.2013.05.028](#)]
- 75 **Ordóñez AA**, Sellmyer MA, Gowrishankar G, Ruiz-Bedoya CA, Tucker EW, Palestro CJ, Hammoud DA, Jain SK. Molecular imaging of bacterial infections: Overcoming the barriers to clinical translation. *Sci Transl Med* 2019; **11** [PMID: [31484790](#) DOI: [10.1126/scitranslmed.aax8251](#)]
- 76 **Ordóñez AA**, Weinstein EA, Bambarger LE, Saini V, Chang YS, DeMarco VP, Klunk MH, Urbanowski ME, Moulton KL, Murawski AM, Pokkali S, Kalinda AS, Jain SK. A Systematic Approach for Developing Bacteria-Specific Imaging Tracers. *J Nucl Med* 2017; **58**: 144-150 [PMID: [27635025](#) DOI: [10.2967/jnumed.116.181792](#)]
- 77 **Sly LM**, Hingley-Wilson SM, Reiner NE, McMaster WR. Survival of Mycobacterium tuberculosis in host macrophages involves resistance to apoptosis dependent upon induction of antiapoptotic Bcl-2 family member Mcl-1. *J Immunol* 2003; **170**: 430-437 [PMID: [12496428](#) DOI: [10.4049/jimmunol.170.1.430](#)]
- 78 **Chen RY**, Dodd LE, Lee M, Paripati P, Hammoud DA, Mountz JM, Jeon D, Zia N, Zahiri H, Coleman MT, Carroll MW, Lee JD, Jeong YJ, Herscovitch P, Lahouar S, Tartakovsky M, Rosenthal A, Somaiyya S, Lee S, Goldfeder LC, Cai Y, Via LE, Park SK, Cho SN, Barry CE 3rd. PET/CT imaging correlates with treatment outcome in patients with multidrug-resistant tuberculosis. *Sci Transl Med* 2014; **6**: 265ra166 [PMID: [25473034](#) DOI: [10.1126/scitranslmed.3009501](#)]
- 79 **Davis SL**, Nuernberger EL, Um PK, Vidal C, Jedynak B, Pomper MG, Bishai WR, Jain SK. Noninvasive pulmonary [18F]-2-fluoro-deoxy-D-glucose positron emission tomography correlates with bactericidal activity of tuberculosis drug treatment. *Antimicrob Agents Chemother* 2009; **53**: 4879-4884 [PMID: [19738022](#) DOI: [10.1128/AAC.00789-09](#)]
- 80 **Lin PL**, Maiello P, Gideon HP, Coleman MT, Cadena AM, Rodgers MA, Gregg R, O'Malley M, Tomko J, Fillmore D, Frye LJ, Rutledge T, DiFazio RM, Janssen C, Klein E, Andersen PL, Fortune SM, Flynn JL. PET CT Identifies Reactivation Risk in Cynomolgus Macaques with Latent M. tuberculosis. *PLoS Pathog* 2016; **12**: e1005739 [PMID: [27379816](#) DOI: [10.1371/journal.ppat.1005739](#)]
- 81 **Esmail H**, Lai RP, Lesosky M, Wilkinson KA, Graham CM, Coussens AK, Oni T, Warwick JM, Said-Hartley Q, Koegelenberg CF, Walz G, Flynn JL, Young DB, Barry Iii CE, O'Garra A, Wilkinson RJ. Characterization of progressive HIV-associated tuberculosis using 2-deoxy-2-[¹⁸F]fluoro-D-glucose positron emission and computed tomography. *Nat Med* 2016; **22**: 1090-1093 [PMID: [27595321](#) DOI: [10.1038/nm.4161](#)]
- 82 **Cherry SR**, Jones T, Karp JS, Qi J, Moses WW, Badawi RD. Total-Body PET: Maximizing Sensitivity to Create New Opportunities for Clinical Research and Patient Care. *J Nucl Med* 2018; **59**: 3-12 [PMID: [28935835](#) DOI: [10.2967/jnumed.116.184028](#)]
- 83 **Jain SK**. The Promise of Molecular Imaging in the Study and Treatment of Infectious Diseases. *Mol Imaging Biol* 2017; **19**: 341-347 [PMID: [28155078](#) DOI: [10.1007/s11307-017-1055-0](#)]
- 84 **Cherry SR**, Badawi RD, Karp JS, Moses WW, Price P, Jones T. Total-body imaging: Transforming the role of positron emission tomography. *Sci Transl Med* 2017; **9** [PMID: [28298419](#) DOI: [10.1126/scitranslmed.aaf6169](#)]
- 85 **Badawi RD**, Shi H, Hu P, Chen S, Xu T, Price PM, Ding Y, Spencer BA, Nardo L, Liu W, Bao J, Jones T, Li H, Cherry SR. First Human Imaging Studies with the EXPLORER Total-Body PET Scanner. *J Nucl Med* 2019; **60**: 299-303 [PMID: [30733314](#) DOI: [10.2967/jnumed.119.226498](#)]
- 86 **Lv Y**, Lv X, Liu W, Judenhofer MS, Zwingenberger A, Wisner E, Berg E, McKenney S, Leung E, Spencer BA, Cherry SR, Badawi RD. Mini EXPLORER II: a prototype high-sensitivity PET/CT scanner for companion animal whole body and human brain scanning. *Phys Med Biol* 2019; **64**: 075004 [PMID: [30620929](#) DOI: [10.1088/1361-6560/aaf6c6](#)]
- 87 **Foss CA**, Kulik L, Ordóñez AA, Jain SK, Michael Holers V, Thurman JM, Pomper MG. SPECT/CT Imaging of Mycobacterium tuberculosis Infection with [¹²⁵I]anti-C3d mAb. *Mol Imaging Biol* 2019; **21**: 473-481 [PMID: [29998399](#) DOI: [10.1007/s11307-018-1228-5](#)]
- 88 **Murooka TT**, Mempel TR. Multiphoton intravital microscopy to study lymphocyte motility in lymph nodes. *Methods Mol Biol* 2012; **757**: 247-257 [PMID: [21909917](#) DOI: [10.1007/978-1-61779-166-6_16](#)]
- 89 **Blanc L**, Lenaerts A, Dartois V, Pridaux B. Visualization of Mycobacterial Biomarkers and Tuberculosis Drugs in Infected Tissue by MALDI-MS Imaging. *Anal Chem* 2018; **90**: 6275-6282 [PMID: [29668262](#) DOI: [10.1021/acs.analchem.8b00985](#)]
- 90 **Niehaus M**, Soltwisch J, Belov ME, Dreisewerd K. Transmission-mode MALDI-2 mass spectrometry imaging of cells

- and tissues at subcellular resolution. *Nat Methods* 2019; **16**: 925-931 [PMID: 31451764 DOI: 10.1038/s41592-019-0536-2]
- 91 **Paine MRI**, Ellis SR, Maloney D, Heeren RMA, Verhaert PDEM. Digestion-Free Analysis of Peptides from 30-year-old Formalin-Fixed, Paraffin-Embedded Tissue by Mass Spectrometry Imaging. *Anal Chem* 2018; **90**: 9272-9280 [PMID: 29975508 DOI: 10.1021/acs.analchem.8b01838]
 - 92 **Casacio**, Catxere and Andrade. Quantum enhanced microscopy. A thesis submitted for the degree of Doctor of Philosophy - The University of Queensland, Australia, 2020. [cited 20 January 2022]. Available from: <https://espace.library.uq.edu.au/>
 - 93 **Martineau AR**, Honecker FU, Wilkinson RJ, Griffiths CJ. Vitamin D in the treatment of pulmonary tuberculosis. *J Steroid Biochem Mol Biol* 2007; **103**: 793-798 [PMID: 17223549 DOI: 10.1016/j.jsbmb.2006.12.052]
 - 94 **Nnoaham KE**, Clarke A. Low serum vitamin D levels and tuberculosis: a systematic review and meta-analysis. *Int J Epidemiol* 2008; **37**: 113-119 [PMID: 18245055 DOI: 10.1093/ije/dym247]
 - 95 **Chung C**, Silwal P, Kim I, Modlin RL, Jo EK. Vitamin D-Cathelicidin Axis: at the Crossroads between Protective Immunity and Pathological Inflammation during Infection. *Immune Netw* 2020; **20**: e12 [PMID: 32395364 DOI: 10.4110/in.2020.20.e12]
 - 96 **Arora VK**, Jaiswal AK. Vitamin D receptor polymorphism and active tuberculosis. [cited 20 January 2022]. Available from: http://tbassindia.org/images/TB_October_2013_issue.pdf
 - 97 **Coussens AK**, Wilkinson RJ, Hanifa Y, Nikolayevskyy V, Elkington PT, Islam K, Timms PM, Venton TR, Bothamley GH, Packe GE, Darmalingam M, Davidson RN, Milburn HJ, Baker LV, Barker RD, Mein CA, Bhaw-Rosun L, Nuamah R, Young DB, Drobniewski FA, Griffiths CJ, Martineau AR. Vitamin D accelerates resolution of inflammatory responses during tuberculosis treatment. *Proc Natl Acad Sci U S A* 2012; **109**: 15449-15454 [PMID: 22949664 DOI: 10.1073/pnas.1200072109]
 - 98 **Sutaria N**, Liu CT, Chen TC. Vitamin D Status, Receptor Gene Polymorphisms, and Supplementation on Tuberculosis: A Systematic Review of Case-Control Studies and Randomized Controlled Trials. *J Clin Transl Endocrinol* 2014; **1**: 151-160 [PMID: 25599020 DOI: 10.1016/j.jcte.2014.08.001]
 - 99 **Lips P**. Vitamin D deficiency and secondary hyperparathyroidism in the elderly: consequences for bone loss and fractures and therapeutic implications. *Endocr Rev* 2001; **22**: 477-501 [PMID: 11493580 DOI: 10.1210/edrv.22.4.0437]
 - 100 **Junaid K**, Rehman A. Impact of vitamin D on infectious disease-tuberculosis-a Review. [cited 20 January 2022]. Available from: [https://www.clinicalnutritionopenscience.com/article/S2352-9393\(19\)30017-X/pdf](https://www.clinicalnutritionopenscience.com/article/S2352-9393(19)30017-X/pdf)
 - 101 **Davies PD**. The role of vitamin D in tuberculosis. *Am Rev Respir Dis* 1989; **139**: 1571 [PMID: 2729764 DOI: 10.1164/ajrccm/139.6.1571]
 - 102 **Merchant S**, Bharati A, Merchant N. Tuberculosis of the genitourinary system-Urinary tract tuberculosis: Renal tuberculosis-Part I. *Indian J Radiol Imaging* 2013; **23**: 46-63 [PMID: 23986618 DOI: 10.4103/0971-3026.113615]
 - 103 **Kathirvel M**, Mahadevan S. The role of epigenetics in tuberculosis infection. *Epigenomics* 2016; **8**: 537-549 [PMID: 27035266 DOI: 10.2217/epi.16.1]
 - 104 **Gaubha K**, Gupta S, Shekhawat J, Sharma P, Yadav D, Banerjee M. Immunomodulation by epigenome alterations in Mycobacterium tuberculosis infection. *Tuberculosis (Edinb)* 2021; **128**: 102077 [PMID: 33812175 DOI: 10.1016/j.tube.2021.102077]
 - 105 **Wang M**, Kong W, He B, Li Z, Song H, Shi P, Wang J. Vitamin D and the promoter methylation of its metabolic pathway genes in association with the risk and prognosis of tuberculosis. *Clin Epigenetics* 2018; **10**: 118 [PMID: 30208925 DOI: 10.1186/s13148-018-0552-6]
 - 106 **Tarashi S**, Badi SA, Moshiri A, Ebrahimzadeh N, Fateh A, Vaziri F, Aazami H, Siadat SD, Fuso A. The inter-talk between Mycobacterium tuberculosis and the epigenetic mechanisms. *Epigenomics* 2020; **12**: 455-469 [PMID: 32267165 DOI: 10.2217/epi-2019-0187]
 - 107 **Faulkner V**, Cox AA, Goh S, van Bohemen A, Gibson AJ, Liebster O, Wren BW, Willcocks S, Kendall SL. Re-sensitization of Mycobacterium smegmatis to Rifampicin Using CRISPR Interference Demonstrates Its Utility for the Study of Non-essential Drug Resistance Traits. *Front Microbiol* 2020; **11**: 619427 [PMID: 33597931 DOI: 10.3389/fmicb.2020.619427]
 - 108 **Lakhani P**, Sundaram B. Deep Learning at Chest Radiography: Automated Classification of Pulmonary Tuberculosis by Using Convolutional Neural Networks. *Radiology* 2017; **284**: 574-582 [PMID: 28436741 DOI: 10.1148/radiol.2017162326]
 - 109 **Vonasek B**, Ness T, Takwoingi Y, Kay AW, van Wyk SS, Ouellette L, Marais BJ, Steingart KR, Mandalakas AM. Screening tests for active pulmonary tuberculosis in children. *Cochrane Database Syst Rev* 2021; **6**: CD013693 [PMID: 34180536 DOI: 10.1002/14651858.CD013693.pub2]
 - 110 **Shivam A**. Edge Computing vs Cloud Computing: What are the Differences. [cited 20 January 2022]. Available from: <https://www.simplilearn.com/edge-computing-vs-cloud-computing-article>
 - 111 **McMahan B**, Ramage D. Federated Learning: Collaborative Machine Learning without Centralized Training Data. Google AI Blog [Internet]. Google, 2017. Introducing an additional approach: Federated Learning. [cited 20 January 2022]. Available from: <https://ai.googleblog.com/2017/04/federated-learning-collaborative.html>
 - 112 **Dean JG**, Ghemawat S. MapReduce: Simplified Data Processing on Large Clusters. Sixth Symposium on Operating System Design and Implementation. San Francisco: Google Inc, 2004. [cited 20 January 2022]. Available from: <https://static.googleusercontent.com/media/research.google.com/en/archive/mapreduce-osdi04.pdf>
 - 113 **Ng D**, Lan X, Yao MM, Chan WP, Feng M. Federated learning: a collaborative effort to achieve better medical imaging models for individual sites that have small labelled datasets. *Quant Imaging Med Surg* 2021; **11**: 852-857 [PMID: 33532283 DOI: 10.21037/qims-20-595]
 - 114 **Sheller MJ**, Edwards B, Reina GA, Martin J, Pati S, Kotrotsou A, Milchenko M, Xu W, Marcus D, Colen RR, Bakas S. Federated learning in medicine: facilitating multi-institutional collaborations without sharing patient data. *Sci Rep* 2020; **10**: 12598 [PMID: 32724046 DOI: 10.1038/s41598-020-69250-1]
 - 115 **Navia-Vazquez A**, Vazquez-Lopez M, and Cid-Sueiro J. Double Confidential Federated Machine Learning Logistic

- Regression for Industrial Data Platforms. In: 37th International Conference on Machine Learning Vienna 2020, Vienna. [cited 20 January 2022]. Available from: https://www.tsc.uc3m.es/~navia/FL-ICML2020/DCFML-FL_ICML2020-A_Navia_Vazquez_et_al.pdf
- 116 **Wikipedia.** Quantum Microscopy. [cited 20 January 2022]. Available from: https://en.wikipedia.org/wiki/Quantum_microscopy
- 117 **Studio TB.** [cited 20 January 2022]. Available from: <https://techcrunch.com/sponsor/qualcomm/the-future-is-not-the-internet-of-things-it-is-the-connected-intelligent-edge/>
- 118 **Ono T, Okamoto R, Takeuchi S.** An entanglement-enhanced microscope. *Nat Commun* 2013; 4: 2426 [PMID: 24026165]
- 119 **Optics.** org. Project QUILT reveals far-reaching potential of quantum optics and imaging. [cited 20 January 2022]. Available from: <https://optics.org/news/13/1/4> (2022)
- 120 **Fraenhofer-Gesellschaft.** Quantum imaging: Pushing the boundaries of optics. [cited 20 January 2022]. Available from: <https://phys.org/news/2022-01-quantum-imaging-boundaries-optics.html>
- 121 **Shor PW.** Algorithms for quantum computation: discrete logarithms and factoring. In: Proceedings 35th Annual Symposium on Foundations of Computer Science 1994: 124-134 [cited 20 January 2022]. Available from: <https://ieeexplore.ieee.org/document/365700>
- 122 **Sharma M.** There's been another huge quantum computing breakthrough. [cited 20 January 2022]. Available from: <https://www.mckinsey.com/business-functions/mckinsey-digital/our-insights/quantum-computing-use-cases-are-getting-real-what-you-need-to-know>
- 123 **Tung L.** Quantum computing: Forget about qubits, here come qutrits. [cited 20 January 2022]. Available from: <https://www.zdnet.com/article/quantum-computing-now-rigetti-explores-qutrits-as-well-as-qubits/>
- 124 **Oikawa A, Ota A.** Quantum computing: Japan takes step toward light-based technology. [cited 20 January 2022]. Available from: <https://asia.nikkei.com/Business/Technology/Quantum-computing-Japan-takes-step-toward-light-based-technology>
- 125 **Kahn J.** Microsoft Quantum Algorithm Boosts Medical Imaging. [cited 20 January 2022]. Available from: <https://fortune.com/2019/07/15/microsoft-quantum-algorithm-boosts-medical-imaging>
- 126 **Charles Q, Choi AI.** Fuses With Quantum Computing in Promising New Memristor Quantum device points the way toward an exponential boost in "smart" computing capabilities. [cited 20 January 2022]. Available from: <https://spectrum.ieee.org/quantum-memristor>
- 127 **Spagnolo M, Morris J, Piacentini S.** Experimental photonic quantum memristor. *Nature Photonics* 2022; 16: 318-323 [cited 20 January 2022]. Available from: <https://www.nature.com/articles/s41566>



Published by **Baishideng Publishing Group Inc**
7041 Koll Center Parkway, Suite 160, Pleasanton, CA 94566, USA

Telephone: +1-925-3991568

E-mail: bpgoffice@wjgnet.com

Help Desk: <https://www.f6publishing.com/helpdesk>

<https://www.wjgnet.com>

