


# World Journal of *Hepatology*

*World J Hepatol* 2022 July 27; 14(7): 1269-1529



### EDITORIAL

- 1269** Checkpoint inhibitor-induced hepatotoxicity: Role of liver biopsy and management approach  
*Bessone F, Bjornsson ES*

### REVIEW

- 1277** Gut microbiota contribution to hepatocellular carcinoma manifestation in non-alcoholic steatohepatitis  
*Liakina V, Strainiene S, Stundiene I, Maksimaityte V, Kazenaite E*
- 1291** Hepatogenous diabetes: Knowledge, evidence, and skepticism  
*Kumar R, García-Compeán D, Maji T*
- 1307** Small extracellular vesicles and liver diseases: From diagnosis to therapy  
*Tsuchiya A, Natsui K, Ishii Y, Koseki Y, Takeda N, Tomiyoshi K, Yamazaki F, Yoshida Y, Terai S*
- 1319** Hepatocellular carcinoma and microbiota: Implications for clinical management and treatment  
*Spanu D, Pretta A, Lai E, Persano M, Donisi C, Mariani S, Dubois M, Migliari M, Saba G, Ziranu P, Pusceddu V, Puzzone M, Astara G, Scartozzi M*

### MINIREVIEWS

- 1333** Challenge of managing hepatitis B virus and hepatitis C virus infections in resource-limited settings  
*Said ZNA, El-Sayed MH*
- 1344** Alfapump® implantable device in management of refractory ascites: An update  
*Weil-Verhoeven D, Di Martino V, Stirnimann G, Cervoni JP, Nguyen-Khac E, Thévenot T*

### ORIGINAL ARTICLE

#### Basic Study

- 1357** Tissue pad degradation of ultrasonic device may enhance thermal injury and impair its sealing performance in liver surgery  
*Kajiwara M, Fujikawa T, Hasegawa S*
- 1365** Regulation of PPAR- $\gamma$  activity in lipid-laden hepatocytes affects macrophage polarization and inflammation in nonalcoholic fatty liver disease  
*Li XY, Ji PX, Ni XX, Chen YX, Sheng L, Lian M, Guo CJ, Hua J*

#### Clinical and Translational Research

- 1382** Transcriptome changes in stages of non-alcoholic fatty liver disease  
*Aljabban J, Rohr M, Syed S, Khorfan K, Borkowski V, Aljabban H, Segal M, Mukhtar M, Mohammed M, Panahiazar M, Hadley D, Spengler R, Spengler E*

**Retrospective Cohort Study**

- 1398** Cardiac risk factors limiting survival to liver transplantation in patients with nonalcoholic fatty liver disease

*Delicce M, Mauch J, Joseph A, Lyu R, Kren H, Bartow R, Ferchill D, Fares M, Wakim-Fleming J*

**Retrospective Study**

- 1408** Differential distribution of gene polymorphisms associated with hypercholesterolemia, hypertriglyceridemia, and hypoalphalipoproteinemia among Native American and Mestizo Mexicans

*Torres-Valadez R, Roman S, Ojeda-Granados C, Gonzalez-Aldaco K, Panduro A*

- 1421** Effect of thrombocytopenia and platelet transfusion on outcomes of acute variceal bleeding in patients with chronic liver disease

*Biswas S, Vaishnav M, Pathak P, Gunjan D, Mahapatra SJ, Kedia S, Rout G, Thakur B, Nayak B, Kumar R, Shalimar*

**Observational Study**

- 1438** Polymorphism AGT2 (rs4762) is involved in the development of dermatologic events: Proof-of-concept in hepatocellular carcinoma patients treated with sorafenib

*Sapena V, Iavarone M, Boix L, Facchetti F, Guarino M, Sanduzzi Zamparelli M, Granito A, Samper E, Scartozzi M, Corominas J, Marisi G, Diaz A, Casadei-Gardini A, Gramantieri L, Lampertico P, Morisco F, Torres F, Bruix J, Reig M*

- 1459** Hepatobiliary phases in magnetic resonance imaging using liver-specific contrast for focal lesions in clinical practice

*Fernandes DA, Dal Lago EA, Oliver FA, Loureiro BMC, Martins DL, Penachim TJ, Barros RHO, Araújo Filho JAB, Eloy da Costa LB, da Silva AMO, de Ataíde EC, Boin IFSF, Caserta NMG*

- 1470** Efficacy and safety of COVID-19 vaccination in patients with cirrhosis

*Ivashkin V, Ismailova A, Dmitrieva K, Maslennikov R, Zharkova M, Aliev S, Bakhitov V, Marcinkevich V*

- 1480** Pre-sarcopenia and Mac-2 binding protein glycosylation isomer as predictors of recurrence and prognosis of early-stage hepatocellular carcinoma

*Nakai M, Morikawa K, Hosoda S, Yoshida S, Kubo A, Tokuchi Y, Kitagataya T, Yamada R, Ohara M, Sho T, Suda G, Ogawa K, Sakamoto N*

- 1495** Hepatitis C virus burden: Treating and educating people without prejudice

*Merola E, Menotti E, Branz G, Michielan A, Seligmann S, Ratti A, Agugiaro F, Moser L, Vettori G, Franceschini A, Mantovani W, Pertile R, de Pretis G, Pravadelli C*

**Prospective Study**

- 1504** Volumetric assessment of hepatic grafts using a light detection and ranging system for 3D scanning: Preliminary data

*Katsanos G, Karakasi KE, Karolos IA, Kofinas A, Antoniadis N, Tsioukas V, Tsoulfas G*

**CASE REPORT**

- 1512** Hepatitis B virus markers in hepatitis B surface antigen negative patients with pancreatic cancer: Two case reports

*Batskikh S, Morozov S, Kostyushev D*

- 1520** "Starry liver" - Von Meyenburg complex clinical case presentation and differential diagnosis discussion: A case report

*Priadko K, Niosi M, Vitale LM, De Sio C, Romano M, De Sio I*

### **RETRACTION NOTE**

- 1528** Retraction Note: Screening and identification of bioactive compounds from citrus against non-structural protein 3 protease of hepatitis C virus genotype 3a by fluorescence resonance energy transfer assay and mass spectrometry

*Khan M, Rauf W, Habib FE, Rahman M, Iqbal M*



**ABOUT COVER**

Editorial Board Member of *World Journal of Hepatology*, Fan-Pu Ji, MD, PhD, Professor, Doctor, Department of Infectious Diseases, The Second Affiliated Hospital of Xi'an Jiaotong University, Xi'an 710004, Shaanxi Province, China. [infection@xjtu.edu.cn](mailto:infection@xjtu.edu.cn)

**AIMS AND SCOPE**

The primary aim of *World Journal of Hepatology* (*WJH*, *World J Hepatol*) is to provide scholars and readers from various fields of hepatology with a platform to publish high-quality basic and clinical research articles and communicate their research findings online.

*WJH* mainly publishes articles reporting research results and findings obtained in the field of hepatology and covering a wide range of topics including chronic cholestatic liver diseases, cirrhosis and its complications, clinical alcoholic liver disease, drug induced liver disease autoimmune, fatty liver disease, genetic and pediatric liver diseases, hepatocellular carcinoma, hepatic stellate cells and fibrosis, liver immunology, liver regeneration, hepatic surgery, liver transplantation, biliary tract pathophysiology, non-invasive markers of liver fibrosis, viral hepatitis.

**INDEXING/ABSTRACTING**

The *WJH* is now abstracted and indexed in PubMed, PubMed Central, Emerging Sources Citation Index (Web of Science), Scopus, Reference Citation Analysis, China National Knowledge Infrastructure, China Science and Technology Journal Database, and Superstar Journals Database. The 2022 edition of Journal Citation Reports® cites the 2021 Journal Citation Indicator (JCI) for *WJH* as 0.52. The *WJH*'s CiteScore for 2021 is 3.6 and Scopus CiteScore rank 2021: Hepatology is 42/70.

**RESPONSIBLE EDITORS FOR THIS ISSUE**

Production Editor: Yi-Xuan Cai; Production Department Director: Xiang Li; Editorial Office Director: Xiang Li.

**NAME OF JOURNAL**

*World Journal of Hepatology*

**ISSN**

ISSN 1948-5182 (online)

**LAUNCH DATE**

October 31, 2009

**FREQUENCY**

Monthly

**EDITORS-IN-CHIEF**

Nikolaos Pyrsopoulos, Ke-Qin Hu, Koo Jeong Kang

**EDITORIAL BOARD MEMBERS**

<https://www.wjnet.com/1948-5182/editorialboard.htm>

**PUBLICATION DATE**

July 27, 2022

**COPYRIGHT**

© 2022 Baishideng Publishing Group Inc

**INSTRUCTIONS TO AUTHORS**

<https://www.wjnet.com/bpg/gerinfo/204>

**GUIDELINES FOR ETHICS DOCUMENTS**

<https://www.wjnet.com/bpg/GerInfo/287>

**GUIDELINES FOR NON-NATIVE SPEAKERS OF ENGLISH**

<https://www.wjnet.com/bpg/gerinfo/240>

**PUBLICATION ETHICS**

<https://www.wjnet.com/bpg/GerInfo/288>

**PUBLICATION MISCONDUCT**

<https://www.wjnet.com/bpg/gerinfo/208>

**ARTICLE PROCESSING CHARGE**

<https://www.wjnet.com/bpg/gerinfo/242>

**STEPS FOR SUBMITTING MANUSCRIPTS**

<https://www.wjnet.com/bpg/GerInfo/239>

**ONLINE SUBMISSION**

<https://www.f6publishing.com>



## Prospective Study

# Volumetric assessment of hepatic grafts using a light detection and ranging system for 3D scanning: Preliminary data

Georgios Katsanos, Konstantina-Eleni Karakasi, Ion-Anastasios Karolos, Athanasios Kofinas, Nikolaos Antoniadis, Vassilios Tsioukas, Georgios Tsoulfas

**Specialty type:** Gastroenterology and hepatology

### Provenance and peer review:

Invited article; Externally peer reviewed.

**Peer-review model:** Single blind

### Peer-review report's scientific quality classification

Grade A (Excellent): A  
Grade B (Very good): B  
Grade C (Good): C  
Grade D (Fair): 0  
Grade E (Poor): 0

**P-Reviewer:** Wang P, China; Yao Y, China

**Received:** January 30, 2022

**Peer-review started:** January 30, 2022

**First decision:** March 7, 2022

**Revised:** April 10, 2022

**Accepted:** June 27, 2022

**Article in press:** June 27, 2022

**Published online:** July 27, 2022



**Georgios Katsanos, Konstantina-Eleni Karakasi, Athanasios Kofinas, Nikolaos Antoniadis, Georgios Tsoulfas,** Department of Transplantation, Medical School, Aristotle University of Thessaloniki, Hippokration General Hospital, Thessaloniki 54642, Greece

**Ion-Anastasios Karolos, Vassilios Tsioukas,** Department of Rural and Surveying Engineering, Aristotle University of Thessaloniki, Thessaloniki 54642, Greece

**Corresponding author:** Georgios Tsoulfas, FACS, FICS, MD, PhD, Professor, Department of Transplantation, Medical School, Aristotle University of Thessaloniki, Hippokration General Hospital, No. 49 Konstantinoupoleos Street, Thessaloniki 54642, Greece. [tsoulfasg@gmail.com](mailto:tsoulfasg@gmail.com)

## Abstract

### BACKGROUND

Liver transplantation has evolved into a safe life-saving operation and remains the golden standard in the treatment of end stage liver disease. The main limiting factor in the application of liver transplantation is graft shortage. Many strategies have been developed in order to alleviate graft shortage, such as living donor partial liver transplantation and split liver transplantation for adult and pediatric patients. In these strategies, liver volume assessment is of paramount importance, as size mismatch can have severe consequences in the success of liver transplantation.

### AIM

To evaluate the safety, feasibility, and accuracy of light detection and ranging (LIDAR) 3D photography in the prediction of whole liver graft volume and mass.

### METHODS

Seven liver grafts procured for orthotopic liver transplantation from brain deceased donors were prospectively measured with an LIDAR handheld camera and their mass was calculated and compared to their actual weight.

### RESULTS

The mean error of all measurements was 17.03 g (range 3.56-59.33 g). Statistical analysis of the data yielded a Pearson correlation coefficient index of 0.9968, indicating a strong correlation between the values and a Student's *t*-test *P* value of 0.26. Mean accuracy of the measurements was calculated at 97.88%.

## CONCLUSION

Our preliminary data indicate that LIDAR scanning of liver grafts is a safe, cost-effective, and feasible method of *ex vivo* determination of whole liver volume and mass. More data are needed to determine the precision and accuracy of this method.

**Key Words:** Light detection and ranging; Graft volume; 3dscan; *Ex vivo* volumetry; Liver grafts

©The Author(s) 2022. Published by Baishideng Publishing Group Inc. All rights reserved.

**Core Tip:** Liver transplantation (LT) is the golden standard in the treatment of end stage liver disease. The main limiting factor in the application of LT is graft shortage and over the years, many strategies have been developed in order to increase graft availability, such as living donor liver transplantation and split liver transplantation. In these strategies, liver volume assessment is of paramount importance in the success of LT. In this preliminary proof-of-concept study, we evaluated the use of light detection and ranging (LIDAR) technology for *ex vivo* measurement of hepatic grafts. Preliminary data indicate that LIDAR scanning of liver grafts is a safe, cost-effective, and feasible method of *ex vivo* determination of whole liver volume and mass.

**Citation:** Katsanos G, Karakasi KE, Karolos IA, Kofinas A, Antoniadis N, Tsioukas V, Tsoulfas G. Volumetric assessment of hepatic grafts using a light detection and ranging system for 3D scanning: Preliminary data. *World J Hepatol* 2022; 14(7): 1504-1511

**URL:** <https://www.wjgnet.com/1948-5182/full/v14/i7/1504.htm>

**DOI:** <https://dx.doi.org/10.4254/wjh.v14.i7.1504>

## INTRODUCTION

Liver transplantation (LT) has evolved into a safe life-saving operation and remains the golden standard in the treatment of end stage liver disease[1]. The main limiting factor in the application of LT in the vast range of diseases that progress to end stage liver failure, as well as in the developing transplant oncology, is graft shortage, affecting thousands of adult and pediatric patients[2].

Over the years, many strategies have been developed in order to alleviate graft shortage, such as living donor liver transplantation[3] and split liver transplantation[4]. In these strategies, liver volume assessment is of paramount importance, as size mismatch can have severe consequences in the success of LT[5].

Although several techniques have been developed in order to assess liver graft volumes, few data and methods can accurately calculate partial split graft volumes in split liver transplantation[6], especially in the scenario of donors that have not been subjected to abdominal imaging studies.

Reality capture, on the other hand, is the use of various technical means to capture a digital 3D model representation of a subject from the real world. Recent technological advancements have made reality capture hardware such as light detection and ranging (LIDAR) 3D technology available to the public at reasonable prices. This technology has a multitude of applications and its value has not been extensively explored in liver surgery and liver transplantation[7,8]. We conducted a preliminary proof-of-concept study in order to evaluate the feasibility, safety, and accuracy of 3D LIDAR scanning photography of whole liver grafts and the prediction of liver volume and mass.

## MATERIALS AND METHODS

Seven liver grafts procured for orthotopic liver transplantation from brain deceased donors were prospectively measured in this single blind, ongoing study. During the standard back table procedure, grafts were weighed and their mass in grams was recorded using a DSW200D weight scale (DELMAC Group, Athens, Greece). Before graft storage in the traditional nylon bags, the graft was placed on a flat sterile surface and photographed using an Original Structure 3D Scanning Sensor from the Occipital company (Occipital inc., Boulder, United States) (Figure 1). This particular sensor can be adapted to any device with the iOS and iPadOS operating system (Figure 2A), using a special bracket suitable for each corresponding model of iPhone or iPad of the end user. For the purposes of this study, an iPad (6th generation; Apple Inc., California, United States) was used (Figure 2B). The structure sensor communicates with the iPad *via* a USB to a lightning cable, while the 3D scanning process is done using a suitable iPadOS compatible application provided by Occipital. This application provides the user with



DOI: 10.4254/wjh.v14.i7.1504 Copyright ©The Author(s) 2022.

**Figure 1** Liver graft measurement using an original structure 3D scanning sensor.



DOI: 10.4254/wjh.v14.i7.1504 Copyright ©The Author(s) 2022.

**Figure 2** The particular sensor can be adapted to any device with iOS and iPadOS operating system. A: The device used in the present study. The structure core sensor, the adjustment bracket, the USB communication cable, and the iPad (6<sup>th</sup> generation) are shown; B: The Occipital original structure sensor; C: An exported 3D model of a liver graft; D: The final 3D model of the liver graft.

the ability to convert the point cloud resulting from the scanning process into a Mesh 3D digital .obj format. The Occipital structure sensor is a mobile based structure light system (SLS). This SLS consists of a laser-emitting diode, an infrared radiation range projector, and an infrared sensor and the iPad's RGB sensor that provide measuring data to an included system on a chip (SOC) for processing. The output stream from the structure sensor alone consists of a point dataset, with a VGA resolution ( $640 \times 480$  pixels), where every pixel records the distance from sensor to the target. The infrared sensor records the reflectance intensity of the infrared (IR) light pattern projected by the IR projector onto the target while its SOC triangulates the 3D scene using specific algorithmic patterns. The main advantage of the above procedure is that the extraction of the 3D model does not require any kind of contact with the physical object (in our case the liver transplant). All measurements were conducted in fully sterile conditions with no contact with the grafts. All measurements lasted less than 3 min.

After completing the 3D reconstruction of the liver graft, the final .obj model is imported into the 3D Mesh and Point Cloud management and editing software, the 3D Slicer, a free, open source and multi-platform software package used for medical, biomedical, and related imaging research. A detailed view of an exported model participating in this study is shown in [Figure 2C](#).



To extract the final volume of the liver model, the part of the surface on which the implant is placed (blue background) is removed from the model. The side of the graft that is in contact with the table is considered as a completely flat surface (Figure 2D). The complete flowchart of the procedure is presented on Figure 3.

In this study, mass and volume calculations were conducted by two separate teams that were blinded as to the other team's results and measurements.

LIDAR calculated volume was converted into mass using a fixed value of liver density defined by convention at 1.07 gr/mL[9,10].

Calculated liver mass was compared to the actual weighted liver mass of each graft.

### Statistical analysis

R studio for windows (R studio, Boston MA, United States) version 4.1.1 was used to perform all the statistical analyses employing packages "rstatix" and "tidyverse".

## RESULTS

From June 2021 until January 2022, seven liver grafts from deceased donors were included in the study. The average donor age was 52.4 years, and the men-to-women ratio was 3:4. Apart from gender and age, we recorded weight, height, body mass index, and body surface area (BSA). Liver core biopsy was performed for all liver grafts as a standard practice in our department. Donor demographics are presented in Table 1. Graft weight was measured in grams (g). LIDAR imaging analysis provided the calculated graft volumes expressed in millilitres (mL). Considering the mean human liver density at 1.07 g/mL, calculated LIDAR volumes were converted to mass in grams by multiplying the volumes by 1.07. The theoretical volume of the grafts was also recorded using the Vauthey-Abdalla formula[11] [total liver volume =  $-794.41 + 1267.28 \times \text{body surface area}$ ]. Table 2 depicts the results.

The mean duration of the measurement was 123 (74-171) s. No incidence was recorded during the procedure, which was conducted during the usual graft preparation by the surgical team. One graft was discarded due to severe steatosis. In the other six grafts, no cases of graft dysfunction or non-function were recorded in the subsequent transplantation.

LIDAR assisted graft volume and mass calculation results were compared with the actual weighed mass of the grafts. The mean error of all measurements was 17.03 g (range 3.56-59.33 g). Initially, data fluctuation analysis was performed for one factor (ANOVA). Average values, fluctuation, and degrees of freedom were calculated, and the null hypothesis ( $F < F_{\text{crit}}$ ) was confirmed (Table 3). Statistical analysis of the data yielded a Pearson correlation coefficient index of 0.9968, indicating a strong correlation between the values and a Student's *t*-test *P* value of 0.26. Mean accuracy of the measurements was calculated at 97.88%. Results are depicted in Figure 4.

## DISCUSSION

Liver graft mass and volume and their relations to recipient somatometric characteristics are essential factors for the outcome of LT. Although in standard whole liver adult to adult orthotopic LT, size is usually not an issue and the already existing methods of graft volume evaluation might be sufficient, accurate prediction of partial liver volumes in living donor[12] and split liver transplantation presents a more complex challenge[13]. Up to date, the main methods for partial liver volume calculation rely on preoperative imaging studies[14,15], which present their own set of challenges[16]. In the present work, we conducted a preliminary proof-of-concept study for the evaluation of the available handheld LIDAR technology for the evaluation of hepatic graft volume, as the first step in the development of a method that could eventually accurately estimate partial split liver volumes of grafts evaluated for split liver transplantation. The use of whole grafts aimed at calibrating the method and detecting eventual technical issues, as well as overcoming the technical issues associated with the split liver surgical technique and the fact that split liver transplantation is not currently performed in Greece. Our preliminary data tend to validate the concept of the study; however, it does not have a valuable clinical application *per se*, as whole liver mass and volume can be easily calculated by simply weighing the graft or by the water displacement method. However, due to the asymmetric structure of the liver, the calculation of partial liver volumes is more complex, and the existing mathematic formulas cannot accurately predict the segmental hepatic volumes that can vary considerably between patients[17], leaving the preoperative imaging studies of the graft in the form of either a computed tomography (CT) or magnetic resonance imaging (MRI) scan as the most used and valuable option. LIDAR assisted liver volumetry could add a useful tool for *ex vivo* partial liver volume calculation mainly in cases of split liver transplantation for donors that for various reasons did not have a pre-procurement CT or MRI study. Compared to traditional methods for liver volumetry such as CT and MRI, LIDAR volumetric assessment is more cost-effective, less time-consuming, and less operator-dependent. Triple phase liver

**Table 1 Donor demographics.**

N	Gender	Age (yr)	Cause of death	Graft steatosis (%)	Weight (kg)	Height (m)	BMI (kg/m <sup>2</sup> )	BSA (m <sup>2</sup> )
1	Female	59	IBI	> 10	60	1.6	23.43	1.76
2	Male	32	IBI	> 10	75	1.7	25.95	1.88
3	Male	64	SH	> 10	85	1.75	27.75	2.03
4	Female	63	ICH	60	70	1.6	27.34	2.06
5	Female	46	ICH	5	90	1.7	31.14	2.41
6	Female	54	ICH	20	120	1.75	39.18	1.63
7	Male	49	IBI	> 10	75	1.83	22.39	1.95

N: Donor number; BMI: Body mass index; BSA: Body surface area; IBI: Ischemic brain injury; SB: Subarachnoid haemorrhage; ICH: Intracerebral haemorrhage.

**Table 2 Results**

N	Graft weight (g)	LIDAR volume (mL)	Vauthey volume (mL)	LIDAR estimated graft mass (g)	LIDAR error (g)	LIDAR error (%)
1	1202	1179	1275.04	1261.53	59.53	4.95
2	1623	1490	1590.52	1594.30	-28.70	-1.77
3	2201	2090	1781.61	2236.30	35.30	1.60
4	1332	1248	1440.86	1335.36	3.36	0.25
5	1227	1141	1818.15	1220.87	-6.13	-0.50
6	1074	1040	2266.36	1112.80	38.80	3.61
7	1623	1482	1680.03	1585.74	-37.26	-2.30

Estimated graft mass = Light detection and ranging (LIDAR) volume mL  $\times$  1.07 gr/mL. The LIDAR error is calculated by subtracting the LIDAR estimated liver mass from the actual mass (weight) of the grafts. N: Donor number; g: Grams; LIDAR: Light detection and ranging.

**Table 3 ANOVA: Single factor**

Source of Variation	SD	df	MS	F	F crit
Between groups	225616.3945	2	112808.1972	0.861884735	3.554557
Within groups	2355938.641	18	130885.4801		
Total	2581555.035	20			

SD: Standard deviation; df: Degrees of freedom; MS: Mean squares; F crit: F critical.

CT scans or MRI scans can be difficult to obtain even in tertiary hospitals, let alone in the setting of a small rural donor hospital. Moreover, the multi-organ donor is not burdened with intravenous contrast media administration, which may affect kidney function. Liver 3D model capture using the LIDAR camera is performed *ex vivo*, just after backtable liver preparation, in less than 3 min and under sterile conditions. Actual volume measurement is done utilizing an open, free software package without the need of an expert radiologist. One obvious drawback in comparison to preoperative donor imaging is that the internal anatomy of the liver cannot be assessed and surgical plane planning is not possible. Another issue is that liver volume is measured during a state of non-perfusion, so liver mass and volume may differ if compared to a perfused organ *in vivo*[10]. LIDAR assisted volumetry showed a better accuracy than the theoretical volume calculation using the VAUTHEY formula. This is probably mainly due to the lack of precise donor data (mainly donor weight), as many rural hospitals do not have the ability to weigh bedridden patients and the donor weight data derive from crude estimation or medical records. Finally, the main flaw of the present study is the inability to scan the inferior surface of the liver and segment I, which lie against a flat surface, and by convention this surface is considered

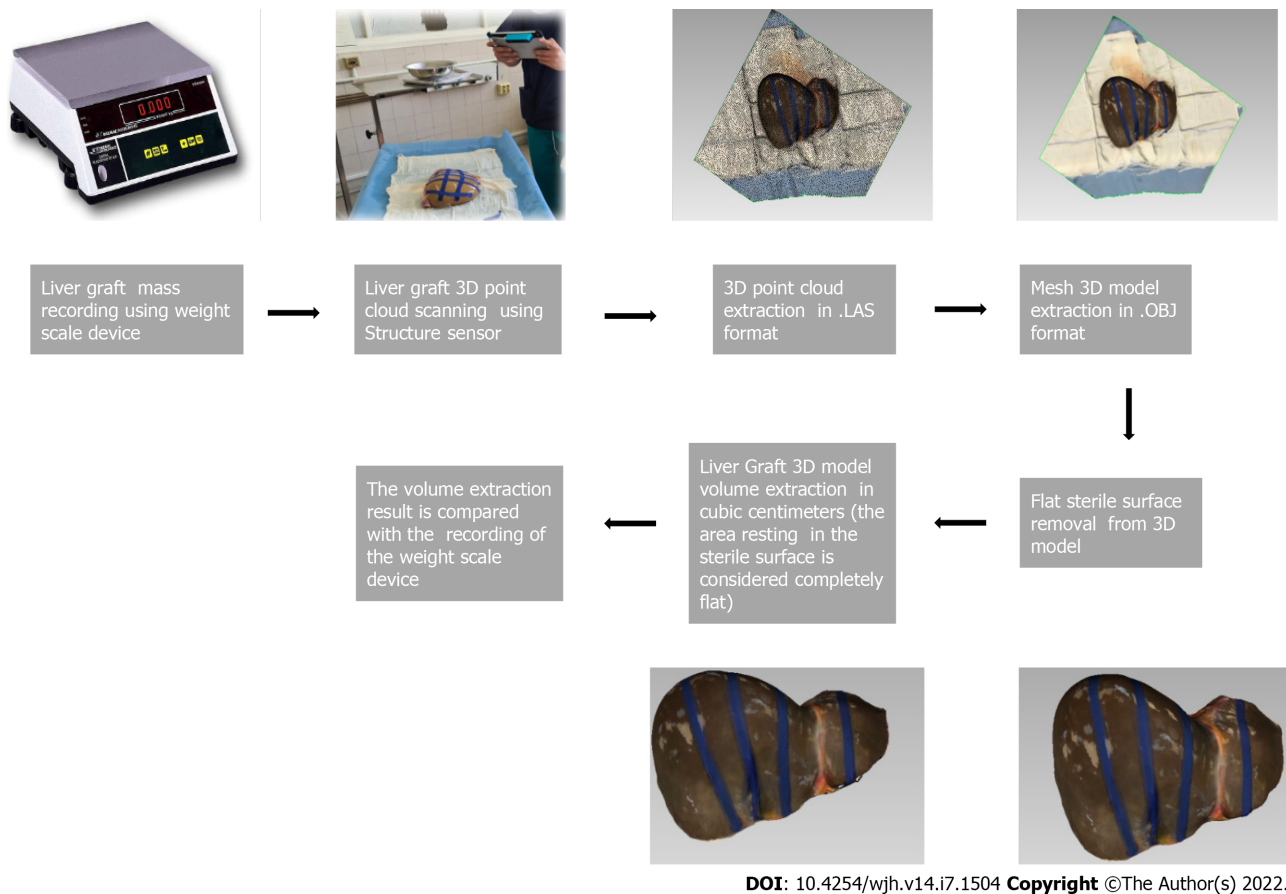


Figure 3 Flowchart of the light detection and ranging assisted volumetric assessment of liver grafts.

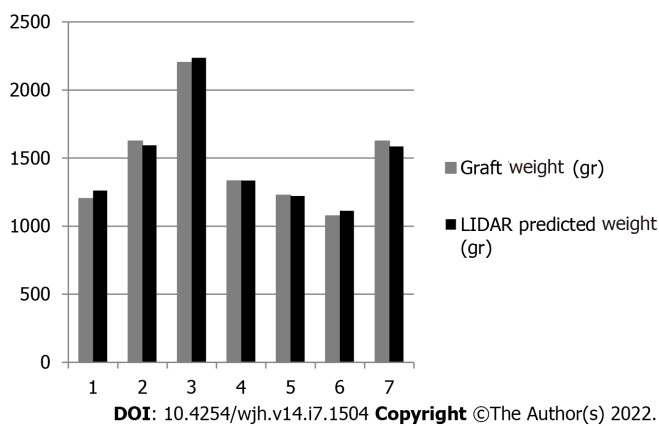


Figure 4 Results of light detection and ranging assisted prediction of whole liver mass in grams in the seven liver grafts.

completely flat in our calculations. The subsequent steps in this ongoing study will be the refinement of the measuring technique, and the evaluation of the method in cadaveric livers with simulation of the *ex situ* splitting procedure and measurement of partial liver volumes (mainly left lateral section volumes), before moving in the actual setting of real world split liver transplantation.

## CONCLUSION

Our preliminary data indicate that LIDAR scanning of liver grafts is a safe, cost-effective, and feasible method of *ex vivo* determination of whole liver volume and mass. More data are needed to determine the precision and accuracy of this method.

## ARTICLE HIGHLIGHTS

### Research background

Split liver transplantation is a viable option of increasing the number of available grafts, as one liver graft can yield two partial grafts for two donors. In this procedure, partial liver volume estimation, particularly left lateral segment volume estimation, is critical to the outcome of the procedure.

### Research motivation

To assess the application of light detection and ranging technology in the *ex vivo* estimation of whole liver grafts.

### Research objectives

To evaluate the feasibility, safety, and accuracy of 3D light detection and ranging (LIDAR) scanning photography of whole liver grafts and the prediction of liver volume and mass.

### Research methods

Seven liver grafts procured for orthotopic liver transplantation from brain deceased donors were prospectively measured in this single blind, ongoing study. All measurements were conducted in fully sterile conditions with no contact with the grafts. LIDAR calculated volume was converted into mass using a fixed value of liver density defined by convention at 1.07 gr/mL. Calculated liver mass was compared to the actual weighted liver mass of each graft.

### Research results

From June 2021 until January 2022, seven liver grafts from deceased donors were included in the study. Graft weight was measured in grams (g). LIDAR imaging analysis provided the calculated graft volumes expressed in millilitres (mL). Considering the mean human liver density at 1.07 g/mL, calculated LIDAR volumes were converted to mass in grams by multiplying the volumes by 1.07. Statistical analysis of the data yielded a Pearson correlation coefficient index of 0.9968, indicating a strong correlation between the values, and a Student's *t*-test *P* value of 0.26. Mean accuracy of the measurements was calculated at 97.88%.

### Research conclusions

Our preliminary data indicate that LIDAR scanning of liver grafts is a safe, cost-effective, and feasible method of *ex vivo* determination of whole liver volume and mass. More data are needed to determine the precision and accuracy of this method.

### Research perspectives

LIDAR assisted liver volumetry could add a useful tool for *ex vivo* partial liver volume calculation mainly in cases of split liver transplantation for donors that for various reasons did not have a pre-procurement computed tomography (CT) or magnetic resonance imaging (MRI) study. Compared to traditional methods for liver volumetry such as CT and MRI, LIDAR volumetric assessment is more cost-effective, less time-consuming, and less operator-dependent.

## FOOTNOTES

**Author contributions:** Katsanos G and Karakasi KE contributed equally to this work; Katsanos G, Karakasi KE, and Tsoulfas G designed the research study; Katsanos G, Karakasi KE, Karolos IA, and Kofinas A performed the research; Antoniadis N and Karakasi KE conducted the data analysis and statistical analysis; Katsanos G, Tsoulfas G, and Tsioukas V analyzed the data and wrote the manuscript; Katsanos G, Kofinas A, and Tsoulfas G revised the manuscript; all authors have read and approved the final manuscript.

**Supported by** the European Union and Greek national funds through the Operational Program Competitiveness, Entrepreneurship and Innovation, No. T1EDK-03599.

**Institutional review board statement:** The study was reviewed and approved by the Aristotle University of Thessaloniki Institutional Review Board (Approval No. 3.479).

**Informed consent statement:** All study participants, or their legal guardian, provided written consent prior to study enrollment.

**Conflict-of-interest statement:** All authors of this manuscript having no conflicts of interest to disclose.

**Data sharing statement:** No additional data are available.



**CONSORT 2010 statement:** The authors have read the STROBE Statement—checklist of items, and the manuscript was prepared and revised according to the STROBE Statement—checklist of items.

**Open-Access:** This article is an open-access article that was selected by an in-house editor and fully peer-reviewed by external reviewers. It is distributed in accordance with the Creative Commons Attribution NonCommercial (CC BY-NC 4.0) license, which permits others to distribute, remix, adapt, build upon this work non-commercially, and license their derivative works on different terms, provided the original work is properly cited and the use is non-commercial. See: <https://creativecommons.org/licenses/by-nc/4.0/>

**Country/Territory of origin:** Greece

**ORCID number:** Georgios Katsanos 0000-0002-5845-8175; Konstantina-Eleni Karakasi 0000-0003-2448-556X; Ion-Anastasios Karolos 0000-0003-0491-1293; Athanasios Kofinas 0000-0002-3180-1930; Nikolaos Antoniadis 0000-0002-3988-4515; Vassilios Tsioukas 0000-0002-2104-4315; Georgios Tsoulfas 0000-0001-5043-7962.

**S-Editor:** Wang LL

**L-Editor:** Wang TQ

**P-Editor:** Wang LL

## REFERENCES

- Müller PC, Kabacam G, Vibert E, Germani G, Petrowsky H. Current status of liver transplantation in Europe. *Int J Surg* 2020; **82S**: 22-29 [PMID: 32454252 DOI: 10.1016/j.ijssu.2020.05.062]
- de Ville de Goyet J, Baumann U, Karam V, Verkade HJ. Letter to the editor: Organ shortage and pediatric liver transplantation: David against Goliath.... *Hepatology* 2022; **75**: 1342-1343 [PMID: 35030272 DOI: 10.1002/hep.32342]
- Pomfret EA, Sung RS, Allan J, Kinkhabwala M, Melancon JK, Roberts JP. Solving the organ shortage crisis: the 7th annual American Society of Transplant Surgeons' State-of-the-Art Winter Symposium. *Am J Transplant* 2008; **8**: 745-752 [PMID: 18261169 DOI: 10.1111/j.1600-6143.2007.02146.x]
- Hackl C, Schmidt KM, Süsal C, Döhler B, Zidek M, Schlitt HJ. Split liver transplantation: Current developments. *World J Gastroenterol* 2018; **24**: 5312-5321 [PMID: 30598576 DOI: 10.3748/wjg.v24.i47.5312]
- Reyes J, Perkins J, Kling C, Montenegro M. Size mismatch in deceased donor liver transplantation and its impact on graft survival. *Clin Transplant* 2019; **33**: e13662 [PMID: 31283049 DOI: 10.1111/ctr.13662]
- Radtke A, Sotiropoulos GC, Nadalin S, Molmenti EP, Schroeder T, Lang H, Saner F, Valentin-Gamazo C, Frilling A, Schenk A, Broelsch CE, Malagó M. Preoperative volume prediction in adult living donor liver transplantation: how much can we rely on it? *Am J Transplant* 2007; **7**: 672-679 [PMID: 17229068 DOI: 10.1111/j.1600-6143.2006.01656.x]
- Zalevsky Z, Buller GS, Chen T, Cohen M, Barton-Grimley R. Light detection and ranging (lidar): introduction. *J Opt Soc Am A Opt Image Sci Vis* 2021; **38**: L1D1-L1D2 [PMID: 34807027 DOI: 10.1364/JOSAA.445792]
- Svanberg S, Zhao G, Zhang H, Huang J, Lian M, Li T, Zhu S, Li Y, Duan Z, Lin H, Svanberg K. Laser spectroscopy applied to environmental, ecological, food safety, and biomedical research. *Opt Express* 2016; **24**: A515-A527 [PMID: 27136872 DOI: 10.1364/OE.24.00A515]
- Overmoyer BA, McLaren CE, Brittenham GM. Uniformity of liver density and nonheme (storage) iron distribution. *Arch Pathol Lab Med* 1987; **111**: 549-554 [PMID: 3579513]
- Niehues SM, Unger JK, Malinowski M, Neymeyer J, Hamm B, Stockmann M. Liver volume measurement: reason of the difference between in vivo CT-volumetry and intraoperative ex vivo determination and how to cope it. *Eur J Med Res* 2010; **15**: 345-350 [PMID: 20947471 DOI: 10.1186/2047-783x-15-8-345]
- Vauthey JN, Abdalla EK, Doherty DA, Gertsch P, Fenstermacher MJ, Loyer EM, Lerut J, Materne R, Wang X, Encarnacion A, Herron D, Mathey C, Ferrari G, Charnsangavej C, Do KA, Denys A. Body surface area and body weight predict total liver volume in Western adults. *Liver Transpl* 2002; **8**: 233-240 [PMID: 11910568 DOI: 10.1053/jlts.2002.31654]
- Radtke A, Sgourakis G, Molmenti EP, Beckebaum S, Cicinnati V, Broelsch CE, Peitgen HO, Malagó M, Schroeder T. Computer-assisted surgical planning in adult-to-adult live donor liver transplantation: how much does it help? *Transplantation* 2012; **94**: 1138-1144 [PMID: 23222737 DOI: 10.1097/TP.0b013e31826e5970]
- Lauterio A, Di Sandro S, Concone G, De Carlis R, Giacomoni A, De Carlis L. Current status and perspectives in split liver transplantation. *World J Gastroenterol* 2015; **21**: 11003-11015 [PMID: 26494957 DOI: 10.3748/wjg.v21.i39.11003]
- Simpson AL, Geller DA, Hemming AW, Jarnagin WR, Clements LW, D'Angelica MI, Dumpuri P, Gönen M, Zendejas I, Miga MI, Stefansic JD. Liver planning software accurately predicts postoperative liver volume and measures early regeneration. *J Am Coll Surg* 2014; **219**: 199-207 [PMID: 24862883 DOI: 10.1016/j.jamcollsurg.2014.02.027]
- Reichman TW, Fiorello B, Carmody I, Bohorquez H, Cohen A, Seal J, Bruce D, Loss GE. Using on-site liver 3-D reconstruction and volumetric calculations in split liver transplantation. *Hepatobiliary Pancreat Dis Int* 2016; **15**: 587-592 [PMID: 27919847 DOI: 10.1016/s1499-3872(16)60155-8]
- Lim MC, Tan CH, Cai J, Zheng J, Kow AW. CT volumetry of the liver: where does it stand in clinical practice? *Clin Radiol* 2014; **69**: 887-895 [PMID: 24824973 DOI: 10.1016/j.crad.2013.12.021]
- Abdalla EK, Denys A, Chevalier P, Nemr RA, Vauthey JN. Total and segmental liver volume variations: implications for liver surgery. *Surgery* 2004; **135**: 404-410 [PMID: 15041964 DOI: 10.1016/j.surg.2003.08.024]



Published by **Baishideng Publishing Group Inc**  
7041 Koll Center Parkway, Suite 160, Pleasanton, CA 94566, USA

**Telephone:** +1-925-3991568

**E-mail:** [bpgoffice@wjgnet.com](mailto:bpgoffice@wjgnet.com)

**Help Desk:** <https://www.f6publishing.com/helpdesk>

<https://www.wjgnet.com>

