

World Journal of *Radiology*

World J Radiol 2022 July 28; 14(7): 180-248



EVIDENCE REVIEW

- 180 Expanding utility of cardiac computed tomography in infective endocarditis: A contemporary review
Hughes D, Linchangco R, Reyalde R, Xu B

MINIREVIEWS

- 194 Molecular imaging as a tool for evaluation of COVID-19 sequelae – A review of literature
Chandekar KR, Satapathy S, Singh H, Bhattacharya A
- 209 Radiological review of rhinocerebral mucormycosis cases during the COVID-19 Pandemic: A single-center experience
Saneesh PS, Morampudi SC, Yelamanchi R
- 219 Impact of X-radiation in the management of COVID-19 disease
Aishwarya T A, Mohan DK, Nandhini K, Raavi V, Perumal V

ORIGINAL ARTICLE**Retrospective Study**

- 229 Type 2 dynamic curves: A diagnostic dilemma
Karavas E, Ece B, Aydın S

SYSTEMATIC REVIEWS

- 238 Catheter-based renal sympathetic nerve denervation on hypertension management outcomes
Singh SP, Varghese KJ, Qureshi FM, Anderson MC, Foxworth J, Knuepfer MM

ABOUT COVER

Editorial Board Member of *World Journal of Radiology*, Ying-Wei Fan, PhD, Associate Research Professor, Department of Biomedical Engineering, School of Medical Technology, Beijing Institute of Technology, Beijing 100081, China. fanyingwei@bit.edu.cn

AIMS AND SCOPE

The primary aim of *World Journal of Radiology* (WJR, *World J Radiol*) is to provide scholars and readers from various fields of radiology with a platform to publish high-quality basic and clinical research articles and communicate their research findings online.

WJR mainly publishes articles reporting research results and findings obtained in the field of radiology and covering a wide range of topics including state of the art information on cardiopulmonary imaging, gastrointestinal imaging, genitourinary imaging, musculoskeletal imaging, neuroradiology/head and neck imaging, nuclear medicine and molecular imaging, pediatric imaging, vascular and interventional radiology, and women's imaging.

INDEXING/ABSTRACTING

The WJR is now abstracted and indexed in PubMed, PubMed Central, Emerging Sources Citation Index (Web of Science), Reference Citation Analysis, China National Knowledge Infrastructure, China Science and Technology Journal Database, and Superstar Journals Database. The 2022 edition of Journal Citation Reports® cites the 2021 Journal Citation Indicator (JCI) for WJR as 0.48.

RESPONSIBLE EDITORS FOR THIS ISSUE

Production Editor: Wen-Wen Qi; Production Department Director: Xu Guo; Editorial Office Director: Jia-Ping Yan.

NAME OF JOURNAL

World Journal of Radiology

ISSN

ISSN 1949-8470 (online)

LAUNCH DATE

January 31, 2009

FREQUENCY

Monthly

EDITORS-IN-CHIEF

Thomas J Vogl

EDITORIAL BOARD MEMBERS

<https://www.wjgnet.com/1949-8470/editorialboard.htm>

PUBLICATION DATE

July 28, 2022

COPYRIGHT

© 2022 Baishideng Publishing Group Inc

INSTRUCTIONS TO AUTHORS

<https://www.wjgnet.com/bpg/gerinfo/204>

GUIDELINES FOR ETHICS DOCUMENTS

<https://www.wjgnet.com/bpg/gerinfo/287>

GUIDELINES FOR NON-NATIVE SPEAKERS OF ENGLISH

<https://www.wjgnet.com/bpg/gerinfo/240>

PUBLICATION ETHICS

<https://www.wjgnet.com/bpg/gerinfo/288>

PUBLICATION MISCONDUCT

<https://www.wjgnet.com/bpg/gerinfo/208>

ARTICLE PROCESSING CHARGE

<https://www.wjgnet.com/bpg/gerinfo/242>

STEPS FOR SUBMITTING MANUSCRIPTS

<https://www.wjgnet.com/bpg/gerinfo/239>

ONLINE SUBMISSION

<https://www.f6publishing.com>



Radiological review of rhinocerebral mucormycosis cases during the COVID-19 Pandemic: A single-center experience

P S Saneesh, Satya Chowdary Morampudi, Raghav Yelamanchi

Specialty type: Radiology, nuclear medicine and medical imaging

Provenance and peer review:

Invited article; Externally peer reviewed.

Peer-review model: Single blind

Peer-review report's scientific quality classification

Grade A (Excellent): A

Grade B (Very good): 0

Grade C (Good): C

Grade D (Fair): D

Grade E (Poor): 0

P-Reviewer: Chavan RP, India; Fan YW, China; Roushdy TM, Egypt

Received: March 28, 2022

Peer-review started: March 28, 2022

First decision: May 12, 2022

Revised: June 9, 2022

Accepted: July 18, 2022

Article in press: July 18, 2022

Published online: July 28, 2022



P S Saneesh, Department of Radiology, Aster MIMS, Kannur 670007, Kerala, India

Satya Chowdary Morampudi, Department of Radiodiagnosis, Pinnamaneni Siddhartha Institute of Medical Sciences & Research Foundation, Gannavaram 521101, Andhra Pradesh, India

Raghav Yelamanchi, Department of Surgery, Atal Bihari Vajpayee Institute of Medical Sciences and Dr. Ram Manohar Lohia Hospital, Delhi 110001, Delhi, India

Corresponding author: Raghav Yelamanchi, DNB, MS, Surgeon, Surgical Oncologist, Department of Surgery, Atal Bihari Vajpayee Institute of Medical Sciences and Dr. Ram Manohar Lohia Hospital, Delhi 110001, Delhi, India. raghavyelamanchi@gmail.com

Abstract

Mucormycosis is caused by the fungi belonging to the order *Mucorales* and class *Zygomycetes*. The incidence of mucormycosis has increased with the onset of the severe acute respiratory syndrome coronavirus 2 infections leading to the coronavirus disease 2019 (COVID-19) pandemic. This rise is attributed to the use of immunosuppressive medication to treat COVID-19 infections. Authors have retrospectively collected data of our cases of mucormycosis diagnosed from April 2020 to April 2021 at our institute. A total of 20 patients with rhinocerebral mucormycosis were studied. Most of the study subjects were male patients (90%) and were of the age group 41-50 years. Most patients in the review had comorbidities (85%) with diabetes being the most common comorbidity. Para nasal sinuses were involved in all the cases. Involvement of the neck spaces was present in 60% of the cases. Involvement of the central nervous system was present in 80% of the cases. Orbital involvement was present in 90% of the cases. The authors reviewed the various imaging findings of mucormycosis on computed tomography and magnetic resonance imaging in this article.

Key Words: Mucormycosis; Rhinocerebral infections; Fungal sinusitis; Medical imaging; Radiodiagnosis; COVID-19 pandemic

©The Author(s) 2022. Published by Baishideng Publishing Group Inc. All rights reserved.

Core Tip: Rhinocerebral mucormycosis constituted the aftermath of the coronavirus disease 2019 pandemic, leading to rapid increase in the number of cases, which were previously restricted only to few susceptible groups of patients. Rhinocerebral mucormycosis is associated with high mortality and morbidity. After clinical examination, imaging is the backbone for the diagnosis of this severe disease. Computed tomography helps in the preliminary diagnosis and helps to stage the disease. However, when orbital and intracranial extension is present, magnetic resonance imaging (MRI) is preferred because it delineates the involvement of these structures better. MRI can also delineate vascular involvement better. This article reviews the various imaging findings of mucormycosis.

Citation: Saneesh PS, Morampudi SC, Yelamanchi R. Radiological review of rhinocerebral mucormycosis cases during the COVID-19 Pandemic: A single-center experience. *World J Radiol* 2022; 14(7): 209-218

URL: <https://www.wjgnet.com/1949-8470/full/v14/i7/209.htm>

DOI: <https://dx.doi.org/10.4329/wjr.v14.i7.209>

INTRODUCTION

Mucormycosis is caused by fungi belonging to the order *Mucorales* and class *Zygomycetes*[1]. Fungal spores that are present in the air constitute a source of infection. However, these fungi rarely infect healthy individuals, as normal host defense mechanisms prevent invasion by these organisms. However, when host defense mechanisms are weakened due to several factors, such as congenital disorders, acquired immunodeficiency syndrome, hematological malignancies, uncontrolled systemic illnesses, and the use of immunosuppressive medication, these organisms invade and proliferate in human tissues. The incidence of mucormycosis has increased over the past few years due to the aging population, medical comorbidities, the increase in the incidence of malignancies, and the pandemic of human immunodeficiency virus infection[2].

The situation has worsened with the onset of the severe acute respiratory syndrome coronavirus 2 infections, which has led to the coronavirus disease 2019 (COVID-19) pandemic that began in late 2019 and has continued till the present. The main pathogenesis of the complications of this viral infection is due to the excessive immunological response that leads to damage to host's own tissues[3]. This has resulted in the use of immunosuppressive medication in the form of corticosteroids, interleukin antagonists, and various antibodies to counter the inflammatory cytokines. These drugs have proved to be efficacious in dealing with the complications and cytokine storm of COVID-19. However, they come with serious side effects of immunosuppression.

The number of cases of mucormycosis has rapidly increased in the last few months. This rise is attributed to the use of immunosuppressive medication to treat COVID-19 infections[4]. The paranasal sinuses and lungs, being the first spaces to come in contact with the fungus, are most commonly affected. Once the disease is established, it spreads to the surrounding structures, such as the orbit, brain, mediastinum, *etc.* The overall mortality of mucormycosis is more than 50%, and the mortality rate for disseminated disease reaches 100%[5]. The infection responds to only a few antifungals, such as amphotericin B, which are very toxic[5].

The authors of the present study have also come across many cases of mucormycosis in the last few months during the times of the COVID-19 pandemic. The following is a mini-review of the radiological findings of the rhinocerebral mucormycosis cases recorded by us in the last few months.

MATERIALS AND METHODS

We have retrospectively collected data on cases of mucormycosis diagnosed from April 2020 to April 2021 at our institute, which is a tertiary care center located in the state of Kerala, India.

All adult patients above the age of 18 years who were diagnosed with mucormycosis by imaging post-COVID-19 infection and confirmed by histopathological examination were studied. Patients with an unknown medical history, absent hospital records, and unknown outcomes were excluded from the review.

Hospital databases in the radiology department of our hospital were searched with the keyword "mucormycosis," and results were obtained. A list of cases was obtained, which was filtered to include only those cases from April 2020 to April 2021. Hospital identification numbers were then used to trace the clinical details and outcomes of the patients. The demographic details of the patients were recorded, and the COVID-19 infection history and treatment history were noted. History of various comorbidities, including malignancies, was obtained from the hospital records. The findings of the CECT scans, which were obtained using a 128-slice dual-energy CT scanner (SOMATOM Definition Flash, Siemens, Germany), were reviewed by the same radiologist to ensure uniformity in reporting. Images were

acquired with 1–3 mm collimation and a pitch of up to 2:1 to allow for coverage of the area of interest in a single breath-hold.

Imaging was repeated at one-month follow-up to study the lesions.

RESULTS

A total of 20 patients with rhinocerebral mucormycosis were studied. Eighteen patients had isolated rhino-cerebral mucormycosis, and two patients had combined pulmonary and rhino-cerebral mucormycosis (Table 1). Most study subjects were male patients (90%). The age distribution of the subjects is as follows: 10% were between 20–30 years of age, 20% were between 31–40 years of age, 30% were between 41–50 years of age, 5% were between 51–60 years of age, 20% were between 61–70 years of age, and 15% were between 71–80 years of age. Most patients in the review had comorbidities (85%): 20% had hematological malignancy, 40% had diabetes, 10% had acquired immunodeficiency syndrome, and 15% were transplant recipients on immunosuppressive medication.

Sinuses were involved in all the cases. Unilateral involvement of the sinuses was more common than bilateral involvement. In most cases (35%), all four sinuses (maxillary, frontal, ethmoid, and sphenoid) were involved. The isolated maxillary sinus was involved in 20% of the cases. The isolated frontal sinus was involved in 5% of the cases. The ethmoid and sphenoid sinuses combined were involved in 10% of the cases. The frontal, ethmoid, and sphenoid sinuses combined were involved in 5% of the cases.

Involvement of the neck spaces was present in 60% of the cases (Table 2). The pterygopalatine space was involved in 50% of the cases. The infratemporal fossa was involved in 40% of the cases. The masticator space, retropharyngeal space, and parapharyngeal spaces were each involved in 10% of the cases.

At one month follow-up, only 50% of the patients survived, 25% had progression of the lesions, 20% had improvement in the lesions, and 5% had static lesions.

There were no cases of isolated cerebral mucormycosis. Involvement of the central nervous system (CNS) was present in 80% of the cases. The involvement of CNS included the following: leptomeningeal enhancement, meningoencephalitis, brain infarcts, brain abscesses, internal carotid artery thrombosis, cavernous sinus thrombosis, dural venous sinus thrombosis, and epidural abscesses.

The involvement of various structures of the CNS is listed in Table 2. Vascular involvement was present in 60% of the patients in our study, with the most common lesion being cavernous sinus thrombosis. Orbital involvement, which included orbital fat involvement, extraocular muscle involvement, and orbital cellulitis, was present in 90% of the cases (Table 2).

DISCUSSION

Most cases of rhinocerebral mucormycosis occurred in males in the present review as in other previous case series and reviews[6,7]. Most patients had comorbidities, with diabetes being the predominant comorbidity as in other previous studies. In the study by Dubey *et al*[8], all post-COVID-19 patients diagnosed with rhinocerebral mucormycosis were diabetic. This also includes new-onset diabetes due to the usage of corticosteroids during the treatment of COVID-19, which is as high as 38.18%[8].

In the present study, similar to the study by Therakathu *et al*[9], unilateral involvement of the sinuses was more common. The ethmoid sinus was the most common sinus to be involved in the present study, followed by the maxillary sinus, as in the studies by Therakathu *et al*[9] and Patel *et al*[10]. In the study by Therakathu *et al*[9], the most common site to be involved other than the sinuses was the orbit (76%) and the face (57%), followed by the orbital apex, masticator space, pterygopalatine fossa, bone, skull base, cavernous sinus, brain, and internal carotid artery. Orbital involvement was also very common in the present study, accounting for 90% of the cases. However, in the study by Patel *et al*[10], orbital involvement was present in only 60% of the cases.

Infection by fungi of the order *Mucorales* begins in the nasal cavity mostly in the middle turbinate and starts spreading, mostly invading the sphenoethmoidal complex[11,12]. As the fungi have the ability to invade the blood vessels and the bony walls, they spread rapidly in immunocompromised hosts and those with chronic debilitating illnesses, to reach the sinus cavity[13]. The necrotic tissue formed due to vascular occlusion acts as a rich niche for the further growth of the organism. Further invasion of the orbits and brain occurs through the foramen and through the sphenopalatine and internal maxillary arteries[14].

The invasion in mucormycosis can be divided into three stages as per Rupa *et al*[15]:

Stage 1: The infection is localized to the nasal cavity and paranasal sinuses.

Stage 2: The infection begins to spread to the peri-sinus areas, which are completely resectable.

Stage 3: The infection spreads into the intracranial cavity and to the surrounding areas of the sinuses, which are partially resectable.

Table 1 Table showing the demographic data and findings of the patients under study

Serial No.	Age	Sex	Co-morbidities	Primary location	Cerebral involvement	Orbital involvement	Involvement of neck spaces
1	34	Male	Acute myeloid leukemia	Right nasal cavity, Right ethmoid, Sphenoid	ICA thrombosis, Cavernous sinus thrombosis, Leptomeningeal enhancement	No	Right pterygopalatine, Right infra temporal, Bilateral parapharyngeal, Retropharyngeal space
2	64	Male	Renal transplant	Pan sinusitis	> Meningoencephalitis, > infiltration into left basifrontal and gangliocapsular region along olfactory fossa	Extra ocular muscles, Orbital cellulitis	No
3	72	Male	Diabetes	Left maxillary, Ethmoid, Frontal, Sphenoid	Ganglio-capsular infarctcavernous sinus thrombosis	Retro- orbitalfat and extra ocular muscles and orbital apex	No
4	50	Male	No	Right maxillary	Cavernous sinus, Subdural abscess	Orbital apex, Orbital abscess	Temporal, pterygopalatine, masticator space
5	40	Male	Post renal transplant	Pan sinus	Cavernous sinus thrombosis, Temporal lobe involvement	Extra conal extension, Right extra ocular muscles, Orbital floor	Infratemporal fossa, pterygopalatine
6	45	Male	Acquired immunodeficiency syndrome	Frontal	ICA thrombosis cavernous sinus thrombosis, Cerebral infarct epidural abscess	Left orbit, Extra ocular muscles	Left pterygopalatine
7	67F	Female	Diabetes	Pan-sinus	Basifrontal brain parenchyma involvement, meningoencephalitis	Orbital apex, extra ocular muscles Subperiosteal abscess	Right infra temporal fossa, retropharyngeal space
8	75	Male	Diabetes	Pan-sinusitis	No cerebral involvement	Extraconal fat involvement	No
9	22	Male	ALL	Right maxillary sinus	ICA thrombosis, Cavernous sinus involvement, Cerebral infarct	Extra ocular muscle, Orbital apex, Subperiosteal abscess	Right Infratemporal fossa, Right pterygopalatine fossa
10	50	Male	Diabetes	Left maxillary sinus	No cerebral involvement	Left extraconal space	No
11	50	Male	Acquired immunodeficiency syndrome	Pan sinusitis	Cavernous sinus, Epidural abscess	Orbital Apex, Extra ocular muscles involvement, Subperiosteal abscess	Pterygopalatine fossa
12	40	Male	Kidney transplant	Frontal, Ethmoid, sphenoid	ICA thrombosis, Temporal lobe abscess	Orbital apex, Extra ocular muscles, Subperiosteal abscess, Cellulitis	No
13	21	Female	Acute lymphocytic leukemia	Right maxillary sinus and nasal cavity	ICA thrombosis, Frontal lobe abscess, Infarct	Extra ocular muscles, Intraconal fat	Pterygopalatine fossa and infratemporal fossa
14	64	Male	Diabetes	Pan sinusitis	Cavernous sinus, Subdural abscess	Orbital apex, Extraocular muscles, Subperiosteal abscess	No
15	48	Male	No	Pan sinusitis	Cavernous sinus, ICA thrombosis	Orbital apex, Extra ocular muscles, Orbital abscess	Pterygopalatine fossa, Infra temporal fossa
16	68	Male	Diabetes	Pan sinusitis	Not involved	Extraconal fat	Pterygopalatine fossa
17	57	Male	Diabetes	Pan sinusitis	Subdural abscess	Extraconal orbital fat, Extra ocular muscles, Orbital cellulitis	Infratemporal fossa
18	71	Male	Diabetes	Sphenoid, Ethmoid, Nasal cavity	Frontal lobe	Orbital apex, Extra ocular muscles	Para pharyngeal space, Pterygopalatine fossa
19	48	Male	No	Right pan sinusitis, Nasal cavity	Frontal lobe, Cavernous sinus	Extraconal fat, extra ocular muscles	No

20	37	Male	Lymphoma	Right sinusitis	Not involved	Extraconal orbital fat	No
----	----	------	----------	-----------------	--------------	------------------------	----

ICA: Internal carotid artery.

Table 2 Table showing the summary of central nervous system involvement, orbital involvement and neck space involvement

Complication/local invasion	N = 20
Cerebral	16/20
Arterial involvement (ICA thrombosis)	6
Cavernous sinus thrombosis	10
Brain Parenchymal involvement	11
Meninges and Dural/epidural involvement	7
Orbit	18/20
Extraocular muscles	14
Orbital apex	9
Orbital fat only/orbital cellulitis/abscess	16
Neck spaces	12/20
Pterygopalatine foramen and fossa	10
Infratemporal fossa	8
Masticator space	2
Retropharyngeal space	2
Parapharyngeal space	2

ICA: Internal carotid artery.

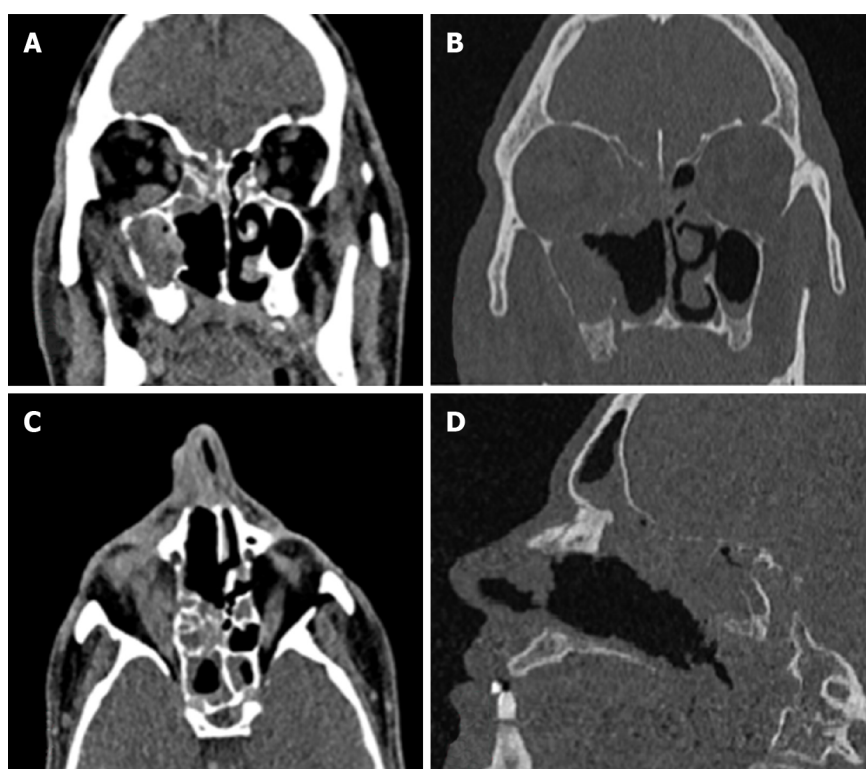Computed tomography appearance of the lesions in the sinuses

Computed tomography (CT) is usually the first investigation to be performed whenever invasive rhinocerebral mucormycosis is suspected based on clinical history and examination. The CT findings are nonspecific and include inflammatory changes in the sinuses. Early changes include mucosal thickening due to inflammation, bony erosions, and the formation of a mass lesion inside the sinuses, leading to the opacification of the sinuses. Hyperattenuation of the secretions on CT is suggestive of fungal sinusitis. The hyperdense areas seen in the sinuses are due to the presence of fungal hyphae and debris. Early changes suggestive of the spread of the infection outside the sinus include loss of normal fat density in the periantral fat (anterior, premaxillary, or retroantral) and orbit owing to edema from vascular congestion[16]. Superficial cellulitis is another early sign of invasion, which is not common in nonfungal sinusitis[10]. Late stages are characterized by signs suggestive of gross invasion of the structures of the orbit and the cranial cavity, which are more specific (Figure 1). Bone changes are also better visualized on CT.

The enhancement pattern of the lesions on contrast-enhanced computed tomography (CECT) varies from none to mild to heterogeneous enhancement, which was also seen in the cases in the present study [9,10]. The mild form was the most common type of enhancement observed by Therakathu *et al*[9]. Mucosal involvement may appear as a diffuse thickening or nodular thickening. Bone involvement was seen in the form of bone rarefaction, erosion, and permeative destruction in 40% of the cases in the study by Therakathu *et al*[9]. Middlebrooks *et al*[17] designed a CT-based model based on seven variables; this model can be used to suspect acute invasive fungal sinusitis. The variables are periantral fat involvement, bone dehiscence, orbital invasion, septal ulceration, pterygopalatine fossa, nasolacrimal duct, and lacrimal sac. In a study by Silverman *et al*[16], most cases of extra sinus invasion occurred without bony invasion, suggesting that perivascular or perineural invasion plays an important role in the spread of mucormycosis. In the same study, Silverman *et al*[16] noted that the presence of retroantral, facial, and orbital fat stranding was associated with a more aggressive infection.

Magnetic resonance imaging appearance of the sinus lesions

Orbital and intracranial invasions are best seen by magnetic resonance imaging (MRI). Early changes are nonspecific. These include mucosal thickening, which appears hypointense on T1-weighted images and



DOI: 10.4329/wjr.v14.i7.209 Copyright ©The Author(s) 2022.

Figure 1 Non contrast computed tomography image of a 40 year old male post renal transplant patient showing. A: Soft tissue density in maxillary, ethmoidal, sphenoidal and frontal sinus; B: Rarefaction of ethmoidal lamella, lamina papyracea and floor of anterior cranial fossa and erosion of maxillary walls; C: Section showing orbital involvement; D: Section showing erosions of the cribriform plate.

hyperintense on T2-weighted images. In the study by Therakathu *et al*[9], on a T2-weighted sequence, 37% of the lesions were isointense to mildly hypointense, 32% were heterogeneous, and 32% were hyperintense. Fungal elements are hypointense on T2-weighted images (Figure 2). The enhancement pattern is best studied on fat-suppressed post-gadolinium images and is different for different lesions. Of all the cases in the study by Therakathu *et al*[9], 29% showed intense homogenous enhancement, 36% showed heterogeneous enhancement, and 36% showed no enhancement.

Because of the angioinvasive nature of mucormycosis, the vessels get thrombosed. Upon injection of the contrast, the normal expected pattern of mucosal enhancement in case of inflammatory lesions may not be visible. Instead, there will be a low-signal intensity of the affected mucosa of the nasal turbinate on T2-weighted MRI images associated with an increased signal on diffusion-weighted images. This was referred to as the black turbinate sign by Safder *et al*[18].

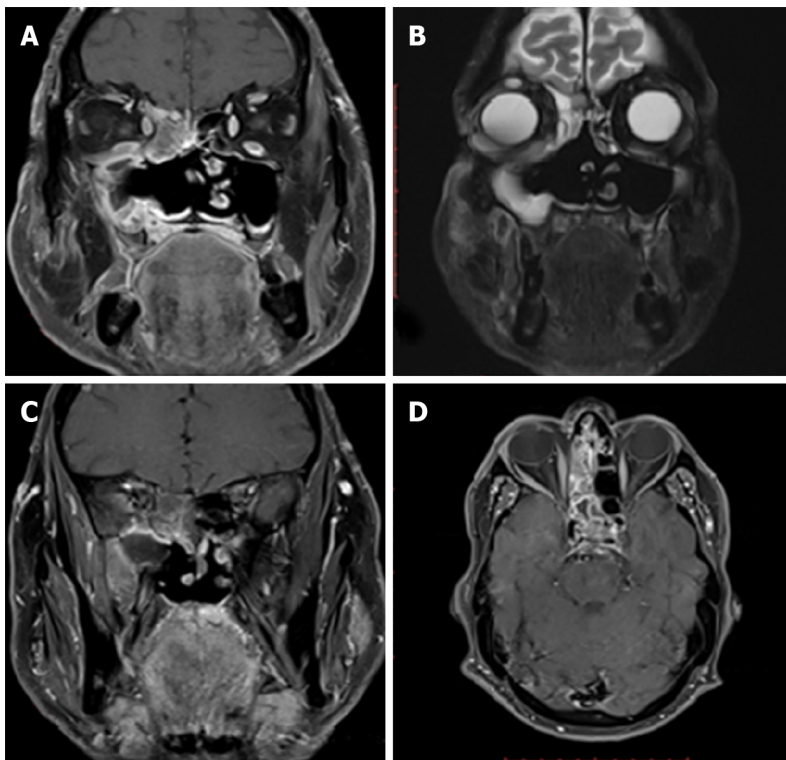
Differential diagnosis on imaging for mucormycosis includes the following: Acute rhinosinusitis with complications, Wegener's granulomatosis, and squamous cell carcinoma.

However, in the COVID-19 pandemic, mucormycosis should be considered the first differential diagnosis.

Imaging features of intracranial mucormycosis

Most of the imaging features correlate with the angioinvasive pattern of the mucormycosis infection. The imaging findings are nonspecific, but early diagnosis is of paramount importance because of the associated morbidity and mortality. Sen *et al*[19] found that cavernous sinus thrombosis and cribriform plate erosion were the commonest pathways of spread into the cranium and were present in 76% and 22% of the patients, respectively[19]. The involvement may appear as leptomeningeal inflammation, which appears as leptomeningeal enhancement and involvement of the cranial nerves with signs of meningism. This may be accompanied by cerebritis. Cerebritis appears as T2-FLAIR hyperintensity with variable enhancement and heterogeneous diffusion restriction on diffusion-weighted imaging. Invasion of the parenchyma may appear as granuloma formation or abscess formation. Fungal granulomas may show faint enhancement and surrounding edema.

In contrast to the pyogenic abscess, fungal abscesses are frequently multiple and form at the corticomedullary junction and in the basal ganglia. Isolated fungal abscesses are rare, and one should suspect intravenous drug abuse if encountered with such a situation. Fungal abscesses have crenated borders and non-enhancing, diffusion-restricting intracavitary projections[20]. They are hypointense on T1 and hyperintense on T2 and show rim enhancement[20]. On diffusion-weighted imaging, Luthra *et al*



DOI: 10.4329/wjrv.v14.i7.209 Copyright ©The Author(s) 2022.

Figure 2 Magnetic resonance imaging of the patient of Figure 1 showing. A: T1 image showing orbital involvement; B: T2 image showing orbital and infratemporal fossa involvement; C: T1+C showing infratemporal fossa involvement; D: T1+C showing cavernous sinus thrombosis.

[20] found that fungal abscesses showed restriction of diffusion in the projections and the wall, and the core of the abscess had no restriction of diffusion. In the same study, the authors found that the apparent diffusion coefficient was higher for the wall of the abscess when compared to the intracavitary projections for the fungal abscess, and it was statistically significant[20].

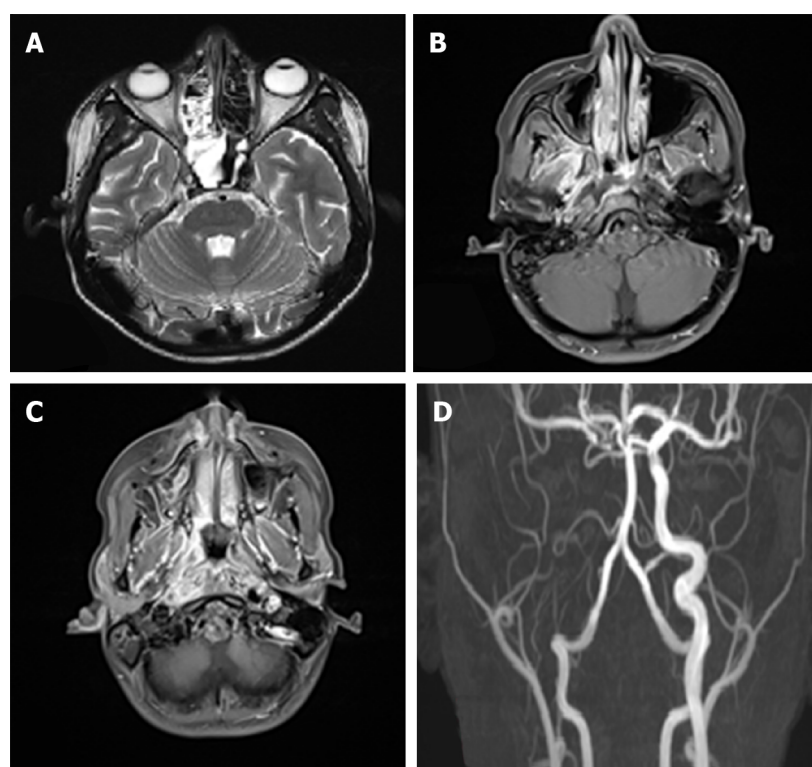
Vascular complications are observed in the late stages. They include both venous and arterial complications such as cavernous sinus thrombosis, arterial thrombosis, and aneurysmal dilatation (Figure 3). In the study by Mohindra *et al*[21], the role of MRI in the detection of vascular lesions was studied. In the study by Razeq *et al*[22], cavernous sinus involvement in mucormycosis appears hypointense on T1 and T2 sequences with intense, inhomogeneous post-contrast enhancement. Cavernous sinus thrombosis is the most common complication in the present study, as in certain published studies.

Cause of the increased incidence and severity of mucormycosis during the COVID-19 pandemic

Diabetes was one of the major predisposing factors for mucormycosis during the COVID-19 pandemic. Prakash *et al*[23] highlighted that rhinocerebral mucormycosis cases were predominantly present in those with uncontrolled diabetes and diabetic ketoacidosis, and few were present in immunosuppressed hosts. The findings were similar to those in other studies by Sen *et al*[18], John *et al*[24], and Hoenigl *et al* [25]. In the afore mentioned studies, the prevalence of diabetes was 78%-94% among patients with mucormycosis post-COVID-19 infection. In Patel *et al*'s study, patients with mucormycosis with poor glycemic control had a more invasive disease, which was statistically significant (P value = 0.040)[10]. The rampant use of corticosteroids and other immunomodulatory drugs to control the severity of the COVID-19 infection has further led to the increased predisposition[26]. During the peak of the pandemic, when healthcare facilities were functioning beyond their capacities, there were instances of unsupervised treatment with these immunomodulatory agents, leading to further escalation of the problem.

CONCLUSION

Rhinocerebral mucormycosis constituted the aftermath of the COVID-19 pandemic, leading to a rapid increase in the number of cases, which were previously restricted to only a few susceptible groups of patients. Rhinocerebral mucormycosis is associated with high mortality and morbidity. Hence, it should be suspected in any patient who presents symptoms of sinusitis, facial swelling, or CNS symptoms.



DOI: 10.4329/wjr.v14.i7.209 Copyright ©The Author(s) 2022.

Figure 3 Magnetic resonance imaging images of a patient of rhinocerebral mucormycosis showing. A: Enhancing soft tissue thickening in right nasal cavity involving right maxillary, ethmoid and sphenoid sinus; B: T1+C showing right infratemporal fossa involvement; C: T1+C showing right parapharyngeal space involvement; D: Angiogram showing right internal carotid artery thrombosis.

After clinical examination, imaging is the backbone of the diagnosis of this severe disease. CT helps in the preliminary diagnosis and helps stage the disease. CT detects bony erosion better. However, when an orbital and intracranial extension is present, MRI is preferred, as it delineates the involvement of these structures better. MRI can also delineate vascular involvement better. In accessible sites, biopsy and potassium hydroxide mount help clinch the diagnosis. The treatment of rhinocerebral mucormycosis consists of debridement of the necrotic tissue along with intravenous antifungals for a prolonged duration. Control of diabetes and judicious use of corticosteroids and immunomodulatory drugs can decrease the incidence of this life-threatening disease.

FOOTNOTES

Author contributions: Saneesh PS analyzed the data; Morampudi SC analyzed the data and wrote the manuscript; Yelamanchi R analyzed the data and wrote the manuscript; All authors have read and approved the final manuscript.

Conflict-of-interest statement: None of the authors in the study have any conflict of interest.

Open-Access: This article is an open-access article that was selected by an in-house editor and fully peer-reviewed by external reviewers. It is distributed in accordance with the Creative Commons Attribution NonCommercial (CC BY-NC 4.0) license, which permits others to distribute, remix, adapt, build upon this work non-commercially, and license their derivative works on different terms, provided the original work is properly cited and the use is non-commercial. See: <https://creativecommons.org/licenses/by-nc/4.0/>

Country/Territory of origin: India

ORCID number: P S Saneesh 0000-0003-1492-7395; Satya Chowdary Morampudi 0000-0002-4061-5363; Raghav Yelamanchi 0000-0001-6786-8056.

S-Editor: Liu JH

L-Editor: A

P-Editor: Liu JH

REFERENCES

- 1 **Ibrahim AS**, Spellberg B, Walsh TJ, Kontoyiannis DP. Pathogenesis of mucormycosis. *Clin Infect Dis* 2012; **54** Suppl 1: S16-S22 [PMID: 22247441 DOI: 10.1093/cid/cir865]
- 2 **Camara-Lemarroy CR**, González-Moreno EI, Rodríguez-Gutiérrez R, Rendón-Ramírez EJ, Ayala-Cortés AS, Fraga-Hernández ML, García-Labastida L, Galarza-Delgado DÁ. Clinical features and outcome of mucormycosis. *Interdiscip Perspect Infect Dis* 2014; **2014**: 562610 [PMID: 25210515 DOI: 10.1155/2014/562610]
- 3 **Sweeney RM**, McAuley DF. Acute respiratory distress syndrome. *Lancet* 2016; **388**: 2416-2430 [PMID: 27133972 DOI: 10.1016/S0140-6736(16)00578-X]
- 4 **Song G**, Liang G, Liu W. Fungal Co-infections Associated with Global COVID-19 Pandemic: A Clinical and Diagnostic Perspective from China. *Mycopathologia* 2020; **185**: 599-606 [PMID: 32737747 DOI: 10.1007/s11046-020-00462-9]
- 5 **Roden MM**, Zaoutis TE, Buchanan WL, Knudsen TA, Sarkisova TA, Schaufele RL, Sein M, Sein T, Chiou CC, Chu JH, Kontoyiannis DP, Walsh TJ. Epidemiology and outcome of zygomycosis: a review of 929 reported cases. *Clin Infect Dis* 2005; **41**: 634-653 [PMID: 16080086 DOI: 10.1086/432579]
- 6 **Herrera DA**, Dublin AB, Ormsby EL, Aminpour S, Howell LP. Imaging findings of rhinocerebral mucormycosis. *Skull Base* 2009; **19**: 117-125 [PMID: 19721767 DOI: 10.1055/s-0028-1096209]
- 7 **Gupta N**, Dembla S. Cranial nerve involvement in mucormycosis in post-COVID patients: a case series. *Egypt J Radiol Nucl Med* 2022; **53**: 28 [DOI: 10.1186/s43055-022-00700-8]
- 8 **Dubey S**, Mukherjee D, Sarkar P, Mukhopadhyay P, Barman D, Bandopadhyay M, Pandit A, Sengupta A, Das S, Ghosh S, Adhikari S, Biswas PS, Pal P, Roy H, Patra N, Das A, Sinha P, Mondal MK, Shrivastava SR, Bhattacharya K, Mukhopadhyay M, Ahmed K, Halder TK, Saha M, Maity S, Mandal A, Chatterjee D, Saha S, Chunakar A, Saha A, Ray BK. COVID-19 associated rhino-orbital-cerebral mucormycosis: An observational study from Eastern India, with special emphasis on neurological spectrum. *Diabetes Metab Syndr* 2021; **15**: 102267 [PMID: 34509790 DOI: 10.1016/j.dsx.2021.102267]
- 9 **Therakathu J**, Prabhu S, Irodi A, Sudhakar SV, Yadav VK, Rupa V. Imaging features of rhinocerebral mucormycosis: a study of 43 patients. *Egypt J Radiol Nucl Med* 2018; **49**: 447-452 [DOI: 10.1016/j.ejrm.2018.01.001]
- 10 **Patel DD**, Adke S, Badhe PV, Lamture S, Marfatia H, Mhatre P. COVID-19 associated Rhino-Orbito-Cerebral Mucormycosis: Imaging spectrum and Clinico-radiological correlation- a single Centre experience. *Clin Imaging* 2022; **82**: 172-178 [PMID: 34864270 DOI: 10.1016/j.clinimag.2021.10.014]
- 11 **Gillespie MB**, Huchton DM, O'Malley BW. Role of middle turbinate biopsy in the diagnosis of fulminant invasive fungal rhinosinusitis. *Laryngoscope* 2000; **110**: 1832-1836 [PMID: 11081595 DOI: 10.1097/00005537-200011000-00013]
- 12 **Gillespie MB**, O'Malley BW Jr, Francis HW. An approach to fulminant invasive fungal rhinosinusitis in the immunocompromised host. *Arch Otolaryngol Head Neck Surg* 1998; **124**: 520-526 [PMID: 9604977 DOI: 10.1001/archotol.124.5.520]
- 13 **Skiada A**, Pavleas I, Drogari-Apiranthitou M. Epidemiology and Diagnosis of Mucormycosis: An Update. *J Fungi (Basel)* 2020; **6** [PMID: 33147877 DOI: 10.3390/jof6040265]
- 14 **Bhandari J**, Thada PK, Nagalli S. Rhinocerebral Mucormycosis. [Updated 2021 Nov 25]. In: StatPearls [Internet]. Treasure Island (FL): StatPearls Publishing; 2022 Jan. Available from: <https://www.ncbi.nlm.nih.gov/books/NBK559288/>
- 15 **Rupa V**, Maheswaran S, Ebenezer J, Mathews SS. Current therapeutic protocols for chronic granulomatous fungal sinusitis. *Rhinology* 2015; **53**: 181-186 [PMID: 26030043 DOI: 10.4193/Rhino14.183]
- 16 **Silverman CS**, Mancuso AA. Periantral soft-tissue infiltration and its relevance to the early detection of invasive fungal sinusitis: CT and MR findings. *AJNR Am J Neuroradiol* 1998; **19**: 321-325 [PMID: 9504486]
- 17 **Middlebrooks EH**, Frost CJ, De Jesus RO, Massini TC, Schmalfuss IM, Mancuso AA. Acute Invasive Fungal Rhinosinusitis: A Comprehensive Update of CT Findings and Design of an Effective Diagnostic Imaging Model. *AJNR Am J Neuroradiol* 2015; **36**: 1529-1535 [PMID: 25882281 DOI: 10.3174/ajnr.A4298]
- 18 **Safder S**, Carpenter JS, Roberts TD, Bailey N. The "Black Turbinate" sign: An early MR imaging finding of nasal mucormycosis. *AJNR Am J Neuroradiol* 2010; **31**: 771-774 [PMID: 19942703 DOI: 10.3174/ajnr.A1808]
- 19 **Sen M**, Honavar SG, Bansal R, Sengupta S, Rao R, Kim U, Sharma M, Sachdev M, Grover AK, Surve A, Budharapu A, Ramadhin AK, Tripathi AK, Gupta A, Bhargava A, Sahu A, Khairnar A, Kochar A, Madhavani A, Shrivastava AK, Desai AK, Paul A, Ayyar A, Bhatnagar A, Singhal A, Nikose AS, Tenagi AL, Kamble A, Nariani A, Patel B, Kashyap B, Dhawan B, Vohra B, Mandke C, Thrishulamurthy C, Sambare C, Sarkar D, Mankad DS, Maheshwari D, Lalwani D, Kanani D, Patel D, Manjandavida FP, Godhani F, Agarwal GA, Ravulaparthi G, Shilpa GV, Deshpande G, Thakkar H, Shah H, Ojha HR, Jani H, Gontia J, Mishrikotkar JP, Likhari K, Prajapati K, Porwal K, Koka K, Dharawat KS, Ramamurthy LB, Bhattacharyya M, Saini M, Christy MC, Das M, Hada M, Panchal M, Pandharpurkar M, Ali MO, Porwal M, Gangashetappa N, Mehrotra N, Bijlani N, Gajendragadkar N, Nagarkar NM, Modi P, Rewri P, Sao P, Patil PS, Giri P, Kapadia P, Yadav P, Bhagat P, Parekh R, Dyaberi R, Chauhan RS, Kaur R, Duvesh RK, Murthy R, Dandu RV, Kathiara R, Beri R, Pandit R, Rani RH, Gupta R, Pherwani R, Sapkal R, Mehta R, Tadepalli S, Fatima S, Karmarkar S, Patil SS, Shah S, Dubey S, Gandhi S, Kanakpur S, Mohan S, Bhomaj S, Kerkar S, Jariwala S, Sahu S, Tara S, Maru SK, Jhavar S, Sharma S, Gupta S, Kumari S, Das S, Menon S, Burkule S, Nisar SP, Kaliaperumal S, Rao S, Pakrasi S, Rathod S, Biradar SG, Kumar S, Dutt S, Bansal S, Ravani SA, Lohiya S, Ali Rizvi SW, Gokhale T, Lahane TP, Vukkadala T, Grover T, Bhesaniya T, Chawla U, Singh U, Une VL, Nandedkar V, Subramaniam V, Eswaran V, Chaudhry VN, Rangarajan V, Dehane V, Sahasrabudhe VM, Sowjanya Y, Tupkary Y, Phadke Y; members of the Collaborative OPAI-IJO Study on Mucormycosis in COVID-19 (COSMIC) Study Group. Epidemiology, clinical profile, management, and outcome of COVID-19-associated rhino-orbital-cerebral mucormycosis in 2826 patients in India - Collaborative OPAI-IJO Study on Mucormycosis in COVID-19 (COSMIC), Report 1. *Indian J Ophthalmol* 2021; **69**: 1670-1692 [PMID: 34156034 DOI: 10.4103/ijo.IJO_1565_21]
- 20 **Luthra G**, Parihar A, Nath K, Jaiswal S, Prasad KN, Husain N, Husain M, Singh S, Behari S, Gupta RK. Comparative evaluation of fungal, tubercular, and pyogenic brain abscesses with conventional and diffusion MR imaging and proton MR spectroscopy. *AJNR Am J Neuroradiol* 2007; **28**: 1332-1338 [PMID: 17698537 DOI: 10.3174/ajnr.A0548]

- 21 **Mohindra S**, Mohindra S, Gupta R, Bakshi J, Gupta SK. Rhinocerebral mucormycosis: the disease spectrum in 27 patients. *Mycoses* 2007; **50**: 290-296 [PMID: 17576322 DOI: 10.1111/j.1439-0507.2007.01364.x]
- 22 **Razek AA**, Castillo M. Imaging lesions of the cavernous sinus. *AJNR Am J Neuroradiol* 2009; **30**: 444-452 [PMID: 19095789 DOI: 10.3174/ajnr.A1398]
- 23 **Prakash H**, Chakrabarti A. Global Epidemiology of Mucormycosis. *J Fungi (Basel)* 2019; **5** [PMID: 30901907 DOI: 10.3390/jof5010026]
- 24 **John TM**, Jacob CN, Kontoyiannis DP. When Uncontrolled Diabetes Mellitus and Severe COVID-19 Converge: The Perfect Storm for Mucormycosis. *J Fungi (Basel)* 2021; **7** [PMID: 33920755 DOI: 10.3390/jof7040298]
- 25 **Hoeningl M**, Seidel D, Carvalho A, Rudramurthy SM, Arastehfar A, Gangneux JP, Nasir N, Bonifaz A, Araiza J, Klimko N, Serris A, Lagrou K, Meis JF, Cornely OA, Perfect JR, White PL, Chakrabarti A; ECMM and ISHAM collaborators. The emergence of COVID-19 associated mucormycosis: a review of cases from 18 countries. *Lancet Microbe* 2022; **3**: e543-e552 [PMID: 35098179 DOI: 10.1016/S2666-5247(21)00237-8]
- 26 **Al-Tawfiq JA**, Alhumaid S, Alshukairi AN, Temsah MH, Barry M, Al Mutair A, Rabaan AA, Al-Omari A, Tirupathi R, AlQahtani M, AlBahrani S, Dhama K. COVID-19 and mucormycosis superinfection: the perfect storm. *Infection* 2021; **49**: 833-853 [PMID: 34302291 DOI: 10.1007/s15010-021-01670-1]



Published by **Baishideng Publishing Group Inc**
7041 Koll Center Parkway, Suite 160, Pleasanton, CA 94566, USA

Telephone: +1-925-3991568

E-mail: bpgoffice@wjgnet.com

Help Desk: <https://www.f6publishing.com/helpdesk>

<https://www.wjgnet.com>

