

World Journal of *Gastrointestinal Surgery*

World J Gastrointest Surg 2022 July 27; 14(7): 632-730



Contents

Monthly Volume 14 Number 7 July 27, 2022

REVIEW

- 632 From advanced diagnosis to advanced resection in early neoplastic colorectal lesions: Never-ending and trending topics in the 2020s

Auriemma F, Sferrazza S, Bianchetti M, Savarese MF, Lamonaca L, Paduano D, Piazza N, Giuffrida E, Mete LS, Tucci A, Milluzzo SM, Iannelli C, Repici A, Mangiavillano B

ORIGINAL ARTICLE

Retrospective Study

- 656 Adult patients with allied disorders of Hirschsprung's disease in emergency department: An 11-year retrospective study

Jiang S, Song CY, Feng MX, Lu YQ

- 670 Impact of comorbid renal dysfunction in patients with hepatocellular carcinoma on long-term outcomes after curative resection

Sakamoto Y, Shimada S, Kamiyama T, Sugiyama K, Asahi Y, Nagatsu A, Orimo T, Kakisaka T, Kamachi H, Ito YM, Taketomi A

- 685 Individualized risk estimation for postoperative pulmonary complications after hepatectomy based on perioperative variables

Xu LN, Xu YY, Li GP, Yang B

SYSTEMATIC REVIEWS

- 696 Skeletal muscle metastasis from colorectal adenocarcinoma: A literature review

Kulkarni N, Khalil A, Bodapati S

CASE REPORT

- 706 Percutaneous aspiration and sclerotherapy of a giant simple hepatic cyst causing obstructive jaundice: A case report and review of literature

He XX, Sun MX, Lv K, Cao J, Zhang SY, Li JN

- 714 Indocyanine green fluorescence imaging for spleen preservation in laparoscopic splenic artery aneurysm resection: A case report

Cheng J, Sun LY, Liu J, Zhang CW

LETTER TO THE EDITOR

- 720 Total mesopancreas excision is the better staging tool of the mesopancreas in pancreatic head carcinoma

Peparini N

- 723 Three-dimensional visualization and virtual reality simulation role in hepatic surgery: Further research warranted

Ahmed F, Jahagirdar V, Gudapati S, Mouchli M

- 727 Signs and syndromes in acute appendicitis: A pathophysiologic approach

Yale SH, Tekiner H, Yale ES

ABOUT COVER

Editorial Board Member of *World Journal of Gastrointestinal Surgery*, Francesco Saverio Mari, FACS, MD, PhD, Doctor, Lecturer, Postdoctoral Fellow, Research Fellow, Surgeon, Surgical Oncologist, Department of Medical and Surgical Sciences and Translational Medicine, School of Medicine and Psychology, University Sapienza of Rome, Rome 00060, Italy. frasavmari@yahoo.it

AIMS AND SCOPE

The primary aim of *World Journal of Gastrointestinal Surgery* (WJGS, *World J Gastrointest Surg*) is to provide scholars and readers from various fields of gastrointestinal surgery with a platform to publish high-quality basic and clinical research articles and communicate their research findings online.

WJGS mainly publishes articles reporting research results and findings obtained in the field of gastrointestinal surgery and covering a wide range of topics including biliary tract surgical procedures, biliopancreatic diversion, colectomy, esophagectomy, esophagostomy, pancreas transplantation, and pancreatectomy, etc.

INDEXING/ABSTRACTING

The WJGS is now abstracted and indexed in Science Citation Index Expanded (SCIE, also known as SciSearch®), Current Contents/Clinical Medicine, Journal Citation Reports/Science Edition, PubMed, PubMed Central, Reference Citation Analysis, China National Knowledge Infrastructure, China Science and Technology Journal Database, and Superstar Journals Database. The 2022 Edition of Journal Citation Reports® cites the 2021 impact factor (IF) for WJGS as 2.505; IF without journal self cites: 2.473; 5-year IF: 3.099; Journal Citation Indicator: 0.49; Ranking: 104 among 211 journals in surgery; Quartile category: Q2; Ranking: 81 among 93 journals in gastroenterology and hepatology; and Quartile category: Q4.

RESPONSIBLE EDITORS FOR THIS ISSUE

Production Editor: Rui-Rui Wu; Production Department Director: Xiang Li; Editorial Office Director: Jia-Ru Fan.

NAME OF JOURNAL

World Journal of Gastrointestinal Surgery

ISSN

ISSN 1948-9366 (online)

LAUNCH DATE

November 30, 2009

FREQUENCY

Monthly

EDITORS-IN-CHIEF

Peter Schemmer

EDITORIAL BOARD MEMBERS

<https://www.wjgnet.com/1948-9366/editorialboard.htm>

PUBLICATION DATE

July 27, 2022

COPYRIGHT

© 2022 Baishideng Publishing Group Inc

INSTRUCTIONS TO AUTHORS

<https://www.wjgnet.com/bpg/gerinfo/204>

GUIDELINES FOR ETHICS DOCUMENTS

<https://www.wjgnet.com/bpg/GerInfo/287>

GUIDELINES FOR NON-NATIVE SPEAKERS OF ENGLISH

<https://www.wjgnet.com/bpg/gerinfo/240>

PUBLICATION ETHICS

<https://www.wjgnet.com/bpg/GerInfo/288>

PUBLICATION MISCONDUCT

<https://www.wjgnet.com/bpg/gerinfo/208>

ARTICLE PROCESSING CHARGE

<https://www.wjgnet.com/bpg/gerinfo/242>

STEPS FOR SUBMITTING MANUSCRIPTS

<https://www.wjgnet.com/bpg/GerInfo/239>

ONLINE SUBMISSION

<https://www.f6publishing.com>



Skeletal muscle metastasis from colorectal adenocarcinoma: A literature review

Nikhil Kulkarni, Ahmed Khalil, Shruti Bodapati

Specialty type: Gastroenterology and hepatology

Provenance and peer review: Invited article; Externally peer reviewed.

Peer-review model: Single blind

Peer-review report's scientific quality classification

Grade A (Excellent): 0
Grade B (Very good): 0
Grade C (Good): C, C
Grade D (Fair): 0
Grade E (Poor): 0

P-Reviewer: Dilek ON, Turkey;
Tang D, China

Received: April 15, 2022

Peer-review started: April 15, 2022

First decision: May 12, 2022

Revised: May 26, 2022

Accepted: June 22, 2022

Article in press: June 22, 2022

Published online: July 27, 2022



Nikhil Kulkarni, Ahmed Khalil, Department of General and Colorectal Surgery, Lincoln County Hospital, Lincoln LN5 2QY, United Kingdom

Shruti Bodapati, Department of General Surgery, Plymouth University Hospitals, Plymouth PL6 8DH, United Kingdom

Corresponding author: Nikhil Kulkarni, MS, MCh, FRCS, Consultant Surgeon, Department of General and Colorectal Surgery, Lincoln County Hospital, Greetwell Road, Lincoln LN5 2QY, United Kingdom. dr_nvkh@yahoo.com

Abstract

BACKGROUND

Colorectal adenocarcinoma is the third most common cancer worldwide. It accounts for almost 10% of all cancer-related deaths. Skeletal muscle is a very unusual site for metastasis from colorectal cancers and is associated with a poor prognosis and high mortality.

AIM

To review the literature for cases of skeletal muscle metastasis (SMM) from colorectal adenocarcinoma.

METHODS

A systematic literature search using a validated search strategy was carried out to identify the incidence of SMM associated with colorectal adenocarcinoma. The studies identified were tabulated in a PRISMA, and data was extracted in a tabulated form.

RESULTS

Twenty-nine studies were included in this literature review. SMM was most commonly detected in the thigh muscles. Most of the tumours had originated from the rectum or the right colon. The histopathology of the primary tumour was generally advanced. The mean time interval between the primary tumour and onset of SMM was 22 mo. In 3 cases, asymptomatic SMM had been picked up by advanced imaging systems, like fluorodeoxyglucose-positron emission tomography scan.

CONCLUSION

SMM from colorectal adenocarcinomas is a rare complication. However, it is possible that the low incidence could be due to under-reporting. Early use of

advanced imaging techniques and a high index of clinical suspicion might increase the reporting of SMM from colorectal adenocarcinoma.

Key Words: Skeletal muscle; Metastasis; Colorectal cancer; Adenocarcinoma; Systematic review

©The Author(s) 2022. Published by Baishideng Publishing Group Inc. All rights reserved.

Core Tip: Skeletal muscle metastasis (SMM) from a colorectal adenocarcinoma is a rare complication. Presentation usually occurs at a late stage, and prognosis remains poor. However, with a high index of suspicion and early use of advanced investigative modalities, like fluorodeoxyglucose-positron emission tomography scan, SMM can be detected and treated at an earlier stage. Further research is required to better understand the prognosis and pathophysiology of SMM.

Citation: Kulkarni N, Khalil A, Bodapati S. Skeletal muscle metastasis from colorectal adenocarcinoma: A literature review. *World J Gastrointest Surg* 2022; 14(7): 696-705

URL: <https://www.wjgnet.com/1948-9366/full/v14/i7/696.htm>

DOI: <https://dx.doi.org/10.4240/wjgs.v14.i7.696>

INTRODUCTION

Colorectal cancer is the third most common cancer worldwide, with at least 1.8 million new cases reported across the globe in 2018, and accounting for almost 10% of all cancer-related deaths worldwide [1,2]. Fortunately, there have been significant improvements in the life expectancy and survival rates after colorectal cancer. In particular, over the last 40 years, 5-year survival rates after a diagnosis of colorectal cancer have increased from 22% to 57% [2]. The improvement in survival has been attributed to a plethora of reasons, including screening and surveillance programmes, advanced endoscopic diagnostic and therapeutic techniques, use of minimally invasive surgical approaches (like laparoscopic and robotic techniques), and refined adjuvant and neoadjuvant chemotherapy and radiotherapy options.

Metastasis of colorectal cancer occurs *via* lymphatic, hematogenous and direct-spread routes, with the most common secondary sites being the liver, lungs, peritoneum, lymph nodes, and bones [3]. Intriguingly, although skeletal muscles constitute almost 50% of the total body mass, the incidence of metastasis to skeletal muscles from all forms of cancers is extremely low [4]. Many studies have commented on the possible reasons for the relatively low incidence of metastases to skeletal muscles. Hypotheses include variable blood flow to skeletal muscles, rare incidence of microvasculature damage due to cancer cells in skeletal muscles, and production of a low molecular weight non-protein factor that may inhibit tumour cell proliferation [5].

The aim of this study was to review the literature for cases of skeletal muscle metastasis (SMM) from colorectal adenocarcinoma.

MATERIALS AND METHODS

A systematic literature search was carried out in December 2021, using a validated search strategy as described below.

Search strategy

The search was performed using Reference Citation Analysis, PubMed, Medline, Embase, Cochrane Library and Google Scholar databases. Journals, as well as society websites, were also searched using the search terms “skeletal muscle metastasis”, “colorectal cancer”, “case reports”, and “review.” The search strategy was standardized using the PRISMA guidelines. Two researchers (Khalil A, Bodapati S) reviewed the summary and abstracts of the articles. A full-text review was then performed by all three authors.

Inclusion criteria

Articles that were not available in English language were excluded from the study. Only studies with full texts available that included data for pathological evidence of SMM from colorectal origin were considered. Studies with pathology data other than adenocarcinoma were excluded. No other exclusion criteria were used. The data were extracted by the three researchers and included patient characteristics,

year of publication, site of primary tumour, presenting symptom, type of surgery performed for the primary lesion, site of skeletal and non-skeletal metastasis, time interval for onset of skeletal metastasis, and final outcome.

Information about the number of relevant citations, number and reasons of studies excluded after full assessment, as well as number of studies included in the systematic review fit in a well-designed PRISMA diagram, as presented in [Figure 1](#).

RESULTS

Characteristics of studies

The initial search yielded 138 eligible studies, of which 29 ultimately fit our inclusion criteria for the review (all case reports). These studies covered a total of 30 patients. Detailed characteristics of the studies are shown in [Table 1](#).

Patient profiles

The median age of the patients was 67 years (range: 23-83 years), with 19 male patients and 11 female patients. The primary tumour was present in the right colon in 10 patients, transverse colon in 4, left colon in 5, and rectum in 11. The presenting symptoms were pain (6 patients), palpable lump (4 patients), painful lump (9 patients), and ocular symptoms (2 patients). Three of the patients had the SMM incidentally diagnosed by imaging. Only 3 of the reported cases mention an early primary lesion (tubulovillous adenoma with high-grade dysplasia or T2 stage tumours). Six cases reported indicated that the primary lesion was of an advanced nature (T3 or T4). The tumours were either moderately or poorly differentiated in 6 cases. Four of the reported cases indicated that the primary lesion was either a mucin-secreting tumour or signet ring cell tumour.

SMM distribution

The mean time interval between the diagnosis of the primary tumour and presentation of SMM was 22 mo. Six cases were diagnosed synchronously with the metastasis. There were a wide range of skeletal muscles that were involved in the metastasis, as follows: Upper limb (extensor carpi ulnaris, thenar, deltoid, biceps); lower limb (thigh, tibialis anterior, semimembranous, adductor, sartorius, vastus lateralis); trunk (teres major, glutei, external oblique, neck muscles, paraspinal, rectus abdominus, intercostal, psoas, piriformis); and, extraocular muscles (lateral rectus, superior rectus). However, the most common site of metastasis was the thigh muscle. In 8 cases, the skeletal muscles were the only site of metastasis.

There was no detailed information about the duration of follow-up and final outcome of the disease; however, 10 case reports mentioned that the patients did not survive the disease.

DISCUSSION

Colorectal cancers account for 10.7% of all new cancers reported worldwide[2]. Our literature review has shown that since 1970, only 30 cases of SMM due to colorectal adenocarcinomas have been reported. This highlights the extremely low incidence of skeletal muscle as a metastatic site due to colorectal adenocarcinoma.

The primary pathology in the majority of the patients was in the rectum (11 patients) and the right colon (10 patients). Left-sided colonic tumours accounted for 5 of the cases and transverse colon for 4. A large meta-analysis carried out by Prasanna *et al*[6] highlighted the different metastatic patterns of colorectal cancers, depending on the site of the primary tumour. This study showed that right colonic tumours were more frequently associated with peritoneal seeding, and rectal tumours were more frequently associated with lung, brain and bone metastases compared to left colonic tumours. Though SMMs were not mentioned in this meta-analysis, the general pattern of higher metastases in right colonic and rectal tumours was also seen in our review. Only 8 patients had no documented simultaneous metastasis in non-skeletal muscles. The other patients had metastases in non-skeletal muscle sites.

The most common presenting symptom of the SMM was a painful lump (9 patients). Six patients had a palpable lump with no description of pain, and 6 patients had pain as the presenting symptom. Three patients had the SMM diagnosed incidentally by imaging. The importance of advanced imaging techniques, especially fluorodeoxyglucose-positron emission tomography (FDG-PET) scanning, for diagnosis of SMM has been highlighted by Emmering *et al*[7]. Lesions that cannot be detected by routine contrast computed tomography or magnetic resonance imaging can be observed by FDG-PET scans. FDG-PET had a significant impact on early diagnosis and patient management in 51% of cases with muscle metastasis. Hence, if there is a suspicion of SMM, the early use of FDG-PET should be encouraged for diagnosis.

Table 1 Characteristics of case reports of skeletal muscle metastasis in colorectal adenocarcinoma

Case	Ref.	Age/sex	Site of primary tumour	Presenting symptom	Surgery of primary tumour	Histology of primary	Site of skeletal metastasis and treatment	Non-skeletal metastases	Time interval in mo	Follow-up/outcome
1	Hasegawa <i>et al</i> [14], 2000	60/M	Transverse colon	Not described	Transverse colon resection and lymph node dissection + FOLFOX	Adenocarcinoma	Right extensor carpi ulnaris muscle; a major part of the right extensor carpi ulnaris and the extensor digiti minimi muscle were resected, warranting a sufficient margin of 5 cm of normal tissue from the tumour	Multiple hepatic metastases detected 14 mo after primary resection and was resected	24	Alive
2	Buemi <i>et al</i> [3], 2019	69/F	Right colon	Pain when mobilizing left leg + elevated CEA of 7.7 ng/mL	Right hemicolectomy	pT3N0M0 (0/44 lymph nodes)	Left gluteus muscle; lesion was resected en bloc		7	Alive; 6 yr after colectomy and 65 mo after resection of the muscular metastasis she was tumour free with normal CEA level
3	Yi <i>et al</i> [17], 2015	67/M	Caecum	Swelling and pain	Right hemicolectomy and subsequent chemotherapy with a regimen containing oxaliplatin	Poorly differentiated	Right thenar muscles	Liver, right kidney, right abdominal wall, left axillary and right subclavicular lymph nodes, skin of right thigh; treatment was given with palliative systemic chemotherapy (FOLFIRI)	Synchronous	Dead (9 mo after diagnosis)
4	Araki <i>et al</i> [18], 1994	66/M	Ascending colon	Painful lump	Right hemicolectomy		Right teres major; excision of the mass was performed		6	Dead (31 mo after surgery)
5	Manafi-Farid <i>et al</i> [19], 2019	23/M	Rectum	Incidentally detected in FDG-PET studies	Proctocolectomy preceded by neoadjuvant chemotherapy and followed by adjuvant chemotherapy, including the FOLFOX regimen	pT3N1	Multiple: Deltoid, external oblique, biceps, tongue; excisional biopsy of the deltoid muscle lesion proved to be metastatic adenocarcinoma; commenced chemotherapy (FOLFIRI)	Lung/adrenal gland/scalp	24	Alive
6	Torosian <i>et al</i> [20], 1987	69/M	Transverse colon		Extended right colectomy		Left thigh; en bloc resection was performed		60	Not specified
7	Okada <i>et al</i> [21], 2009	70/M	Rectum	Painful lump	Rectal resection		Right thigh; resection and chemotherapy were given	Lung	12	Alive; the resection of SMM made a positive contribution to his quality of life
8	Chang <i>et al</i> [22], 1994	62/M	Descending colon	Painful lump			Left tibialis anterior; excision of the mass was performed		Synchronous	Not specified
9	Yoshikawa <i>et al</i> [23], 1999	54/M	Sigmoid colon	Severe buttocks pain	Partial sigmoid colectomy		Right buttocks; en bloc resection performed	Multiple metastases	24	Died after 8 mo from multiple metastases

10	Guo <i>et al</i> [16], 2021	43/M	Ascending colon	Right thigh mass 4 cm × 4 cm with intolerable pain	Laparoscopic extended right hemicolectomy and four cycles of chemotherapy with CapeOX	PT4N2bM0; poorly differentiated adenocarcinoma	Right thigh; a complete resection was suggested but was refused by the patient; unresponsive to FOLFIRI; switched to bevacizumab, irinotecan, and capecitabine	Bony metastasis and multiple lymph node metastases around the abdominal aorta	5	Deteriorated and died 9 mo after primary resection
11	Tatsuta <i>et al</i> [24], 2022	83/M	Ascending colon	Pain in the back of his neck	Curative resection	Adenocarcinoma	Cervical (neck muscle); he was prescribed palliative radiation therapy because of his poor performance status	None	11	Died 2 mo after diagnosis of muscle metastasis
12	Iusco <i>et al</i> [25], 2005	73/F	Ascending colon	Painful lump	Right hemicolectomy	Dukes C	Left calf; the mass was excised and received adjuvant radiotherapy	None	24	Alive; no sign of recurrence at a 2-yr follow-up
13	Landriscina <i>et al</i> [9], 2013	71/F	Right colon	Detected on PET/CT scan	Right hemicolectomy with subsequent systemic neoadjuvant chemotherapy for liver metastasis followed by radical hepatectomy	Poorly differentiated adenocarcinoma	Deltoid, sternocleidomastoid and other multiple sites; chemotherapy with FOLFOX was administered for 3 cycles but discontinued due to traumatic femur fracture	Liver/lung	23	Disease progression and death
14	Hattori <i>et al</i> [26], 2008	64/F	Rectum	Asymptomatic; increased CEA; discovered by FDG-PET	Abdominoperineal rectal resection	Moderately differentiated adenocarcinoma	Right thoracic paraspinal muscles; <i>en bloc</i> excision was performed including the paraspinal muscles	Solitary lung metastasis, which was resected 3 yr previously by lobectomy with subsequent immunochemotherapy	96	Alive
15	Choi <i>et al</i> [27], 2008	83/F	Rectum	Painful lump	Low anterior resection and right liver lobectomy	T2N1M1	Semimembranous muscle of right thigh	Solitary pulmonary nodule in left lobe	48	Died of heart failure on second postoperative day
16	Doroudinia <i>et al</i> [28], 2019	48/M	Rectum	Subcutaneous lump	Abdominoperineal rectal resection followed by adjuvant radiotherapy and chemotherapy	High grade mucinous adenocarcinoma	Right proximal thigh; the patient became a candidate for tumour excision (metastasectomy) followed by additional course of chemotherapy.	None	38	Not specified
17	Tunio <i>et al</i> [29], 2013	28/M	Transverse colon	Abdominal pain and hard nodule at anterior abdominal wall	Extended right hemicolectomy; radiotherapy; FOLFOX4	Mucinous moderately differentiated adenocarcinoma T4N2bM0	Rectus abdominis muscle and right gluteus maximus; underwent palliative radiotherapy followed by systemic chemotherapy	None	11	Alive at time of publication with progressive disease
18	Simeunovic <i>et al</i> [30], 2014	55/F	Rectum	Lower back pain and left hip pain as first manifestation of the primary tumour	Radiotherapy; chemotherapy with FOLFOX	Poorly differentiated adenocarcinoma	Left adductor muscle	None	Synchronous	Not specified
19	Prabhu <i>et al</i> [31], 2017	69/M	Rectum	Severe low back ache	Neoadjuvant; abdominoperineal resection; capecitabine	Adenocarcinoma with signet ring cell features T3N2; Dukes C1	Multiple skeletal muscles: left sartorius, left vastus lateralis, left infraspinatus, left levator scapulae, left tenth	None	4	Not specified

							Intercostal muscle, right subscapularis muscle				
20	Tai <i>et al</i> [32], 2014	81/M	Caecum	Severe right shoulder pain	Palliative chemotherapy; palliative right hemicolectomy	Poorly differentiated adenocarcinoma	Right supraspinatus muscle	Right lobe of lung	Synchronous	Patient transitioned to hospice	
21	Farraj <i>et al</i> [33], 2021	52/F	Rectum	Noted with preoperative staging	Low anterior resection; adjuvant combination of oxaliplatin, capecitabine, and pelvic external beam radiation therapy	Moderately differentiated adenocarcinoma T2N1a	Left psoas muscle	None	Synchronous	Patient is currently maintained on platinum doublet chemotherapy with control of metastatic disease	
22	Salar <i>et al</i> [34], 2012	67/F	Rectum	Deep pelvic and left buttock pain	EUA; submucosal polypectomy	Tubulovillous adenomatous polyp with high grade dysplasia	Left piriformis muscle	None	18	Patient began cycles of chemoradiotherapy with plans for further surgical resection	
23	Homan <i>et al</i> [35], 2000	72/F	Descending colon		Surgical resection; FOLFOX		Thigh			NA	
24	Takada <i>et al</i> [36], 2011	71/M	Sigmoid colon		Radiotherapy; FOLFOX; resection “Hartmann”	Stage III adenocarcinoma	Left iliopsoas muscle; received radiotherapy and 15 courses of FOLFOX + bevacizumab for decreasing large and unresectable tumour; then resection was performed	GI metastasis	60	5 mo after resection of muscle metastasis, there was no recurrence	
25	Naik <i>et al</i> [37], 2005	56/M	Ascending colon	A lump	Resection; chemotherapy FOLFOX; radiotherapy	Mucin secreting adenocarcinoma	Rectus abdominis muscle; resection was performed	NA	60	Not specified	
26	Burgueño Montañés and López Roger[38], 2002	60/M	Rectosigmoid	Exophthalmos	Radiotherapy; FOLFOX		Lateral rectus muscle			Not specified	
27	García-Fernández <i>et al</i> [39], 2012	32/M	Colon	Palpebral oedema, conjunctival chemosis, severe exophthalmos, complete ptosis in left eye and limitation in eye movement mainly in abduction and supraversion	Resistant to chemotherapy	Stage IV	Superior rectus elevator muscle of upper eyelid complex and external rectus muscle			Due to the patient generally feeling unwell, radiotherapy was not considered, and an intravenous bolus of corticoids was given, without response, resulting in the death of the patient	
28	Lampenfeld <i>et al</i> [40], 1990	75/F	Rectum	Progressive growth of left buttock mass	Excision of mass	Adenocarcinoma	Left gluteus maximus and medius		24		
29	Laurence and Murray[41], 1970; Case 1	70/F	Caecum	Painful mass in posterolateral aspect of right calf and leg	Right hemicolectomy	Ulcerated villous adenocarcinoma	Right calf; en bloc resection was performed	Generalized metastasis	24	Died due to generalized metastasis	

			oedema					
30	Laurence and Murray[41], 1970; Case 2	51/M	Transverse colon	Right colectomy	Right forearm; en bloc resection was performed	Generalized metastasis	Synchronous	Died due to generalized metastasis

CapeOX: Combination of capecitabine and oxaliplatin; CEA: Carcinoembryonic antigen; EUA: Examination under anaesthesia; F: Female; FDG-PET: Fluorodeoxyglucose positron emission tomography; FOLFOX: Combination of folinic acid, 5-fluorouracil and oxaliplatin; FOLFOX4: Combination of 5-fluorouracil, leucovorin and oxaliplatin; FOLFIRI: Combination of leucovorin, 5-fluorouracil and irinotecan; GI: Gastrointestinal; M: Male; NA: Not available; PET/CT: Positron emission tomography computed tomography; SMM: Skeletal muscle metastasis.

Our review showed that most of the primary tumours were of an advanced nature (either T3 or T4 with positive lymph node status and poor differentiation). Three patients had mucinous features, and 1 patient had signet ring cell features. This raises the possibility that colorectal cancers with advanced aggressive features on the primary pathology have a higher incidence of SMM. Studies have shown that colorectal cancers with advanced pathological features have worse outcomes than early cancers[8]. It has been proposed that the presence of other coexisting pathologies could increase the chances of getting SMM due to colorectal adenocarcinomas. Landriscina *et al*[9] commented that dermatomyositis and other paraneoplastic syndromes could increase the chances of getting SMM. Kanani *et al*[10] also documented a case of multiple SMM associated with colorectal adenocarcinoma and non-Hodgkin's lymphoma with ulcerative colitis. However, no other studies in our literature review commented on any other coexisting pathologies.

The use of minimally invasive approaches has revolutionized the surgical treatment of colorectal cancers. Colorectal resections are now routinely undertaken with the laparoscopic and robotic approaches. Patients have smaller incisions, shorter hospital stays and equal oncological outcomes[11]. The use of laparoscopic surgery for colorectal procedures started in 1990 but became more widespread only in the 21st century. Our case reports were from a lengthy time period, beginning in 1970. Only two case reports specifically mention the use of a laparoscopic approach for the resection. Previous studies have shown that the incidence of distant metastasis and peritoneal seeding is not different between laparoscopic and open approaches[12]. In our search, we did not find any studies that observed that the laparoscopic approach led to fewer distant metastases. However, due to the advantage of decreased environmental exposure due to operating in closed cavities and smaller incisions, the possibility always remains that peritoneal seeding and subsequent metastasis incidence could be lower in minimally invasive approaches.

The incidence of SMM was detected in up to 5.6% of patients in a post-mortem series of cancer patients[13]. However, the incidence of SMM due to colorectal cancers is still extremely low and has been reported to be about 0.028%[14]. The outcome from SMM is generally poor. A large study investigating soft tissue metastases postulated that the survival time from diagnosis to death is 5.4 mo[15]. The studies included in our review were all case reports, and the duration of follow-up was not documented in most of these studies. Hence, it is not possible to comment on the exact mortality of SMM from our study. However, the presence of SMM generally indicates disseminated disease, which would indicate a very poor prognosis.

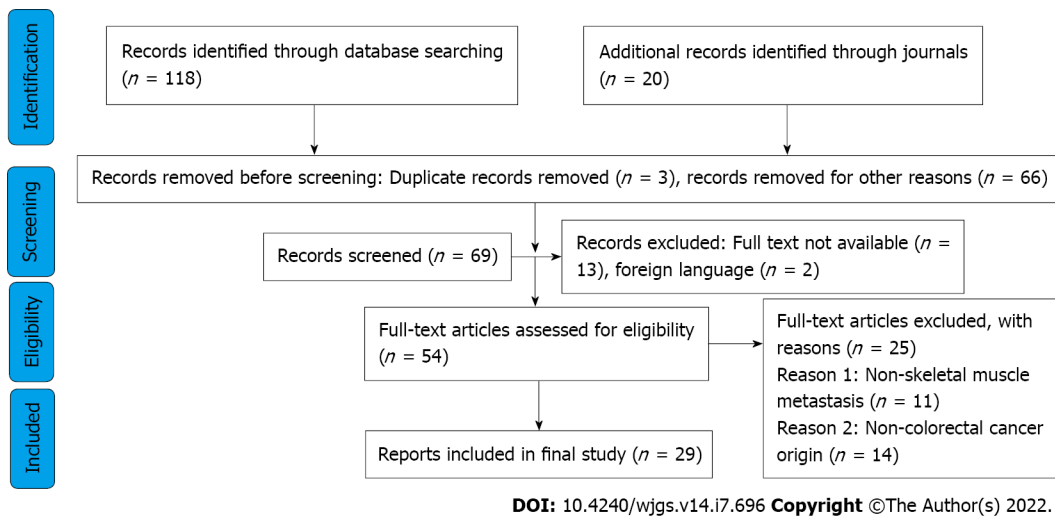


Figure 1 Flow diagram of the study design according to PRISMA 2009.

There have been previous studies that have studied the incidence of SMM due to colorectal cancer [16]. However, we found SMM has been documented in 30 patients in the literature. We believe that this is the maximum number of cases of SMM due to colorectal cancers that have been reported in the literature. All the studies identified were case reports, and very few of these had long-term follow-up. Hence, it is not possible to definitely comment on the treatment strategies and long-term outcomes for these patients. This study again highlights that there is a paucity of literature on SMM due to colorectal adenocarcinoma. This is certainly a field that needs more research in the future.

CONCLUSION

Our review showed that SMM from colorectal adenocarcinomas is a rare complication. However, it is possible that the low incidence could be due to under-reporting. Early use of advanced imaging techniques like FDG-PET and a high index of clinical suspicion might increase the reporting of SMM from colorectal adenocarcinoma.

ARTICLE HIGHLIGHTS

Research background

Skeletal muscle metastasis (SMM) is a rare complication of colorectal adenocarcinomas. The study was conducted to explore, in more detail, the present literature of this unusual finding.

Research motivation

The study encompassed a thorough review of the present literature on SMM due to colorectal adenocarcinoma. Our goal was to highlight the significance of this type of metastasis and increase awareness for early diagnosis and detection.

Research objectives

The aim of this study was to review the literature for cases of SMM from colorectal adenocarcinoma.

Research methods

A systematic literature search was carried out in December 2021. The search strategy was standardized using the PRISMA guidelines.

Research results

SMM were most commonly detected in the thigh muscles. Most of the tumours originated from the rectum or the right colon. The mean time interval between the primary lesion and onset of SMM was 22 mo.

Research conclusions

Our review showed that SMM from colorectal adenocarcinomas is a rare complication. However, it is possible that the low incidence could be due to under-reporting. Early use of advanced imaging techniques, like fluorodeoxyglucose-positron emission tomography, and a high index of clinical suspicion might increase the reporting of SMM from colorectal adenocarcinoma.

Research perspectives

This study again highlights that there is a paucity of literature on SMM after colorectal adenocarcinoma. This is certainly a field that needs more research in the future.

FOOTNOTES

Author contributions: Kulkarni N conceptualized and designed the review; Khalil A and Bodapati S performed the initial literature review; all authors analysed the data; Kulkarni N and Khalil A wrote the final manuscript.

Conflict-of-interest statement: All the authors report no relevant conflicts of interest for this article.

PRISMA 2009 Checklist statement: The authors have read the PRISMA 2009 Checklist, and the manuscript was prepared and revised according to the PRISMA 2009 Checklist.

Open-Access: This article is an open-access article that was selected by an in-house editor and fully peer-reviewed by external reviewers. It is distributed in accordance with the Creative Commons Attribution NonCommercial (CC BY-NC 4.0) license, which permits others to distribute, remix, adapt, build upon this work non-commercially, and license their derivative works on different terms, provided the original work is properly cited and the use is non-commercial. See: <https://creativecommons.org/licenses/by-nc/4.0/>

Country/Territory of origin: United Kingdom

ORCID number: Nikhil Kulkarni 0000-0002-8172-761X; Ahmed Khalil 0000-0002-2264-3571; Shruti Bodapati 0000-0002-6128-4938.

S-Editor: Fan JR

L-Editor: A

P-Editor: Fan JR

REFERENCES

- 1 **World Cancer Research Fund.** Worldwide cancer data. [cited 10 March 2022]. Available from: <https://www.wcrf.org/dietandcancer/worldwide-cancer-data/>
- 2 **Cancer Research UK.** Bowel cancer statistics. [cited 10 March 2022]. Available from: <https://www.cancerresearchuk.org/health-professional/cancer-statistics/statistics-by-cancer-type/bowel-cancer>
- 3 **Buemi A, Aunak S, Mansvelt B.** The Gluteus Muscle an Unusual Localization of a Colon cancer metastasis: Case report and review of literature. *Clin Sur* 2019; **4**: 2575
- 4 **Damron TA, Heiner J.** Distant soft tissue metastases: a series of 30 new patients and 91 cases from the literature. *Ann Surg Oncol* 2000; **7**: 526-534 [PMID: 10947022 DOI: 10.1007/s10434-000-0526-7]
- 5 **Djaldetti M, Sredni B, Zigelman R, Verber M, Fishman P.** Muscle cells produce a low molecular weight factor with anti-cancer activity. *Clin Exp Metastasis* 1996; **14**: 189-196 [PMID: 8674272 DOI: 10.1007/BF00053891]
- 6 **Prasanna T, Karapetis CS, Roder D, Tie J, Padbury R, Price T, Wong R, Shapiro J, Nott L, Lee M, Chua YJ, Craft P, Piantadosi C, Soric M, Gibbs P, Yip D.** The survival outcome of patients with metastatic colorectal cancer based on the site of metastases and the impact of molecular markers and site of primary cancer on metastatic pattern. *Acta Oncol* 2018; **57**: 1438-1444 [PMID: 30035653 DOI: 10.1080/0284186X.2018.1487581]
- 7 **Emmering J, Vogel WV, Stokkel MP.** Intramuscular metastases on FDG PET-CT: a review of the literature. *Nucl Med Commun* 2012; **33**: 117-120 [PMID: 22124361 DOI: 10.1097/MNM.0b013e32834e3ad0]
- 8 **Pozos-Ochoa LI, Lino-Silva LS, León-Takahashi AM, Salcedo-Hernández RA.** Prognosis of Signet Ring Cell Carcinoma of the Colon and Rectum and their Distinction of Mucinous Adenocarcinoma with Signet Ring Cells. A Comparative Study. *Pathol Oncol Res* 2018; **24**: 609-616 [PMID: 28785968 DOI: 10.1007/s12253-017-0283-6]
- 9 **Landriscina M, Gerardi AM, Fersini A, Modoni S, Stoppino LP, Macarini L, Sanguedolce F, Bufo P, Neri V.** Multiple skeletal muscle metastases from colon carcinoma preceded by paraneoplastic dermatomyositis. *Case Rep Med* 2013; **2013**: 392609 [PMID: 23983709 DOI: 10.1155/2013/392609]
- 10 **Kanani H, Gandhi N, Sheth A, Kulkarni N.** Multiple primary malignant neoplasms: a case of colonic adenocarcinoma and non-Hodgkin's lymphoma on a background of ulcerative colitis. *Ann R Coll Surg Engl* 2022; **104**: 47-49 [PMID: 35100853 DOI: 10.1308/rcsann.2021.1008]
- 11 **Schwenk W, Haase O, Neudecker J, Müller JM.** Short term benefits for laparoscopic colorectal resection. *Cochrane Database Syst Rev* 2005; CD003145 [PMID: 16034888 DOI: 10.1002/14651858.CD003145.pub2]

- 12 **Zanghi A**, Cavallaro A, Piccolo G, Fisichella R, Di Vita M, Sparta D, Zanghi G, Berretta S, Palermo F, Cappellani A. Dissemination metastasis after laparoscopic colorectal surgery vs conventional open surgery for colorectal cancer: a metanalysis. *Eur Rev Med Pharmacol Sci* 2013; **17**: 1174-1184 [PMID: [23690186](#)]
- 13 **Nocun A**, Chrapko B. Multiple and solitary skeletal muscle metastases on 18F-FDG PET/CT imaging. *Nucl Med Commun* 2015; **36**: 1091-1099 [PMID: [26275016](#) DOI: [10.1097/MNM.0000000000000368](#)]
- 14 **Hasegawa S**, Sakurai Y, Imazu H, Matsubara T, Ochiai M, Funabiki T, Suzuki K, Mizoguchi Y, Kuroda M, Kasahara M. Metastasis to the forearm skeletal muscle from an adenocarcinoma of the colon: report of a case. *Surg Today* 2000; **30**: 1118-1123 [PMID: [11193747](#) DOI: [10.1007/s005950070013](#)]
- 15 **Plaza JA**, Perez-Montiel D, Mayerson J, Morrison C, Suster S. Metastases to soft tissue: a review of 118 cases over a 30-year period. *Cancer* 2008; **112**: 193-203 [PMID: [18040999](#) DOI: [10.1002/cncr.23151](#)]
- 16 **Guo Y**, Wang S, Zhao ZY, Li JN, Shang A, Li DL, Wang M. Skeletal muscle metastasis with bone metaplasia from colon cancer: A case report and review of the literature. *World J Clin Cases* 2021; **9**: 9285-9294 [PMID: [34786415](#) DOI: [10.12998/wjcc.v9.i30.9285](#)]
- 17 **Yi C**, Liu Z, Chu Y, Li S, Liu L, Li J, Yu X. Ileocecal adenocarcinoma with overexpression of P53 protein metastasized to the thenar muscle: report of a rare case and review of literature. *Int J Clin Exp Pathol* 2015; **8**: 13546-13551 [PMID: [26722571](#)]
- 18 **Araki K**, Kobayashi M, Ogata T, Takuma K. Colorectal carcinoma metastatic to skeletal muscle. *Hepatogastroenterology* 1994; **41**: 405-408 [PMID: [7851845](#)]
- 19 **Manafi-Farid R**, Ayati N, Eftekhari M, Fallahi B, Masoumi F. A Rare Presentation of Colorectal Cancer with Unusual Progressive Intramuscular and Subcutaneous Metastatic Spread. *Asia Ocean J Nucl Med Biol* 2019; **7**: 89-94 [PMID: [30705915](#) DOI: [10.22038/AOJNMB.2018.11934](#)]
- 20 **Torosian MH**, Botet JF, Paglia M. Colon carcinoma metastatic to the thigh--an unusual site of metastasis. Report of a case. *Dis Colon Rectum* 1987; **30**: 805-808 [PMID: [2820673](#) DOI: [10.1007/BF02554632](#)]
- 21 **Okada T**, Nishimura T, Nakamura M, Sakata K, Setoguchi M, Ihara K. [Skeletal muscle metastasis of rectal carcinoma--a case report]. *Gan To Kagaku Ryoho* 2009; **36**: 2248-2250 [PMID: [20037385](#)]
- 22 **Chang PC**, Low HC, Mitra AK. Colonic carcinoma with metastases to the tibialis anterior muscle--a case report. *Ann Acad Med Singap* 1994; **23**: 115-116 [PMID: [8185259](#)]
- 23 **Yoshikawa H**, Kameyama M, Ueda T, Kudawara I, Nakanishi K. Ossifying intramuscular metastasis from colon cancer: report of a case. *Dis Colon Rectum* 1999; **42**: 1225-1227 [PMID: [10496567](#) DOI: [10.1007/BF02238580](#)]
- 24 **Tatsuta K**, Harada T, Nishiwaki Y. Cervical Skeletal Muscle Metastasis of Colorectal Cancer. *Intern Med* 2022; **61**: 263-264 [PMID: [34176845](#) DOI: [10.2169/internalmedicine.7817-21](#)]
- 25 **Iusco D**, Sarli L, Mazzeo A, Donadei E, Roncoroni L. Calf metastasis of colorectal cancer: report of a case. *Chir Ital* 2005; **57**: 783-787 [PMID: [16400777](#)]
- 26 **Hattori H**, Nishimura H, Matsuoka H, Yamamoto K. FDG-PET demonstration of asymptomatic skeletal muscle metastasis from colorectal carcinoma. *J Orthop Sci* 2008; **13**: 481-484 [PMID: [18843466](#) DOI: [10.1007/s00776-008-1251-5](#)]
- 27 **Choi PW**, Kim CN, Kim HS, Lee JM, Heo TG, Park JH, Lee MS, Chang SH. Skeletal Muscle Metastasis from Colorectal Cancer: Report of a Case. *J Korean Soc Coloproctol* 2008; **24** [DOI: [10.3393/jksc.2008.24.6.492](#)]
- 28 **Doroudinia A**, Mehrian P, Doroudinia A, Kaghazchi F. Rectal adenocarcinoma presenting with thigh muscle metastasis as the only metastatic site. *BMJ Case Rep* 2019; **12** [PMID: [30674489](#) DOI: [10.1136/bcr-2018-226802](#)]
- 29 **Tunio MA**, Al Asiri M, Riaz K, Al Shakwer W, Alarifi A. Skeletal Muscle Metastasis Secondary to Adenocarcinoma of Colon: A Case report and review of literature. *J Gastroint Dig Syst* 2013 [DOI: [10.4172/2161-069X.S12-002](#)]
- 30 **Simeunovic K**, Sharma D, Jain V, Botic J, Ramasamy V, Anklesaria A, Korsten M, Ahmed A. A Rare Case of a Skeletal Muscle Mass as an Initial Presentation of Metastatic Colon Carcinoma. *Official J Am College Gas* 2014; **109**: S412
- 31 **Prabhu M**, Raju SHVN, Sachani H. Rectal Carcinoma Metastases to Multiple Skeletal Muscles-Role of F-18 FDG PET/CT. *Indian J Nucl Med* 2017; **32**: 214-216 [PMID: [28680207](#) DOI: [10.4103/ijnm.IJNM_167_16](#)]
- 32 **Tai CH**, Park C, Bhardwaj R, Jean RD, Harshan M, Ilyas N, Swaminath A. Skeletal Muscle (SM) Metastasis: A Rare Initial Presentation of Metastatic Colon Cancer. *Official J Am College Gas* 2014; **114** [DOI: [10.14309/01.ajg.0000595900.09276.16](#)]
- 33 **Farraj K**, Im J, Gonzalez LF, Lu A, Portnoy R 3rd, Podrumar A. Solitary Cystic Psoas Muscle Metastasis From Rectosigmoid Adenocarcinoma. *J Investig Med High Impact Case Rep* 2021; **9**: 23247096211024067 [PMID: [34111988](#) DOI: [10.1177/23247096211024067](#)]
- 34 **Salar O**, Flockton H, Singh R, Reynolds J. Piriformis muscle metastasis from a rectal polyp. *BMJ Case Rep* 2012; **2012** [PMID: [23087286](#) DOI: [10.1136/bcr-2012-007208](#)]
- 35 **Homan HH**, Mühlberger T, Kuhnen C, Steinau HU. [Intramuscular extremity metastasis of adenocarcinoma of the colon]. *Chirurg* 2000; **71**: 1392-1394 [PMID: [11132328](#) DOI: [10.1007/s001040051232](#)]
- 36 **Takada J**, Watanabe K, Kuraya D, Kina M, Hayashi S, Hamada H, Katsuk Y. [An example of metastasis to the iliopsoas muscle from sigmoid colon cancer]. *Gan To Kagaku Ryoho* 2011; **38**: 2294-2297 [PMID: [22202360](#)]
- 37 **Naik VR**, Jaafar H, Mutum SS. Heterotopic ossification in skeletal muscle metastasis from colonic adenocarcinoma--a case report. *Malays J Pathol* 2005; **27**: 119-121 [PMID: [17191396](#)]
- 38 **Burgueño Montañés C**, López Roger R. [Exophthalmos secondary to a lateral rectus muscle metastasis]. *Arch Soc Esp Oftalmol* 2002; **77**: 507-510 [PMID: [12221543](#)]
- 39 **García-Fernández M**, Castro-Navarro J, Saiz-Ayala A, Álvarez-Fernández C. [Orbital metastases in colorectal cancer: a case report]. *Arch Soc Esp Oftalmol* 2012; **87**: 216-219 [PMID: [22732120](#) DOI: [10.1016/j.oftal.2011.08.001](#)]
- 40 **Lampenfild ME**, Reiley MA, Fein MA, Zaloudek CJ. Metastasis to skeletal muscle from colorectal carcinoma. A case report. *Clin Orthop Relat Res* 1990; **193**: 193-196 [PMID: [2364608](#)]
- 41 **Laurence AE**, Murray AJ. Metastasis in skeletal muscle secondary to carcinoma of the colon--presentation of two cases. *Br J Surg* 1970; **57**: 529-530 [PMID: [5427475](#) DOI: [10.1002/bjs.1800570712](#)]



Published by **Baishideng Publishing Group Inc**
7041 Koll Center Parkway, Suite 160, Pleasanton, CA 94566, USA

Telephone: +1-925-3991568

E-mail: bpgoffice@wjgnet.com

Help Desk: <https://www.f6publishing.com/helpdesk>

<https://www.wjgnet.com>

