



Giant cavernous hemangioma of the liver with satellite nodules: Aspects on tumour/tissue interface: A case report

Anne Kristin Fischer, Karl Tobias Erich Beckurts, Reinhard Büttner, Uta Drebber

Specialty type: Gastroenterology and hepatology

Provenance and peer review: Unsolicited article; Externally peer reviewed.

Peer-review model: Single blind

Peer-review report's scientific quality classification

Grade A (Excellent): A
Grade B (Very good): B
Grade C (Good): C
Grade D (Fair): 0
Grade E (Poor): 0

P-Reviewer: Chae HB, South Korea; D'Alessio V, Italy; Zharikov YO, Russia

Received: September 1, 2022

Peer-review started: September 1, 2022

First decision: November 14, 2022

Revised: December 3, 2022

Accepted: April 18, 2023

Article in press: April 18, 2023

Published online: May 27, 2023



Anne Kristin Fischer, Institute of Pathology, University of Cologne, Köln 50937, North Rhine Westphalia, Germany

Karl Tobias Erich Beckurts, Visceral Surgery, Severinsklösterchen Hospital Cologne, Cologne 50678, North Rhine Westphalia, Germany

Reinhard Büttner, Uta Drebber, Institute of Pathology, University Hospital of Cologne, Cologne 50937, North Rhine Westphalia, Germany

Corresponding author: Anne Kristin Fischer, MD, Doctor, Institute of Pathology, University of Cologne, Kerpener Street, Köln 50937, North Rhine Westphalia, Germany. anne.fischer1@uk-koeln.de

Abstract

BACKGROUND

Giant hepatic cavernous hemangioma with multiple satellite nodules is a rare subtype of hepatic cavernous hemangioma, the most common vascular liver tumor. We report on a tumor with unusual histologic features: (1) Finger-like infiltration pattern; (2) lack of encapsulation; (3) blurred tumor/liver interface; and (4) massive satellitosis-referring to the article "Hepatic cavernous hemangioma: underrecognized associated histologic features".

CASE SUMMARY

A 60-year-old man presented with increasing uncharacteristic abdominal discomfort and mildly elevated blood parameters of acute inflammation. Imaging revealed an unclear, giant liver tumor of the left liver lobe. A massive vascular tumor with extensive satellitosis broadly infiltrating the adjacent liver parenchyma was resected *via* hemihepatectomy of segments II/III. Histopathological diagnosis was giant hepatic cavernous hemangioma with multiple satellite nodules, featuring unusual characteristics hardly portrayed in the literature. Retrospectively, this particular morphology can explain the difficult pre- and perioperative diagnosis of a vascular liver tumor that is usually readily identifiable by modern imaging methods.

CONCLUSION

This case emphasizes the exact histological workup of tumor and tumor-induced parenchyma changes in radiologically unclassifiable liver tumors.

Key Words: Giant hepatic cavernous hemangioma; Satellite nodules; Tumour/liver

interface; Vascular liver tumours; Preoperative imaging; Case report

©The Author(s) 2023. Published by Baishideng Publishing Group Inc. All rights reserved.

Core Tip: This case highlights that attention to tumour/tissue borders and knowledge about unusual perilesional parenchyma changes is not only of academic pathological interest, but has an important role in unclear preoperative imaging to discriminate between benign and malignant entities in interdisciplinary hepato-oncology and highly precise modern imaging techniques.

Citation: Fischer AK, Beckurts KTE, Büttner R, Drebbler U. Giant cavernous hemangioma of the liver with satellite nodules: Aspects on tumour/tissue interface: A case report. *World J Hepatol* 2023; 15(5): 707-714

URL: <https://www.wjgnet.com/1948-5182/full/v15/i5/707.htm>

DOI: <https://dx.doi.org/10.4254/wjh.v15.i5.707>

INTRODUCTION

Giant hepatic cavernous hemangioma with multiple satellite nodules is a rare subtype of hepatic cavernous hemangioma, the most common vascular liver tumor. We report on a tumor with unusual histologic features: (1) Finger-like infiltration pattern; (2) lack of encapsulation; (3) blurred tumor/liver interface; and (4) massive satellitosis-referring to the article “Hepatic cavernous hemangioma: underrecognized associated histologic features” by Kim *et al*[1], 2005, in *Liver International*.

CASE PRESENTATION

Chief complaints

We report on a 60-year-old man with an unclear liver tumour of the left liver lobe. Increasing abdominal pressure, finally emanating to the left thorax, indigestion, and night sweat.

History of present illness

Symptoms increased for two months.

History of past illness

No special notes.

Personal and family history

Sixty-year-old man with an unclear liver tumor of the left liver lobe.

Physical examination

Symptoms comprised increasing abdominal pressure, finally emanating to the left thorax, indigestion, and night sweat over two months. Weight loss or exhaustion were not perceived.

Laboratory examinations

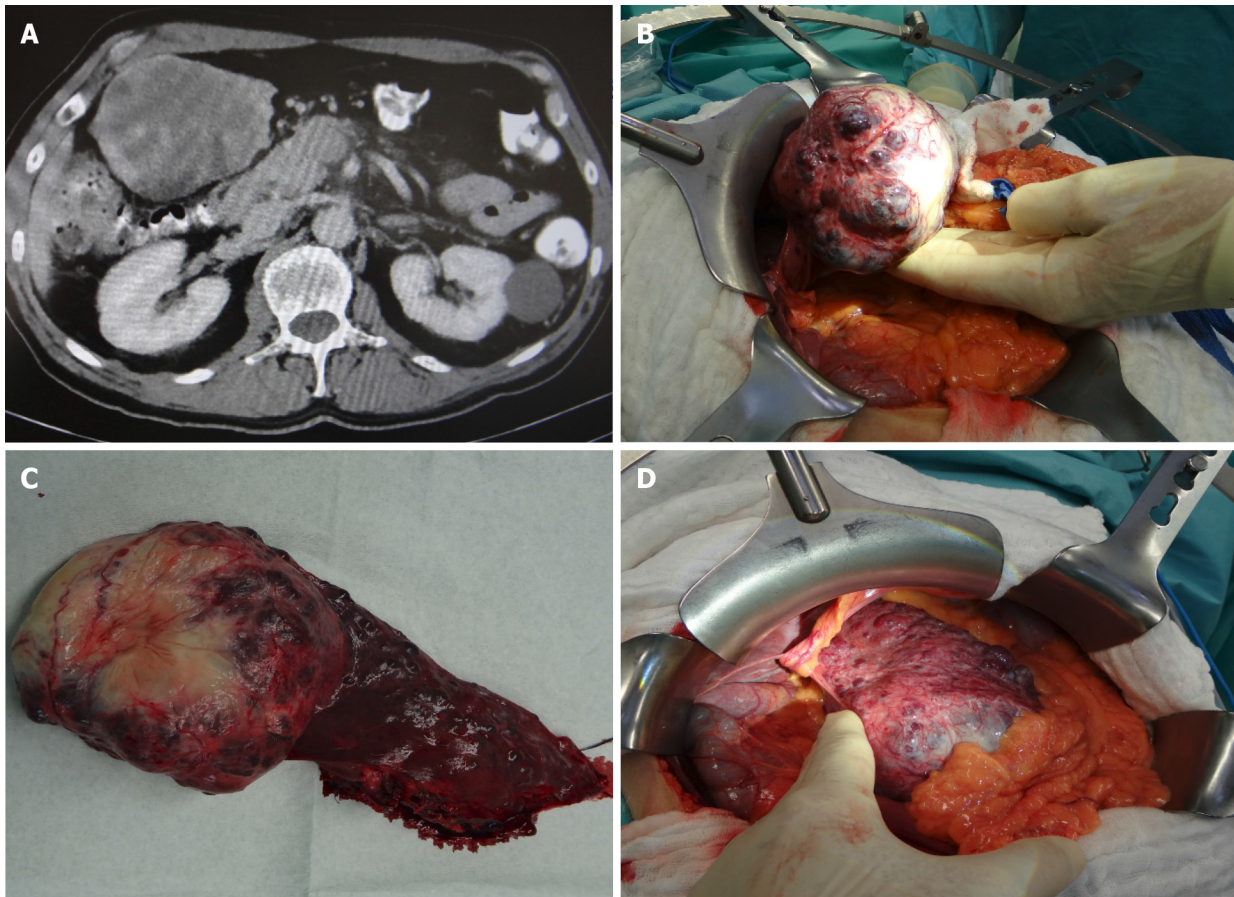
Leukocytes, aspartate transaminase, alanine transaminase, and lactate dehydrogenase were mildly elevated, liver enzymes in the normal range. C reactive protein was mildly elevated at first but increased significantly with aggravation of symptoms.

Imaging examinations

Contrast enhanced computed tomography (CT) showed a voluminous exophytic tumor arising from liver segment III, with atrophy of the left liver lobe, compression of the liver hilus and the left colon flexur (Figure 1A). Radiological diagnosis of hemangioma remained unclear because of blurred tumour borders and multiple tumour satellites in the adjacent liver parenchyma.

Intraoperative presentation

Intraoperatively a solid and spongy dark red tumour measuring 10.5 cm was detected, with multiple small satellite nodules (0.1-0.9 cm) in the neighbouring liver parenchyma (Figure 1B + hypen + D), reminding of metastasis.



DOI: 10.4254/wjh.v15.i5.707 Copyright ©The Author(s) 2023.

Figure 1 Computed tomography imaging and intraoperative pictures. A: Computed tomography imaging demonstrating a giant multicystic vascular liver tumor; B and D: Intraoperative presentation; C: Macroscopic tumor. Main vascular tumor on the left side, adjacent liver parenchyma with multiple small tumor nodules on the right side.

Histological Presentation

Histology revealed a main vascular tumour with a fibrous capsule (Figure 2A), with multiple diffusely spreading unencapsulated capillary tumour foci at the periphery (Figure 2C, Figure 3A + hypen + F), readily identifiable through dilated vessels with intravascular hemocongestion and capillaries in a retiform pattern, with interposed trabecula of liver parenchyma (Figure 3C + hypen + F, Figure 4A). The vessels were lined by flat inconspicuous endothelial cells without mitotic activity. Immunohistochemistry (CD34, ERG and Fli1) highlighted the vascular nature (Figure 4B + hypen + D). No pathological nuclear TP53 accumulation or proliferative activity was found (Figure 4E and F). Capsule-like fibrosis was only observed around the main tumour, whereas satellite nodules lacked a fibrous interface with the adjacent liver parenchyma. Sometimes, small bile ducts and sparse lymphoplasmocytic inflammatory infiltration surrounded the main tumour.

FINAL DIAGNOSIS

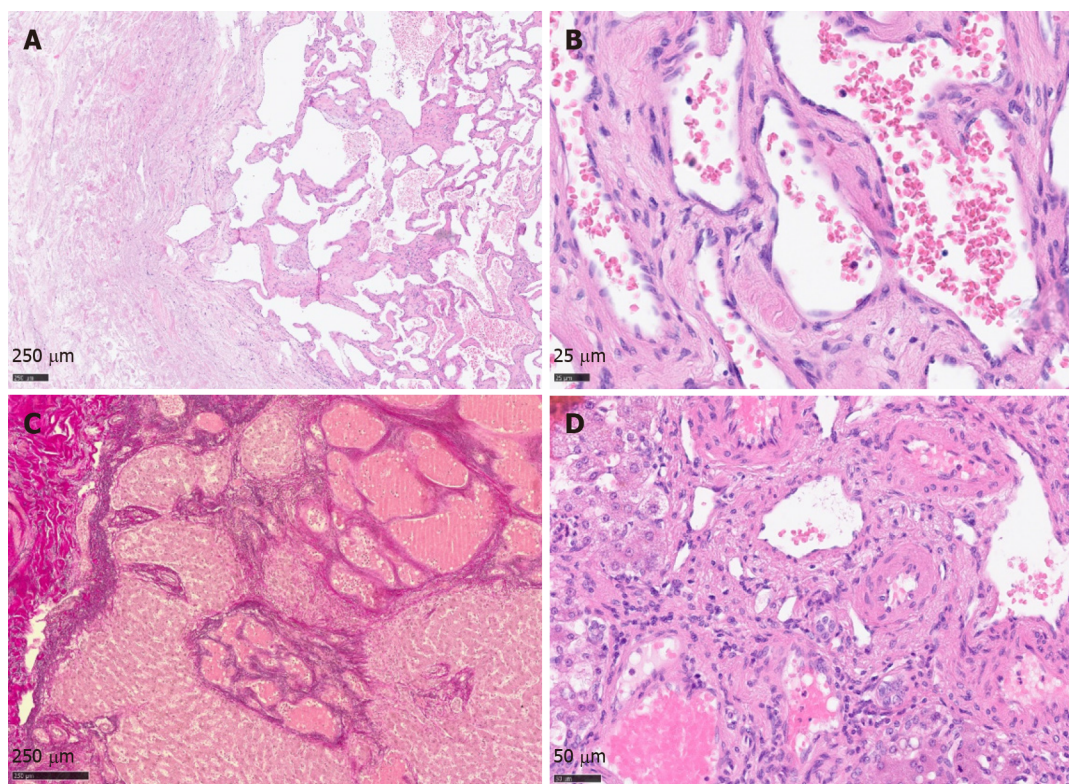
Giant hepatic vascular hemangioma with satellite nodules.

TREATMENT

Left lateral hemihepatectomy of segments II/III with construction of a bladder fistula was performed.

OUTCOME AND FOLLOW-UP

After resection the patient recovered well and was devoid of symptoms.



DOI: 10.4254/wjh.v15.i5.707 Copyright ©The Author(s) 2023.

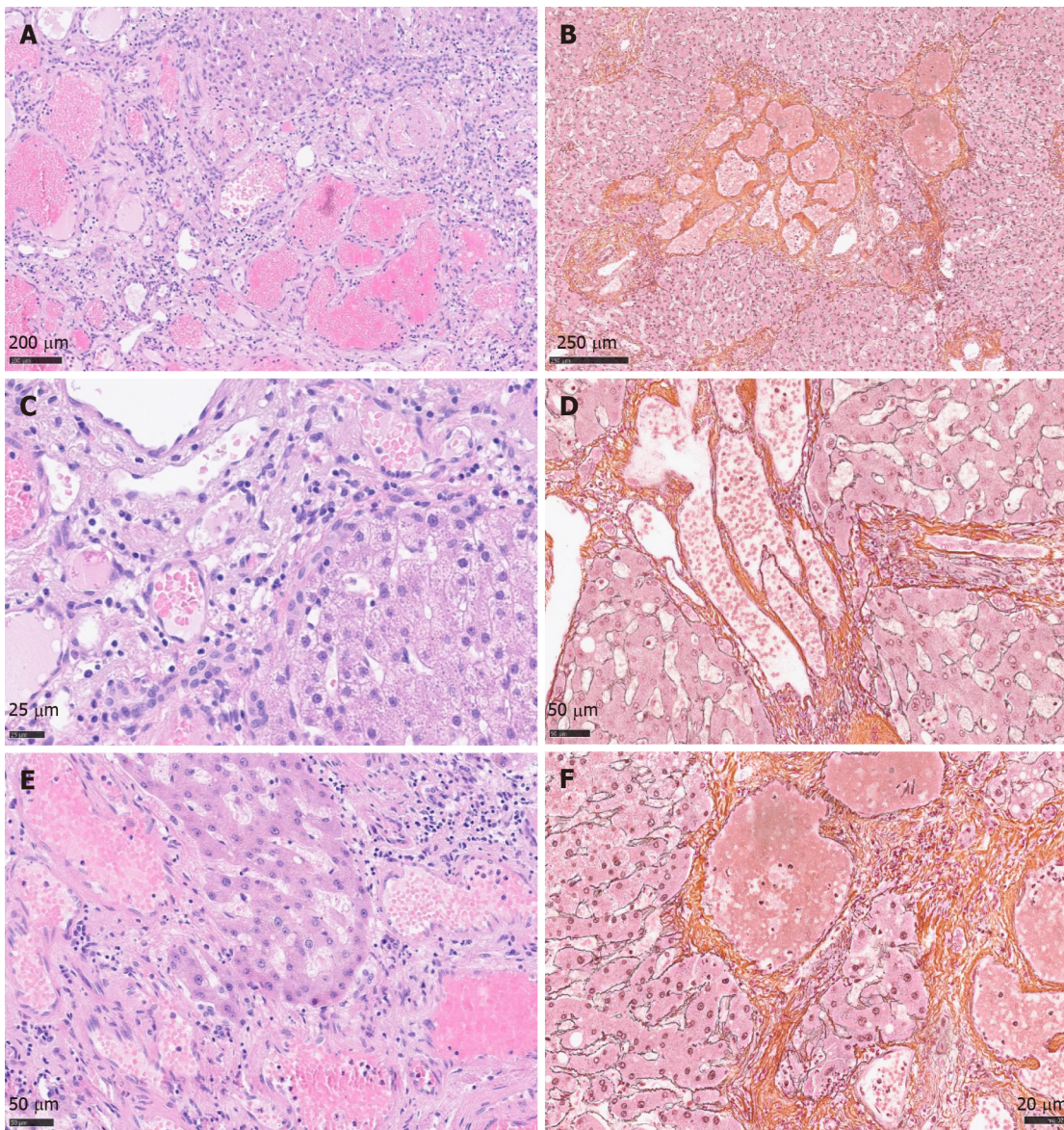
Figure 2 Histology of giant cavernous hemangioma with satellite nodules. A: Tumor overview with dilatated vascular channels on the right side and fibrous regressive tissue on the left side; B and C: Main tumor, high resolution. Vascular channels lined by inconspicuous endothelium; D: EvG staining highlighting tumor nodules in the periphery.

DISCUSSION

Hepatic cavernous hemangioma (CH) is a well-known entity, the most common benign vascular liver tumor with an incidence of 0.4% to 20% in autopsies[1-4]. The term “giant cavernous hemangioma” should be applied for tumors greater than 4 cm[2,5,6], 5 cm[1,7], or even 10 cm[6], depending on the literature. It occurs more often and has greater dimensions in (young) women than in men[1-7]. Etiology and pathogenesis are still unknown, though hormonal influence is discussed as a possible trigger[1,2,7]. Some tumors express estrogen receptors, and growth during puberty, pregnancy, and under medication with oral contraceptives is observed[1,2,7,8-11]. However, single studies also negate a correlation between hormonal influence, sex, and tumor size[5]. A solitary lesion under 3 cm is typical, classically seen in the right posterior liver lobe[2,12], although tumors can occur anywhere in the liver[2,5,12]. In up to 10% of cases, multifocal tumors arise and seldom diffuse hemangiomatosis is found, both much more often in women than in men[1,2,5]. Rarely are hemangiomas associated with focal nodular hyperplasia[2]. They are also observed in hereditary hemorrhagic telangiectasia (HHT; Rendu-Osler-Weber disease)[1,2].

Spontaneous involution by intratumoral thrombosis and vascular obliteration, as well as secondary fibrosis and calcification with phleboliths can occur[1,2,5,7], rarely resulting in a so-called “solitary necrotic nodule” as an end-stage form of completely sclerosed hemangioma[2]. Most tumors are asymptomatic and only detected by incidence. If the hemangioma lies directly under the liver capsule and starts to expand, capsule stretching can cause abdominal pain, and the tumor can even be palpable by clinical examination. Small CH only require surgery if symptomatic, extended tumors should be resected because of the elevated risk of rupture, acute thrombosis and tumor bleeding[1,2,7,13]. Alternatively, transarterial embolization or percutaneous radiofrequency ablation can be an option[2]. Rarely is liver transplantation necessary[1,5]. A rare complication in giant hemangioma in the liver or in extremities is Kasabach Merritt syndrome[2,5], a form of disseminated intravascular coagulopathy in convoluted tumor vessels with coagulopathy, thrombocythemia, and hypofibrinogenemia, triggered by intravascular aggregation of thrombocytes, strong activation of coagulation, and consumption of fibrinogen, with extensive bleeding[14,15].

In most cases highly precise contrast enhanced ultrasound of the liver or contrast-enhanced CT or magnetic resonance imaging does not require histological confirmation of the diagnosis, sparing invasive liver biopsy with the risk of bleeding. Typical imaging reveals peripheral nodular enhancement in the arterial phase, resulting from tumor feeding *via* liver arteries, with progressive

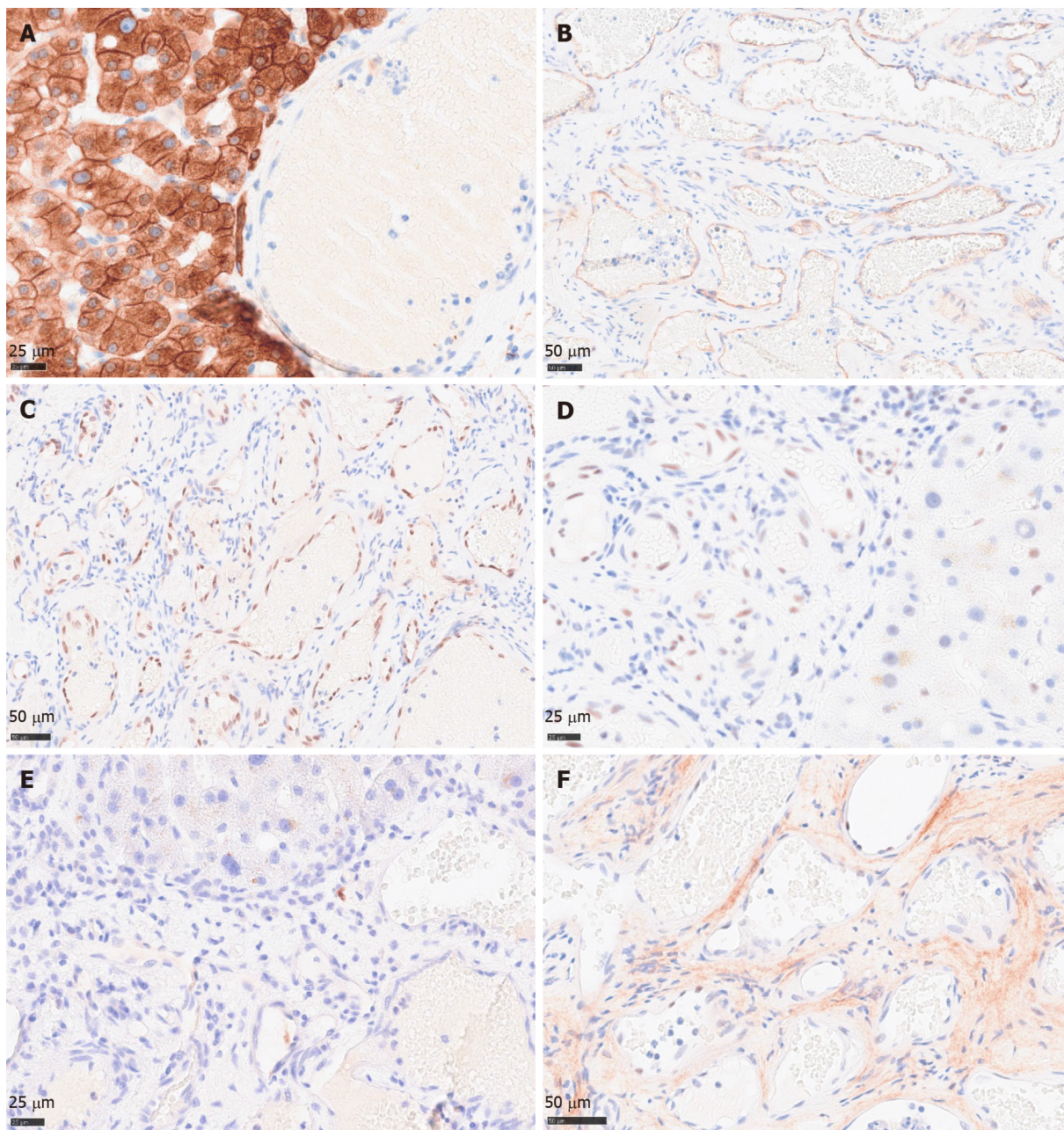


DOI: 10.4254/wjgh.v15.i5.707 Copyright ©The Author(s) 2023.

Figure 3 Histology of giant cavernous hemangioma with satellite nodules. A and B: Satellite nodules of giant hepatic cavernous hemangioma with ill-defined borders, overview in H&E staining and Gomori reticulin fiber staining; C-F: Dilated vascular channels, partially with hemangioma-like morphology, showing bland endothelial lining. Direct contact with adjacent liver parenchyma without formation of a fibrous capsule. High resolution. H&E, left side; Gomori, right side.

centripetal partial or complete fill-in in the portal venous phase, and washout in the late phase[16-18]. However, classical radio-morphological features can be lost with increasing tumor size and morphological variations like multinodularity[1,2,5] or rarely even liver infiltration, then referred to as diffuse hemangiomatosis[†]. Differential diagnosis of hepatic hemangiosarcoma must be considered. Other (vascular) disorders like peliosis hepatis, Budd Chiari syndrome, or venous occlusive disease/sinus obstruction syndrome can mostly be excluded by anatomic distribution in the liver, lacking zonal growth and filling phenomenon[2].

Cavernous hemangioma endothelial cells, so-called “CHECs” by Zhang *et al*[19], 2006, show an enhanced angiogenic activity compared with normal liver sinusoidal endothelial cells or “LSECs”. They express elevated levels of vascular endothelial growth factor (VEGF), metalloproteinases, and angiopoietins[19,20]. The VEGF influence on vascular proliferation of liver hemangioma was also clinically noted. Shrinkage of incidentally detected liver hemangioma was observed during antiangiogenic therapy in patients with colon carcinoma who were treated with bevacicumab[21,22], a recombinant humanized monoclonal anti-VEGF-antibody hampering neoangiogenesis in various tumors or diabetic retinopathy. In hypoxic conditions, (neo) angiogenesis is promoted by autocrine and paracrine secretion of VEGF, which activates the PI3-Kinase/Akt-pathway and the Ras-dependent signaling pathway through Mitogen-activated protein kinases extracellular signal-regulated protein kinase 1 (ERK1) and ERK2. Hypoxia leads to ERK1 and ERK2 activation by phosphorylation, which then hamper degradation of hypoxia inducible factor 1 α (HIF1 α). This factor consecutively binds the



DOI: 10.4254/wjh.v15.i5.707 Copyright ©The Author(s) 2023.

Figure 4 Immunohistochemical profile of cavernous hemangioma. A: Broad spectrum keratine CKAE1/AE3 demonstrating pushing growth pattern of satellite tumor nodules against preexistent liver parenchyma; B: CD34 highlighting vascular tumor channels; C and D: ERG and Flt1 nuclear staining of endothelial tumor cells; E: Negative proliferative activity of satellite tumor nodules, protruding into the liver parenchyma; F: Negative or weak nuclear accumulation of TP53.

hypoxia-responsible element of the VEGF promotor in the nucleus, enhancing VEGF expression, and resulting finally in the proliferation of endothelial cells[21,22]. Hu *et al*[23], 2006, found an aberrantly enlarged endoplasmic reticulum (ER) in “CHECs” by electron microscopy and a downregulation of the protein Derlin-1 that plays a role in the transport of misfolded proteins from the ER to the cytosol for degradation. A shrinkage of the ER to normal size again was observed when Derlin-1 was overexpressed[19], implying a possible error in protein degradation in consecutive storage in ER in “CHECs”.

In our case, the tumor displayed massive satellitosis, but not the diffuse small cystic infiltration pattern of hemangiomatosis. Apart from the main tumor, we did not find the classical histomorphological criteria for CH (“well demarcated”, “fibrous capsule-like border”)[1,2,5,7] in the satellite nodules. However, we recognized several atypical features reported by Zimmermann *et al*[24], 1996, and Kim *et al*[5], 2005, in their series of giant cavernous liver hemangiomas with unusual features, like the so-described “interdigitating pattern”[24] where tumor parts have finger-like expansion into the liver parenchyma, without formation of a typical fibrous interface (Figure 2C + hypen + F). Considering these particular features, together with the classical morphology of the main tumor, other differential diagnosis like peliosis hepatis, hereditary hemorrhagic telangiectasia, or hemangiosarcoma could be

readily excluded.

Spreading pattern also evoked the question of primarily multiple solitary hemangiomas in one liver lobe, of which one nodule started to expand massively, perhaps because of benefited localization next to greater arteria, or general arterial supply only sufficient for the expansion of one nodule. However, a review by Bioulac-Sage *et al*[2], 2008, describes a similar extension pattern of dilated vessels in the close periphery of giant hemangiomas (0.1-2.0 cm beyond tumor borders), so-called hemangioma-like vessels (HLV)[2], discussing the “HLVs” as a process of expansion. In our case, we found satellite nodules infiltrating the whole resected liver lobe, up to 10 cm away from the main tumor (Figure 1C). The extremely low proliferation index and lack of TP53 accumulation in satellite nodules contradicted a rapid tumor expansion.

Blurred tumor borders and satellite nodules were a challenging aspect in preoperative imaging and, together with the untypical clinical setting (age, sex), did not permit a firm preoperative radiological diagnosis or definite exclusion of malignancy.

CONCLUSION

Giant cavernous hemangioma of the liver with unusual features is a challenging preoperative diagnosis. It requires thorough combined radiological and histomorphological workup with special regard to (1) finger-like infiltration pattern; (2) lack of encapsulation; (3) blurred tumor/liver interface; and (4) massive satellitosis. Moreover, attention must be paid to areas with diffuse and dense vascular spreading pattern, so that hemangiomatosis is not overlooked. Considering these rarely described features is essential in preoperative imaging and liver biopsy, to not prematurely drop the diagnosis of cavernous hemangioma, as well as to enlarge the portfolio of (malignant) differential diagnosis. Cases like this enhance the importance of interdisciplinary collaboration of radiology, hepatology, and hepatopathology, and the correlation of rare histomorphological aspects with modern imaging methods.

ACKNOWLEDGEMENTS

We thank Dr. Jochen Müller, MD, who greatly supported this work.

FOOTNOTES

Author contributions: Fischer AK designed, wrote and edited the manuscript; Drebber U made the final diagnosis; Beckurts KTE performed the operation and delivered clinical information; all authors discussed the results and contributed to the final manuscript.

Informed consent statement: Informed consent was obtained from the patient for the publication of his information and imaging.

Conflict-of-interest statement: All the authors do not have any conflicts to disclose.

CARE Checklist (2016) statement: The authors have read the CARE Checklist (2016), and the manuscript was prepared and revised according to the CARE Checklist (2016).

Open-Access: This article is an open-access article that was selected by an in-house editor and fully peer-reviewed by external reviewers. It is distributed in accordance with the Creative Commons Attribution NonCommercial (CC BY-NC 4.0) license, which permits others to distribute, remix, adapt, build upon this work non-commercially, and license their derivative works on different terms, provided the original work is properly cited and the use is non-commercial. See: <https://creativecommons.org/licenses/by-nc/4.0/>

Country/Territory of origin: Germany

ORCID number: Anne Kristin Fischer 0000-0003-0665-9693; Karl Tobias Erich Beckurts 0000-0002-0717-165X; Reinhard Büttner 0000-0001-8806-4786; Uta Drebber 0000-0002-2697-4685.

S-Editor: Liu JH

L-Editor: A

P-Editor: Liu JH

REFERENCES

- 1 **Kim GE**, Thung SN, Tsui WM, Ferrell LD. Hepatic cavernous hemangioma: underrecognized associated histologic features. *Liver Int* 2006; **26**: 334-338 [PMID: [16584396](#) DOI: [10.1111/j.1478-3231.2005.01226.x](#)]
- 2 **Torbenson M**, Zen Y, The, MM. Tumors of the liver. AFIP Atlas of Tumor Pathology Series 4 2018. ISBN-10. 1933477415
- 3 **Bioulac-Sage P**, Laumonier H, Laurent C, Blanc JF, Balabaud C. Benign and malignant vascular tumors of the liver in adults. *Semin Liver Dis* 2008; **28**: 302-314 [PMID: [18814083](#) DOI: [10.1055/s-0028-1085098](#)]
- 4 **Adam YG**, Huvos AG, Fortner JG. Giant hemangiomas of the liver. *Ann Surg* 1970; **172**: 239-245 [PMID: [5433290](#) DOI: [10.1097/0000658-197008000-00010](#)]
- 5 **Sandulescu LD**, Urhut CM, Sandulescu SM, Ciurea AM, Cazacu SM, Iordache S. One stop shop approach for the diagnosis of liver hemangioma. *World J Hepatol* 2021; **13**: 1892-1908 [PMID: [35069996](#) DOI: [10.4254/wjh.v13.i12.1892](#)]
- 6 **Di Carlo I**, Koshy R, Al Mudares S, Arditi A, Bertino G, Toro A. Giant cavernous liver hemangiomas: is it the time to change the size categories? *Hepatobiliary Pancreat Dis Int* 2016; **15**: 21-29 [PMID: [26818540](#) DOI: [10.1016/s1499-3872\(15\)60035-2](#)]
- 7 **Lerut J**, Iesari S. Vascular tumours of the liver: a particular story. *Transl Gastroenterol Hepatol* 2018; **3**: 62 [PMID: [30363746](#) DOI: [10.21037/tgh.2018.09.02](#)]
- 8 **Conter RL**, Longmire WP Jr. Recurrent hepatic hemangiomas. Possible association with estrogen therapy. *Ann Surg* 1988; **207**: 115-119 [PMID: [2829759](#) DOI: [10.1097/0000658-198802000-00001](#)]
- 9 **Baum JK**, Bookstein JJ, Holtz F, Klein EW. Possible association between benign hepatomas and oral contraceptives. *Lancet* 1973; **2**: 926-929 [PMID: [4126557](#) DOI: [10.1016/s0140-6736\(73\)92594-4](#)]
- 10 **Christopherson WM**, Mays ET, Barrows GH. Liver tumors in women on contraceptive steroids. *Obstet Gynecol* 1975; **46**: 221-223 [PMID: [168523](#)]
- 11 **Nissen ED**, Kent DR, Nissen SE, McRae DM. Association of liver tumors with oral contraceptives. *Obstet Gynecol* 1976; **48**: 49-55 [PMID: [180466](#)]
- 12 **Kamyab AA**, Rezaei-Kalantari K. Hepatic Hemangioma in a Cluster of Iranian Population. *J Med Ultrasound* 2019; **27**: 97-100 [PMID: [31316220](#) DOI: [10.4103/JMU.JMU_98_18](#)]
- 13 **Yang YG**, Chen WF, Mai WH, Li XF, Zhou HL, Liu LJ, Li MY. Spontaneous intracapsular hemorrhage of a giant hepatic cavernous hemangioma: a rare case report and literature review. *BMC Gastroenterol* 2021; **21**: 84 [PMID: [33622256](#) DOI: [10.1186/s12876-021-01666-z](#)]
- 14 **Osman NM**. Kasabach - Merritt syndrome: A case report. *Sudan J Paediatr* 2013; **13**: 49-52 [PMID: [27493358](#)]
- 15 **Sarkar M**, Mulliken JB, Kozakewich HP, Robertson RL, Burrows PE. Thrombocytopenic coagulopathy (Kasabach-Merritt phenomenon) is associated with Kaposiform hemangioendothelioma and not with common infantile hemangioma. *Plast Reconstr Surg* 1997; **100**: 1377-1386 [PMID: [9385948](#) DOI: [10.1097/00006534-199711000-00001](#)]
- 16 **Doyle DJ**, Khalili K, Guindi M, Atri M. Imaging features of sclerosed hemangioma. *AJR Am J Roentgenol* 2007; **189**: 67-72 [PMID: [17579154](#) DOI: [10.2214/AJR.06.1076](#)]
- 17 **Song JS**, Kim YN, Moon WS. A sclerosing hemangioma of the liver. *Clin Mol Hepatol* 2013; **19**: 426-430 [PMID: [24459649](#) DOI: [10.3350/cmh.2013.19.4.426](#)]
- 18 **Shin YM**. Sclerosing hemangioma in the liver. *Korean J Hepatol* 2011; **17**: 242-246 [PMID: [22102394](#) DOI: [10.3350/kjhep.2011.17.3.242](#)]
- 19 **Zhang WJ**, Ye LY, Wu LQ, Xin YL, Gu F, Niu JX, Yang ZH, Zhu GJ, Grau GE, Lou JN. Morphologic, phenotypic and functional characteristics of endothelial cells derived from human hepatic cavernous hemangioma. *J Vasc Res* 2006; **43**: 522-532 [PMID: [17008795](#) DOI: [10.1159/000095965](#)]
- 20 **Mahajan D**, Miller C, Hirose K, McCullough A, Yerian L. Incidental reduction in the size of liver hemangioma following use of VEGF inhibitor bevacizumab. *J Hepatol* 2008; **49**: 867-870 [PMID: [18814928](#) DOI: [10.1016/j.jhep.2008.06.028](#)]
- 21 **Homs J**, Daud AI. Spectrum of activity and mechanism of action of VEGF/PDGF inhibitors. *Cancer Control* 2007; **14**: 285-294 [PMID: [17615535](#) DOI: [10.1177/107327480701400312](#)]
- 22 **Shibuya M**. Differential roles of vascular endothelial growth factor receptor-1 and receptor-2 in angiogenesis. *J Biochem Mol Biol* 2006; **39**: 469-478 [PMID: [17002866](#) DOI: [10.5483/bmbrep.2006.39.5.469](#)]
- 23 **Hu D**, Ran YL, Zhong X, Hu H, Yu L, Lou JN, Sun LX, Yang ZH. Overexpressed Derlin-1 inhibits ER expansion in the endothelial cells derived from human hepatic cavernous hemangioma. *J Biochem Mol Biol* 2006; **39**: 677-685 [PMID: [17129402](#) DOI: [10.5483/bmbrep.2006.39.6.677](#)]
- 24 **Zimmermann A**, Baer HU. Fibrous tumor-liver interface in large hepatic neoplasms: its significance for tumor resection and enucleation. *Liver Transpl Surg* 1996; **2**: 192-199 [PMID: [9346648](#) DOI: [10.1002/Lt.500020304](#)]



Published by **Baishideng Publishing Group Inc**
7041 Koll Center Parkway, Suite 160, Pleasanton, CA 94566, USA

Telephone: +1-925-3991568

E-mail: bpgoffice@wjgnet.com

Help Desk: <https://www.f6publishing.com/helpdesk>

<https://www.wjgnet.com>

