

World Journal of *Clinical Cases*

World J Clin Cases 2022 November 26; 10(33): 12066-12461



Contents

Thrice Monthly Volume 10 Number 33 November 26, 2022

MINIREVIEWS

- 12066** Review of risk factors, clinical manifestations, rapid diagnosis, and emergency treatment of neonatal perioperative pneumothorax
Zhang X, Zhang N, Ren YY

ORIGINAL ARTICLE

Clinical and Translational Research

- 12077** Integrative analysis of platelet-related genes for the prognosis of esophageal cancer
Du QC, Wang XY, Hu CK, Zhou L, Fu Z, Liu S, Wang J, Ma YY, Liu MY, Yu H
- 12089** Comprehensive analysis of the relationship between cuproptosis-related genes and esophageal cancer prognosis
Xu H, Du QC, Wang XY, Zhou L, Wang J, Ma YY, Liu MY, Yu H
- 12104** Molecular mechanisms of Baihedihuang decoction as a treatment for breast cancer related anxiety: A network pharmacology and molecular docking study
Li ZH, Yang GH, Wang F
- 12116** Single-cell RNA-sequencing combined with bulk RNA-sequencing analysis of peripheral blood reveals the characteristics and key immune cell genes of ulcerative colitis
Dai YC, Qiao D, Fang CY, Chen QQ, Que RY, Xiao TG, Zheng L, Wang LJ, Zhang YL

Retrospective Study

- 12136** Diagnosis and treatment of tubal endometriosis in women undergoing laparoscopy: A case series from a single hospital
Jiao HN, Song W, Feng WW, Liu H
- 12146** Different positive end expiratory pressure and tidal volume controls on lung protection and inflammatory factors during surgical anesthesia
Wang Y, Yang Y, Wang DM, Li J, Bao QT, Wang BB, Zhu SJ, Zou L
- 12156** Transarterial chemoembolization combined with radiofrequency ablation in the treatment of large hepatocellular carcinoma with stage C
Sun SS, Li WD, Chen JL
- 12164** Coexistence of anaplastic lymphoma kinase rearrangement in lung adenocarcinoma harbouring epidermal growth factor receptor mutation: A single-center study
Zhong WX, Wei XF

Observational Study

- 12175** Prognostic values of optic nerve sheath diameter for comatose patients with acute stroke: An observational study

Zhu S, Cheng C, Wang LL, Zhao DJ, Zhao YL, Liu XZ

- 12184** Quality of care in patients with inflammatory bowel disease from a public health center in Brazil

Takamune DM, Cury GSA, Ferrás G, Herrerias GSP, Rivera A, Barros JR, Baima JP, Saad-Hossne R, Sasaki LY

- 12200** Comparison of the prevalence of sarcopenia in geriatric patients in Xining based on three different diagnostic criteria

Pan SQ, Li XF, Luo MQ, Li YM

Prospective Study

- 12208** Predictors of bowel damage in the long-term progression of Crohn's disease

Fernández-Clotet A, Panés J, Ricart E, Castro-Pocheiro J, Masamunt MC, Rodríguez S, Caballol B, Ordás I, Rimola J

Randomized Controlled Trial

- 12221** Protective effect of recombinant human brain natriuretic peptide against contrast-induced nephropathy in elderly acute myocardial infarction patients: A randomized controlled trial

Zhang YJ, Yin L, Li J

META-ANALYSIS

- 12230** Prognostic role of pretreatment serum ferritin concentration in lung cancer patients: A meta-analysis

Gao Y, Ge JT

CASE REPORT

- 12240** Non-surgical management of dens invaginatus type IIIB in maxillary lateral incisor with three root canals and 6-year follow-up: A case report and review of literature

Arora S, Gill GS, Saquib SA, Saluja P, Baba SM, Khateeb SU, Abdulla AM, Bavabeedu SS, Ali ABM, Elagib MFA

- 12247** Unusual presentation of Loeys-Dietz syndrome: A case report of clinical findings and treatment challenges

Azrad-Daniel S, Cupa-Galvan C, Farca-Soffer S, Perez-Zincer F, Lopez-Acosta ME

- 12257** Peroral endoscopic myotomy assisted with an elastic ring for achalasia with obvious submucosal fibrosis: A case report

Wang BH, Li RY

- 12261** Subclavian brachial plexus metastasis from breast cancer: A case report

Zeng Z, Lin N, Sun LT, Chen CX

- 12268** Case mistaken for leukemia after mRNA COVID-19 vaccine administration: A case report

Lee SB, Park CY, Park SG, Lee HJ

- 12278** Orthodontic-surgical treatment of an Angle Class II malocclusion patient with mandibular hypoplasia and missing maxillary first molars: A case report

Li GF, Zhang CX, Wen J, Huang ZW, Li H

- 12289** Multiple cranial nerve palsies with small angle exotropia following COVID-19 mRNA vaccination in an adolescent: A case report
Lee H, Byun JC, Kim WJ, Chang MC, Kim S
- 12295** Surgical and nutritional interventions for endometrial receptivity: A case report and review of literature
Hernández-Melchor D, Palafox-Gómez C, Madrazo I, Ortiz G, Padilla-Viveros A, López-Bayghen E
- 12305** Conversion therapy for advanced penile cancer with tislelizumab combined with chemotherapy: A case report and review of literature
Long XY, Zhang S, Tang LS, Li X, Liu JY
- 12313** Endoscopic magnetic compression stricturoplasty for congenital esophageal stenosis: A case report
Liu SQ, Lv Y, Luo RX
- 12319** Novel *hydroxymethylbilane synthase* gene mutation identified and confirmed in a woman with acute intermittent porphyria: A case report
Zhou YQ, Wang XQ, Jiang J, Huang SL, Dai ZJ, Kong QQ
- 12328** Modified fixation for periprosthetic supracondylar femur fractures: Two case reports and review of the literature
Li QW, Wu B, Chen B
- 12337** Erbium-doped yttrium aluminum garnet laser and advanced platelet-rich fibrin+ in periodontal diseases: Two case reports and review of the literature
Tan KS
- 12345** Segmental artery injury during transforaminal percutaneous endoscopic lumbar discectomy: Two case reports
Cho WJ, Kim KW, Park HY, Kim BH, Lee JS
- 12352** Pacemaker electrode rupture causes recurrent syncope: A case report
Zhu XY, Tang XH, Huang WY
- 12358** Hybrid intercalated duct lesion of the parotid: A case report
Stankevicius D, Petroska D, Zaleckas L, Kutanovaite O
- 12365** Clinical features and prognosis of multiple myeloma and orbital extramedullary disease: Seven cases report and review of literature
Hu WL, Song JY, Li X, Pei XJ, Zhang JJ, Shen M, Tang R, Pan ZY, Huang ZX
- 12375** Colon mucosal injury caused by water jet malfunction during a screening colonoscopy: A case report
Patel P, Chen CH
- 12380** Primary malignant pericardial mesothelioma with difficult antemortem diagnosis: A case report
Oka N, Orita Y, Oshita C, Nakayama H, Teragawa H
- 12388** Typical imaging manifestation of neuronal intranuclear inclusion disease in a man with unsteady gait: A case report
Gao X, Shao ZD, Zhu L

- 12395** Multimodality imaging and treatment of paranasal sinuses nuclear protein in testis carcinoma: A case report
Huang WP, Gao G, Qiu YK, Yang Q, Song LL, Chen Z, Gao JB, Kang L
- 12404** T1 rectal mucinous adenocarcinoma with bilateral enlarged lateral lymph nodes and unilateral metastasis: A case report
Liu XW, Zhou B, Wu XY, Yu WB, Zhu RF
- 12410** Influence of enhancing dynamic scapular recognition on shoulder disability, and pain in diabetics with frozen shoulder: A case report
Mohamed AA
- 12416** Acute myocardial necrosis caused by aconitine poisoning: A case report
Liao YP, Shen LH, Cai LH, Chen J, Shao HQ
- 12422** Danggui Sini decoction treatment of refractory allergic cutaneous vasculitis: A case report
Chen XY, Wu ZM, Wang R, Cao YH, Tao YL
- 12430** Phlegmonous gastritis after biloma drainage: A case report and review of the literature
Yang KC, Kuo HY, Kang JW
- 12440** Novel *TINF2* gene mutation in dyskeratosis congenita with extremely short telomeres: A case report
Picos-Cárdenas VJ, Beltrán-Ontiveros SA, Cruz-Ramos JA, Contreras-Gutiérrez JA, Arámbula-Meraz E, Angulo-Rojo C, Guadrón-Llanos AM, Leal-León EA, Cedano-Prieto DM, Meza-Espinoza JP
- 12447** Synchronous early gastric and intestinal mucosa-associated lymphoid tissue lymphoma in a *Helicobacter pylori*-negative patient: A case report
Lu SN, Huang C, Li LL, Di LJ, Yao J, Tuo BG, Xie R

LETTER TO THE EDITOR

- 12455** Diagnostic value of metagenomics next-generation sequencing technology in disseminated strongyloidiasis
Song P, Li X
- 12458** Diagnostic value of imaging examination in autoimmune pancreatitis
Wang F, Peng Y, Xiao B

ABOUT COVER

Editorial Board Member of *World Journal of Clinical Cases*, Cornelia Bala, MD, PhD, Professor, Department of Diabetes and Nutrition Diseases, "Iuliu Hatieganu" University of Medicine and Pharmacy, Cluj-Napoca 400006, Romania. cbala@umfcluj.ro

AIMS AND SCOPE

The primary aim of *World Journal of Clinical Cases* (WJCC, *World J Clin Cases*) is to provide scholars and readers from various fields of clinical medicine with a platform to publish high-quality clinical research articles and communicate their research findings online.

WJCC mainly publishes articles reporting research results and findings obtained in the field of clinical medicine and covering a wide range of topics, including case control studies, retrospective cohort studies, retrospective studies, clinical trials studies, observational studies, prospective studies, randomized controlled trials, randomized clinical trials, systematic reviews, meta-analysis, and case reports.

INDEXING/ABSTRACTING

The WJCC is now abstracted and indexed in Science Citation Index Expanded (SCIE, also known as SciSearch®), Journal Citation Reports/Science Edition, Current Contents®/Clinical Medicine, PubMed, PubMed Central, Scopus, Reference Citation Analysis, China National Knowledge Infrastructure, China Science and Technology Journal Database, and Superstar Journals Database. The 2022 Edition of Journal Citation Reports® cites the 2021 impact factor (IF) for WJCC as 1.534; IF without journal self cites: 1.491; 5-year IF: 1.599; Journal Citation Indicator: 0.28; Ranking: 135 among 172 journals in medicine, general and internal; and Quartile category: Q4. The WJCC's CiteScore for 2021 is 1.2 and Scopus CiteScore rank 2021: General Medicine is 443/826.

RESPONSIBLE EDITORS FOR THIS ISSUE

Production Editor: *Ying-Yi Yuan*; Production Department Director: *Xiang Li*; Editorial Office Director: *Jin-Lei Wang*.

NAME OF JOURNAL

World Journal of Clinical Cases

ISSN

ISSN 2307-8960 (online)

LAUNCH DATE

April 16, 2013

FREQUENCY

Thrice Monthly

EDITORS-IN-CHIEF

Bao-Gan Peng, Jerzy Tadeusz Chudek, George Kontogeorgos, Maurizio Serati, Ja Hyeon Ku

EDITORIAL BOARD MEMBERS

<https://www.wjgnet.com/2307-8960/editorialboard.htm>

PUBLICATION DATE

November 26, 2022

COPYRIGHT

© 2022 Baishideng Publishing Group Inc

INSTRUCTIONS TO AUTHORS

<https://www.wjgnet.com/bpg/gerinfo/204>

GUIDELINES FOR ETHICS DOCUMENTS

<https://www.wjgnet.com/bpg/GerInfo/287>

GUIDELINES FOR NON-NATIVE SPEAKERS OF ENGLISH

<https://www.wjgnet.com/bpg/gerinfo/240>

PUBLICATION ETHICS

<https://www.wjgnet.com/bpg/GerInfo/288>

PUBLICATION MISCONDUCT

<https://www.wjgnet.com/bpg/gerinfo/208>

ARTICLE PROCESSING CHARGE

<https://www.wjgnet.com/bpg/gerinfo/242>

STEPS FOR SUBMITTING MANUSCRIPTS

<https://www.wjgnet.com/bpg/GerInfo/239>

ONLINE SUBMISSION

<https://www.f6publishing.com>



Review of risk factors, clinical manifestations, rapid diagnosis, and emergency treatment of neonatal perioperative pneumothorax

Xu Zhang, Ning Zhang, Yue-Yi Ren

Specialty type: Medicine, research and experimental

Provenance and peer review: Unsolicited article; Externally peer reviewed.

Peer-review model: Single blind

Peer-review report's scientific quality classification

Grade A (Excellent): 0
Grade B (Very good): B
Grade C (Good): C
Grade D (Fair): 0
Grade E (Poor): 0

P-Reviewer: Hakimi T, Afghanistan; Pei-Hung L, Taiwan

Received: July 16, 2022

Peer-review started: July 16, 2022

First decision: September 5, 2022

Revised: September 16, 2022

Accepted: October 19, 2022

Article in press: October 19, 2022

Published online: November 26, 2022



Xu Zhang, Yue-Yi Ren, Department of Heart Center, Women's and Children's Hospital Affiliated to Qingdao University, Qingdao 266034, Shandong Province, China

Ning Zhang, Department of Clinical Laboratory, Women's and Children's Hospital Affiliated to Qingdao University, Qingdao 266034, Shandong Province, China

Corresponding author: Yue-Yi Ren, MD, Associate Chief Physician, Associate Professor, Department of Heart Center, Women's and Children's Hospital Affiliated to Qingdao University, No. 217 Liaoyang West Road, Shibei District, Qingdao 266034, Shandong Province, China. xxgmz1173@126.com

Abstract

Perioperative neonatal pneumothorax (NP) is rare but very fatal. Most of the surgeries and treatments in the neonatal period are time-limited or emergent, and there are often some risk factors for pneumothorax before surgery. Physicians, surgeons and anesthesiologists need to identify possible risk factors for pneumothorax before surgery in preterm babies, patients receiving mechanical ventilation and those with underlying lung disease. The clinical presentation of NP is nonspecific, and patients may rapidly develop life-threatening complications if not promptly diagnosed and managed. This review highlights recent progress in the identification of risk factors, clinical manifestations, diagnosis and management of NP during the perioperative period.

Key Words: Neonatal; Perioperative; Pneumothorax; Risk factors; Clinical manifestations; Diagnosis; Management

©The Author(s) 2022. Published by Baishideng Publishing Group Inc. All rights reserved.

Core Tip: Perioperative neonatal pneumothorax (NP) is rare but very fatal. The clinical presentation of NP is nonspecific, and patients may rapidly develop life-threatening complications if not promptly diagnosed and managed. This review highlights recent progress in the identification of risk factors, clinical manifestations, diagnosis and management of NP during the perioperative period.

Citation: Zhang X, Zhang N, Ren YY. Review of risk factors, clinical manifestations, rapid diagnosis, and emergency treatment of neonatal perioperative pneumothorax. *World J Clin Cases* 2022; 10(33): 12066-12076

URL: <https://www.wjgnet.com/2307-8960/full/v10/i33/12066.htm>

DOI: <https://dx.doi.org/10.12998/wjcc.v10.i33.12066>

INTRODUCTION

Perioperative neonatal pneumothorax (NP) is a very rare incidental event that can rapidly develop life-threatening complications. With the exception of perioperative neonatal pneumothorax (PNP) risk factors, most incidents of PNP are related to surgery or anesthesia (Figure 1)[1]. The importance of early diagnosis of pneumothorax is very clear, but diagnosis is difficult for the following reasons: The operating space is limited, the newborn is relatively difficult to access under the sterile sheet, and there are many other factors other than pneumothorax that may affect the judgment of the anesthesiologist. Therefore, it is very important to quickly identify and accurately diagnose pneumothorax in the neonatal perioperative period and to conduct a timely and effective clinical intervention.

In this review, we summarized the risk factors, clinical manifestations, diagnosis and treatment of PNP and prepared a flow-process diagram for the rapid diagnosis and treatment of patients (Figure 2).

RISK FACTORS

Neonatal self-risk factors

Pneumothorax can occur at all ages but more often in the neonatal period. The most important risk factors for NP are prematurity, mechanical ventilation, and continuous positive airway pressure (CPAP). Other risk factors include underlying lung disease and spontaneous pneumothorax[2-5]. Pneumothorax is more likely to occur perioperatively when the newborn has one or multiple risk factors.

Preterm birth: In a multicenter study, researchers reported that the incidence of NP in tertiary hospitals decreased as gestational age increased; by 5.7% in infants aged 28 wk, 1.4% in infants aged 28-37 wk, and 0.8% in infants older than 37 wk[3]. A study showed that for newborns with respiratory distress receiving primary noninvasive respiratory support at 28-36 wk of gestation, prediction in infants of a lower gestational age and with a higher FiO₂ require intubation within 72 h of admission[6]. In infants born at < 32 wk of gestation, both bronchopulmonary dysplasia (BPD) and patent ductus arteriosus may require endotracheal intubation for mechanical ventilation. However, intubation is associated with adverse respiratory outcomes, such as pneumothorax and prolonged positive pressure ventilation[7]. Due to the lack of alveolar surfactant in premature infants, alveolar stability decreases, resulting in widespread alveolar collapse and uneven alveolar pressure. Pneumothorax is more likely to occur when airway pressure changes and mechanical ventilation is used[8].

Mechanical ventilation and CPAP: Mechanical ventilation and CPAP therapy are considered to be two of the most important risk factors for NP[2-4]. A few studies have shown the incidence of pneumothorax after mechanical ventilation (25.6%-76%) or CPAP (30%-96%). Some newborns need respiratory support after birth (such as premature infants with patent ductus arteriosus, congenital diaphragmatic hernia, preoperative mechanical ventilation, and CPAP) to improve ventilation, provide adequate oxygenation, and increase tidal volume and airway peak pressure, but this can result in alveolar rupture, and once that occurs, pneumothorax is inevitable[9].

Potential lung disease: When newborns or premature infants have respiratory distress syndrome, meconium aspiration syndrome, neonatal transient shortness of breath, BPD, pneumonia and other potential lung diseases, lack of lung surfactant or sputum obstruction causing uneven alveolar ventilation, some alveoli can rupture due to excessive inflation expansion, thus pneumothorax occurs [4]. In neonates requiring surgery immediately after birth, such as those with esophageal atresia or with esophageal tracheal fistulas, it is easy to aspirate gastric contents into the lungs, thus causing neonatal atelectasis and pneumonia. Prematurity occurs in 30% to 40% of these newborns, and respiratory distress in premature infants may also lead to lung injury, increasing the incidence of PNP[10].

Spontaneous pneumothorax: The incidence of spontaneous pneumothorax in newborns is approximately 1%-2%, and approximately half of all newborns have pneumothorax symptoms, usually diagnosed within a few hours of birth[11,12]. A study by Aly *et al*[6] showed that the median time to NP diagnosis was 34 h in newborns smaller than 2500 g, but before diagnosis, the newborn may develop tension pneumothorax when undergoing surgery or mechanical ventilation. Park and Lee[13] reported that a newborn with a sudden pneumothorax during esophageal atresia repair was highly suspected of

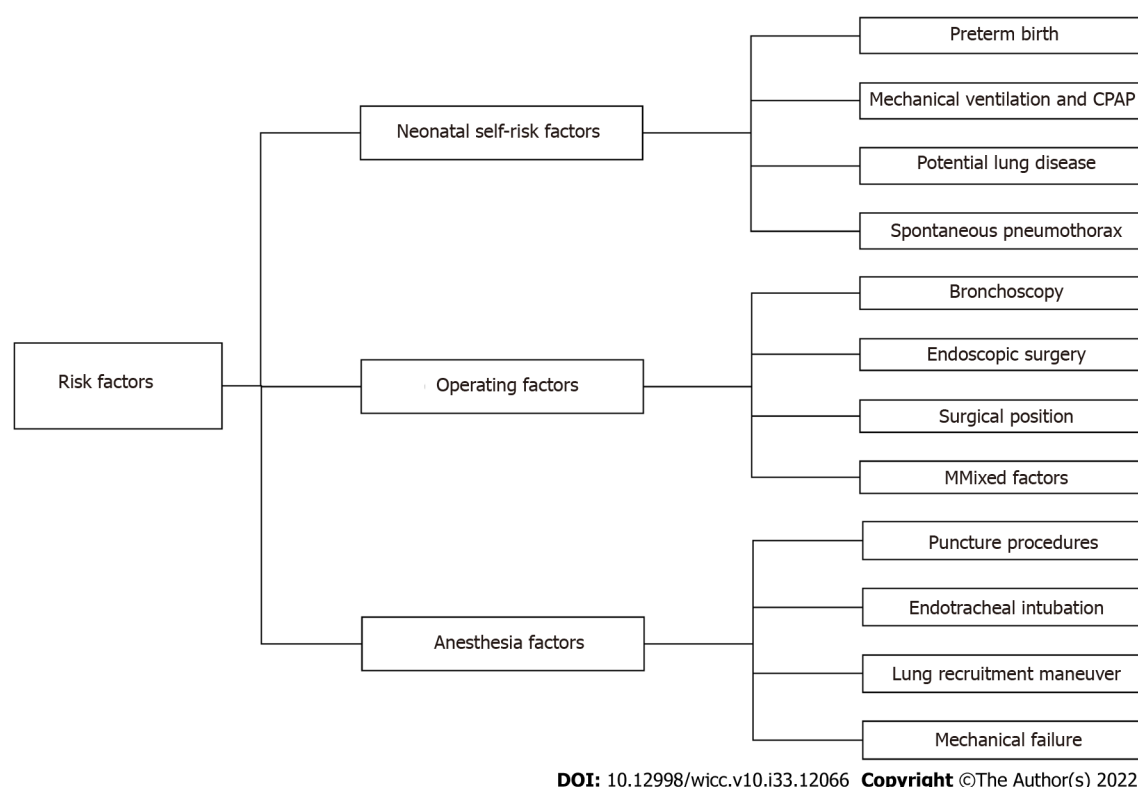


Figure 1 Risk factors for perioperative pneumothorax in neonates. CPAP: Continuous positive airway pressure.

having spontaneous pneumothorax.

Mixed factors: PNP may be the result of a combination of one or more risk factors (Figure 3). Freed *et al* [14] reported a 26-wk premature girl who underwent emergency retinal laser photocoagulation surgery in the operating room at 12 wk of age. She had life-threatening complications with ventilation immediately after anesthesia-induced intubation, and the child underwent needle decompression and insertion of a chest drain. Later, it was believed that the child might have had BPD after birth, and she received mechanical ventilation for prolonged periods. The child had poor lung compliance with abdominal distension and required high airway pressure for ventilation, leaving the patient in a high-risk state for pneumothorax, and tension pneumothorax developed during positive pressure ventilation.

Operating factors

During surgical procedures and examinations, neonates experience iatrogenic factors that cause increased airway pressure, rupture of alveoli, or pleural damage that can cause tension pneumothorax.

Bronchoscopy: Previous studies have reported cases of pneumothorax in neonates undergoing rigid bronchoscopy[15,16]. At present, neonatal fiberoptic bronchoscopy (FOB) has replaced rigid bronchoscopy, so the safety of bronchoscopy has been greatly improved. However, serious complications during FOB in neonates have still been reported in the literature, including bronchospasm, severe hypoxia, bradycardia, and tension pneumothorax[17]. The cause of tension pneumothorax in intubated infants may be that the FOB was introduced through the endotracheal tube (ETT) and occupied almost all of the space of the neonatal ETT. While oxygen was being insufflated through the suction channel of the FOB, the gas blown in was more than that exhaled, leading to barotrauma and alveolar rupture[18]. For non-intubated infants, it seems safe to suggest careful control of oxygen flow into the infant's trachea *via* the FOB. However, some cases of pneumothorax still occurred, and the most likely analysis was that the FOB was pushed into the lobar bronchus to form a seal[19]. Therefore, if a coarser bronchoscope is used in newborns, severe airway obstruction may occur, and the airway pressure at the distal end of the blockage may continuously increase, causing tension pneumothorax.

Endoscopic surgery: The application of endoscopic surgery in newborns can provide a minimally invasive, aesthetic incision that reduces trauma and facilitates postoperative musculoskeletal recovery, especially during thoracic surgery[20]. However, endoscopic surgery requires greater proficiency and anesthesia management, which may prolong the operation time and increase the incidence of surgical complications. Carbon dioxide artificial pneumothorax and single-lung ventilation (SLV) are often used in thoracoscopic surgery to improve the surgical conditions of these procedures[21]. The use of artificial

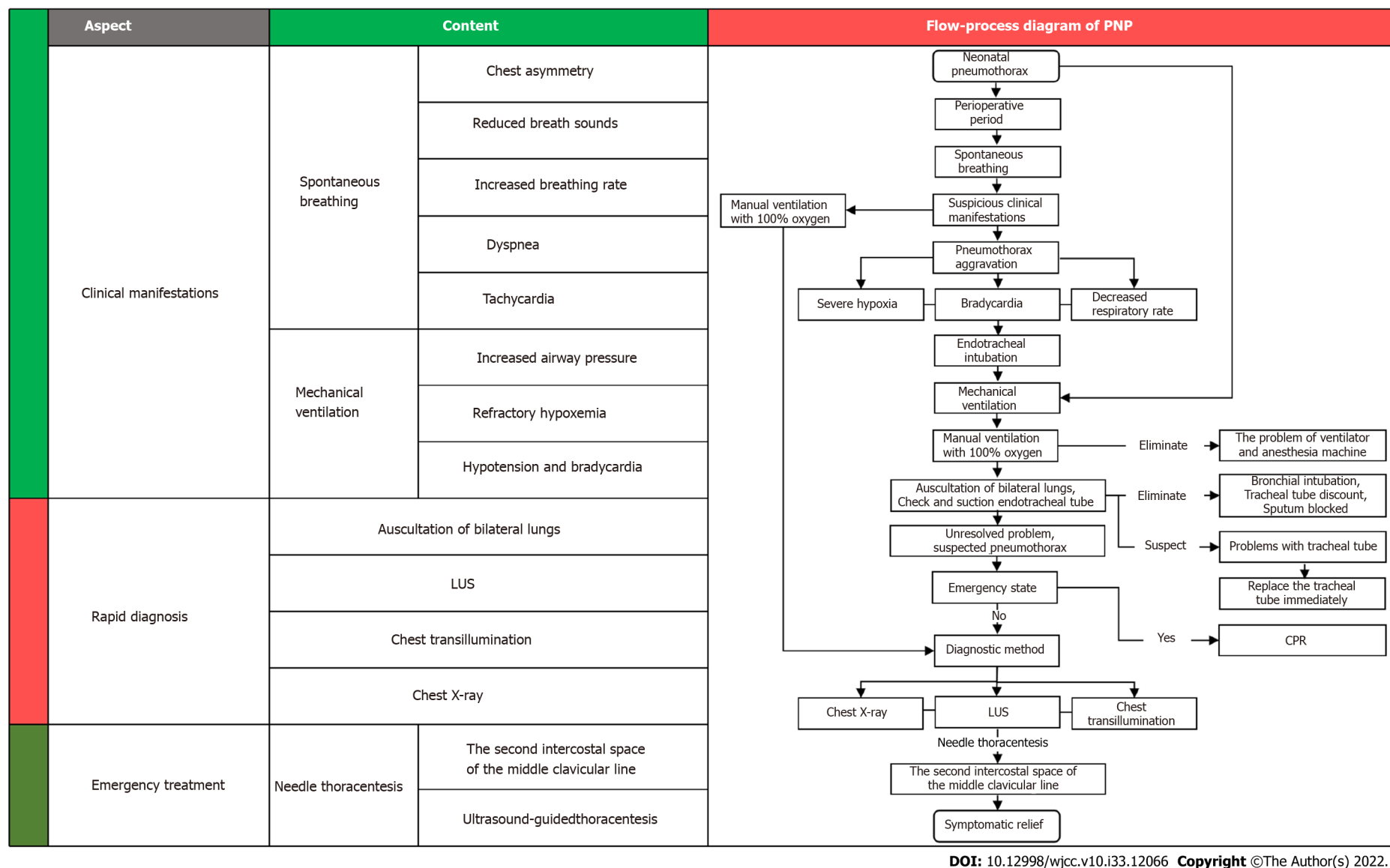


Figure 2 Flow-process diagram for the rapid diagnosis and treatment of perioperative neonatal pneumothorax. PNP: Perioperative neonatal pneumothorax; LUS: Lung ultrasound; CPR: Cardiopulmonary resuscitation.

pneumothorax and SLV in neonatal thoroscopic surgery often causes hypercapnia and spikes in airway pressure, increasing the incidence of barotrauma and pneumothorax, while in some laparoscopic surgeries adjacent to the parietal pleura, the procedure may tear the pleura, leading to the formation of iatrogenic pneumothorax[22].

Surgical position: During lateral recumbent surgery in newborns, the mediastinum compresses the supine lung, and the activity of the diaphragmatic muscles on the recumbent side is more limited than that of the contralateral diaphragm, so neonatal alveoli rupture and pneumothorax occurs when the supine lung is ventilated at a higher airway pressure. Sharma *et al*[23] reported a case of sudden pneumothorax in a neonatal left recumbent position during tracheoesophageal fistula (TEF) repair, with a high suspicion that the pneumothorax was caused by increased lung compliance and ventilation under high airway pressure after fistula ligation.

Anesthesia factors

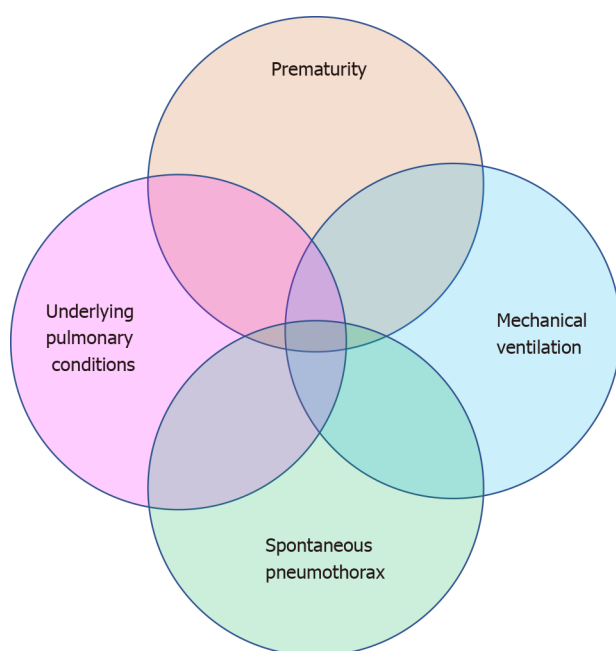
When anesthesiologists perform invasive procedures on newborns during the perioperative period, such as deep vein puncture catheterization, peripheral nerve block, endotracheal intubation, and anesthesia circuit failure, they often result in injury and pneumothorax.

Puncture procedures: The significant anatomical differences between newborns and older children or adults are short neck length, small neck space, loose skin and subcutaneous connective tissue, and inconspicuous anatomical markers. Punctures that include upper extremity block, subclavian or intrajugular venous puncture catheterization, are less successful and have complications[24]. Goli *et al* [25] reported a 32-wk premature infant who underwent peripherally inserted central catheter (PICC) catheterization at 4 d of birth. After the PICC was placed for 2 h, the baby's oxygen saturation decreased to 45%, and the baby developed tachycardia and shortness of breath. The baby received a chest X-ray again, and the presence of a completely white right chest indicated pneumothorax and collapse of the right lung.

Endotracheal intubation: Pneumothorax caused by endotracheal intubation has the following conditions: (1) The ETT is mistakenly inserted into the bronchus during endotracheal intubation and is not found in time, and mechanical ventilation is performed according to the originally set respiratory parameters. Studies reported by Niwas *et al*[26] show that NP occurs predominantly on the right side (72.5%), with 67% of these cases associated with endotracheal intubation of the right main bronchi; (2) When SLV is performed, intentional endotracheal-bronchial intubation makes ventilation more effective but causes higher pressure ventilation, which may lead to pneumothorax and lung damage; and (3) When using endotracheal intubation aids such as a bougie, the tracheal wall is damaged. The bougie, also known as the ETT introducer, is often used to expose a difficult airway for laryngoscopic intubation or to assist in the replacement of endotracheal intubation[27]. However, there have been several reports of pneumothorax in neonates who were intubated with the use of the bougie. Kumar and Walker[28] reported cases of perforation of the airway caused by the bougie. Glaisyer and Way[29] reported 3 cases of pneumothorax during surgery in neonates, and no specific cause was determined, but 2 cases were reintubated using the bougie. In two patients with pneumothorax reported by Parekh *et al*[1], it was suspected that pneumothorax was caused by trauma to the tracheal wall that occurred during bougie-guided endotracheal intubation. In the study by Sakhuja *et al*[30], the examination before neonatal tracheal intubation showed loss of right breath sounds, and chest photography confirmed pneumothorax immediately after intubation. In the analysis, the suspected causes were that the insertion of the bougie into the airway during the replacement of the intubation was too deep, which may have caused trauma and air leakage. Therefore, the use of the bougie is an unusual choice in neonates. It should be used with extreme caution, paying attention to the depth of insertion and associated complications.

Lung recruitment maneuver (LRM): Lung collapse always occurs during mechanical ventilation, usually after induction of general anesthesia[31]. Compared with adults, the residual capacity of neonatal function is lower than that of closed capacity, and its anatomical and physiological characteristics make it more susceptible to alveolar collapse[32]. Therefore, anesthesiologists often perform LRMs and positive end-expiratory pressure (PEEP) during surgery to prevent induction and mechanical ventilation-related atelectasis[33]. However, they are not risk-free. Pneumothorax and barotrauma are major clinical problems, especially in newborns and infants, as their chest compliance is poor, which makes them particularly sensitive to increased airway pressure and prone to pneumothorax. When safe pressure is exceeded, barotrauma may result in trauma and is accompanied by hemodynamic instability. Recent studies have hoped to use the automatic program of LRM software for related operations, as FLOW-i4.3 Anesthesia System (FLOW-i4.3 Anesthesia System®) automatic step-back relapse operation software is safe and effective for healthy newborn models. No adverse respiratory or hemodynamic events were observed during the implementation of the LRM in the pressure-controlled ventilation mode using a gradually increased PEEP (30/15 cmH₂O) approach[34].

Mechanical failure: During the use of the anesthesia machine, the one-way valve can malfunction, and



DOI: 10.12998/wjcc.v10.i33.12066 Copyright ©The Author(s) 2022.

Figure 3 Perioperative neonatal pneumothorax may be the result of a combination of one or more risk factors.

the anesthesia circuit may be kinked, resulting in only gas in (not out), and the pressure in the lungs continues to rise, resulting in barotrauma. In a report by Sabar *et al*[35], pneumothorax occurred during FOB performed prior to tracheoesophageal fistula repair, which was likely due to a kink in the Jackson-Rees breathing circuit that prevented gas from entering but not exiting.

CLINICAL MANIFESTATIONS

Autonomous breathing neonates

Most NP manifest with asymmetric thoracic fluctuations, weakened breathing sounds, and increased breathing rates. If these manifestations are not detected, patients continue to develop shortness of breath, respiratory distress, hypoxemia, tachycardia, and even cardiac arrest[22]. A study on early neonatal signs with pneumothorax concluded that a sudden increase in respiratory rate helped to reliably identify early signs of impending NP with a sensitivity and specificity of 77% and 90%, respectively[36].

Mechanically ventilated neonates

NP manifests with increased airway pressure, increased end expiratory carbon dioxide, and decreased pulse oxygen saturation. However, during neonatal anesthesia and surgery, changes in ventilation parameters, oxygen saturation and decline are common for many reasons, such as increased airway pressure, hypercapnia, and hypoxemia, which are often similar to pneumothorax. This leads anesthesiologists and surgeons to miss the occurrence of pneumothorax, and anesthesiologists may turn to artificial ventilation, leading to increased peak airway pressure. The strong positive pressure expansion further intensifies the degree of pneumothorax and hypoxemia so that patients even develop tension pneumothorax, a slow heartbeat, and cardiac arrest[37,38].

RAPID DIAGNOSIS

The importance of early diagnosis of pneumothorax is very clear, but it is often difficult to diagnose, especially in the operating room. The infants are covered with sterile sheets and are relatively inaccessible, and there are many other tasks that the anesthesiologist must pay attention to. Therefore, pneumothorax is almost impossible to diagnose within the first minutes of oxygenation deterioration and hemodynamic failure, while the sterile sheets are still on. The diagnosis of pneumothorax is generally based on clinical presentation, lung auscultation and associated respiratory function tests.

Clinical manifestations and respiratory sounds on auscultation

In diagnosing pneumothorax according to the clinical manifestations, other causes similar to pneumothorax manifestations should be excluded. Respiratory sounds on auscultation weaken or disappear on the pneumothorax side, especially in cases of left pneumothorax, since a lack of respiratory sounds may be mistaken for unintentional right bronchial intubation, and a high airway pressure is also present under these circumstances[39].

Chest X-ray and computed tomography

In adults, the most commonly used auxiliary examination for the diagnosis of pneumothorax is still chest X-ray. In the study by Cizmeci *et al*[40], positive chest X-ray signs were found to be only 46.6% sensitive and 93.3% specific for accurately identifying pneumothorax in neonatal patients placed in the supine position, and 46% did not have occult pneumothorax before clinical diagnosis. Among the studied X-ray positive signs, deep groove and medial stripe signs were suggestive of occult pneumothorax. The report by Alrajhi *et al*[41] also revealed that chest X-ray reliability is limited in younger preterm and low birth weight infants because pneumothorax may not appear with classic positive signs, and the missed diagnosis rate is up to 30%, resulting in delayed diagnosis. A computed tomography (CT) scan is the gold standard for pneumothorax imaging diagnosis[42]. NP on CT images displays an absence of lung texture in the pleural cavity and sometimes the compressed edge of the affected lung. CT can accurately display the small amount of gas in the pneumothorax and mediastinum, which is very beneficial for clarifying the volume and location of gas accumulation[43]. Simple pneumothorax in mechanically ventilated newborns runs the risk of developing into tension pneumothorax, which may rapidly become life-threatening. Chest X-ray and CT imaging are not easy to obtain in the perioperative period. Therefore, they are not suitable for rapidly diagnosing PNP.

Transillumination

Chest transillumination technology is easier to use in the operating room than chest X-ray equipment, and allows for a rapid diagnosis[44]. A high-strength transmittance portable fiber cold light source is usually used to prevent thermal damage. As the ambient light darkens, the probe is positioned directly above the newborn's nipple while they are in the supine position. The pneumothorax presents as a translucent area within the thorax with an opaque lung parenchyma. A large pneumothorax was reported in a patient at 32 wk gestation with hemodynamic deterioration, and chest ultrasound was not very helpful in diagnosing NP. However, chest transillumination was positive, and an anti-medial NP was found. This study suggests that chest illumination may be more rapid for diagnosing primary NP. Transillumination is the most beneficial method for detecting sudden life-threatening pneumothorax (which requires immediate treatment) because it can be done rapidly, and it is an effective tool for PNP [45]. Notably, strong light radiation causes thermal damage to the skin and photochemical damage to the retina[46]. Attention should be given to protecting the eyes of newborns, and long-term exposure to light radiation should be avoided[47].

Lung ultrasound

Recent studies have shown that lung ultrasound (LUS) is a safe, rapid and effective means to diagnose pneumothorax, especially in the operating room[48]. Pneumothorax can be quickly identified using LUS, even when applied in newborns[49]. In neonates with pneumothorax, LUS also has a higher sensitivity and specificity than chest X-ray. In a meta-analysis[50], the overall specificity and sensitivity of LUS for identifying NP were 98% and 99%, respectively. The most commonly used positive signs for pneumothorax when using LUS are lung sliding and the disappearance of the B-line, which has good sensitivity (100%) for the diagnosis of NP[51]. It has been reported that there are also reliable indicators of pneumothorax in the presence of pleural and A-lines, and their sensitivity and specificity for diagnosing pneumothorax are 100%[52]. The lung point sign is also a positive sign for pneumothorax, which is a transitional phase between the normal (lung sliding) and abnormal (no lung sliding) lung signs and can help providers determine the severity of pneumothorax[53]. Its presence indicates that the pneumothorax is mild to moderate; otherwise, the pneumothorax will be severe[54]. Of course, some positive signs can help exclude pneumothorax. When lung pulse is present (suggesting that the visceral pleura and parietal pleura are in the same location), pneumothorax can be excluded at the examination site. Lung pulse is present when there is atelectasis, but the lung sliding sign is not. Lung pulse and lung sliding signs also occur with endotracheal tube bronchial intubation. For example, during right bronchial intubation, lung sliding signs can appear on the right side, while the left lung collapses with lung pulse without lung sliding signs[55]. Although LUS is influenced by operator experience, it also has high reliability for NP diagnosis, even when used by beginner operators (but prolonged diagnostic time can occur)[52]. Therefore, for experienced operators, portable chest ultrasound diagnosis of pneumothorax is convenient and fast and is suitable for the diagnosis of PNP. In the case of obvious pneumothorax, it is noteworthy that LUS cannot replace clinical judgment and should be actively managed.

EMERGENCY TREATMENT

Changes in ventilation parameters and decreases in oxygen saturation are more common during neonatal anesthesia and surgery, and other common causes must be urgently ruled out before pneumothorax can be diagnosed. Hand ventilation of NP with a T tube and 100% oxygen can exclude circuit problems with the ventilator or anesthesia machine and help to gain understanding regarding the compliance of the lungs. Small endotracheal tubes are prone to bronchial intubation and kinking, and their prolapse is also easily blocked by secretions. They should be carefully and strictly inspected. Endotracheal suction can quickly and safely rule out the above reasons for blockage. If there is still doubt about the tracheal tube, the endotracheal tube should be replaced. In most cases, the problem is resolved quickly. However, when these conditions are not resolved, pneumothorax, although rare, must be considered. Depending on the clinical characteristics of NP, a treatment process is prepared for the perioperative period.

In neonates with tension pneumothorax[32], needle thoracentesis is usually performed with a 22-G intravenous indwelling needle in the midclavicular line of the second intercostal space or the midaxillary line of the fifth intercostal space. Medical evidence shows that compared to traditional thoracic puncture and drainage treatment, puncture and drainage with an intravenous indwelling needle have the same effect and allow for a shorter operation time[56].

Recent research has shown that bedside LUS used in neonates can both improve the accuracy of pneumothorax diagnosis and the effectiveness of thoracic paracentesis. In the four NP patients reported by Gregorio-Hernández *et al*[57], two patients had anterior thoracentesis before ultrasound, but their pneumothorax problems were not resolved, putting them at an additional risk. A recent consensus by international experts on the neonatal diagnosis of pneumothorax ultrasound and ultrasound-guided thoracentesis is that ultrasound can monitor the development of pneumothorax as well as healing after thoracic drainage[58]. The key steps in the successful implementation of thoracentesis are accurate diagnosis of the presence of pneumothorax and accurate location of puncture points. For formally trained and skilled doctors, this task is easily accomplished with ultrasound, which determines the precise location of the lung points, reduces radiation, and increases the safety of neonatal thoracentesis[59].

CONCLUSION

Pneumothorax is a relatively rare complication in neonatal surgery. In cases of neonatal pneumothorax, if not treated quickly, it may lead to fatal events. All procedures during the perioperative period have the potential to cause pneumothorax in neonates, especially premature infants. Therefore, neonates should be closely monitored to prevent a sudden rise in airway pressure, causing drastic changes in lung compliance. Anesthesiologists should identify the potential risk factors for PNP. The perioperative elevation of unexplained airway pressure and hypoxemia should raise suspicion for pneumothorax. Other possible causes can be quickly excluded, and timely diagnosis and emergency thoracocentesis with auxiliary equipment are key to managing pneumothorax. In an emergency, thoracentesis in the midclavicular line of the second intercostal space remains the fastest and safest treatment method for tension pneumothorax. Advanced ultrasound equipment and lung ultrasound technology provide strong support for the rapid diagnosis and management of pneumothorax.

FOOTNOTES

Author contributions: Zhang X and Ren YY designed this review; Zhang X and Zhang N wrote the review; Ren YY revised the review; all authors have read and approved the final manuscript.

Conflict-of-interest statement: All the authors report no relevant conflicts of interest for this article.

Open-Access: This article is an open-access article that was selected by an in-house editor and fully peer-reviewed by external reviewers. It is distributed in accordance with the Creative Commons Attribution NonCommercial (CC BY-NC 4.0) license, which permits others to distribute, remix, adapt, build upon this work non-commercially, and license their derivative works on different terms, provided the original work is properly cited and the use is non-commercial. See: <https://creativecommons.org/licenses/by-nc/4.0/>

Country/Territory of origin: China

ORCID number: Xu Zhang 0000-0002-6481-2505; Ning Zhang 0000-0001-8358-2197; Yue-Yi Ren 0000-0002-0410-7978.

S-Editor: Liu GL

L-Editor: Webster JR

P-Editor: Liu GL

REFERENCES

- 1 Parekh UR, Maguire AM, Emery J, Martin PH. Pneumothorax in neonates: Complication during endotracheal intubation, diagnosis, and management. *J Anaesthesiol Clin Pharmacol* 2016; **32**: 397-399 [PMID: 27625498 DOI: 10.4103/0970-9185.188820]
- 2 Hadzic D, Skokic F, Husaric E, Alihodzic H, Softic D, Kovacevic D. Risk Factors and Outcome of Neonatal Pneumothorax in Tuzla Canton. *Mater Sociomed* 2019; **31**: 66-70 [PMID: 31213960 DOI: 10.5455/msm.2019.31.66-70]
- 3 Vibede L, Vibede E, Bendtsen M, Pedersen L, Ebbesen F. Neonatal Pneumothorax: A Descriptive Regional Danish Study. *Neonatology* 2017; **111**: 303-308 [PMID: 28013308 DOI: 10.1159/000453029]
- 4 Joshi A, Kumar M, Rebekah G, Santhanam S. Etiology, clinical profile and outcome of neonatal pneumothorax in tertiary care center in South India: 13 years experience. *J Matern Fetal Neonatal Med* 2022; **35**: 520-524 [PMID: 32075452 DOI: 10.1080/14767058.2020.1727880]
- 5 Al Matary A, Munshi HH, Abozaid S, Qaraqi M, Wani TA, Abu-Shaheen AK. Characteristics of Neonatal Pneumothorax in Saudi Arabia: Three Years' Experience. *Oman Med J* 2017; **32**: 135-139 [PMID: 28439384 DOI: 10.5001/omj.2017.24]
- 6 Aly H, Massaro A, Acun C, Ozen M. Pneumothorax in the newborn: clinical presentation, risk factors and outcomes. *J Matern Fetal Neonatal Med* 2014; **27**: 402-406 [PMID: 23790085 DOI: 10.3109/14767058.2013.818114]
- 7 Roberts CT, Owen LS, Frøisland DH, Doyle LW, Davis PG, Manley BJ. Predictors and Outcomes of Early Intubation in Infants Born at 28-36 Weeks of Gestation Receiving Noninvasive Respiratory Support. *J Pediatr* 2020; **216**: 109-116.e1 [PMID: 31610936 DOI: 10.1016/j.jpeds.2019.09.026]
- 8 Duong HH, Mirea L, Shah PS, Yang J, Lee SK, Sankaran K. Pneumothorax in neonates: Trends, predictors and outcomes. *J Neonatal Perinatal Med* 2014; **7**: 29-38 [PMID: 24815703 DOI: 10.3233/NPM-1473813]
- 9 Garcia-Muñoz Rodrigo F, Urquía Martí L, Galán Henríquez G. Perinatal risk factors for pneumothorax and morbidity and mortality in very low birth weight infants. *J Matern Fetal Neonatal Med* 2017; **30**: 2679-2685 [PMID: 27852166 DOI: 10.1080/14767058.2016.1261281]
- 10 Edelman B, Selvaraj BJ, Joshi M, Patil U, Yarmush J. Anesthesia Practice: Review of Perioperative Management of H-Type Tracheoesophageal Fistula. *Anesthesiol Res Pract* 2019; **2019**: 8621801 [PMID: 31781201 DOI: 10.1155/2019/8621801]
- 11 Smith J, Schumacher RE, Donn SM, Sarkar S. Clinical course of symptomatic spontaneous pneumothorax in term and late preterm newborns: report from a large cohort. *Am J Perinatol* 2011; **28**: 163-168 [PMID: 20700862 DOI: 10.1055/s-0030-1263300]
- 12 Phuyal R, Basnet R, Sapkota A, Gautam U, Chikanbanjar VK. Pneumothorax in a Preterm Neonate: A Case Report. *JNMA J Nepal Med Assoc* 2021; **59** (238): 608-610 [PMID: 34508413 DOI: 10.31729/jnma.5819]
- 13 Park S, Lee H. Tension pneumothorax during tracheoesophageal fistula repair -A case report-. *Proceedings of the Royal Society of Medicine* 2015; **10** (2): 134-137 [DOI: 10.17085/apm.2015.10.2.134]
- 14 Freed C, Guha R. Tension pneumothorax at anesthetic induction in an ex-premature infant with bronchopulmonary dysplasia. *BMJ Case Rep* 2012 [PMID: 22967679 DOI: 10.1136/bcr-2012-006386]
- 15 Gallagher MJ, Muller BJ. Tension pneumothorax during pediatric bronchoscopy. *Anesthesiology* 1981; **55**: 685-686 [PMID: 7305058 DOI: 10.1097/0000542-198155060-00015]
- 16 Harar RP, Pratap R, Chadha N, Tolley N. Bilateral tension pneumothorax following rigid bronchoscopy: a report of an epignathus in a newborn delivered by the EXIT procedure with a fatal outcome. *J Laryngol Otol* 2005; **119**: 400-402 [PMID: 15949108 DOI: 10.1258/0022215053945813]
- 17 Yan C, Hu Y, Qiu G, Gong X, Elda D. The clinical safety and efficacy of flexible bronchoscopy in a neonatal intensive care unit. *Exp Ther Med* 2020; **20**: 95 [PMID: 32973944 DOI: 10.3892/etm.2020.9223]
- 18 Chan IA, Gamble JJ. Tension pneumothorax during flexible bronchoscopy in a nonintubated infant. *Paediatr Anaesth* 2016; **26** (4): 452-454 [PMID: 26740408 DOI: 10.1111/pan.12835]
- 19 Khan RM, Sharma PK, Kaul N. Barotrauma: a life-threatening complication of fiberoptic endotracheal intubation in a neonate. *Paediatr Anaesth* 2010; **20** (8): 782-784 [PMID: 20670252 DOI: 10.1111/j.1460-9592.2010.03360.x]
- 20 Lacher M, Kuebler JF, Dingemann J, Ure BM. Minimal invasive surgery in the newborn: current status and evidence. *Semin Pediatr Surg* 2014; **23**: 249-256 [PMID: 25459008 DOI: 10.1053/j.sempedsurg.2014.09.004]
- 21 Fabila TS, Menghraj SJ. One lung ventilation strategies for infants and children undergoing video assisted thoracoscopic surgery. *Indian J Anaesth* 2013; **57**: 339-344 [PMID: 24163446 DOI: 10.4103/0019-5049.118539]
- 22 Phillips S, Falk GL. Surgical tension pneumothorax during laparoscopic repair of massive hiatus hernia: a different situation requiring different management. *Anaesth Intensive Care* 2011; **39**: 1120-1123 [PMID: 22165368 DOI: 10.1177/0310057X1103900621]
- 23 Sharma R, Dwivedi D, Choudhary R. Pneumothorax in a preterm during tracheoesophageal fistula repair: Challenges in diagnosis and management. *Saudi J Anaesth* 2018; **12** (1): 154-155 [PMID: 29416484 DOI: 10.4103/sja.SJA_231_17]
- 24 Parienti JJ, Mongardon N, Mégarbane B. Intravascular Complications of Central Venous Catheterization by Insertion Site. *N Engl J Med* 2015; **373**: 1220-1229 [PMID: 26398070 DOI: 10.1056/NEJMoa1500964]
- 25 Goli R, Zafarmokhtarian S, Ghalandari M, Babakeshi-Sheytanabad N, Rostami S, Farajollahi H. Pneumothorax as a rare complication of peripherally inserted central catheter (PICC) in neonates: A case report study. *Int J Surg Case Rep* 2021; **88**: 106472 [PMID: 34637990 DOI: 10.1016/j.ijscr.2021.106472]
- 26 Niwas R, Nadroo AM, Sutija VG, Gudavalli M, Narula P. Malposition of endotracheal tube: association with pneumothorax in ventilated neonates. *Arch Dis Child Fetal Neonatal Ed* 2007; **92**: F233-234 [PMID: 17449860 DOI: 10.1136/adc.2006.114111]

- 10.1136/adc.2006.106245]
- 27 **Driver BE**, Prekker ME, Klein LR. Effect of Use of a Bougie vs Endotracheal Tube and Stylet on First-Attempt Intubation Success Among Patients With Difficult Airways Undergoing Emergency Intubation: A Randomized Clinical Trial. *JAMA* 2018; **319**: 2179-2189 [PMID: 29800096 DOI: 10.1001/jama.2018.6496]
 - 28 **Kumar S**, Walker R. Bougie-related tension pneumothorax in a neonate. *Paediatr Anaesth* 2009; **19** (8): 800-801 [PMID: 19624370 DOI: 10.1111/j.1460-9592.2009.03064.x]
 - 29 **Glaisher H**, Way C. Neonatal pneumothorax--an unexpected perioperative complication. *Paediatr Anaesth* 2005; **15**: 997-1000 [PMID: 16238564 DOI: 10.1111/j.1460-9592.2004.01558.x]
 - 30 **Sakhujia P**, Ferenc BA, Fierens I, Garg A, Ratnavel N. Association of pneumothorax with use of a bougie for endotracheal intubation in a neonate. *J Paediatr Child Health* 2019; **55** (3): 376 [PMID: 30828942 DOI: 10.1111/jpc.14383]
 - 31 **Tusman G**, Böhm SH, Warner DO, Sprung J. Atelectasis and perioperative pulmonary complications in high-risk patients. *Curr Opin Anaesthesiol* 2012; **25**: 1-10 [PMID: 22113182 DOI: 10.1097/ACO.0b013e32834dd1eb]
 - 32 **Neumann RP**, von Ungern-Sternberg BS. The neonatal lung--physiology and ventilation. *Paediatr Anaesth* 2014; **24**: 10-21 [PMID: 24152199 DOI: 10.1111/pan.12280]
 - 33 **Blazek EV**, East CE, Jauncey-Cooke J, Bogossian F, Grant CA, Hough J. Lung recruitment manoeuvres for reducing mortality and respiratory morbidity in mechanically ventilated neonates. *Cochrane Database Syst Rev* 2021; **3** (3): CD009969 [PMID: 33781001 DOI: 10.1002/14651858.CD009969.pub2]
 - 34 **Serrano Zuera C**, Guilló Moreno V, Santos González M, Gómez Nieto FJ, Hedenstierna G, García Fernández J. Safety and efficacy evaluation of the automatic stepwise recruitment maneuver in the neonatal population: An in vivo interventional study. Can anesthesiologists safely perform automatic lung recruitment maneuvers in neonates. *Paediatr Anaesth* 2021; **31**: 1003-1010 [PMID: 34152683 DOI: 10.1111/pan.14243]
 - 35 **Sabar MA**, Teale KF, Fryer JM. Tension pneumothorax during ventilation via Ayre's T-piece. *Eur J Anaesthesiol* 1996; **13**: 143-146 [PMID: 8829947 DOI: 10.1046/j.1365-2346.1996.00943.x]
 - 36 **Cizmeci MN**, Kanburoglu MK, Akelma AZ, Andan H, Akin K, Tatli MM. An abrupt increment in the respiratory rate is a sign of neonatal pneumothorax. *J Matern Fetal Neonatal Med* 2015; **28**: 583-587 [PMID: 24849247 DOI: 10.3109/14767058.2014.927425]
 - 37 **Ioannidis G**, Lazaridis G, Baka S. Barotrauma and pneumothorax. *J Thorac Dis* 2015; **7**: S38-43 [PMID: 25774306 DOI: 10.3978/j.issn.2072-1439.2015.01.31]
 - 38 **Moitra VK**, Einav S, Thies KC. Cardiac Arrest in the Operating Room: Resuscitation and Management for the Anesthesiologist: Part 1. *Anesth Analg* 2018; **126**: 876-888 [PMID: 29135598 DOI: 10.1213/ANE.0000000000002596]
 - 39 **Bacon AK**, Paix AD, Williamson JA, Webb RK, Chapman MJ. Crisis management during anaesthesia: pneumothorax. *Qual Saf Health Care* 2005; **14**: e18 [PMID: 15933291 DOI: 10.1136/qshc.2002.004424]
 - 40 **Cizmeci MN**, Akin K, Kanburoglu MK. The utility of special radiological signs on routinely obtained supine anteroposterior chest radiographs for the early recognition of neonatal pneumothorax. *Neonatology* 2013; **104**: 305-311 [PMID: 24192982 DOI: 10.1159/000354545]
 - 41 **Alrajhi K**, Woo MY, Vaillancourt C. Test characteristics of ultrasonography for the detection of pneumothorax: a systematic review and meta-analysis. *Chest* 2012; **141**: 703-708 [PMID: 21868468 DOI: 10.1378/chest.11-0131]
 - 42 **Oveland NP**, Lossius HM, Wemmelund K, Stokkeland PJ, Knudsen L, Sloth E. Using thoracic ultrasonography to accurately assess pneumothorax progression during positive pressure ventilation: a comparison with CT scanning. *Chest* 2013; **143**: 415-422 [PMID: 23188058 DOI: 10.1378/chest.12-1445]
 - 43 **Leonhard G**, Overhoff D, Wessel L. Determining optimal needle size for decompression of tension pneumothorax in children - a CT-based study. *Scand J Trauma Resusc Emerg Med* 2019; **27**: 90 [PMID: 31604472 DOI: 10.1186/s13049-019-0671-x]
 - 44 **Sharma D**, Murki S, Pratap T. Point of care in nursery to diagnose pneumothorax in neonates by new use of LED torch. *New Building Materials* 2015; **9**: (1) [DOI: 10.4103/0975-2870.167973]
 - 45 **Razak A**, Mohanty PK, Venkatesh HA. Anteromedial pneumothorax in a neonate: 'the diagnostic dilemma' and the importance of clinical signs. *BMJ Case Rep* 2014 [PMID: 25471107 DOI: 10.1136/bcr-2013-202487]
 - 46 **Arya A**, Verma A. Trans-illumination in Pneumothorax: A Useful Bedside Tool. *Indian Pediatr* 2017; **54**: 149 [PMID: 28285289 DOI: 10.1007/s13312-017-1020-7]
 - 47 **Miller S**, James R, Landry R, Pfefer J. Optical characterization of cutaneous transilluminators for eye safety. *Biomed Opt Express* 2010; **1**: 771-779 [PMID: 21258508 DOI: 10.1364/BOE.1.000771]
 - 48 **Skinner JR**. Detection of pneumothorax in the preterm infant with ultrasound. *J Paediatr Child Health* 2016; **52**: 1122 [PMID: 27989007 DOI: 10.1111/jpc.13363]
 - 49 **Raimondi F**, Rodriguez Fanjul J, Aversa S. Lung Ultrasound for Diagnosing Pneumothorax in the Critically Ill Neonate. *J Pediatr* 2016; **175**: 74-78.e1 [PMID: 27189678 DOI: 10.1016/j.jpeds.2016.04.018]
 - 50 **Fei Q**, Lin Y, Yuan TM. Lung Ultrasound, a Better Choice for Neonatal Pneumothorax: A Systematic Review and Meta-analysis. *Ultrasound Med Biol* 2021; **47**: 359-369 [PMID: 33341304 DOI: 10.1016/j.ultrasmedbio.2020.11.011]
 - 51 **Hiles M**, Culpam AM, Watts C, Munyombwe T, Wolstenhulme S. Neonatal respiratory distress syndrome: Chest X-ray or lung ultrasound? *Ultrasound* 2017; **25**: 80-91 [PMID: 28567102 DOI: 10.1177/1742271X16689374]
 - 52 **Liu J**, Chi JH, Ren XL. Lung ultrasonography to diagnose pneumothorax of the newborn. *Am J Emerg Med* 2017; **35**: 1298-1302 [PMID: 28404216 DOI: 10.1016/j.ajem.2017.04.001]
 - 53 **Santos-Silva J**, Lichtenstein D, Tuinman PR, Elbers PWG. The lung point, still a sign specific to pneumothorax. *Intensive Care Med* 2019; **45** (9): 1327-1328 [PMID: 31399778 DOI: 10.1007/s00134-019-05677-z]
 - 54 **Deng BY**, Li N, Wu WS. Use of Neonatal Lung Ultrasound for the Early Detection of Pneumothorax. *Am J Perinatol* 2020; **37**: 907-913 [PMID: 31146293 DOI: 10.1055/s-0039-1688999]
 - 55 **Mayo PH**, Copetti R, Feller-Kopman D. Thoracic ultrasonography: a narrative review. *Intensive Care Med* 2019; **45**: 1200-1211 [PMID: 31418060 DOI: 10.1007/s00134-019-05725-8]
 - 56 **Bruschettini M**, Romantsik O, Ramenghi LA. Needle aspiration versus intercostal tube drainage for pneumothorax in the

- newborn. *Cochrane Database Syst Rev* 2016 [PMID: [26751585](#) DOI: [10.1002/14651858.CD011724.pub2](#)]
- 57 **Gregorio-Hernández R**, Pérez-Pérez A, Alonso-Ojembarrena A, Arriaga-Redondo M, Ramos-Navarro C, Sánchez-Luna M. Neonatal pneumothoraces with atypical location: the role of lung ultrasound. *Eur J Pediatr* 2022; **181**: 1751-1756 [PMID: [34845527](#) DOI: [10.1007/s00431-021-04329-z](#)]
- 58 **Liu J**, Kurepa D, Feletti F. International Expert Consensus and Recommendations for Neonatal Pneumothorax Ultrasound Diagnosis and Ultrasound-guided Thoracentesis Procedure. *J Vis Exp* 2020 [PMID: [32225145](#) DOI: [10.3791/60836](#)]
- 59 **Shumbusho JP**, Duanmu Y, Kim SH. Accuracy of Resident-Performed Point-of-Care Lung Ultrasound Examinations Versus Chest Radiography in Pneumothorax Follow-up After Tube Thoracostomy in Rwanda. *J Ultrasound Med* 2020; **39**: 499-506 [PMID: [31490569](#) DOI: [10.1002/jum.15126](#)]



Published by **Baishideng Publishing Group Inc**
7041 Koll Center Parkway, Suite 160, Pleasanton, CA 94566, USA

Telephone: +1-925-3991568

E-mail: bpgoffice@wjgnet.com

Help Desk: <https://www.f6publishing.com/helpdesk>

<https://www.wjgnet.com>

