

World Journal of *Gastroenterology*

World J Gastroenterol 2023 July 14; 29(26): 4099-4221



REVIEW

- 4099 Impact of COVID-19 in individuals with and without pre-existent digestive disorders with a particular focus on elderly patients

Papa A, Covino M, De Lucia SS, Del Gaudio A, Fiorani M, Polito G, Settanni CR, Piccioni A, Franceschi F, Gasbarrini A

- 4120 Irritable bowel syndrome: Epidemiology, overlap disorders, pathophysiology and treatment

Huang KY, Wang FY, Lv M, Ma XX, Tang XD, Lv L

- 4136 Peroxisome proliferator-activated receptors as targets to treat metabolic diseases: Focus on the adipose tissue, liver, and pancreas

Souza-Tavares H, Miranda CS, Vasques-Monteiro IML, Sandoval C, Santana-Oliveira DA, Silva-Veiga FM, Fernandes-da-Silva A, Souza-Mello V

MINIREVIEWS

- 4156 Schistosomal (bilharzial) polyps: Travel through the colon and beyond

Emara MH, Mahros AM, Rasheda AMA, Radwan MI, Mohamed B, Abdelrazik O, Elazab M, Elbatae H

- 4166 Mortality from chronic liver disease: Recent trends and impact of the COVID-19 pandemic

Fedeli U, Barbiellini Amidei C, Casotto V, Grande E, Saia M, Zanetto A, Russo FP

- 4174 Progress in immunotherapy for neuroendocrine neoplasm of the digestive system

Pan WX, Zhang XM, Hao SL, Han W

ORIGINAL ARTICLE

Retrospective Study

- 4186 Radiomics model based on contrast-enhanced computed tomography to predict early recurrence in patients with hepatocellular carcinoma after radical resection

Li SQ, Su LL, Xu TF, Ren LY, Chen DB, Qin WY, Yan XZ, Fan JX, Chen HS, Liao WJ

Clinical Trials Study

- 4200 Raf kinase inhibitor protein combined with phosphorylated extracellular signal-regulated kinase offers valuable prognosis in gastrointestinal stromal tumor

Qu WZ, Wang L, Chen JJ, Wang Y

CASE REPORT

- 4214 Value of contrast-enhanced ultrasound in deep angiomyxoma using a biplane transrectal probe: A case report

Zhang Q, Yan HL, Lu Q, Luo Y

ABOUT COVER

Editorial Board Member of *World Journal of Gastroenterology*, Zoltán Rakonczay Jr, DSc, MD, PhD, Professor, Department of Pathophysiology, University of Szeged, Szeged 6701, Hungary. akonczay.zoltan@med.u-szeged.hu

AIMS AND SCOPE

The primary aim of *World Journal of Gastroenterology* (WJG, *World J Gastroenterol*) is to provide scholars and readers from various fields of gastroenterology and hepatology with a platform to publish high-quality basic and clinical research articles and communicate their research findings online. WJG mainly publishes articles reporting research results and findings obtained in the field of gastroenterology and hepatology and covering a wide range of topics including gastroenterology, hepatology, gastrointestinal endoscopy, gastrointestinal surgery, gastrointestinal oncology, and pediatric gastroenterology.

INDEXING/ABSTRACTING

The WJG is now abstracted and indexed in Science Citation Index Expanded (SCIE, also known as SciSearch®), Current Contents/Clinical Medicine, Journal Citation Reports, Index Medicus, MEDLINE, PubMed, PubMed Central, Scopus, Reference Citation Analysis, China National Knowledge Infrastructure, China Science and Technology Journal Database, and Superstar Journals Database. The 2023 edition of Journal Citation Reports® cites the 2022 impact factor (IF) for WJG as 4.3; IF without journal self cites: 4.1; 5-year IF: 5.3; Journal Citation Indicator: 0.82; Ranking: 33 among 93 journals in gastroenterology and hepatology; and Quartile category: Q2. The WJG's CiteScore for 2021 is 8.3 and Scopus CiteScore rank 2022: Gastroenterology is 22/149.

RESPONSIBLE EDITORS FOR THIS ISSUE

Production Editor: *Ying-Yi Yuan*; Production Department Director: *Xu Guo*; Editorial Office Director: *Jia-Ru Fan*.

NAME OF JOURNAL

World Journal of Gastroenterology

ISSN

ISSN 1007-9327 (print) ISSN 2219-2840 (online)

LAUNCH DATE

October 1, 1995

FREQUENCY

Weekly

EDITORS-IN-CHIEF

Andrzej S Tarnawski

EDITORIAL BOARD MEMBERS

<http://www.wjgnet.com/1007-9327/editorialboard.htm>

PUBLICATION DATE

July 14, 2023

COPYRIGHT

© 2023 Baishideng Publishing Group Inc

INSTRUCTIONS TO AUTHORS

<https://www.wjgnet.com/bpg/gerinfo/204>

GUIDELINES FOR ETHICS DOCUMENTS

<https://www.wjgnet.com/bpg/GerInfo/287>

GUIDELINES FOR NON-NATIVE SPEAKERS OF ENGLISH

<https://www.wjgnet.com/bpg/gerinfo/240>

PUBLICATION ETHICS

<https://www.wjgnet.com/bpg/GerInfo/288>

PUBLICATION MISCONDUCT

<https://www.wjgnet.com/bpg/gerinfo/208>

ARTICLE PROCESSING CHARGE

<https://www.wjgnet.com/bpg/gerinfo/242>

STEPS FOR SUBMITTING MANUSCRIPTS

<https://www.wjgnet.com/bpg/GerInfo/239>

ONLINE SUBMISSION

<https://www.f6publishing.com>



Schistosomal (bilharzial) polyps: Travel through the colon and beyond

Mohamed H Emara, Aya M Mahros, Abdelrahman M Ahmed Rasheda, Mohamed I Radwan, Beshar Mohamed, Osama Abdelrazik, Mostafa Elazab, Hassan Elbatae

Specialty type: Gastroenterology and hepatology

Provenance and peer review: Invited article; Externally peer reviewed.

Peer-review model: Single blind

Peer-review report's scientific quality classification

Grade A (Excellent): A
Grade B (Very good): B
Grade C (Good): 0
Grade D (Fair): 0
Grade E (Poor): 0

P-Reviewer: Gao F, China;
Khelifa F, Tunisia

Received: December 24, 2022

Peer-review started: December 24, 2022

First decision: January 14, 2023

Revised: January 18, 2023

Accepted: March 29, 2023

Article in press: March 29, 2023

Published online: July 14, 2023



Mohamed H Emara, Aya M Mahros, Mostafa Elazab, Hassan Elbatae, Department of Hepatology, Gastroenterology and Infectious Diseases, Kafrelsheikh University, Kafr-Elshikh 33516, Egypt

Abdelrahman M Ahmed Rasheda, Department of Internal Medicine, Gastroenterology Unit, Security Forces Hospital, Riyadh 11481, Saudi Arabia

Mohamed I Radwan, Department of Tropical Medicine, Zagazig University, Zagazig 44519, Egypt

Beshar Mohamed, Department of Gastroenterology, Surrey and Sussex Hospitals NHS Trust, Surrey RH1 5RH, United Kingdom

Osama Abdelrazik, Department of Hepato-Gastroenterology and Infectious Diseases, Al-Azhar University, Cairo 11651, Egypt

Corresponding author: Mohamed H Emara, MD, MSc, Professor, Department of Hepatology, Gastroenterology and Infectious Diseases, Kafrelsheikh University, Ageish Street, Kafr-Elshikh 33516, Egypt. emara_20007@yahoo.com

Abstract

Schistosomiasis (bilharziasis) is a major neglected tropical disease. It is endemic in many tropical and subtropical communities. Schistosomal polyps (S. polyps) are not uncommon presentation of this infection. Although the colon is the most commonly affected organ, many other organs are affected. S. polyps are associated with a variable range of morbidity independent of the Schistosomal infection. S. polyps are frequently described in endemic areas and increasingly reported in non-endemic areas mainly among immigrants and visitors to the endemic areas. This review aimed to increase awareness of practitioners, especially gastroenterologists, for this peculiar type of polyps caused by this neglected infection hence improving patient outcomes. Web-based search of different databases was conducted for the literature focusing the development of S. polyps in the colon and other organs with analysis of the clinical manifestations, diagnosis and treatment. The following key words were used in the search, "Schistosomiasis" OR "Bilharziasis" AND "Polyps" OR "Polyp" AND "Colon" OR "Small intestine" OR "Duodenum" OR "Stomach" OR "Esophagus" OR "Gallbladder" OR "Pharynx" OR "Larynx" OR "Trachea" OR "Urinary bladder" OR "Ureter" OR "Renal Pelvis" OR "Urethra". All publication types including case reports, case series, original research, and review articles were retrieved and analyzed. S.

polyps are not infrequent presentation of acute or chronic Schistosomal infection. *S. polyps* are described in many organs including the bowel, genitourinary tract, skin, gallbladder and the larynx. Presentation of *S. polyps* is variable and depends on the site, number as well as the polyp size. The relationship of *S. polyps* to malignant transformation is a matter of discussion. Presence of *S. polyps* is sometimes the only manifestation of Schistosomiasis. Small polyps can be treated medically with praziquantel, while large accessible polyps are amendable for endoscopic excision through different polyp resection techniques. However, huge, complicated, non-accessible and suspicious polyps are indicated for surgical management or advanced endoscopic resection when appropriate. Clinicians and endoscopists should be aware about these facts when treating patients living in, immigrated from or visiting endemic areas.

Key Words: Schistosomiasis; Bilharziasis; *Schistosomal polyps*; Colon; Praziquantel

©The Author(s) 2023. Published by Baishideng Publishing Group Inc. All rights reserved.

Core Tip: Schistosomiasis is associated with a wide range of pathological lesions including development of polyps. Colon is the commonest site for polyp development, however polyps are reported in many organs including urinary bladder, ureters, larynx, duodenum, small intestine, gallbladder, anus, uterine cervix and external genitalia. Schistosomal polyps are associated with a wide range of morbidity according to the polyp site, size and number. The malignant potential of these polyps is a hot point of discussion. Although small sized polyps can regress with medical therapy using praziquantel, large accessible polyps can be retrieved endoscopically. Complicated, huge and inaccessible polyps can be treated surgically.

Citation: Emara MH, Mahros AM, Rasheda AMA, Radwan MI, Mohamed B, Abdelrazik O, Elazab M, Elbatae H. Schistosomal (bilharzial) polyps: Travel through the colon and beyond. *World J Gastroenterol* 2023; 29(26): 4156-4165

URL: <https://www.wjgnet.com/1007-9327/full/v29/i26/4156.htm>

DOI: <https://dx.doi.org/10.3748/wjg.v29.i26.4156>

INTRODUCTION

Schistosomiasis is a major neglected tropical disease. It is endemic in many geographical regions mainly in Africa, Latin America and Asia. Many data have been published from endemic areas and also from areas where the infection is not likely to occur with diverse clinical presentations. In non-endemic areas the infection is reported among immigrants or visitors to endemic areas[1,2].

This parasitic infestation was described in early human history, with evidence of infection reported in the ancient Egyptian papers and probably other old civilizations. The infection was characterized in the 19th century by the German pathologist Theodor Bilharz; that is why it is named after him as “Bilharziasis”. There are many species of the parasite. Human infection is likely caused by five species, namely *Schistosoma Mansoni*, *S. Haematobium*, *S. Japonicum*, *S. Intercalatum* and *S. Mekongi*[1]. It is obvious that, the infection is linked to water supplies because of the snail intermediate host settles in the water canals and hence agricultural communities are the ultimate victims of the infestations, although persons who came in contact with infected water are prone also to catch the infection.

The clinical manifestation of this infection is either acute or chronic. The acute manifestations are related to the invasion of the human body by the cercarial invading stage through the skin, migration within the body and the early stage of ovi-position. Chronic manifestations are related to the establishment of adult worms and trapping of the deposited ova within the tissues and consequently granuloma formation[1]. The acute presentations include constitutional manifestations with fever, myalgia, urticarial rashes and with ovi-position the manifestations will change to hematuria (urinary Schistosomiasis), diarrhea with blood (intestinal Schistosomiasis), and chronic blood loss; manifested as anemia[1,3]. In chronic cases, development of fibrosis is the hallmark of the disease and this results in devastating sequelae including portal hypertension, hepatic peri-portal fibrosis, and splenomegaly for intestinal Schistosomiasis, while urinary Schistosomiasis is associated with obstructive lesions, increased incidence of stone formation, chronic urinary tract infections, and urinary bladder malignancy[4].

The current review aimed to increase awareness of practitioners, especially gastroenterologists, for this peculiar type of polyps caused by this neglected infection and hence improve patient outcomes.

LITERATURE SEARCH

Web-based search of different databases was conducted, including PubMed/MEDLINE, Cochrane library, Web of Science, Ovid, Science Direct, Scopus, Directory of Open Access Journals, EBSCO HOST, ProQuest, Institute for Scientific Information, EBESCO, Egyptian knowledge bank, Google scholar, *Reference Citation Analysis* (<https://www.referencecitationanalysis.com/>) and the Research Gate, for relevant articles focusing on the development of Schistosomal polyps (*S.*

polyps) in the colon and other organs with analysis of the clinical manifestations, diagnosis and treatment. The following key words were used in the search, “Schistosomiasis” OR “Bilharziasis” AND “Polyps” OR “Polyp” AND “Colon” OR “Small intestine” OR “Duodenum” OR “Stomach” OR “Esophagus” OR “Gallbladder” OR “Pharynx” OR “Larynx” OR “Trachea” OR “Urinary bladder” OR “Ureter” OR “Renal Pelvis” OR “Urethra”. All publication types including case reports, case series, original research, and review articles were retrieved and analyzed.

PATHOGENESIS OF S. POLYPS

The development of polyps in general is linked to hollow organs or organs with contact to space; this enables external growth. Consequently, polyps are frequently reported in the bowel rather than other organs. The final shelters for adults Schistosomes are the intestinal and pelvic venous plexuses whatever the species are and hence the development of S. polyps in the hollow organs drained by this plexuses is not strange, *e.g.*, colon and urinary bladder, while development of polyps in other organs, *e.g.*, skin is considered ectopic. Furthermore, S. polyps may develop in atypical sites, *e.g.*, duodenum, that are not drained by the intestinal or pelvic veins.

The development of polyps in different stages

Stage of ova deposition and trapping: The eggs laid by the adult parasite had a characteristic spine that helps it to dig and find way out, *e.g.*, through the colon mucosa to be released with the stool. The initial step in polyp formation starts when Bilharzial eggs are deposited and trapped within the superficial layers of submucosa. The submucosal connective tissue is delicate and not superficially bound by firmer tissue. Consequently, accumulation of large amounts of eggs, reactive cellular debris and vascular granulation tissue do occur. In the submucosa, the trapped ova produce a TH2 cell-mediated inflammatory response with many cellular and chemical elements being recruited to the area and granuloma formation begins. The hallmark of the granuloma is infiltration by eosinophils (eosinophilic granuloma)[1], however, during this exudative stage of granuloma formation, other inflammatory cells are seen including the epithelioid macrophages and mononuclear cells[1,5].

Stage of proliferation: Within the granuloma necrosis occur[5]. Healing of the developed necrotic foci is associated with fibrous connective tissue formation. Furthermore, the adjacent muscularis mucosa becomes hypertrophied[1,5]. The fibrous tissue in the submucosa and the hypertrophied muscularis mucosa form a barrier hindering the ova transit from the veins to the lumen, hence more ova are entrapped. Sometimes, the adult worms either alone or matted are seen lodged and obstructing small venules within the polyp[5].

Stage of growth and protrusion: The granuloma formation is the basic pathology unit of chronic Schistosomiasis. Ova entrapment induces a foreign body reaction with progressive inflammation and fibrosis (chronic granuloma). As this process continues, a nodule is formed that elevates the hypertrophied muscularis mucosa and mucosa to form the polyp [6]. The polyp's mucosa harbors many goblet cells which secrete large amounts of mucus and this matches the abdominal pain and passage of mucus with stool seen among those patients. Furthermore, the delicate, and highly vascular nature of the polyp facilitates bleeding with the passage of stools[1,5-7].

This previously described mechanism of fibrosis and ova entrapment explain why the Schistosomal eggs are concentrated within the polyps more frequently than in the surrounding mucosa and submucosa[8]. Furthermore, non-inflammatory polyps associated with Schistosomiasis including adenomatous, hamartomatous, and hyperplastic polyps have been reported[1,9].

Stage of fibrosis: When the infection became chronic, the developed granulomas are infiltrated with fibroblasts, and fibrosis does occur[2,10]. Consequently, the polyps may become fibrotic. Small polyps especially when medically treated with praziquantel (PZQ) can then regress in size[11].

SCHISTOSOMAL COLONIC POLYPS

Site

The most common site for the development of S. polyps is the left colon, mainly recto-sigmoid region[3,12] because mesenteric (especially inferior mesenteric) and pelvic venous plexuses are the final habitat of the adult parasite. However, no part of the colon is immune against development of S. polyps. The polyps were described in all parts of the colon mainly in the rectosigmoid[12], but also were described in the caecum[13], ileocaecal valve[14], appendix[15], ascending colon[16], transverse colon[17] as well as the descending colon[12], some reports documented the distribution of S. polyps all through the large bowel starting from the caecum up to the anus during the course of heavy infestations in endemic areas[18].

Number

Schistosomiasis in the endemic areas, is associated with development of multiple polyps and multiplicity correlates with the density of infection[3,18]. However, there are many reports that Schistosomiasis can manifest by single colon polyp discovered either incidentally during colonoscopy or complicated[13,16,19] even without any clinical manifestations suggestive of Schistosomal infection.

Size

Schistosomiasis is usually associated with small-sized polyps[1,3,12]. However, large-sized *S.* polyps have been described in many case reports[12,16,18,19]. We reported earlier[20] that, no part of the colon was immune against development of large *S.* polyps. Many cases presented with solitary *S.* polyps[13,16,19,21] even in absence of any Schistosomiasis-related colon inflammation[9,13,16,19,21].

Atypical presentations and complications

Schistosomal colonic polyps had a wide range of atypical presentations. Elbatee *et al*[19], Alyhari *et al*[7], and Al-Zubaidi *et al*[22], described colo-rectal cancer (CRC) like presentation due to huge polyp size, abnormal polyp morphology or both, respectively. Furthermore, Smith *et al*[23], described diffuse colonic polypoid masses with dysenteric features, a picture endoscopically indistinguishable from familial polyposis and severe ulcerative colitis. Polyp-like lesion in the appendix manifested as acute appendicitis was reported in a Chinese woman by Zhu *et al*[15], while pan-colonic inflammation and polyposis were described in Kenia by Bosire *et al*[18].

S. POLYPS BEYOND THE COLON

Urinary bladder polyps due to *S. Haematobium* have long been described and development of polyps correlates with heaviness of the infection in endemic areas[23]. Urinary bladder *S.* polyps were also reported among visitors to endemic areas[24]. Urinary *S.* polyps are not limited to urinary bladder, they were described within the ureters with a prevalence of 5.9% (30/511) in a large Egyptian study[25]. Due to the anatomical constraints, ureteric *S.* polyps tend to be small[25].

The atypical sites of *S.* polyps (Table 1) were described not infrequently in the literature. As early as in 1951, Gilges [26], described a skin polyp in the clitoris area of an African child. Furthermore, Schistosomal vulvular polyps have been described as vulvular swelling in 9- and 11-year-old girls from endemic areas in Senegal[27] and Nigera[28] respectively.

An ectopic cervical polyp was reported in Puerto Rico by File *et al*[29], despite the light Schistosomal infection. While Eladl *et al*[30] reported an endocervical polyp containing granulomas rich in viable eggs of *S. Hematobium* in a 43-year-old Egyptian woman who manifested with vaginal bleeding.

A slowly growing anal polyp containing Schistosomal ova as well as adult worms was described in a young Brazilian adult by Raso *et al*[5], the parasites probably migrated to the anus through the veins of hemorrhoidal plexus and it was associated with troublesome mass lesion with intense pruritus.

Duodenal polyps due to schistosomiasis have been reported in the literature although not common. In the duodenum it is discovered during endoscopic evaluation for obscure anemia and/or abdominal pain. The described duodenal *S.* polyps are either small, multiple and sessile[31] or solitary and large[32]. One case of dull abdominal pain was diagnosed in the United States with Schistosomiasis complicating a huge duodenal Peutz-Jeghers hamartomatous polyp[9].

The small intestine is infrequently affected with *S.* polyps and due to its narrow lumen, which is usually characterized by obstructive manifestations and diagnosis is established either at laparotomy or more frequently retrograde through histopathologic assessment. Small bowel obstruction due to huge polyp/polypoid mass at the ileocaecal valve[14] was described among visitors as well as residents of endemic areas[33] and small bowel obstruction is the usual presentation of such cases.

Gallbladder *S.* polyps are infrequently reported in the literature, the developed polyps are usually small in size and grew in the fundus, hence obstructive presentation is not likely and it is usually manifest (if any) as right upper quadrant pain. Both urinary (*S. Haematobium*) and intestinal Schistosomiasis (*S. Mansonii* and *S. Japonicum*) have been associated with gallbladder Schistosomiasis[34,35].

Larynx is less commonly affected during the course of Schistosomiasis. Toppozada described *S.* polyp involving the right vocal cord of a 25-year-old Egyptian male presented with 5-mo progressive hoarseness of voice, surgical microscopic excision and pathological examination showed granuloma with terminal sine ova[36].

S. POLYPS AND MALIGNANT TRANSFORMATION

The malignant potential of *S.* polyps is debatable. Although the relationship of urinary Schistosomiasis to malignancy is well established, the direct tumorigenic impact of intestinal *S.* polyps is questionable.

The bowel *S.* polyps have been implicated in the development of CRC and liver (HCC) cancers. The evidence supporting the malignant potential of intestinal Schistosomiasis is in favor of *S. Japonicum* rather than *S. Mansonii*. The chronic inflammatory state induced by ovi-position in the submucosa and other tissues have been proposed as the potential mechanism linking *S. Japonicum* in the Far East to the development of CRC and liver cancer[37].

So far the link between *S. Mansonii* and CRC has been viewed as no more than an epidemiological association and most published literatures deny the precancerous potential of the *S. Mansonii*-associated lesions including the polyps[38]. However, the mood of clinicians is spoiled by the emerging evidence incriminating *S. Mansonii* as a potential carcinogen. A large Egyptian study proposed an association between *S. Mansonii* infection and CRC relying on the increased levels of carcinoembryonic antigen within Bilharzial polyps' tissue[39]. In addition, one case report[40] retrieved Schistosome ova from the CRC specimens during histologic examination. Parasitism is associated with DNA repair defects with resultant genome instability, a commonly reported anomaly in CRC[38]. Furthermore, an emerging evidence through biomolecular mechanisms suggests an association between *S. Mansonii* and human carcinogenesis mainly for HCC and CRC and this is

Table 1 Summary of atypical and ectopic schistosomal polyps

Ref.	Site	Size	Presentation	Source
Raso <i>et al</i> [5], 2013	Anus	Large (2.5 cm)	Swelling with pain and intense pruritus	Endemic area
Gilges[26], 1951	External genitalia (clitoris)	Not mentioned	Mass like	Report from endemic area
Eladl <i>et al</i> [30], 2012	Cervix	Large sized (3 mc)	Vaginal bleeding	Endemic area
File <i>et al</i> [29], 1998	Cervix	Large	Gynecologic	Common area of spread. Adult worms within the polyp
Dioussé <i>et al</i> [27], 2016	Vulva	Large	Mass like	Endemic area
Sahabi and Rabiou [28], 2017	Vulva	Large	Mass like	Endemic area
Gonzalez <i>et al</i> [9], 2021	Duodenum	Huge (≥ 4 cm)	Dull abdominal pain	Resident of non-endemic area with a history of travel to endemic areas
Altonbary <i>et al</i> [31], 2014	Duodenum	Diminutive (≤ 4 mm)	Abdominal pain and generalized lymphadenopathy	Endemic area
Thatcher <i>et al</i> [32], 1984	Duodenum	Large	Isolated polyp	Non-endemic area
Lamyman <i>et al</i> [14], 2006	Ileocaecal valve area	Large	Intestinal obstruction	Visitor to endemic areas
Ali <i>et al</i> [34], 2021	Gallbladder fundus	Small 6 mm	Vague Abdominal pain	Patient from endemic area
Ghimire <i>et al</i> [35], 2020	Gallbladder fundus	Diminutive 3 mm	Right hypochondrial pain	Non-endemic areas
Toppozada[36], 1985	Larynx, right vocal cord	Large	Hoarseness of voice	Endemic area

likely through many egg-related agents and Th2-immune mechanisms[41]. A single recent report described for the first time a concomitant infection with *S. Mekongi* and rectal cancer[42].

The association of *S. Haematobium* and the urinary bladder squamous cell cancer is well established[43] and that is why *S. Haematobium* is classified as group 1 definitive biological carcinogenic. This association is probable with all forms of urinary bladder- induced Schistosomal pathology including chronic bladder wall inflammation and irritation by the deposited ova, the induced ulcers, sandy patches and also to the developed *S. polyps*[44]. There is no clear evidence in the literature linking intestinal Schistosomiasis to bladder tumors and vice versa[9].

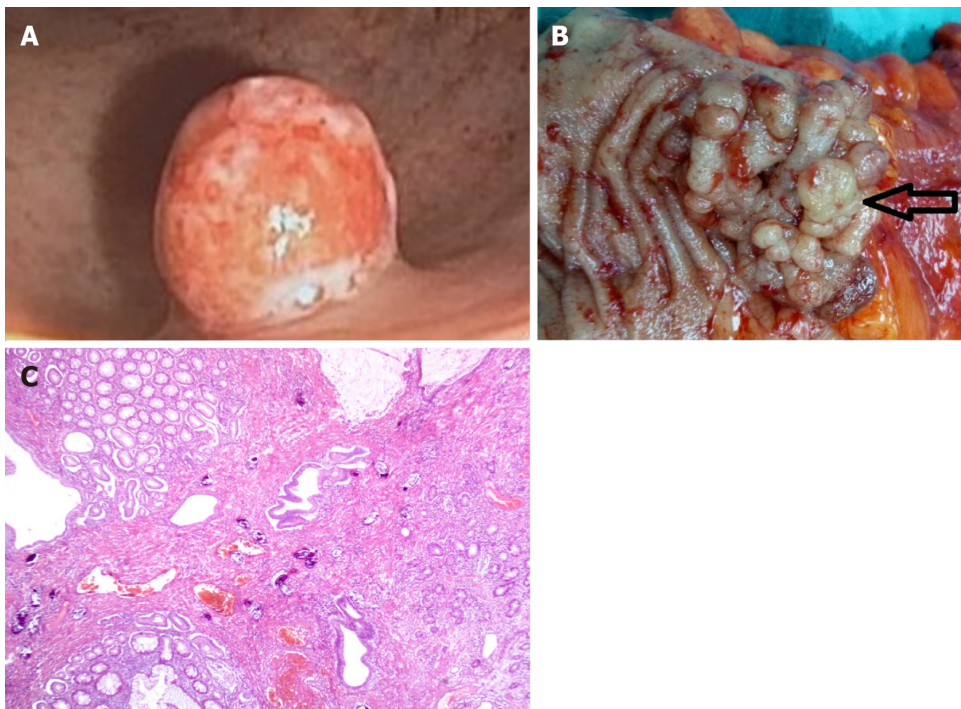
DIFFERENTIAL DIAGNOSIS

The severe forms of intestinal Schistosomiasis are characterized by the presence of multiple variable sized polyps against a background of diffuse mucosal affection showing mucosal erythema, and ulcerations, a picture mistaken with inflammatory bowel disease[3]. *S. polyps* of the colon are usually located in the recto-sigmoid region[12] and tend to be small[3, 12] (Figure 1A) and dark grey in color with surface ulceration, however other conditions with multiple colonic polyps should be considered in the differential diagnosis.

The solitary forms of *S. polyps* should be differentiated from other polyps according to the location. In fact, there is no characteristic morphology for *S. polyps*[45]. The huge polyps are commonly mistaken as malignant polyps (Figure 1B) and in such cases diagnosis is achieved through histopathology either by biopsy or after excision[19,21,22].

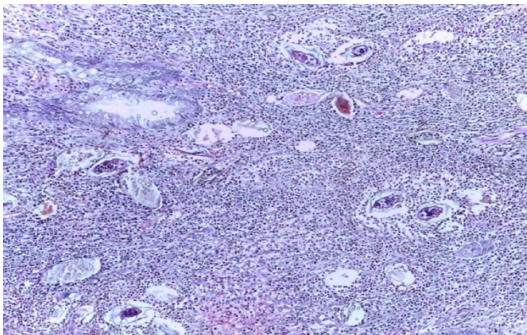
DIAGNOSIS

Diagnosis of polyps of the Schistosomal origin is sometimes challenging. There are no peculiar endoscopic morphologic features of *S. polyps* in comparison to other types of polyps and high index of suspicion is required especially in endemic areas. However, most cases are diagnosed either through endoscopic biopsy from the polyps or retrograde upon histopathology examination of removed polyps where the characteristic eosinophilic granulomas with the pathogenomic ova (Figure 2) of the parasite are seen [12-19,22] and infrequently the mature parasites may also be seen embedded within the background tissue of the excised polyps[22,29] or is seen lodged within thrombosed veins inside the polyp[5].



DOI: 10.3748/wjg.v29.i26.4156 Copyright ©The Author(s) 2023.

Figure 1 Schistosomal polyp. A: Small Schistosomal polyp located in the rectum. Note its dark red color with minute surface ulcerations; B: Surgical specimen of huge lobulated Schistosomal polyp morphologically and radiological confused with colo-rectal cancer; C: Schistosomal polyp with noticeable mucoid hyperplasia.



DOI: 10.3748/wjg.v29.i26.4156 Copyright ©The Author(s) 2023.

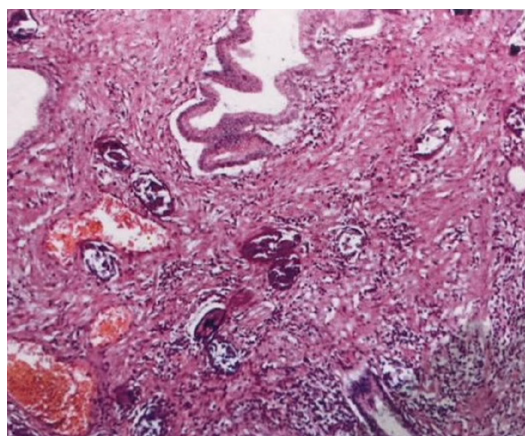
Figure 2 Active schistosomal granuloma; multiple schistosomal eggs in the submucosa surrounded by cellular infiltrate composed of eosinophils, lymphocytes, plasma cells and macrophages.

Linking the developed polyps, whatever its location, with active intestinal or urinary Schistosomiasis is not always achievable. In many cases described in the literature, identification of Bilharzial ova in fresh stool or urine samples taken from the same cases was not possible[9,16,31]. Furthermore, S. polyps may be the only clue of a Bilharzial infection[19,31].

Barium enema was used frequently to diagnose Bilharzial polyps of the bowel[46] in endemic areas before the era of endoscopy. However, currently the role of contrast study in diagnosis of intestinal or urinary Schistosomiasis is not likely to replace the standard methods for direct ova detection in stool or urine samples or detection of the ova with its characteristic granuloma on endoscopic or surgical specimens due to low sensitivity and specificity of these contrast studies[47].

Upon histologic examination, the polyp had a stalk of fibrous connective tissue that project from the submucosa into the lumen and is covered with mucosa. The overlying mucosa harbor distorted glands showing variable degrees of mucoid activity (Figure 1C), mucinous degeneration, and adenomatous hyperplasia. The covering mucosa frequently had focal areas of ulceration. Larger areas of ulceration may be replaced by granulation tissue. Mononuclear cells, eosinophils, and few polymorphonuclear leucocytes infiltrate the mucosa[48].

The peculiar granuloma had a centrally located ova (viable and/or nonviable) surrounded by cellular infiltrate characteristically with eosinophils, mononuclear cells and multinucleated histiocytes (Figure 2)[1,5], chronic granulomas are surrounded by fibroblasts (Figure 3). The supporting tissue is composed of fibrous connective tissue and muscle derived from the muscularis mucosa. Blood vessels may be present in large numbers but diminish with progression of fibrosis [48].



DOI: 10.3748/wjg.v29.i26.4156 Copyright ©The Author(s) 2023.

Figure 3 Schistosomal granuloma infiltrated by fibroblasts with dense submucosal fibrosis.

TREATMENT

Medical treatment

Currently, PZQ is the recommended first-line medical therapy for Schistosomiasis. The drug is active and effective in treatment of all Schistosome species with no reports of resistance[49]. Small-sized polyps can be cured with PZQ therapy alone. The dose is 40-60 mg/kg, it is given as a single dose after a meal[1] and can be divided over one day[3,9], and can be repeated[7]. The side effects associated with PZQ are usually mild and include nausea, vomiting, abdominal cramps and allergic reactions. S. polyps are exceptional types of polyps that can regress with medical treatment[11] especially when they are small and are not associated with manifestations necessitating excision. All cases associated with large or ectopic polyps after being excised either endoscopically or surgically were followed by treatment with PZQ irrespective of the patients' active intestinal or urinary Schistosomiasis state[9,13,19,34].

Endoscopic treatment

Large polyps are indicated for excision. Endoscopic excision for S. polyps have been reported thoroughly in the literature as early as the 80s of the last century[50,51] with the early time of endoscopy. S. polyps were excised with different techniques including cold snare for small polyps, standard direct hot polypectomy for larger polyps whatever the site is the duodenum[9], or the colon[3]. Hot polypectomy after application of endoloop[52], or clips[13] has been associated with good outcomes. While advanced endoscopic resection techniques including endoscopic mucosal resection[21,22] and endoscopic submucosal dissection[53] were also used for endoscopic removal of large S. polyps. All endoscopic resection techniques were used with accepted safety profile. The adverse events reported were not different from those reported with other types of polyps[3,9,13,16,22]. Resection of S. polyps combined with medical treatment using PZQ was successful [3,9,13,16,22,48]. Endoscopic resection of urinary S. polyps is less frequently performed in comparison to bowel and was associated with acceptable success rates[24].

Surgical treatment

Surgical excision is not the standard of care in treatment of S. polyps. However, surgery is usually the ultimate solution for challenging situations including cases presented with bowel obstruction[14,33], or when the lesion is morphologically or radiologically suspected to be malignant[7,12,19] and also for lesions in ectopic areas including the anus[5], cervix[30] and the external genitalia[27,28]. Atypical sites of S. polyps may require special surgical approaches, *e.g.*, in the larynx, the surgical microscope is essential to excise the polyp[36], while in other situations, *e.g.*, gallbladder, the organ is excised with the polyp en bloc[34]. All cases managed by surgery, similar to endoscopic management, should be followed by PZQ therapy.

Outcomes of treatment

The outcome of S. polyps achieved by the above mentioned treatments depend on many factors. First, the number of lesions detected. For single lesions excision (either endoscopic or surgical) is usually curative, while multiple lesions may require more rounds of excision[3]. Second, patients' residency; patients residing in endemic areas are susceptible to re-infection and hence should follow the general preventive measures together with PZQ therapy that sometimes given as chemoprophylaxis or as mass treatment campaigns even without testing for the presence of the parasite[54], while patients out of the endemic areas a single course of PZQ is usually sufficient for treatment. Third, the location of the polyps, some polyps are accessible for endoscopic treatment, such as polyps in the colon, and urinary bladder, while other lesions, *e.g.*, gallbladder are not. Last, presentation of the lesions, such as lesions presented with acute manifestations including bowel obstruction, surgery usually the corner stone of treatment and in such cases diagnosis is often achieved retrograde[14,33].

CONCLUSION

Schistosomiasis is a neglected tropical disease and its prevalence is no more limited to endemic areas. *S. polyps* are not infrequent presentation of acute or chronic Schistosomal infection. *S. polyps* are described in many organs including the bowel, genitourinary tract, skin, gallbladder and the larynx. Presentation of *S. polyps* is variable and depends on the site, number as well as the polyp size. The relationship of *S. polyps* to malignant transformation is a matter of discussion. Small polyps can be treated medically with PZQ, while large accessible polyps are amendable for endoscopic excision through different polyp resection techniques. However, huge, complicated and suspicious polyps are indicated for surgical management or advanced endoscopic resection if appropriate. Clinicians and endoscopists should be aware about these facts when treating patients living in, immigrated from or visiting endemic areas.

FOOTNOTES

Author contributions: Emara MH, Mahros AM, Radwan MI, and Rasheda AMA developed concept of the study, and retrieved the evidence; Elbatae H, Emara MH, Abdelrazik O, and Elazab M searched the literature; Elbatae H, Emara MH, Abdelrazik O, Elazab M, Mahros AM, and Radwan MI analyzed the evidence; Emara MH, Rasheda AMA, Elazab M, and Mahros AM drafted the article; All authors revised the article.

Conflict-of-interest statement: All the authors report no relevant conflicts of interest for this article.

Open-Access: This article is an open-access article that was selected by an in-house editor and fully peer-reviewed by external reviewers. It is distributed in accordance with the Creative Commons Attribution NonCommercial (CC BY-NC 4.0) license, which permits others to distribute, remix, adapt, build upon this work non-commercially, and license their derivative works on different terms, provided the original work is properly cited and the use is non-commercial. See: <https://creativecommons.org/licenses/by-nc/4.0/>

Country/Territory of origin: Egypt

ORCID number: Mohamed H Emara 0000-0002-1504-7851; Aya M Mahros 0000-0002-6849-4065; Hassan Elbatae 0000-0001-7804-8424.

Corresponding Author's Membership in Professional Societies: Egyptian Association for Research and Training in Hepatogastroenterology.

S-Editor: Fan JR

L-Editor: Ma JY

P-Editor: Zhang XD

REFERENCES

- 1 Elbaz T, Esmat G. Hepatic and intestinal schistosomiasis: review. *J Adv Res* 2013; **4**: 445-452 [PMID: 25685451 DOI: 10.1016/j.jare.2012.12.001]
- 2 Hams E, Aviello G, Fallon PG. The schistosoma granuloma: friend or foe? *Front Immunol* 2013; **4**: 89 [PMID: 23596444 DOI: 10.3389/fimmu.2013.00089]
- 3 Abd El-Latif N, Bedewy E. Bilharzial Colonic Polyps: Case Presentation. *Afro-Egyptian J Infect Endemic Dis* 2020; **10**: 233-236 [DOI: 10.21608/aeji.2020.29738.1079]
- 4 Barsoum RS. Urinary schistosomiasis: review. *J Adv Res* 2013; **4**: 453-459 [PMID: 25685452 DOI: 10.1016/j.jare.2012.08.004]
- 5 Raso P, Sander EM, Raso LA, Andrade Filho Jde S. Anal polyp caused by *Schistosoma mansoni*. *Rev Soc Bras Med Trop* 2013; **46**: 252-254 [PMID: 23740071 DOI: 10.1590/0037-8682-1681-2013]
- 6 Mostafa I. Schistosomal colonic polyposis. *Gastrointest Endosc* 1997; **46**: 584-587 [PMID: 9434242]
- 7 Alyhari Q, Ahmed F, Al Shaibani H, Al Kubati M, Alhadi A. Huge Colonic Granuloma of Schistosomiasis Mimicked Cancer in a 10-Years-Old Child: A Case Report. *Int Med Case Rep J* 2022; **15**: 379-384 [PMID: 35903496 DOI: 10.2147/IMCRJ.S372186]
- 8 Cao J, Liu WJ, Xu XY, Zou XP. Endoscopic findings and clinicopathologic characteristics of colonic schistosomiasis: a report of 46 cases. *World J Gastroenterol* 2010; **16**: 723-727 [PMID: 20135720 DOI: 10.3748/wjg.v16.i6.723]
- 9 Gonzalez A, Gupta K, Rodriguez S, Wadhwa V, Bejarano P, Charles R. Unique Case of a Hamartomatous Duodenal Polyp Associated With Intestinal Schistosomiasis. *ACG Case Rep J* 2021; **8**: e00485 [PMID: 33532510 DOI: 10.14309/crj.0000000000000485]
- 10 Pesce JT, Ramalingam TR, Mentink-Kane MM, Wilson MS, El Kasbi KC, Smith AM, Thompson RW, Cheever AW, Murray PJ, Wynn TA. Arginase-1-expressing macrophages suppress Th2 cytokine-driven inflammation and fibrosis. *PLoS Pathog* 2009; **5**: e1000371 [PMID: 19360123 DOI: 10.1371/journal.ppat.1000371]
- 11 Nebel OT, el-Masry NA, Castell DO, Farid Z, Fornes MF, Sparks HA. Schistosomal disease of the colon: a reversible form of polyposis. *Gastroenterology* 1974; **67**: 939-943 [PMID: 4426495]
- 12 Ahmed MH, Emara MH, Elfert AA, El-Saka AM, Abd-Elsalam S, Yousef M. Persistent Colonic Schistosomiasis among Symptomatic Rural Inhabitants in the Egyptian Nile Delta. *Mediterr J Hematol Infect Dis* 2021; **13**: e2021033 [PMID: 34007421 DOI: 10.4084/MJHID.2021.033]
- 13 Orare K, Mohamed A, Thakkar M, Rajula A, Gatheru J. Colonic polyps: a rare clinical manifestation of schistosomiasis (a case report). *Pan Afr Med J* 2022; **42**: 187 [PMID: 36212935 DOI: 10.11604/pamj.2022.42.187.34227]
- 14 Lamyman MJ, Noble DJ, Narang S, Dehalvi N. Small bowel obstruction secondary to intestinal schistosomiasis. *Trans R Soc Trop Med Hyg* 2006; **100**: 885-887 [PMID: 16443245 DOI: 10.1016/j.trstmh.2005.10.013]

- 15 **Zhu XL**, Song JZ, Yu WY, Hua LQ, Zhang ML. Intestinal schistosomiasis masquerading as intestinal polyps. *BMC Infect Dis* 2021; **21**: 434 [PMID: 33964884 DOI: 10.1186/s12879-021-06125-4]
- 16 **Issa I**, Osman M, Aftimos G. Schistosomiasis manifesting as a colon polyp: a case report. *J Med Case Rep* 2014; **8**: 331 [PMID: 25296942 DOI: 10.1186/1752-1947-8-331]
- 17 **Lin CT**, Chen CY, Jao SW, Wu CC. An unusual pedunculated polyp of the transverse colon associated with schistosomiasis. *Endoscopy* 2010; **42** Suppl 2: E160 [PMID: 20556713 DOI: 10.1055/s-0029-1244142]
- 18 **Bosire F**, Orwa I, Mwachiro M, Parker R, Whit R. Schistosoma Mansonii Proctocolitis with Polyposis. *Ann African Surg* 2018; **15**: 81-85
- 19 **Elbatee HE**, Emara MH, Zaghloul MS, Ahmed MH, Radwan MI, Seif AS, Elmoghazy MB, Elkashef WF. Huge bilharzial polyp mimicking colon cancer. *JGH Open* 2020; **4**: 280-283 [PMID: 32280778 DOI: 10.1002/jgh3.12181]
- 20 **Emara MH**, Ahmed MH, Mahros AM, Amer IF, Elkerdawy MA. No part of the colon is immune from large Bilharzial polyps. *Eur J Gastroenterol Hepatol* 2020; **32**: 896-897 [PMID: 32472818 DOI: 10.1097/MEG.0000000000001727]
- 21 **Farooq A**, Hussain A, Singh C, Kadkhodayan K, Arain M, Hasan MK, Yang D. Large Colon Polyp as the Only Manifestation of Chronic Schistosomiasis Infection. *ACG Case Rep J* 2022; **9**: e00889 [PMID: 36237280 DOI: 10.14309/crj.0000000000000889]
- 22 **Al-Zubaidi AM**, Bashanfer GA, Alqannas MH, Al Atawi AS. Colonic Polyps an Unusual Manifestation of Schistosomiasis. *Am J Case Rep* 2020; **21**: e923177 [PMID: 32764533 DOI: 10.12659/AJCR.923177]
- 23 **Smith JH**, Torky H, Kelada AS, Farid Z. Schistosomal polyposis of the urinary bladder. *Am J Trop Med Hyg* 1977; **26**: 85-88 [PMID: 842788 DOI: 10.4269/ajtmh.1977.26.85]
- 24 **Dessyn JF**, Duquenne S, Hoarau G. Incidental pseudolymphomatous bladder inflammatory polyp revealing urinary schistosomiasis. *Int J Infect Dis* 2016; **53**: 39-40 [PMID: 27810520 DOI: 10.1016/j.ijid.2016.10.022]
- 25 **Saad SM**, Hanafy HM. Bilharzial (schistosomal) polypi of ureter. *Urology* 1974; **4**: 85-89 [PMID: 21322991 DOI: 10.1016/0090-4295(74)90114-9]
- 26 **Gilges W**. Skin polyp-only symptom of bilharzia infection. *East Afr Med J* 1951; **28**: 288 [PMID: 14872783]
- 27 **Dioussé P**, Dione H, Bammo M, Dial C, Thiam M, Diamé AA, Diop BM, Ka MM. Vulvar bilharzia on nine-year old girl: A case report. *Int J Case Rep Images* 2016; **7**: 724-728
- 28 **Sahabi MS**, Rabiou FA. Unusual presentation of schistosomiasis as vulvar polyp. *Obs Gyne Review: J Obstet Gynecol* 2017; **3**: 33-37 [DOI: 10.17511/joog.2017.i04.01]
- 29 **File S**, Francheschini AB, Fernandez-Santiago A. Short report: A case of ectopic schistosomiasis in Puerto Rico with some observations on the biology of the parasite. *Am J Trop Med Hyg* 1998; **58**: 671-672 [PMID: 9598459 DOI: 10.4269/ajtmh.1998.58.671]
- 30 **Eladi AE**, Shebl AM, Elkashef WF, Zalata KR. Bilharzial endocervical polyp. *Indian J Pathol Microbiol* 2012; **55**: 377-378 [PMID: 23032837 DOI: 10.4103/0377-4929.101750]
- 31 **Altonbary A**, Bahgat M, Elkashef W. Bilharzial granuloma of the duodenum. *OA Case Rep* 2014; **3**: 62
- 32 **Thatcher BS**, Fleischer D, Rankin GB, Petras R. Duodenal schistosomiasis diagnosed by endoscopic biopsy of an isolated polyp. *Am J Gastroenterol* 1984; **79**: 927-929 [PMID: 6507419]
- 33 **Gul R**, Khalid K, Al-Rajhi MF, Bismar HA. Acute small bowel obstruction due to bilharziasis. *Saudi Med J* 2005; **26**: 1624-1626 [PMID: 16228068]
- 34 **Ali GA**, Goravey W, Al-Bozom I, Al Maslamani MA, Abdel Hadi H. Schistosoma gallbladder polyp masquerading as a neoplasm: Rare case report and literature review. *Clin Case Rep* 2021; **9**: e04420 [PMID: 34267906 DOI: 10.1002/ccr3.4420]
- 35 **Ghimire PG**, Ghimire P. Gallbladder schistosomiasis - a rare presentation as gallbladder polyp: a case report. *Radiol Case Rep* 2020; **15**: 1394-1397 [PMID: 32636981 DOI: 10.1016/j.radcr.2020.06.013]
- 36 **Toppozada HH**. Laryngeal bilharzia. *J Laryngol Otol* 1985; **99**: 1039-1041 [PMID: 4056583 DOI: 10.1017/s0022215100098145]
- 37 **Hamid HKS**. Schistosoma japonicum-Associated Colorectal Cancer: A Review. *Am J Trop Med Hyg* 2019; **100**: 501-505 [PMID: 30560774 DOI: 10.4269/ajtmh.18-0807]
- 38 **H Salim OE**, Hamid HK, Mekki SO, Suleiman SH, Ibrahim SZ. Colorectal carcinoma associated with schistosomiasis: a possible causal relationship. *World J Surg Oncol* 2010; **8**: 68 [PMID: 20704754 DOI: 10.1186/1477-7819-8-68]
- 39 **Abdulla H**, Khalil RY, Ibrahim MS, Elais N, Abdulaziz A. The relationship between colonic Bilharzial polyposis and colorectal cancer, Sci. Med J ESCME 1996; **8**: 129-140
- 40 **Herman AM**, Kishe A, Babu H, Shilanaiman H, Tarmohamed M, Lodhia J, Amsi P, Pyuza J, Mremi A, Mwasamwaja A, Nyindo M, Chilonga K, Msuya D. Colorectal cancer in a patient with intestinal schistosomiasis: a case report from Kilimanjaro Christian Medical Center Northern Zone Tanzania. *World J Surg Oncol* 2017; **15**: 146 [PMID: 28768520 DOI: 10.1186/s12957-017-1217-1]
- 41 **von Bülow V**, Lichtenberger J, Grevelding CG, Falcone FH, Roeb E, Roderfeld M. Does Schistosoma Mansonii Facilitate Carcinogenesis? *Cells* 2021; **10** [PMID: 34440754 DOI: 10.3390/cells10081982]
- 42 **Burky M**, Trembath D, Bookhout C. Rectal carcinoma arising in a patient with intestinal and hepatic schistosomiasis due to Schistosoma mekongi. *IDCases* 2022; **27**: e01383 [PMID: 35036322 DOI: 10.1016/j.idcr.2022.e01383]
- 43 **Mostafa MH**, Sheweita SA, O'Connor PJ. Relationship between schistosomiasis and bladder cancer. *Clin Microbiol Rev* 1999; **12**: 97-111 [PMID: 9880476 DOI: 10.1128/CMR.12.1.97]
- 44 **Ishida K**, Hsieh MH. Understanding Urogenital Schistosomiasis-Related Bladder Cancer: An Update. *Front Med (Lausanne)* 2018; **5**: 223 [PMID: 30159314 DOI: 10.3389/fmed.2018.00223]
- 45 **Ye C**, Tan S, Jiang L, Li M, Sun P, Shen L, Luo H. Endoscopic characteristics and causes of misdiagnosis of intestinal schistosomiasis. *Mol Med Rep* 2013; **8**: 1089-1093 [PMID: 23969514 DOI: 10.3892/mmr.2013.1648]
- 46 **El-Masry NA**, Farid Z, Kilpatrick ME, Watten RH. Role of the barium enema in schistosomal colonic polyposis. *East Afr Med J* 1982; **59**: 465-468 [PMID: 7160324]
- 47 **Shebel HM**, Elsayes KM, Abou El Atta HM, Elguindy YM, El-Diasty TA. Genitourinary schistosomiasis: life cycle and radiologic-pathologic findings. *Radiographics* 2012; **32**: 1031-1046 [PMID: 22786992 DOI: 10.1148/rg.324115162]
- 48 **Mostafa IM**, Zakaria S, Khalil A, El-Kaluoby A. The effect of medical treatment and endoscopic polypectomy on clinicopathological, immunological and endoscopic aspects of schistosomal colonic polyposis in Egypt. In: Proceedings of the world congresses of gastroenterology 1990. Australia: Sydney; 1990: 1260
- 49 **Vale N**, Gouveia MJ, Rinaldi G, Brindley PJ, Gärtner F, Correia da Costa JM. Praziquantel for Schistosomiasis: Single-Drug Metabolism Revisited, Mode of Action, and Resistance. *Antimicrob Agents Chemother* 2017; **61** [PMID: 28264841 DOI: 10.1128/AAC.02582-16]

- 50 **Thakeb F**, El-Kalouby AH, Ibrahim IM, Hunter S, Zakaria S. Colonoscopic polypectomy in management of schistosomal colonic polyposis. *Egypt J Bilh* 1980; **7**: 49-56
- 51 **Bessa SM**, Helmy I, El-Kharadly Y. Colorectal schistosomiasis. Endoscopic polypectomy. *Dis Colon Rectum* 1983; **26**: 772-774 [PMID: 6641458 DOI: [10.1007/BF02554745](https://doi.org/10.1007/BF02554745)]
- 52 **Ahmed S**, Babiker F, Elshafie A, Alhedaithy M, Yousif OE, Toulaymat M. Unusual Presentations of Intestinal Schistosomiasis. *Dr. Sulaiman Al Habib Med J* 2020; **2**: 33-37
- 53 **Probst A**, Schaller T, Ebigbo A, Messmann H. Colonic schistosomiasis and early rectal cancer: coincidence or causal relationship? *Endoscopy* 2014; **46** Suppl 1: E671 [PMID: 25526419 DOI: [10.1055/s-0034-1390863](https://doi.org/10.1055/s-0034-1390863)]
- 54 **Kabuyaya M**, Chimbari MJ, Mukaratirwa S. Efficacy of praziquantel treatment regimens in pre-school and school aged children infected with schistosomiasis in sub-Saharan Africa: a systematic review. *Infect Dis Poverty* 2018; **7**: 73 [PMID: 29986763 DOI: [10.1186/s40249-018-0448-x](https://doi.org/10.1186/s40249-018-0448-x)]



Published by **Baishideng Publishing Group Inc**
7041 Koll Center Parkway, Suite 160, Pleasanton, CA 94566, USA

Telephone: +1-925-3991568

E-mail: bpgoffice@wjgnet.com

Help Desk: <https://www.f6publishing.com/helpdesk>

<https://www.wjgnet.com>

