

# World Journal of *Otorhinolaryngology*

*World J Otorhinolaryngol* 2023 May 9; 10(2): 4-35



**REVIEW**

- 4 Post-COVID-19 persistent olfactory, gustatory, and trigeminal chemosensory disorders: Definitions, mechanisms, and potential treatments

*Hamed SA*

**CASE REPORT**

- 23 Transoral robotic surgery for adult parapharyngeal lymphangioma: A case report

*Dabas S, Menon NN, Ranjan R, Gurung B, Shukla H, Sharma AK, Tiwari S, Sinha A, Bhatti SS, Sangal R*

- 30 Wet cupping (Al-hijamah) as a strange cause of ear trauma: A case report

*Al-Ani RM*

**ABOUT COVER**

Peer Reviewer of *World Journal of Otorhinolaryngology*, Kádima N Teixeira, PhD, Professor, Campus Toledo, Universidade Federal do Paraná, 3796 Max Planck Av, 85919-899, Toledo, PR Brazil. [kadimateixeira@ufpr.br](mailto:kadimateixeira@ufpr.br)

**AIMS AND SCOPE**

The primary aim of *World Journal of Otorhinolaryngology* (WJO, *World J Otorhinolaryngol*) is to provide scholars and readers from various fields of otorhinolaryngology with a platform to publish high-quality basic and clinical research articles and communicate their research findings online.

WJO mainly publishes articles reporting research results and findings obtained in the field of otorhinolaryngology and covering a wide range of topics including adenoidectomy, audiology, auditory brain stem implantation, ciliary motility disorders, cochlear implantation, ear diseases, endolymphatic shunt, fenestration, labyrinth, laryngeal diseases, laryngectomy, laryngoplasty, laryngoscopy, middle ear ventilation, myringoplasty, nasal surgical procedures, neck dissection, nose diseases, ossicular replacement, otologic surgical procedures, otorhinolaryngologic diseases, otorhinolaryngologic neoplasms, otorhinolaryngologic surgical procedures, pharyngeal diseases, pharyngectomy, pharyngostomy, rhinoplasty, stapes surgery, tonsillectomy, tracheostomy, transtympanic micropressure treatment, and tympanoplasty.

**INDEXING/ABSTRACTING**

The WJO is now abstracted and indexed in Reference Citation Analysis, China National Knowledge Infrastructure, China Science and Technology Journal Database, and Superstar Journals Database.

**RESPONSIBLE EDITORS FOR THIS ISSUE**

Production Editor: *Si Zhao*; Production Department Director: *Xu Guo*; Editorial Office Director: *Yun-jie Ma*.

**NAME OF JOURNAL**

*World Journal of Otorhinolaryngology*

**ISSN**

ISSN 2218-6247 (online)

**LAUNCH DATE**

December 28, 2011

**FREQUENCY**

Continuous Publication

**EDITORS-IN-CHIEF**

Amr El-Shazly

**EDITORIAL BOARD MEMBERS**

<https://www.wjnet.com/2218-6247/editorialboard.htm>

**PUBLICATION DATE**

May 9, 2023

**COPYRIGHT**

© 2023 Baishideng Publishing Group Inc

**INSTRUCTIONS TO AUTHORS**

<https://www.wjnet.com/bpg/gerinfo/204>

**GUIDELINES FOR ETHICS DOCUMENTS**

<https://www.wjnet.com/bpg/GerInfo/287>

**GUIDELINES FOR NON-NATIVE SPEAKERS OF ENGLISH**

<https://www.wjnet.com/bpg/gerinfo/240>

**PUBLICATION ETHICS**

<https://www.wjnet.com/bpg/GerInfo/288>

**PUBLICATION MISCONDUCT**

<https://www.wjnet.com/bpg/gerinfo/208>

**ARTICLE PROCESSING CHARGE**

<https://www.wjnet.com/bpg/gerinfo/242>

**STEPS FOR SUBMITTING MANUSCRIPTS**

<https://www.wjnet.com/bpg/GerInfo/239>

**ONLINE SUBMISSION**

<https://www.f6publishing.com>

## Wet cupping (Al-hijamah) as a strange cause of ear trauma: A case report

Raid M Al-Ani

### Specialty type:

Otorhinolaryngology

### Provenance and peer review:

Unsolicited article; Externally peer reviewed.

### Peer-review model:

Single blind

### Peer-review report's scientific quality classification

Grade A (Excellent): 0  
Grade B (Very good): B  
Grade C (Good): C, C, C  
Grade D (Fair): 0  
Grade E (Poor): 0

**P-Reviewer:** Mahmoud MZ, Saudi Arabia; Mirsalehi M, Iran

**Received:** December 31, 2022

**Peer-review started:** December 31, 2022

**First decision:** April 13, 2023

**Revised:** April 14, 2023

**Accepted:** April 27, 2023

**Article in press:** April 27, 2023

**Published online:** May 9, 2023



**Raid M Al-Ani**, Department of Surgery/Otolaryngology, University of Anbar College of Medicine, Ramadi City 31001, Anbar, Iraq

**Corresponding author:** Raid M Al-Ani, MBChB, Academic Editor, Consultant Physician-Scientist, Full Professor, Researcher, Science Editor, Department of Surgery/Otolaryngology, University of Anbar College of Medicine, Al-Andulus, Ramadi City 31001, Anbar, Iraq.  
[med.raed.alani2003@uoanbar.edu.iq](mailto:med.raed.alani2003@uoanbar.edu.iq)

### Abstract

#### BACKGROUND

Cupping therapy is used across the globe since ancient Egypt. It is used as a complementary or alternative to daily clinical practice. Cupping therapy could be dry or wet (Al-hijamah) type. It is considered a relatively safe procedure for a variety of clinical problems like lower backache, shoulder pain, neck pain, headache, and migraine. Application of cupping therapy over body orifices is contraindicated.

#### CASE SUMMARY

A 27-year-old gentleman presented with sudden left-sided hearing loss and tinnitus for 7 d. He gave a history of upper respiratory tract infection 14 d before his complaints. He received Al-hijamah over his left ear 3 d before seeking advice from the Otolaryngology clinic, but without benefit. Physical examination showed a dull-looking left ear drum, hemotympanum in the posterior part of the tympanic cavity, two blood clots over the eardrum, and multiple bleeding points over the external ear canal and tympanic membrane. A pure tone audiogram and tympanogram confirmed the diagnosis of middle ear effusion. Conservative treatment (avoidance of water entry, antibiotics, and local and systemic decongestants) was given for 5 d. The presenting symptoms as well as ear injuries resolved completely two weeks after the follow-up.

#### CONCLUSION

We do not recommend using Al-hijamah directly over the ear as a treatment option for hearing loss to avoid unwanted ear trauma as well as there is no benefit from this kind of treatment.

**Key Words:** Al-hijamah; Ear trauma; Hemotympanum; Secretary otitis media; Cupping therapy; Hearing loss; Case report

**Core Tip:** Al-hijamah is a useful treatment for a variety of local and systemic diseases. However, Al-hijamah is contraindicated over the body orifices. A 27-year-old gentleman presented with left-sided hearing loss and tinnitus was treated with a Al-hijamah over the left ear. The patient condition persist as well as there were signs of bleeding (fresh blood, clots, and hemotympanum). Secretary otitis media following upper respiratory tract infection was established on clinical background and audiological tests. He was treated successfully by avoidance of water entry, antibiotics, and decongestant. We don't recommend the usage of Al-hijamah over the ear to treat hearing loss.

**Citation:** Al-Ani RM. Wet cupping (Al-hijamah) as a strange cause of ear trauma: A case report. *World J Otorhinolaryngol* 2023; 10(2): 30-35

**URL:** <https://www.wjgnet.com/2218-6247/full/v10/i2/30.htm>

**DOI:** <https://dx.doi.org/10.5319/wjo.v10.i2.30>

## INTRODUCTION

Wet cupping or Al-hijamah is an old traditional therapeutic procedure that is performed in many countries and referred to as the Unani part of medicine. The procedure involves bloodletting from acupoints on a subject's skin to achieve a satisfactory result[1]. Cupping therapy has many indications, both for local (lower back pain, neck and shoulder pain, and headache) and systemic diseases like diabetes mellitus[2]. Cupping therapy should be avoided in patients with organ failure, cancer, cardiovascular diseases, increased risk of cardiovascular disorders (like high serum cholesterol level), hemophilia or other similar blood disorders, and pacemaker. It should not be applied directly over veins, arteries, nerves, skin abnormalities, eyes, body orifices, lymph nodes, and dermatological inflammation[3].

Cupping therapy, like any kind of treatment modality, has adverse effects, especially in the hands of unqualified therapists[4,5]. A recent study reported a beneficial effect of wet cupping therapy as a complementary to steroids in the treatment of a 48-year-old woman with sudden sensorineural hearing loss[6]. However, there is no other study that investigated the use of cupping therapy in the treatment of hearing loss. We reported a 27-year-old male presented with left-sided conductive hearing loss who was treated (by an inexperienced) by the application of an Al-hijamah cup directly over the left ear. Unfortunately, this treatment modality was not useful in resolving the patient condition and resulted in a trauma to the external and middle ears.

## CASE PRESENTATION

### Chief complaints

Left-sided hearing loss and tinnitus.

### History of present illness

A 27-year-old gentleman presented with sudden onset left-sided hearing loss and subjective tinnitus 7 d ago. He gave a history of upper respiratory tract infection 2 wk before his complaints. He was subjected to Al-hijamah directly over the left ear by a therapist to get rid of his presenting features. In addition to the bleeding from the affected ear following Al-hijamah, his clinical symptoms persist. There was no bruising over the affected auricle or postauricular region. The patient denied any history of otorrhea or vertigo.

### History of past illness

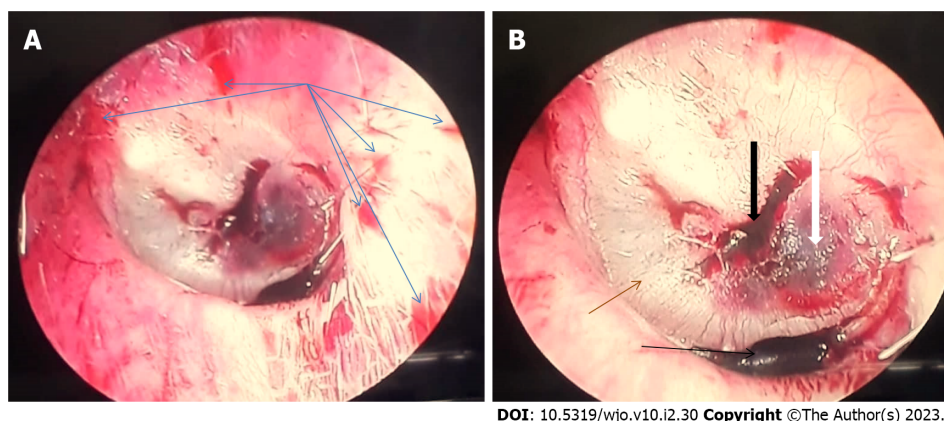
The patient was healthy with no history of chronic medical diseases.

### Personal and family history

The patient had no specific personal or family history.

### Physical examination

The patient visited an Otolaryngology clinic. Otoendoscopy revealed several bleeding points covering the left external ear canal, two blood clots, dull looking eardrum, an absent cone of light, and hemotympanum in the posterior part of the left tympanic cavity (Figure 1).



**Figure 1** Shows multiple bleeding points (blue arrows) over the left external ear canal, two blood clots over the eardrum (black arrows), hemotympanum in the posterior part of the tympanic cavity (white arrow), absent cone of light, and dull-looking tympanic membrane (brown arrow). A: A little bit far away from the tympanic membrane; B: Closer to the eardrum.

The right ear was completely normal. Tuning fork tests revealed a negative Rinne test on the left side and a positive on the right side, while the Weber test was lateralized to the left ear. Nasal endoscopy revealed clear both nasal cavities and nasopharynx apart from the congestion of the left nasopharyngeal opening of the Eustachian tube.

### **Audiological tests**

Audiological tests in form of pure tone audiogram, which revealed conductive hearing loss in the left ear with an air-bone gap of 37 dB (Figure 2), and a tympanogram that showed a type B curve on the left ear and a type A curve on the right side (Figure 3).

## **FINAL DIAGNOSIS**

The diagnosis was left secretory otitis media superadded by ear trauma from the Al-hijamah procedure.

## **TREATMENT**

We advised the patient to avoid water entry to his left ear, antibiotic cover (amoxicillin 500 mg three times daily for 5 d), nasal decongestant drops (0.05% xylometazoline nasal drops 3 drops for each nostril three time daily for five days), and a combination of systemic decongestant and analgesia tablets (one tablet per day for five days).

## **OUTCOME AND FOLLOW-UP**

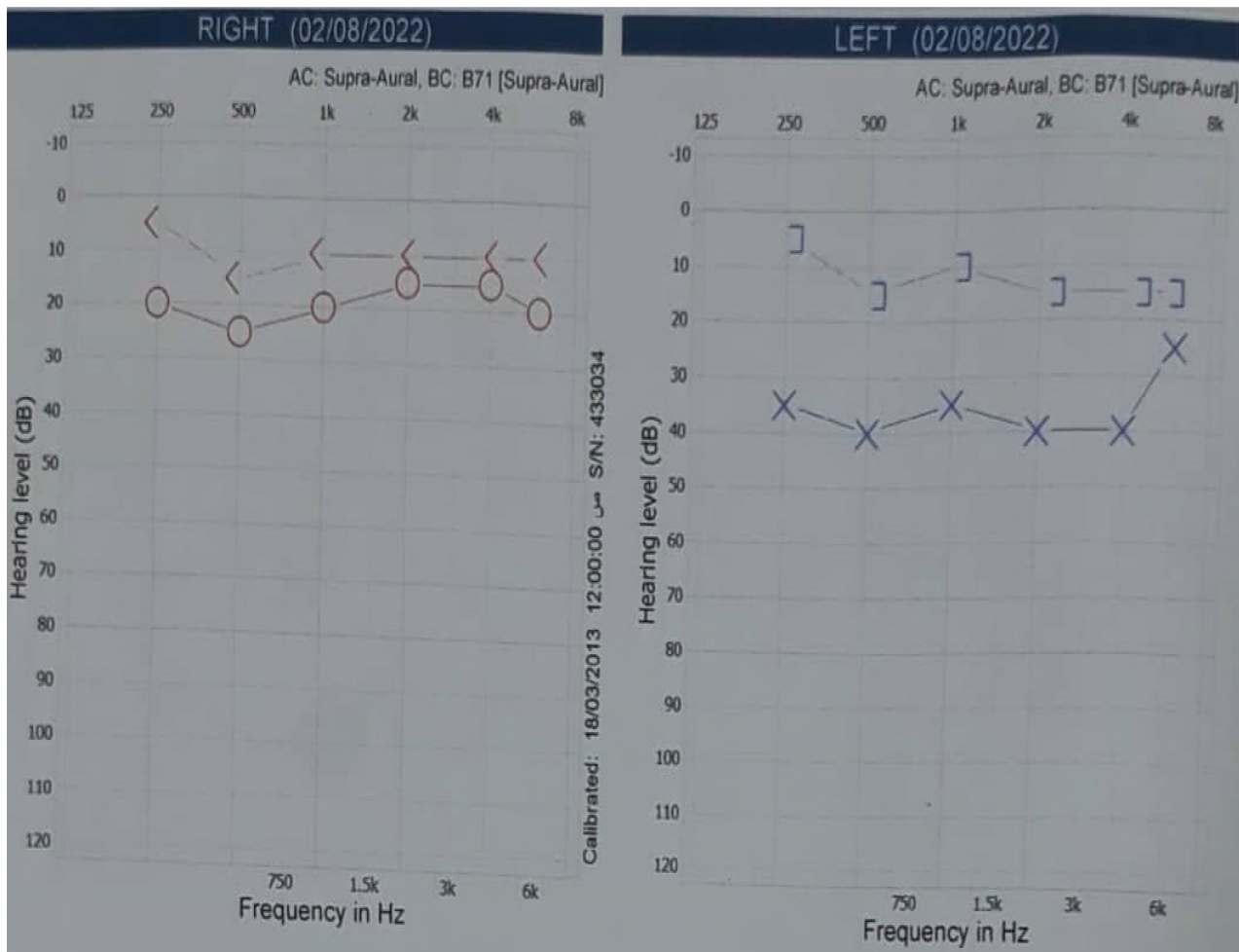
At two weeks follow-up, there was a full recovery of all the presenting symptoms, and the left ear canal and ear drum returned to normal.

## **DISCUSSION**

Cupping therapy is used as a complementary or alternative to the usual practice of medicine. It was practiced since ancient Egypt across the globe. It is useful for the management of a wide range of local or systemic clinical problems[7]. The exact therapeutic mechanism of action is not yet described even though an increasing number of investigations include a meta-analysis[8].

Cupping therapy is considered a safe procedure and is part of complementary and alternative medicine. However, frequent cupping treatment over a short period may result in generalized weakness, unsteadiness or drowsiness, and light headiness[9]. Other adverse effects might lead to bruising and skin discoloration, ecchymosis, bleeding, anemia, skin pigmentation, blisters, wound infection, and abscesses, particularly, if cupping therapy is performed by an unqualified or inexperienced person[4,5]. However, ear trauma due to Al-hijamah, as in our case, is not reported.





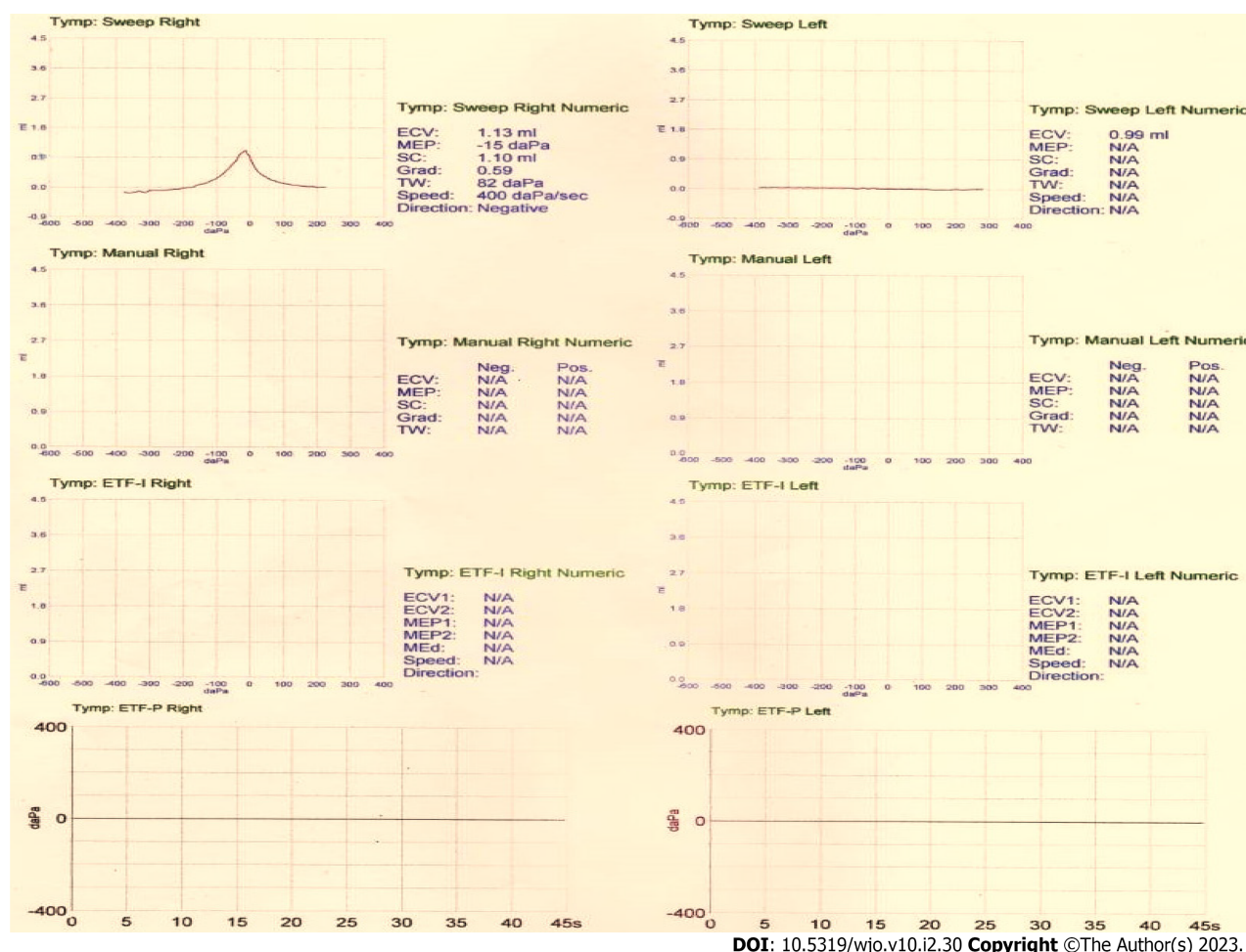
DOI: 10.5319/wjo.v10.i2.30 Copyright ©The Author(s) 2023.

**Figure 2** Pure tone audiogram of the 27-year-old man shows conductive hearing loss of 37 dB in the left ear. Hz: Hertz; dB: Decibel; Circle: Air conduction hearing threshold at a specific frequency of the right ear; X: Air conduction hearing threshold at a specific frequency of the left ear; <: Bone conduction hearing threshold at a specific frequency of the right ear with masking of the left ear; ]: Bone conduction hearing threshold at a specific frequency of the left ear.

Ear trauma usually occurs in young adult men owing to the high outdoor activities. It is usually caused during personal assaults, sports, or following personal accidents and road traffic accidents. Ear injury results in various clinical problems depending on the velocity and mechanism of the injury. These include; hematoma auris, lacerations or wounds, partial or complete avulsion of the auricle, hemotympanum, eardrum perforation, dislocation of the ossicles, Otic barotrauma, facial palsy, and inner ear injury[10]. Although, Al-hijamah is widely used in Iraq due to cultural and religious beliefs and resulted in the improvement of many conditions like diabetes mellitus, hypertension, and hyperlipidemia, treatment for hearing loss is not used before[11]. A recent case report study from Qatar reported that Al-hijamah is used for the treatment of sudden sensorineural hearing loss as a complementary treatment with steroids in a 48-year-old woman with satisfactory results[6]. To our best knowledge, there is no other study in the world that used cupping therapy as a treatment modality for hearing loss. Unfortunately, in the presenting case, cupping therapy was applied directly on the auricle resulting in hemotympanum and bleeding from the ear without improvement of the patient complaints (hearing loss and tinnitus). We do not recommend using Al-hijamah directly over the ear to avoid unwanted ear injuries as well as there is no benefit from its use. Furthermore, this study supports that cupping therapy is contraindicated over body orifices[3].

## CONCLUSION

The direct application of cupping therapy on the external meatus results in bleeding from the ear canal and haemotympanum as well as there was no improvement of the patients' hearing loss. Therefore, we do not recommend using Al-hijamah directly on the ear.



DOI: 10.5319/wjo.v10.i2.30 Copyright ©The Author(s) 2023.

**Figure 3** Tympanogram of the 27-year-old man shows type A on the right ear and type B (flat curve) on the left ear. The left external canal volume is 0.99 mL.

## FOOTNOTES

**Author contributions:** Al-Ani RM has the responsibility for the design of the study, writing the abstract, core tip, introduction, case presentation, discussion, conclusion, and references according to the journal style, and edited the draft and preparing the final version of the manuscript; Al-Ani RM revised and approved the final version of the manuscript.

**Informed consent statement:** Informed consent was obtained from the patient for publication of the case with its related images.

**Conflict-of-interest statement:** The author declares that there is no conflict of interest.

**CARE Checklist (2016) statement:** The author have read the CARE Checklist (2016), and the manuscript was prepared and revised according to the CARE Checklist (2016).

**Open-Access:** This article is an open-access article that was selected by an in-house editor and fully peer-reviewed by external reviewers. It is distributed in accordance with the Creative Commons Attribution NonCommercial (CC BY-NC 4.0) license, which permits others to distribute, remix, adapt, build upon this work non-commercially, and license their derivative works on different terms, provided the original work is properly cited and the use is non-commercial. See: <https://creativecommons.org/licenses/by-nc/4.0/>

**Country/Territory of origin:** Iraq

**ORCID number:** Raid M Al-Ani 0000-0003-4263-9630.

**S-Editor:** Fan JR

**L-Editor:** A

**P-Editor:** Zhao S



## REFERENCES

- 1 **Almaiman AA.** Proteomic effects of wet cupping (Al-hijamah). *Saudi Med J* 2018; **39**: 10-16 [PMID: [29332103](#) DOI: [10.15537/smj.2018.1.21212](#)]
- 2 **Aboushanab TS, AlSanad S.** Cupping Therapy: An Overview from a Modern Medicine Perspective. *J Acupunct Meridian Stud* 2018; **11**: 83-87 [PMID: [29436369](#) DOI: [10.1016/j.jams.2018.02.001](#)]
- 3 **Furhad S, Bokhari AA.** Cupping Therapy. 2023 Jan 2. In: StatPearls [Internet]. Treasure Island (FL): StatPearls Publishing; 2023 Jan- [PMID: [30855841](#)]
- 4 **Refaat B, El-Shemi AG, Ebid AA, Ashshi A, BaSalamah MA.** Islamic wet cupping and risk factors of cardiovascular diseases: effects on blood pressure, metabolic profile and serum electrolytes in healthy young adult men. *Altern Integ Med* 2014; **3**: 151 [DOI: [10.4172/2327-5162.1000151](#)]
- 5 **Vaccaro M, Coppola M, Ceccarelli M, Montopoli M, Guarneri C.** The good and the bad of cupping therapy: case report and review of the literature. *Eur Rev Med Pharmacol Sci* 2021; **25**: 2327-2330 [PMID: [33755970](#) DOI: [10.26355/eurev.202103.25266](#)]
- 6 **Almusleh ZA, El Ansari W.** Integrating Cupping Therapy in the Management of Sudden Sensorineural Hearing Loss: A Case Report. *Cureus* 2020; **12**: e7063 [PMID: [32226665](#) DOI: [10.7759/cureus.7063](#)]
- 7 **Choi TY, Ang L, Ku B, Jun JH, Lee MS.** Evidence Map of Cupping Therapy. *J Clin Med* 2021; **10** [PMID: [33920643](#) DOI: [10.3390/jcm10081750](#)]
- 8 **Al-Bedah AMN, Elsubai IS, Qureshi NA, Aboushanab TS, Ali GIM, El-Olemy AT, Khalil AAH, Khalil MKM, Alqaed MS.** The medical perspective of cupping therapy: Effects and mechanisms of action. *J Tradit Complement Med* 2019; **9**: 90-97 [PMID: [30963043](#) DOI: [10.1016/j.jtcme.2018.03.003](#)]
- 9 **Kim KH, Kim TH, Hwangbo M, Yang GY.** Anaemia and skin pigmentation after excessive cupping therapy by an unqualified therapist in Korea: a case report. *Acupunct Med* 2012; **30**: 227-228 [PMID: [22738805](#) DOI: [10.1136/acupmed-2012-010185](#)]
- 10 **Eagles K, Fralich L, Stevenson JH.** Ear trauma. *Clin Sports Med* 2013; **32**: 303-316 [PMID: [23522511](#) DOI: [10.1016/j.csm.2012.12.011](#)]
- 11 **Rahman HS, Ahmad GA, Mustapha B, Al-Rawi HA, Hussein RH, Amin K, Othman HH, Abdullah R.** Wet cupping therapy ameliorates pain in patients with hyperlipidemia, hypertension, and diabetes: A controlled clinical study. *Int J Surg Open* 2020; **26**: 10-15 [DOI: [10.1016/j.ijso.2020.07.003](#)]



Published by **Baishideng Publishing Group Inc**  
7041 Koll Center Parkway, Suite 160, Pleasanton, CA 94566, USA

**Telephone:** +1-925-3991568

**E-mail:** [bpgoffice@wjgnet.com](mailto:bpgoffice@wjgnet.com)

**Help Desk:** <https://www.f6publishing.com/helpdesk>

<https://www.wjgnet.com>

