

World Journal of *Gastrointestinal Endoscopy*

World J Gastrointest Endosc 2023 October 16; 15(10): 584-633



ORIGINAL ARTICLE

Basic Study

- 584 Magnetic anchor technique assisted endoscopic submucosal dissection for early esophageal cancer
Pan M, Zhang MM, Xu SQ, Lyu Y, Yan XP

Retrospective Cohort Study

- 593 Direct cost variance analysis of peroral endoscopic myotomy *vs* heller myotomy for management of achalasia: A tertiary referral center experience
Haider SA, Bills GS, Gyawali CP, Laoveeravat P, Miller J, Softic S, Wagh MS, Gabr M
- 602 Transoral outlet reduction: Outcomes of endoscopic Roux-en-Y gastric bypass revision in 284 patients at a community practice
Maselli DB, Chittajallu V, Wooley C, Waseem A, Lee D, Secic M, Donnangelo LL, Coan B, McGowan CE

Retrospective Study

- 614 Efficacy and safety of endoscopic retrograde cholangiopancreatography in recurrent pancreatitis of pediatric asparaginase-associated pancreatitis
Yang KH, Zeng JQ, Ding S, Zhang TA, Wang WY, Zhang JY, Wang L, Xiao J, Gong B, Deng ZH

CASE REPORT

- 623 Polyposis found on index colonoscopy in a 56-year-old female - *BMPR1A* variant in juvenile polyposis syndrome: A case report
Wu MY, Toon C, Field M, Wong M
- 629 Gallbladder plication as a rare complication of endoscopic sleeve gastropasty: A case report
Quiroz Guadarrama CD, Saenz Romero LA, Saucedo Moreno EM, Rojano Rodríguez ME

ABOUT COVER

Editorial Board Member of *World Journal of Gastrointestinal Endoscopy*, Mesut Akarsu, MD, Full Professor, Division of Gastroenterology, Department of Internal Medicine, Faculty of Medicine, Dokuz Eylul University, Izmir 35320, Turkey. mesut.akarsu@deu.edu.tr

AIMS AND SCOPE

The primary aim of *World Journal of Gastrointestinal Endoscopy* (WJGE, *World J Gastrointest Endosc*) is to provide scholars and readers from various fields of gastrointestinal endoscopy with a platform to publish high-quality basic and clinical research articles and communicate their research findings online.

WJGE mainly publishes articles reporting research results and findings obtained in the field of gastrointestinal endoscopy and covering a wide range of topics including capsule endoscopy, colonoscopy, double-balloon enteroscopy, duodenoscopy, endoscopic retrograde cholangiopancreatography, endosonography, esophagoscopy, gastrointestinal endoscopy, gastroscopy, laparoscopy, natural orifice endoscopic surgery, proctoscopy, and sigmoidoscopy.

INDEXING/ABSTRACTING

The WJGE is now abstracted and indexed in Emerging Sources Citation Index (Web of Science), PubMed, PubMed Central, Reference Citation Analysis, China National Knowledge Infrastructure, China Science and Technology Journal Database, and Superstar Journals Database. The 2023 Edition of Journal Citation Reports® cites the 2022 impact factor (IF) for WJGE as 2.0; IF without journal self cites: 1.9; 5-year IF: 3.3; Journal Citation Indicator: 0.28.

RESPONSIBLE EDITORS FOR THIS ISSUE

Production Editor: Yi-Xuan Cai; Production Department Director: Xu Guo; Editorial Office Director: Jia-Ping Yan.

NAME OF JOURNAL

World Journal of Gastrointestinal Endoscopy

ISSN

ISSN 1948-5190 (online)

LAUNCH DATE

October 15, 2009

FREQUENCY

Monthly

EDITORS-IN-CHIEF

Anastasios Koulaouzidis, Bing Hu, Sang Chul Lee, Joo Young Cho

EDITORIAL BOARD MEMBERS

<https://www.wjgnet.com/1948-5190/editorialboard.htm>

PUBLICATION DATE

October 16, 2023

COPYRIGHT

© 2023 Baishideng Publishing Group Inc

INSTRUCTIONS TO AUTHORS

<https://www.wjgnet.com/bpg/gerinfo/204>

GUIDELINES FOR ETHICS DOCUMENTS

<https://www.wjgnet.com/bpg/GerInfo/287>

GUIDELINES FOR NON-NATIVE SPEAKERS OF ENGLISH

<https://www.wjgnet.com/bpg/gerinfo/240>

PUBLICATION ETHICS

<https://www.wjgnet.com/bpg/GerInfo/288>

PUBLICATION MISCONDUCT

<https://www.wjgnet.com/bpg/gerinfo/208>

ARTICLE PROCESSING CHARGE

<https://www.wjgnet.com/bpg/gerinfo/242>

STEPS FOR SUBMITTING MANUSCRIPTS

<https://www.wjgnet.com/bpg/GerInfo/239>

ONLINE SUBMISSION

<https://www.f6publishing.com>



Polyposis found on index colonoscopy in a 56-year-old female - *BMPRI1A* variant in juvenile polyposis syndrome: A case report

Michael Yulong Wu, Christopher Toon, Michael Field, May Wong

Specialty type: Gastroenterology and hepatology

Provenance and peer review: Unsolicited article; Externally peer reviewed.

Peer-review model: Single blind

Peer-review report's scientific quality classification

Grade A (Excellent): 0
Grade B (Very good): B, B
Grade C (Good): C
Grade D (Fair): D
Grade E (Poor): 0

P-Reviewer: Kishikawa H, Japan; Sahin Y, Turkey; Zhang X, United States; Zhao ZY, China

Received: May 10, 2023

Peer-review started: May 10, 2023

First decision: July 9, 2023

Revised: July 21, 2023

Accepted: July 31, 2023

Article in press: July 31, 2023

Published online: October 16, 2023



Michael Yulong Wu, May Wong, Department of Gastroenterology and Hepatology, Royal North Shore Hospital, Sydney 2065, New South Wales, Australia

Michael Yulong Wu, May Wong, Northern Clinical School, The University of Sydney, Sydney 2065, New South Wales, Australia

Christopher Toon, NSW Health Pathology, Department of Anatomical Pathology, Royal North Shore Hospital, Sydney 2065, New South Wales, Australia

Michael Field, Clinical Genetics, Royal North Shore Hospital, Sydney 2065, New South Wales, Australia

Corresponding author: Michael Yulong Wu, MD, Doctor, Department of Gastroenterology and Hepatology, Royal North Shore Hospital, 1 Reserve Road, Sydney 2065, New South Wales, Australia. michaelyulong@gmail.com

Abstract

BACKGROUND

Juvenile polyposis syndrome (JPS) is a rare hereditary polyposis disease frequently associated with an autosomal-dominant variant of the *SMAD4* or *BMPRI1A* gene. It often manifests with symptoms in children and adolescents and is infrequently diagnosed in asymptomatic adults. Establishing the diagnosis is important as patients with JPS have a high risk of developing gastrointestinal cancer and require genetic counselling and close routine follow-up.

CASE SUMMARY

We report on the case of a 56-year-old female diagnosed with JPS after genetic testing revealed a rare variant of the *BMPRI1A* gene *BMPRI1A c.1409T>C* (p.Met470Thr). She was initially referred for colonoscopy by her general practitioner after testing positive on a screening faecal immunochemical test and subsequently found to have polyposis throughout the entire colorectum on her index screening colonoscopy. The patient was asymptomatic with a normal physical examination and no related medical or family history. Blood tests revealed only mild iron deficiency without anemia. To date, there has only been one other reported case of JPS with the same genetic variant. Subsequent colonoscopies were organised for complete polyp clearance and the patient was returned for surveillance follow-up.

CONCLUSION

JPS patients can present with no prior symptoms or family history. Genetic testing plays an important diagnostic role guiding management.

Key Words: Juvenile polyposis syndrome; Polyps; Colorectal polyp; Hereditary polyposis; Cancer; Case report

©The Author(s) 2023. Published by Baishideng Publishing Group Inc. All rights reserved.

Core Tip: Juvenile polyposis syndrome (JPS) is a hereditary autosomal dominant disease that phenotypically presents with polyposis throughout the colorectum. Detection and diagnosis is important as patients have a high risk of developing gastrointestinal cancer. Symptoms often manifest in childhood and adolescence with most having evidence of an associated family history. We report a case of polyposis found on index screening endoscopy in an asymptomatic female with no prior related family or medical history. Subsequent genetic testing led to the diagnosis of JPS after detecting a rare variant of the *BMPR1A* gene previously only reported in one other case of JPS.

Citation: Wu MY, Toon C, Field M, Wong M. Polyposis found on index colonoscopy in a 56-year-old female - *BMPR1A* variant in juvenile polyposis syndrome: A case report. *World J Gastrointest Endosc* 2023; 15(10): 623-628

URL: <https://www.wjgnet.com/1948-5190/full/v15/i10/623.htm>

DOI: <https://dx.doi.org/10.4253/wjge.v15.i10.623>

INTRODUCTION

Hereditary gastrointestinal polyposis syndromes are a rare group of diseases that account for up to approximately 5% of all colorectal cancers[1]. These polyposis syndromes are broadly categorised based on whether polyps demonstrate predominantly adenomatous or hamartomatous changes. Hamartomatous polyposis syndromes include Peutz-Jeghers syndrome, phosphatase and tensin homolog (PTEN) hamartomatous syndromes (Cowden syndrome and PTEN-related Proteus syndromes) and Juvenile Polyposis syndrome (JPS)[2]. Early recognition and detection of these hereditary diseases is important due to the lifetime risk of developing gastrointestinal cancer. JPS often manifests with gastrointestinal symptoms such as rectal bleeding, anemia, bowel habit changes and abdominal pain in childhood with an average age of diagnosis in the adolescent years[3,4]. We present a case of a patient with polyposis found on index screening endoscopy and discovery of a rare *de novo* variant of the *BMPR1A* gene on genetic testing leading to the subsequent diagnosis of JPS. This is a unique presentation of an asymptomatic adult with no related medical or family history and to date, there has been only one other reported case of JPS with the same genetic variant. This case highlights the importance of clinician vigilance as many individuals may present with no related history and emphasises the need for early genetic testing to guide appropriate management and surveillance intervals.

CASE PRESENTATION

Chief complaints

A 56-year-old female was referred in by her general practitioner after she tested positive on screening faecal immunochemical test.

History of present illness

She reported some infrequent constipation but no acute bowel habit changes. Overall, she was constitutionally well with no history of abdominal pain, malaena, haematochezia, or weight loss.

History of past illness

She had a medical history of gastroesophageal reflux disease and asthma. Her only regular medication was a budesonide-formoterol (200 mcg/6 mcg) inhaler.

Personal and family history

She had no history of smoking or alcohol use. There was no family history of colorectal cancer or other gastrointestinal diseases.

Physical examination

The patient was fit and well with normal vital signs. There were no significant findings on physical examination such as skin lesions commonly associated with Cowden and other PTEN hamartoma syndromes, mucosal pigmentation associated with Peutz-Jeghers syndrome and macrocephaly associated with JPS[5-7]. There were no features of alopecia,

onychodystrophy or hyperpigmentation that may be seen in Cronkhite-Canada syndrome[8]. She had no features of Hereditary Haemorrhagic Telangiectasia typically seen in *SMAD4* juvenile polyposis.

Laboratory examinations

The only abnormalities on her blood tests were a mild iron deficiency with ferritin level 25 µg/L (reference range 30–300 µg/L) without anaemia.

Imaging examinations

The patient proceeded to a gastroscopy which found a single medium-sized fundic gland polyp and a colonoscopy demonstrating more than one hundred pedunculated polyps throughout the caecum, ascending colon, transverse colon, descending colon, sigmoid colon, rectosigmoid colon and rectum (Figure 1). Initial biopsies were taken throughout the gastrointestinal tract and several larger polyps were removed for histology. A computed tomography enterography of the small bowel did not show any small bowel polyps.

FURTHER DIAGNOSTIC WORK-UP

On histology, the polypoid colonic mucosa showed epithelial-stromal hamartomatous features with variable epithelial hyperplasia and subtle myofibroblastic proliferation in the lamina propria (Figure 2). Overall features were consistent with a hamartomatous polyposis syndrome. JPS, Peutz-Jegher syndrome, Cronkhite-Canada syndrome and Cowden syndrome were considered differential diagnoses however sub-classification proved difficult as there were no further distinguishing histological features[9,10].

The patient was referred for multi-gene panel testing which included *STK11* associated with Peutz-Jeghers syndrome, *PTEN* associated with PTEN hamartoma syndromes (Cowden syndrome and PTEN-related Proteus syndromes) and *SMAD4* and *BMPR1A* associated with JPS. Massively Parallel Sequencing of > 99% of the coding sequences including the exon/intron boundaries to a depth of > 200 was performed to generate this result. SOPHiA genetics DDM (Sophia Genetics, Saint-Sulpice, Switzerland) was used to generate aligned reads and call variants against the hg19 human reference genome. A rare variant of *BMPR1A* written as *BMPR1A* c.1409T>C (p.Met470Thr) was identified and JPS was diagnosed as the likely cause of her polyposis phenotype. The patient has three siblings and one surviving parent none of whom have a history of colorectal cancer or polyps. All but one of these relatives lives overseas. The patient's 35-year-old son subsequently underwent a colonoscopy which showed no polyps. Genetic testing was also offered to the son which returned negative for the *BMPR1A* variant.

FINAL DIAGNOSIS

The combination of colonoscopy findings, histopathology and multi-gene panel testing led to the diagnosis of JPS.

TREATMENT

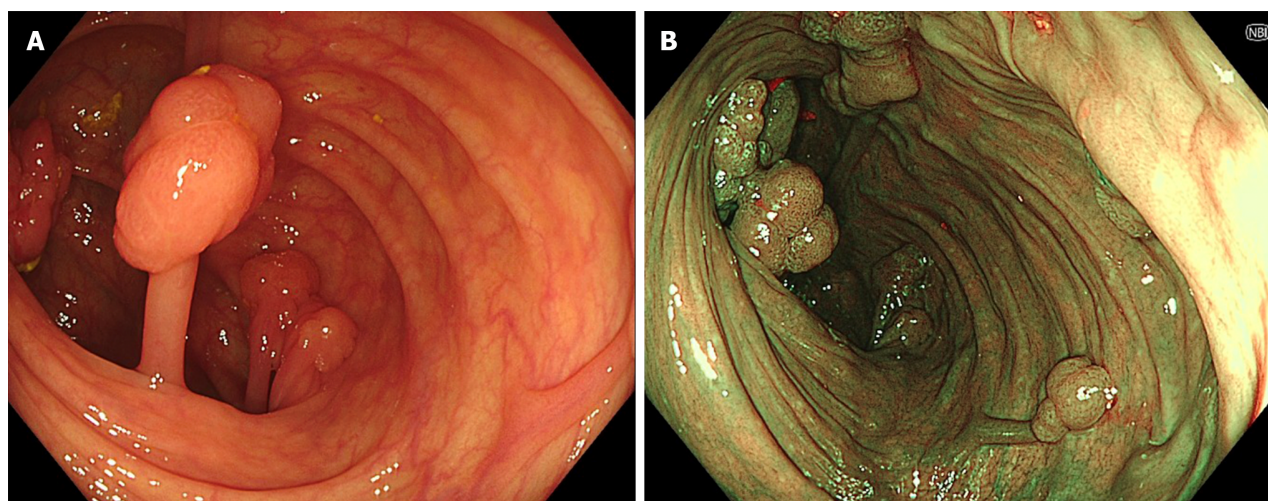
Three subsequent colonoscopies were organised for complete polyp clearance and histopathology demonstrated similar hamartomatous polyps with some showing early adenomatous changes.

OUTCOME AND FOLLOW-UP

The patient was recommended to return for yearly colonoscopy surveillance given the initial polyp burden.

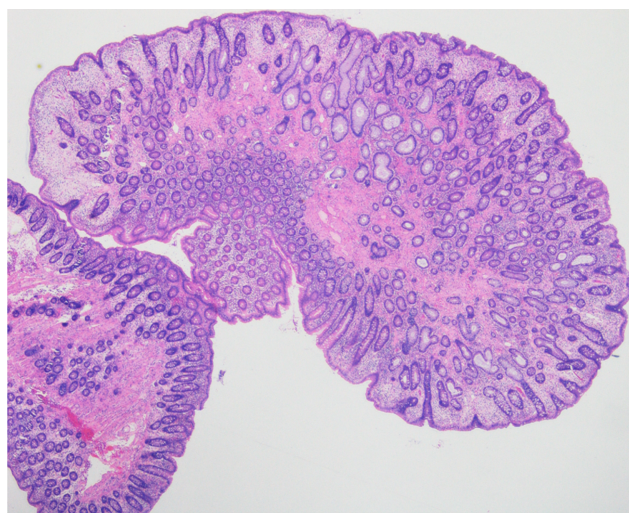
DISCUSSION

JPS is a rare autosomal dominant disease with an estimated incidence around 1/100000–1/160000 and a 39%–68% lifetime risk of colon cancer[11]. Polyp growth occurs primarily in the colorectum but can also appear in the stomach and small bowel. Macroscopically JPS polyps appear as pedunculated, exophytic, shiny and spherical growths[2,12]. Histologically, juvenile polyps typically demonstrate dilated thick mucin-filled glands with inflammatory infiltrates in the lamina propria. Despite these features, polyps in JPS can often still be indistinguishable from other polyposis syndromes. Clinical diagnostic criteria also exist in which a diagnosis can be made with the presence of any of the following: > 5 juvenile polyps in the colorectum, juvenile polyps in other parts of the gastrointestinal tract or any number of juvenile polyps and a positive family history[13]. Confirmatory genetic testing is recommended for all patients meeting clinical diagnostic criteria however the presence of germline mutations may only be present in 20%–60% of individuals[4,12]. Making an accurate diagnosis of JPS can remain a challenge for clinicians due to the similarity of features with other polyposis



DOI: 10.4253/wjge.v15.i10.623 Copyright ©The Author(s) 2023.

Figure 1 Endoscopic view. A and B: White Light Endoscopy Transverse Colon (A) and Narrow Band Imaging Transverse colon (B) showing pedunculated polyps in the transverse colon with some grouped into grapelike clusters.



DOI: 10.4253/wjge.v15.i10.623 Copyright ©The Author(s) 2023.

Figure 2 Histology of ascending colon polyp.

syndromes and a lack of a clear ‘gold standard’ diagnostic. In our case, a diagnosis was made on the basis of polyp morphology, histology and confirmatory genetic testing.

The heterozygous *BMPR1A* *c.1409T>C* (p.Met470Thr) variant is a missense mutation of Methionine to Threonine and identified only in one other patient with JPS[14]. In silico analysis predicted the variant affects protein function. Based on a lack of functional proof and biological information that the variant was damaging, the variant was classified as a variant of unclear significance (class 3) according to the American College of Medical Genetics and Genomics-Association for Molecular Pathology SHERLOC guidelines[15]. Whilst 45% to 60% of JPS cases are attributed to more common disease-causing variants in either the *BMPR1A* or *SMAD4* gene, there are still a number of cases without an identifiable pathogenic variant[16]. Since the variant is absent in a large population control group (gnomAD), has been previously reported in a patient with JPS and showed limited segregation with disease in this family, the *BMPR1A* *c.1409T>C* (p.Met470Thr) variant was considered by the authors to be the likely cause of the patients phenotype[17]. Given the rarity of disease, reporting on the polyposis features of this patient diagnosed with JPS contributes to the growing body of knowledge on the pathogenicity of *BMPR1A* variants.

The role of genetic counselling is invaluable in the management of a patient with JPS. Around 50% of individuals with JPS will have affected parents whilst the remaining half will have no prior family history of polyps and represent a *de novo* mutation[18]. Children of affected individuals have a 50% chance of inheritance. It is recommended that even asymptomatic relatives of individuals with JPS undergo evaluations with either genetic testing, if the gene variant is known, or endoscopic screening if the variant is unknown[18]. In the case of this patient, genetic screening was performed on the son to ensure early disease surveillance and monitoring.

For patients with polyposis syndrome, current guidelines by the American College of Gastroenterology (ACG) recommend screening gastroscopy and colonoscopy from age 12 or earlier if individuals are symptomatic with repeat surveillance endoscopy every 1–3 years depending on polyp burden[4]. The European Society of Gastrointestinal Endoscopy (ESGE) outline similar colonoscopy age intervals however recommend gastroscopy in asymptomatic individuals start at 18 years for those with a *SMAD4* mutation and at 25 years in those with *BMPR1A* mutation[19]. The ACG recommends removal of all polyps ≥ 5 mm whilst the ESGE recommends removal of those > 10 mm[4,19]. Periodic surveillance of the small bowel is recommended by the ACG however is not recommended by the ESGE given the rarity of small bowel involvement in JPS[4,19]. Surgical management with colectomy and ileo-rectal anastomosis is recommended if cancer, high-grade dysplasia or polyposis cannot be managed endoscopically[4]. In our patient, serial colonoscopies at 3 monthly intervals were adequate for complete polyp clearance and follow-up was organised for yearly surveillance given the significant polyp burden on initial colonoscopy. Current guidelines provide blanket recommendations to all patients diagnosed with JPS regardless of the gene-phenotype. Therefore a better understanding of the pathogenicity of gene variants can provide information that may help individualise clinical surveillance intervals.

This case highlights the presentation of an asymptomatic female found to have a rare potentially *de novo* variant in the *BMPR1A* gene leading to the diagnosis of JPS. This case serves as a reminder that many patients may be asymptomatic with no related medical or family history. It demonstrates the importance of referral to a geneticist for multigene panel testing for confirmatory diagnosis, guidance on further management of the patient and cancer surveillance intervals.

CONCLUSION

JPS is a rare disease that can be a challenging diagnosis to be distinguished from other hereditary polyposis syndromes. This case demonstrates that some patients may present in adulthood with no related symptoms or prior history. We describe the second reported case in literature of a rare potentially *de novo* variant of the *BMPR1A* gene in a patient with JPS. This report contributes to the developing body of literature and understanding in the pathogenicity of variants in *BMPR1A* gene.

FOOTNOTES

Author contributions: Wu MY and Wong M contributed to manuscript writing and editing; Toon C contributed to anatomical pathology analysis and manuscript editing; Field M contributed to genetic analysis and manuscript editing; All authors have read and approved the final manuscript.

Informed consent statement: Informed written consent was obtained from the patient for publication of this report and any accompanying images.

Conflict-of-interest statement: The authors declare no conflict-of-interests.

CARE Checklist (2016) statement: The authors have read the CARE Checklist (2016), and the manuscript was prepared and revised according to the CARE Checklist (2016).

Open-Access: This article is an open-access article that was selected by an in-house editor and fully peer-reviewed by external reviewers. It is distributed in accordance with the Creative Commons Attribution NonCommercial (CC BY-NC 4.0) license, which permits others to distribute, remix, adapt, build upon this work non-commercially, and license their derivative works on different terms, provided the original work is properly cited and the use is non-commercial. See: <https://creativecommons.org/licenses/by-nc/4.0/>

Country/Territory of origin: Australia

ORCID number: Michael Yulong Wu 0000-0003-1659-8599; Christopher Toon 0000-0002-0750-918X; Michael Field 0000-0001-7455-934X; May Wong 0000-0003-2856-7327.

S-Editor: Lin C

L-Editor: A

P-Editor: Cai YX

REFERENCES

- 1 **Patel R**, Hyer W. Practical management of polyposis syndromes. *Frontline Gastroenterol* 2019; **10**: 379-387 [PMID: 31656563 DOI: 10.1136/flgastro-2018-101053]
- 2 **Aretz S**. The differential diagnosis and surveillance of hereditary gastrointestinal polyposis syndromes. *Dtsch Arztebl Int* 2010; **107**: 163-173 [PMID: 20358032 DOI: 10.3238/arztebl.2010.0163]
- 3 **Manfredi M**. Hereditary hamartomatous polyposis syndromes: understanding the disease risks as children reach adulthood. *Gastroenterol Hepatol (N Y)* 2010; **6**: 185-196 [PMID: 20567567]

- 4 **Syngal S**, Brand RE, Church JM, Giardiello FM, Hampel HL, Burt RW; American College of Gastroenterology. ACG clinical guideline: Genetic testing and management of hereditary gastrointestinal cancer syndromes. *Am J Gastroenterol* 2015; **110**: 223-62; quiz 263 [PMID: 25645574 DOI: 10.1038/ajg.2014.435]
- 5 **Beggs AD**, Latchford AR, Vasen HF, Moslein G, Alonso A, Aretz S, Bertario L, Blanco I, Bülow S, Burn J, Capella G, Colas C, Friedl W, Möller P, Hes FJ, Järvinen H, Mecklin JP, Nagengast FM, Parc Y, Phillips RK, Hyer W, Ponz de Leon M, Renkonen-Sinisalo L, Sampson JR, Stormorken A, Tejpar S, Thomas HJ, Wijnen JT, Clark SK, Hodgson SV. Peutz-Jeghers syndrome: a systematic review and recommendations for management. *Gut* 2010; **59**: 975-986 [PMID: 20581245 DOI: 10.1136/gut.2009.198499]
- 6 **Brosens LA**, Langeveld D, van Hattem WA, Giardiello FM, Offerhaus GJ. Juvenile polyposis syndrome. *World J Gastroenterol* 2011; **17**: 4839-4844 [PMID: 22171123 DOI: 10.3748/wjg.v17.i44.4839]
- 7 **Pilarski R**, Burt R, Kohlman W, Pho L, Shannon KM, Swisher E. Cowden syndrome and the PTEN hamartoma tumor syndrome: systematic review and revised diagnostic criteria. *J Natl Cancer Inst* 2013; **105**: 1607-1616 [PMID: 24136893 DOI: 10.1093/jnci/djt277]
- 8 **Sweetser S**, Ahlquist DA, Osborn NK, Sanderson SO, Smyrk TC, Chari ST; Boardman LA. Clinicopathologic features and treatment outcomes in Cronkhite-Canada syndrome: support for autoimmunity. *Dig Dis Sci* 2012; **57**: 496-502 [PMID: 21881972 DOI: 10.1007/s10620-011-1874-9]
- 9 **Kopáčová M**, Urban O, Cyrany J, Laco J, Bureš J, Rejchrt S, Bártošová J, Tachecí I. Cronkhite-Canada syndrome: review of the literature. *Gastroenterol Res Pract* 2013; **2013**: 856873 [PMID: 24369458 DOI: 10.1155/2013/856873]
- 10 **Schreibman IR**, Baker M, Amos C, McGarrity TJ. The hamartomatous polyposis syndromes: a clinical and molecular review. *Am J Gastroenterol* 2005; **100**: 476-490 [PMID: 15667510 DOI: 10.1111/j.1572-0241.2005.40237.x]
- 11 **Kidambi TD**, Kohli DR, Samadder NJ, Singh A. Hereditary Polyposis Syndromes. *Curr Treat Options Gastroenterol* 2019; **17**: 650-665 [PMID: 31705372 DOI: 10.1007/s11938-019-00251-4]
- 12 **Zbuk KM**, Eng C. Hamartomatous polyposis syndromes. *Nat Clin Pract Gastroenterol Hepatol* 2007; **4**: 492-502 [PMID: 17768394 DOI: 10.1038/npcgasthep0902]
- 13 **Latchford AR**, Neale K, Phillips RK, Clark SK. Juvenile polyposis syndrome: a study of genotype, phenotype, and long-term outcome. *Dis Colon Rectum* 2012; **55**: 1038-1043 [PMID: 22965402 DOI: 10.1097/DCR.0b013e31826278b3]
- 14 **Kim IJ**, Park JH, Kang HC, Kim KH, Kim JH, Ku JL, Kang SB, Park SY, Lee JS, Park JG. Identification of a novel *BMPR1A* germline mutation in a Korean juvenile polyposis patient without *SMAD4* mutation. *Clin Genet* 2003; **63**: 126-130 [PMID: 12630959 DOI: 10.1034/j.1399-0004.2003.00008.x]
- 15 **Nykamp K**, Anderson M, Powers M, Garcia J, Herrera B, Ho YY, Kobayashi Y, Patil N, Thusberg J, Westbrook M; Invitae Clinical Genomics Group, Topper S. Sherloc: a comprehensive refinement of the ACMG-AMP variant classification criteria. *Genet Med* 2017; **19**: 1105-1117 [PMID: 28492532 DOI: 10.1038/gim.2017.37]
- 16 **Papadopoulos ME**, Plazzer JP, Macrae FA. Genotype-phenotype correlation of *BMPR1A* disease causing variants in juvenile polyposis syndrome. *Hered Cancer Clin Pract* 2023; **21**: 12 [PMID: 37400896 DOI: 10.1186/s13053-023-00255-3]
- 17 **Karczewski KJ**, Francioli LC, Tiao G, Cummings BB, Alfoldi J, Wang Q, Collins RL, Laricchia KM, Ganna A, Birnbaum DP, Gauthier LD, Brand H, Solomonson M, Watts NA, Rhodes D, Singer-Berk M, England EM, Seaby EG, Kosmicki JA, Walters RK, Tashman K, Farjoun Y, Banks E, Poterba T, Wang A, Seed C, Whiffin N, Chong JX, Samocha KE, Pierce-Hoffman E, Zappala Z, O'Donnell-Luria AH, Minikel EV, Weisburd B, Lek M, Ware JS, Vittal C, Armean IM, Bergelson L, Cibulskis K, Connolly KM, Covarrubias M, Donnelly S, Ferriera S, Gabriel S, Gentry J, Gupta N, Jeandet T, Kaplan D, Llanwarne C, Munshi R, Novod S, Petrillo N, Roazen D, Ruano-Rubio V, Saltzman A, Schleicher M, Soto J, Tibbetts K, Tolonen C, Wade G, Talkowski ME; Genome Aggregation Database Consortium, Neale BM, Daly MJ, MacArthur DG. The mutational constraint spectrum quantified from variation in 141,456 humans. *Nature* 2020; **581**: 434-443 [PMID: 32461654 DOI: 10.1038/s41586-020-2308-7]
- 18 **Larsen Haidle J**, MacFarland SP, Howe JR. Juvenile Polyposis Syndrome. In: Adam MP, Mirzaa GM, Pagon RA, Wallace SE, Bean LJH, Gripp KW, Amemiya A, editors. GeneReviews®. Seattle (WA): University of Washington, Seattle, 1993–2023
- 19 **van Leerdam ME**, Roos VH, van Hooft JE, Dekker E, Jover R, Kaminski MF, Latchford A, Neumann H, Pellisé M, Saurin JC, Tanis PJ, Wagner A, Balaguer F, Ricciardiello L. Endoscopic management of polyposis syndromes: European Society of Gastrointestinal Endoscopy (ESGE) Guideline. *Endoscopy* 2019; **51**: 877-895 [PMID: 31342472 DOI: 10.1055/a-0965-0605]



Published by **Baishideng Publishing Group Inc**
7041 Koll Center Parkway, Suite 160, Pleasanton, CA 94566, USA

Telephone: +1-925-3991568

E-mail: bpgoffice@wjgnet.com

Help Desk: <https://www.f6publishing.com/helpdesk>

<https://www.wjgnet.com>

