

# World Journal of *Clinical Cases*

*World J Clin Cases* 2023 September 26; 11(27): 6318-6669



**MINIREVIEWS**

- 6318 Characteristics of amino acid metabolism in colorectal cancer

*Xu F, Jiang HL, Feng WW, Fu C, Zhou JC*

**ORIGINAL ARTICLE****Clinical and Translational Research**

- 6327 Exploring the pharmacological mechanism of Wuzhuyu decoction on hepatocellular carcinoma using network pharmacology

*Ouyang JY, Lin WJ, Dong JM, Yang Y, Yang HK, Zhou ZL, Wang RQ*

- 6344 Identification of potential diagnostic and prognostic biomarkers for breast cancer based on gene expression omnibus

*Zhang X, Mi ZH*

**Retrospective Cohort Study**

- 6363 Treatment of proximal humeral fractures accompanied by medial calcar fractures using fibular autografts: A retrospective, comparative cohort study

*Liu N, Wang BG, Zhang LF*

**Retrospective Study**

- 6374 Effectiveness of out-fracture of the inferior turbinate with reduction nasal bone fracture

*Kim SY, Nam HJ, Byeon JY, Choi HJ*

- 6383 Prognostic model of hepatocellular carcinoma based on cancer grade

*Zhang GX, Ding XS, Wang YL*

- 6398 Oncologic efficacy of gonadotropin-releasing hormone agonist in hormone receptor-positive very young breast cancer patients treated with neoadjuvant chemotherapy

*Choi HJ, Lee JH, Jung CS, Ryu JM, Chae BJ, Lee SK, Yu JH, Kim SW, Nam SJ, Lee JE, Jung YJ, Kim HY*

- 6407 Correlation analysis of serum thyroglobulin, thyroid-stimulating hormone levels, and thyroid-cancer risk in thyroid nodule surgery

*Shuai JH, Leng ZF, Wang P, Ji YC*

- 6415 Closed thoracic drainage in elderly patients with chronic obstructive pulmonary disease complicated with spontaneous pneumothorax: A retrospective study

*Wang W, Zhu DN, Shao SS, Bao J*

**Observational Study**

- 6424 *Helicobacter pylori* eradication treatment for primary gastric diffuse large B-cell lymphoma: A single-center analysis

*Saito M, Mori A, Kajikawa S, Yokoyama E, Kanaya M, Izumiyama K, Morioka M, Kondo T, Tanei ZI, Shimizu A*

**Prospective Study**

- 6431** Effect of polyene phosphatidylcholine/ursodeoxycholic acid/ademetionine on pregnancy outcomes in intrahepatic cholestasis  
*Dong XR, Chen QQ, Xue ML, Wang L, Wu Q, Luo TF*

**SYSTEMATIC REVIEWS**

- 6440** Maternal diaphragmatic hernia in pregnancy: A systematic review with a treatment algorithm  
*Augustin G, Kovač D, Karadjole VS, Zajec V, Herman M, Hrbač P*

**META-ANALYSIS**

- 6455** Laparoscopic *vs* open radical resection in management of gallbladder carcinoma: A systematic review and meta-analysis  
*He S, Yu TN, Cao JS, Zhou XY, Chen ZH, Jiang WB, Cai LX, Liang X*

**CASE REPORT**

- 6476** Acute acquired concomitant esotropia with congenital paralytic strabismus: A case report  
*Zhang MD, Liu XY, Sun K, Qi SN, Xu CL*
- 6483** Tumor recurrence after pathological complete response in locally advanced gastric cancer after neoadjuvant therapy: Two case reports  
*Xing Y, Zhang ZL, Ding ZY, Song WL, Li T*
- 6491** Acute peritonitis secondary to post-traumatic appendicitis: A case report and literature review  
*Habachi G, Aziza B, Ben-Ammar S, Maherzi O, Houas Y, Kerkeni Y, Sahli S, Jouini R*
- 6498** Fournier's gangrene after insertion of thermo-expandable prostatic stent for benign prostatic hyperplasia: A case report  
*Jung HC, Kim YU*
- 6505** Methyl-CpG-Binding protein 2 duplication syndrome in a Chinese patient: A case report and review of the literature  
*Xing XH, Takam R, Bao XY, Ba-alwi NA, Ji H*
- 6515** Blood purification for treatment of non-liquefied multiple liver abscesses and improvement of T-cell function: A case report  
*Tang ZQ, Zhao DP, Dong AJ, Li HB*
- 6523** Eosinophilic granulomatosis with polyangiitis, asthma as the first symptom, and subsequent Loeffler endocarditis: A case report  
*He JL, Liu XY, Zhang Y, Niu L, Li XL, Xie XY, Kang YT, Yang LQ, Cai ZY, Long H, Ye GF, Zou JX*
- 6531** Left atrium veno-arterial extra corporeal membrane oxygenation as temporary mechanical support for cardiogenic shock: A case report  
*Lamastra R, Abbott DM, Degani A, Pellegrini C, Veronesi R, Pelenghi S, Dezza C, Gazzaniga G, Belliato M*

- 6537** Successful treatment of eyebrow intradermal nevi by shearing combined with electrocautery and curettage: Two case reports  
*Liu C, Liang JL, Yu JL, Hu Q, Li CX*
- 6543** Amniotic membrane mesenchymal stromal cell-derived secretome in the treatment of acute ischemic stroke: A case report  
*Lin FH, Yang YX, Wang YJ, Subbiah SK, Wu XY*
- 6551** Managing spindle cell sarcoma with surgery and high-intensity focused ultrasound: A case report  
*Zhu YQ, Zhao GC, Zheng CX, Yuan L, Yuan GB*
- 6558** Triplet regimen as a novel modality for advanced unresectable hepatocellular carcinoma: A case report and review of literature  
*Zhao Y, He GS, Li G*
- 6565** Acute diquat poisoning case with multiorgan failure and a literature review: A case report  
*Fan CY, Zhang CG, Zhang PS, Chen Y, He JQ, Yin H, Gong XJ*
- 6573** Fungal corneal ulcer after repair of an overhanging filtering bleb: A case report  
*Zhao J, Xu HT, Yin Y, Li YX, Zheng YJ*
- 6579** Combination therapy with toripalimab and anlotinib in advanced esophageal squamous cell carcinoma: A case report  
*Chen SC, Ma DH, Zhong JJ*
- 6587** Removal of a pulmonary artery foreign body during pulse ablation in a patient with atrial fibrillation: A case report  
*Yan R, Lei XY, Li J, Jia LL, Wang HX*
- 6592** Delayed-onset *micrococcus luteus*-induced postoperative endophthalmitis several months after cataract surgery: A case report  
*Nam KY, Lee HW*
- 6597** Anesthetic management of a pregnant patient with Eisenmenger's syndrome: A case report  
*Zhang Y, Wei TT, Chen G*
- 6603** Recurrence of unilateral angioedema of the tongue: A case report  
*Matsuhisa Y, Kenzaka T, Shimizu H, Hirose H, Gotoh T*
- 6613** Transverse mesocolic hernia with intestinal obstruction as a rare cause of acute abdomen in adults: A case report  
*Zhang C, Guo DF, Lin F, Zhan WF, Lin JY, Lv GF*
- 6618** Compound heterozygous mutations in tripeptidyl peptidase 1 cause rare autosomal recessive spinocerebellar ataxia type 7: A case report  
*Liu RH, Wang XY, Jia YY, Wang XC, Xia M, Nie Q, Guo J, Kong QX*

- 6624** Treatment of posterior interosseous nerve entrapment syndrome with ultrasound-guided hydrodissection: A case report  
*Qin LH, Cao W, Chen FT, Chen QB, Liu XX*
- 6631** Rapidly growing extensive polypoid endometriosis after gonadotropin-releasing hormone agonist discontinuation: A case report  
*Zhang DY, Peng C, Huang Y, Cao JC, Zhou YF*
- 6640** Preserving finger length in a patient with symmetric digital gangrene under local anesthesia: A case report  
*Kim KH, Ko IC, Kim H, Lim SY*
- 6646** Reconstruction of the lower back wound with delayed infection after spinal surgery: A case report  
*Kim D, Lim S, Eo S, Yoon JS*
- 6653** Solitary intraosseous neurofibroma in the mandible mimicking a cystic lesion: A case report and review of literature  
*Zhang Z, Hong X, Wang F, Ye X, Yao YD, Yin Y, Yang HY*
- 6664** Complete response of metastatic *BRAF* V600-mutant anaplastic thyroid cancer following adjuvant dabrafenib and trametinib treatment: A case report  
*Lee SJ, Song SY, Kim MK, Na HG, Bae CH, Kim YD, Choi YS*

**ABOUT COVER**

Editorial Board Member of *World Journal of Clinical Cases*, Alexandru Corlateanu, MD, PhD, Reader (Associate Professor), Department of Respiratory Medicine, Nicolae Testemitanu State University of Medicine and Pharmacy, Chisinau 2001, Moldova. alexandru\_corlateanu@yahoo.com

**AIMS AND SCOPE**

The primary aim of *World Journal of Clinical Cases* (WJCC, *World J Clin Cases*) is to provide scholars and readers from various fields of clinical medicine with a platform to publish high-quality clinical research articles and communicate their research findings online.

WJCC mainly publishes articles reporting research results and findings obtained in the field of clinical medicine and covering a wide range of topics, including case control studies, retrospective cohort studies, retrospective studies, clinical trials studies, observational studies, prospective studies, randomized controlled trials, randomized clinical trials, systematic reviews, meta-analysis, and case reports.

**INDEXING/ABSTRACTING**

The WJCC is now abstracted and indexed in Science Citation Index Expanded (SCIE, also known as SciSearch®), Journal Citation Reports/Science Edition, Current Contents®/Clinical Medicine, PubMed, PubMed Central, Reference Citation Analysis, China National Knowledge Infrastructure, China Science and Technology Journal Database, and Superstar Journals Database. The 2023 Edition of Journal Citation Reports® cites the 2022 impact factor (IF) for WJCC as 1.1; IF without journal self cites: 1.1; 5-year IF: 1.3; Journal Citation Indicator: 0.26; Ranking: 133 among 167 journals in medicine, general and internal; and Quartile category: Q4.

**RESPONSIBLE EDITORS FOR THIS ISSUE**

Production Editor: *Ying-Yi Yuan*; Production Department Director: *Xiang Li*; Editorial Office Director: *Jin-Lei Wang*.

**NAME OF JOURNAL**

*World Journal of Clinical Cases*

**ISSN**

ISSN 2307-8960 (online)

**LAUNCH DATE**

April 16, 2013

**FREQUENCY**

Thrice Monthly

**EDITORS-IN-CHIEF**

Bao-Gan Peng, Jerzy Tadeusz Chudek, George Kontogeorgos, Maurizio Serati, Ja Hyeon Ku

**EDITORIAL BOARD MEMBERS**

<https://www.wjgnet.com/2307-8960/editorialboard.htm>

**PUBLICATION DATE**

September 26, 2023

**COPYRIGHT**

© 2023 Baishideng Publishing Group Inc

**INSTRUCTIONS TO AUTHORS**

<https://www.wjgnet.com/bpg/gerinfo/204>

**GUIDELINES FOR ETHICS DOCUMENTS**

<https://www.wjgnet.com/bpg/GerInfo/287>

**GUIDELINES FOR NON-NATIVE SPEAKERS OF ENGLISH**

<https://www.wjgnet.com/bpg/gerinfo/240>

**PUBLICATION ETHICS**

<https://www.wjgnet.com/bpg/GerInfo/288>

**PUBLICATION MISCONDUCT**

<https://www.wjgnet.com/bpg/gerinfo/208>

**ARTICLE PROCESSING CHARGE**

<https://www.wjgnet.com/bpg/gerinfo/242>

**STEPS FOR SUBMITTING MANUSCRIPTS**

<https://www.wjgnet.com/bpg/GerInfo/239>

**ONLINE SUBMISSION**

<https://www.f6publishing.com>

# Treatment of posterior interosseous nerve entrapment syndrome with ultrasound-guided hydrodissection: A case report

Lan-Hui Qin, Wan Cao, Fei-Tong Chen, Qi-Bo Chen, Xi-Xia Liu

**Specialty type:** Rehabilitation

**Provenance and peer review:**

Unsolicited article; Externally peer reviewed.

**Peer-review model:** Single blind

**Peer-review report's scientific quality classification**

Grade A (Excellent): 0

Grade B (Very good): B, B, B

Grade C (Good): 0

Grade D (Fair): 0

Grade E (Poor): 0

**P-Reviewer:** Chang KV, Taiwan;  
Naganuma H, Japan;  
Papazafiropoulou A, Greece

**Received:** July 5, 2023

**Peer-review started:** July 5, 2023

**First decision:** August 10, 2023

**Revised:** August 20, 2023

**Accepted:** September 6, 2023

**Article in press:** September 6, 2023

**Published online:** September 26, 2023



Lan-Hui Qin, Wan Cao, Fei-Tong Chen, Qi-Bo Chen, Xi-Xia Liu, Department of Rehabilitation Medicine, The People's Hospital of Guangxi Zhuang Autonomous Region, Nanning 530021, Guangxi Zhuang Autonomous Region, China

**Corresponding author:** Xi-Xia Liu, PhD, Doctor, Department of Rehabilitation Medicine, The People's Hospital of Guangxi Zhuang Autonomous Region, No. 6 Taoyuan Road, Qingxiu District, Nanning 530021, Guangxi Zhuang Autonomous Region, China. [liuxixia2008@126.com](mailto:liuxixia2008@126.com)

## Abstract

### BACKGROUND

Posterior interosseous nerve (PIN) entrapment syndrome is one of the causes of weakness and pain of the arm muscles, which is prone to missed diagnosis and misdiagnosis in clinic practice. This paper reports a case of PIN entrapment syndrome, with PIN injury indicated by electrophysiology. Musculoskeletal ultrasound was applied to identify that the entrapment point was located at the inlet of the Frohse arch and the outlet of the supinator muscle. Treatment with ultrasound-guided nerve hydrodissection was performed on the entrapment point, which significantly improved the symptoms. Ultrasound-guided nerve hydrodissection is an effective therapeutic method for PIN entrapment syndrome.

### CASE SUMMARY

A male patient, 35 years old, worked as an automobile mechanic. He felt slightly weak extension activity of his right fingers 2 years ago but sought no treatment. Later, the symptoms gradually became aggravated and led to finger drop, particularly severe in the right middle finger, accompanied by supination weakness of the right forearm. Neural electrophysiological examination showed that the patient had partial PIN injury of the right radius. Musculoskeletal ultrasound examination indicated PIN entrapment at the inlet of the Frohse arch and the outlet of the supinator muscle. Therefore, PIN entrapment syndrome was diagnosed. After treatment with ultrasound-guided nerve hydrodissection around the entrapment point, the dorsiflexion weakness of the right hand was significantly improved compared with before treatment.

### CONCLUSION

Ultrasound-guided hydrodissection is efficacious for PIN entrapment syndrome, with high clinical value and great application prospects.

**Key Words:** Ultrasound-guided injection; Nerve hydrodissection; Posterior interosseous

nerve entrapment syndrome; Radial nerve; Case report

©The Author(s) 2023. Published by Baishideng Publishing Group Inc. All rights reserved.

**Core Tip:** Posterior interosseous nerve (PIN) entrapment syndrome, a cause of weakness and pain of the arm muscles, can be easily missed and misdiagnosed. This paper reports a case of PIN entrapment syndrome in which the PIN entrapment was located at the supinator muscle, according to the diagnosis by ultrasound. The entrapment point was treated with ultrasound-guided nerve hydrodissection, which had good efficacy, making this an option for the treatment of PIN entrapment syndrome.

**Citation:** Qin LH, Cao W, Chen FT, Chen QB, Liu XX. Treatment of posterior interosseous nerve entrapment syndrome with ultrasound-guided hydrodissection: A case report. *World J Clin Cases* 2023; 11(27): 6624-6630

**URL:** <https://www.wjgnet.com/2307-8960/full/v11/i27/6624.htm>

**DOI:** <https://dx.doi.org/10.12998/wjcc.v11.i27.6624>

## INTRODUCTION

Posterior interosseous nerve (PIN) entrapment syndrome refers to a series of symptoms and signs of movement disorders caused by such factors as traction, friction, inflammation, and mechanical compression of the deep branch of the radial nerve on the proximal dorsal side of the forearm[1]. The key to the treatment of this disease is to relieve compression as soon as possible. However, drug therapies have poor effects[2], and the large trauma from surgery may cause secondary injury[3].

Musculoskeletal ultrasound applied to the diagnosis and treatment of peripheral nerves can reveal the cause and secondary changes of nerve entrapment, which is conducive to the diagnosis of PIN entrapment syndrome[4]. Recently, our department conducted ultrasound-guided injection for nerve hydrodissection to treat a case of PIN entrapment, and good efficacy was obtained, providing a new idea for the treatment of the disease.

## CASE PRESENTATION

### Chief complaints

A 35-year-old male patient working as an automobile mechanic had a chronic course of disease. He visited the outpatient clinic of our hospital due to dorsiflexion weakness of the right fingers for 2 years and aggravated symptoms for 6 mo.

### History of present illness

The patient felt slight weakness of the extension activity of his right fingers 2 years ago but sought no treatment. Later, the symptoms gradually became aggravated and led to fingerdrop, particularly severe in the right middle finger.

### History of past illness

The patient denied any history of diabetes mellitus, trauma, drinking, poisoning, *etc.*

### Personal and family history

The patient denied any family history of similar diseases or the past use of special drugs.

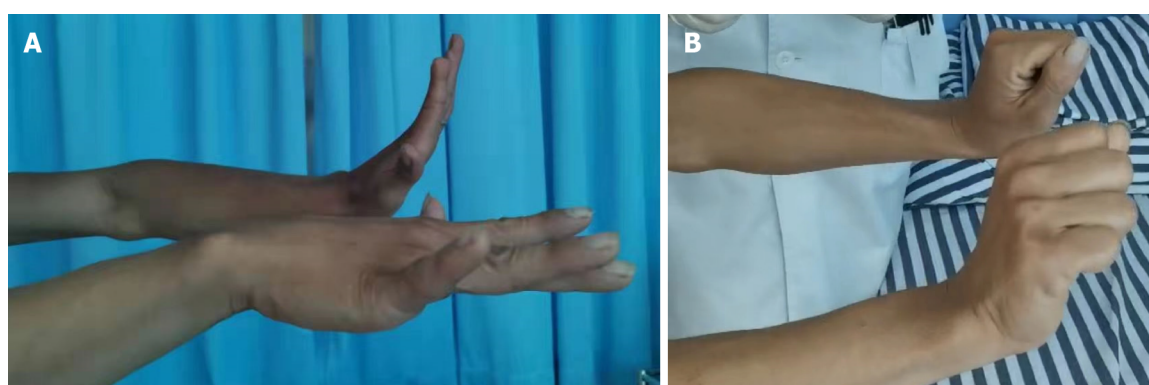
### Physical examination

There was no wound or scar on the right arm, no apparent muscle atrophy of the right forearm, but restricted active dorsiflexion of the right fingers. This was the most obvious for the middle finger, with muscle strength at grade 2. Passive dorsiflexion was possible, with no limitation of bilateral wrist extension (Figure 1A and B), but the strength of the supinator muscle of the right forearm was relatively poor (grade 4). The flexion-extension motion of the elbow and wrist joints was normal, and there were no abnormalities in the sensations of pain or touch in the forearm or hand.

### Laboratory examinations

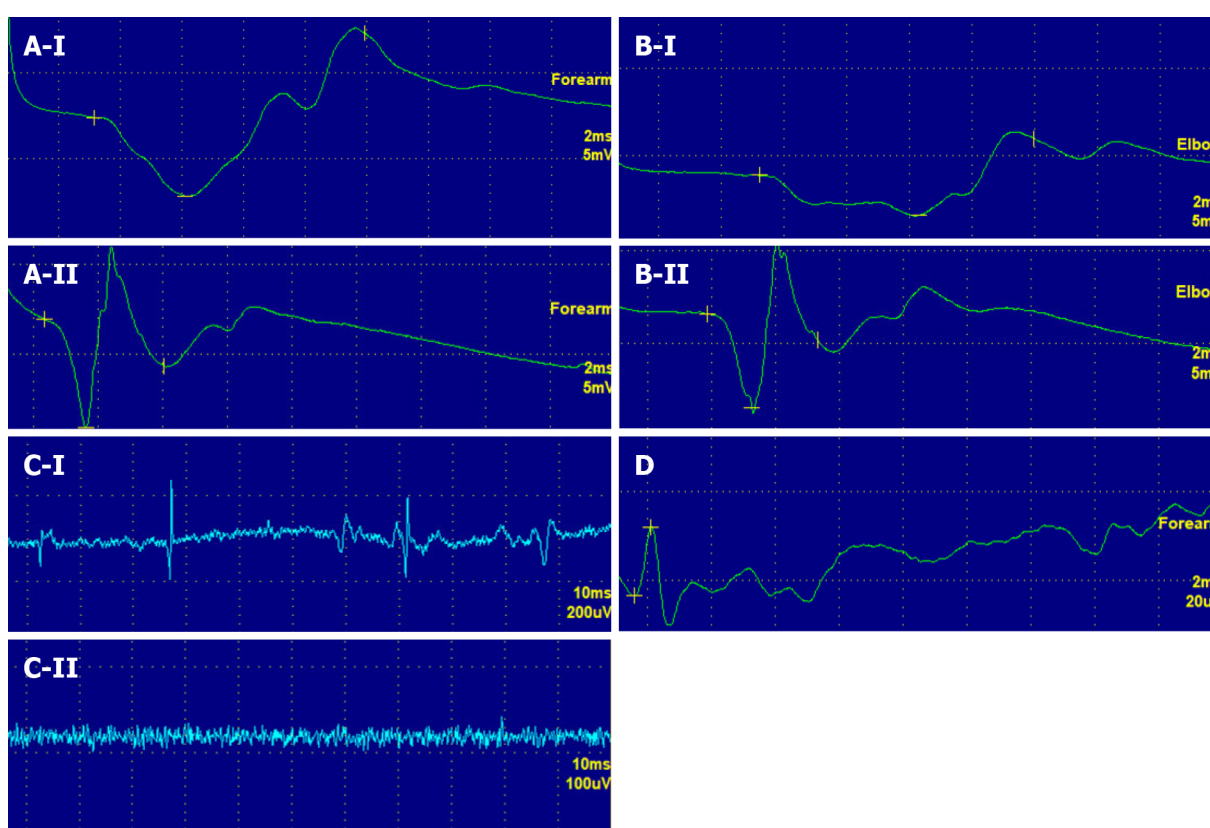
The neural electrophysiological examination performed on July 25, 2022, showed that the motor conduction amplitude and velocity of the right radial nerve were low, while the conduction of the right superficial radial nerve had no significant abnormality. Moreover, a small number of spontaneous potentials were detected in some of the right arm muscles. These are the electrophysiological manifestations of partial PIN injury of the right radius (Figure 2A-D).





DOI: 10.12998/wjcc.v11.i27.6624 Copyright ©The Author(s) 2023.

**Figure 1 Symptoms of finger extension disorder in patients.** A: The patient had poor strength of the extensor digitorum of the right hand; B: but his wrist extension was not different from that on the normal side.

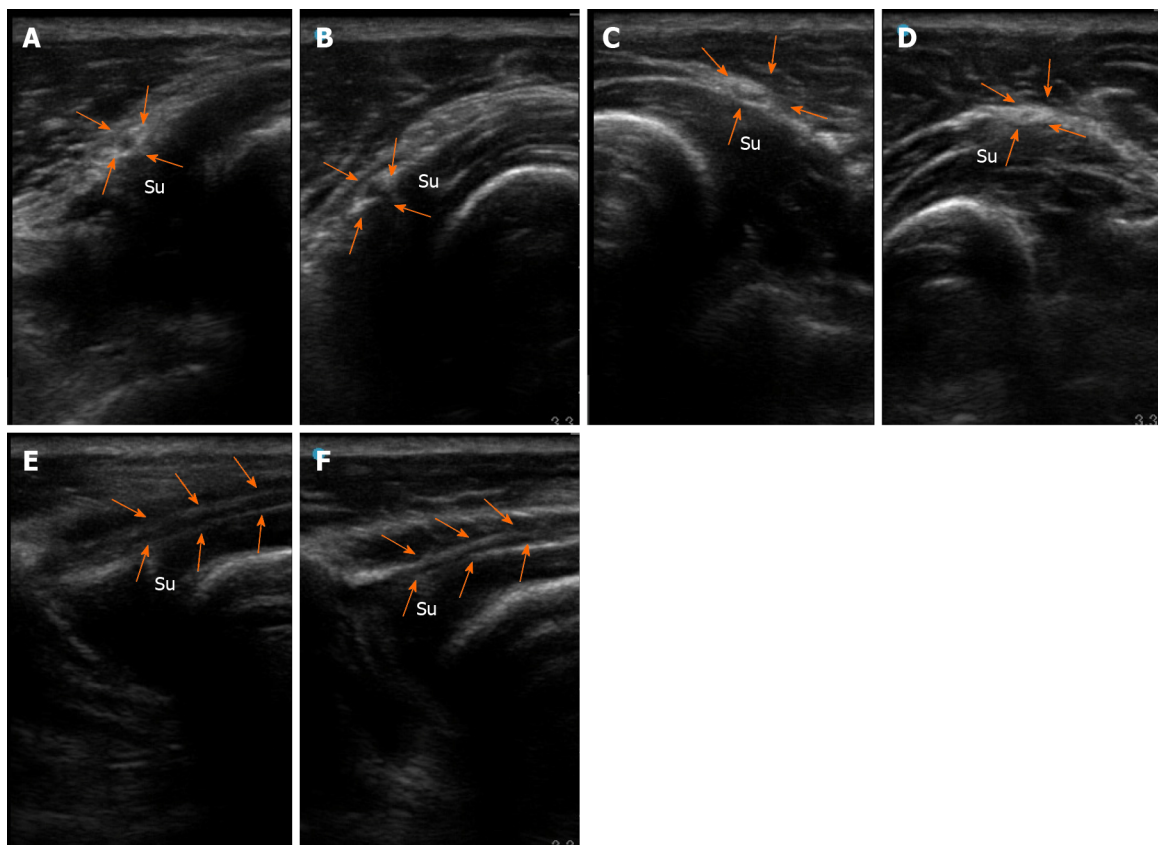


DOI: 10.12998/wjcc.v11.i27.6624 Copyright ©The Author(s) 2023.

**Figure 2 Nerve conduction and electromyogram examination results.** A and B: The amplitude of the right radial nerve conduction at the forearm and elbow joint was low, and the conduction time was long (A-I and B-I); C: A few spontaneous potentials were observed in some of the right arm muscles (C-I); D: Right superficial radial nerve conduction was normal (D). After treatment, the amplitude and time of the right radial nerve conduction at the forearm and elbow joint had basically recovered to normal (A-II and B-II), and there was no spontaneous potential in the right arm muscles (C-II).

### Imaging examinations

According to the musculoskeletal ultrasound examination on July 26, 2022, there were no abnormalities in the C5, C6, C7, or C8 nerve root, the brachial plexus nerve, the ulnar nerve, or the median nerve on the right side. No obvious mass was found in the region of the nerve course. The right supinator muscle was thicker than the left one, and tendinous thickening at the inlet of the Frohse arch was observed, where the nerves were compressed, thinned, and partially adhered to surrounding tissues, with unclear boundaries (Figure 3A). The branches of the PIN swelled and thickened after leaving the supinator tunnel (Figure 3C). PIN entrapment was observed on the longitudinal axis, and the nerves distal to the entrapment point showed swelling, thickening, and myelin thickening, with unclear boundaries with surrounding tissues (Figure 3E). Given all the above, entrapment of right PIN and its branches was diagnosed.



DOI: 10.12998/wjcc.v11.i27.6624 Copyright ©The Author(s) 2023.

**Figure 3 B-mode ultrasound images of the patient's posterior interosseous nerve.** A and B: Affected side (A) and healthy side (B): Transverse axis of the posterior interosseous nerve (PIN) at the inlet of the Frohse arch of the supinator muscle; C and D: Affected side (C) and healthy side (D): Transverse axis of the PIN at the outlet of the supinator muscle; E and F: Affected side (E) and healthy side (F): longitudinal axis of a PIN segment inside the supinator muscle. White arrows: PIN; su: Supinator muscle. The inlet of the right Frohse arch showed tendinous thickening, the PIN was compressed and thinned. There was local adhesion with the surrounding tissues, with unclear demarcation (A), and the left side was normal (B). The right PIN was swollen and thickened at the outlet of the supinator muscle (C), while the left PIN was normal (D). On the longitudinal axis, the right PIN is entrapped, the nerves distal to the entrapment point manifest swelling, thickening, and myelin thickening, with unclear boundaries with the surrounding tissues (E), and the left PIN is normal (F).

## FINAL DIAGNOSIS

As an automobile mechanic who had frequently repeated right forearm for a long time, the patient had a chronic course of disease, manifested as weakness of right finger extension (which was gradually exacerbated) and weakness of forearm supination. These were indicated by the neural electrophysiological finding that the PIN of the right radius was partially injured. Musculoskeletal ultrasound showed that the PIN was compressed and thinned after passing through the supinator muscle, and it was thickened at the distal and proximal ends of the entrapment. Hence, PIN entrapment syndrome was diagnosed.

## TREATMENT

The patient had a definite diagnosis, no obvious contraindications to puncture, and no history of drug allergy. After fully communicating with the patient and obtaining his informed consent, our department performed ultrasound-guided hydrodissection of the entrapped PIN with a 5% glucose injection using a 5 mL syringe and matched No. 7 needle. Specifically, 2-3 mL of 5% glucose was injected at each of the six points around the PIN entrapment points at the inlet of the Frohse arch and the outlet of the supinator muscle tunnel (Figure 4). Then, dissection of the nerve from the surrounding adhesive tissues could be observed. After injection, the patient received education on rehabilitation, and he was recommended to change the type of work he did to avoid repeated pronation and supination movements of the arm.

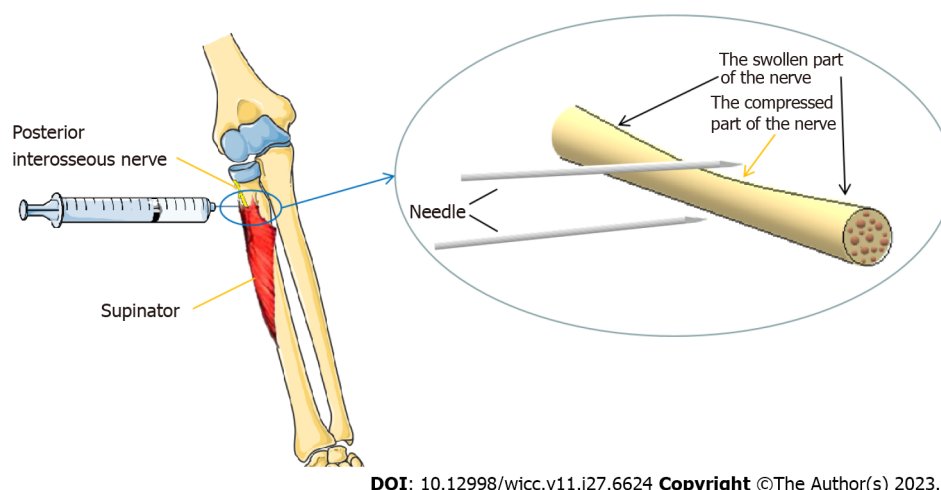
## OUTCOME AND FOLLOW-UP

One week after injection, the weakness of right finger extension was improved compared with that before injection (Table 1), the strength of right extensor digitorum was recovered to grade 3, but the strength of the supinator muscle of

**Table 1 Comparisons of muscle strength, motor conduction amplitude, and electromyography findings before and after treatment**

Examination	Location	Time		
		Before treatment	1 wk after treatment	3 mo after treatment
Manual muscle test (grade)	Extensor digitorum	2	3	4+
	Supinator muscle	4	4	5-
Motor conduction amplitude	Radial nerve at the forearm (mV)	4.55	-	6
	Radial nerve at the elbow (mV)	2.3	-	5.06
	Superficial radial nerve (mV)	27.4	-	-
Spontaneous potential on electromyogram	Extensor indicis	DP (1+)	-	0
	Extensor digitorum communis muscle	DP (2+)	-	0
	Extensor carpi radialis muscle	0	-	0

DP: Deep potential.

**Figure 4 Schematic diagram of hydrodissection injection of the posterior interosseous nerve.**

the right forearm was not significantly ameliorated. After 3 mo, the strength of his right extensor digitorum had recovered to grade 4+, and that of the supinator muscle of his right forearm was at grade 5-. These both allowed fully normal daily life and work activities. As revealed by the neural electrophysiological reexamination on October 28, 2022, the amplitude and velocity of motor conduction of the right radial nerve were basically restored to normal levels, markedly better than the findings of July 25. Moreover, no spontaneous potential was found in the right arm muscles. To sum up, the PIN of the right radius was generally normal (Figure 2, A-I/II, B-I/II, and C-I/II).

## DISCUSSION

PIN entrapment syndrome refers to the compression of the deep branch of the radial nerve, usually manifesting as incomplete paralysis of the forearm extensor muscles innervated by the deep branch of radial nerve, including thumb abduction dysfunction, finger extension dysfunction, and forearm pain. The etiology of nontraumatic PIN syndrome is classified as mechanical and nonmechanical. The former is induced by external pressure on the nerve, and the latter is attributed to inherent inflammatory response within the nerve[5]. The former is more common, and long-term mechanical repetition of pronation and supination movements of the forearm and entrapment of the Frohse tendon arch or tensioned supinator muscle are the leading causes of PIN entrapment syndrome[6]. Radial head fracture, dislocation, lipoma in the supinator tunnel, entrapment by a ganglion cyst, pyogenic arthritis, rheumatoid synovitis, and vasculitis can also result in PIN entrapment[7-9]. In this case, the patient was an automobile mechanic, so we concluded that the long-term, repetitive screwing and rotation movements of the forearm thickened the Frohse arch to cause PIN entrapment.

According to anatomical studies, the PIN presents a fishtail shape after passing through the supinator muscle. In its two relatively constant branches, the ulnar branch innervates the extensor digitorum minimis, extensor digitorum, and extensor carpi ulnaris, and the radial branch innervates the abductor pollicis longus, extensor pollicis brevis, and extensor

indicus[10]. In this case, the patient only had weakness of finger extension and supination, with worse symptoms in the middle and ring fingers than the index finger, no disorders of thumb abduction or extension movements, and no pain in the elbow joint or forearm. We concluded that the ulnar branch of the PIN was the main part that was injured, the radial branch having no or mild injury.

The entrapment of peripheral nerves can lead to demyelinating changes in peripheral nerve fibers, and peripheral nerve myelin breakdown, axonal degeneration, and fibrous connective tissue hyperplasia are gradually worsen[3], and the chance of nerve functional recovery decreases with longer entrapment time. Therefore, for similar cases in the clinic, definite diagnosis in the early stage, relief of nerve compression as early as possible, promotion of nerve functional recovery, and prevention of further nerve degeneration are the keys to treatment.

The clinical diagnosis of PIN entrapment syndrome mainly depends on its clinical symptoms. Due to the many similarities in PIN entrapment syndrome with other diseases in terms of etiology, clinical manifestations, and signs, misdiagnosis and missed diagnosis are likely. Various imaging methods for peripheral nerve injury fail to continuously and dynamically display the peripheral nerves, especially the small peripheral nerve branches, making them prone to misdiagnosis and missed diagnosis. Even the gold standard for diagnosing nerve entrapment lesions, electrophysiological diagnosis, cannot accurately locate the nerve compression. In this case, the electrophysiological examination of the patient suggested PIN injury. Then, through ultrasound examination as well as observation and measurement of PIN morphology[11], changes of internal echoes and surrounding anatomic structure, it was clarified that the entrapment point was located at the inlet of the Frohse arch and the outlet of the supinator muscle. The patient's symptoms improved after the treatment with ultrasound-guided hydrodissection at the entrapment point. Therefore, ultrasound can serve as an important supplement to neural electrophysiology owing to its advantages of noninvasiveness, simplicity, continuous dynamic scanning, and bilateral comparison. It can provide precise visual guidance for injection therapies and more accurate treatment.

Currently, conventional conservative treatments (oral medication, physical therapy, *etc.*) for PIN entrapment syndrome have poor efficacy. PIN entrapment syndrome is mainly treated through surgery, where the Frohse arch and supinator tunnel are cut open to resect the tendinous part at the initial portion of the extensor carpi radialis brevis tendon and remove the causes of PIN entrapment. However, given the disadvantages of a long open incision and large trauma on the soft tissues around the forearm, this will cause soft tissue adhesion and scarring around the forearm after surgery, which may ultimately lead the PIN entrapment to recur. The nerve hydrodissection technique is a locally invasive treatment in which liquids are injected into the neuroanatomical space to promote perineural stripping and adhesion dissolution, reduce repetitive compression[12], promote blood flow, enhance nerve conduction, and achieve physical separation and chemical repair, thereby exerting a therapeutic effect. The nerve hydrodissection technique has good clinical efficacy in treating carpal tunnel syndrome, cubital tunnel syndrome, lateral femoral cutaneous neuropathy, and common peroneal nerve entrapment syndrome[13,14]. By using ultrasound, perineural injections have become significantly safer and more effective[15], but ultrasound-guided nerve hydrodissection for PIN entrapment syndrome has not been reported yet.

The available injections for nerve hydrodissection include normal saline, 5% glucose, corticosteroid, local anesthetics, and platelet-rich plasma. Both 5% glucose and platelet-rich plasma always produce better results than vehicle control or corticosteroid, but the platelet-rich plasma has complex production process and high costs[16]. Therefore, this patient received nerve hydrodissection combined with 5% glucose solution. The efficacy study confirmed that nerve hydrodissection combined with 5% glucose effectively improved this patient's PIN entrapment-induced motor dysfunction. Moreover, no immobilization of the elbow joint or forearm was needed after the injection. The treatment did not affect the daily life of the patient, nor did it cause forearm movement dysfunction due to long-term immobilization of the elbow joint and forearm.

## CONCLUSION

Ultrasound-guided injection is an ideal image-guided peripheral nerve interventional therapy, through which the appropriate path for needle insertion can be selected visually, and the nerve imaging and drug injection can be displayed in real time, thus reducing the patient's discomfort. There has been no report of ultrasound-guided nerve hydrodissection for PIN entrapment syndrome in China or elsewhere. This case report details the treatment of a patient by ultrasound-guided nerve hydrodissection in our department, the first report of its kind. A comprehensive evaluation of the efficacy suggests that the treatment is effective for PIN entrapment syndrome, with high clinical value and good application prospects.

## FOOTNOTES

**Author contributions:** Qin LH was a major contributor in writing the manuscript; Cao W, Chen QB, and Chen FT analyzed and interpreted the patient data; Liu XX presented information and contributed to editing and revision of the article; All authors approved submission of the manuscript.

**Supported by** the Guangxi Natural Science Foundation, No. 2022GXNSFBA035519; and No. 2023GXNSFAA026175; Self-funded Project of Guangxi Health Commission, No. Z20180776 and No. Z20210179; and Guangxi Medical and Health Appropriate Technology Development and Promotion Application Project, No. S2020081.



**Informed consent statement:** Informed written consent was obtained from the patient's parents for publication of this report and any accompanying images.

**Conflict-of-interest statement:** All the authors report no relevant conflicts of interest for this article.

**CARE Checklist (2016) statement:** The authors have read the CARE Checklist (2016), and the manuscript was prepared and revised according to the CARE Checklist (2016).

**Open-Access:** This article is an open-access article that was selected by an in-house editor and fully peer-reviewed by external reviewers. It is distributed in accordance with the Creative Commons Attribution NonCommercial (CC BY-NC 4.0) license, which permits others to distribute, remix, adapt, build upon this work non-commercially, and license their derivative works on different terms, provided the original work is properly cited and the use is non-commercial. See: <https://creativecommons.org/licenses/by-nc/4.0/>

**Country/Territory of origin:** China

**ORCID number:** Lan-Hui Qin 0000-0002-4883-1327; Wan Cao 0000-0002-9585-3529; Xi-Xia Liu 0000-0001-5458-2964.

**S-Editor:** Liu JH

**L-Editor:** A

**P-Editor:** Liu JH

## REFERENCES

- 1 **Strohl AB**, Zelouf DS. Ulnar Tunnel Syndrome, Radial Tunnel Syndrome, Anterior Interosseous Nerve Syndrome, and Pronator Syndrome. *J Am Acad Orthop Surg* 2017; **25**: e1-e10 [PMID: 27902538 DOI: 10.5435/JAAOS-D-16-00010]
- 2 **Bak K**, Tørholm C. [Supinator syndrome. Entrapment of the posterior interosseous nerve]. *Ugeskr Laeger* 1996; **158**: 919-921 [PMID: 8638330]
- 3 **Matsumoto J**, Isu T, Kim K, Iwamoto N, Yamazaki K, Isobe M. Clinical Features and Surgical Treatment of Superficial Peroneal Nerve Entrapment Neuropathy. *Neurol Med Chir (Tokyo)* 2018; **58**: 320-325 [PMID: 29925720 DOI: 10.2176/nmc.oa.2018-0039]
- 4 **Sancho Saldaña A**, Ciotti López M, Capablo Liesa JL. Posterior interosseous nerve syndrome as an isolated symptom of haemorrhagic stroke: The central mimicking the peripheral. *Neurologia (Engl Ed)* 2020; **35**: 659-660 [PMID: 31771780 DOI: 10.1016/j.nrl.2019.08.003]
- 5 **Sigamoney KV**, Rashid A, Ng CY. Management of Atraumatic Posterior Interosseous Nerve Palsy. *J Hand Surg Am* 2017; **42**: 826-830 [PMID: 28969808 DOI: 10.1016/j.jhsa.2017.07.026]
- 6 **Schoen DC**. Upper extremity nerve entrapments. *Orthop Nurs* 2002; **21**: 15-31; quiz 31 [PMID: 11949236 DOI: 10.1097/00006416-200203000-00005]
- 7 **Kim Y**, Ha DH, Lee SM. Ultrasonographic findings of posterior interosseous nerve syndrome. *Ultrasonography* 2017; **36**: 363-369 [PMID: 28494524 DOI: 10.14366/usc.17007]
- 8 **Anania P**, Fiaschi P, Ceraudo M, Balestrino A, Zaotini F, Martinoli C, Gennaro S. Posterior interosseous nerve entrapments: review of the literature. Is the entrapment distal to the arcade of Frohse a really rare condition? *Acta Neurochir (Wien)* 2018; **160**: 1857-1864 [PMID: 29974240 DOI: 10.1007/s00701-018-3615-8]
- 9 **Niu X**, Hu Y, Zha G, Hu J, Yi J, Xiao L. Posterior interosseous nerve syndrome secondary to compression by an intramuscular hemangioma. *Muscle Nerve* 2019; **60**: E5-E6 [PMID: 31049980 DOI: 10.1002/mus.26506]
- 10 **Hohenberger GM**, Schwarz AM, Grechenig P, Maier MJ, Schwarz U, Kuchling S, Gänsslen A, Weiglein AH. Morphology of the Posterior Interosseous Nerve with Regard to Entrapment Syndrome. *Indian J Orthop* 2020; **54**: 188-192 [PMID: 32952929 DOI: 10.1007/s43465-020-00084-9]
- 11 **Wu CH**, Chang KV, Özçakar L, Hsiao MY, Hung CY, Shyu SG, Wang TG, Chen WS. Sonographic tracking of the upper limb peripheral nerves: a pictorial essay and video demonstration. *Am J Phys Med Rehabil* 2015; **94**: 740-747 [PMID: 26135374 DOI: 10.1097/PHM.0000000000000344]
- 12 **Kim SD**. Efficacy of tendon and nerve gliding exercises for carpal tunnel syndrome: a systematic review of randomized controlled trials. *J Phys Ther Sci* 2015; **27**: 2645-2648 [PMID: 26357452 DOI: 10.1589/jpts.27.2645]
- 13 **Alaa L**, Dena MS, Asmaa ARAL, Dina SF. Clinical, electrophysiological, and ultrasound evaluation for early detection of musculoskeletal hand disorders and nerve entrapment in mobile phone users. *Revista Colombiana de Reumatología* 2021; **28**: 267-275 [DOI: 10.1016/j.rcreu.2020.08.008]
- 14 **Cass SP**. Ultrasound-Guided Nerve Hydrodissection: What is it? A Review of the Literature. *Curr Sports Med Rep* 2016; **15**: 20-22 [PMID: 26745165 DOI: 10.1249/JSR.0000000000000226]
- 15 **Chang KV**, Wu WT, Özçakar L. Ultrasound imaging and guidance in peripheral nerve entrapment: hydrodissection highlighted. *Pain Manag* 2020; **10**: 97-106 [PMID: 32162601 DOI: 10.2217/pmt-2019-0056]
- 16 **Lin CP**, Chang KV, Huang YK, Wu WT, Özçakar L. Regenerative Injections Including 5% Dextrose and Platelet-Rich Plasma for the Treatment of Carpal Tunnel Syndrome: A Systematic Review and Network Meta-Analysis. *Pharmaceuticals (Basel)* 2020; **13** [PMID: 32197544 DOI: 10.3390/ph13030049]



Published by **Baishideng Publishing Group Inc**  
7041 Koll Center Parkway, Suite 160, Pleasanton, CA 94566, USA

**Telephone:** +1-925-3991568

**E-mail:** [bpgoffice@wjgnet.com](mailto:bpgoffice@wjgnet.com)

**Help Desk:** <https://www.f6publishing.com/helpdesk>

<https://www.wjgnet.com>

