

# World Journal of *Clinical Cases*

*World J Clin Cases* 2023 October 16; 11(29): 6974-7260



## MINIREVIEWS

- 6974 Applications of time series analysis in epidemiology: Literature review and our experience during COVID-19 pandemic

*Tomov L, Chervenkov L, Miteva DG, Batselova H, Velikova T*

## ORIGINAL ARTICLE

## Retrospective Cohort Study

- 6984 Acute cholangitis: Does malignant biliary obstruction *vs* choledocholithiasis etiology change the clinical presentation and outcomes?

*Tsou YK, Su YT, Lin CH, Liu NJ*

## Retrospective Study

- 6995 Usefulness of analyzing endoscopic features in identifying the colorectal serrated sessile lesions with and without dysplasia

*Wang RG, Ren YT, Jiang X, Wei L, Zhang XF, Liu H, Jiang B*

- 7004 Roles of biochemistry data, lifestyle, and inflammation in identifying abnormal renal function in old Chinese

*Chen CH, Wang CK, Wang CY, Chang CF, Chu TW*

- 7017 Clinical efficacy and safety of Guipi decoction combined with escitalopram oxalate tablets in patients with depression

*Yu J, Xu FQ*

- 7026 Artificial intelligence technology and ultrasound-guided nerve block for analgesia in total knee arthroplasty

*Tong SX, Li RS, Wang D, Xie XM, Ruan Y, Huang L*

- 7034 Axenfeld-Reiger syndrome: A search for the missing links

*Morya AK, Ramesh PV, Sinha S, Nishant P, Nain N, Ramavath RN, Gone C, Prasad R*

## Observational Study

- 7043 Self-management of osteoarthritis while waiting for total knee arthroplasty during the COVID-19 pandemic among older Malaysians

*Mahdzir ANK, Mat S, Seow SR, Abdul Rani R, Che Hasan MK, Mohamad Yahaya NH*

- 7053 "In situ bone flap" combined with vascular pedicled mucous flap to reconstruction of skull base defect

*Qian M, Chen X, Zhang LY, Wang ZF, Zhang Y, Wang XJ*

- 7061 Reference values of gait parameters in healthy Chinese university students: A cross-sectional observational study

*Yu JS, Zhuang C, Guo WX, Chen JJ, Wu XK, Xie W, Zhou X, Su H, Chen YX, Wang LK, Li WK, Tian K, Zhuang RJ*

- 7075** Effect of T-regulatory cells and interleukin-35, interleukin-10, and transforming growth factor-beta on diffuse large B-cell lymphoma

*Wu H, Sun HC, Ouyang GF*

### META-ANALYSIS

- 7082** Meta-analysis on the effectiveness of parent education for children with disabilities

*Jang J, Kim G, Jeong H, Lee N, Oh S*

- 7091** Meta-analysis of the efficacy and safety of daratumumab in the treatment of multiple myeloma

*Wang P, Jin SY*

### CASE REPORT

- 7101** Varicella-zoster virus meningitis with hypoglycorrhachia: A case report

*Cao LJ, Zheng YM, Li F, Hao HJ, Gao F*

- 7107** Unusual presentation of penile giant condyloma acuminatum with spontaneous prepuce perforation: A case report

*Hsu FC, Yu DS, Pu TW, Wu MJ, Meng E*

- 7113** Primary renal lymphoma presenting as renal failure: A case report and review of literature from 1989

*Lee SB, Yoon YM, Hong R*

- 7127** Intravascular ultrasonography assisted carotid artery stenting for treatment of carotid stenosis: Two case reports

*Fu PC, Wang JY, Su Y, Liao YQ, Li SL, Xu GL, Huang YJ, Hu MH, Cao LM*

- 7136** Mucoepidermoid carcinoma of the lung with hemoptysis as initial symptom: A case report

*Xie WX, Liu R, Li Z, Zhou PL, Duan LN, Fu DD*

- 7144** Co-infection of *Chlamydia psittaci* and *Tropheryma whippelii*: A case report

*Du ZM, Chen P*

- 7150** Surgical treatment of severe anterior capsular organized hard core cataract: A case report

*Wang LW, Fang SF*

- 7156** First platelet transfusion refractoriness in a patient with acute myelocytic leukemia: A case report

*Tu SK, Fan HJ, Shi ZW, Li XL, Li M, Song K*

- 7162** Rare finding of primary aortoduodenal fistula on single-photon emission computed tomography/computed tomography of gastrointestinal bleeding: A case report

*Kuo CL, Chen CF, Su WK, Yang RH, Chang YH*

- 7170** Rituximab combined with Bruton tyrosine kinase inhibitor to treat elderly diffuse large B-cell lymphoma patients: Two case reports

*Zhang CJ, Zhao ML*

- 7179** Use of Ilizarov technique for bilateral knees flexion contracture in Juvenile-onset ankylosing spondylitis: A case report  
*Xia LW, Xu C, Huang JH*
- 7187** Case of takotsubo cardiomyopathy after surgical treatment of liver hydatid cyst: A case report  
*Altaş Y, Abdullayeva Ü*
- 7193** Laparoscopic choledocholithotomy and transductal T-tube insertion with indocyanine green fluorescence imaging and laparoscopic ultrasound: A case report  
*Yoo D*
- 7200** Hematopoietic stem cell transplantation of aplastic anemia by relative with mutations and normal telomere length: A case report  
*Yan J, Jin T, Wang L*
- 7207** Emphysematous thrombophlebitis caused by a misplaced central venous catheter: A case report  
*Chen N, Chen HJ, Chen T, Zhang W, Fu XY, Xing ZX*
- 7214** Aggressive angiomyxoma of the epididymis: A case report  
*Liu XJ, Su JH, Fu QZ, Liu Y*
- 7221** Gastric and intestinal ectopic pancreas: Two case reports  
*Zhang H, Zhao HY, Zhang FH, Liang W*
- 7227** Congenital leukemia: A case report and review of literature  
*Yang CX, Yang Y, Zhang FL, Wang DH, Bian QH, Zhou M, Zhou MX, Yang XY*
- 7234** Imaging misdiagnosis and clinical analysis of significant hepatic atrophy after bilioenteric anastomosis: A case report  
*Liang SY, Lu JG, Wang ZD*
- 7242** Surgical treatment of mixed cervical spondylosis with spontaneous cerebrospinal fluid leakage: A case report  
*Yu Z, Zhang HFZ, Wang YJ*
- 7248** Simultaneous thyroglossal duct cyst with parathyroid cyst: A case report  
*Chen GY, Li T*
- 7253** Submandibular solid-cystic mass as the first and sole manifestation of occult thyroid papillary carcinoma: A case report  
*Chen GY, Li T*

**LETTER TO THE EDITOR**

- 7258** Artificial intelligence and machine learning in motor recovery: A rehabilitation medicine perspective  
*Swarnakar R, Yadav SL*



**ABOUT COVER**

Editorial Board Member of *World Journal of Clinical Cases*, Zeid J Khitan, FACP, FASN, MBBS, MD, Academic Research, Director, Full Professor, Department of Medicine, Marshall University, Huntington, WV 25701, United States. zkhitan@marshall.edu

**AIMS AND SCOPE**

The primary aim of *World Journal of Clinical Cases* (WJCC, *World J Clin Cases*) is to provide scholars and readers from various fields of clinical medicine with a platform to publish high-quality clinical research articles and communicate their research findings online.

WJCC mainly publishes articles reporting research results and findings obtained in the field of clinical medicine and covering a wide range of topics, including case control studies, retrospective cohort studies, retrospective studies, clinical trials studies, observational studies, prospective studies, randomized controlled trials, randomized clinical trials, systematic reviews, meta-analysis, and case reports.

**INDEXING/ABSTRACTING**

The WJCC is now abstracted and indexed in Science Citation Index Expanded (SCIE, also known as SciSearch®), Journal Citation Reports/Science Edition, Current Contents®/Clinical Medicine, PubMed, PubMed Central, Reference Citation Analysis, China National Knowledge Infrastructure, China Science and Technology Journal Database, and Superstar Journals Database. The 2023 Edition of Journal Citation Reports® cites the 2022 impact factor (IF) for WJCC as 1.1; IF without journal self cites: 1.1; 5-year IF: 1.3; Journal Citation Indicator: 0.26; Ranking: 133 among 167 journals in medicine, general and internal; and Quartile category: Q4.

**RESPONSIBLE EDITORS FOR THIS ISSUE**

Production Editor: Hua-Ge Yin; Production Department Director: Xiang Li; Editorial Office Director: Jin-Lei Wang.

**NAME OF JOURNAL**

*World Journal of Clinical Cases*

**ISSN**

ISSN 2307-8960 (online)

**LAUNCH DATE**

April 16, 2013

**FREQUENCY**

Thrice Monthly

**EDITORS-IN-CHIEF**

Bao-Gan Peng, Jerzy Tadeusz Chudek, George Kontogeorgos, Maurizio Serati, Ja Hyeon Ku

**EDITORIAL BOARD MEMBERS**

<https://www.wjgnet.com/2307-8960/editorialboard.htm>

**PUBLICATION DATE**

October 16, 2023

**COPYRIGHT**

© 2023 Baishideng Publishing Group Inc

**INSTRUCTIONS TO AUTHORS**

<https://www.wjgnet.com/bpg/gerinfo/204>

**GUIDELINES FOR ETHICS DOCUMENTS**

<https://www.wjgnet.com/bpg/GerInfo/287>

**GUIDELINES FOR NON-NATIVE SPEAKERS OF ENGLISH**

<https://www.wjgnet.com/bpg/gerinfo/240>

**PUBLICATION ETHICS**

<https://www.wjgnet.com/bpg/GerInfo/288>

**PUBLICATION MISCONDUCT**

<https://www.wjgnet.com/bpg/gerinfo/208>

**ARTICLE PROCESSING CHARGE**

<https://www.wjgnet.com/bpg/gerinfo/242>

**STEPS FOR SUBMITTING MANUSCRIPTS**

<https://www.wjgnet.com/bpg/GerInfo/239>

**ONLINE SUBMISSION**

<https://www.f6publishing.com>

# Emphysematous thrombophlebitis caused by a misplaced central venous catheter: A case report

Ni Chen, Hua-Jun Chen, Tao Chen, Wen Zhang, Xiao-Yun Fu, Zhou-Xiong Xing

**Specialty type:** Critical care medicine

**Provenance and peer review:**

Unsolicited article; Externally peer reviewed.

**Peer-review model:** Single blind

**Peer-review report's scientific quality classification**

Grade A (Excellent): 0

Grade B (Very good): B, B, B

Grade C (Good): 0

Grade D (Fair): 0

Grade E (Poor): 0

**P-Reviewer:** Carlan SJ, United States; Ferraioli G, Italy; Juneja D, India

**Received:** July 18, 2023

**Peer-review started:** July 18, 2023

**First decision:** August 9, 2023

**Revised:** August 22, 2023

**Accepted:** September 19, 2023

**Article in press:** September 19, 2023

**Published online:** October 16, 2023



**Ni Chen, Hua-Jun Chen, Tao Chen, Wen Zhang, Xiao-Yun Fu, Zhou-Xiong Xing**, Department of Critical Care Medicine, The Affiliated Hospital of Zunyi Medical University, Zunyi 563000, Guizhou Province, China

**Zhou-Xiong Xing**, Department of Critical Care Medicine, Kweichow Moutai Hospital, Renhuai 564500, Guizhou Province, China

**Corresponding author:** Zhou-Xiong Xing, MD, Doctor, Department of Critical Care Medicine, The Affiliated Hospital of Zunyi Medical University, No. 149 Dalian Road, Zunyi 563000, Guizhou Province, China. [xingzhouxiong111@126.com](mailto:xingzhouxiong111@126.com)

## Abstract

### BACKGROUND

Central venous catheters (CVCs) often cause life-threatening complications, especially CVC-related bloodstream infection (CVC-BSI) and catheter-related thrombosis (CRT). Here, we report an unusual case of misplaced CVC-induced emphysematous thrombophlebitis, a rare but potentially lethal form of CRT and CVC-BSI characterized by both thrombosis and gas formation.

### CASE SUMMARY

A 48-year-old male presented to the emergency room of a local hospital with sudden-onset headache and coma for 4 h. Computed tomography (CT) revealed right basal ganglia hemorrhage, so emergency decompressive craniotomy was performed and a CVC was inserted through the right subclavian vein for fluid resuscitation during anesthesia. Two days later, the patient was transferred to the intensive care unit of our hospital for further critical care. On day 9 after CVC insertion, the patient suddenly developed fever and hypotension. Point-of-care ultrasound (POCUS) demonstrated thrombosis and dilatation of the right internal jugular vein (IJV) filled with thrombosis. Ultrasonography also revealed that the CVC tip had been misplaced into the IJV and was surrounded by gas bubbles, which manifested as hyperechoic lines with dirty shadowing and comet-tail artifacts. Further CT scan confirmed air bubbles surrounding the CVC in the right neck. The final diagnosis was septic emphysematous thrombophlebitis induced by a misplaced CVC and ensuing septic shock. The responsible CVC was removed immediately. The patient received fluid resuscitation, intravenous noradrenaline, and a 10-d ultra-broad spectrum antibiotic treatment to combat septic shock. Both CVC and peripheral venous blood cultures yielded methicillin-resistant *Staphylococcus cohnii*. The patient was gradually weaned off vasopressors and the

symptoms of redness and swelling in the right neck subsided within 7 d.

## CONCLUSION

Emphysematous thrombophlebitis is a fulminant and life-threatening CVC-BSI associated with thrombosis and gas formation in the vein. A misplaced CVC may facilitate the development of emphysematous thrombophlebitis. POCUS can easily identify the artifacts produced by gas and thrombosis, facilitating rapid diagnosis at the bedside.

**Key Words:** Emphysematous thrombophlebitis; Septic thrombophlebitis; Central venous catheter; Ultrasound; Catheter-related thrombosis; Central venous catheter-related bloodstream infection; Case report

©The Author(s) 2023. Published by Baishideng Publishing Group Inc. All rights reserved.

**Core Tip:** Central venous catheters (CVCs) often cause life-threatening complications, especially CVC-related bloodstream infection and catheter-related thrombosis. Emphysematous thrombophlebitis is a rare but life-threatening CVC-related bloodstream infection associated with thrombosis and gas formation in the vein. However, timely diagnosis remains a challenge for clinicians. Here, we report an unusual case of misplaced CVC-induced emphysematous thrombophlebitis rapidly diagnosed by point-of-care ultrasound (POCUS). POCUS revealed thrombosis surrounding the misplaced CVC in the right internal jugular vein and gas bubbles manifesting as hyperechoic lines with dirty shadowing and comet-tail artifacts. Knowledge of air-related artifacts may help physicians rapidly diagnose emphysematous thrombophlebitis.

**Citation:** Chen N, Chen HJ, Chen T, Zhang W, Fu XY, Xing ZX. Emphysematous thrombophlebitis caused by a misplaced central venous catheter: A case report. *World J Clin Cases* 2023; 11(29): 7207-7213

**URL:** <https://www.wjgnet.com/2307-8960/full/v11/i29/7207.htm>

**DOI:** <https://dx.doi.org/10.12998/wjcc.v11.i29.7207>

## INTRODUCTION

Central venous catheters (CVCs) are commonly used in anesthesiology, emergency and critical care medicine, nephrology, hematology, and oncology for delivering medications and nutrition, fluid resuscitation, hemodialysis, and measuring blood pressure in central veins[1]. However, CVCs often cause complications, especially CVC-related bloodstream infection (CVC-BSI) and catheter-related thrombosis (CRT)[2]. In fact, CVC-BSI is the most frequent hospital-acquired blood stream infection and is documented to increase the length of intensive care unit (ICU) stay, in-hospital morbidity and mortality, and therapy-related costs[3], while CRT occurs in approximately one-third of patients with indwelling CVCs and accounts for up to 50% of all deep venous thromboses in children and 10% in adults[4]. Similarly, CRT can lead to catheter stenosis and dysfunction, higher infection risk, increased care costs, and substantial morbidity and mortality[4].

Emphysematous thrombophlebitis is a very rare condition defined as septic thrombophlebitis in a vein complicated by gas formation[5]. Like emphysematous infection in other organs such as emphysematous pyelonephritis, the air bubbles in emphysematous thrombophlebitis are usually produced by the pathogenic organism *via* fermentation of glucose and lactate in infected tissues[6]. While emphysematous thrombophlebitis is rare, it is frequently fulminant and lethal. Here, we reported a rare case of misplaced CVC-related emphysematous thrombophlebitis, a unique subtype of CRT and CVC-BSI. In addition, we report for the first time the imaging features of emphysematous thrombophlebitis on point-of-care ultrasound (POCUS) to facilitate early diagnosis at the bedside.

## CASE PRESENTATION

### Chief complaints

A 48-year-old Asian male suddenly developed fever, tachycardia, and hypotension 9 d after CVC insertion. In addition, the right neck was swollen, with redness, tenderness, and warmth.

### History of present illness

The patient presented to the emergency room of a local hospital with sudden onset headache and coma for 4 h. Emergency decompressive craniotomy was performed at the local hospital, and a CVC was inserted through the right subclavian vein without ultrasound assistance for fluid resuscitation during anesthesia. Further, CVC catheter tip position was not assessed by chest X-ray after the operation. Two days later, the patient was transferred to the ICU of our tertiary teaching hospital for further critical care. Seven days after admission to ICU (9 d after CVC insertion), his right neck was severely swollen, red, warm, and sensitive to touch.

**Table 1** Laboratory values before and after right neck swelling and hypotension

Variables	Before	After	Normal range
White blood cells	$10.1 \times 10^9/L$	$13.69 \times 10^9/L$	$3.5-9.5 \times 10^9/L$
Platelets	$184 \times 10^9/L$	$244 \times 10^9/L$	$100-300 \times 10^9/L$
Alanine aminotransferase	23 U/L	82 U/L	9-50 U/L
Aspartate aminotransferase	27 U/L	179 U/L	15-40 U/L
C-reactive protein	33.3 mg/L	75.9 mg/L	0.068-8.2 mg/L
Procalcitonin	0.07 ng/mL	5.8 ng/mL	< 0.05 ng/mL
Lactate	0.6 mmol/L	3.8 mmol/L	0.5-1.7 mmol/L

### History of past illness

The patient had a 7-year history of poorly controlled hypertension and did not have diabetes.

### Personal and family history

The patient was a farmer with no history of smoking, alcohol, or drug abuse.

### Physical examination

On physical examination, the patient presented with acute fever (39 °C), hypotension (80/60 mmHg), tachycardia (140 bpm), and slightly elevated respiratory rate (22 breaths/min). These findings combined with other laboratory and imaging results indicated septic shock. In addition, CVC-BSI was suspected given the severe neck swelling and hypotension.

### Laboratory examinations

Laboratory studies prior to and after the onset of the right neck swelling and hypotension were obtained and are summarized in Table 1. After the onset of neck symptoms, blood analysis revealed leukocytosis ( $13.69 \times 10^9/L$ ) and elevated inflammatory markers including C-reactive protein (75.9 mg/L) and procalcitonin (5.8 ng/mL). In addition, alanine aminotransferase (82 U/L) and aspartate aminotransferase (179 U/L) were elevated. Alternatively, renal function parameters were normal. Arterial blood gas measures were as follows: pH, 7.30; PaCO<sub>2</sub>, 33 mmHg; PaO<sub>2</sub>, 108 mmHg; lactate, 3.8 mmol/L; HCO<sub>3</sub><sup>-</sup>, 16.8 mmol/L.

### Imaging examinations

Computed tomography scans were not obtained immediately at presentation due to the critical status of the patient. Rather, we conducted urgent POCUS using a portable machine (Mindray M9, Shenzhen, China) to assess the clinical status at the bedside, which demonstrated normal blood flow in the right internal carotid artery (Figure 1A) but thrombosis and dilatation of the right internal jugular vein (IJV) without detectable blood flow (Figure 1B). Also, ultrasonography revealed that the misplaced CVC had been placed into the IJV rather than into the ideal position of superior vena cava (SVC) through the right subclavian vein approach and was surrounded by gas bubbles, manifesting as hyperechoic lines with dirty shadowing and comet-tail artifacts (Figure 1C and D; Video 1). The patient's hypotension was improved by fluid resuscitation. A subsequent CT scan was performed afterwards on the same day and also confirmed air bubbles surrounding the CVC in the right neck (Figure 1E), and septic emphysematous thrombophlebitis induced by a misplaced CVC and septic shock was definitively diagnosed. The responsible CVC was removed immediately after paired peripheral venous blood and CVC blood sampling for aerobic and anaerobic culture to identify potential causative pathogens.

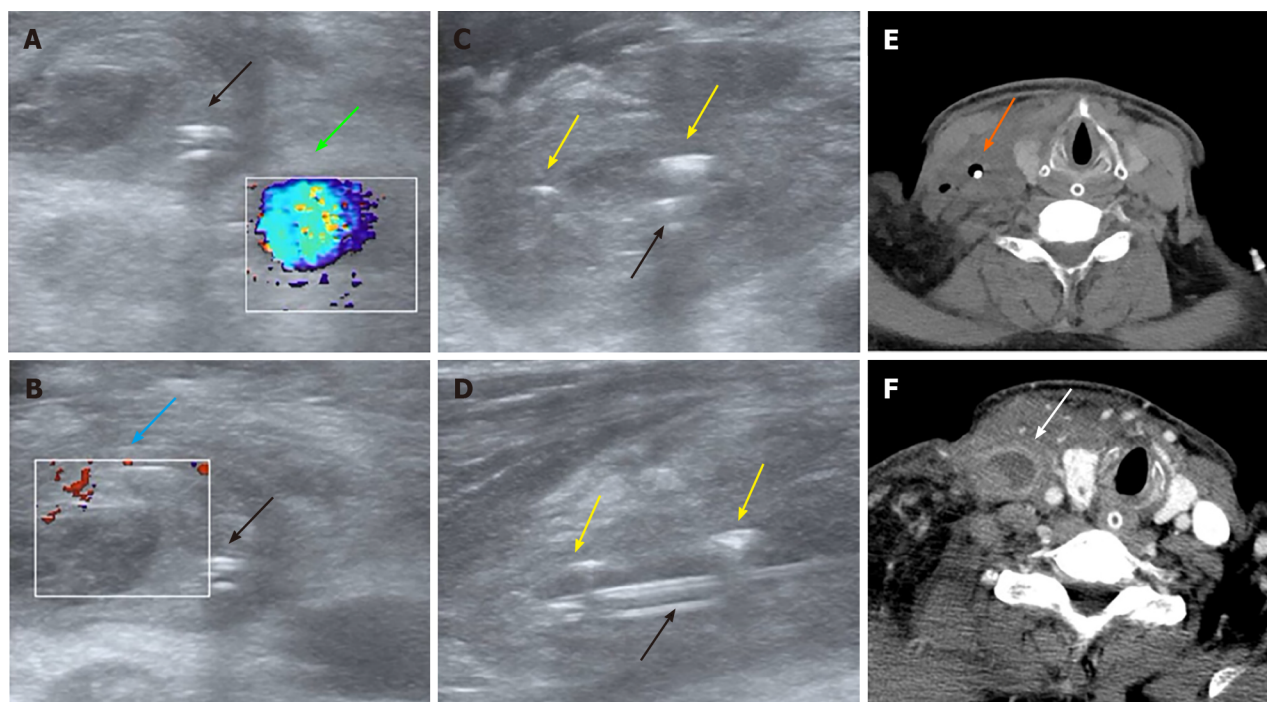
## FINAL DIAGNOSIS

Septic emphysematous thrombophlebitis induced by a misplaced CVC and septic shock was definitively diagnosed based on POCUS findings, clinical symptoms, and physical signs.

## TREATMENT

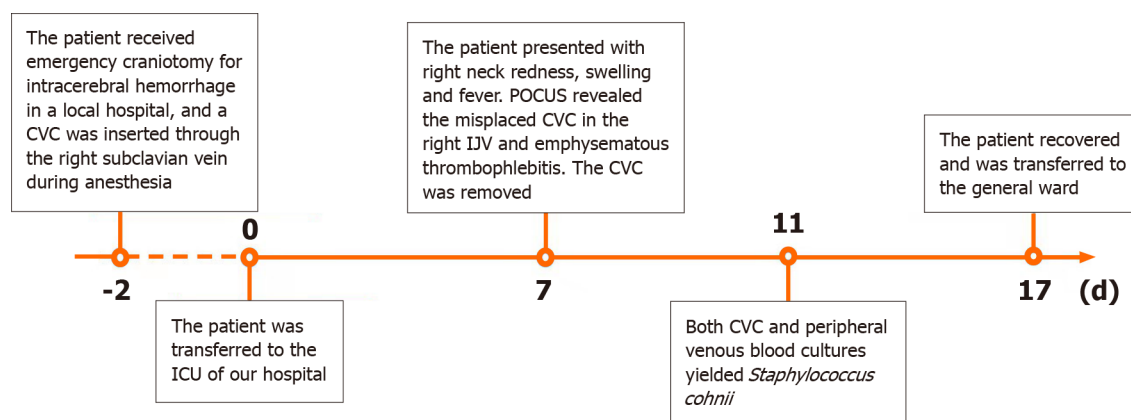
Figure 2 illustrates the clinical course of the patient. The responsible CVC was removed immediately after paired peripheral venous blood and CVC blood sampling for aerobic and anaerobic culture to identify potential causative pathogens. The patient received fluid resuscitation, intravenous noradrenaline, and a 10-d ultra-broad spectrum antibiotic treatment including intravenous vancomycin (1 g every 12 h per day) and imipenem-cilastatin (1 g every 8 h per day) to combat the CVC-BSI and septic shock. In addition, an urgent vascular surgery consultation was obtained and low-





DOI: 10.12998/wjcc.v11.i29.7207 Copyright ©The Author(s) 2023.

**Figure 1** Ultrasound and computed tomography images of emphysematous thrombophlebitis caused by a misplaced central venous catheter. A and B: Panel A and B: Color Doppler ultrasound on day 9 after central venous catheter (CVC) insertion showing normal blood flow in the right internal carotid artery (green arrow) and thrombosis in the dilated right internal jugular vein (IJV) without blood flow (blue arrow) (transverse section); C and D: Transverse section (C) and longitudinal section (D). Ultrasound on day 9 after CVC insertion showing the misplaced CVC (black arrows) and gas bubbles in the IJV manifesting as hyperechoic lines with dirty shadowing and comet-tail artifacts (yellow arrows); E: Computed tomography (CT) image on day 9 after CVC insertion showing air bubbles surrounding the misplaced CVC (orange arrow) (transverse section); F: Contrast-enhanced CT image on day 2 after CVC removal showing the swollen right IJV filled with thrombus material but no gas (white arrow) (transverse section).



DOI: 10.12998/wjcc.v11.i29.7207 Copyright ©The Author(s) 2023.

**Figure 2** Timeline of the clinical course. ICU: Intensive care unit; CVC: Central venous catheter; POCUS: Point-of-care ultrasound; IJV: Internal jugular vein.

molecular-weight heparin was administered to treat CRT. On day 2 after CVC removal, contrast-enhanced CT scan again revealed a swollen right IJV filled by a thrombus but no gas bubbles (Figure 1F). Both CVC and peripheral venous blood cultures on day 4 after CVC removal yielded methicillin-resistant *Staphylococcus cohnii* (*S. cohnii*) with differential time to positivity (DTP) of 5 h. The *S. cohnii* strain isolated by blood culture demonstrated moderate sensitivity to vancomycin (minimum inhibitory concentration of 1 mg/L). Thus, CVC-BSI caused by *S. cohnii* was finally diagnosed.

## OUTCOME AND FOLLOW-UP

The patient was gradually weaned off vasopressors and the symptoms of redness and swelling in the right neck subsided within 7 d. At this time, the patient was fully conscious but exhibited left limb weakness due to stroke and

emphysematous thrombophlebitis, and so was transferred from the ICU to a general ward for neurological rehabilitation. The patient was discharged in 8 days with full recovery. At one-month followed-up, the right IJV thrombus appeared organized and blood flow was stable. The patient and family expressed satisfaction with the medical care received from our team.

## DISCUSSION

A CVC provides convenient venous access in the ICU, saving the patient from repeated needle punctures, but long-term CVC indwelling can result in infection, including serious CVC-BSI and thrombosis (CRT). Either condition may increase the risk or severity of the other[7]. Major risk factors for CVC-BSI include CRT, longer duration of catheterization, emergency surgery, use of steroids, coexistence of infection, and mechanical ventilation[8-10]. In addition, jugular-vein or femoral-vein catheterization may carry greater risk than subclavian-vein catheterization[11]. Risk factors associated with CRT include catheter-related infection, malposition of the CVC tip, older age, longer duration of catheterization, catheter-to-vein ratio > 0.45, a greater number of insertion attempts, absence of ultrasound assistance for insertion, and no use of anticoagulants[4]. In the current case, we suggest that emphysematous thrombophlebitis may be attributed to emergency surgery, absence of anticoagulant use, insertion without ultrasound assistance, and misplacement of the CVC tip from the right subclavian vein into the IJV[4,12]. The term 'misplacement' refers to migration of the CVC tip to an improper position[13]. It is recommended that the CVC tip be positioned at the junction of the SVC and right atrium[14], a location with high blood flow to reduce the risk of thrombosis but still lying outside the atrium, thereby preventing arrhythmia [15]. In the current case, the tip of the CVC was implanted *via* subclavian vein access towards the head rather than caudally toward the junction of the SVC and right atrium. Improper positioning of the catheter tip has been reported to greatly increase the risk of CRT due to reflux of blood[4]. We speculate that the relatively slow blood flow in the IJV and reflux of blood across the distal tip of the misplaced CVC resulted in CRT.

Emphysematous thrombophlebitis may manifest with clinical symptoms and physical signs similar to other CRT and CVC-BSI types. In this case, the patient presented with common symptoms of CVC-BSI including fever, septic shock, bacteremia, and leukocytosis[16]. While most patients with CRT are asymptomatic, the reported case exhibited localized swelling in the neck which may be attributed to IJV stenosis[4]. In addition, emphysematous thrombophlebitis with gas formation produced by pathogenic bacteria may lead to more severe sepsis-associated symptoms than common CVC-BSI without gas, such as circulatory shock as reported in this case. The most common causative pathogen for CVC-BSI is *Staphylococcus*[3], and indeed this Gram-positive bacteria was isolated from blood samples of the reported case. Other pathogens such as *Klebsiella pneumoniae* and *E. coli* may also cause similar clinical manifestations due to gas production.

Treatment of emphysematous thrombophlebitis is presently empirical and largely focused on managing CVC-BSI or CRT as there are few published reports on this specific condition. As shown in this case, CVC-BSI is diagnosed based on quantitative blood cultures from a catheter hub and another peripheral vein and by a DTP  $\geq 2$  h[17-19]. Duplex ultrasound plays a key role in the initial diagnosis of CRT by highlighting the absence of blood flow in the thrombotic vein[20,21]. POCUS has revolutionized the diagnosis and management of critical illnesses, especially lesions associated with gas bubbles[22]. Due to an inherent impedance mismatch with other human tissues, air has characteristic manifestations on ultrasound, including irregular hyperechoic structures, "dirty shadowing", and A-lines that impede visualization of deeper structures[22]. These gas bubbles are easily detected by POCUS[23]. In the reported case, the comet-tail artifacts and dirty shadowing on POCUS facilitated rapid diagnosis of emphysematous thrombophlebitis and so may have contributed to favorable clinical outcome after antibiotic treatment, fluid resuscitation, rapid removal of the catheter, and anticoagulant administration.

## CONCLUSION

Emphysematous thrombophlebitis is a fulminant and life-threatening CVC-BSI with hallmark signs of thrombosis and gas formation in the vein. POCUS can easily identify the artifacts produced by gas and thrombosis, facilitating rapid diagnosis at the bedside. Emergency and critical care professionals should consider this CVC-BSI type in differential diagnosis, especially in cases with a misplaced CVC, and recognize the value of POCUS for early diagnosis of emphysematous thrombophlebitis. Last, this case highlights the value of radiographic guidance for ensuring proper CVC tip location and thus preventing complications such as thrombosis.

## ACKNOWLEDGEMENTS

We would like to acknowledge the patient and his family.

## FOOTNOTES

**Author contributions:** Chen N reviewed the literature, and contributed to manuscript drafting; Chen HJ and Zhang W summarized the clinical features and drafted the manuscript; Chen T and Fu XY helped draft the manuscript and review the literature; Xing ZX helped

review the literature, performed the bedside ultrasound and made important contributions to the manuscript; all authors have approved the final version of the manuscript.

**Supported by** Foundation of Guizhou Science and Technology Department, No. QIANKEHEZHICHEN[2022]YIBAN179; Foundation of Kweichow Moutai Hospital, No. MTyk2022-12; Foundation of Department of Health of Guizhou Province, No. gzwkj2021-036; and Guizhou Education Department, No. QIANJIAOHEKYZI[2018]239.

**Informed consent statement:** Informed written consent was obtained from the patient's son for publication of this report and any accompanying images.

**Conflict-of-interest statement:** All the authors report no relevant conflicts of interest for this article.

**CARE Checklist (2016) statement:** The authors have read CARE Checklist (2016), and the manuscript was prepared and revised according to CARE Checklist (2016).

**Open-Access:** This article is an open-access article that was selected by an in-house editor and fully peer-reviewed by external reviewers. It is distributed in accordance with the Creative Commons Attribution NonCommercial (CC BY-NC 4.0) license, which permits others to distribute, remix, adapt, build upon this work non-commercially, and license their derivative works on different terms, provided the original work is properly cited and the use is non-commercial. See: <https://creativecommons.org/licenses/by-nc/4.0/>

**Country/Territory of origin:** China

**ORCID number:** Ni Chen 0000-0002-6061-6582; Hua-Jun Chen 0000-0001-9728-5804; Tao Chen 0000-0001-5956-4407; Wen Zhang 0000-0002-2668-1882; Xiao-Yun Fu 0000-0003-1727-449X; Zhou-Xiong Xing 0000-0003-1678-3241.

**S-Editor:** Yan JP

**L-Editor:** A

**P-Editor:** Yan JP

## REFERENCES

- Geerts W. Central venous catheter-related thrombosis. *Hematology Am Soc Hematol Educ Program* 2014; **2014**: 306-311 [PMID: 25696870 DOI: 10.1182/asheducation-2014.1.306]
- Fahy B, Sockrider M. Central Venous Catheter. *Am J Respir Crit Care Med* 2019; **199**: P21-P22 [PMID: 31149851 DOI: 10.1164/rccm.19911P21]
- Hebeisen UP, Atkinson A, Marschall J, Buetti N. Catheter-related bloodstream infections with coagulase-negative staphylococci: are antibiotics necessary if the catheter is removed? *Antimicrob Resist Infect Control* 2019; **8**: 21 [PMID: 30719282 DOI: 10.1186/s13756-019-0474-x]
- Citla Sridhar D, Abou-Ismael MY, Ahuja SP. Central venous catheter-related thrombosis in children and adults. *Thromb Res* 2020; **187**: 103-112 [PMID: 31981840 DOI: 10.1016/j.thromres.2020.01.017]
- Khor T, Anderson J, McRae P. Central venous thrombophlebitis diagnosed by computerized tomography scanning. *Aust N Z J Surg* 1992; **62**: 820-822 [PMID: 1445066 DOI: 10.1111/j.1445-2197.1992.tb06928.x]
- Ubee SS, McGlynn L, Fordham M. Emphysematous pyelonephritis. *BJU Int* 2011; **107**: 1474-1478 [PMID: 20840327 DOI: 10.1111/j.1464-410X.2010.09660.x]
- Buetti N, Timsit JF. Management and Prevention of Central Venous Catheter-Related Infections in the ICU. *Semin Respir Crit Care Med* 2019; **40**: 508-523 [PMID: 31585477 DOI: 10.1055/s-0039-1693705]
- Pawar M, Mehta Y, Kapoor P, Sharma J, Gupta A, Trehan N. Central venous catheter-related blood stream infections: incidence, risk factors, outcome, and associated pathogens. *J Cardiothorac Vasc Anesth* 2004; **18**: 304-308 [PMID: 15232809 DOI: 10.1053/j.jvca.2004.03.009]
- Dedunska K, Dyk D. Prevention of central venous catheter-associated bloodstream infections: A questionnaire evaluating the knowledge of the selected 11 evidence-based guidelines by Polish nurses. *Am J Infect Control* 2015; **43**: 1368-1371 [PMID: 26307045 DOI: 10.1016/j.ajic.2015.07.022]
- Septimus EJ, Moody J. Prevention of Device-Related Healthcare-Associated Infections. *F1000Res* 2016; **5** [PMID: 26918162 DOI: 10.12688/f1000research.7493.1]
- Parienti JJ, Mongardon N, Mégarbane B, Mira JP, Kalfon P, Gros A, Marqué S, Thuong M, Pottier V, Ramakers M, Savary B, Seguin A, Valette X, Terzi N, Sauneuf B, Cattoir V, Mermel LA, du Cheyron D; 3SITES Study Group. Intravascular Complications of Central Venous Catheterization by Insertion Site. *N Engl J Med* 2015; **373**: 1220-1229 [PMID: 26398070 DOI: 10.1056/NEJMoa1500964]
- Saugel B, Scheeren TWL, Teboul JL. Ultrasound-guided central venous catheter placement: a structured review and recommendations for clinical practice. *Crit Care* 2017; **21**: 225 [PMID: 28844205 DOI: 10.1186/s13054-017-1814-y]
- Gibson F, Bodenham A. Misplaced central venous catheters: applied anatomy and practical management. *Br J Anaesth* 2013; **110**: 333-346 [PMID: 23384735 DOI: 10.1093/bja/aes497]
- Şahinkaya HH, Parlak M, Tekgul ZT. Assessment of the Tip Position of Central Venous Catheters Inserted Using Peres' Height Formula. *Cureus* 2022; **14**: e31988 [PMID: 36589175 DOI: 10.7759/cureus.31988]
- Bannon MP, Heller SF, Rivera M. Anatomic considerations for central venous cannulation. *Risk Manag Healthc Policy* 2011; **4**: 27-39 [PMID: 22312225 DOI: 10.2147/RMHP.S10383]
- Hanna H, Afif C, Alakech B, Boktour M, Tarrand J, Hachem R, Raad I. Central venous catheter-related bacteremia due to gram-negative bacilli: significance of catheter removal in preventing relapse. *Infect Control Hosp Epidemiol* 2004; **25**: 646-649 [PMID: 15357155 DOI: 10.1086/502455]

- 17 **Mermel LA**, Allon M, Bouza E, Craven DE, Flynn P, O'Grady NP, Raad II, Rijnders BJ, Sherertz RJ, Warren DK. Clinical practice guidelines for the diagnosis and management of intravascular catheter-related infection: 2009 Update by the Infectious Diseases Society of America. *Clin Infect Dis* 2009; **49**: 1-45 [PMID: [19489710](#) DOI: [10.1086/599376](#)]
- 18 **Orihuela-Martín J**, Rodríguez-Núñez O, Morata L, Cardozo C, Puerta-Alcalde P, Hernández-Meneses M, Ambrosioni J, Linares L, Bodro M, de Los Angeles Guerrero-León M, Del Río A, García-Vidal C, Almela M, Pitart C, Marco F, Soriano A, Martínez JA. Performance of differential time to positivity as a routine diagnostic test for catheter-related bloodstream infections: a single-centre experience. *Clin Microbiol Infect* 2020; **26**: 383.e1-383.e7 [PMID: [31288101](#) DOI: [10.1016/j.cmi.2019.07.001](#)]
- 19 **Javeri Y**, Jagathkar G, Dixit S, Chaudhary D, Zirpe KG, Mehta Y, Govil D, Mishra RC, Samavedam S, Pandit RA, Savio RD, Clerk AM, Srinivasan S, Juneja D, Ray S, Sahoo TK, Jakkinaboina S, Jampala N, Jain R. Indian Society of Critical Care Medicine Position Statement for Central Venous Catheterization and Management 2020. *Indian J Crit Care Med* 2020; **24**: S6-S30 [PMID: [32205954](#) DOI: [10.5005/jp-journals-10071-G23183](#)]
- 20 **Bhagra A**, Tierney DM, Sekiguchi H, Soni NJ. Point-of-Care Ultrasonography for Primary Care Physicians and General Internists. *Mayo Clin Proc* 2016; **91**: 1811-1827 [PMID: [27825617](#) DOI: [10.1016/j.mayocp.2016.08.023](#)]
- 21 **Huang Z**, Chen H, Liu Z. The 100 top-cited systematic reviews/meta-analyses in central venous catheter research: A PRISMA-compliant systematic literature review and bibliometric analysis. *Intensive Crit Care Nurs* 2020; **57**: 102803 [PMID: [32035805](#) DOI: [10.1016/j.iccn.2020.102803](#)]
- 22 **Buttar S**, Cooper D Jr, Olivieri P, Barca M, Drake AB, Ku M, Rose G, Siadecki SD, Saul T. Air and its Sonographic Appearance: Understanding the Artifacts. *J Emerg Med* 2017; **53**: 241-247 [PMID: [28372830](#) DOI: [10.1016/j.jemermed.2017.01.054](#)]
- 23 **Shabana W**, Bude RO, Rubin JM. Comparison between color Doppler twinkling artifact and acoustic shadowing for renal calculus detection: an *in vitro* study. *Ultrasound Med Biol* 2009; **35**: 339-350 [PMID: [19041171](#) DOI: [10.1016/j.ultrasmedbio.2008.09.023](#)]



Published by **Baishideng Publishing Group Inc**  
7041 Koll Center Parkway, Suite 160, Pleasanton, CA 94566, USA

**Telephone:** +1-925-3991568

**E-mail:** [bpgoffice@wjgnet.com](mailto:bpgoffice@wjgnet.com)

**Help Desk:** <https://www.f6publishing.com/helpdesk>

<https://www.wjgnet.com>

