

Artificial Intelligence in *Gastroenterology*

Artif Intell Gastroenterol 2023 December 8; 4(3): 48-71





Artificial Intelligence in Gastroenterology

Contents

Quarterly Volume 4 Number 3 December 8, 2023

REVIEW

- 48 Role of artificial intelligence in the characterization of indeterminate pancreatic head mass and its usefulness in preoperative diagnosis

Rawlani P, Ghosh NK, Kumar A

SYSTEMATIC REVIEWS

- 64 Use of artificial intelligence in total mesorectal excision in rectal cancer surgery: State of the art and perspectives

Mosca V, Fuschillo G, Sciaudone G, Sahnan K, Selvaggi F, Pellino G

Contents

Artificial Intelligence in Gastroenterology

Quarterly Volume 4 Number 3 December 8, 2023

ABOUT COVER

Editorial Board Member of *Artificial Intelligence in Gastroenterology*, Tsung-Hsueh Lu, MD, PhD, Professor, Department of Public Health, College of Medicine, National Cheng Kung University, Tainan 701, Taiwan. robertlu@mail.ncku.edu.tw

AIMS AND SCOPE

The primary aim of *Artificial Intelligence in Gastroenterology* (AIG, *Artif Intell Gastroenterol*) is to provide scholars and readers from various fields of artificial intelligence in gastroenterology with a platform to publish high-quality basic and clinical research articles and communicate their research findings online.

AIG mainly publishes articles reporting research results obtained in the field of artificial intelligence in gastroenterology and covering a wide range of topics, including artificial intelligence in gastrointestinal cancer, liver cancer, pancreatic cancer, hepatitis B, hepatitis C, nonalcoholic fatty liver disease, inflammatory bowel disease, irritable bowel syndrome, and *Helicobacter pylori* infection.

INDEXING/ABSTRACTING

The AIG is now abstracted and indexed in Reference Citation Analysis, China Science and Technology Journal Database.

RESPONSIBLE EDITORS FOR THIS ISSUE

Production Editor: Si Zhao; Production Department Director: Xu Guo; Editorial Office Director: Jin-Lei Wang.

NAME OF JOURNAL

Artificial Intelligence in Gastroenterology

ISSN

ISSN 2644-3236 (online)

LAUNCH DATE

July 28, 2020

FREQUENCY

Quarterly

EDITORS-IN-CHIEF

Rajvinder Singh, Ferruccio Bonino

EDITORIAL BOARD MEMBERS

<https://www.wjgnet.com/2644-3236/editorialboard.htm>

PUBLICATION DATE

December 8, 2023

COPYRIGHT

© 2023 Baishideng Publishing Group Inc

INSTRUCTIONS TO AUTHORS

<https://www.wjgnet.com/bpg/gerinfo/204>

GUIDELINES FOR ETHICS DOCUMENTS

<https://www.wjgnet.com/bpg/GerInfo/287>

GUIDELINES FOR NON-NATIVE SPEAKERS OF ENGLISH

<https://www.wjgnet.com/bpg/gerinfo/240>

PUBLICATION ETHICS

<https://www.wjgnet.com/bpg/GerInfo/288>

PUBLICATION MISCONDUCT

<https://www.wjgnet.com/bpg/gerinfo/208>

ARTICLE PROCESSING CHARGE

<https://www.wjgnet.com/bpg/gerinfo/242>

STEPS FOR SUBMITTING MANUSCRIPTS

<https://www.wjgnet.com/bpg/GerInfo/239>

ONLINE SUBMISSION

<https://www.f6publishing.com>

© 2023 Baishideng Publishing Group Inc. All rights reserved. 7041 Koll Center Parkway, Suite 160, Pleasanton, CA 94566, USA

E-mail: bpgoffice@wjgnet.com <https://www.wjgnet.com>

Role of artificial intelligence in the characterization of indeterminate pancreatic head mass and its usefulness in preoperative diagnosis

Palash Rawlani, Nalini Kanta Ghosh, Ashok Kumar

Specialty type: Gastroenterology and hepatology

Provenance and peer review: Invited article; Externally peer reviewed.

Peer-review model: Single blind

Peer-review report's scientific quality classification

Grade A (Excellent): 0
Grade B (Very good): 0
Grade C (Good): C, C
Grade D (Fair): 0
Grade E (Poor): 0

P-Reviewer: Cabezuelo AS, Spain

Received: July 27, 2023

Peer-review started: July 27, 2023

First decision: August 31, 2023

Revised: September 11, 2023

Accepted: October 8, 2023

Article in press: October 8, 2023

Published online: December 8, 2023



Palash Rawlani, Nalini Kanta Ghosh, Ashok Kumar, Department of Surgical Gastroenterology, Sanjay Gandhi Post Graduate Institute of Medical Sciences, Lucknow 226014, Uttar Pradesh, India

Corresponding author: Ashok Kumar, BSc, FASCRS, FRCS, FRCS (Ed), FRCS (Hon), MBBS, MCh, MS, Professor, Department of Surgical Gastroenterology, Sanjay Gandhi Post Graduate Institute of Medical Sciences, Raebareli Road, Lucknow 226014, Uttar Pradesh, India.
doc.ashokgupta@gmail.com

Abstract

Artificial intelligence (AI) has been used in various fields of day-to-day life and its role in medicine is immense. Understanding of oncology has been improved with the introduction of AI which helps in diagnosis, treatment planning, management, prognosis, and follow-up. It also helps to identify high-risk groups who can be subjected to timely screening for early detection of malignant conditions. It is more important in pancreatic cancer as it is one of the major causes of cancer-related deaths worldwide and there are no specific early features (clinical and radiological) for diagnosis. With improvement in imaging modalities (computed tomography, magnetic resonance imaging, endoscopic ultrasound), most often clinicians were being challenged with lesions that were difficult to diagnose with human competence. AI has been used in various other branches of medicine to differentiate such indeterminate lesions including the thyroid gland, breast, lungs, liver, adrenal gland, kidney, etc. In the case of pancreatic cancer, the role of AI has been explored and is still ongoing. This review article will focus on how AI can be used to diagnose pancreatic cancer early or differentiate it from benign pancreatic lesions, therefore, management can be planned at an earlier stage.

Key Words: Artificial intelligence; Indeterminate pancreatic lesion; Imaging; Biomarkers; Diagnosis

©The Author(s) 2023. Published by Baishideng Publishing Group Inc. All rights reserved.

Core Tip: Surgical management of a pancreatic head lesion usually requires pancreaticoduodenectomy, which is associated with significant morbidity and mortality. For a benign lesion it is unacceptable. The investigation modalities *i.e.* computed tomography, magnetic resonance imaging, endoscopic ultrasound, positron emission tomography, and biochemical markers are available today to distinguish benign from malignant lesions and have their limitations (human judgmental errors). The application of artificial intelligence (AI) algorithms can minimize human errors and improve the sensitivity and specificity of diagnostic yield. The AI can help with great precision in differentiating benign from malignant lesions, affecting the management strategy and minimizing post-operative complications.

Citation: Rawlani P, Ghosh NK, Kumar A. Role of artificial intelligence in the characterization of indeterminate pancreatic head mass and its usefulness in preoperative diagnosis. *Artif Intell Gastroenterol* 2023; 4(3): 48-63

URL: <https://www.wjgnet.com/2644-3236/full/v4/i3/48.htm>

DOI: <https://dx.doi.org/10.35712/aig.v4.i3.48>

INTRODUCTION

The concept of a machine that can think like a human being was proposed by Mr. Alan Turing in the year 1950 in his book entitled "Computing Machinery and Intelligence" and later, the term "artificial intelligence (AI)" was coined by John McCarthy[1,2]. The applicability of AI ranges from simple tasks to more complex tasks mimicking a human brain. There are six major sub-fields of AI: machine learning (ML), neural network, deep learning (DL), natural language processing (NLP), cognitive computing, and computer vision. ML can learn from data, recognize typical patterns, and make decisions with little or no human interference. A neural network is the field of AI that is inspired by the human brain, where a set of algorithms is used to derive a correlation. Most of the AI models in the medical field use ML and neural networks. NLP is a method where textual data has been used to search, analyze, and comprehend complex information. Computer vision understands visual inputs (radiological or pathological images, surgical videos) and derives desired information. There are many modifications of conventional sub-fields of AI which have been in use. The twentieth century has seen that AI has become an essential part of day-to-day life, including health tracking devices[3], automobiles[4], banking and finances (robo-traders)[5], surveillance, social media, entertainment, education, space exploration, and disaster management, *etc*[6,7].

AI has been used in various fields of medicine including online appointments and hospital check-ins, medical records digitalization, follow-up, drug dosage reminders, adverse effect warnings, *etc*. Moreover, its application in the field of oncology is paramount. AI can be useful in cancer detection, screening, diagnosis, classification, prognostication, new drug discovery, *etc*[8-11]. It has played its role in differentiating various indeterminate lesions in the thyroid gland[12, 13], breast[14], lungs[15,16], liver[17], adrenal[18,19], kidneys[20], and indeterminate biliary strictures[21] (Table 1). Various authors have studied the role of AI algorithms to identify pancreatic lesions from imaging modalities computed tomography (CT), magnetic resonance imaging (MRI), endoscopic ultrasonography (EUS), positron emission tomography (PET) scan, *etc* and thus can differentiate malignant indeterminate pancreatic lesions (IPLs) from benign ones for better management at an early stage.

IPLs are those detected by imaging techniques performed for non-specific abdominal complaints or detected incidentally, otherwise known as pancreatic incidentaloma. With the increase in imaging modalities, the detection of such IPLs has increased[22]. These incidentalomas are mostly detected in other organs, *i.e.* the thyroid gland, pituitary gland, kidney, lungs, adrenal gland, *etc*. Though, the incidence of indeterminate lesions is less in the pancreas, however, most of them are malignant compared to other sites[23]. Identification of such lesions creates confusion in clinicians and anxiety among the patients. Moreover, early diagnosis of malignancy can provide reasonably early management and better overall outcomes. Therefore, it is necessary to diagnose such lesions for better patient management.

The overall prevalence of such lesions was reported to be 0.01%–0.6% in 2009, which may be less compared to its true incidence[24]. A review of a series of pancreatic resections shows an asymptomatic neoplastic lesion to be 6%–23% (24% to 50% of them are malignant, and 24% to 47% are considered potentially malignant or pre-malignant)[25,26]. A recently published Leopard-2 trial comparing laparoscopic and open pancreaticoduodenectomy has shown the incidence of benign or pre-malignant lesions to be 12%[27]. Frequently, cystic lesions of the pancreas are detected on MRI and their incidence is up to 20%[28] and recent series shows the incidence to be 49% in the general population[29]. The majority of cystic lesions are benign, however, approximately, 3% are malignant or potentially malignant[30].

The etiology of such lesions is diverse, benign adenoma to adenocarcinoma, borderline malignant tumors, mesenchymal tumors, neuroendocrine tumors, cysts, congenital changes, metastatic lesions, inflammatory masses *etc*[23]. These lesions may be broadly divided into benign, pre-malignant, or malignant lesions[24]. Figure 1 shows different pathologies of IPLs[31].

There is a considerable overlap of imaging features of different benign and malignant pancreatic lesions. Cystic degeneration of solid tumors may masquerade as cystic lesions. Various modalities (ultrasonography, contrast-enhanced CT, MRI, EUS, PET, cytopathology, histopathology, and tumor markers) have been used to differentiate the possible etiology, however, there are limitations of each modality intrinsic to the investigation itself or on the operator. Recently, AI has been used to distinguish various indeterminate lesions in the breast, lungs, adrenal gland, kidney, *etc*. Thus, the use of AI in association with conventional imaging or diagnostic modalities can improve their overall diagnostic yield

Table 1 Studies on differentiation of indeterminate lesions using artificial intelligence

No.	Ref.	Number of patients	Organ of interest	Sub-type of AI	Outcome
1	Ippolito <i>et al</i> [12], 2004	453	Thyroid nodule (benign <i>vs</i> malignant)	ANN	Refinement of risk stratification of FNAB and clinical data
2	Daniels <i>et al</i> [13], 2020	121	Indeterminant thyroid nodule	ML	ML and ultrasonography can identify genetically high risk lesions
3	Becker <i>et al</i> [14], 2018	632	Breast lesion (benign <i>vs</i> malignant)	Generic DLS	Aids diagnosing cancer on breast ultrasound images with an accuracy comparable to radiologists
4	Scott <i>et al</i> [15], 2019	125	Lung GGO (benign <i>vs</i> malignant)	ANN	Improve diagnostic ability using CT scan, PET, and clinical data
5	Guo <i>et al</i> [16], 2022	20	Indeterminant small lung lesions	DNN	DNN based method may detect small lesions < 10 mm at an effective radiation dose < 0.1 mSv.
6	Yasaka <i>et al</i> [17], 2018	460	Liver mass (HCC <i>vs</i> others)	CNN	High diagnostic performance in differentiation of liver masses using dynamic CT
7	Moawad <i>et al</i> [18], 2021	40	Adrenal incidentaloma (benign <i>vs</i> malignant)	ML	Machine learning and CT texture analysis can differentiate between benign and malignant indeterminate adrenal tumors
8	Stanzione <i>et al</i> [19], 2021	55	Indeterminant solid adrenal lesions	ML	MRI handcrafted radiomics and ML can be used to different adrenal incidentalomas
9	Massa'a <i>et al</i> [20], 2022	160	Indeterminant solid renal mass (benign <i>vs</i> malignant)	ML	MRI-based radiomics and ML can be useful in differentiation
10	Saraiva <i>et al</i> [21], 2022	85	Indeterminant biliary strictures	CNN	CNN can accurately differentiate benign strictures from malignant ones

AI: Artificial intelligence; ANN: Artificial neural network; CNN: Convolutional neural network; CT: Computed tomography; DNN: Deep neural network; DLS: Deep learning software; FNAB: Fine needle aspiration biopsy; GGO: Ground glass opacities; HCC: Hepatocellular carcinoma; ML: Machine learning; MRI: Magnetic resonance imaging.

and therefore, more precise diagnosis and patient care.

This paper reviews the current status of AI in the differentiation of various IPLs and its future implications.

METHODS AND LITERATURE SEARCH

All the relevant articles were searched from PubMed and Google Scholar using the keywords, *i.e.* “artificial intelligence” AND “pancreatic lesions” OR “cystic lesions”, OR “CT”, OR “MRI”, OR “EUS”, OR “PET” OR “pathology”, OR “biomarkers” between 2005 and 2023, and only full articles were studied. Articles discussing the differentiation of different types of pancreatic lesions were included and screened by all authors. Abstracts and conference presentations were excluded. Studies discussing the differentiation of any pancreatic lesion (benign *vs.* malignant) were included in relevant sections for discussion. The study flow chart is shown in Figure 2.

Role of clinical parameters and AI on the identification of IPLs

Pancreatic cancer is one of the leading causes of cancer-related death worldwide, thus early diagnosis is crucial for better management. Often, patients are asymptomatic to start with, so presentation is delayed leading to advanced disease at diagnosis. This delay in diagnosis can be minimized by the identification of high-risk groups and the introduction of targeted screening of high-risk populations. Any lesion identified in these patient groups can be subjected to further evaluation using an AI augmented imaging system (CT, MRI, PET, EUS), which will be discussed later. The proposed schema of patient evaluation and management is presented in Figure 3.

Several clinical parameters can be used to predict the future incidence of pancreatic cancer including, symptoms, hereditary factors (BRCA1, BRCA2, PALB2, Hereditary pancreatitis, and Peutz-Jeghers Syndrome), pre-existing clinical conditions (new-onset diabetes mellitus), lifestyle (smoking, alcohol, obesity, nutrient-poor diet), and demographic factors. Elevation of CA 19-9, CEA, and recently developed CEMIP (cell migration-inducing hyaluronan binding protein) can be considered as an early indicator of pancreatic cancer[32-34]. None of these parameters can confirm pancreatic cancer, however, a combined assessment can suggest a possible pancreatic cancer leading to screening of high-risk populations. In a retrospective study from Kaiser Permanente Southern California, an algorithm for risk stratification for pancreatic cancer was generated using imaging (CT/magnetic resonance) and clinical factors[35]. In this study, imaging features used were pancreatic duct dilatation as a predictor of malignancy and other features such as atrophy, calcification, pancreatic cyst, and irregular pancreatic duct. Multi-state prediction model showed a discriminatory index (c-index: 0.825–0.833) between normal individuals and individuals with pancreatic cancer. A study at the Biomedical

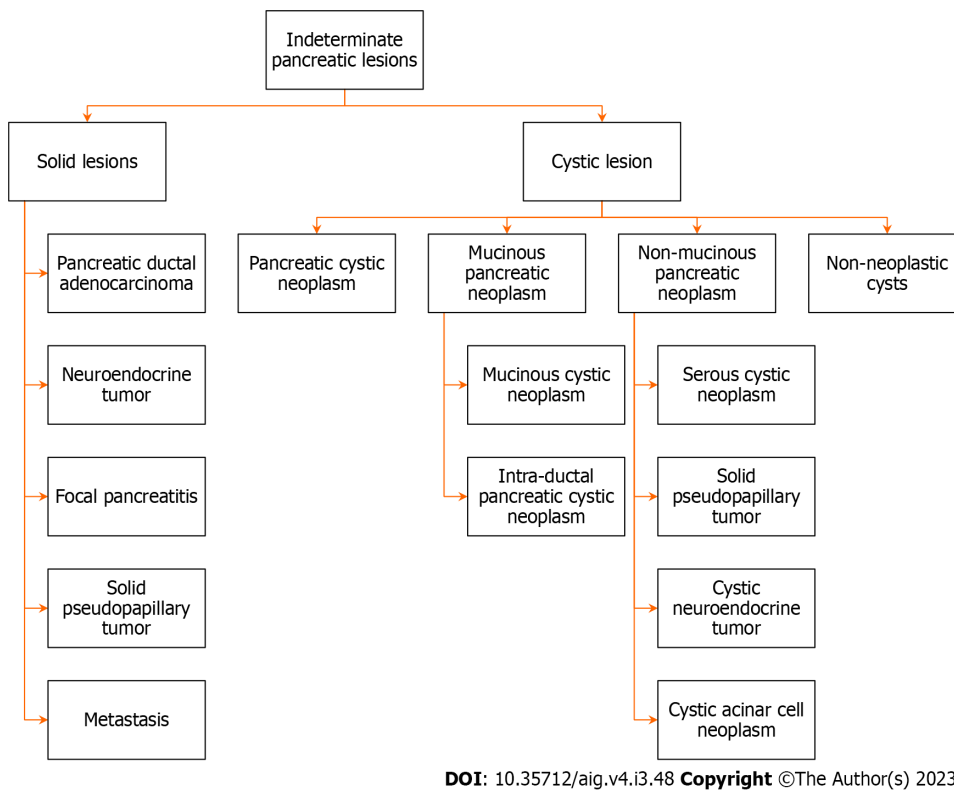


Figure 1 Pathology of different indeterminate pancreatic lesions.

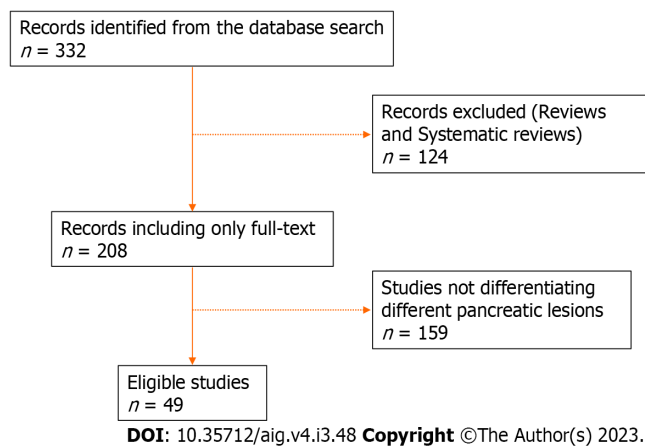


Figure 2 Study flow chart.

Imaging Research Institute of Cedars Sinai Medical Center, Los Angeles used ML and CT-based radiomic features as an indicator of pancreatic ductal adenocarcinoma (PDAC)[36]. The scans were obtained in non-pancreatic cancer patients for different purposes, who later developed pancreatic cancer after 6 mo to 3 years. The AI model had an accuracy of 86% in the prediction of PDAC. As CT scans were performed frequently for different purposes, such AI models can identify patients having potential risk for future pancreatic malignancy.

Muhammad *et al*[37], Placido *et al*[38], and Chen *et al*[39] used demographic and clinical parameters with artificial neural networks (ANNs) algorithms to predict pancreatic cancer. In the validation arm, the area under the curve (AUC) was 0.85, and the sensitivity and specificity of diagnosis were 80.7%. Malhotra *et al*[40] used ML principles to identify symptoms to predict pancreatic cancer. Their algorithm could detect 41.3% of patients with pancreatic cancer < 60 years of age, 20 mo earlier than diagnosis (AUC: 0.66), and 43.2% of patients with pancreatic cancer > 60 years of age, 17 mo earlier than diagnosis (AUC: 0.61). Appelbaum *et al*[41] used neural network algorithms to identify high-risk groups 1 year in advance. Thus, these AI techniques not only help to detect pancreatic cancer but also, earlier than conventional imaging.

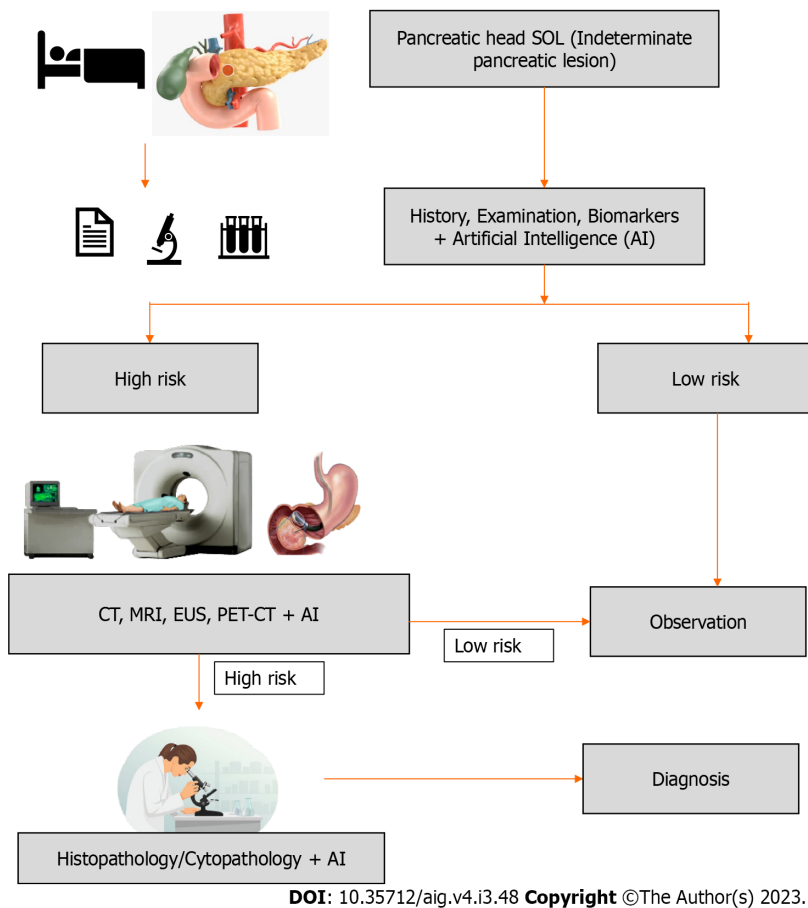


Figure 3 Schematic presentation of diagnosis of indeterminate pancreatic lesion using artificial intelligence. AI: Artificial intelligence; CT: Computed tomography; EUS: Endoscopic ultrasonography; MRI: Magnetic resonance imaging; PET: Positron emission tomography; SOL: Space occupying lesion.

Role of AI on CT scan imaging on detection of pancreatic lesions

If a mass lesion is detected in the pancreas, the possibility of neoplasm is kept as a differential diagnosis. The most common (85%–95%) among the lesions is pancreatic ductal adenocarcinoma (PDAC) and it has a poor prognosis[42,43]. Ill-defined hypovascular mass is the characteristic of PDAC in contrast-enhanced imaging[44]. Atypical imaging of a solid mass may harbor a malignancy, however, its mimic, an inflammatory mass, can have a better prognosis than PDAC, and management of both these conditions is different.

Among all the imaging modalities, CT is most commonly favored for the investigation of a pancreatic lesion, as it is widely available, quick to acquire, has a high spatial resolution, assesses relationship to vascular structures, and determines surgical planning. Recent advances in CT imaging in the form of multiplanar reformatted images, and three-dimensional (3D) techniques have improved sensitivity by up to 96% in tumor identification[45,46]. However, small tumors or tumors with atypical features may not be visible on CT scans or subtle changes may not be appreciable to the human eye and prone to errors. These limitations of conventional CT imaging can be overcome by the use of AI algorithms.

Differentiation of PDAC

Among all malignancies, PDAC has the worst overall survival[47]. It is because patients present late at an advanced stage due to late detection of asymptomatic subtle pancreatic lesions on imaging[40]. Zhu *et al*[48] and Liu *et al*[49] have used DL to detect pancreatic cancer and in the study by Liu *et al*[49], malignancy could be detected in just 3 s with an AUC of 0.96. Chu *et al*[50] could diagnose PDAC with an AUC of 99.9% using ML algorithms.

Differentiation of cystic lesions

With the increase in the frequency of cross-sectional imaging, the detection of cystic lesions of the pancreas has increased and it is aptly called “technopathies”. Management of these cystic lesions requires classification of the type of lesion and the risk of malignancy which is sub-optimal with present imaging modalities[51,52]. AI has been used to differentiate the types of cystic lesions into, intraductal papillary mucinous neoplasm (IPMN), mucinous cystic neoplasm (MCN), serous cystic neoplasia (SCN), solid pseudopapillary neoplasia, *etc*[53,54]. Dmitriev *et al*[53] used the convolutional neural network (CNN) model (contrast-enhanced CT and clinical data) to differentiate the types of cystic lesions with an accuracy of 84% which is better than radiologists which has an accuracy of less than 70%[53,55]. However, Li *et al*[54] used only CT images and AI (DL) to differentiate the cystic lesions with an accuracy of 73% compared to radiologists in

their study which had an accuracy of only 48%. Differentiation of SCN from other cystic lesions is important as they have a rare chance of being malignant, thus, Wei *et al*[56] used an ML-based algorithm to distinguish SCN from others based on CT images. Yang *et al*[57] and Chen *et al*[58] have used AI algorithms to distinguish SCN from MCN. Chakraborty *et al*[59] and Polk *et al*[60] used the RF model to differentiate low-grade IPMN from high-grade IPMN which has management implications. Table 2 summarizes studies on the uses of AI along with CT images in the differentiation of pancreatic lesions.

Role of AI on MRI on the detection of pancreatic lesions

MRI is favored over CT scan due to superior soft tissue delineation and it also helps to detect small lesions, assessment of the vascular relationship, and relationship to the pancreatic duct, lymph node, or distant metastasis[43,61]. Detection of iso-attenuating pancreatic lesions on CT scan is challenging which is observed in approximately 10% of patients. In these situations, indirect evidence of malignancy is used for diagnosis, *i.e.* convex pancreatic contour, double duct sign, vascular involvement, mass effect, *etc*[42]. However, MRI can be helpful to diagnose such lesions. Recently, the use of AI algorithms has improved the diagnostic ability of MRI. Li *et al*[62] and Chen *et al*[63] used AI algorithms for the identification of PDAC on different phases of MRI (Table 3).

Management of cystic lesions depends upon the precise characterization, which indicates its clinical behavior[64]. However, overlapping imaging features make differentiation challenging[64]. The role of imaging is to differentiate benign from malignant cystic neoplasms. MRI uses T2 images to identify ductal communication and post-contrast images to characterize the lesion. It is limited in the detection of calcifications which is better appreciated on a CT image. MRI can differentiate benign from malignant lesions with an accuracy of 73% to 81% compared to a CT scan which has an accuracy of 75% to 78%[52,65,66].

The use of AI has enabled MRI to detect high-grade dysplasia or malignancy in IPMN with a sensitivity and specificity of 75% and 78%, respectively[67]. Corral *et al*[67] used 3D CNN to classify IPMN into different types with an accuracy of 58%. Interestingly, Cheng *et al*[68] compared radiomics features of CT and MRI using AL algorithms [LASSO, LR, support vector machine (SVM)] and found out that, the MRI-based model(AUC: 0.940) had better diagnostic ability than the CT based model(AUC: 0.864). Studies on the use of AI with MRI to detect the type of cystic or solid pancreatic lesions are presented in Table 3.

Role of AI on EUS in the detection of pancreatic lesions

EUS uses a high-frequency transducer at the tip of an endoscope. It helps to obtain high-resolution images of the pancreas through the esophagus, stomach, or duodenum. Various modalities of EUS including contrast-enhanced EUS, EUS-guided fine needle aspiration (FNA), and EUS elastography have been used for the evaluation of pancreatic cancer, detection of small lesions, differentiation of solid from cystic tumors, and assessment of resectability[69]. Most importantly, it helps to obtain tissue for cytopathology or histopathology[70,71]. The main drawback is operator dependency, which may reduce the diagnostic yield[72,73]. AI algorithms have been used in association with EUS to detect pancreatic cancers and to differentiate from other lesions (Table 4). Mass-forming chronic pancreatitis may masquerade as pancreatic malignancy, EUS based AI algorithms can be used to distinguish pancreatic cancer from chronic pancreatitis.

Authors have used ML algorithms to differentiate normal pancreatic tissue from PDAC with more than 93% accuracy [74-76]. Two studies have used AI to distinguish chronic pancreatitis from PDAC on EUS images with an accuracy of more than 80%[77,78]. Săftoiu *et al*[79] demonstrated better diagnostic ability of contrast-enhanced EUS (94.6% and a specificity of 94.4%) compared to EUS-FNA (87.5% and 92.7%) in differentiating CP from PDAC using AI.

Recently, EUS elastography has been used to diagnose focal pancreatic lesions. Using ANN, it can differentiate benign from malignant lesions with an accuracy of 95%[80]. In another multicenter prospective study using ANN, they demonstrated that EUS elastography (sensitivity (87.6%) and specificity (82.9%)) had better diagnostic ability than two experienced endoscopists combined (sensitivity 80.0%, specificity 50.0%)[81]. Udristoiu *et al*[82] used ML principles to distinguish focal pancreatitis from pancreatic mass (neuroendocrine tumor or PDAC) with an accuracy of 98.26%. Differentiation of benign IPMN from malignant IPMN has management implications, Kuwahara *et al*[83] studied to detect malignant IPMN using CNN (ResNet-50).

Role of AI on PET imaging on the detection of pancreatic lesions

PET is a functional imaging technique used for staging malignant lesions and is based on the physiological characteristics of tumor cells[84,85]. However, inflammation may mimic a malignant lesion due to high metabolic activity giving rise to false positive results, conversely, in patients with hyperglycemia, it can give a false negative result[86,87]. PET CT is also useful in the assessment of tumor response to therapy[43]. Li *et al*[88] used a hybrid feedback-SVM-random forest model to detect pancreatic cancer from a normal pancreas with an accuracy of 96.47%. Liu *et al*[89] studied the role of dual time PET/CT and SVM model to differentiate PDAC from AIP with an AUC of 0.96 similarly, Xing *et al*[90] showed a diagnostic performance of 0.93 of AUC.

Role of AI in pathological examination on detection of pancreatic lesions

Often, imaging cannot achieve an accurate diagnosis, requiring a tissue diagnosis-cytology or histology[91,92]. AI can be applied to hematoxylin-eosin-stained slides for the detection of pancreatic cancer[93]. Song *et al*[94] used AI algorithms to segment epithelial cell nuclei on slide images and extract morphological features and could differentiate SCN from MCN and grading of PDAC[95]. The CNN was used by Kriegsmann *et al*[96] to localize pancreatic intra-epithelial neoplasm or PDAC in a slide. Niazi *et al*[97] used DL to detect neuroendocrine tumors from normal tissues on Ki-67 stained biopsy

Table 2 Studies on differentiation of indeterminate lesions using artificial intelligence algorithms on computed tomography images

No.	Ref.	Number of patients	Primary objective	Sub-type of AI used	Outcome
1	Qureshi <i>et al</i> [36], 2022	108	Identification of PDAC	ML	Accuracy: 86%
2	Ebrahimian <i>et al</i> [121], 2022	103	Differentiation of benign <i>vs</i> malignant pancreatic lesions	RF	AUC: 0.94
3	Chakraborty <i>et al</i> [59], 2018	103	High risk <i>vs</i> low risk IPMN	RF, SVM	AUC: 0.81
4	Polk <i>et al</i> [60], 2020	29	High risk <i>vs</i> low risk IPMN	LR	AUC: 0.90
5	Ikeda <i>et al</i> [122], 1997	71	PDAC <i>vs</i> pancreatitis	NN	AUC: 0.916
6	Chen <i>et al</i> [58], 2021	100	SCN <i>vs</i> MCN	LASSO and RFE_Linear SVC	AUC: 0.932
7	Yang <i>et al</i> [57], 2019	53	SCN <i>vs</i> MCN	LASSO	AUC: 0.66
8	Yang <i>et al</i> [123], 2022	63	SCN <i>vs</i> MCN	MMRF-ResNet	AUC: 0.98
9	Ren <i>et al</i> [124], 2020	112	PDAC <i>vs</i> pancreatic adenosquamous carcinoma	RF	AUC: 0.98
10	Xie <i>et al</i> [125], 2021	226	MCN <i>vs</i> ASCN	RF	AUC: 0.734
11	Ziegelmayr <i>et al</i> [126], 2020	86	AIP <i>vs</i> PDAC	CNN, ML	AUC: 0.90
12	Li <i>et al</i> [62], 2022	97	Focal-type AIP <i>vs</i> PDAC	LASSO regression	AUC: 0.97
13	Gao <i>et al</i> [127], 2021	170	MCN <i>vs</i> SCN	mRMR + LASSO	AUC: 0.91
14	Dmitriev <i>et al</i> [53], 2017	134	Classification of pancreatic cyst	RF, CNN	Accuracy: 83.6%
15	Li <i>et al</i> [54], 2019	206	Classification of pancreatic cysts	DNN (Dense-Net)	Accuracy: 72.8%
16	Wei <i>et al</i> [56], 2019	260	SCN <i>vs</i> other cystic neoplasms	ML	AUC: 0.767

AI: Artificial intelligence; AIP: Autoimmune pancreatitis; ASCN: Atypical serous cystic neoplasm; AUC: Area under the curve; CNN: Convolutional neural network; DNN: Deep neural network; IPMN: Intraductal papillary mucinous neoplasm; LASSO: Least absolute shrinkage and selection operator; LR: Logistic regression; MCN: Mucinous cystic neoplasm; ML: Machine learning; PDAC: Pancreatic ductal adenocarcinoma; RFE: Recursive feature elimination; RF: Random forest; SCN: Serous cystic neoplasm; SVM: Support vector machine; NN: Neural network; mRMR: Minimum redundancy maximum relevance; SVC: Support vector classifier; MMRF: Multi-channel-multiclassifier-random forest.

Table 3 Studies on differentiation of indeterminate lesions using artificial intelligence algorithms on magnetic resonance images

No.	Ref.	Number of patients	Primary objective	Sub-type of AI used	Outcome
1	Li <i>et al</i> [62], 2022	267	PDAC detection	UDA + meta learning + GCN	DSC (62.08%, T1), (61.35%, T2), (61.88%, DWI), (60.43%, AP)
2	Chen <i>et al</i> [63], 2022	73	PDAC detection	Spiral-ResUNet	DSC: 65.60%, Jaccard index: 49.64%
3	Liang Y <i>et al</i> [128], 2020	56	PDAC detection	CNN	DSC: 71%
5	Cui <i>et al</i> [129], 2021	202	Grading-BD IPMN	LASSO	AUC: 0.903
6	Corral <i>et al</i> [67], 2019	139	Classification of IPMN	CNN	AUC: 0.783
7	Cheng <i>et al</i> [68], 2022	60	Malignant IPMN	LR, SVM	MRI + SVM: AUC: 0.940, CT + SVM: AUC: 0.864
8	Hussein <i>et al</i> [130], 2019	171	Classification of IPMN	SVM, RF, 3D, CNN	Accuracy 84.22%

AI: Artificial intelligence; AP: Arterial phase; AUC: Area under the curve; CT: Computed tomography; CNN: Convolutional neural network; DSC: Dice similarity coefficient; DWI: Diffusion weighted image; GCN: Graph convolutional network; IPMN: Intraductal papillary mucinous neoplasm; LASSO: Least absolute shrinkage and selection operator; LR: Logistic regression; MRI: Magnetic resonance and imaging; PDAC: Pancreatic ductal adenocarcinoma; RF: Random forest; SVM: Support vector machine; UDA: Unsupervised data augmentation.

Table 4 Studies on differentiation of indeterminate lesions using artificial intelligence algorithms on endoscopic ultrasonography images

No.	Ref.	Number of patients	Primary outcome	Sub type of AI used	Outcome
1	Zhu <i>et al</i> [78], 2013	262	PDAC <i>vs</i> CP	SVM	Accuracy: 94.2%
2	Zhu <i>et al</i> [131], 2015	100	AIP <i>vs</i> CP	SVM	Accuracy: 89.3%
3	Zhang <i>et al</i> [74], 2010	216	Normal pancreas <i>vs</i> PDAC	SVM	Accuracy: 97.98%
4	Ozkan <i>et al</i> [76], 2016	332	Recognition of pancreatic cancer amongst various age group	ANN	Accuracy: Average: 87.5% (all ages), Min: 88.46% (40-60 yr), Max: 92% (< 40 yr)
5	Kuwahara <i>et al</i> [83], 2019	50	Benign <i>vs</i> malignant IPMN	CNN	Accuracy: 94%
6	Das <i>et al</i> [75], 2008	56	PDAC <i>vs</i> normal pancreas <i>vs</i> CP	ANN	AUC: 0.93
7	Săftoiu <i>et al</i> [80], 2008	68	Benign <i>vs</i> malignant pancreatic lesion	ANN	Accuracy: 89.7%
8	Tonozuka <i>et al</i> [132], 2021	139	PDAC <i>vs</i> CP	CNN	AUC: 0.94
9	Marya <i>et al</i> [133], 2021	583	PDAC <i>vs</i> benign causes of pancreatic SOL	CNN	AUC: 0.976
10.	Xu <i>et al</i> [134], 2013	Systemic Analysis of 6 studies	Benign <i>vs</i> malignant pancreatic lesion	-	AUC: 0.962

AI: Artificial intelligence; AIP: Autoimmune pancreatitis; ANN: Artificial neural network; CNN: Convolved neural network; CP: Chronic pancreatitis; IPMN: Intraductal papillary mucinous neoplasm; PDAC: Pancreatic ductal adenocarcinoma; SOL: Space occupying lesion; SVM: Support vector machine.

images with a 97.8% sensitivity and 88.8% specificity. Momeni-Boroujeni *et al*[98] could differentiate benign from malignant pathology using a K-means clustering algorithm from FNA-based slides with an accuracy of 100%. Naito *et al* [99] used CNN in FNB-based slides to assess PDAC with an AUC of 0.984. Cyst fluid analysis is an essential part of the diagnosis of pancreatic cystic lesions. Kurita *et al*[100] used a neural network to differentiate benign from malignant cysts taking into consideration biomarkers in cyst fluid, cytology and clinical parameters.

Role of AI in biomarkers on detection of pancreatic lesions

Biomarkers act as an adjunct in diagnosis, prognosis, and screening for recurrence and they can be used for early diagnosis of tumors. However, in the case of pancreatic cancer, it lacks sensitivity and specificity for routine clinical practice[91,101,102]. Liquid biopsy is one of the recent developments in oncology, developed with the intent of detecting tumor cells from blood when biopsy cannot be obtained, or to assess tumor response to therapy (surgery or chemoradiotherapy) and assess genetic mutation. It includes three types of sampling of biological materials; which are circulating tumor cells (CTCs), circulating tumor DNA, and exosomes. CTCs have faced difficulties for years because of very low concentrations in many studies, which is 1–10 cells per 10-mL of blood (much lower than billions of hematopoietic cells) and short half-life (approximately from 1 to 2.4 h) in blood which poses difficulty in further study. AI can be used in the detection of disease from these biomarkers and various studies have explored AI algorithms for biomarkers for diagnosis [91,103]. Studies used exosomes[104–106], cell-free DNA[107], extracellular vesicles long RNA[108], proteins[109–112], and circulating microRNA[113] in association with AI for diagnosis of pancreatic cancer. Table 5 shows studies on the role of biomarkers and AI in the differentiation of pancreatic lesions.

This review has shown that AI can be used in routine investigation modalities (CT, MRI, EUS, PET, biomarkers) to improve diagnostic and differentiating potential; however, it is still in progress. In the beginning, studies have trained and validated AI algorithms, in the future it is a challenge to implement such studies at different geographical locations, ethnicity, genetic makeup, *etc.* The majority of studies have explored the potential to differentiate, chronic pancreatitis from pancreatic ductal adenocarcinoma, SCN from MCN, and high-risk *vs.* low-risk IPMN, however, there can be other differential diagnoses in a clinical scenario.

DISCUSSION

Surgery for malignant pancreatic head lesions was standardized by Whipple *et al*[114] which is acceptable worldwide. It includes a complex single-stage procedure of pancreaticoduodenectomy, which is associated with morbidity (25%) and mortality (0%–9.3%) even in high-volume centers[115–117]. Professor Whipple[118] reported a mortality of 29.2% in his series of patients who underwent pancreaticoduodenectomy. Though, recent series have reported reduced mortality following pancreaticoduodenectomy, morbidity of the procedure continues to be high. Recently, many modifications have been made to reduce morbidity, however, none of the measures appeared to be successful. Are *et al*[119] reported a

Table 5 Studies on differentiation of indeterminate lesions using artificial intelligence algorithms on different biomarkers

No.	Ref.	Number of samples	Type of biomarker used	Sub-type of AI used	Conclusion
1	Chen <i>et al</i> [104], 2019	28	Exosomes	LDA	Accuracy: 100%
2	Zheng <i>et al</i> [105], 2022	220	Exosomes	ANN	AUC: 0.86
3	Ko <i>et al</i> [106], 2017	28	Exosomes	LDA	Accuracy: 100%
4	Cristiano <i>et al</i> [107], 2019	34	Cell-free DNA	GBM	AUC: 0.86
5	Yu <i>et al</i> [108], 2020	501	extracellular vesicles long RNA	SVM	AUC: 0.96
6	Gao <i>et al</i> [109], 2012	199	Proteomes	SVM, KNN, ANN	AUC: 0.971
7	Yu <i>et al</i> [110], 2005	100	Proteomes	DT	Sensitivity: 88.9%, specificity: 74.1%
8	Qiao <i>et al</i> [112], 2022	136	Proteomes	CNN	Accuracy: 87.63%
9	Alizadeh <i>et al</i> [113], 2020	671	Circulating micro RNA	ANN	Accuracy: 0.86

AI: Artificial intelligence; ANN: Artificial neural network; CNN: Convolved neural network; DT: Digital transformation; KNN: K-nearest neighbor; GBM: Gradient boosting machine; LDA: Linear discriminant analysis; SVM: Support vector machine.

historical perspective where 7 out of 37 pancreaticoduodenectomies performed by Prof Whipple AO turned out to be chronic pancreatitis (18.9%), where such a morbid procedure could have been avoided. Recent series have also supported these findings of incidence of benign pathology following pancreaticoduodenectomy in the range of 5%-10% [117,120]. Hence, there is an unmet need to differentiate benign pancreatic lesions from malignant ones. Multiple imaging modalities have been used to distinguish benign from malignant lesions, however, each investigation modality has its limitations which are compounded by human errors. The application of AI has minimized those errors and can make diagnoses earlier. Table 6 shows how AI increases the yield of different imaging modalities for predicting a malignant pancreatic head lesion. We have proposed an algorithm for the diagnosis of such entities. Whenever a patient presents to a clinician, history and clinical examination precede imaging. Hence, AI can be used to develop algorithms to predict malignancy [32-34]. In a patient with a high risk of pancreatic malignancy, a pancreatic indeterminate lesion should be investigated further with imaging or biopsy to rule out malignancy. Studies have reported the usefulness of biomarkers in the diagnosis of pancreatic cancer [107-110]. Hence, all non-invasive markers (clinical, biochemical) can be used to develop an algorithm that can predict pancreatic cancer before imaging has been performed and it can differentiate malignant pancreatic lesions. As shown in Table 6, AI has an added advantage over conventional imaging in differentiating pancreatic cancer from benign conditions. So, those high-risk patients marked on non-invasive pancreatic cancer detection models can be subjected to AI-enhanced imaging for better diagnosis. Further in line, to clarify the final tissue diagnosis, AI can help to detect subtle markers that can be ignored by human error. Therefore, AI can be used in every step of the diagnosis of an indeterminate pancreatic head mass, to detect malignant lesions early thus, availing proper oncological management.

Pancreatic incidentalomas or indeterminate lesions are on the rise due to the plethora of cross-sectional imaging performed to diagnose non-specific abdominal complaints. Though plenty of studies have been made in the fields of breast cancer, lung cancer, hepatocellular carcinoma, renal cell carcinoma, and adrenal tumors, there is a dearth of literature discussing how to differentiate benign pancreatic lesions from benign ones. The current literature included studies comparing individual pancreatic lesions, *i.e.* serous cystadenoma *vs.* mucinous cystadenoma, autoimmune pancreatitis *vs.* pancreatic adenocarcinoma, low-grade *vs.* high-grade IPMN, *etc.* However, a comprehensive review discussing how to differentiate various malignant pancreatic lesions (both cystic and solid) from benign lesions with the help of AI is lacking. Hence, in this review, we have discussed how to differentiate different pancreatic lesions encountered in day-to-day clinical practice using different algorithms of AI. We have discussed individually about different diagnostic modalities and different types of pancreatic lesions. There are more studies available in the field of radiological investigations and fewer studies available for the histopathological diagnosis or intra-operative differentiation of malignant from benign lesions. As the understanding of the usefulness of AI is increasing, these limitations can be curtailed in the near future.

FUTURE PERSPECTIVES

There is a surge in the number of medical imaging for different indications leading to the identification of many indeterminate pancreatic lesions (IPLs), which help to diagnose a disease earlier or can lead to a plethora of other investigations, psychological stress, clinical dilemmas, *etc.* Human judgment is prone to errors as subtle differences in these small or atypical lesions are challenging to discern leading to inter-observer and intra-observer variations which can be

Table 6 Studies demonstrating impact of artificial intelligence on increasing efficacy of diagnostic modalities

No.	Ref.	Objective	Modality	Sensitivity	Specificity	Accuracy
1	Corral <i>et al</i> [67], 2019	Differentiate cystic SOL of pancreas	Fukuoka guideline	62%	77	77.5%
			Deep learning	75%	78%	78.3%
2	Kuwahara <i>et al</i> [83], 2019	Detection of malignant IPMN	Human pre-operative diagnosis (Clinical + lab + imaging)	95.7%	22.2%	56%
			Artificial intelligence	95.7%	92.66	94%
3	Gao <i>et al</i> [135], 2020	Ability to differentiate pancreatic disease	CE-MR	NA	NA	83.93%
			GAN	NA	NA	76.79%
4	Rigioli <i>et al</i> [136], 2021	Detection of pancreatic cancer and SMA involvement	CT scan	NA	NA	71%
			Artificial intelligence	62%	77%	54%
5	Chen <i>et al</i> [137], 2023	Detection of pancreatic cancer	CT scan	89.9%	95.9%	AUC: 0.96
			CNN	90%	93%	NA
6	Tang <i>et al</i> [138], 2023	Pancreatic mass diagnosis	EUS FNA	81.6%	100%	87.9%
			CE EUS Master-guided FNA	90.9%	100%	93.8%

CE-MR: Contrast enhanced-magnetic resonance; CT: Computed tomography; CNN: Convoluted neural network; EUS: Endoscopic ultrasound; FNA: Fine needle aspiration; GAN: Generative adversarial network; IPMN: Intraductal papillary mucinous neoplasm; NA: Not available; SMA: Superior mesenteric artery; SOL: Space occupying lesion.

minimized with the use of AI.

CONCLUSION

AI is an evolving technical advancement in the field of medicine and can play a significant role in differentiating IPLs into benign or malignant, by enhancing the diagnostic yield of conventional imaging (CT, MRI, PET), EUS, tissue diagnosis (cytopathology, histopathology), and biomarkers (liquid biopsy). An early and accurate diagnosis may lead to timely intervention, thereby improving the patient outcome. The current literature on this is still limited and sparse, therefore, more studies are required to reach a standard approach for the application of AI in IPLs.

FOOTNOTES

Author contributions: Kumar A designed the concept, corrected, and finalized the manuscript; Ghosh NK and Palash R wrote the manuscript and reviewed the literature; All authors have read and approved the final manuscript.

Conflict-of-interest statement: Dr. Kumar has nothing to disclose.

Open-Access: This article is an open-access article that was selected by an in-house editor and fully peer-reviewed by external reviewers. It is distributed in accordance with the Creative Commons Attribution NonCommercial (CC BY-NC 4.0) license, which permits others to distribute, remix, adapt, build upon this work non-commercially, and license their derivative works on different terms, provided the original work is properly cited and the use is non-commercial. See: <https://creativecommons.org/licenses/by-nc/4.0/>

Country/Territory of origin: India

ORCID number: Palash Rawlani 0009-0008-4478-2020; Nalini Kanta Ghosh 0000-0003-1213-0235; Ashok Kumar 0000-0003-3959-075X.

S-Editor: Lin C

L-Editor: Filipodia

P-Editor: Zhao S

REFERENCES

- 1 **Kaul V**, Enslin S, Gross SA. History of artificial intelligence in medicine. *Gastrointest Endosc* 2020; **92**: 807-812 [PMID: [32565184](#) DOI: [10.1016/j.gie.2020.06.040](#)]
- 2 **Hamamoto R**, Suvarna K, Yamada M, Kobayashi K, Shinkai N, Miyake M, Takahashi M, Jinnai S, Shimoyama R, Sakai A, Takasawa K, Bolatkan A, Shozu K, Dozen A, Machino H, Takahashi S, Asada K, Komatsu M, Sese J, Kaneko S. Application of Artificial Intelligence Technology in Oncology: Towards the Establishment of Precision Medicine. *Cancers (Basel)* 2020; **12** [PMID: [33256107](#) DOI: [10.3390/cancers12123532](#)]
- 3 **Meng Y**, Speier W, Shufelt C, Joung S, E Van Eyk J, Bairey Merz CN, Lopez M, Spiegel B, Arnold CW. A Machine Learning Approach to Classifying Self-Reported Health Status in a Cohort of Patients With Heart Disease Using Activity Tracker Data. *IEEE J Biomed Health Inform* 2020; **24**: 878-884 [PMID: [31199276](#) DOI: [10.1109/JBHI.2019.2922178](#)]
- 4 **Kirsch D**. Autopilot and algorithms: accidents, errors, and the current need for human oversight. *J Clin Sleep Med* 2020; **16**: 1651-1652 [PMID: [32844741](#) DOI: [10.5664/jcsm.8762](#)]
- 5 **Bredt S**. Artificial Intelligence (AI) in the Financial Sector-Potential and Public Strategies. *Front Artif Intell* 2019; **2**: 16 [PMID: [33733105](#) DOI: [10.3389/frai.2019.00016](#)]
- 6 **Goli A**, Malmir B. A Covering Tour Approach for Disaster Relief Locating and Routing with Fuzzy Demand. *Int J Intell Transp Syst Res* 2019; **18**: 140-152 [DOI: [10.1007/s13177-019-00185-2](#)]
- 7 **Goli A**, Mohammadi H. Developing a sustainable operational management system using hybrid Shapley value and Multimoor method: case study petrochemical supply chain. *Environ Dev Sustain* 2021; **24**: 10540-10569 [DOI: [10.1007/s10668-021-01844-9](#)]
- 8 **Bhinder B**, Gilvary C, Madhukar NS, Elemento O. Artificial Intelligence in Cancer Research and Precision Medicine. *Cancer Discov* 2021; **11**: 900-915 [PMID: [33811123](#) DOI: [10.1158/2159-8290.CD-21-0090](#)]
- 9 **Kann BH**, Hosny A, Aerts HJWL. Artificial intelligence for clinical oncology. *Cancer Cell* 2021; **39**: 916-927 [PMID: [33930310](#) DOI: [10.1016/j.ccell.2021.04.002](#)]
- 10 **Huynh E**, Hosny A, Guthrie C, Bitterman DS, Petit SF, Haas-Kogan DA, Kann B, Aerts HJWL, Mak RH. Artificial intelligence in radiation oncology. *Nat Rev Clin Oncol* 2020; **17**: 771-781 [PMID: [32843739](#) DOI: [10.1038/s41571-020-0417-8](#)]
- 11 **Benzekry S**. Artificial Intelligence and Mechanistic Modeling for Clinical Decision Making in Oncology. *Clin Pharmacol Ther* 2020; **108**: 471-486 [PMID: [32557598](#) DOI: [10.1002/cpt.1951](#)]
- 12 **Ippolito AM**, De Laurentiis M, La Rosa GL, Eleuteri A, Tagliaferri R, De Placido S, Vigneri R, Belfiore A. Neural network analysis for evaluating cancer risk in thyroid nodules with an indeterminate diagnosis at aspiration cytology: identification of a low-risk subgroup. *Thyroid* 2004; **14**: 1065-1071 [PMID: [15650360](#) DOI: [10.1089/thy.2004.14.1065](#)]
- 13 **Daniels K**, Gummadi S, Zhu Z, Wang S, Patel J, Swendseid B, Lyschchik A, Curry J, Cottrill E, Eisenbrey J. Machine Learning by Ultrasonography for Genetic Risk Stratification of Thyroid Nodules. *JAMA Otolaryngol Head Neck Surg* 2020; **146**: 36-41 [PMID: [31647509](#) DOI: [10.1001/jamaoto.2019.3073](#)]
- 14 **Becker AS**, Mueller M, Stoffel E, Marcon M, Ghafoor S, Boss A. Classification of breast cancer in ultrasound imaging using a generic deep learning analysis software: a pilot study. *Br J Radiol* 2018; **91**: 20170576 [PMID: [29215311](#) DOI: [10.1259/bjr.20170576](#)]
- 15 **Scott JA**, McDermott S, Kilcoyne A, Wang Y, Halpern EF, Ackman JB. Comparison of (18)F-FDG avidity at PET of benign and malignant pure ground-glass opacities: a paradox? Part II: artificial neural network integration of the PET/CT characteristics of ground-glass opacities to predict their likelihood of malignancy. *Clin Radiol* 2019; **74**: 692-696 [PMID: [31202569](#) DOI: [10.1016/j.crad.2019.04.024](#)]
- 16 **Guo H**, Wu J, Xie Z, Tham IWK, Zhou L, Yan J. Investigation of small lung lesion detection for lung cancer screening in low dose FDG PET imaging by deep neural networks. *Front Public Health* 2022; **10**: 1047714 [PMID: [36438275](#) DOI: [10.3389/fpubh.2022.1047714](#)]
- 17 **Yasaka K**, Akai H, Abe O, Kiryu S. Deep Learning with Convolutional Neural Network for Differentiation of Liver Masses at Dynamic Contrast-enhanced CT: A Preliminary Study. *Radiology* 2018; **286**: 887-896 [PMID: [29059036](#) DOI: [10.1148/radiol.2017170706](#)]
- 18 **Moawad AW**, Ahmed A, Fuentes DT, Hazle JD, Habra MA, Elsayes KM. Machine learning-based texture analysis for differentiation of radiologically indeterminate small adrenal tumors on adrenal protocol CT scans. *Abdom Radiol (NY)* 2021; **46**: 4853-4863 [PMID: [34085089](#) DOI: [10.1007/s00261-021-03136-2](#)]
- 19 **Stanzione A**, Cuocolo R, Verde F, Galatola R, Romeo V, Mainenti PP, Aprea G, Guadagno E, Del Basso De Caro M, Maurea S. Handcrafted MRI radiomics and machine learning: Classification of indeterminate solid adrenal lesions. *Magn Reson Imaging* 2021; **79**: 52-58 [PMID: [33727148](#) DOI: [10.1016/j.mri.2021.03.009](#)]
- 20 **Massa'a RN**, Stoeckl EM, Lubner MG, Smith D, Mao L, Shapiro DD, Abel EJ, Wentland AL. Differentiation of benign from malignant solid renal lesions with MRI-based radiomics and machine learning. *Abdom Radiol (NY)* 2022; **47**: 2896-2904 [PMID: [35723716](#) DOI: [10.1007/s00261-022-03577-3](#)]
- 21 **Saraiva MM**, Ribeiro T, Ferreira JPS, Boas FV, Afonso J, Santos AL, Parente MPL, Jorge RN, Pereira P, Macedo G. Artificial intelligence for automatic diagnosis of biliary stricture malignancy status in single-operator cholangioscopy: a pilot study. *Gastrointest Endosc* 2022; **95**: 339-348 [PMID: [34508767](#) DOI: [10.1016/j.gie.2021.08.027](#)]
- 22 **Rosenkrantz AB**, Hanna TN, Babb JS, Duszak R Jr. Changes in Emergency Department Imaging: Perspectives From National Patient Surveys Over Two Decades. *J Am Coll Radiol* 2017; **14**: 1282-1290 [PMID: [28483547](#) DOI: [10.1016/j.jacr.2017.03.004](#)]
- 23 **Del Chiaro M**, Torphy RJ, Schulick RD. Pancreatic incidentalomas: Investigation and management. *J Intern Med* 2021; **290**: 969-979 [PMID: [34237168](#) DOI: [10.1111/joim.13359](#)]
- 24 **Herrera MF**, Pantoja JP, Salazar MS, Velázquez-Fernández, D. Pancreatic Incidentaloma. In: Hubbard J, Inabnet W, Lo CY, editor. *Endocrine Surgery*. London: Springer, 2009 [DOI: [10.1007/978-1-84628-881-4_41](#)]
- 25 **Karatzas T**, Dimitroulis D, Charalampoudis P, Misiakos EP, Vasileiadis I, Kouraklis G. Management of cystic and solid pancreatic incidentalomas: a review analysis. *J BUON* 2013; **18**: 17-24 [PMID: [23613384](#)]
- 26 **Herrera MF**, Åkerström G, Angelos P, Grant CS, Hoff AO, Pantoja JP, Pérez-Johnston R, Sahani DV, Wong RJ, Randolph G. AACE/ACE disease state clinical review: pancreatic neuroendocrine incidentalomas. *Endocr Pract* 2015; **21**: 546-553 [PMID: [25962093](#) DOI: [10.4158/EP14465.DSC](#)]
- 27 **van Hilst J**, de Rooij T, Bosscha K, Brinkman DJ, van Dieren S, Dijkgraaf MG, Gerhards MF, de Hingh IH, Karsten TM, Lips DJ, Luyer MD, Busch OR, Festen S, Besselink MG; Dutch Pancreatic Cancer Group. Laparoscopic versus open pancreatoduodenectomy for pancreatic or periampullary tumours (LEOPARD-2): a multicentre, patient-blinded, randomised controlled phase 2/3 trial. *Lancet Gastroenterol Hepatol*

- 2019; **4**: 199-207 [PMID: [30685489](#) DOI: [10.1016/S2468-1253\(19\)30004-4](#)]
- 28 **Udare A**, Agarwal M, Alabousi M, McInnes M, Rubino JG, Marcaccio M, van der Pol CB. Diagnostic Accuracy of MRI for Differentiation of Benign and Malignant Pancreatic Cystic Lesions Compared to CT and Endoscopic Ultrasound: Systematic Review and Meta-analysis. *J Magn Reson Imaging* 2021; **54**: 1126-1137 [PMID: [33847435](#) DOI: [10.1002/jmri.27606](#)]
 - 29 **Kromrey ML**, Bülow R, Hübner J, Paperlein C, Lerch MM, Ittermann T, Völzke H, Mayerle J, Kühn JP. Prospective study on the incidence, prevalence and 5-year pancreatic-related mortality of pancreatic cysts in a population-based study. *Gut* 2018; **67**: 138-145 [PMID: [28877981](#) DOI: [10.1136/gutjnl-2016-313127](#)]
 - 30 **Kobayashi G**, Fujita N, Maguchi H, Tanno S, Mizuno N, Hanada K, Hatori T, Sadakari Y, Yamaguchi T, Tobita K, Doi R, Yanagisawa A, Tanaka M; Working Group for the Natural History of IPMN of the Japan Pancreas Society. Natural history of branch duct intraductal papillary mucinous neoplasm with mural nodules: a Japan Pancreas Society multicenter study. *Pancreas* 2014; **43**: 532-538 [PMID: [24717801](#) DOI: [10.1097/MPA.0000000000000080](#)]
 - 31 **Caban M**, Małecka-Wojcieszko E. Pancreatic Incidentaloma. *J Clin Med* 2022; **11** [PMID: [36012893](#) DOI: [10.3390/jcm11164648](#)]
 - 32 **Meng Q**, Shi S, Liang C, Liang D, Xu W, Ji S, Zhang B, Ni Q, Xu J, Yu X. Diagnostic and prognostic value of carcinoembryonic antigen in pancreatic cancer: a systematic review and meta-analysis. *Onco Targets Ther* 2017; **10**: 4591-4598 [PMID: [28979147](#) DOI: [10.2147/OTT.S145708](#)]
 - 33 **van Manen L**, Groen JV, Putter H, Vahrmeijer AL, Swijnenburg RJ, Bonsing BA, Mieog JSD. Elevated CEA and CA19-9 serum levels independently predict advanced pancreatic cancer at diagnosis. *Biomarkers* 2020; **25**: 186-193 [PMID: [32009482](#) DOI: [10.1080/1354750X.2020.1725786](#)]
 - 34 **Lee HS**, Jang CY, Kim SA, Park SB, Jung DE, Kim BO, Kim HY, Chung MJ, Park JY, Bang S, Park SW, Song SY. Combined use of CEMIP and CA 19-9 enhances diagnostic accuracy for pancreatic cancer. *Sci Rep* 2018; **8**: 3383 [PMID: [29467409](#) DOI: [10.1038/s41598-018-21823-x](#)]
 - 35 **Chen W**, Butler RK, Zhou Y, Parker RA, Jeon CY, Wu BU. Prediction of Pancreatic Cancer Based on Imaging Features in Patients With Duct Abnormalities. *Pancreas* 2020; **49**: 413-419 [PMID: [32132511](#) DOI: [10.1097/MPA.0000000000001499](#)]
 - 36 **Qureshi TA**, Gaddam S, Wachsman AM, Wang L, Azab L, Asadpour V, Chen W, Xie Y, Wu B, Pandol SJ, Li D. Predicting pancreatic ductal adenocarcinoma using artificial intelligence analysis of pre-diagnostic computed tomography images. *Cancer Biomark* 2022; **33**: 211-217 [PMID: [35213359](#) DOI: [10.3233/CBM-210273](#)]
 - 37 **Muhammad W**, Hart GR, Nartowt B, Farrell JJ, Johung K, Liang Y, Deng J. Pancreatic Cancer Prediction Through an Artificial Neural Network. *Front Artif Intell* 2019; **2**: 2 [PMID: [33733091](#) DOI: [10.3389/frai.2019.00002](#)]
 - 38 **Placido D**, Yuan B, Hjalteinn JX, Zheng C, Haue AD, Chmura PJ, Yuan C, Kim J, Umeton R, Antell G, Chowdhury A, Franz A, Brais L, Andrews E, Marks DS, Regev A, Ayandeh S, Brophy MT, Do NV, Kraft P, Wolpin BM, Rosenthal MH, Fillmore NR, Brunak S, Sander C. A deep learning algorithm to predict risk of pancreatic cancer from disease trajectories. *Nat Med* 2023; **29**: 1113-1122 [PMID: [37156936](#) DOI: [10.1038/s41591-023-02332-5](#)]
 - 39 **Chen Q**, Cherry DR, Nalawade V, Qiao EM, Kumar A, Lowy AM, Simpson DR, Murphy JD. Clinical Data Prediction Model to Identify Patients With Early-Stage Pancreatic Cancer. *JCO Clin Cancer Inform* 2021; **5**: 279-287 [PMID: [33739856](#) DOI: [10.1200/CCI.20.00137](#)]
 - 40 **Malhotra A**, Rachet B, Bonaventure A, Pereira SP, Woods LM. Can we screen for pancreatic cancer? Identifying a sub-population of patients at high risk of subsequent diagnosis using machine learning techniques applied to primary care data. *PLoS One* 2021; **16**: e0251876 [PMID: [34077433](#) DOI: [10.1371/journal.pone.0251876](#)]
 - 41 **Appelbaum L**, Cambronero JP, Stevens JP, Horng S, Pollick K, Silva G, Haneuse S, Piatkowski G, Benhaga N, Duey S, Stevenson MA, Mamon H, Kaplan ID, Rinard MC. Development and validation of a pancreatic cancer risk model for the general population using electronic health records: An observational study. *Eur J Cancer* 2021; **143**: 19-30 [PMID: [33278770](#) DOI: [10.1016/j.ejca.2020.10.019](#)]
 - 42 **de la Santa LG**, Retortillo JA, Miguel AC, Klein LM. Radiology of pancreatic neoplasms: An update. *World J Gastrointest Oncol* 2014; **6**: 330-343 [PMID: [25232458](#) DOI: [10.4251/wjgo.v6.i9.330](#)]
 - 43 **Lee ES**, Lee JM. Imaging diagnosis of pancreatic cancer: a state-of-the-art review. *World J Gastroenterol* 2014; **20**: 7864-7877 [PMID: [24976723](#) DOI: [10.3748/wjg.v20.i24.7864](#)]
 - 44 **Gandhi NS**, Feldman MK, Le O, Morris-Stiff G. Imaging mimics of pancreatic ductal adenocarcinoma. *Abdom Radiol (NY)* 2018; **43**: 273-284 [PMID: [29038855](#) DOI: [10.1007/s00261-017-1330-1](#)]
 - 45 **Raman SP**, Horton KM, Fishman EK. Multimodality imaging of pancreatic cancer-computed tomography, magnetic resonance imaging, and positron emission tomography. *Cancer J* 2012; **18**: 511-522 [PMID: [23187837](#) DOI: [10.1097/PPO.0b013e318274a461](#)]
 - 46 **Mizrahi JD**, Surana R, Valle JW, Shroff RT. Pancreatic cancer. *Lancet* 2020; **395**: 2008-2020 [PMID: [32593337](#) DOI: [10.1016/S0140-6736\(20\)30974-0](#)]
 - 47 **Stupp A**, Singerman D, Celi LA. The reproducibility crisis in the age of digital medicine. *NPJ Digit Med* 2019; **2**: 2 [PMID: [31304352](#) DOI: [10.1038/s41746-019-0079-z](#)]
 - 48 **Zhu Z**, Xia Y, Xie L, Fishman EK, Yuille AL. Multi-scale coarse-to-fine segmentation for screening pancreatic ductal adenocarcinoma. In: Shen D, Liu T, Peters TM, Staib LH, Essert C, Zhou S, Yap PT. Ali Khan Medical Image Computing and Computer Assisted Intervention - MICCAI 2019. 22nd International Conference; October 13-17; Shenzhen, China. Cham: Springer, 2019 [DOI: [10.1007/978-3-030-32226-7_1](#)]
 - 49 **Liu SL**, Li S, Guo YT, Zhou YP, Zhang ZD, Lu Y. Establishment and application of an artificial intelligence diagnosis system for pancreatic cancer with a faster region-based convolutional neural network. *Chin Med J (Engl)* 2019; **132**: 2795-2803 [PMID: [31856050](#) DOI: [10.1097/CM9.0000000000000544](#)]
 - 50 **Chu LC**, Park S, Kawamoto S, Fouladi DF, Shayesteh S, Zinreich ES, Graves JS, Horton KM, Hruban RH, Yuille AL, Kinzler KW, Vogelstein B, Fishman EK. Utility of CT Radiomics Features in Differentiation of Pancreatic Ductal Adenocarcinoma From Normal Pancreatic Tissue. *AJR Am J Roentgenol* 2019; **213**: 349-357 [PMID: [31012758](#) DOI: [10.2214/AJR.18.20901](#)]
 - 51 **Jang DK**, Song BJ, Ryu JK, Chung KH, Lee BS, Park JK, Lee SH, Kim YT, Lee JY. Preoperative Diagnosis of Pancreatic Cystic Lesions: The Accuracy of Endoscopic Ultrasound and Cross-Sectional Imaging. *Pancreas* 2015; **44**: 1329-1333 [PMID: [26465956](#) DOI: [10.1097/MPA.0000000000000396](#)]
 - 52 **Lee HJ**, Kim MJ, Choi JY, Hong HS, Kim KA. Relative accuracy of CT and MRI in the differentiation of benign from malignant pancreatic cystic lesions. *Clin Radiol* 2011; **66**: 315-321 [PMID: [21356393](#) DOI: [10.1016/j.crad.2010.06.019](#)]
 - 53 **Dmitriev K**, Kaufman AE, Javed AA, Hruban RH, Fishman EK, Lennon AM, Saltz JH. Classification of Pancreatic Cysts in Computed Tomography Images Using a Random Forest and Convolutional Neural Network Ensemble. *Med Image Comput Comput Assist Interv* 2017; **10435**: 150-158 [PMID: [29881827](#) DOI: [10.1007/978-3-319-66179-7_18](#)]
 - 54 **Li H**, Shi K, Reichert M, Lin K, Tselousov N, Braren R, Fu D, Schmid R, Li J, Menze B. Differential Diagnosis for Pancreatic Cysts in CT

- Scans Using Densely-Connected Convolutional Networks. *Annu Int Conf IEEE Eng Med Biol Soc* 2019; **2019**: 2095-2098 [PMID: [31946314](#) DOI: [10.1109/EMBC.2019.8856745](#)]
- 55 **Sahani DV**, Sainani NI, Blake MA, Crippa S, Mino-Kenudson M, del-Castillo CF. Prospective evaluation of reader performance on MDCT in characterization of cystic pancreatic lesions and prediction of cyst biologic aggressiveness. *AJR Am J Roentgenol* 2011; **197**: W53-W61 [PMID: [21700995](#) DOI: [10.2214/AJR.10.5866](#)]
- 56 **Wei R**, Lin K, Yan W, Guo Y, Wang Y, Li J, Zhu J. Computer-Aided Diagnosis of Pancreas Serous Cystic Neoplasms: A Radiomics Method on Preoperative MDCT Images. *Technol Cancer Res Treat* 2019; **18**: 1533033818824339 [PMID: [30803366](#) DOI: [10.1177/1533033818824339](#)]
- 57 **Yang J**, Guo X, Ou X, Zhang W, Ma X. Discrimination of Pancreatic Serous Cystadenomas From Mucinous Cystadenomas With CT Textural Features: Based on Machine Learning. *Front Oncol* 2019; **9**: 494 [PMID: [31245294](#) DOI: [10.3389/fonc.2019.00494](#)]
- 58 **Chen HY**, Deng XY, Pan Y, Chen JY, Liu YY, Chen WJ, Yang H, Zheng Y, Yang YB, Liu C, Shao GL, Yu RS. Pancreatic Serous Cystic Neoplasms and Mucinous Cystic Neoplasms: Differential Diagnosis by Combining Imaging Features and Enhanced CT Texture Analysis. *Front Oncol* 2021; **11**: 745001 [PMID: [35004272](#) DOI: [10.3389/fonc.2021.745001](#)]
- 59 **Chakraborty J**, Midya A, Gazit L, Attiyeh M, Langdon-Embry L, Allen PJ, Do RKG, Simpson AL. CT radiomics to predict high-risk intraductal papillary mucinous neoplasms of the pancreas. *Med Phys* 2018; **45**: 5019-5029 [PMID: [30176047](#) DOI: [10.1002/mp.13159](#)]
- 60 **Polk SL**, Choi JW, McGettigan MJ, Rose T, Ahmed A, Kim J, Jiang K, Balagurunathan Y, Qi J, Farah PT, Rath A, Permut JB, Jeong D. Multiphase computed tomography radiomics of pancreatic intraductal papillary mucinous neoplasms to predict malignancy. *World J Gastroenterol* 2020; **26**: 3458-3471 [PMID: [32655269](#) DOI: [10.3748/wjg.v26.i24.3458](#)]
- 61 **Vachiranubhap B**, Kim YH, Balci NC, Semelka RC. Magnetic resonance imaging of adenocarcinoma of the pancreas. *Top Magn Reson Imaging* 2009; **20**: 3-9 [PMID: [19687720](#) DOI: [10.1097/RMR.0b013e3181b48392](#)]
- 62 **Li J**, Feng C, Lin X, Qian X. Utilizing GCN and Meta-Learning Strategy in Unsupervised Domain Adaptation for Pancreatic Cancer Segmentation. *IEEE J Biomed Health Inform* 2022; **26**: 79-89 [PMID: [34057903](#) DOI: [10.1109/JBHI.2021.3085092](#)]
- 63 **Chen X**, Chen Z, Li J, Zhang YD, Lin X, Qian X. Model-Driven Deep Learning Method for Pancreatic Cancer Segmentation Based on Spiral-Transformation. *IEEE Trans Med Imaging* 2022; **41**: 75-87 [PMID: [34383646](#) DOI: [10.1109/TMI.2021.3104460](#)]
- 64 **Brugge WR**. Diagnosis and management of cystic lesions of the pancreas. *J Gastrointest Oncol* 2015; **6**: 375-388 [PMID: [26261724](#) DOI: [10.3978/j.issn.2078-6891.2015.057](#)]
- 65 **Sainani NI**, Saokar A, Deshpande V, Fernández-del Castillo C, Hahn P, Sahani DV. Comparative performance of MDCT and MRI with MR cholangiopancreatography in characterizing small pancreatic cysts. *AJR Am J Roentgenol* 2009; **193**: 722-731 [PMID: [19696285](#) DOI: [10.2214/AJR.08.1253](#)]
- 66 **Kim JH**, Eun HW, Park HJ, Hong SS, Kim YJ. Diagnostic performance of MRI and EUS in the differentiation of benign from malignant pancreatic cyst and cyst communication with the main duct. *Eur J Radiol* 2012; **81**: 2927-2935 [PMID: [22227264](#) DOI: [10.1016/j.ejrad.2011.12.019](#)]
- 67 **Corral JE**, Hussein S, Kandel P, Bolan CW, Bagci U, Wallace MB. Deep Learning to Classify Intraductal Papillary Mucinous Neoplasms Using Magnetic Resonance Imaging. *Pancreas* 2019; **48**: 805-810 [PMID: [31210661](#) DOI: [10.1097/MPA.0000000000001327](#)]
- 68 **Cheng S**, Shi H, Lu M, Wang C, Duan S, Xu Q. Radiomics Analysis for Predicting Malignant Potential of Intraductal Papillary Mucinous Neoplasms of the Pancreas: Comparison of CT and MRI. *Acad Radiol* 2022; **29**: 367-375 [PMID: [34112528](#) DOI: [10.1016/j.acra.2021.04.013](#)]
- 69 **Kitano M**, Yoshida T, Itonaga M, Tamura T, Hatamaru K, Yamashita Y. Impact of endoscopic ultrasonography on diagnosis of pancreatic cancer. *J Gastroenterol* 2019; **54**: 19-32 [PMID: [30406288](#) DOI: [10.1007/s00535-018-1519-2](#)]
- 70 **Moutinho-Ribeiro P**, Iglesias-Garcia J, Gaspar R, Macedo G. Early pancreatic cancer - The role of endoscopic ultrasound with or without tissue acquisition in diagnosis and staging. *Dig Liver Dis* 2019; **51**: 4-9 [PMID: [30337098](#) DOI: [10.1016/j.dld.2018.09.027](#)]
- 71 **Bhutani MS**, Koduru P, Joshi V, Saxena P, Suzuki R, Irisawa A, Yamao K. The role of endoscopic ultrasound in pancreatic cancer screening. *Endosc Ultrasound* 2016; **5**: 8-16 [PMID: [26879161](#) DOI: [10.4103/2303-9027.175876](#)]
- 72 **ASGE Standards of Practice Committee**, Eloubeidi MA, Decker GA, Chandrasekhara V, Chathadi KV, Early DS, Evans JA, Fanelli RD, Fisher DA, Foley K, Hwang JH, Jue TL, Lightdale JR, Pasha SF, Saltzman JR, Sharaf R, Shergill AK, Cash BD, DeWitt JM. The role of endoscopy in the evaluation and management of patients with solid pancreatic neoplasia. *Gastrointest Endosc* 2016; **83**: 17-28 [PMID: [26706297](#) DOI: [10.1016/j.gie.2015.09.009](#)]
- 73 **Tummers WS**, Willmann JK, Bonsing BA, Vahrmeijer AL, Gambhir SS, Swijnenburg RJ. Advances in Diagnostic and Intraoperative Molecular Imaging of Pancreatic Cancer. *Pancreas* 2018; **47**: 675-689 [PMID: [29894417](#) DOI: [10.1097/MPA.0000000000001075](#)]
- 74 **Zhang MM**, Yang H, Jin ZD, Yu JG, Cai ZY, Li ZS. Differential diagnosis of pancreatic cancer from normal tissue with digital imaging processing and pattern recognition based on a support vector machine of EUS images. *Gastrointest Endosc* 2010; **72**: 978-985 [PMID: [20855062](#) DOI: [10.1016/j.gie.2010.06.042](#)]
- 75 **Das A**, Nguyen CC, Li F, Li B. Digital image analysis of EUS images accurately differentiates pancreatic cancer from chronic pancreatitis and normal tissue. *Gastrointest Endosc* 2008; **67**: 861-867 [PMID: [18179797](#) DOI: [10.1016/j.gie.2007.08.036](#)]
- 76 **Ozkan M**, Kakiroglu M, Kocaman O, Kurt M, Yilmaz B, Can G, Korkmaz U, Dandil E, Eksi Z. Age-based computer-aided diagnosis approach for pancreatic cancer on endoscopic ultrasound images. *Endosc Ultrasound* 2016; **5**: 101-107 [PMID: [27080608](#) DOI: [10.4103/2303-9027.180473](#)]
- 77 **Norton ID**, Zheng Y, Wiersema MS, Greenleaf J, Clain JE, Dimagno EP. Neural network analysis of EUS images to differentiate between pancreatic malignancy and pancreatitis. *Gastrointest Endosc* 2001; **54**: 625-629 [PMID: [11677484](#) DOI: [10.1067/mge.2001.118644](#)]
- 78 **Zhu M**, Xu C, Yu J, Wu Y, Li C, Zhang M, Jin Z, Li Z. Differentiation of pancreatic cancer and chronic pancreatitis using computer-aided diagnosis of endoscopic ultrasound (EUS) images: a diagnostic test. *PLoS One* 2013; **8**: e63820 [PMID: [23704940](#) DOI: [10.1371/journal.pone.0063820](#)]
- 79 **Săftoiu A**, Vilmann P, Dietrich CF, Iglesias-Garcia J, Hocke M, Seicean A, Ignee A, Hassan H, Streba CT, Ioniță AM, Gheonea DI, Ciurea T. Quantitative contrast-enhanced harmonic EUS in differential diagnosis of focal pancreatic masses (with videos). *Gastrointest Endosc* 2015; **82**: 59-69 [PMID: [25792386](#) DOI: [10.1016/j.gie.2014.11.040](#)]
- 80 **Săftoiu A**, Vilmann P, Gorunescu F, Gheonea DI, Gorunescu M, Ciurea T, Popescu GL, Iordache A, Hassan H, Iordache S. Neural network analysis of dynamic sequences of EUS elastography used for the differential diagnosis of chronic pancreatitis and pancreatic cancer. *Gastrointest Endosc* 2008; **68**: 1086-1094 [PMID: [18656186](#) DOI: [10.1016/j.gie.2008.04.031](#)]
- 81 **Săftoiu A**, Vilmann P, Gorunescu F, Janssen J, Hocke M, Larsen M, Iglesias-Garcia J, Arcidiacono P, Will U, Giovannini M, Dietrich CF, Havre R, Gheorghe C, McKay C, Gheonea DI, Ciurea T; European EUS Elastography Multicentric Study Group. Efficacy of an artificial

- neural network-based approach to endoscopic ultrasound elastography in diagnosis of focal pancreatic masses. *Clin Gastroenterol Hepatol* 2012; **10**: 84-90.e1 [PMID: 21963957 DOI: 10.1016/j.cgh.2011.09.014]
- 82 **Udriștoiu AL**, Cazacu IM, Gruionu LG, Gruionu G, Iacob AV, Burtea DE, Ungureanu BS, Costache MI, Constantin A, Popescu CF, Udriștoiu Ș, Săftoiu A. Real-time computer-aided diagnosis of focal pancreatic masses from endoscopic ultrasound imaging based on a hybrid convolutional and long short-term memory neural network model. *PLoS One* 2021; **16**: e0251701 [PMID: 34181680 DOI: 10.1371/journal.pone.0251701]
- 83 **Kuwahara T**, Hara K, Mizuno N, Okuno N, Matsumoto S, Obata M, Kurita Y, Koda H, Toriyama K, Onishi S, Ishihara M, Tanaka T, Tajika M, Niwa Y. Usefulness of Deep Learning Analysis for the Diagnosis of Malignancy in Intraductal Papillary Mucinous Neoplasms of the Pancreas. *Clin Transl Gastroenterol* 2019; **10**: 1-8 [PMID: 31117111 DOI: 10.14309/ctg.0000000000000045]
- 84 **Fonti R**, Conson M, Del Vecchio S. PET/CT in radiation oncology. *Semin Oncol* 2019; **46**: 202-209 [PMID: 31378377 DOI: 10.1053/j.seminoncol.2019.07.001]
- 85 **Blodgett TM**, Meltzer CC, Townsend DW. PET/CT: form and function. *Radiology* 2007; **242**: 360-385 [PMID: 17255408 DOI: 10.1148/radiol.2422051113]
- 86 **Yokoyama Y**, Nagino M, Hiromatsu T, Yuasa N, Oda K, Arai T, Nishio H, Ebata T, Nimura Y. Intense PET signal in the degenerative necrosis superimposed on chronic pancreatitis. *Pancreas* 2005; **31**: 192-194 [PMID: 16025008 DOI: 10.1097/01.mpa.0000168226.36085.58]
- 87 **Feldman MK**, Gandhi NS. Imaging Evaluation of Pancreatic Cancer. *Surg Clin North Am* 2016; **96**: 1235-1256 [PMID: 27865275 DOI: 10.1016/j.suc.2016.07.007]
- 88 **Li S**, Jiang H, Wang Z, Zhang G, Yao YD. An effective computer aided diagnosis model for pancreas cancer on PET/CT images. *Comput Methods Programs Biomed* 2018; **165**: 205-214 [PMID: 30337075 DOI: 10.1016/j.cmpb.2018.09.001]
- 89 **Liu Z**, Li M, Zuo C, Yang Z, Yang X, Ren S, Peng Y, Sun G, Shen J, Cheng C. Radiomics model of dual-time 2-[(18)F]FDG PET/CT imaging to distinguish between pancreatic ductal adenocarcinoma and autoimmune pancreatitis. *Eur Radiol* 2021; **31**: 6983-6991 [PMID: 33677645 DOI: 10.1007/s00330-021-07778-0]
- 90 **Xing H**, Hao Z, Zhu W, Sun D, Ding J, Zhang H, Liu Y, Huo L. Preoperative prediction of pathological grade in pancreatic ductal adenocarcinoma based on (18)F-FDG PET/CT radiomics. *EJNMMI Res* 2021; **11**: 19 [PMID: 33630176 DOI: 10.1186/s13550-021-00760-3]
- 91 **Yang J**, Xu R, Wang C, Qiu J, Ren B, You L. Early screening and diagnosis strategies of pancreatic cancer: a comprehensive review. *Cancer Commun (Lond)* 2021; **41**: 1257-1274 [PMID: 34331845 DOI: 10.1002/cac2.12204]
- 92 **Nicola M**, Onorati M, Albertoni MM, Bianchi CL, De Nucci G, Mandelli ED, Nicola L, Di Nuovo F. Fine Needle Aspiration versus Fine Needle Biopsy of Biliopancreatic Lesions: Are They Really Opposing Techniques or Can They Be Complementary? Our Experience in a Large Cohort of Cases from a Single Institution. *Acta Cytol* 2021; **65**: 40-47 [PMID: 33099544 DOI: 10.1159/000510755]
- 93 **Elemento O**, Leslie C, Lundin J, Tourassi G. Artificial intelligence in cancer research, diagnosis and therapy. *Nat Rev Cancer* 2021; **21**: 747-752 [PMID: 34535775 DOI: 10.1038/s41568-021-00399-1]
- 94 **Song JW**, Lee JH, Choi JH, Chun SJ. Automatic differential diagnosis of pancreatic serous and mucinous cystadenomas based on morphological features. *Comput Biol Med* 2013; **43**: 1-15 [PMID: 23200461 DOI: 10.1016/j.compbiomed.2012.10.009]
- 95 **Song JW**, Lee JH. New morphological features for grading pancreatic ductal adenocarcinomas. *Biomed Res Int* 2013; **2013**: 175271 [PMID: 23984321 DOI: 10.1155/2013/175271]
- 96 **Kriegsmann M**, Kriegsmann K, Steinbuss G, Zgorzelski C, Kraft A, Gaida MM. Deep Learning in Pancreatic Tissue: Identification of Anatomical Structures, Pancreatic Intraepithelial Neoplasia, and Ductal Adenocarcinoma. *Int J Mol Sci* 2021; **22** [PMID: 34065423 DOI: 10.3390/ijms22105385]
- 97 **Niazi MKK**, Tavolara TE, Arole V, Hartman DJ, Pantanowitz L, Gurcan MN. Identifying tumor in pancreatic neuroendocrine neoplasms from Ki67 images using transfer learning. *PLoS One* 2018; **13**: e0195621 [PMID: 29649302 DOI: 10.1371/journal.pone.0195621]
- 98 **Momeni-Boroujeni A**, Yousefi E, Somma J. Computer-assisted cytologic diagnosis in pancreatic FNA: An application of neural networks to image analysis. *Cancer Cytopathol* 2017; **125**: 926-933 [PMID: 28885766 DOI: 10.1002/ency.21915]
- 99 **Naito Y**, Tsuneki M, Fukushima N, Koga Y, Higashi M, Notohara K, Aishima S, Ohike N, Tajiri T, Yamaguchi H, Fukumura Y, Kojima M, Hirabayashi K, Hamada Y, Norose T, Kai K, Omori Y, Sukeda A, Noguchi H, Uchino K, Itakura J, Okabe Y, Yamada Y, Akiba J, Kanavati F, Oda Y, Furukawa T, Yano H. A deep learning model to detect pancreatic ductal adenocarcinoma on endoscopic ultrasound-guided fine-needle biopsy. *Sci Rep* 2021; **11**: 8454 [PMID: 33875703 DOI: 10.1038/s41598-021-87748-0]
- 100 **Kurita Y**, Kuwahara T, Hara K, Mizuno N, Okuno N, Matsumoto S, Obata M, Koda H, Tajika M, Shimizu Y, Nakajima A, Kubota K, Niwa Y. Diagnostic ability of artificial intelligence using deep learning analysis of cyst fluid in differentiating malignant from benign pancreatic cystic lesions. *Sci Rep* 2019; **9**: 6893 [PMID: 31053726 DOI: 10.1038/s41598-019-43314-3]
- 101 **Pereira SP**, Oldfield L, Ney A, Hart PA, Keane MG, Pandol SJ, Li D, Greenhalf W, Jeon CY, Koay EJ, Almario CV, Halloran C, Lennon AM, Costello E. Early detection of pancreatic cancer. *Lancet Gastroenterol Hepatol* 2020; **5**: 698-710 [PMID: 32135127 DOI: 10.1016/S2468-1253(19)30416-9]
- 102 **Singhi AD**, Koay EJ, Chari ST, Maitra A. Early Detection of Pancreatic Cancer: Opportunities and Challenges. *Gastroenterology* 2019; **156**: 2024-2040 [PMID: 30721664 DOI: 10.1053/j.gastro.2019.01.259]
- 103 **Iovanna J**. Implementing biological markers as a tool to guide clinical care of patients with pancreatic cancer. *Transl Oncol* 2021; **14**: 100965 [PMID: 33248412 DOI: 10.1016/j.tranon.2020.100965]
- 104 **Chen C**, Zong S, Liu Y, Wang Z, Zhang Y, Chen B, Cui Y. Profiling of Exosomal Biomarkers for Accurate Cancer Identification: Combining DNA-PAINT with Machine- Learning-Based Classification. *Small* 2019; **15**: e1901014 [PMID: 31478613 DOI: 10.1002/smll.201901014]
- 105 **Zheng H**, Zhao J, Wang X, Yan S, Chu H, Gao M, Zhang X. Integrated Pipeline of Rapid Isolation and Analysis of Human Plasma Exosomes for Cancer Discrimination Based on Deep Learning of MALDI-TOF MS Fingerprints. *Anal Chem* 2022; **94**: 1831-1839 [PMID: 35025210 DOI: 10.1021/acs.analchem.1c04762]
- 106 **Ko J**, Bhagwat N, Yee SS, Ortiz N, Sahmoud A, Black T, Aiello NM, McKenzie L, O'Hara M, Redlinger C, Romeo J, Carpenter EL, Stanger BZ, Issadore D. Combining Machine Learning and Nanofluidic Technology To Diagnose Pancreatic Cancer Using Exosomes. *ACS Nano* 2017; **11**: 11182-11193 [PMID: 29019651 DOI: 10.1021/acs.nano.7b05503]
- 107 **Cristiano S**, Leal A, Phallen J, Fiksel J, Adleff V, Bruhm DC, Jensen SØ, Medina JE, Hruban C, White JR, Palsgrove DN, Niknafs N, Anagnostou V, Forde P, Naidoo J, Marrone K, Brahmer J, Woodward BD, Husain H, van Rooijen KL, Ørntoft MW, Madsen AH, van de Velde CJH, Verheij M, Cats A, Punt CJA, Vink GR, van Grieken NCT, Koopman M, Fijneman RJA, Johansen JS, Nielsen HJ, Meijer GA, Andersen CL, Scharpf RB, Velculescu VE. Genome-wide cell-free DNA fragmentation in patients with cancer. *Nature* 2019; **570**: 385-389 [PMID: 31142840 DOI: 10.1038/s41586-019-1272-6]

- 108 Yu S, Li Y, Liao Z, Wang Z, Qian L, Zhao J, Zong H, Kang B, Zou WB, Chen K, He X, Meng Z, Chen Z, Huang S, Wang P. Plasma extracellular vesicle long RNA profiling identifies a diagnostic signature for the detection of pancreatic ductal adenocarcinoma. *Gut* 2020; **69**: 540-550 [PMID: 31562239 DOI: 10.1136/gutjnl-2019-318860]
- 109 Gao H, Zheng Z, Yue Z, Liu F, Zhou L, Zhao X. Evaluation of serum diagnosis of pancreatic cancer by using surface-enhanced laser desorption/ionization time-of-flight mass spectrometry. *Int J Mol Med* 2012; **30**: 1061-1068 [PMID: 22941199 DOI: 10.3892/ijmm.2012.1113]
- 110 Yu Y, Chen S, Wang LS, Chen WL, Guo WJ, Yan H, Zhang WH, Peng CH, Zhang SD, Li HW, Chen GQ. Prediction of pancreatic cancer by serum biomarkers using surface-enhanced laser desorption/ionization-based decision tree classification. *Oncology* 2005; **68**: 79-86 [PMID: 15864000 DOI: 10.1159/000084824]
- 111 Yang Y, Chen H, Wang D, Luo W, Zhu B, Zhang Z. Diagnosis of pancreatic carcinoma based on combined measurement of multiple serum tumor markers using artificial neural network analysis. *Chin Med J (Engl)* 2014; **127**: 1891-1896 [PMID: 24824251]
- 112 Qiao Z, Ge J, He W, Xu X, He J. Artificial Intelligence Algorithm-Based Computerized Tomography Image Features Combined with Serum Tumor Markers for Diagnosis of Pancreatic Cancer. *Comput Math Methods Med* 2022; **2022**: 8979404 [PMID: 35281945 DOI: 10.1155/2022/8979404]
- 113 Alizadeh Savareh B, Asadzadeh Aghdaie H, Behmanesh A, Bashiri A, Sadeghi A, Zali M, Shams R. A machine learning approach identified a diagnostic model for pancreatic cancer through using circulating microRNA signatures. *Pancreatology* 2020; **20**: 1195-1204 [PMID: 32800647 DOI: 10.1016/j.pan.2020.07.399]
- 114 Whipple AO, Parsons WB, Mullins CR. TREATMENT OF CARCINOMA OF THE AMPULLA OF VATER. *Ann Surg* 1935; **102**: 763-779 [PMID: 17856666 DOI: 10.1097/00000658-193510000-00023]
- 115 Cameron JL, Riall TS, Coleman J, Belcher KA. One thousand consecutive pancreaticoduodenectomies. *Ann Surg* 2006; **244**: 10-15 [PMID: 16794383 DOI: 10.1097/01.sla.0000217673.04165.ca]
- 116 Wojcicki J, Zen Y, Peddu P, Jain R, Patel AG, Atkinson S, Srinivasan P, Rela M, Heaton N, Prachalias A. Benign histology after pancreaticoduodenectomy for suspected malignancy. Lessons to be learned—a single centre experience. *Pol Przegl Chir* 2015; **87**: 6-15 [PMID: 25980043 DOI: 10.1515/pjs-2015-0011]
- 117 Cameron JL, Pitt HA, Yeo CJ, Lillemoe KD, Kaufman HS, Coleman J. One hundred and forty-five consecutive pancreaticoduodenectomies without mortality. *Ann Surg* 1993; **217**: 430-5; discussion 435 [PMID: 8098202 DOI: 10.1097/00000658-199305010-00002]
- 118 Whipple AO. Radical surgery in the treatment of cancer. *Ann Surg* 1950; **131**: 812-823 [PMID: 15413940 DOI: 10.1097/00000658-195006000-00002]
- 119 Are C, Dhir M, Ravipati L. History of pancreaticoduodenectomy: early misconceptions, initial milestones and the pioneers. *HPB (Oxford)* 2011; **13**: 377-384 [PMID: 21609369 DOI: 10.1111/j.1477-2574.2011.00305.x]
- 120 Yarandi SS, Runge T, Wang L, Liu Z, Jiang Y, Chawla S, Woods KE, Keilin S, Willingham FF, Xu H, Cai Q. Increased Incidence of Benign Pancreatic Pathology following Pancreaticoduodenectomy for Presumed Malignancy over 10 Years despite Increased Use of Endoscopic Ultrasound. *Diagn Ther Endosc* 2014; **2014**: 701535 [PMID: 25002810 DOI: 10.1155/2014/701535]
- 121 Ebrahimian S, Singh R, Netaji A, Madhusudhan KS, Homayounieh F, Primak A, Lades F, Saini S, Kalra MK, Sharma S. Characterization of Benign and Malignant Pancreatic Lesions with DECT Quantitative Metrics and Radiomics. *Acad Radiol* 2022; **29**: 705-713 [PMID: 34412944 DOI: 10.1016/j.acra.2021.07.008]
- 122 Ikeda M, Ito S, Ishigaki T, Yamauchi K. Evaluation of a neural network classifier for pancreatic masses based on CT findings. *Comput Med Imaging Graph* 1997; **21**: 175-183 [PMID: 9258595 DOI: 10.1016/s0895-6111(97)00006-2]
- 123 Yang R, Chen Y, Sa G, Li K, Hu H, Zhou J, Guan Q, Chen F. CT classification model of pancreatic serous cystic neoplasms and mucinous cystic neoplasms based on a deep neural network. *Abdom Radiol (NY)* 2022; **47**: 232-241 [PMID: 34636931 DOI: 10.1007/s00261-021-03230-5]
- 124 Ren S, Zhao R, Cui W, Qiu W, Guo K, Cao Y, Duan S, Wang Z, Chen R. Computed Tomography-Based Radiomics Signature for the Preoperative Differentiation of Pancreatic Adenosquamous Carcinoma From Pancreatic Ductal Adenocarcinoma. *Front Oncol* 2020; **10**: 1618 [PMID: 32984030 DOI: 10.3389/fonc.2020.01618]
- 125 Xie T, Wang X, Zhang Z, Zhou Z. CT-Based Radiomics Analysis for Preoperative Diagnosis of Pancreatic Mucinous Cystic Neoplasm and Atypical Serous Cystadenomas. *Front Oncol* 2021; **11**: 621520 [PMID: 34178619 DOI: 10.3389/fonc.2021.621520]
- 126 Ziegelmayr S, Kaissis G, Harder F, Jungmann F, Müller T, Makowski M, Braren R. Deep Convolutional Neural Network-Assisted Feature Extraction for Diagnostic Discrimination and Feature Visualization in Pancreatic Ductal Adenocarcinoma (PDAC) versus Autoimmune Pancreatitis (AIP). *J Clin Med* 2020; **9** [PMID: 33322559 DOI: 10.3390/jcm9124013]
- 127 Gao J, Han F, Wang X, Duan S, Zhang J. Multi-Phase CT-Based Radiomics Nomogram for Discrimination Between Pancreatic Serous Cystic Neoplasm From Mucinous Cystic Neoplasm. *Front Oncol* 2021; **11**: 699812 [PMID: 34926238 DOI: 10.3389/fonc.2021.699812]
- 128 Liang Y, Schott D, Zhang Y, Wang Z, Nasief H, Paulson E, Hall W, Knechtges P, Erickson B, Li XA. Auto-segmentation of pancreatic tumor in multi-parametric MRI using deep convolutional neural networks. *Radiother Oncol* 2020; **145**: 193-200 [PMID: 32045787 DOI: 10.1016/j.radonc.2020.01.021]
- 129 Cui S, Tang T, Su Q, Wang Y, Shu Z, Yang W, Gong X. Radiomic nomogram based on MRI to predict grade of branching type intraductal papillary mucinous neoplasms of the pancreas: a multicenter study. *Cancer Imaging* 2021; **21**: 26 [PMID: 33750453 DOI: 10.1186/s40644-021-00395-6]
- 130 Hussein S, Kandel P, Bolan CW, Wallace MB, Bagci U. Lung and Pancreatic Tumor Characterization in the Deep Learning Era: Novel Supervised and Unsupervised Learning Approaches. *IEEE Trans Med Imaging* 2019; **38**: 1777-1787 [PMID: 30676950 DOI: 10.1109/TMI.2019.2894349]
- 131 Zhu J, Wang L, Chu Y, Hou X, Xing L, Kong F, Zhou Y, Wang Y, Jin Z, Li Z. A new descriptor for computer-aided diagnosis of EUS imaging to distinguish autoimmune pancreatitis from chronic pancreatitis. *Gastrointest Endosc* 2015; **82**: 831-836.e1 [PMID: 25952089 DOI: 10.1016/j.gie.2015.02.043]
- 132 Tonozuka R, Itoi T, Nagata N, Kojima H, Sofuni A, Tsuchiya T, Ishii K, Tanaka R, Nagakawa Y, Mukai S. Deep learning analysis for the detection of pancreatic cancer on endosonographic images: a pilot study. *J Hepatobiliary Pancreat Sci* 2021; **28**: 95-104 [PMID: 32910528 DOI: 10.1002/jhbp.825]
- 133 Marya NB, Powers PD, Chari ST, Gleeson FC, Leggett CL, Abu Dayyeh BK, Chandrasekhara V, Iyer PG, Majumder S, Pearson RK, Petersen BT, Rajan E, Sawas T, Storm AC, Vege SS, Chen S, Long Z, Hough DM, Mara K, Levy MJ. Utilisation of artificial intelligence for the development of an EUS-convolutional neural network model trained to enhance the diagnosis of autoimmune pancreatitis. *Gut* 2021; **70**: 1335-1344 [PMID: 33028668 DOI: 10.1136/gutjnl-2020-322821]

- 134 **Xu W**, Shi J, Li X, Zeng X, Lin Y. Endoscopic ultrasound elastography for differentiation of benign and malignant pancreatic masses: a systemic review and meta-analysis. *Eur J Gastroenterol Hepatol* 2013; **25**: 218-224 [PMID: [23169307](#) DOI: [10.1097/MEG.0b013e32835a7f7c](#)]
- 135 **Gao X**, Wang X. Performance of deep learning for differentiating pancreatic diseases on contrast-enhanced magnetic resonance imaging: A preliminary study. *Diagn Interv Imaging* 2020; **101**: 91-100 [PMID: [31375430](#) DOI: [10.1016/j.diii.2019.07.002](#)]
- 136 **Rigiroli F**, Hoye J, Lerebours R, Lafata KJ, Li C, Meyer M, Lyu P, Ding Y, Schwartz FR, Mettu NB, Zani S Jr, Luo S, Morgan DE, Samei E, Marin D. CT Radiomic Features of Superior Mesenteric Artery Involvement in Pancreatic Ductal Adenocarcinoma: A Pilot Study. *Radiology* 2021; **301**: 610-622 [PMID: [34491129](#) DOI: [10.1148/radiol.2021210699](#)]
- 137 **Chen PT**, Wu T, Wang P, Chang D, Liu KL, Wu MS, Roth HR, Lee PC, Liao WC, Wang W. Pancreatic Cancer Detection on CT Scans with Deep Learning: A Nationwide Population-based Study. *Radiology* 2023; **306**: 172-182 [PMID: [36098642](#) DOI: [10.1148/radiol.220152](#)]
- 138 **Tang A**, Gong P, Fang N, Ye M, Hu S, Liu J, Wang W, Gao K, Wang X, Tian L. Endoscopic ultrasound diagnosis system based on deep learning in images capture and segmentation training of solid pancreatic masses. *Med Phys* 2023; **50**: 4197-4205 [PMID: [36965116](#) DOI: [10.1002/mp.16390](#)]



Published by **Baishideng Publishing Group Inc**
7041 Koll Center Parkway, Suite 160, Pleasanton, CA 94566, USA

Telephone: +1-925-3991568

E-mail: bpgoffice@wjgnet.com

Help Desk: <https://www.f6publishing.com/helpdesk>

<https://www.wjgnet.com>

