

World Journal of *Gastrointestinal Endoscopy*

World J Gastrointest Endosc 2024 February 16; 16(2): 51-97



EDITORIAL

- 51 Editorial article to: Animal experimental study on magnetic anchor technique-assisted endoscopic submucosal dissection of early gastric cancer

Fiori E, Lamazza A, Crocetti D, Sterpetti AV

ORIGINAL ARTICLE

Retrospective Study

- 55 Association between triglyceride-glucose index and colorectal polyps: A retrospective cross-sectional study

Teng YJ, Yang YX, Yang JJ, Lu QY, Shi JY, Xu JH, Bao J, Wang QH

- 64 Retrospective analysis of discordant results between histology and other clinical diagnostic tests on *helicobacter pylori* infection

Qi X, Kuan K, El Jabbour T, Lo Y, Liu Q, Fang Y

- 72 Comparative efficacy and safety between endoscopic submucosal dissection, surgery and definitive chemoradiotherapy in patients with cT1N0M0 esophageal cancer

Luo SA, Sun YY, Zeng YT, Huang CY

Clinical Trials Study

- 83 Coca-Cola consumption *vs* fragmentation in the management of patients with phytobezoars: A prospective randomized controlled trial

Liu FG, Meng DF, Shen X, Meng D, Liu Y, Zhang LY

CASE REPORT

- 91 Treatment of benign rectal stricture caused by repeated anal insertion by endoscopy and balloon dilation: A case report

Liu SH, Kang JC, Hu JM, Chen CY, Lin KH, Pu TW

ABOUT COVER

Editor-in-Chief of *World Journal of Gastrointestinal Endoscopy*, Bing Hu, MD, Professor, Vice Chief, Department of Gastroenterology and Hepatology, West China Hospital of Sichuan University, Chengdu 610000, Sichuan Province, China. hubing@wchscu.edu.cn

AIMS AND SCOPE

The primary aim of *World Journal of Gastrointestinal Endoscopy* (WJGE, *World J Gastrointest Endosc*) is to provide scholars and readers from various fields of gastrointestinal endoscopy with a platform to publish high-quality basic and clinical research articles and communicate their research findings online.

WJGE mainly publishes articles reporting research results and findings obtained in the field of gastrointestinal endoscopy and covering a wide range of topics including capsule endoscopy, colonoscopy, double-balloon enteroscopy, duodenoscopy, endoscopic retrograde cholangiopancreatography, endosonography, esophagoscopy, gastrointestinal endoscopy, gastroscopy, laparoscopy, natural orifice endoscopic surgery, proctoscopy, and sigmoidoscopy.

INDEXING/ABSTRACTING

The WJGE is now abstracted and indexed in Emerging Sources Citation Index (Web of Science), PubMed, PubMed Central, Reference Citation Analysis, China Science and Technology Journal Database, and Superstar Journals Database. The 2023 Edition of Journal Citation Reports® cites the 2022 impact factor (IF) for WJGE as 2.0; IF without journal self cites: 1.9; 5-year IF: 3.3; Journal Citation Indicator: 0.28.

RESPONSIBLE EDITORS FOR THIS ISSUE

Production Editor: Yi-Xuan Cai; Production Department Director: Xu Guo; Editorial Office Director: Jia-Ping Yan.

NAME OF JOURNAL

World Journal of Gastrointestinal Endoscopy

ISSN

ISSN 1948-5190 (online)

LAUNCH DATE

October 15, 2009

FREQUENCY

Monthly

EDITORS-IN-CHIEF

Anastasios Koulaouzidis, Bing Hu, Sang Chul Lee, JooYoung Cho

EDITORIAL BOARD MEMBERS

<https://www.wjgnet.com/1948-5190/editorialboard.htm>

PUBLICATION DATE

February 16, 2024

COPYRIGHT

© 2024 Baishideng Publishing Group Inc

PUBLISHING PARTNER

Digestive Endoscopy Center of West China Hospital, SCU

INSTRUCTIONS TO AUTHORS

<https://www.wjgnet.com/bpg/gerinfo/204>

GUIDELINES FOR ETHICS DOCUMENTS

<https://www.wjgnet.com/bpg/GerInfo/287>

GUIDELINES FOR NON-NATIVE SPEAKERS OF ENGLISH

<https://www.wjgnet.com/bpg/gerinfo/240>

PUBLICATION ETHICS

<https://www.wjgnet.com/bpg/GerInfo/288>

PUBLICATION MISCONDUCT

<https://www.wjgnet.com/bpg/gerinfo/208>

ARTICLE PROCESSING CHARGE

<https://www.wjgnet.com/bpg/gerinfo/242>

STEPS FOR SUBMITTING MANUSCRIPTS

<https://www.wjgnet.com/bpg/GerInfo/239>

ONLINE SUBMISSION

<https://www.f6publishing.com>

PUBLISHING PARTNER's OFFICIAL WEBSITE

<http://www.cd120.com/index.html>



Clinical Trials Study

Coca-Cola consumption vs fragmentation in the management of patients with phytobezoars: A prospective randomized controlled trial

Fu-Guo Liu, De-Feng Meng, Xia Shen, Dan Meng, Ying Liu, Ling-Yun Zhang

Specialty type: Integrative and complementary medicine

Provenance and peer review: Unsolicited article; Externally peer reviewed.

Peer-review model: Single blind

Peer-review report's scientific quality classification

Grade A (Excellent): 0
Grade B (Very good): B
Grade C (Good): 0
Grade D (Fair): 0
Grade E (Poor): 0

P-Reviewer: Anestiadou E, Greece

Received: October 28, 2023

Peer-review started: October 28, 2023

First decision: December 29, 2023

Revised: January 4, 2024

Accepted: January 16, 2024

Article in press: January 16, 2024

Published online: February 16, 2024



Fu-Guo Liu, De-Feng Meng, Xia Shen, Dan Meng, Ying Liu, Department of Gastroenterology, The Affiliated Hospital of Qingdao University, Qingdao 266000, Shandong Province, China

Ling-Yun Zhang, Endoscopy Center, The Affiliated Hospital of Qingdao University, Qingdao 266000, Shandong Province, China

Corresponding author: Ling-Yun Zhang, MA, Adjunct Associate Professor, Endoscopy Center, The Affiliated Hospital of Qingdao University, No. 59 Haier Road, Qingdao 266000, Shandong Province, China. zhanglingyun@qdu.edu.cn

Abstract

BACKGROUND

Gastric phytobezoars (GPBs) are very common in northern China. Combined therapy involving carbonated beverage consumption and endoscopic lithotripsy has been shown to be effective and safe. Existing studies on this subject are often case reports highlighting the successful dissolution of phytobezoars through Coca-Cola consumption. Consequently, large-scale prospective investigations in this domain remain scarce. Therefore, we conducted a randomized controlled trial to examine the effects of Coca-Cola consumption on GPBs.

AIM

To evaluate the impact of Coca-Cola on GPBs, including the dissolution rate, medical expenses, ulcer rate, and operation time.

METHODS

A total of 160 consecutive patients diagnosed with GPBs were allocated into two groups (a control group and an intervention group) through computer-generated randomization. Patients in the intervention group received a Coca-Cola-based regimen (Coca-Cola 2000-4000 mL per day for 7 d), while those in the control group underwent emergency fragmentation.

RESULTS

Complete dissolution of GPBs was achieved in 100% of the patients in the intervention group. The disparity in expenses between the control group and intervention group ($t = 25.791$, $P = 0.000$) was statistically significant, and the difference in gastric ulcer occurrence between the control group and intervention

group ($\chi^2 = 6.181$, $P = 0.013$) was also statistically significant.

CONCLUSION

Timely ingestion of Coca-Cola yields significant benefits, including a complete dissolution rate of 100%, a low incidence of gastric ulcers, no need for fragmentation and reduced expenses.

Key Words: Coca-Cola; Bezoars; Solubility; Lithotripsy; Gastroscopy

©The Author(s) 2024. Published by Baishideng Publishing Group Inc. All rights reserved.

Core Tip: The timely and sufficient ingestion of Coca-Cola by patients with phytobezoars yields significant benefits, including a high rate of complete dissolution, a low incidence of gastric ulcers, no need for surgery, and reduced medical expenses.

Citation: Liu FG, Meng DF, Shen X, Meng D, Liu Y, Zhang LY. Coca-Cola consumption vs fragmentation in the management of patients with phytobezoars: A prospective randomized controlled trial. *World J Gastrointest Endosc* 2024; 16(2): 83-90

URL: <https://www.wjgnet.com/1948-5190/full/v16/i2/83.htm>

DOI: <https://dx.doi.org/10.4253/wjge.v16.i2.83>

INTRODUCTION

Gastric bezoars are defined as foreign objects that develop within the gastrointestinal tract due to the accumulation of ingested material[1]. Specifically, gastric phytobezoars (GPBs) were consisted of indigestible cellulose, tannin, and lignin derived from the consumption of persimmons, hawthorn fruits, or date plum persimmons. Tannin undergoes polymerization, resulting in a coagulum that includes protein, pepsins, cellulose, and hemicellulose, forming bezoars[2]. In recent years, a combined therapy approach involving litholysis with carbonated beverages and endoscopic lithotripsy has emerged as an effective and safe treatment for GPBs[3]. However, despite the excellent outcomes, this therapeutic approach causes significant discomfort and has high costs and a prolonged operation time[4]. Notably, in 2013, Ladas *et al*[5] proposed the consumption of Coca-Cola as a first-line treatment option, highlighting its ability to effectively dissolve GPBs. Coca-Cola consumption has been recognized as a particularly safe, cost-effective, and well-tolerated intervention [6]. While case reports documenting the successful dissolution of phytobezoars exist, large-scale clinical studies in this domain are scarce. Therefore, we conducted a randomized controlled trial to evaluate the impact of Coca-Cola consumption on GPBs, including the dissolution rate, medical expenses, ulcer rate, and operation time.

MATERIALS AND METHODS

Study design and sample estimation

This meticulously designed study followed a prospective, single-blinded approach with balanced randomization at a 1:1 ratio. Ethical approval for the study was obtained from the Institutional Review Board of the Affiliated Hospital of Qingdao University (QYFYWZLL 26293), and the study was registered in the ClinicalTrial.gov Protocol Registration System with the registration number NCT05645263. The study was conducted at the Affiliated Hospital of Qingdao University from January 1st, 2018, to December 1st, 2022. All participants who expressed willingness to take part in the study provided digital informed consent. The study strictly adhered to the principles outlined in the World Medical Association Declaration of Helsinki.

The sample size was calculated using the following website: <http://riskcalc.org:3838/samplesize/>. Ultimately, a total of 160 patients (2 arms) were enrolled in the study and randomly allocated to the control or intervention group at a 1:1 ratio.

Participants

The study employed specific inclusion and exclusion criteria to ensure the selection of appropriate participants. The inclusion criteria encompassed the absence of contraindications (such as severe heart diseases, suspected shock, or digestive tract perforation), suspected mental diseases, or infectious diseases of the digestive tract that could hinder gastroscopy. Additionally, participants were required to have a bezoar history of no more than 14 d, no history of peptic ulcer diseases and an age range between 14 and 80 years. The exclusion criteria comprised individuals who had history of upper gastrointestinal surgery, underwent previous therapies before enrollment or individuals who did not consent to random allocation.

Equipment and consumables

The following instruments and materials were used in this study: CV-290 (Olympus Co. Ltd), GIF-Q260J (Olympus Co. Ltd), the WF-DTH fragmentation kit (Wilson Shanghai Co. Ltd), disposable snares (Micro-Tech Nanjing Co. Ltd), and Coca-Cola.

Method

A total of 160 consecutive patients were enrolled in the study by doctors in the outpatient department and randomly assigned at a 1:1 ratio to either the control group, which underwent emergency fragmentation with gastroscopy, or the intervention group, which consumed Coca-Cola in the endoscopy center. The enrollment period spanned from January 1, 2018, to December 1, 2022. Randomization was conducted by the investigator using a web-based computer-generated random number system (www.randomization.com). In the intervention group, patients consumed Coca-Cola to treat GPBs. The amount consumed was 250 mL–500 mL every 2 h until bedtime, tailored to individual health conditions and lifestyle habits. Close attention was given to the patients' bowel movements to assess the excretion of bezoars (which are usually harder than normal stool and not scattered by flushing water). The duration of Coca-Cola ingestion was 7 d for the intervention group. Upon completion of the Coca-Cola therapy, patients underwent another endoscopy because endoscopy can observe the mucosa of the stomach directly and further intervention if fragmentation was necessary. The endoscopist recorded all images for every patient. The volume of GPBs was estimated under endoscopy and the evaluation for gastric ulcer was performed in the first endoscopy. Prior to endoscopy, all patients provided digital informed consent.

Statistical analysis was performed using SPSS version 22 (IBM, Inc. Armonk, NY, United States). Continuous variables are presented as the mean and standard deviation (SD). Independent samples *t* test was utilized for continuous variable analysis. Categorical variables were compared using the chi-square test or Fisher's exact test, as appropriate. A significance level of $P < 0.05$ was considered statistically meaningful.

RESULTS

The CONSORT 2010 Flow Diagram is illustrated in [Figure 1](#). Atypical images pertaining to the study findings are shown in [Figures 2 and 3](#). The images of [Figures 2 and 3](#) are all from the intervention group. The patient in [Figure 2](#) has a GPB history of 7 d and the patient in [Figure 3](#) has a GPBs history of 14 d. The former 2 images of [Figure 2](#) shows the GPBs in the stomach and an ulcer which is shallow and bleeding located in the angulus in the first endoscopy and the last image shows nothing anomaly except the ulcer in the second endoscopy after Coca-Cola therapy. The former 2 images of [Figure 3](#) shows the GPBs in the stomach and a deep ulcer located in the angulus in the first endoscopy and the last image shows nothing anomaly except the shallower ulcer in the second endoscopy after Coca-Cola therapy.

General data

Data on age, bezoar volume and medical expenses are presented in [Table 1](#). There were no statistically significant differences in age or bezoar volume between the 2 groups, but there was a significant difference in medical expenses.

Dissolution rate

Remarkably, a complete dissolution rate of 100% was achieved in the intervention group, highlighting the effectiveness of the intervention in treating GPBs.

Medical expenses

[Table 1](#) provides information regarding the medical expenses incurred during the study. The statistical analysis revealed significant differences in the medical expenses between the control and intervention groups (1540.01 ± 250.81 RMB *vs* 27.59 ± 7.96 RMB, $t = 25.971$, $P = 0.000$).

Operation time

The gastric fragmentation time of the control group was 31.23 ± 9.62 min; however, no patients had gastric fragmentation in the intervention group.

Gastric ulcer rate

Information on the occurrence of gastric ulcers between the control and intervention groups is presented in [Table 2](#). The rate of gastric ulcer occurrence was 86.25% in the control group and 70.0% in the intervention group. Notably, a statistically significant difference was observed between the control group and intervention group in terms of gastric ulcer occurrence ($\chi^2 = 6.181$, $P = 0.021$). The results shed light on the varying rates of gastric ulcer occurrence associated with different treatment approaches.

DISCUSSION

GPBs often arise from the ingestion of persimmons, hawthorn fruits, or date plums on an empty stomach. They can also

Table 1 Comparisons between the control group and intervention group

Group	n	Age (yr)	Volume of bezoar (cm × cm)	Expenses (RMB)
Control group	80	53.80 ± 11.76	18.07 ± 8.16	1540.01 ± 520.381
Intervention group	80	50.79 ± 12.95	18.38 ± 8.31	27.59 ± 7.96
t value		1.54	-0.233	25.791
P value		0.327	0.487	0.000

Table 2 Comparison of the gastric ulcer rate between the control group and intervention group

Group	n	Ulcer	No ulcer	χ ²	P value
Control group	80	69	11	6.181	0.013
Intervention group	80	56	24		

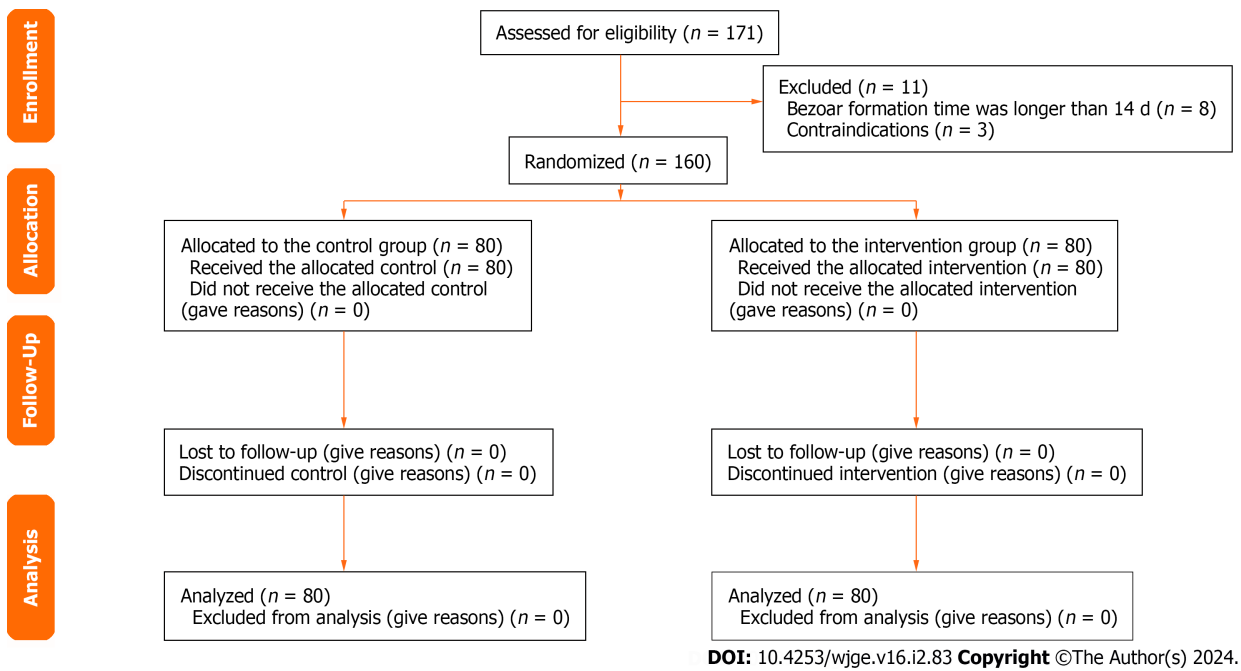
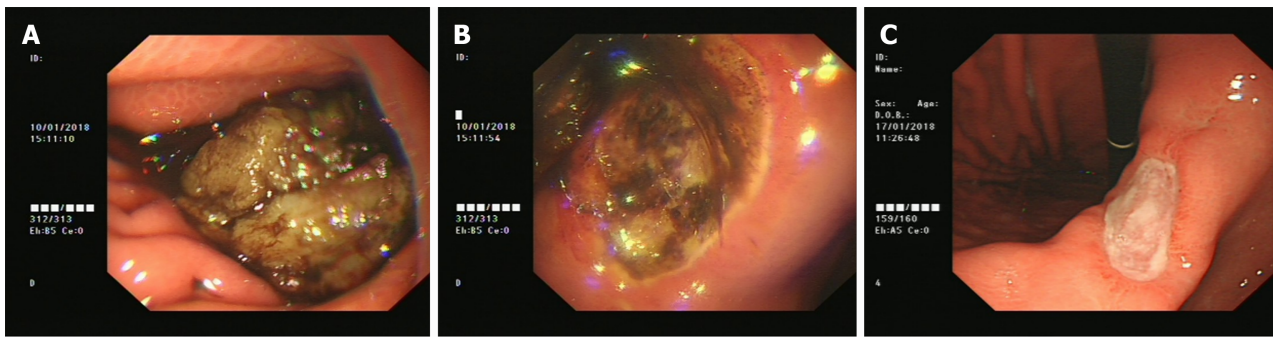


Figure 1 CONSORT 2010 flow diagram.

be associated with conditions such as diabetic gastroparesis[7] and endoscopic sclerotherapy, which can lead to delayed gastric emptying[8,9]. In the present study[10], patients were successfully treated using a combination of endoscopic fragmentation and pharmacotherapy. While this combined therapy has been indicated to be effective, it involves high costs, discomfort, and long operation time.

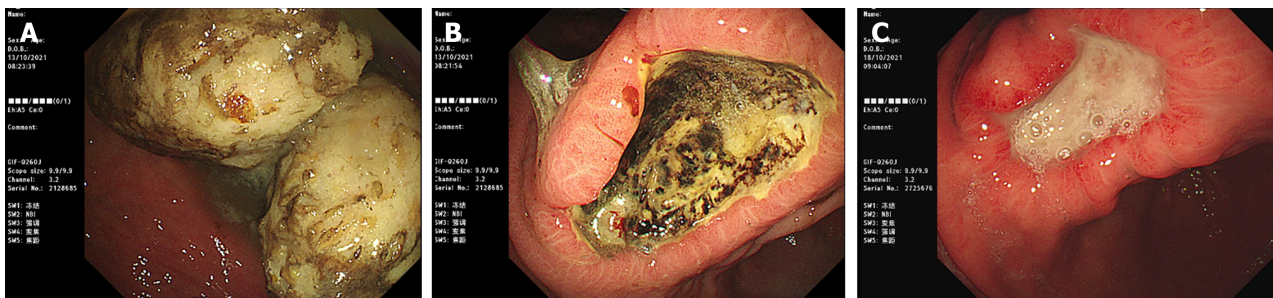A significant milestone in the use of Coca-Cola for phytobezoar treatment was the publication of the article "Gastric phytobezoars may be treated by nasogastric cola lavage" in 2002 by Ladas *et al*[11]. This study documented complete success in the treatment of five phytobezoar patients using Coca-Cola lavage. In a systematic review conducted by Ladas *et al*[5] in 2013, it was concluded that Coca-Cola can effectively dissolve GPBs and could be considered a first-line treatment option, with a complete dissolution rate of 50% and a favorable outcome observed in 91.3% of patients. It has been reported that the consumption of 3 Liters of Coca-Cola every 12 h has a satisfactory effect on bezoar lysis[5,12,13]. Our study demonstrated a complete phytobezoar dissolution rate of 100%, which aligns with previous findings.

The article "In Vitro Analysis of Gastric Phytobezoar Dissolubility by Cola, Cola Zero, Cellulose and Papain" reported that Coca-Cola exhibited the highest phytolytic activity, with an 18.5% ± 5.8% decrease in weight, while Coke Zero also demonstrated substantial phytolytic action (16.1% ± 0.4%). In patients who consumed carbonated beverages, bezoars were easily broken when grasped with forceps, which was not observed in patients who consumed water, cellulose or papain. These findings provide scientific evidence supporting the efficacy of Coca-Cola in bezoar lysis[14]. Although the exact mechanism of the dissolution of bezoars by Coca-Cola has not been fully explained, it may be attributed to the low acidity. The pH of Coca-Cola is 1.9, which is more acidic than that of 0.010 mol/L hydrochloric acid (pH 2.0). Furthermore, the pH of Coca-Cola remains relatively stable (2.0) even after 3 h of exposure to room air[12]. The dissolution effect



DOI: 10.4253/wjge.v16.i2.83 Copyright ©The Author(s) 2024.

Figure 2 Image of gastric phytobezoars in a patient with a gastric phytobezoars history of 7 d. A: Gastric phytobezoars (GPBs) located in the stomach; B: The gastric ulcer, which is shallow and bleeding located in the angulus of the stomach; C: No GPBs or bleeding in the stomach was observed after Coca-Cola therapy.



DOI: 10.4253/wjge.v16.i2.83 Copyright ©The Author(s) 2024.

Figure 3 Image of gastric phytobezoars in another patient with a gastric phytobezoars history of 14 d. A: Gastric phytobezoars (GPBs) located in the stomach; B: A deep gastric ulcer is located in the angulus of the stomach; C: No GPBs was observed and the gastric ulcer became smaller and shallower after Coca-Cola therapy.

of Coca-Cola on bezoars may be attributed to carbonic and phosphoric acids, which are believed to be important for fiber digestion[7,12,13,15]. Acetic acid (CH_3COOH) reacts with calcium phosphate to form calcium acetate [$\text{Ca}(\text{CH}_3\text{COO})_2$][2] and phosphoric acid, both of which are water-soluble[16]. Additionally, the mucolytic effect of NaHCO_3 and the presence of CO_2 bubbles may contribute to the mechanism of dissolution[12]. The consumption of a large volume of Coca-Cola can enhance gastrointestinal motility, leading to the rapid decomposition and elimination of phytobezoars. "Cola lysis" serves as a clinically appropriate term to describe the mechanism of phytobezoar dissolution, signifying the dissolution and lysis of the accumulated mass[7].

In terms of adverse effects, short-term Coca-Cola therapy may cause temporary bloating, reflux, and gastritis. However, the long-term use of Coca-Cola can lead to tooth decay and osteoporosis[17,18]. These issues should be taken into account when utilizing Coca-Cola as a therapeutic intervention for GPBs. The participants in our study had no obvious side effects because of the short regimen.

Intestinal obstructions caused by phytobezoars are a rare occurrence in adults with normally functioning intestinal tracts[19]. However, in cases where ileus is present or when patients have refractory bezoars, surgical removal becomes necessary[20]. Avoiding severe complications associated with phytobezoars poses a challenge for medical professionals. Partially dissolved bezoars have the potential to pass through the pylorus and obstruct the small bowel, particularly in the presence of ankylosis, enterostasis, or poor gastric motility[13,21-27]. Therefore, it is crucial for patients receiving Coca-Cola therapy to be vigilant about their stool and monitor symptoms of ileus. Once a patient is confident that the bezoar has been discharged in the stool, they can discontinue the Coca-Cola diet to prevent small bowel obstruction. The duration of Coca-Cola consumption can be prolonged as necessary without any set limitations. Additionally, a low-fiber diet during Coca-Cola therapy is recommended to support the treatment process.

GPBs as foreign bodies located in the stomach, can cause mechanical friction and/or compression, leading to erosion, ulceration, or bleeding of the gastric mucosa[2]. The incidence of gastric ulcers associated with phytobezoars is approximately 80%[28]. The presence of a gastric bezoar can result in gastric mucosal injury, but as the bezoar dissolves, the gastric mucosa becomes less affected. In our study, the gastric ulcer occurrence rate in the intervention group (70.00%) was lower than that in the control group (86.25%). This lower rate of gastric ulcers in the intervention group may be attributed to the consumption of Coca-Cola. Coca-Cola softens bezoars[29], and the gastric mucosa becomes less irritated once bezoars are softened. Gastric ulcers can manifest as single or multiple lesions located in various regions of the stomach, including the angulus, body, or antrum. The overall occurrence of gastric ulcers in our study was 78.13%, which aligns with previous findings. The timely administration of Coca-Cola appears to yield better outcomes, as the occurrence rate of gastric ulcers decreases with the dissolution of bezoars.

CONCLUSION

Treating GPBs with Coca-Cola consumption offers a practical, cost-effective, and effective approach. Patients with GPBs should consume Coca-Cola at the earliest opportunity to minimize the occurrence of gastric ulcers, making it a routine practice in clinical settings. However, the optimal dosage and duration of Coca-Cola ingestion for treating GPBs have not been definitively established through large-scale experimental studies. Therefore, further extensive research is warranted to investigate and establish guidelines regarding the appropriate dose and duration of Coca-Cola consumption in the treatment of GPBs.

ARTICLE HIGHLIGHTS

Research background

With the publication of Ladas SD's article (Systematic review: Coca-Cola can effectively dissolve gastric phytobezoars as a first-line treatment), Coca-Cola dissolution therapy in patients with gastric phytobezoars (GPBs) is gradually being accepted in clinical practice. However, existing studies on this subject are often case reports highlighting the successful dissolution of phytobezoars using Coca-Cola. Consequently, large-scale prospective investigations in this domain remain scarce. Therefore, we conducted a randomized controlled trial to examine the effects of Coca-Cola administration on GPBs.

Research motivation

This study evaluated the intervention treatment of patients with Coca-Cola dissolution therapy, including the complete resolution rate, gastric ulcer rate, medical expenses and endoscopic operation time. Additionally, this study aimed to find a treatment plan that can attain the expected results and minimize the side effects.

Research objectives

The aim was to evaluate the impact of Coca-Cola on GPBs, including the dissolution rate, medical expenses, ulcer rate, and operation time.

Research methods

In this study, a total of 160 consecutive patients diagnosed with GPBs were allocated into two groups (a control group and an intervention group) through computer-generated randomization. Patients in the intervention group were receive a Coca-Cola-based regimen (Coca-Cola 2000-4000 mL per day for 7 d), while those in the control group underwent emergency fragmentation.

Research results

Complete dissolution of GPBs was achieved in 100% of the patients in the intervention group. The disparity in expenses between the control group and intervention group ($t = 25.791$, $P = 0.000$) was statistically significant, and the difference in the gastric ulcer occurrence rate between the control group and intervention group ($\chi^2 = 6.181$, $P = 0.013$) was also statistically significant.

Research conclusions

Timely ingestion of Coca-Cola yields significant benefits, including a complete dissolution rate of 100%, a low incidence of gastric ulcers, no need for fragmentation and reduced expenses.

Research perspectives

This treatment is beneficial for relieving patients' pain, reducing the need for emergency gastroscopy, decreasing medical expenses and lowering the gastric ulcer rate. Therefore, Coca-Cola dissolution therapy for GPBs is a safe, feasible, simple and effective method that is worthy of clinical application and promotion.

FOOTNOTES

Author contributions: Liu FG designed the study and reviewed the manuscript. Liu Y and Shen X collected the data; Meng DF analyzed the data. Meng D and Zhang LY wrote and drafted the manuscript; all authors have read and approve the final manuscript.

Institutional review board statement: This study was approved by the Institutional Review Board of the Affiliated Hospital of Qingdao University (QYFYWZLL 26293).

Clinical trial registration statement: The study was registered in the ClinicalTrial.gov Protocol Registration System, registration No. NCT05645263.

Informed consent statement: All study participants or their legal guardian provided informed written consent about personal and

medical data collection prior to study enrolment.

Conflict-of-interest statement: All the authors declare that they have no conflicts of interest regarding this work.

Data sharing statement: All data available from the corresponding author at zhanglingyun@qdu.edu.cn

CONSORT 2010 statement: The authors have read the CONSORT 2010 statement, and the manuscript was prepared and revised according to the CONSORT 2010 statement.

Open-Access: This article is an open-access article that was selected by an in-house editor and fully peer-reviewed by external reviewers. It is distributed in accordance with the Creative Commons Attribution NonCommercial (CC BY-NC 4.0) license, which permits others to distribute, remix, adapt, build upon this work non-commercially, and license their derivative works on different terms, provided the original work is properly cited and the use is non-commercial. See: <https://creativecommons.org/licenses/by-nc/4.0/>

Country/Territory of origin: China

ORCID number: Fu-Guo Liu 0000-0003-1507-7257; Ling-Yun Zhang 0000-0001-5855-096X.

S-Editor: Liu JH

L-Editor: A

P-Editor: Cai YX

REFERENCES

- Awawda A, Al Ashhab H, Shammass I, Al Mohtasib M, Abu Asbeh Y. Endoscopic Management of Unusual Bezoar in a Prader-Willi Syndrome Patient. *Cureus* 2022; **14**: e29900 [PMID: 36348828 DOI: 10.7759/cureus.29900]
- Zhang RL, Yang ZL, Fan BG. Huge gastric disopyro bezoar: a case report and review of literatures. *World J Gastroenterol* 2008; **14**: 152-154 [PMID: 18176981 DOI: 10.3748/wjg.14.152]
- Hu X, Guo Q, Xu QW, Zhang RY, Yang YC, Han SX, Liu WH. Novel endoscopic tangential sawing technique in treatment of giant gastric bezoars: a retrospective single-center study (with video). *Gastrointest Endosc* 2022; **96**: 150-154 [PMID: 35016893 DOI: 10.1016/j.gie.2021.12.040]
- Tabesh E, Dehghan A, Tahmasebi M, Javadi N. Gastric phytobezoars as a very unusual cause of gastric outlet obstruction. *J Res Med Sci* 2021; **26**: 25 [PMID: 34221054 DOI: 10.4103/jrms.JRMS_115_20]
- Ladas SD, Kamberoglou D, Karamanolis G, Vlachogiannakos J, Zouboulis-Vafiadis I. Systematic review: Coca-Cola can effectively dissolve gastric phytobezoars as a first-line treatment. *Aliment Pharmacol Ther* 2013; **37**: 169-173 [PMID: 23252775 DOI: 10.1111/apt.12141]
- Nelson A, Romo N, Levanon D, Blumfield E, Gershel J. Gastric Bezoar Treatment Using Oral Coca-Cola. *Clin Pediatr (Phila)* 2017; **56**: 485-487 [PMID: 28006980 DOI: 10.1177/0009922816684608]
- Whitson BA, Asolati M, Kandaswamy R, Sutherland DE. Diabetic gastroparesis-associated bezoar resolution via "cola-lysis". *Clin Transplant* 2008; **22**: 242-244 [PMID: 18339146 DOI: 10.1111/j.1399-0012.2007.00763.x]
- Bi D, Choi C, League J, Camilleri M, Prichard DO. Food Residue During Esophagogastrroduodenoscopy Is Commonly Encountered and Is Not Pathognomonic of Delayed Gastric Emptying. *Dig Dis Sci* 2021; **66**: 3951-3959 [PMID: 33237388 DOI: 10.1007/s10620-020-06718-0]
- Davion T, Delamarre J, Reix N, Lambert A, Capron JP. Gastric bezoar: another side effect of endoscopic variceal sclerotherapy. *Scand J Gastroenterol* 1989; **24**: 818-820 [PMID: 2799285 DOI: 10.3109/00365528909089220]
- Gayà J, Barranco L, Llompert A, Reyes J, Obrador A. Persimmon bezoars: a successful combined therapy. *Gastrointest Endosc* 2002; **55**: 581-583 [PMID: 11923779 DOI: 10.1067/mge.2002.122332]
- Ladas SD, Triantafyllou K, Tzathas C, Tassios P, Rokkas T, Raptis SA. Gastric phytobezoars may be treated by nasogastric Coca-Cola lavage. *Eur J Gastroenterol Hepatol* 2002; **14**: 801-803 [PMID: 12169994 DOI: 10.1097/00042737-200207000-00017]
- Komaki Y, Kanmura S, Tanaka A, Nakashima M, Komaki F, Iwaya H, Arima S, Sasaki F, Nasu Y, Tanoue S, Hashimoto S, Ido A. Cola Dissolution Therapy via Ileus Tube Was Effective for Ileus Secondary to Small Bowel Obstruction Induced by an Enterolith. *Intern Med* 2019; **58**: 2473-2478 [PMID: 31118399 DOI: 10.2169/internalmedicine.2745-19]
- Lee BJ, Park JJ, Chun HJ, Kim JH, Yeon JE, Jeon YT, Kim JS, Byun KS, Lee SW, Choi JH, Kim CD, Ryu HS, Bak YT. How good is cola for dissolution of gastric phytobezoars? *World J Gastroenterol* 2009; **15**: 2265-2269 [PMID: 19437568 DOI: 10.3748/wjg.15.2265]
- Iwamuro M, Kawai Y, Shiraha H, Takaki A, Okada H, Yamamoto K. In vitro analysis of gastric phytobezoar dissolubility by coca-cola, coca-cola zero, cellulase, and papain. *J Clin Gastroenterol* 2014; **48**: 190-191 [PMID: 24045274 DOI: 10.1097/MCG.0b013e3182a39116]
- Okamoto Y, Yamauchi M, Sugihara K, Kato H, Nagao M. Is coca-cola effective for dissolving phytobezoars? *Eur J Gastroenterol Hepatol* 2007; **19**: 611-612 [PMID: 17556912 DOI: 10.1097/01.meg.0000252638.18915.45]
- McCloy RF, Greenberg GR, Baron JH. Duodenal pH in health and duodenal ulcer disease: effect of a meal, Coca-Cola, smoking, and cimetidine. *Gut* 1984; **25**: 386-392 [PMID: 6706217 DOI: 10.1136/gut.25.4.386]
- Maladkar SR, Yadav P, Muniraja ANA, Uchil GS, George LV, Augustine D, Rao RS, Patil S, Sowmya SV, Haragannavar VC. Erosive Effect of Acidic Beverages and Dietary Preservatives on Extracted Human Teeth-An In Vitro Analysis. *Eur J Dent* 2022; **16**: 919-929 [PMID: 35436789 DOI: 10.1055/s-0041-1742131]
- Mondelli J, Sene F, Ramos RP, Benetti AR. Tooth structure and fracture strength of cavities. *Braz Dent J* 2007; **18**: 134-138 [PMID: 17982553 DOI: 10.1590/S0103-64402007000200009]
- Pitiakoudis M, Tsaroucha A, Mimidis K, Constantinidis T, Anagnostoulis S, Stathopoulos G, Simopoulos C. Esophageal and small bowel obstruction by occupational bezoar: report of a case. *BMC Gastroenterol* 2003; **3**: 13 [PMID: 12795814 DOI: 10.1186/1471-230X-3-13]

- 20 **Iwamuro M**, Okada H, Matsueda K, Inaba T, Kusumoto C, Imagawa A, Yamamoto K. Review of the diagnosis and management of gastrointestinal bezoars. *World J Gastrointest Endosc* 2015; **7**: 336-345 [PMID: [25901212](#) DOI: [10.4253/wjge.v7.i4.336](#)]
- 21 **Aydin I**, Sengul I, Sengul D. Phytobezoar: An Unusual Condition Leading to Small Bowel Obstruction. *Cureus* 2022; **14**: e23885 [PMID: [35402121](#) DOI: [10.7759/cureus.23885](#)]
- 22 **Bouali M**, Ballati A, El Bakouri A, Elhattabi K, Bensardi F, Fadil A. Phytobezoar: An unusual cause of small bowel obstruction. *Ann Med Surg (Lond)* 2021; **62**: 323-325 [PMID: [33552491](#) DOI: [10.1016/j.amsu.2021.01.048](#)]
- 23 **Kannan NL**, Singaraju H, Sim SW. Laparoscopic-assisted removal of gastric trichobezoar: a novel technique to reduce operative complications and time. *J Pediatr Surg* 2013; **48**: 1826-1827 [PMID: [23932631](#) DOI: [10.1016/j.jpedsurg.2013.05.069](#)]
- 24 **Serpa E**, Luciano E, Pacheco F, Solh W. Phytobezoar causing small bowel obstruction in a patient with Crohn's disease: A case report. *Int J Surg Case Rep* 2022; **99**: 107615 [PMID: [36108380](#) DOI: [10.1016/j.ijscr.2022.107615](#)]
- 25 **Somuncu E**, Solak IHA. Colonic Obstruction Secondary to Phytobezoar Caused by Vitex Agnus-Castus Seeds: A Case Report. *J Coll Physicians Surg Pak* 2022; **32**: S115-S117 [PMID: [36210666](#) DOI: [10.29271/jcpsp.2022.Supp2.S115](#)]
- 26 **Toka B**, Eminler AT, Karacaer C, Uslan MI, Koksas AS, Parlak E. A Simple Method for Endoscopic Treatment of Large Gastric Phytobezoars: "Hand-Made Bezoaratome". *Turk J Gastroenterol* 2021; **32**: 141-147 [PMID: [33960937](#) DOI: [10.5152/tjg.2021.20199](#)]
- 27 **Wei KY**, Sung CC, Lin SH. Phytobezoar-induced small bowel obstruction in an elderly patient undergoing dialysis: a case report. *J Int Med Res* 2020; **48**: 300060520962942 [PMID: [33103517](#) DOI: [10.1177/0300060520962942](#)]
- 28 **Liu LN**, Wang L, Jia SJ, Wang P. Clinical Features, Risk Factors, and Endoscopic Treatment of Bezoars: A Retrospective Analysis from a Single Center in Northern China. *Med Sci Monit* 2020; **26**: e926539 [PMID: [33027245](#) DOI: [10.12659/MSM.926539](#)]
- 29 **Park SE**, Ahn JY, Jung HY, Na S, Park SJ, Lim H, Choi KS, Lee JH, Kim DH, Choi KD, Song HJ, Lee GH, Kim JH. Clinical outcomes associated with treatment modalities for gastrointestinal bezoars. *Gut Liver* 2014; **8**: 400-407 [PMID: [25071905](#) DOI: [10.5009/gnl.2014.8.4.400](#)]



Published by **Baishideng Publishing Group Inc**
7041 Koll Center Parkway, Suite 160, Pleasanton, CA 94566, USA

Telephone: +1-925-3991568

E-mail: office@baishideng.com

Help Desk: <https://www.f6publishing.com/helpdesk>

<https://www.wjgnet.com>

