

World Journal of *Gastrointestinal Oncology*

World J Gastrointest Oncol 2024 April 15; 16(4): 1091-1675



EDITORIAL

- 1091** Parallel pathways: A chronicle of evolution in rectal and breast cancer surgery
Pesce A, Fabbri N, Iovino D, Feo CV
- 1097** Hepatitis B virus genotypes in precision medicine of hepatitis B-related hepatocellular carcinoma: Where we are now
Sukowati CHC, Jayanti S, Turyadi T, Muljono DH, Tiribelli C

REVIEW

- 1104** Novel milestones for early esophageal carcinoma: From bench to bed
Qi JH, Huang SL, Jin SZ
- 1119** Colorectal cancer screening: A review of current knowledge and progress in research
Lopes SR, Martins C, Santos IC, Teixeira M, Gamito É, Alves AL
- 1134** New avenues for the treatment of immunotherapy-resistant pancreatic cancer
Silva LGO, Lemos FFB, Luz MS, Rocha Pinheiro SL, Calmon MDS, Correa Santos GL, Rocha GR, de Melo FF

MINIREVIEWS

- 1154** Present situation of minimally invasive surgical treatment for early gastric cancer
Li CY, Wang YF, Luo LK, Yang XJ
- 1166** Mixed neuroendocrine non-neuroendocrine neoplasms in gastroenteropancreatic tract
Díaz-López S, Jiménez-Castro J, Robles-Barraza CE, Ayala-de Miguel C, Chaves-Conde M
- 1180** Esophageal cancer screening, early detection and treatment: Current insights and future directions
Qu HT, Li Q, Hao L, Ni YJ, Luan WY, Yang Z, Chen XD, Zhang TT, Miao YD, Zhang F

ORIGINAL ARTICLE

Retrospective Cohort Study

- 1192** Pre-operative enhanced magnetic resonance imaging combined with clinical features predict early recurrence of hepatocellular carcinoma after radical resection
Chen JP, Yang RH, Zhang TH, Liao LA, Guan YT, Dai HY
- 1204** Clinical analysis of multiple primary gastrointestinal malignant tumors: A 10-year case review of a single-center
Zhu CL, Peng LZ

Retrospective Study

- 1213** Predictive model for non-malignant portal vein thrombosis associated with cirrhosis based on inflammatory biomarkers
Nie GL, Yan J, Li Y, Zhang HL, Xie DN, Zhu XW, Li X
- 1227** Predictive modeling for postoperative delirium in elderly patients with abdominal malignancies using synthetic minority oversampling technique
Hu WJ, Bai G, Wang Y, Hong DM, Jiang JH, Li JX, Hua Y, Wang XY, Chen Y
- 1236** Efficacy and predictive factors of transarterial chemoembolization combined with lenvatinib plus programmed cell death protein-1 inhibition for unresectable hepatocellular carcinoma
Ma KP, Fu JX, Duan F, Wang MQ
- 1248** Should we perform sigmoidoscopy for colorectal cancer screening in people under 45 years?
Leong W, Guo JQ, Ning C, Luo FF, Jiao R, Yang DY
- 1256** Computed tomography-based radiomics diagnostic approach for differential diagnosis between early- and late-stage pancreatic ductal adenocarcinoma
Ren S, Qian LC, Cao YY, Daniels MJ, Song LN, Tian Y, Wang ZQ
- 1268** Prognostic analysis of related factors of adverse reactions to immunotherapy in advanced gastric cancer and establishment of a nomogram model
He XX, Du B, Wu T, Shen H

Clinical Trials Study

- 1281** Safety and efficacy of a programmed cell death 1 inhibitor combined with oxaliplatin plus S-1 in patients with Borrmann large type III and IV gastric cancers
Bao ZH, Hu C, Zhang YQ, Yu PC, Wang Y, Xu ZY, Fu HY, Cheng XD

Observational Study

- 1296** Computed tomography radiogenomics: A potential tool for prediction of molecular subtypes in gastric stromal tumor
Yin XN, Wang ZH, Zou L, Yang CW, Shen CY, Liu BK, Yin Y, Liu XJ, Zhang B
- 1309** Application of texture signatures based on multiparameter-magnetic resonance imaging for predicting microvascular invasion in hepatocellular carcinoma: Retrospective study
Nong HY, Cen YY, Qin M, Qin WQ, Xie YX, Li L, Liu MR, Ding K
- 1319** Causal roles of gut microbiota in cholangiocarcinoma etiology suggested by genetic study
Chen ZT, Ding CC, Chen KL, Gu YJ, Lu CC, Li QY
- 1334** Is recovery enhancement after gastric cancer surgery really a safe approach for elderly patients?
Li ZW, Luo XJ, Liu F, Liu XR, Shu XP, Tong Y, Lv Q, Liu XY, Zhang W, Peng D
- 1344** Establishment of a cholangiocarcinoma risk evaluation model based on mucin expression levels
Yang CY, Guo LM, Li Y, Wang GX, Tang XW, Zhang QL, Zhang LF, Luo JY

- 1361** Effectiveness of fecal DNA syndecan-2 methylation testing for detection of colorectal cancer in a high-risk Chinese population

Luo WF, Jiao YT, Lin XL, Zhao Y, Wang SB, Shen J, Deng J, Ye YF, Han ZP, Xie FM, He JH, Wan Y

Clinical and Translational Research

- 1374** Clinical and socioeconomic determinants of survival in biliary tract adenocarcinomas

Sahyoun L, Chen K, Tsay C, Chen G, Protiva P

- 1384** Risk factors, prognostic factors, and nomograms for distant metastasis in patients with diagnosed duodenal cancer: A population-based study

Shang JR, Xu CY, Zhai XX, Xu Z, Qian J

- 1421** NOX4 promotes tumor progression through the MAPK-MEK1/2-ERK1/2 axis in colorectal cancer

Xu YJ, Huo YC, Zhao QT, Liu JY, Tian YJ, Yang LL, Zhang Y

Basic Study

- 1437** Curcumin inhibits the growth and invasion of gastric cancer by regulating long noncoding RNA AC022424.2

Wang BS, Zhang CL, Cui X, Li Q, Yang L, He ZY, Yang Z, Zeng MM, Cao N

- 1453** MicroRNA-298 determines the radio-resistance of colorectal cancer cells by directly targeting human dual-specificity tyrosine(Y)-regulated kinase 1A

Shen MZ, Zhang Y, Wu F, Shen MZ, Liang JL, Zhang XL, Liu XJ, Li XS, Wang RS

- 1465** Human β -defensin-1 affects the mammalian target of rapamycin pathway and autophagy in colon cancer cells through long non-coding RNA TCONS_00014506

Zhao YX, Cui Y, Li XH, Yang WH, An SX, Cui JX, Zhang MY, Lu JK, Zhang X, Wang XM, Bao LL, Zhao PW

- 1479** FAM53B promotes pancreatic ductal adenocarcinoma metastasis by regulating macrophage M2 polarization

Pei XZ, Cai M, Jiang DW, Chen SH, Wang QQ, Lu HM, Lu YF

- 1500** Transcriptome sequencing reveals novel biomarkers and immune cell infiltration in esophageal tumorigenesis

Sun JR, Chen DM, Huang R, Wang RT, Jia LQ

- 1514** Construction of CDKN2A-related competitive endogenous RNA network and identification of GAS5 as a prognostic indicator for hepatocellular carcinoma

Pan Y, Zhang YR, Wang LY, Wu LN, Ma YQ, Fang Z, Li SB

- 1532** Two missense STK11 gene variations impaired LKB1/adenosine monophosphate-activated protein kinase signaling in Peutz-Jeghers syndrome

Liu J, Zeng SC, Wang A, Cheng HY, Zhang QJ, Lu GX

- 1547** Long noncoding RNAs HAND2-AS1 ultrasound microbubbles suppress hepatocellular carcinoma progression by regulating the miR-873-5p/tissue inhibitor of matrix metalloproteinase-2 axis

Zou Q, Wang HW, Di XL, Li Y, Gao H

- 1564** Upregulated lncRNA PRNT promotes progression and oxaliplatin resistance of colorectal cancer cells by regulating HIPK2 transcription

Li SN, Yang S, Wang HQ, Hui TL, Cheng M, Zhang X, Li BK, Wang GY

SYSTEMATIC REVIEWS

- 1578** Prognosis value of heat-shock proteins in esophageal and esophagogastric cancer: A systematic review and meta-analysis

Nakamura ET, Park A, Pereira MA, Kikawa D, Tustumi F

- 1596** Risk factors for hepatocellular carcinoma associated with hepatitis C genotype 3 infection: A systematic review

Farooq HZ, James M, Abbott J, Oyibo P, Divall P, Choudhry N, Foster GR

META-ANALYSIS

- 1613** Effectiveness and tolerability of programmed cell death protein-1 inhibitor + chemotherapy compared to chemotherapy for upper gastrointestinal tract cancers

Zhang XM, Yang T, Xu YY, Li BZ, Shen W, Hu WQ, Yan CW, Zong L

- 1626** Success rate of current human-derived gastric cancer organoids establishment and influencing factors: A systematic review and meta-analysis

Jiang KL, Wang XX, Liu XJ, Guo LK, Chen YQ, Jia QL, Yang KM, Ling JH

CASE REPORT

- 1647** Pathologically successful conversion hepatectomy for advanced giant hepatocellular carcinoma after multidisciplinary therapy: A case report and review of literature

Chu JH, Huang LY, Wang YR, Li J, Han SL, Xi H, Gao WX, Cui YY, Qian MP

- 1660** Clinical pathological characteristics of "crawling-type" gastric adenocarcinoma cancer: A case report

Xu YW, Song Y, Tian J, Zhang BC, Yang YS, Wang J

- 1668** Primary pancreatic peripheral T-cell lymphoma: A case report

Bai YL, Wang LJ, Luo H, Cui YB, Xu JH, Nan HJ, Yang PY, Niu JW, Shi MY

ABOUT COVER

Peer Reviewer of *World Journal of Gastrointestinal Oncology*, Lie Zheng, Director, Professor, Department of Gastroenterology, Shaanxi Provincial Hospital of Traditional Chinese Medicine, Xi'an 730000, Shaanxi Province, China. xinliwen696@126.com

AIMS AND SCOPE

The primary aim of *World Journal of Gastrointestinal Oncology* (WJGO, *World J Gastrointest Oncol*) is to provide scholars and readers from various fields of gastrointestinal oncology with a platform to publish high-quality basic and clinical research articles and communicate their research findings online.

WJGO mainly publishes articles reporting research results and findings obtained in the field of gastrointestinal oncology and covering a wide range of topics including liver cell adenoma, gastric neoplasms, appendiceal neoplasms, biliary tract neoplasms, hepatocellular carcinoma, pancreatic carcinoma, cecal neoplasms, colonic neoplasms, colorectal neoplasms, duodenal neoplasms, esophageal neoplasms, gallbladder neoplasms, *etc.*

INDEXING/ABSTRACTING

The WJGO is now abstracted and indexed in PubMed, PubMed Central, Science Citation Index Expanded (SCIE, also known as SciSearch®), Journal Citation Reports/Science Edition, Scopus, Reference Citation Analysis, China Science and Technology Journal Database, and Superstar Journals Database. The 2023 edition of Journal Citation Reports® cites the 2022 impact factor (IF) for WJGO as 3.0; IF without journal self cites: 2.9; 5-year IF: 3.0; Journal Citation Indicator: 0.49; Ranking: 157 among 241 journals in oncology; Quartile category: Q3; Ranking: 58 among 93 journals in gastroenterology and hepatology; and Quartile category: Q3. The WJGO's CiteScore for 2022 is 4.1 and Scopus CiteScore rank 2022: Gastroenterology is 71/149; Oncology is 197/366.

RESPONSIBLE EDITORS FOR THIS ISSUE

Production Editor: Xiang-Di Zhang; Production Department Director: Xiang Li; Cover Editor: Jia-Ru Fan.

NAME OF JOURNAL

World Journal of Gastrointestinal Oncology

ISSN

ISSN 1948-5204 (online)

LAUNCH DATE

February 15, 2009

FREQUENCY

Monthly

EDITORS-IN-CHIEF

Monjur Ahmed, Florin Burada

EDITORIAL BOARD MEMBERS

<https://www.wjgnet.com/1948-5204/editorialboard.htm>

PUBLICATION DATE

April 15, 2024

COPYRIGHT

© 2024 Baishideng Publishing Group Inc

INSTRUCTIONS TO AUTHORS

<https://www.wjgnet.com/bpg/gerinfo/204>

GUIDELINES FOR ETHICS DOCUMENTS

<https://www.wjgnet.com/bpg/GerInfo/287>

GUIDELINES FOR NON-NATIVE SPEAKERS OF ENGLISH

<https://www.wjgnet.com/bpg/gerinfo/240>

PUBLICATION ETHICS

<https://www.wjgnet.com/bpg/GerInfo/288>

PUBLICATION MISCONDUCT

<https://www.wjgnet.com/bpg/gerinfo/208>

ARTICLE PROCESSING CHARGE

<https://www.wjgnet.com/bpg/gerinfo/242>

STEPS FOR SUBMITTING MANUSCRIPTS

<https://www.wjgnet.com/bpg/GerInfo/239>

ONLINE SUBMISSION

<https://www.f6publishing.com>



Pathologically successful conversion hepatectomy for advanced giant hepatocellular carcinoma after multidisciplinary therapy: A case report and review of literature

Ju-Hang Chu, Lu-Yao Huang, Ya-Ru Wang, Jun Li, Shi-Long Han, Hao Xi, Wen-Xue Gao, Ying-Yu Cui, Ming-Ping Qian

Specialty type: Oncology

Provenance and peer review:

Unsolicited article; Externally peer reviewed.

Peer-review model: Single blind

Peer-review report's scientific quality classification

Grade A (Excellent): 0
Grade B (Very good): B, B
Grade C (Good): 0
Grade D (Fair): 0
Grade E (Poor): 0

P-Reviewer: Liakina V, Lithuania; Oley MH, Indonesia

Received: November 18, 2023

Peer-review started: November 18, 2023

First decision: December 22, 2023

Revised: January 8, 2024

Accepted: February 19, 2024

Article in press: February 19, 2024

Published online: April 15, 2024



Ju-Hang Chu, Lu-Yao Huang, Ya-Ru Wang, Jun Li, Ming-Ping Qian, Department of General Surgery, Shanghai Tenth People's Hospital, School of Medicine, Tongji University, Shanghai 200072, China

Shi-Long Han, Department of Interventional and Vascular Surgery, Shanghai Tenth People's Hospital, School of Medicine, Tongji University, Shanghai 200072, China

Hao Xi, Department of Pathology, Shanghai Tenth People's Hospital, School of Medicine, Tongji University, Shanghai 200072, China

Wen-Xue Gao, Clinical Research Management Office, Shanghai Tenth People's Hospital, Shanghai 200072, China

Ying-Yu Cui, Department of Cell Biology, Institute of Medical Genetics, State Key Laboratory of Cardiology, Tongji University School of Medicine, Shanghai 200331, China

Corresponding author: Ying-Yu Cui, PhD, Associate Professor, Editor-in-Chief, Teacher, Department of Cell Biology, Institute of Medical Genetics, State Key Laboratory of Cardiology, Tongji University School of Medicine, No. 500 Zhennan Road, Putuo District, Shanghai 200331, China. yycui@tongji.edu.cn

Abstract

BACKGROUND

Hepatocellular carcinoma (HCC) is one of the leading causes of death due to its complexity, heterogeneity, rapid metastasis and easy recurrence after surgical resection. We demonstrated that combination therapy with transcatheter arterial chemoembolization (TACE), hepatic arterial infusion chemotherapy (HAIC), Epluse, Lenvatinib and Sintilimab is useful for patients with advanced HCC.

CASE SUMMARY

A 69-year-old man who was infected with hepatitis C virus (HCV) 30 years previously was admitted to the hospital with abdominal pain. Enhanced computed tomography (CT) revealed a low-density mass in the right lobe of the liver, with a volume of 12.9 cm × 9.4 cm × 15 cm, and the mass exhibited a "fast-in/fast-out" pattern, with extensive filling defect areas in the right branch of the portal vein and an alpha-fetoprotein level as high as 657 ng/mL. Therefore, he

was judged to have advanced HCC. During treatment, the patient received three months of Epclusa, three TACE treatments, two HAIC treatments, three courses of sintilimab, and twenty-one months of lenvatinib. In the third month of treatment, the patient developed severe side effects and had to stop immunotherapy, and the Lenvatinib dose had to be halved. Postoperative pathological diagnosis indicated a complete response. The patient recovered well after the operation, and no tumor recurrence was found.

CONCLUSION

Multidisciplinary conversion therapy for advanced enormous HCC caused by HCV infection has a significant effect. Individualized drug adjustments should be made during any treatment according to the patient's tolerance to treatment.

Key Words: Hepatocellular therapy; Conversion hepatectomy; Interventional therapy; Epclusa; Lenvatinib; Sintilimab; Case report

©The Author(s) 2024. Published by Baishideng Publishing Group Inc. All rights reserved.

Core Tip: The present study describes the excellent efficacy of conversion therapy including interventional therapy, anti-hepatitis C virus therapy, and immunotargeted therapy for advanced giant hepatocellular carcinoma (HCC). After 21 months of conversion therapy, the patient underwent surgical resection completely and the postoperative pathology suggested a complete response. In summary, conversion therapy is a promising treatment option for unresectable HCC patients.

Citation: Chu JH, Huang LY, Wang YR, Li J, Han SL, Xi H, Gao WX, Cui YY, Qian MP. Pathologically successful conversion hepatectomy for advanced giant hepatocellular carcinoma after multidisciplinary therapy: A case report and review of literature. *World J Gastrointest Oncol* 2024; 16(4): 1647-1659

URL: <https://www.wjgnet.com/1948-5204/full/v16/i4/1647.htm>

DOI: <https://dx.doi.org/10.4251/wjgo.v16.i4.1647>

INTRODUCTION

At present, primary liver cancer is the fourth most common malignant tumor in China and the second most common cause of death[1]. It has seriously threatened the life and health of Chinese people, and hepatocellular carcinoma (HCC) accounts for the majority of of this disease[2]. Several liver diseases, such as hepatitis virus infection, alcoholism, and nonalcoholic fatty liver disease, are often associated with the development of HCC[3-5]. When diagnosed, more than 80% of patients are in the advanced stage when they are diagnosed and have obvious resistance to conventional chemotherapy and radiotherapy[6-8].

Conversion therapy is an effective method for transforming unresectable HCC into resectable HCC[9,10]. However, large tumors and portal vein invasion contribute to a poor prognosis in all stages of HCC[11]. In recent years, immunotargeted therapy has become an attractive and promising approach because it can improve the efficacy of antitumor drugs [12]. Lenvatinib, a newly developed polytyrosine kinase inhibitor, has a stronger effect on tumor vasculature and a greater tumor regression effect than does sorafenib[13]. Moreover, the development of immunotherapy has also promoted the treatment of advanced HCC[14]. Sintilimab, a programmed cell death factor-1 (PD-1) inhibitor, was introduced into clinical practice in 2018 and has now become an important therapy for patients with advanced HCC[15].

For people with hepatitis C virus (HCV), antiviral treatment can help prevent further damage to the liver from the virus. The earlier the time of antiviral treatment, the better the therapeutic effect. Epclusa is a single tablet fixed-dose compound preparation composed of two potent active antiviral ingredients. The drug has few side effects and a 98% cure rate for HCV[16].

Transcatheter arterial chemoembolization (TACE) is the main treatment method for primary liver cancer patients who cannot be treated by radical surgery[17]. TACE is less traumatic than the other surgical methods, significantly improves the therapeutic efficacy of patients and prolongs patient survival. In hepatic arterial infusion chemotherapy (HAIC), which is another local interventional therapy used in treating HCC, chemical drugs are delivered directly to the tumor vessel through hepatic arterial infusion. In 2013, EACH released the FOLFOX regimen (oxaliplatin + calcium folinate + 5-fluorouracil), which has good efficacy in the treatment of advanced HCC, and confirmed for the first time that the FOLFOX protocol can improve the survival rate of HCC patients[18].

To our knowledge, few studies have reported that patients with giant advanced HCC caused by hepatitis C successfully underwent surgical resection and achieved a pathological complete response after individualized conversion therapy.

CASE PRESENTATION

Chief complaints

A 69-year-old male patient who presented with abdominal pain for several days was admitted to the Shanghai Tenth People's Hospital on November 9, 2021.

History of present illness

The patient presented with abdominal pain that started 1 wk prior to hospitalization, and ultrasound indicated a space-occupying lesion in the right liver, so he was hospitalized.

History of past illness

The man underwent subtotal gastrectomy 30 years prior to treating the bleeding from a gastric ulcer, and the patient was infected with HCV through an intraoperative blood transfusion and visited a primary doctor. However, he did not receive any therapy for HCV. Before the tumor was discovered, the patient was in poor health and had cirrhosis resulting in hypersplenism and ascites, atrial fibrillation, and malnutrition.

Personal and family history

The patient had been smoking and drinking for more than 40 years and had stopped smoking 10 years prior. The patient had no significant family history.

Physical examination

Physical examination revealed light pressure pain in the right upper abdomen and a hard liver upon palpation.

Laboratory examinations

Venous blood was collected, and the indicators in [Table 1](#) were measured.

Imaging examinations

Enhanced computed tomography (CT) of the upper abdomen showed a low-density mass in the right lobe of the liver, with a volume of 12.9 cm × 9.4 cm × 15 cm; this mass exhibited a “fast-in/fast-out” pattern, with extensive filling defect areas in the right branch of the portal vein ([Figure 1A and B](#)). In addition, CT revealed that the total liver volume was 2764 cm³, the residual liver tissue was 786 cm³, and the residual liver tissue/total liver volume was 0.2843 ([Figure 2](#)).

FINAL DIAGNOSIS

The patient was diagnosed with advanced HCC (T4N0M0, stage IIIB) according to the 8th edition of the American Joint Committee on Cancer TNM Classification for HCC. The tumor was judged to be unresectable because the patient had an insufficient volume of his remaining healthy liver, and he had many basic diseases and malnutrition and was Child-Pugh stage B ([Table 2](#))[19].

TREATMENT

Symptomatic supportive treatment was given to improve the general condition of the patient. From the first day of hospitalization, 20 mg of albumin was administered intravenously daily for 5 consecutive days, and his albumin concentration increased from 25.7 g/L to 37 g/L. After a comprehensive analysis of the patient's condition, TACE with epirubicin was performed first. To further increase the antitumor efficacy, the patient was given intravenous Sintilimab 200 mg of intravenous Sintilimab in combination with oral Lenvatinib 8 mg of oral lenvatinib after the first TACE treatment. During the whole treatment period, the patient received a total of 3 TACE and 2 HAIC treatments (FOLFOX regimen, oxaliplatin 150 mg + calcium folinate 200 mg + fluorouracil 3 g micropump) treatments ([Figure 3](#)). Epclusa was administered orally, 1 tablet once daily, for 3 months from the time that HCC was initially diagnosed, at which point the patient's HCV RNA test became negative, and the patient did not develop any adverse reactions.

OUTCOME AND FOLLOW-UP

After 3 months, CT three-dimensional CT reconstruction of the liver and volume calculations showed that the tumor size was 14 cm × 9.6 cm × 12 cm ([Figure 1C and D](#)); the total liver volume was 1975 cm³; the residual liver tissue was 650 cm³; and the residual liver tissue/total liver volume was 0.3291 ([Figure 2](#)). This finding demonstrated the effectiveness of the combined treatment regimen. Unfortunately, the patient presented with mild neutropenia (neutrophil: 1.47 × 10⁹), thrombocytopenia [platelet (PLT): 33 × 10⁹], grade 3 diarrhea, and moderate hypothyroidism ([Figure 4](#)) at the point where the immunotherapy had to be discontinued and the oral lenvatinib dose was halved. Surprisingly, after three months of anti-HCV therapy with oral Epclusa, his HCV RNA level decreased to normal, and the drug was discontinued. For

Table 1 Local laboratory data before the initiation of therapy in a 69-year-old man with advanced hepatocellular carcinoma with invasion of the right branch of the portal vein

Variables	Value	Unit
AFP	657	ng/mL
WBC	3.18	10 ⁹ /L
Hemoglobin	104	g/L
Platelet	95	10 ⁹ /L
ALT	36.7	U/L
AST	102.8	U/L
ALP	212	U/L
γ-GTP	111.1	U/L
Albumin	25.7	g/L
T-BIL	15.3	umol/L
D-BIL	7.6	umol/L
PT	13.6	s
APTT	31.2	s
TT	19.1	s
Fibrinogen	2.16	s

γ-GTP: γ-glutamyl transpeptidase; AFP: Alpha-fetoprotein; ALP: Alkaline phosphatase; ALT: Alanine aminotransferase; AST: Aspartate aminotransferase; D-BIL: Direct bilirubin; T-BIL: Total-bilirubin; PT: Prothrombin time; APTT: Activated partial thromboplastin time; TT: Thrombin time; WBC: White blood cell.

Table 2 Child-Pugh scores

Variables	1	2	3
Hepatic encephalopathy (stage)	None	1-2	3-4
Ascites	None	mild	Moderate-severe
T-BIL (umol/L)	< 34	34-51	< 51
Albumin (g/L)	< 35	28-35	< 28
Prothrombin time (s)	< 14	14-18	< 18

Child-Pugh stage A: 5-6; Child-Pugh stage B: 7-9; Child-Pugh stage C: ≥ 10.

neutropenia, human granulocyte colony-stimulating factor was injected as a treatment, and the neutrophil count returned to the normal range after treatment. Recombinant human thrombopoietin as an injection was used to treat the thrombocytopenia, but the PLT was still at a low level after two treatments, which may be related to the patient's hypersplenism. Furthermore, we used smectite powder and bifico to treat his Grade 3 diarrhea. Euthyrox is one of the most commonly used drugs for the treatment of hypothyroidism and is used for the treatment of patients with subclinical hypothyroidism, but the effect was limited in these patients. After the treatment regimen was changed, the thyroid function of the man improved significantly.

After up to 21 months of treatment, the patient's liver function (Child-Pugh A) and nutritional status were significantly improved, especially his albumin concentration and weight (Figure 5), which reached the highest values during treatment, and liver enhanced magnetic resonance imaging revealed that the tumor volume had decreased to 11.2 cm × 7.3 cm × 9.4 cm (Figure 1E and F). Some of the test indicators obtained during the whole treatment of the patient are shown in Figure 6. The patient underwent partial hepatectomy one month after the end of the discontinuation of oral lenvatinib. The operation time was 236 min, and the bleeding volume was 500 mL. Two units of red blood cells were given intraoperatively.

The postoperative pathological diagnosis revealed extensive coagulation necrosis of the tumor tissue because of the combination therapy. The arteries contained a lot of lipiodol deposition. The noncancerous liver tissue exhibited a micronodular pattern, indicating liver cirrhosis. However, no active cancer cells were found upon pathological

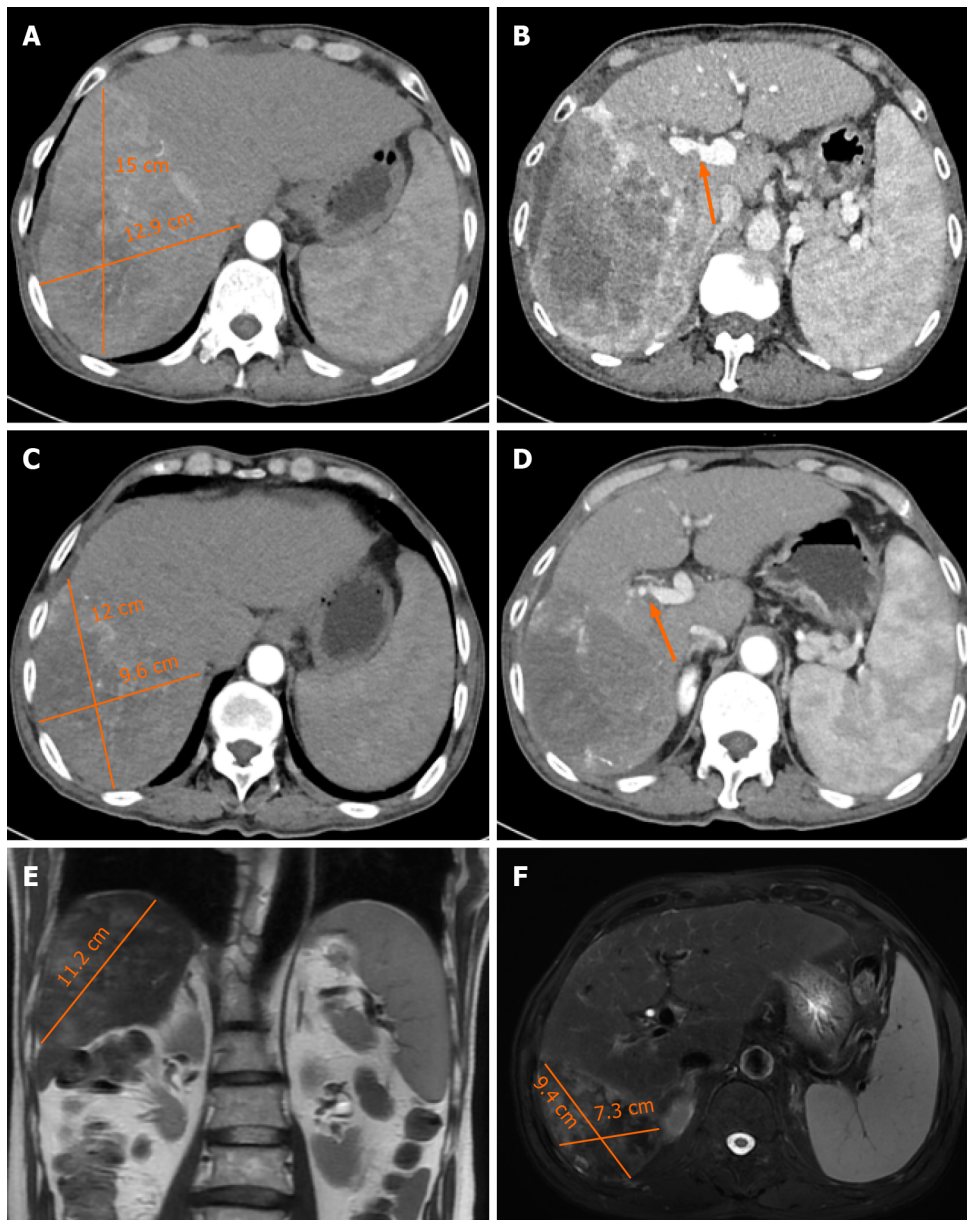


Figure 1 Contrast-enhanced computed tomography and magnetic resonance images of the patient. A: Axial images of the arterial phase before treatment; B: Axial images of the portal phase before treatment; C: Axial images of the arterial phase after 3 months of treatment; D: Axial images of the portal phase after 3 months of treatment; E: Sagittal sectional magnetic resonance image (MRI) images before surgery; F: Cross-sectional MRI images before surgery.

examination (Figure 7). In other words, the patient achieved a complete pathological response.

The patient was discharged from the hospital on the 9th d after surgery without serious complications. All tumor marker levels were within the normal range. We used a timeline figure to summarize the patient's clinical characteristics and treatment (Figure 8).

DISCUSSION

HCV are a group of single-stranded RNA viruses that belong to the Flaviviridae family, and HCV does not integrate with host chromosomes *in vivo*, as compared with those of hepatitis B virus group (HBV); therefore, the clinical characteristics of HCV-associated HCC and HBV-associated HCC may differ. It has been suggested that patients with HCV-associated HCC are older than patients without HCV-associated HCC[20], have a better prognosis, and have a lower risk of recurrence[21]. A sustained virological response can reduce the incidence of HCC in most patients with HCV. Therefore, the introduction of a direct-acting antiviral agent into HCV therapy makes HCV curable. As a result, for large HCV-associated unresectable HCC patients, the addition of antiviral therapy to conversion therapy may be beneficial.

HCC conversion therapy mainly includes immunotherapy, targeted therapy, interventional therapy, radiation therapy, traditional Chinese medicine therapy, etc. Conversion therapy for advanced liver cancer has also been described in detail by other clinicians (Table 3)[22-30], suggesting the importance of individualized therapy and multidisciplinary

Table 3 Summary of published case reports of conversion therapy in advanced hepatocellular carcinoma patients

Ref.	Age	Sex	Underlying liver disease	Tumor size	Symptom	Previous treatment	Pathological response rate
Wei <i>et al</i> [22]	67	Male	Hepatitis B	7.2 cm × 7.1 cm × 6.4 cm	Abdominal discomfort	HAIC, TACE, Immunotargeted therapy	PR
Ning <i>et al</i> [23]	48	Male	Hepatitis B	16.2 cm × 11.2 cm	Palpable mass	TACE, Immunotargeted therapy	PR
Ning <i>et al</i> [23]	54	Male	Hepatitis B	14.9 cm × 11.8 cm	Abdominal pain	TACE, Immunotargeted therapy	CR
Zhou <i>et al</i> [24]	69	Male	Hepatitis B	12.7 cm × 10.3 cm	None	HAIC, TAE, Immunotargeted therapy	PR
Wu <i>et al</i> [25]	41	Male	Hepatitis B	7.1 cm × 5.5 cm × 5.1 cm	Abdominal pain	Immunotargeted therapy	CR
Chen <i>et al</i> [26]	49	Male	Hepatitis B	7.1 cm × 5.5 cm	None	Immunotargeted therapy	PR
Chen <i>et al</i> [27]	52	Male	Hepatitis B	11.3 cm × 12.0 cm × 11.9 cm	Abdominal pain	TACE, Targeted therapy	CR
Chen <i>et al</i> [27]	42	Male	Hepatitis B	11.4 cm × 8.9 cm × 10.0 cm	None	HAIC, TACE, Targeted therapy	PR
Yano <i>et al</i> [28]	68	Male	None	7.2 cm in S1	None	Immunotargeted therapy	PR
Zhang <i>et al</i> [29]	67	Male	None	The largest was ≥ 10 cm	Epigastric distention	TACE, antiviral therapy	PR
Tomonari <i>et al</i> [30]	69	Male	Alcoholic cirrhosis	7.3 cm	Abdominal pain	TAE, targeted therapy	PR
Tomonari <i>et al</i> [30]	71	Female	Nonalcoholic steato-hepatitis	5.8 cm in S3	None	TAE, targeted therapy	PR
Tomonari <i>et al</i> [30]	73	Male	Alcoholic cirrhosis	5.2 cm in S5	None	TAE, targeted therapy	PR

HAIC: Hepatic arterial infusion chemotherapy; TAE: Transcatheter arterial embolization; TACE: Transcatheter arterial chemoembolization; PR: Partial remission; CR: Complete remission.

management in achieving surgical resection. Wei *et al*[22] successfully performed R0 hepatectomy after 5 months of conversion therapy in a 67-year-old man who had bulky bilobar HCC with right hepatic artery anatomic variation and achieved partial remission. Ning *et al*[23] performed two-stage associating liver partition and portal vein ligation for staged hepatectomy (ALPPS) for a male patient with large, unresectable HCC with HBV after TACE and immunotherapy, and the postoperative pathological diagnosis suggested a complete response. This result suggested that ALPPS may provide another salvage option for future HCC conversion therapy.

At present, there have been breakthroughs in the systemic treatment of liver cancer that range from molecular targeted drugs to immune checkpoint inhibitors; however, single-target or immunotherapy effects are limited[31]. Numerous studies have confirmed that combined immunotargeted therapy can improve the treatment and prolong the overall survival of HCC patients, but its efficacy still cannot be used to meet clinical needs[32,33]. To further meet the patient's expectations for a good prognosis of the disease, several scholars have proposed that the combination of immunotargeted therapy and local therapy may be a potential treatment option.

Interventional therapy, including TACE and HAIC, is an effective method for treating liver cancer. TACE involves the use of a mixture of chemical drugs and iodized oil or drug-loaded microspheres to block tumor blood supply vessels, and these microspheres continuously release high concentrations of chemotherapeutic drugs to cause tumor ischemia necrosis and shrinkage[34]. In addition, TACE may improve the immune microenvironment of tumors and stimulate the exposure of neoantigens to enhance the effectiveness of immunotherapy, and the antitumor angiogenesis effect of targeted therapy and immunotherapy may also help reduce the recurrence of tumors caused by tumor angiogenesis after TACE[35]. On the other hand, HAIC involves selective insertion of a catheter into the hepatic artery without embolization or continuous infusion of chemotherapy drugs alone. Notably, HAIC is associated with less severe grade 3-4 adverse reactions than TACE, especially liver function damage, and provides necessary conditions for liver reserve function for subsequent combined treatment of unresectable liver cancer[36]. Recently, clinical experts have actively explored local treatment based on interventional therapy combined with immunotargeted therapy for HCC, which has shown good efficacy[37].

Vascular endothelial growth factor receptor, fibroblast growth factor receptor, and PLT-derived growth factor receptor alpha are the loci of lenvatinib blockade. In 2018, the REFLECT study showed that the overall survival of the patients in the lenvatinib group was not inferior to that of patients in the sorafenib group; thus, lenvatinib became the second first-line drug for unresectable HCC, overcoming the treatment dilemma associated with HCC[38]. Common side effects of lenvatinib include hypertension, hemorrhage, hypothyroidism, and diarrhea[39]. In this patient, Grade 3 diarrhea and

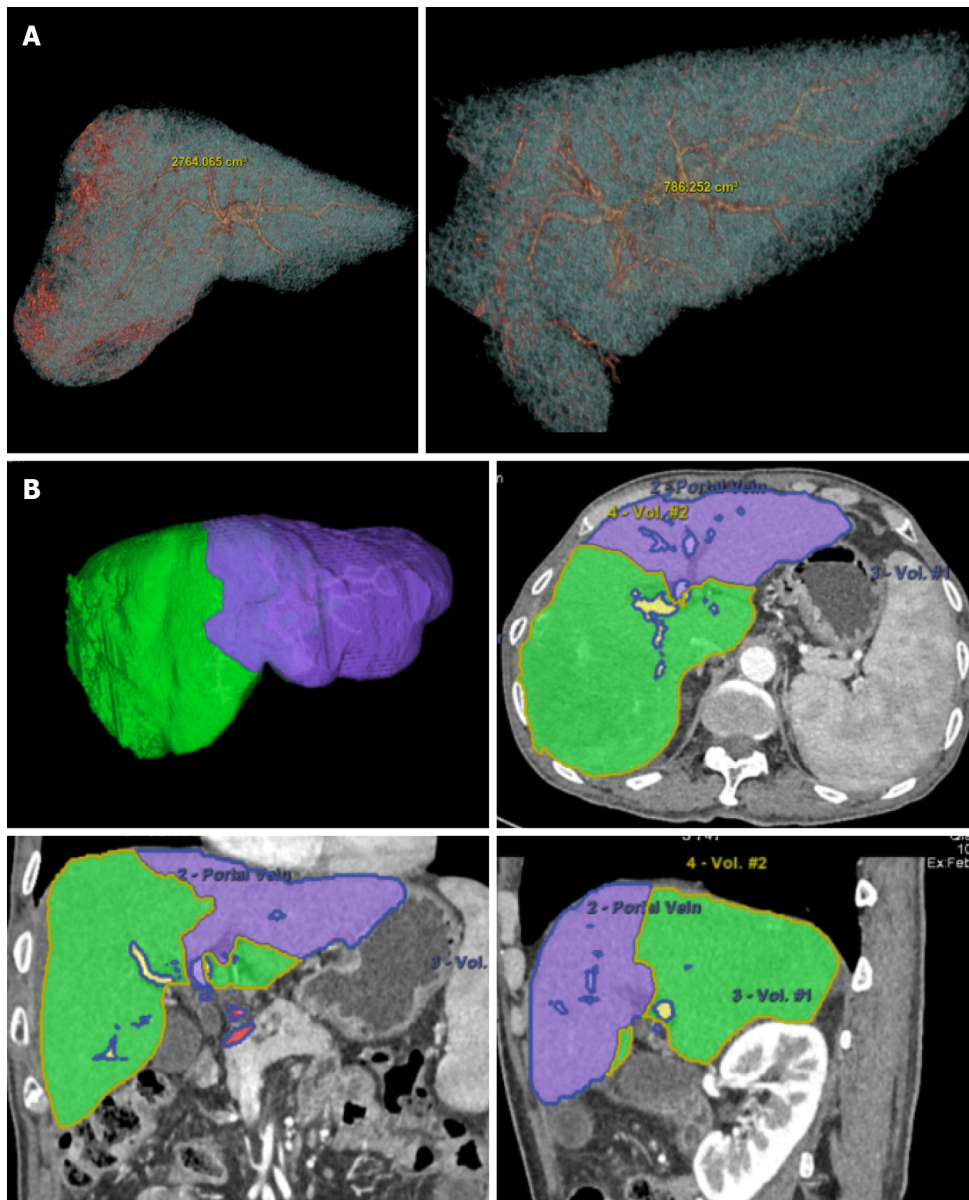


Figure 2 Three-dimensional computed tomography reconstruction of the liver and volume calculation. A: The total liver volume was 2764 cm³ and the residual was 786 cm³ before treatment; B: After three months of conversion therapy, the total liver volume was 1975 cm³ and the residual was 650 cm³.

moderate hypothyroidism occurred during the use of this drug. Hence, we halved the dose of lenvatinib after 3 months of standard treatment. After the use of this personalized treatment, the patient's treatment tolerance was significantly improved.

PD-1 inhibitors are immune checkpoint inhibitors that can prevent tumor cells from hiding and enhance the body's immune response to tumor cells by blocking the binding of PD-1 and ligands on tumor cells to play an antitumor role. PD-1 inhibitors have shown good antitumor potential in many advanced tumors[40]. The microenvironment of HCC can induce the expression of vascular endothelial growth factor and promote tumor angiogenesis, during which the expression of a variety of tumor inhibitory receptors, including PD-1 and cytotoxic T lymphocyte associated antigen 4, is upregulated[14]. PD-1 expression was found during treatment of patients with middle-stage and advanced HCC with immune checkpoint inhibitors. Theoretically, actively blocking the binding of PD-1 to its ligand can effectively improve the prognosis of patients with middle-stage and advanced HCC. Sintilimab, as one of the most commonly used PD-1 inhibitors, has become a treatment option for patients with advanced HCC and has achieved good results. The side effects of sintilimab are an issue that clinicians cannot ignore. Common side effects include diarrhea, hypothyroidism, thrombocytopenia, and liver and kidney damage[41]. In this case, the patient developed severe diarrhea, hypothyroidism, and thrombocytopenia during standard-dose immunotargeted therapy. In addition to the side effects of immunotherapy, thrombocytopenia may also be related to the hypersplenism caused by liver cirrhosis in patients. After the injection of recombinant human thrombopoietin and oral leucogen, the number of PLT increased at the initial stage of immunotherapy. However, PLT count continued to decrease after 1 month of treatment, and the immunotherapy had to be stopped after comprehensively considering the patient's situation. After stopping the drug treatment, the patient's PLTs gradually recovered.

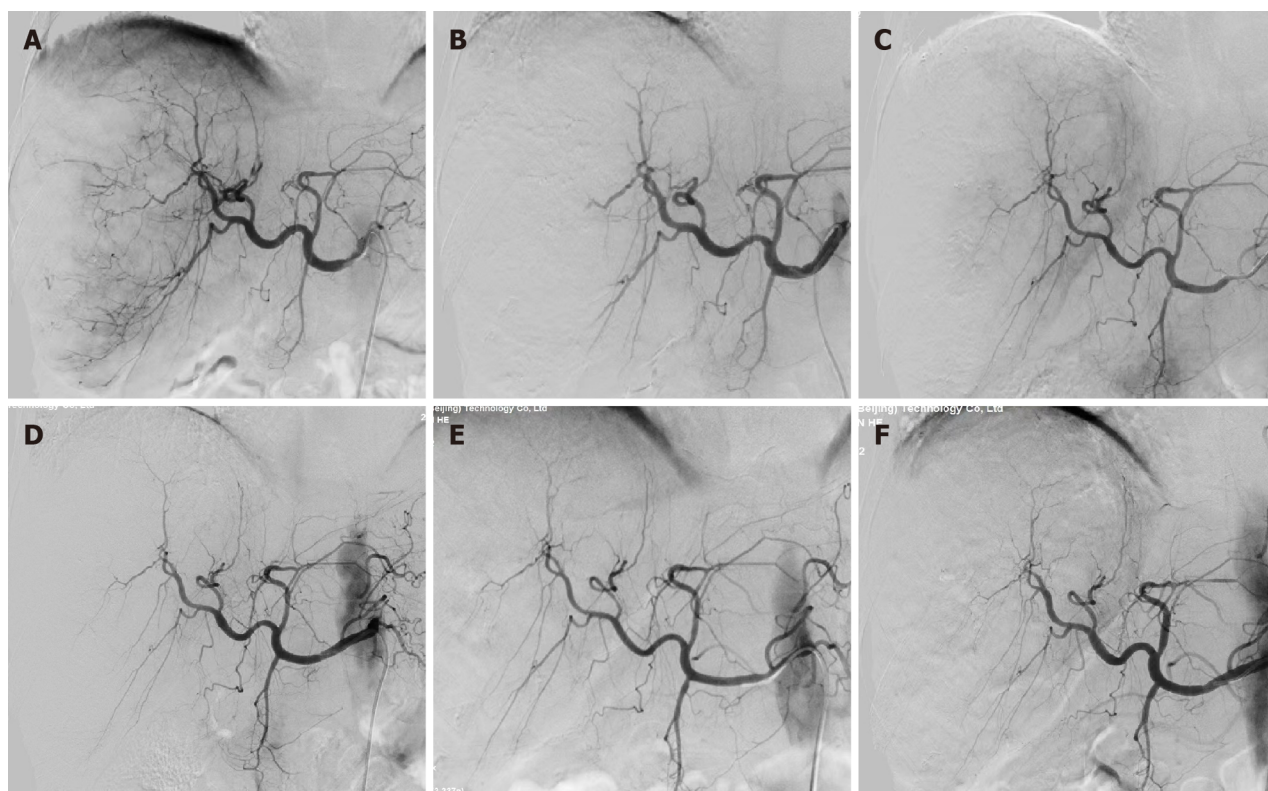


Figure 3 Angiography with the iodine contrast agent. A: Before the first transcatheter arterial chemoembolization (TACE) treatment on November 19, 2021; B: After the first TACE treatment on November 19, 2021; C: Before the second TACE treatment on December 10, 2021; D: After the second TACE treatment on December 10, 2021; E: Before the third TACE treatment on December 31, 2021; F: After the third TACE treatment on December 31, 2021.

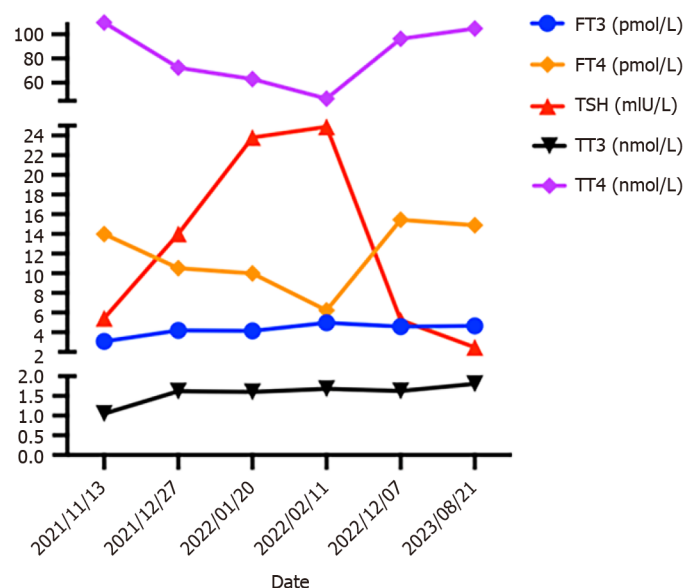


Figure 4 Changes in thyroid function indices with treatment time.

As the world's first oral anti-HCV drug for treating all 1-6 genotypes of hepatitis C, Epclusa has had excellent clinical performance[16]. It can be used alone in patients without cirrhosis or compensatory cirrhosis or in combination with ribavirin in patients with uncompensatory cirrhosis. Epclusa has achieved a good curative efficacy in all genotypes of patients, and it is expected to eliminate genotyping tests and improve the cure rate of hepatitis C patients[42]. After three months of oral administration of Epclusa, the patient's HCV RNA test became negative. Therefore, the drug was no longer used in follow-up treatment, and the patient did not experience common adverse effects such as headache, fatigue or nausea during treatment.

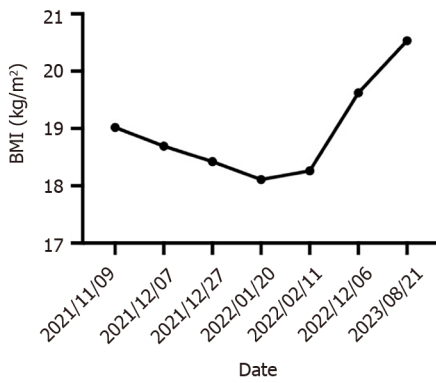


Figure 5 Changes in body mass index over time. BMI: Body mass index.

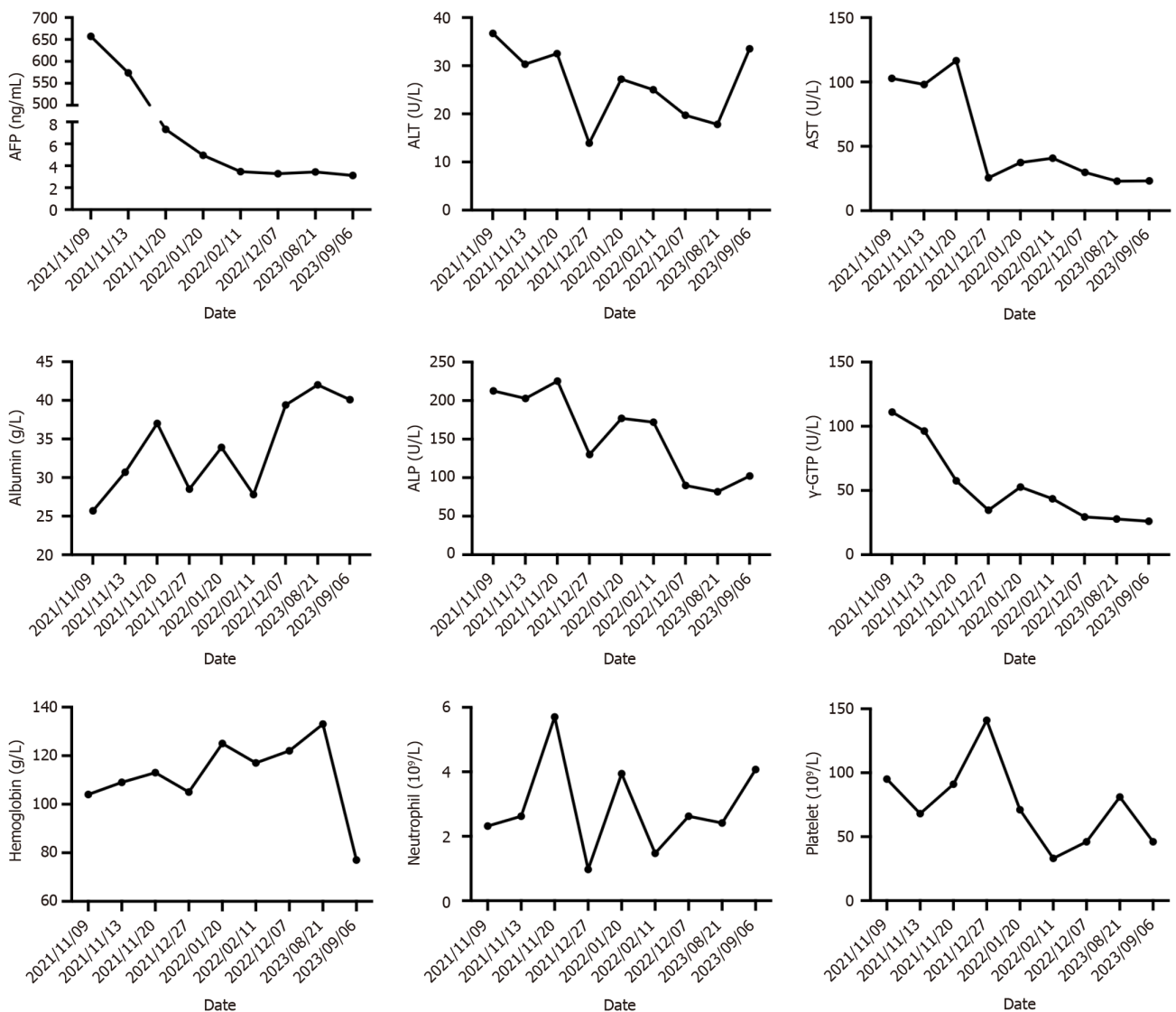


Figure 6 Changes in laboratory indices over the time of treatment.

In this patient, tumor shrinkage and marked improvement in liver function were observed following immunotherapy, targeted therapy, or anti-HCV therapy combined with interventional therapy. The improvement in liver function may be due to the death of tumor cells and the regeneration of healthy liver cells. When alanine aminotransferase and aspartate aminotransferase levels are elevated during antitumor therapy, we recommend the use of glutathione and polyene phosphatidylcholine to promote liver cell repair and regeneration. Moreover, based on the Response Evaluation Criteria in Solid Tumors, the patient was judged to exhibit complete remission[43].

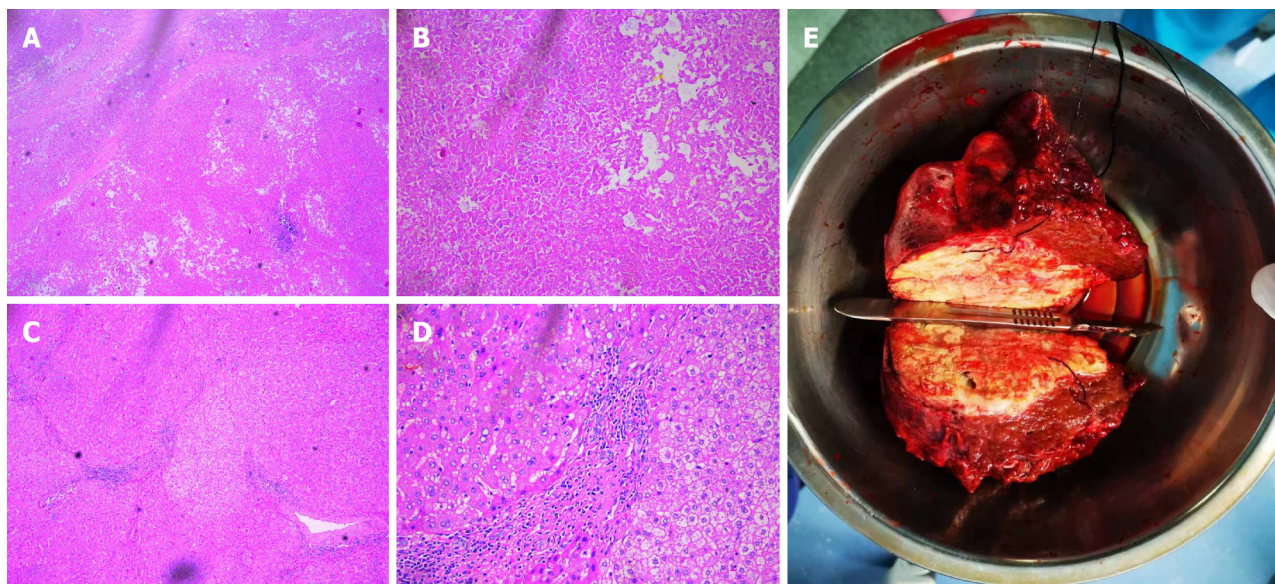


Figure 7 Histopathology of tumor tissue after conversion therapy and resection. A and B: At low magnification (50 ×) and high magnification (200 ×), the primary lesion showed massive coagulation necrosis with lymphocyte infiltration; C and D: At low magnification (50 ×) and high magnification (200 ×), hyperplasia of the surrounding fibrous tissue and lymphocyte infiltration were visible in nontumor normal tissues; E: Macroscopic view of the patient's intrahepatic lesion.

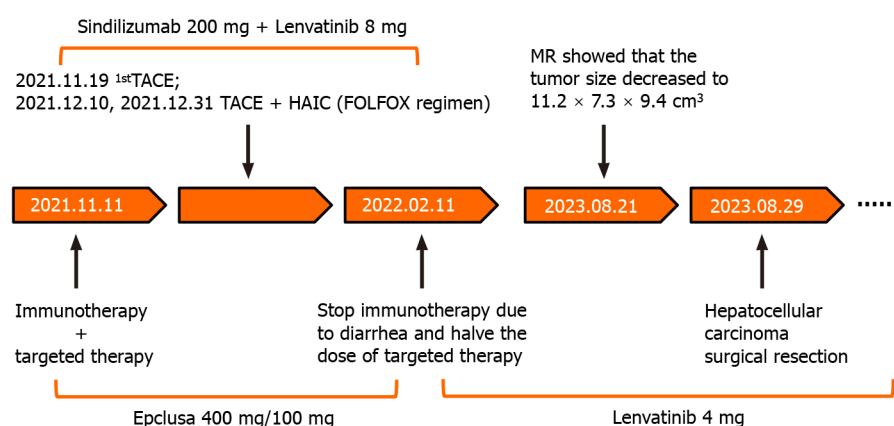


Figure 8 Timeline of patient history development.

In summary, multidisciplinary treatments, which include conversion hepatectomy, TACE, HAIC, Epicla and immunotargeted therapy, could be potential treatment options for advanced HCC. For serious adverse drug reactions, individual treatments, such as drug adjustment, should be carried out at the same time as active symptomatic treatment to find a long-term treatment plan suitable for patients. In addition, this paper has several limitations. First, patient indicators should be tested more frequently to determine the most suitable time for surgery. Second, long-term follow-up of patients should be conducted after surgery. Third, due to the poor physical condition of the patient, no needle biopsy of liver tissue was performed before conversion therapy.

CONCLUSION

This study describes the case of an unresectable advanced HCC patient who underwent complete conversion therapy and surgical resection completely, and the postoperative pathology suggested a complete response. Moreover, the drug dose should be reasonably adjusted according to the patient's body tolerance and adverse reactions to better complete the conversion therapy.

FOOTNOTES

Co-corresponding authors: Ying-Yu Cui and Ming-Ping Qian.

Author contributions: Chu JH, Huang LY and Wang YR collected the pathological, biological, and clinical data; Chu JH drafted the initial manuscript; Han SL and Xi H reviewed the pathological results; Li J, Gao WX, Cui YY and Qian MP reviewed or revised the manuscript and approved the final version; Qian MP had full access to all the data and had final responsibility for the decision to submit for publication; and all the authors contributed to the article and approved the final manuscript. Qian MP and Cui YY contributed equally to this work as co-corresponding authors. The reasons for designating Qian MP and Cui YY as co-corresponding authors are threefold. Qian MP had full access to all the data and had final responsibility for the decision to submit for publication; and all the authors contributed to the article and approved the final manuscript. In addition, Cui YY ensures effective communication and management of post-submission matters, ultimately enhancing the paper's quality and reliability.

Supported by Shanghai Hospital Development Center Foundation, No. SHDC2022CRS033.

Informed consent statement: Informed written consent was obtained from the patient for publication of this report and any accompanying images.

Conflict-of-interest statement: The authors declare that they have no conflict of interest.

CARE Checklist (2016) statement: The authors have read the CARE Checklist (2016), and the manuscript was prepared and revised according to the CARE Checklist (2016).

Open-Access: This article is an open-access article that was selected by an in-house editor and fully peer-reviewed by external reviewers. It is distributed in accordance with the Creative Commons Attribution NonCommercial (CC BY-NC 4.0) license, which permits others to distribute, remix, adapt, build upon this work non-commercially, and license their derivative works on different terms, provided the original work is properly cited and the use is non-commercial. See: <https://creativecommons.org/licenses/by-nc/4.0/>

Country/Territory of origin: China

ORCID number: Ju-Hang Chu 0009-0007-4865-3392; Lu-Yao Huang 0009-0002-9556-7343; Ya-Ru Wang 0009-0009-6088-709X; Shi-Long Han 0009-0005-4468-1957; Hao Xi 0009-0006-8277-4473; Wen-Xue Gao 0009-0005-2533-567X; Ying-Yu Cui 0000-0002-6324-0795; Ming-Ping Qian 0000-0001-5802-6404.

S-Editor: Qu XL

L-Editor: A

P-Editor: Yuan YY

REFERENCES

- 1 Li C, Qu L, Farragher C, Vella A, Zhou B. MicroRNA Regulated Macrophage Activation in Obesity. *J Transl Int Med* 2019; **7**: 46-52 [PMID: 31380236 DOI: 10.2478/jtim-2019-0011]
- 2 Ogawa E, Nomura H, Nakamuta M, Furusyo N, Kajiwaru E, Dohmen K, Kawano A, Ooho A, Azuma K, Takahashi K, Satoh T, Koyanagi T, Ichiki Y, Kuniyoshi M, Yanagita K, Amagase H, Morita C, Sugimoto R, Kato M, Shimoda S, Hayashi J; Kyushu University Liver Disease Study (KULDS) Group. Development of Hepatocellular Carcinoma in Patients Aged 75-84 Years With Chronic Hepatitis C Treated With Direct-Acting Antivirals. *J Infect Dis* 2022; **226**: 431-440 [PMID: 32584386 DOI: 10.1093/infdis/jiaa359]
- 3 Zhang H, Xu K, Xiang Q, Zhao L, Tan B, Ju P, Lan X, Liu Y, Zhang J, Fu Z, Li C, Wang J, Song J, Xiao Y, Cheng Z, Wang Y, Zhang S, Xiang T. LPCAT1 functions as a novel prognostic molecular marker in hepatocellular carcinoma. *Genes Dis* 2022; **9**: 151-164 [PMID: 35005115 DOI: 10.1016/j.gendis.2020.07.007]
- 4 Qiu L, Zhan K, Malale K, Wu X, Mei Z. Transcriptomic profiling of peroxisome-related genes reveals a novel prognostic signature in hepatocellular carcinoma. *Genes Dis* 2022; **9**: 116-127 [PMID: 35005112 DOI: 10.1016/j.gendis.2020.04.010]
- 5 Liu R, Qian MP, Cui YY. Protein kinases: The key contributors in pathogenesis and treatment of nonalcoholic fatty liver disease-derived hepatocellular carcinoma. *Metabolism* 2023; **147**: 155665 [PMID: 37517794 DOI: 10.1016/j.metabol.2023.155665]
- 6 Chen J, Gao G, Zhang Y, Dai P, Huang Y. Comprehensive analysis and validation of SNX7 as a novel biomarker for the diagnosis, prognosis, and prediction of chemotherapy and immunotherapy response in hepatocellular carcinoma. *BMC Cancer* 2023; **23**: 899 [PMID: 37743471 DOI: 10.1186/s12885-023-11405-0]
- 7 Xu Y, Yang Y, Ouyang J, Zhou Y, Li L, Ye F, Yang H, Huang Z, Zhou A, Zhang W, Zhou J, Zhao X, Zhao H. Reclassification of therapeutic response of unresectable hepatocellular carcinoma to anti-angiogenic therapy and immunotherapy using alpha RECIST. *Eur Radiol* 2023 [PMID: 37740779 DOI: 10.1007/s00330-023-10222-0]
- 8 Takada H, Yamashita K, Osawa L, Komiyama Y, Muraoka M, Suzuki Y, Sato M, Kobayashi S, Yoshida T, Takano S, Maekawa S, Enomoto N. Significance of the autoantibody assay in predicting the development of immune-related adverse events in patients receiving atezolizumab plus bevacizumab combination therapy for unresectable hepatocellular carcinoma. *Hepatol Res* 2024; **54**: 162-173 [PMID: 37740643 DOI: 10.1111/hepr.13969]
- 9 Peng Y, Tang H, Huang Y, Yuan X, Wang X, Ran Z, Deng W, Liu R, Lan X, Shen H, Zhang J. CT-derived extracellular volume and liver

- volumetry can predict posthepatectomy liver failure in hepatocellular carcinoma. *Insights Imaging* 2023; **14**: 145 [PMID: 37697217 DOI: 10.1186/s13244-023-01496-5]
- 10 **Wang W**, Ye CH, Deng ZF, Wang JL, Zhang L, Bao L, Xu BH, Zhu H, Guo Y, Wen Z. CD4(+)CD25(+) regulatory T cells decreased future liver remnant after associating liver partition and portal vein ligation for staged hepatectomy. *World J Gastrointest Surg* 2023; **15**: 917-930 [PMID: 37342857 DOI: 10.4240/wjgs.v15.i5.917]
- 11 **Zhang D**, Zhang Y, Luo Y, Qi E, Yu J, Liang P. Perfluoropentane/apatinib-encapsulated metal-organic framework nanoparticles enhanced the microwave ablation of hepatocellular carcinoma. *Nanoscale Adv* 2023; **5**: 4892-4900 [PMID: 37705776 DOI: 10.1039/d2na00880g]
- 12 **Ouyang J**, Yang Y, Zhou Y, Ye F, Wang Z, Li Q, Xu Y, Li L, Zhao X, Zhang W, Zhou A, Huang Z, Wang Y, Cai J, Zhao H, Zhou J. The MAPS-CRAFITY score: a novel efficacy predictive tool for unresectable hepatocellular carcinoma treated with targeted therapy plus immunotherapy. *Hepatol Int* 2023; **17**: 1519-1531 [PMID: 37707759 DOI: 10.1007/s12072-023-10580-3]
- 13 **Limousin W**, Laurent-Puig P, Ziol M, Ganne-Carrié N, Nahon P, Ait-Omar A, Seror O, Sidali S, Campani C, Blanc P, Lermine A, Marisa L, Zucman-Rossi J, Nault JC. Molecular-based targeted therapies in patients with hepatocellular carcinoma and hepato-cholangiocarcinoma refractory to atezolizumab/bevacizumab. *J Hepatol* 2023; **79**: 1450-1458 [PMID: 37647991 DOI: 10.1016/j.jhep.2023.08.017]
- 14 **Kamal MA**, Badary HA, Omran D, Shousha HI, Abdelaziz AO, El Tayebi HM, Mandour YM. Virtual Screening and Biological Evaluation of Potential PD-1/PD-L1 Immune Checkpoint Inhibitors as Anti-Hepatocellular Carcinoma Agents. *ACS Omega* 2023; **8**: 33242-33254 [PMID: 37744828 DOI: 10.1021/acsomega.3c00279]
- 15 **Ning S**, Li X, Ma X, Liu J, Chang X. Efficacy of TACE Combined with Lenvatinib Plus Sintilimab for Hepatocellular Carcinoma with Tumor Thrombus in the Inferior Vena Cava and/or Right Atrium. *J Hepatocell Carcinoma* 2023; **10**: 1511-1525 [PMID: 37724186 DOI: 10.2147/JHC.S410967]
- 16 **Link JO**, Taylor JG, Trejo-Martin A, Kato D, Katana AA, Krygowski ES, Yang ZY, Zipfel S, Cottell JJ, Bacon EM, Tran CV, Yang CY, Wang Y, Wang KW, Zhao G, Cheng G, Tian Y, Gong R, Lee YJ, Yu M, Gorman E, Mogalian E, Perry JK. Discovery of velpatasvir (GS-5816): A potent pan-genotypic HCV NS5A inhibitor in the single-tablet regimens Vosevi® and Epclusa®. *Bioorg Med Chem Lett* 2019; **29**: 2415-2427 [PMID: 31230974 DOI: 10.1016/j.bmcl.2019.04.027]
- 17 **Xiang Z**, Li G, Mu L, Wang H, Zhou C, Yan H, Huang M. TACE Combined with Lenvatinib and Camrelizumab for Unresectable Multiple Nodular and Large Hepatocellular Carcinoma (>5 cm). *Technol Cancer Res Treat* 2023; **22**: 15330338231200320 [PMID: 37723998 DOI: 10.1177/15330338231200320]
- 18 **Pan Y**, Yuan Z, Wang J, Ngai S, Hu Z, Sun L, Yang Z, Hu D, Chen M, Zhou Z, Zhang Y. Survival benefit and impact of adjuvant therapies following FOLFOX-HAIC-based conversion therapy with unresectable hepatocellular carcinoma: a retrospective cohort study. *J Cancer Res Clin Oncol* 2023; **149**: 14761-14774 [PMID: 37589925 DOI: 10.1007/s00432-023-05243-7]
- 19 **Kikugawa C**, Uchikawa S, Kawaoka T, Kinami T, Yano S, Amioka K, Naruto K, Ando Y, Yamaoka K, Tsuge M, Kosaka Y, Ohya K, Mori N, Takaki S, Tsuji K, Kouno H, Kohno H, Morio K, Moriya T, Nonaka M, Aisaka Y, Masaki K, Honda Y, Naeshiro N, Hiramatsu A, Aikata H, Oka S. Outcomes of patients with Child-Pugh B and unresectable hepatocellular carcinoma undergoing first-line systemic treatment with sorafenib, lenvatinib, or atezolizumab plus bevacizumab. *Oncology* 2023 [PMID: 37729889 DOI: 10.1159/000533859]
- 20 **Huo TI**, Huang YH, Hsia CY, Su CW, Lin HC, Hsu CY, Lee PC, Lui WY, Loong CC, Chiang JH, Chiou YY, Lee SD. Characteristics and outcome of patients with dual hepatitis B and C-associated hepatocellular carcinoma: are they different from patients with single virus infection? *Liver Int* 2009; **29**: 767-773 [PMID: 19018974 DOI: 10.1111/j.1478-3231.2008.01908.x]
- 21 **Katsuta E**, Tanaka S, Mogushi K, Matsumura S, Ban D, Ochiai T, Irie T, Kudo A, Nakamura N, Tanaka H, Tanabe M, Arai S. Age-related clinicopathologic and molecular features of patients receiving curative hepatectomy for hepatocellular carcinoma. *Am J Surg* 2014; **208**: 450-456 [PMID: 24972857 DOI: 10.1016/j.amjsurg.2014.01.015]
- 22 **Wei YG**, Su H, Lv ZL, Liao XW, Zeng ZM, Jia YX, Huang HS, Shen XQ, Zhu GZ, Han CY, Ye XP, Peng T. Case Report: A case of hepatocellular carcinoma with aberrant right hepatic artery treated with transarterial chemoembolization and infusion chemotherapy separately to bilobar lesion combining with systemic therapies and sequential hepatectomy. *Front Oncol* 2023; **13**: 1165538 [PMID: 37469401 DOI: 10.3389/fonc.2023.1165538]
- 23 **Ning C**, Liu G, Zhang J, Yang X, Xu Y, Zhao H. Case Report: The application of associating liver partition and portal vein ligation for staged hepatectomy in patients with hepatitis b virus-related hepatocellular carcinoma after undergoing treatment with an immune checkpoint inhibitor: a report of two cases. *Front Immunol* 2023; **14**: 1159885 [PMID: 37228608 DOI: 10.3389/fimmu.2023.1159885]
- 24 **Zhou Z**, Xu X, Sun M, Liu Y, Liu Q, Chen C, Yin Y. Conversion therapy for massive hepatocellular carcinoma: A case report and literature review. *Clin Case Rep* 2023; **11**: e7533 [PMID: 37323266 DOI: 10.1002/ccr3.7533]
- 25 **Wu Y**, Ou S, Liao X, Han C, Yang C, Qin W, Tan Y, Lao Q, Peng T, Ye X. Massive Hepatocellular Carcinoma with Situs Inversus Totalis Achieved a Complete Response Following Camrelizumab Plus Apatinib and Combined with Two-Stage Hepatectomy: A Case Report. *Pharmgenomics Pers Med* 2023; **16**: 111-120 [PMID: 36785780 DOI: 10.2147/PGPM.S376596]
- 26 **Chen Z**, Chen Z, Fan W, Zou Y, Zhang Y, Shi N, Jin H. Conversion surgery for advanced hepatocellular carcinoma after combination treatment of lenvatinib and camrelizumab: a case report. *World J Surg Oncol* 2023; **21**: 29 [PMID: 36721173 DOI: 10.1186/s12957-023-02910-4]
- 27 **Chen K**, Luo CP, Ge DX, Wang KL, Luo Q, Li YZ, You XM, Xiang BD, Li LQ, Ma L, Zhong JH. Case report: Conversion therapy to permit resection of initially unresectable hepatocellular carcinoma. *Front Oncol* 2022; **12**: 946693 [PMID: 36276151 DOI: 10.3389/fonc.2022.946693]
- 28 **Yano S**, Kawaoka T, Johira Y, Miura R, Kosaka M, Shirane Y, Murakami S, Amioka K, Naruto K, Ando Y, Kosaka Y, Yamaoka K, Kodama K, Uchikawa S, Fujino H, Ohno A, Nakahara T, Murakami E, Okamoto W, Yamauchi M, Imamura M, Mori K, Arihiro K, Kuroda S, Kobayashi T, Ohdan H, Aikata H. Advanced hepatocellular carcinoma with response to lenvatinib after atezolizumab plus bevacizumab. *Medicine (Baltimore)* 2021; **100**: e27576 [PMID: 34678902 DOI: 10.1097/MD.00000000000027576]
- 29 **Zhang JJ**, Wang ZX, Niu JX, Zhang M, An N, Li PF, Zheng WH. Successful totally laparoscopic right trihepatectomy following conversion therapy for hepatocellular carcinoma: A case report. *World J Clin Cases* 2021; **9**: 6469-6477 [PMID: 34435014 DOI: 10.12998/wjcc.v9.i22.6469]
- 30 **Tomonari T**, Sato Y, Tanaka H, Tanaka T, Taniguchi T, Sogabe M, Okamoto K, Miyamoto H, Mugeruma N, Saito Y, Imura S, Bando Y, Shimada M, Takayama T. Conversion therapy for unresectable hepatocellular carcinoma after lenvatinib: Three case reports. *Medicine (Baltimore)* 2020; **99**: e22782 [PMID: 33080748 DOI: 10.1097/MD.00000000000022782]
- 31 **Xu Q**, Hu H, Mo Z, Chen T, He Q, Xu Z. A multifunctional nanotheranostic agent based on Lenvatinib for multimodal synergistic hepatocellular carcinoma therapy with remarkably enhanced efficacy. *J Colloid Interface Sci* 2023; **638**: 375-391 [PMID: 36746055 DOI: 10.1016/j.jcis.2023.03.015]

- 10.1016/j.jcis.2023.01.144]
- 32 **Dong H**, Jian Y, Wang M, Liu F, Zhang Q, Peng Z, Cheng N, Zhang W. Hepatic artery intervention combined with immune-targeted therapy is superior to sequential therapy in BCLC-C hepatocellular carcinoma. *J Cancer Res Clin Oncol* 2023; **149**: 5405-5416 [PMID: [36454282](#) DOI: [10.1007/s00432-022-04386-3](#)]
- 33 **Nong X**, Zhang YM, Liang JC, Xie JL, Zhang ZM. Complete response by patients with advanced hepatocellular carcinoma after combination immune/targeted therapy and transarterial chemoembolization: two case reports and literature review. *Transl Cancer Res* 2022; **11**: 2973-2984 [PMID: [36093545](#) DOI: [10.21037/tcr-21-2691](#)]
- 34 **Hu Y**, Pan T, Cai X, He QS, Zheng YB, Huang MS, Jiang ZB, Chen JW, Wu C. Addition of transarterial chemoembolization improves outcome of tyrosine kinase and immune checkpoint inhibitors regime in patients with unresectable hepatocellular carcinoma. *J Gastrointest Oncol* 2023; **14**: 1837-1848 [PMID: [37720446](#) DOI: [10.21037/jgo-23-486](#)]
- 35 **Guo Y**, Wu J, Liang L, Zhu K, Zhou J, Lin L, Chen Y, Cao B, He M, Lian H, Huang W, Cai M. Tyrosine-kinase inhibitor combined with iodine-125 seed brachytherapy for hepatocellular carcinoma refractory to transarterial chemoembolization: a propensity-matched study. *Cancer Imaging* 2023; **23**: 91 [PMID: [37749616](#) DOI: [10.1186/s40644-023-00604-4](#)]
- 36 **Yang Z**, Fu Y, Wu W, Hu Z, Pan Y, Wang J, Chen J, Hu D, Zhou Z, Chen M, Zhang Y. Comparison of hepatic arterial infusion chemotherapy with mFOLFOX vs. first-line systemic chemotherapy in patients with unresectable intrahepatic cholangiocarcinoma. *Front Pharmacol* 2023; **14**: 1234342 [PMID: [37731737](#) DOI: [10.3389/fphar.2023.1234342](#)]
- 37 **Huang P**, Huang X, Zhou Y, Yang G, Sun Q, Shi G, Chen Y. The Efficacy and Safety of Hepatic Arterial Infusion Chemotherapy Based on FOLFIRI for Advanced Intrahepatic Cholangiocarcinoma as Second-Line and Successive Treatment: A Real-World Study. *Can J Gastroenterol Hepatol* 2022; **2022**: 9680933 [PMID: [36199981](#) DOI: [10.1155/2022/9680933](#)]
- 38 **Takeda H**, Nishijima N, Nasu A, Komekado H, Kita R, Kimura T, Kudo M, Osaki Y. Long-term antitumor effect of lenvatinib on unresectable hepatocellular carcinoma with portal vein invasion. *Hepatol Res* 2019; **49**: 594-599 [PMID: [30499247](#) DOI: [10.1111/hepr.13294](#)]
- 39 **He Y**, Lin W, Cai Z, Huang Y, You M, Lei M, Chen R. Cost-effectiveness analysis of transarterial chemoembolization combined with lenvatinib as the first-line treatment for advanced hepatocellular carcinoma. *Front Pharmacol* 2023; **14**: 1219694 [PMID: [37745079](#) DOI: [10.3389/fphar.2023.1219694](#)]
- 40 **Qiu Q**, Wu C, Tang W, Ji L, Dai G, Gao Y, Chen E, Jiang H, Xie X, Zhang J. Development and validation of a risk-prediction model for immune-related adverse events in patients with non-small-cell lung cancer receiving PD-1/PD-L1 inhibitors. *J Zhejiang Univ Sci B* 2023; **24**: 935-942 [PMID: [37752094](#) DOI: [10.1631/jzus.B2200631](#)]
- 41 **Sun C**, Wang Q, Hou L, Zhang R, Chen Y, Niu L. A contrast-enhanced ultrasound-based nomogram for the prediction of therapeutic efficiency of anti-PD-1 plus anti-VEGF agents in advanced hepatocellular carcinoma patients. *Front Immunol* 2023; **14**: 1229560 [PMID: [37575236](#) DOI: [10.3389/fimmu.2023.1229560](#)]
- 42 **Glombicki SE**, Cohen PR. Sofosbuvir-Velpatasvir (Epclusa)-Associated Photosensitivity in a Hepatitis C Patient: Case Report and Review of Photosensitivity to Hepatitis C Antiviral Agents. *Cureus* 2021; **13**: e16496 [PMID: [34430111](#) DOI: [10.7759/cureus.16496](#)]
- 43 **Zhao SM**, Qiu LW, Zhao H, Gu WW, Yang XH, Gu ZX, Shi RF, Ni CF. Prognostic nomogram for hepatocellular carcinoma patients after transarterial chemoembolization based on des- γ -carboxy prothrombin reactivity and modified Response Evaluation Criteria in Solid Tumors. *J Cancer Res Ther* 2021; **17**: 707-714 [PMID: [34269303](#) DOI: [10.4103/jcrt.JCRT_651_20](#)]



Published by **Baishideng Publishing Group Inc**
7041 Koll Center Parkway, Suite 160, Pleasanton, CA 94566, USA

Telephone: +1-925-3991568

E-mail: office@baishideng.com

Help Desk: <https://www.f6publishing.com/helpdesk>

<https://www.wjgnet.com>

