

# World Journal of *Orthopedics*

*World J Orthop* 2024 April 18; 15(4): 310-385



**EDITORIAL**

- 310 Mortality rate after total knee arthroplasty or total hip arthroplasty in patients with a history of liver transplant  
*Rodriguez-Merchan EC*
- 312 Expandable endoprotheses in skeletally immature patients: Where we are  
*Öztürk R*
- 318 Effect of weight-adjusted antimicrobial antibiotic prophylaxis on postoperative dosage and surgical site infection incidence in total joint arthroplasty  
*Gupta A, Jain VK*

**ORIGINAL ARTICLE****Retrospective Cohort Study**

- 321 Investigation of contact behavior on a model of the dual-mobility artificial hip joint for Asians in different inner liner thicknesses  
*Hidayat T, Ammarullah MI, Ismail R, Saputra E, Lamura MDP, K N C, Bayuseno AP, Jamari J*

**Retrospective Study**

- 337 Effect of inflammatory response on joint function after hip fracture in elderly patients: A clinical study  
*Wang JM, Pan YT, Yang CS, Liu MC, Ji SC, Han N, Liu F, Sun GX*

**Observational Study**

- 346 Safety of tranexamic acid in surgically treated isolated spine trauma  
*Zahra W, Nayar SK, Bhadresha A, Jasani V, Aftab S*

**Prospective Study**

- 355 Long-term assessment of collagenase treatment for Dupuytren's contracture: A 10-year follow-up study  
*Passiatore M, Cilli V, Cannella A, Caruso L, Sassara GM, Taccardo G, De Vitis R*

**Basic Study**

- 363 Exercise promotes osteogenic differentiation by activating the long non-coding RNA H19/microRNA-149 axis  
*Zhou XC, Wang DX, Zhang CY, Yang YJ, Zhao RB, Liu SY, Ni GX*
- 379 Anatomic location of the first dorsal extensor compartment for surgical De-Quervain's tenosynovitis release: A cadaveric study  
*Thandoni A, Yetter WN, Regal SM*

**ABOUT COVER**

Peer Reviewer of *World Journal of Orthopedics*, Vaibhav Jain, MS, Assistant Professor, Surgeon, Department of Orthopaedics, Gandhi Medical College, Bhopal 462001, India. vaibhavjmc@gmail.com

**AIMS AND SCOPE**

The primary aim of *World Journal of Orthopedics* (*WJO*, *World J Orthop*) is to provide scholars and readers from various fields of orthopedics with a platform to publish high-quality basic and clinical research articles and communicate their research findings online.

*WJO* mainly publishes articles reporting research results and findings obtained in the field of orthopedics and covering a wide range of topics including arthroscopy, bone trauma, bone tumors, hand and foot surgery, joint surgery, orthopedic trauma, osteoarthropathy, osteoporosis, pediatric orthopedics, spinal diseases, spine surgery, and sports medicine.

**INDEXING/ABSTRACTING**

*WJO* is now abstracted and indexed in PubMed, PubMed Central, Emerging Sources Citation Index (Web of Science), Scopus, Reference Citation Analysis, China Science and Technology Journal Database, and Superstar Journals Database. The 2023 Edition of Journal Citation Reports® cites the 2022 impact factor (IF) for *WJO* as 1.9. The *WJO*'s CiteScore for 2022 is 2.6.

**RESPONSIBLE EDITORS FOR THIS ISSUE**

Production Editor: *Yu-Qing Zhao*; Production Department Director: *Xiang Li*; Cover Editor: *Jin-Lei Wang*.

**NAME OF JOURNAL**

*World Journal of Orthopedics*

**ISSN**

ISSN 2218-5836 (online)

**LAUNCH DATE**

November 18, 2010

**FREQUENCY**

Monthly

**EDITORS-IN-CHIEF**

Massimiliano Leigheb, Xiao-Jian Ye

**EXECUTIVE ASSOCIATE EDITORS-IN-CHIEF**

Xin Gu

**EDITORIAL BOARD MEMBERS**

<http://www.wjgnet.com/2218-5836/editorialboard.htm>

**PUBLICATION DATE**

April 18, 2024

**COPYRIGHT**

© 2024 Baishideng Publishing Group Inc

**PUBLISHING PARTNER**

The Minimally Invasive Spine Surgery Research Center Of Shanghai Jiaotong University

**INSTRUCTIONS TO AUTHORS**

<https://www.wjgnet.com/bpg/gerinfo/204>

**GUIDELINES FOR ETHICS DOCUMENTS**

<https://www.wjgnet.com/bpg/GerInfo/287>

**GUIDELINES FOR NON-NATIVE SPEAKERS OF ENGLISH**

<https://www.wjgnet.com/bpg/gerinfo/240>

**PUBLICATION ETHICS**

<https://www.wjgnet.com/bpg/GerInfo/288>

**PUBLICATION MISCONDUCT**

<https://www.wjgnet.com/bpg/gerinfo/208>

**POLICY OF CO-AUTHORS**

<https://www.wjgnet.com/bpg/GerInfo/310>

**ARTICLE PROCESSING CHARGE**

<https://www.wjgnet.com/bpg/gerinfo/242>

**STEPS FOR SUBMITTING MANUSCRIPTS**

<https://www.wjgnet.com/bpg/GerInfo/239>

**ONLINE SUBMISSION**

<https://www.f6publishing.com>

**PUBLISHING PARTNER'S OFFICIAL WEBSITE**

[https://www.shtrhospital.com/zkjs/info\\_29.aspx?itemid=647](https://www.shtrhospital.com/zkjs/info_29.aspx?itemid=647)



## Basic Study

# Anatomic location of the first dorsal extensor compartment for surgical De-Quervain's tenosynovitis release: A cadaveric study

Aditya Thandoni, William Nicholas Yetter, Steven Michael Regal

**Specialty type:** Orthopedics

**Provenance and peer review:**

Invited article; Externally peer reviewed.

**Peer-review model:** Single blind

**Peer-review report's scientific quality classification**

Grade A (Excellent): 0  
Grade B (Very good): 0  
Grade C (Good): 0  
Grade D (Fair): 0  
Grade E (Poor): 0

**P-Reviewer:** Gocmen-Mas N, Turkey

**Received:** November 28, 2023

**Revised:** February 7, 2027

**Accepted:** April 2, 2024

**Published online:** April 18, 2024



**Aditya Thandoni, William Nicholas Yetter, Steven Michael Regal**, Department of Orthopaedic Surgery, Allegheny Health Network, Pittsburgh, PA 15212, United States

**Corresponding author:** Aditya Thandoni, MD, Doctor, Researcher, Surgeon, Department of Orthopaedic Surgery, Allegheny Health Network, 320 E North Avenue, Pittsburgh, PA 15212, United States. [adityathandoni@gmail.com](mailto:adityathandoni@gmail.com)

## Abstract

### BACKGROUND

De-Quervain's tenosynovitis is a disorder arising from the compression and irritation of the first dorsal extensor compartment of the wrist. Patients who fail conservative treatment modalities are candidates for surgical release. However, risks with surgery include damage to the superficial radial nerve and an incomplete release due to inadequate dissection. Currently, there is a paucity of literature demonstrating the exact anatomic location of the first dorsal extensor compartment in reference to surface anatomy. Thus, this cadaveric study was performed to determine the exact location of the first extensor compartment and to devise a reliable surgical incision to prevent complications.

### AIM

To describe the location of the first dorsal compartment in relation to bony surface landmarks to create replicable surgical incisions.

### METHODS

Six cadaveric forearms, including four left and two right forearm specimens were dissected. Dissections were performed by a single fellowship trained upper extremity orthopaedic surgeon. Distance of the first dorsal compartment from landmarks such as Lister's tubercle, the wrist crease, and the radial styloid were calculated. Other variables studied included the presence of the superficial radial nerve overlying the first dorsal compartment, additional compartment sub-sheaths, number of abductor pollicis longus (APL) tendon slips, and the presence of a pseudo-retinaculum.

### RESULTS

Distance from the radial most aspect of the wrist crease to the extensor retinaculum was  $5.14 \text{ mm} \pm 0.80 \text{ mm}$ . The distance from Lister's tubercle to the distal aspect of the extensor retinaculum was  $13.37 \text{ mm} \pm 2.94 \text{ mm}$ . Lister's tubercle to the start of the first dorsal compartment was  $18.43 \text{ mm} \pm 2.01 \text{ mm}$ . The radial

styloid to the initial aspect of the extensor retinaculum measured  $2.98 \text{ mm} \pm 0.99 \text{ mm}$ . The retinaculum length longitudinally on average was  $26.82 \text{ mm} \pm 3.34 \text{ mm}$ . Four cadaveric forearms had separate extensor pollicis brevis compartments. The average number of APL tendon slips was three. A pseudo-retinaculum was present in four cadavers. Two cadavers had a superficial radial nerve that crossed over the first dorsal compartment and retinaculum proximally ( $7.03 \text{ mm}$  and  $13.36 \text{ mm}$ ).

## CONCLUSION

An incision that measures 3 mm proximal from the radial styloid, 2 cm radial from Lister's tubercle, and 5 mm proximal from the radial wrist crease will safely place surgeons at the first dorsal compartment.

**Key Words:** De-Quervain's tenosynovitis; First extensor compartment; Cadaveric study; Superficial radial nerve; Radial styloid; Lister's tubercle

©The Author(s) 2024. Published by Baishideng Publishing Group Inc. All rights reserved.

**Core Tip:** Surgical release of the first extensor compartment at the level of the wrist has been well documented with multiple different techniques. Injury to the superficial radial nerve, decompressing the incorrect compartment, tendon injury, and incomplete release of the compartment leads to patient morbidity. We describe the precise anatomic location of the first dorsal compartment in relation to bony surface landmarks to create replicable surgical incisions. We demonstrate the location of the superficial radial nerve and document the variances in the first compartment sub-sheaths. In doing so, we have created a surgical protocol that will ensure a complete first compartment release.

**Citation:** Thandoni A, Yetter WN, Regal SM. Anatomic location of the first dorsal extensor compartment for surgical De-Quervain's tenosynovitis release: A cadaveric study. *World J Orthop* 2024; 15(4): 379-385

**URL:** <https://www.wjgnet.com/2218-5836/full/v15/i4/379.htm>

**DOI:** <https://dx.doi.org/10.5312/wjo.v15.i4.379>

## INTRODUCTION

De-Quervain's tenosynovitis is a common pathology of the wrist resulting in thickening of the synovial sheath and extensor retinaculum containing the first dorsal extensor compartment[1]. Subsequent irritation of the first dorsal compartment, containing the abductor pollicis longus (APL) and extensor pollicis brevis (EPB) tendons, leads to radial sided wrist pain and inflammation[2]. Repetitive grasping and twisting motions of the hand and wrist leads to increased inflammation along with decreased functional use of the wrist. Initial non-operative management of De-Quervain's tenosynovitis includes the use of over-the-counter anti-inflammatory medications, supportive thumb spica bracing, and corticosteroid injections[3,4]. Failure of these conservative measures warrants surgical intervention[2-4].

Surgical release of the first extensor compartment is the standard of care following failure of conservative treatment modalities. Various surgical techniques have been described in the literature to ensure a complete release of the compartment. Prior studies have compared the efficacy of transverse *vs* longitudinal incisions to achieve a safe release of the compartment, with both techniques having their own risks and benefit profiles[5-8]. Novel techniques including ultrasound guided and percutaneous release of the first dorsal compartment have also been studied to ensure efficacy and safety[9,10]. However, surgical intervention does pose risk, mainly to the superficial radial nerve which courses in close proximity to the surgical incision. The literature has closely documented the course and associated branches of the superficial radial nerve, which can arise 1.5 cm-2 cm proximal to Lister's tubercle and 5 cm-8 cm from the radial styloid, placing great emphasis on meticulous care to avoid iatrogenic nerve injury during release of the tendon sheath[11-15].

Interestingly, multiple anatomic variants and sub-sheaths within the compartment itself can hinder a complete surgical release and resolution of clinical symptoms. Cadaveric studies have documented varying numbers of tendons and tendon slips of the APL in the first dorsal compartment[16-18]. Differing numbers of subsheaths and septi between tendons were found once the compartment was exposed, requiring further dissection to ensure a complete release of all constricting factors on the tendon sheath[18-20].

However, there is currently a paucity of literature that accurately demonstrates the exact anatomic location of the first dorsal compartment at the level of the wrist[21,22]. The inability to accurately replicate a reliable surgical incision into the first compartment places the superficial radial nerve at risk and may lead to inadequate releases based on sub-sheath variability. Therefore, the inability to create reproducible incisions intra-operatively can lead to unnecessary dissection into other extensor compartments, damage to surrounding neurovascular structures, increased operative time, and wound complications.

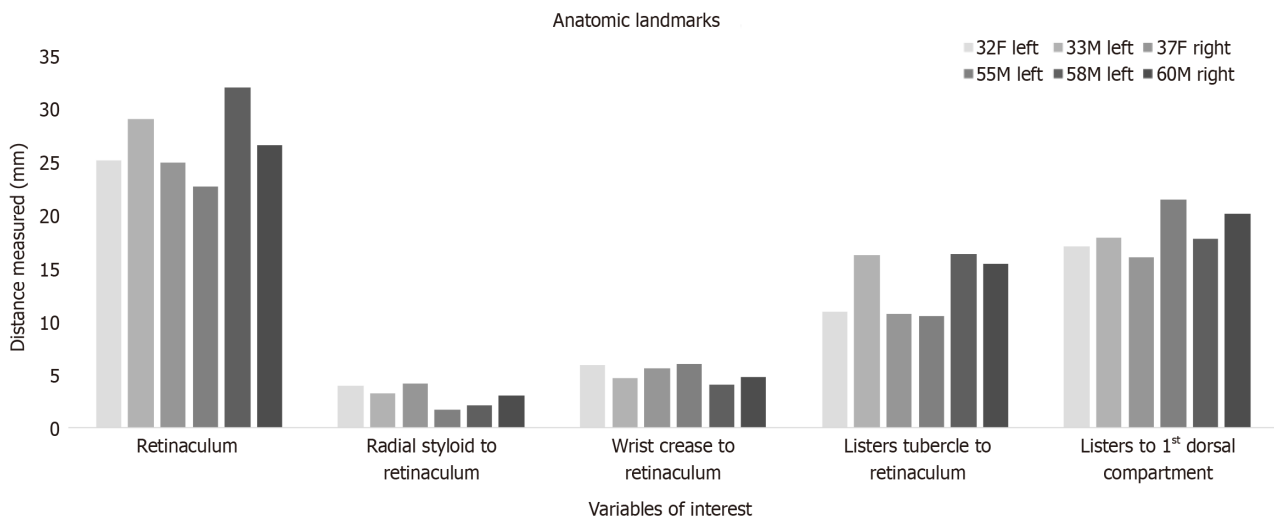
The aim of this study is to determine the precise anatomic location of the first dorsal compartment in relation to bony surface landmarks in order to create reliable and replicable surgical incisions. Secondary aims of this project are to document the location of the superficial radial nerve and to document the variances in the first compartment sub-sheaths. In doing so, our aim is to create a surgical protocol that will ensure a complete first compartment release without injury to

the surrounding neurovascular structures when treating De-Quervain's tenosynovitis.

## MATERIALS AND METHODS

Six cadaveric forearms were obtained to perform this study including four left and two right forearm specimens. All specimens included the entire forearm and hand from the proximal ulna to the fingertips. In total, four cadavers were male and two were female. All cadaver specimens were obtained from different individuals. Cadaver specifications included age ranges from thirty to sixty years of age. The two right forearm specimens were from a sixty-year-old male and a thirty-seven-year-old female specimen. Of the four left forearm specimens, three were from male cadavers while one forearm was from a female cadaver. The age ranges for the left forearm cadavers included a fifty-five-year-old male, fifty-eight-year-old male, thirty-three-year-old male, and a thirty-two-year-old female.

Inclusion criteria for our study included cadaver models within age ranges of 30-60 with no prior trauma history or surgical intervention to the wrist and hand region that would otherwise confound results from a soft tissue standpoint. Exclusion criteria included cadavers with prior history of wrist or hand surgical intervention. Cadavers with a history of surgical history including retained hardware, prior fractures, history of skin grafting, or soft tissue or bony trauma were excluded. All specimens included the entire forearm and hand from the proximal ulna to the fingertips. Any specimens with evidence of prior amputations related to trauma or vascular disease were excluded. Fresh frozen cadaveric forearms were thawed only once at which time all surgical dissections were undertaken (Figure 1). The cadaveric forearms were purchased using institutional research funding.



**Figure 1 Histogram demonstrating superficial landmark data points for six cadaveric specimens.** Each data bar demonstrates the value obtained for the cadaveric forearm specified in the legend provided. Notably, all variables do not demonstrate a significant outlier and maintain a close distribution of variables independent of laterality, age, and sex of the specimen. This demonstrates that the radial styloid, wrist crease, and Lister's tubercle are all reliable markers to use to determine the location of the first dorsal compartment.

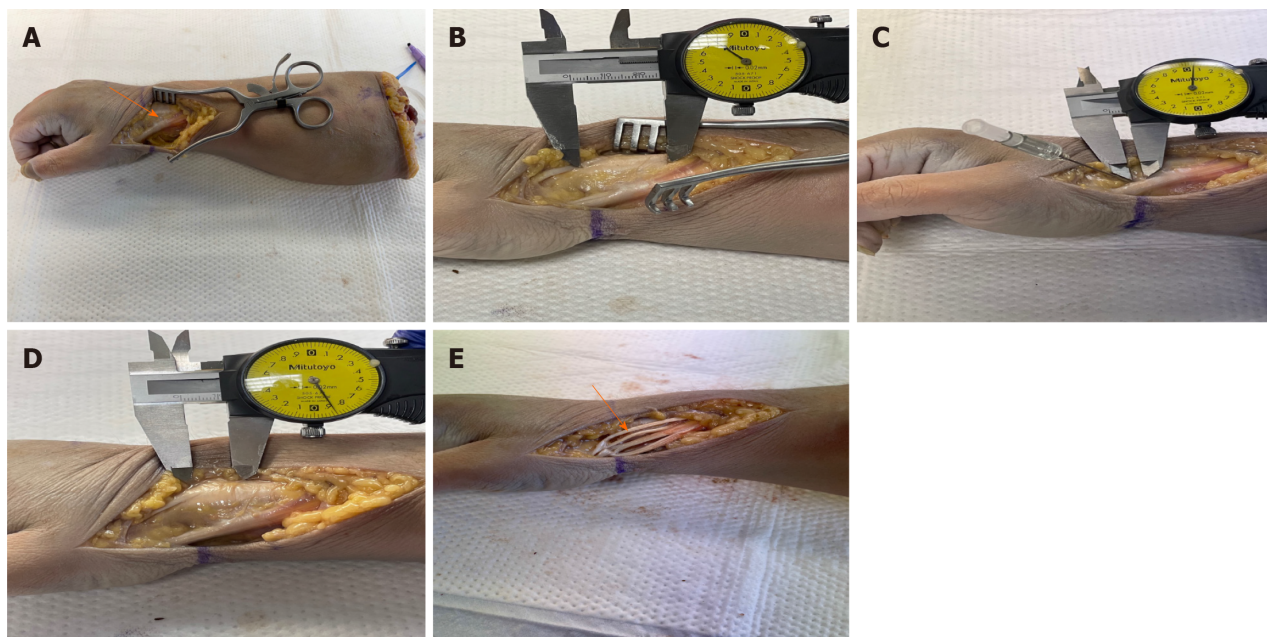
### Surgical technique

All cadaveric dissections and data measurements were performed by a single fellowship trained hand and upper extremity orthopaedic attending surgeon under loupe magnification. Dissection was performed in one sitting with all cadaveric arms having undergone the same timeframe of thawing. A longitudinal incision was used for all specimens centered dorsally over the radial styloid and extended proximally to ensure full exposure of all structures. Dissection was performed using a #15 scalpel to incise skin and dermis. Metzenbaum scissors were subsequently used to dissect subcutaneous tissues in order to identify structures such as the superficial radial nerve, the first dorsal compartment, and all associated sub-sheaths. The entire first dorsal compartment, extensor retinaculum, and available branches of the superficial radial nerve were identified and marked. After appropriate exposure was achieved, the pre-determined variables were measured using caliper instruments (Figure 2A-D).

### Variables of interest

Various data points were obtained to maximize a reproducible surgical site incision over the first dorsal compartment. The length of the distal phalanx of the thumb and the distance from the thumb distal interphalangeal joint to the tip of the digit were two topographical data points that were collected. Creating an incision centered over the first dorsal compartment based on those two measurements was analyzed to determine the proximity of those values to the extensor retinaculum. The overall length of the extensor retinaculum was obtained and served as a key measurement that allowed comparison measurements from other landmarks (Figure 2A). Other landmarks of interest included Lister's tubercle, the





**Figure 2 Cadaveric dissection.** A: Initial cadaveric dissection of the first dorsal compartment. Right forearm cadaver model with a longitudinal incision centered over the first dorsal extensor compartment. Superficial dissection through the subcutaneous fat was performed with a scalpel blade and Metzenbaum scissors. Deep dissection and retraction of the soft tissues demonstrates the underlying musculature and extensor retinaculum as shown by the black arrow; B: Full length view of the extensor retinaculum. Cadaveric dissection demonstrating the full extent of the extensor retinaculum. Caliper measurements were performed as demonstrated in this graphic. The average length of the extensor retinaculum from its proximal to its distal length was  $26.82 \text{ mm} \pm 3.34 \text{ mm}$ ; C: Deep dissection of the radial styloid and extensor retinaculum. Dissection demonstrating the most distal aspect of the radial styloid to the most distal aspect of the extensor retinaculum. An 18-gauge needle is used to mark the radial styloid process. The length from the radial styloid to the initial aspect of the extensor retinaculum measured  $2.98 \text{ mm} \pm 0.99 \text{ mm}$ ; D: Anatomic relationship shown between Lister's tubercle to the first dorsal extensor compartment. Lister's tubercle is seen marked by the most distal aspect of the caliper, while the first extensor compartment shown by the proximal caliper marker. The distance from Lister's tubercle to the proximal aspect of the retinaculum measured  $13.37 \text{ mm} \pm 2.94 \text{ mm}$  while distance from Lister's tubercle to the start of the first dorsal compartment was  $18.43 \text{ mm} \pm 2.01 \text{ mm}$ ; E: Multiple abductor pollicis longus (APL) tendon slips and sub-sheaths. Deep dissection into the first extensor compartment demonstrates multiple tendon slips of the APL tendon as shown by the black arrow. Four separate tendon slips are shown by the arrow, ultimately resulting in incomplete compartment release if not thoroughly dissected. The average number of APL tendon slips was three. A pseudo-retinaculum was also present in four out of six cadavers.

wrist crease, and the radial styloid. Obtaining distances from each of these landmarks to the extensor retinaculum were obtained to determine which data points reliably placed our incision over the first dorsal compartment (Figure 2B-D). Important other parameters that were documented included the presence or absence of the superficial radial nerve overlying the first dorsal compartment, additional compartment sub-sheaths, number of APL tendon slips, and the presence of a pseudoretinaculum (Figure 2E). All measurements were obtained using the same methodology in each cadaveric forearm.

### Statistical analysis

Cadaveric measurement data were analyzed using descriptive statistics. The mean, standard deviation and standard error values were calculated manually using standard equations. Confidence intervals were then computed manually using standard formulas prior to the creation of the data figures and tables. Statistical review of the study was performed by a biomedical statistical team at our home institution.

## RESULTS

Data points from all six cadavers were analyzed to determine the overall distribution of each variable of interest (Figure 1). Data gathered remained in proximity within each variable analyzed as no significant outliers were seen after histogram analysis (Figure 1). All measurements from the six cadavers were also averaged prior to comparison amongst the other data points. The average length of the thumb distal phalanx was  $30.11 \text{ mm} \pm 3.39 \text{ mm}$  while the average length of the distal phalanx crease to the tip of the digit was  $30.70 \text{ mm} \pm 3.74 \text{ mm}$ . The average length of the extensor retinaculum from its proximal to its distal length was  $26.82 \text{ mm} \pm 3.34 \text{ mm}$ . Therefore, the length from the thumb interphalangeal joint to the thumb tip gives a reasonable estimate of about 3 mm and can be used as a measurement to determine the overall length of the extensor retinaculum. The distance from the radial most aspect of the wrist crease to the retinaculum was  $5.14 \text{ mm} \pm 0.80 \text{ mm}$ . The distance from Lister's tubercle to the proximal aspect of the retinaculum measured  $13.37 \text{ mm} \pm 2.94 \text{ mm}$  while distance from Lister's tubercle to the start of the first dorsal compartment was  $18.43 \text{ mm} \pm 2.01 \text{ mm}$ . The length from the radial styloid to the initial aspect of the extensor retinaculum measured  $2.98 \text{ mm} \pm 0.99 \text{ mm}$  (Table 1).

**Table 1 Superficial landmarks and associated distance from the first dorsal compartment**

Anatomic landmarks	Mean (mm)	SD	N	SE	95%CI
Distal phalanx	30.11	3.39	6	1.38	(27.40-32.82)
Distal phalanx crease to tip of finger	30.70	3.74	6	1.52	(27.71-33.68)
Retinaculum	26.82	3.34	6	1.37	(24.14-29.49)
Radial styloid to retinaculum	2.98	0.99	6	0.40	(2.18-3.77)
Superficial radial nerve crossing proximal to retinaculum	10.20	4.48	2	3.17	(3.99-16.40)
Wrist crease to retinaculum	5.14	0.80	6	0.33	(4.50-5.78)
Listers tubercle to retinaculum	13.37	2.94	6	1.20	(11.02-15.73)
Listers tubercle to 1 <sup>st</sup> dorsal compartment	18.43	2.01	6	0.82	(16.82-20.04)
Separate EPB compartment	0.66	N/A	6	N/A	
Number of APL slips	3.00	0.63	6	0.26	(2.49-3.51)
Pseudo-retinaculum	N/A	N/A	4	N/A	

Various data points and anatomic landmarks obtained from the cadaveric dissection presented as averages for all specimens included in the study. The average length of the extensor retinaculum was 26.82 mm  $\pm$  3.34 mm. The distance from the radial most aspect of the wrist crease to the retinaculum was 5.14 mm  $\pm$  0.80 mm. The distance from Lister's tubercle to the proximal aspect of the retinaculum measured 13.37 mm  $\pm$  2.94 mm while distance from Lister's tubercle to the start of the first dorsal compartment was 18.43 mm  $\pm$  2.01 mm. The presence of a pseudo-retinaculum and separate extensor pollicis brevis compartments were only seen in 4 out of 6 cadavers. Average abductor pollicis longus slips in all cadavers was 3. Of note, the superficial radial nerve was only seen in two cadaver dissections. SD: Standard deviation; N: Sample size; SE: Standard error; CI: Confidence interval; EPB: Extensor pollicis brevis; APL: Abductor pollicis longus; N/A: Not available.

Only two cadavers had a superficial radial nerve that crossed over the first dorsal compartment. In two cadaver specimens, the superficial radial nerve was initially encountered at 7.03 mm and 13.36 mm proximal to the most proximal aspect of the extensor retinaculum. In both of those dissections, the superficial radial nerve was seen continuing its course directly dorsal over the extensor retinaculum and radial to the radial styloid. The superficial radial nerve was not encountered even with thorough dissection in the remaining four cadavers. Four out of six cadaveric forearms had a separate EPB compartments and sub-sheaths. The average number of APL tendon slips was three. A pseudo-retinaculum was also present in four out of six cadavers. A pseudo-retinaculum was not appreciated in cadavers that did not have a separate EPB sub-sheath (Table 1).

## DISCUSSION

De-Quervain's tenosynovitis warrants surgical intervention in patients who continue to suffer from significant wrist pain and decreased function after failing conservative modalities including physical therapy, anti-inflammatory medications, and corticosteroid injections. Surgical release of the first extensor compartment at the level of the wrist has been well documented with multiple different techniques implementing either longitudinal or transverse incisions. Risk of iatrogenic injury to the superficial radial nerve, decompressing the incorrect compartment, tendon injury, and incomplete release of the compartment can lead to significant patient morbidity. Currently, there has not been a documented reproducible incision that reliably places surgeons in the first dorsal compartment that ensures a safe and complete surgery.

Wilhelmi *et al* [23] demonstrated that the distance from the palmar digital crease to the proximal interphalangeal crease (mean, 2.42 cm  $\pm$  0.03 cm) correlated to the distance of the proximal edge of the A1 pulley from the digital palmar crease (mean, 2.45 cm  $\pm$  0.03 cm). They determined that surface landmark ratios can be a reliable and reproducible tool that can lead to successful A1 pulley release without complication in trigger finger surgery [23]. Hazani *et al* [21] performed a bony landmark cadaveric study that mapped out and demonstrated that the radial styloid is 0.32 cm  $\pm$  0.57 cm from the distal edge of the extensor retinaculum.

Our study demonstrated that the radial styloid was similarly only 2.98 mm  $\pm$  0.99 mm from the distal aspect of the retinaculum. Notably, we also noted that Lister's tubercle is only 13.37 mm  $\pm$  2.94 mm from the proximal aspect of the retinaculum and 18.43 mm  $\pm$  2.01 mm from the first compartment itself. The most radial aspect of the wrist crease is only about 5 mm distal to the retinaculum as well. The length from the thumb interphalangeal joint to the thumb tip provides an estimate of about 3 mm for the entire distance from the radial styloid to the end of the retinaculum. Thus, any incision extending 3 cm distal to the radial styloid will place the surgeon at end of the retinaculum, establishing a complete release. Ultimately, placing an incision 3 mm from the radial styloid, 2 cm from Lister's tubercle, and 5 mm from the radial wrist crease can be used to safely place the incision at the level of the first dorsal compartment.



Matzon *et al*[24] demonstrated the common presence of multiple APL slips in 78% of patients and found that 55% of patients had two subsheaths while 8% had three subsheaths. Kulthanan and Chareonwat[25] re-affirmed those results and demonstrated in contrast that the EPB had a single tendon in 98% of cases. Their study demonstrated that the APL had multiple slips in 89% of cases ( $P < 0.001$ )[25]. Our cadaver forearms had a mean of 3 separate APL slips, with multiple slips being present in each case. EPB sub-sheaths were present in 67% of our cadaveric cases. Therefore, we recommend a thorough evaluation intra-operatively to document and subsequently release all noted APL slips and to also release all EPB sub-sheaths as they will be present in the majority of cases. Being cognizant of this anatomic variant intra-operatively will allow for a full surgical release that can be accomplished during each case.

Importantly, Samarakoon *et al*[12] found that the superficial radial nerve branches 5.1 cm proximal to the radial styloid. They also found that the superficial radial nerve can branch 0.4 cm from the center of the first dorsal compartment and 1.6 cm from Lister's tubercle[12]. Gurses *et al*[11] found that the lateral dorsal digital branch to the thumb, off of the superficial radial nerve, coursed directly over the first dorsal compartment in 8 out of 20 cadavers. In our study, we found the superficial radial nerve present in close proximity in only 2 out of the 6 cadavers (7.03 mm and 13.36 mm proximal to the retinaculum). The other four dissections did not demonstrate a clear superficial radial nerve nearby our surgical site. However, if the superficial bony landmark measurements stated above are followed, we anticipate that the superficial radial nerve will not be encountered as unnecessary dissection will not be undertaken.

The main limitation of our study includes the small sample size. We were only able to perform six cadaveric dissections which limits the overall data points available for comparison to other studies and diminishes the overall generalizability to the general population. Ultimately, a higher sample size of cadaveric forearms could be dissected in the future to obtain a larger data set.

## CONCLUSION

Superficial landmarks are a reliable way to create a reproducible incision over the first dorsal compartment in order to obtain a complete release and protect the superficial radial nerve. Creating an incision that measures 3 mm proximal from the radial styloid, 2 cm proximal from Lister's tubercle, and 5 mm radial from the radial wrist crease will safely place surgeons at the level of the first dorsal compartment. Extending the incision 3 cm proximal to the radial styloid will fully encompass the extensor retinaculum and allow for a complete release. The APL tendon does reliably have multiple slips and the EPB does contain multiple sub-sheaths in the majority of cases, which are important anatomic variants to be cognizant of intra-operatively.

## FOOTNOTES

**Author contributions:** All authors contributed equally to this project; Thandoni A wrote the proposal, obtained funding for the cadavers and wrote the manuscript; Thandoni A and Yetter WN performed all data collection and analysis; Yetter WN and Regal SM made edits to the manuscript; Regal SM performed all cadaveric dissections, coordinated and designed the study; all authors approved the final version of the article.

**Institutional review board statement:** This study was a cadaveric investigation and did not involve human subjects; institutional review board approval was therefore not necessary for the research presented in this article. However, we will provide our institutional tissue approval protocol.

**Institutional animal care and use committee statement:** This study does not involve animal subjects.

**Conflict-of-interest statement:** The authors have no conflict of interests to disclose.

**Data sharing statement:** No additional data are available beyond what is presented in this manuscript.

**Open-Access:** This article is an open-access article that was selected by an in-house editor and fully peer-reviewed by external reviewers. It is distributed in accordance with the Creative Commons Attribution NonCommercial (CC BY-NC 4.0) license, which permits others to distribute, remix, adapt, build upon this work non-commercially, and license their derivative works on different terms, provided the original work is properly cited and the use is non-commercial. See: <https://creativecommons.org/licenses/by-nc/4.0/>

**Country/Territory of origin:** United States

**ORCID number:** Aditya Thandoni 0000-0001-5498-1586; William Nicholas Yetter 0000-0002-4700-942X; Steven Michael Regal 0000-0002-8276-4252.

**S-Editor:** Luo ML

**L-Editor:** A

**P-Editor:** Zhao YQ

## REFERENCES

- 1 **Patel KR**, Tadisina KK, Gonzalez MH. De Quervain's Disease. *Eplasty* 2013; **13**: ic52 [PMID: [23943679](#)]
- 2 **Goel R**, Abzug JM. de Quervain's tenosynovitis: a review of the rehabilitative options. *Hand (N Y)* 2015; **10**: 1-5 [PMID: [25762881](#) DOI: [10.1007/s11552-014-9649-3](#)]
- 3 **Ilyas AM**, Ast M, Schaffer AA, Thoder J. De quervain tenosynovitis of the wrist. *J Am Acad Orthop Surg* 2007; **15**: 757-764 [PMID: [18063716](#) DOI: [10.5435/00124635-200712000-00009](#)]
- 4 **Oh JK**, Messing S, Hyrien O, Hammert WC. Effectiveness of Corticosteroid Injections for Treatment of de Quervain's Tenosynovitis. *Hand (N Y)* 2017; **12**: 357-361 [PMID: [28644946](#) DOI: [10.1177/1558944716681976](#)]
- 5 **Gundes H**, Tosun B. Longitudinal incision in surgical release of De Quervain disease. *Tech Hand Up Extrem Surg* 2005; **9**: 149-152 [PMID: [16175118](#) DOI: [10.1097/01.bth.0000181105.24124.c0](#)]
- 6 **Ostic SA**, Martin WJ, Derman GH. Intersecting the intersection: a reliable incision for the treatment of de Quervain's and second dorsal compartment tenosynovitis. *Plast Reconstr Surg* 2007; **119**: 2341-2342 [PMID: [17519769](#) DOI: [10.1097/01.prs.0000261070.92579.f5](#)]
- 7 **Abresham SJ**, Karbasi MH, Zare J, Behnamfar Z, Tafti AD, Shishesaz B. De quervian tenosynovitis: clinical outcomes of surgical treatment with longitudinal and transverse incision. *Oman Med J* 2011; **26**: 91-93 [PMID: [22043391](#) DOI: [10.5001/omj.2011.23](#)]
- 8 **Poublon AR**, Kleinrensink GJ, Kerver A, Coert JH, Walbeehm ET. Optimal surgical approach for the treatment of Quervains disease: A surgical-anatomical study. *World J Orthop* 2018; **9**: 7-13 [PMID: [29468135](#) DOI: [10.5312/wjo.v9.i2.7](#)]
- 9 **Croutzet P**, Guinand R, Mares O, Aparid T, Candelier G, David I. Ultrasound-Guided de Quervain's Tendon Release, Feasibility, and First Outcomes. *J Wrist Surg* 2019; **8**: 513-519 [PMID: [31815068](#) DOI: [10.1055/s-0039-1678688](#)]
- 10 **Güleç A**, Türkmen F, Tokar S, Acar MA. Percutaneous Release of the First Dorsal Extensor Compartment: A Cadaver Study. *Plast Reconstr Surg Glob Open* 2016; **4**: e1022 [PMID: [27826460](#) DOI: [10.1097/GOX.0000000000001022](#)]
- 11 **Gurses IA**, Coskun O, Gayretli O, Kale A, Ozturk A. The relationship of the superficial radial nerve and its branch to the thumb to the first extensor compartment. *J Hand Surg Am* 2014; **39**: 480-483 [PMID: [24495622](#) DOI: [10.1016/j.jhsa.2013.12.004](#)]
- 12 **Samarakoon LB**, Lakmal KC, Thillainathan S, Bataduwaarachchi VR, Anthony DJ, Jayasekara RW. Anatomical relations of the superficial sensory branches of the radial nerve: a cadaveric study with clinical implications. *Patient Saf Surg* 2011; **5**: 28 [PMID: [22054296](#) DOI: [10.1186/1754-9493-5-28](#)]
- 13 **Suresh SS**, Zaki H. De quervain disease: Ibri technique to avoid superficial radial nerve injury. *Tech Hand Up Extrem Surg* 2009; **13**: 113-115 [PMID: [19516139](#) DOI: [10.1097/BTH.0b013e31819f6cdd](#)]
- 14 **Robson AJ**, See MS, Ellis H. Applied anatomy of the superficial branch of the radial nerve. *Clin Anat* 2008; **21**: 38-45 [PMID: [18092362](#) DOI: [10.1002/ca.20576](#)]
- 15 **Ikiz ZA**, Uçerler H. Anatomic characteristics and clinical importance of the superficial branch of the radial nerve. *Surg Radiol Anat* 2004; **26**: 453-458 [PMID: [15365770](#) DOI: [10.1007/s00276-004-0256-9](#)]
- 16 **Shiraishi N**, Matsumura G. Anatomical variations of the extensor pollicis brevis tendon and abductor pollicis longus tendon--relation to tenosynovectomy. *Okajimas Folia Anat Jpn* 2005; **82**: 25-29 [PMID: [15934601](#) DOI: [10.2535/ofaj.82.25](#)]
- 17 **Nam YS**, Doh G, Hong KY, Lim S, Eo S. Anatomical study of the first dorsal extensor compartment for the treatment of de Quervain's disease. *Ann Anat* 2018; **218**: 250-255 [PMID: [29746921](#) DOI: [10.1016/j.aanat.2018.04.007](#)]
- 18 **Sugiura S**, Matsuura Y, Kuniyoshi K, Nishikawa S, Toyooka T, Mori C, Suzuki T. Anatomic study of the first extensor compartment and the relationship between the extensor tendon width and its distal insertion. *Surg Radiol Anat* 2017; **39**: 1223-1226 [PMID: [28484860](#) DOI: [10.1007/s00276-017-1867-2](#)]
- 19 **Xu H**, Wu JX, Wang Q, Gao ZY. Anatomical variations in the first extensor compartment: a cadaver study. *ANZ J Surg* 2018; **88**: 913-916 [PMID: [30117658](#) DOI: [10.1111/ans.14808](#)]
- 20 **Lee ZH**, Stranix JT, Anzai L, Sharma S. Surgical anatomy of the first extensor compartment: A systematic review and comparison of normal cadavers vs. De Quervain syndrome patients. *J Plast Reconstr Aesthet Surg* 2017; **70**: 127-131 [PMID: [27693273](#) DOI: [10.1016/j.bjps.2016.08.020](#)]
- 21 **Hazani R**, Engineer NJ, Cooney D, Wilhelmi BJ. Anatomic landmarks for the first dorsal compartment. *Eplasty* 2008; **8**: e53 [PMID: [19092992](#)]
- 22 **Rousset P**, Vuillemin-Bodaghi V, Laredo JD, Parlier-Cuau C. Anatomic variations in the first extensor compartment of the wrist: accuracy of US. *Radiology* 2010; **257**: 427-433 [PMID: [20829530](#) DOI: [10.1148/radiol.10092265](#)]
- 23 **Wilhelmi BJ**, Snyder N 4th, Verbesey JE, Ganchi PA, Lee WP. Trigger finger release with hand surface landmark ratios: an anatomic and clinical study. *Plast Reconstr Surg* 2001; **108**: 908-915 [PMID: [11547146](#) DOI: [10.1097/00006534-200109150-00014](#)]
- 24 **Matzon JL**, Graham JG, Lutsky KF, Takei TR, Gallant GG, Beredjiklian PK. A Prospective Evaluation of the Anatomy of the First Dorsal Compartment in Patients Requiring Surgery for De Quervain's Tenosynovitis. *J Wrist Surg* 2019; **8**: 380-383 [PMID: [31579546](#) DOI: [10.1055/s-0039-1688700](#)]
- 25 **Kulthanan T**, Chareonwat B. Variations in abductor pollicis longus and extensor pollicis brevis tendons in the Quervain syndrome: a surgical and anatomical study. *Scand J Plast Reconstr Surg Hand Surg* 2007; **41**: 36-38 [PMID: [17484184](#) DOI: [10.1080/02844310600869720](#)]



Published by **Baishideng Publishing Group Inc**  
7041 Koll Center Parkway, Suite 160, Pleasanton, CA 94566, USA

**Telephone:** +1-925-3991568

**E-mail:** [office@baishideng.com](mailto:office@baishideng.com)

**Help Desk:** <https://www.f6publishing.com/helpdesk>

<https://www.wjgnet.com>

